

Nevus sebaceous of Jadassohn

Jadassohn'un nevüs sebaceusu

Enver Turan¹, Yavuz Yesilova¹, Hacer Altın Sürücü¹, Naime Eroglu¹

¹Harran University Faculty of Medicine, Department of Dermatology, 63200-Sanlıurfa, TURKEY

Yazışma adresi: Enver Turan, Harran Üniversitesi, Tıp Fakültesi Dermatoloji Anabilim Dalı, Tel: 0505 3323929 E-mail: enverturan@gmail.com

Geliş tarihi / Received: 03.01.2013

Kabul tarihi / Accepted: 23.08.2013

A 19-year-old healthy man presented with a new verrucous papules in a previously asymptomatic lesion that had been present on his left postauricular scalp since birth. The patient had no previous history of cutaneous or internal malignancies, and complete review of systems was negative. Physical examination of the scalp revealed a 10x5 cm pale-yellow verrucous plaque devoid of hair on the left post-auricular part of her scalp extending to the posterior part of auricula. Within this lesion there were multiple small (1–2 mm in diameter) verrucous firm nodules and multiple papillomatous lesion 2-4 mm in diameter (Fig. 1). There was no local or regional lymphadenopathy. Complete skin and lymph node examinations were otherwise unremarkable. Complete excision of the entire plaque was performed. Histopathological examination revealed the piece of skin to include a large papillomatous component that was related to hyperplasia with underlying sebaceous glands and prominent apocrine glands (Fig. 2). These are the features characterizing a sebaceous naevus. NS is considered as malformation with epidermal follicular, sebaceous and apocrine gland components (1). A wide variety of benign and malignant tumors have been described in association with nevus sebaceous. Syringocystadenoma papilliferum and trichoblastoma are the most common benign tumors associated with NS (2).

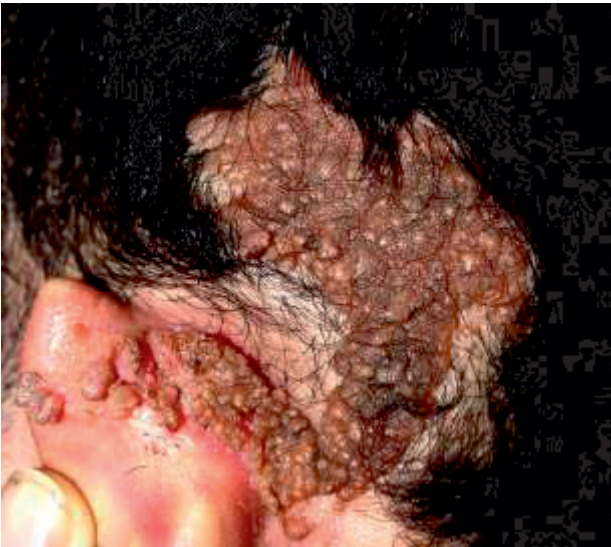

Figure 1: A 10x5 cm pale-yellow verrucous plaque devoid of hair on the left post-auricular part of her scalp

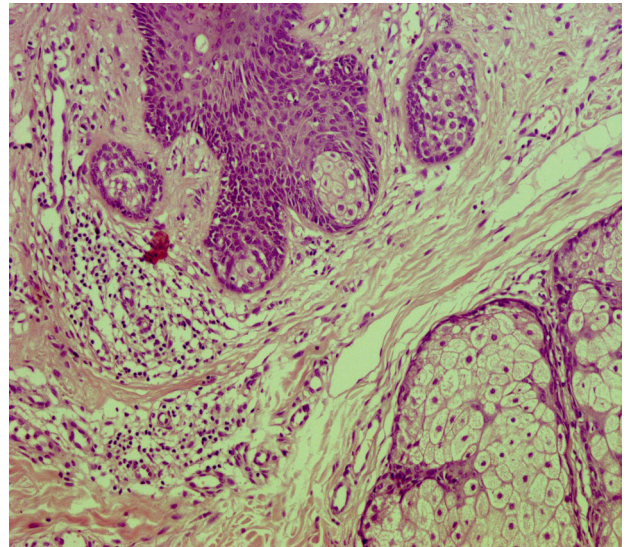


Figure 1: Hyperplasia with underlying sebaceous glands and prominent apocrine glands in dermis

Yazarlarla ilgili bildirilmesi gereken konular (Conflict of interest statement) : Yok (None)

Kaynaklar

1) Karnbach C, Neuber K, Diaz-Cascajo C, Steinkraus V. Syringocystadenoma papilliferum and trichoblastoma within a sebaceous nevus. *Hautarzt* 1998;49(8):654-6.

2) Manonukul J, Omeapinyan P, Vongjirad A. Mucoepidermoid (adenosquamous) carcinoma, trichoblastoma, trichilemmoma, sebaceous adenoma, tumor of follicular infundibulum and syringocystadenoma papilliferum arising within 2

persistent lesions of nevus sebaceous: report of a case. *Am J Dermatopathol* 2009;31(7):658-63