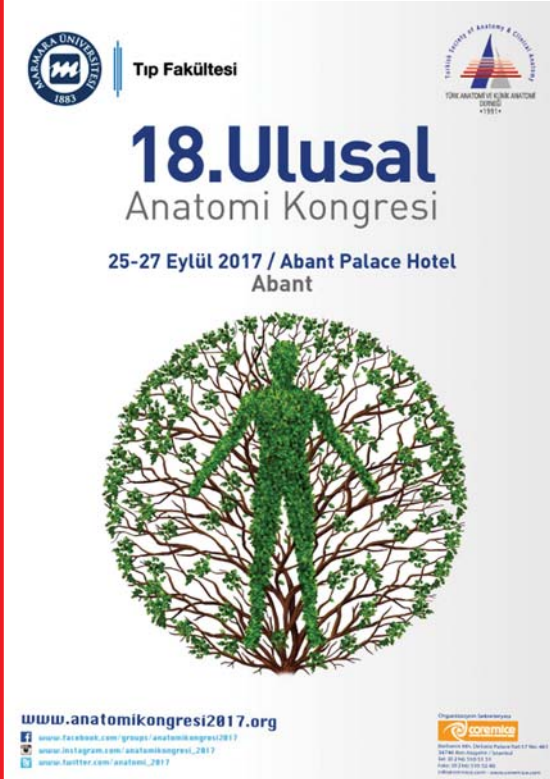


# anatomy

An International Journal of Experimental and Clinical Anatomy

Volume 11  
Supplement 2  
September 2017

Special Issue includes  
abstracts for the 18th National  
Anatomy Congress  
25–27 September 2017,  
Abant, Turkey



The poster for the 18th National Anatomy Congress is set against a white background. At the top left is the Ankara University logo (1853) and the text 'Tıp Fakültesi'. At the top right is the logo of the Turkish Society of Anatomy and Clinical Anatomy (1984). The main title '18. Ulusal Anatomi Kongresi' is in large blue font, with the dates and location '25-27 Eylül 2017 / Abant Palace Hotel Abant' below it. The central image is a circular silhouette of a human figure composed of green leaves and brown branches. At the bottom left, the website 'www.anatomikongresi2017.org' is listed along with social media links for Facebook, Instagram, and Twitter. At the bottom right, there is a 'Co-Organizer' logo and contact information for the organizing committee.

## Official Publication of the Turkish Society of Anatomy and Clinical Anatomy

### Aim and Scope

**Anatomy**, an international journal of experimental and clinical anatomy, is a peer-reviewed journal published three times a year with an objective to publish manuscripts with high scientific quality from all areas of anatomy. The journal offers a forum for anatomical investigations involving gross, histologic, developmental, neurological, radiological and clinical anatomy, and anatomy teaching methods and techniques. The journal is open to original papers covering a link between gross anatomy and areas related with clinical anatomy such as experimental and functional anatomy, neuroanatomy, comparative anatomy, modern imaging techniques, molecular biology, cell biology, embryology, morphological studies of veterinary discipline, and teaching anatomy. The journal is currently indexing and abstracting in TUBITAK ULAKBIM Turkish Medical Index, Proquest, EBSCO Host, Index Copernicus and Google Scholar.

### Publication Ethics

**Anatomy** is committed to upholding the highest standards of publication ethics and observes the principles of Journal's Publication Ethics and Malpractice Statement which is based on the recommendations and guidelines for journal editors developed by the Committee on Publication Ethics (COPE), Council of Science Editors (CSE), World Association of Medical Editors (WAME) and International Committee of Medical Journal Editors (ICMJE). For detailed information please visit the online version of the journal which is available at [www.anatomy.org.tr](http://www.anatomy.org.tr)

### Authorship

All persons designated as authors should have participated sufficiently in the work to take public responsibility for the content of the manuscript. Authorship credit should be based on substantial contributions to (1) conception and design or analysis and interpretation of data, (2) drafting of the manuscript or revising it for important intellectual content and, (3) final approval of the version to be published. The Editor may require the authors to justify assignment of authorship. In the case of collective authorship, the key persons responsible for the article should be identified and others contributing to the work should be recognized with proper acknowledgment.

### Copyright

Copyright © 2017, by the Turkish Society of Anatomy and Clinical Anatomy, TSACA. All rights reserved. No part of this publication may be reproduced, stored or transmitted in any form without permission in writing from the copyright holder beforehand, exceptionally for research purpose, criticism or review. The publisher and the Turkish Society of Anatomy and Clinical Anatomy assume no liability for any material published in the journal. All statements are the responsibility of the authors. Although all advertising material is expected to conform ethical standards, inclusion in this publication does not constitute a guarantee or endorsement of the quality or value of such product or of the claims made of it by its manufacturer. Permission requests should be addressed to the publisher.

### Publication Information

**Anatomy** (p-ISSN 1307-8798; e-ISSN 1308-8459) is published by Deomed Publishing, Istanbul, for the Turkish Society of Anatomy and Clinical Anatomy, TSACA. Due the Press Law of Turkish Republic dated as June 26, 2004 and numbered as 5187, this publication is classified as a periodical in English language.

### Ownership

On behalf of the Turkish Society of Anatomy and Clinical Anatomy, Ahmet Kağan Karabulut, MD, PhD; Konya

### Responsible Managing Editor

Nihal Apaydın, MD, PhD; Ankara

### Administrative Office

Güven Mah. Güvenlik Cad. Onlar Ap. 129/2 Aşağı Ayrancı, Ankara  
Phone: +90 312 447 55 52-53

### Publisher

Deomed Publishing  
Gür Sok. No:7/B Kadıköy, Istanbul, Turkey  
Phone: +90 216 414 83 43 (Pbx) / Fax: +90 216 414 83 42  
[www.deomed.com](http://www.deomed.com) / e-mail: [medya@deomed.com](mailto:medya@deomed.com)

### Submission of Manuscripts

Contributions should be submitted for publication under the following categories to:

Gülgün Şengül, MD  
Editor-in-Chief, *Anatomy*

Department of Anatomy,  
Faculty of Medicine, Ege University,  
35100, Bornova, Izmir, Turkey  
Phone: 0090 232 390 39 84  
Fax: 0090 232 342 21 42  
e-mail: [gulgun.sengul@gmail.com](mailto:gulgun.sengul@gmail.com); [gulgun.sengul@ege.edu.tr](mailto:gulgun.sengul@ege.edu.tr)

### Categories of Articles

• **Original Articles** describe substantial original research that falls within the scope of the Journal.

• **Teaching Anatomy** section contains regular or all formats of papers which are relevant to comparing teaching models or to introducing novel techniques, including especially the own experiences of the authors.

• **Reviews** section highlights current development in relevant areas of anatomy. The reviews are generally invited; other prospective authors should consult with the Editor-in-Chief.

• **Case Reports** include new, noteworthy or unusual cases which could be of help for basic notions and clinical practice.

• **Technical Note** articles cover technical innovations and developments with a specific technique or procedure or a modification of an existing technique. They should be sectioned like an original research article but not exceed 2000 words.

• **Viewpoint** articles give opinions on controversial topics or future projections, some of these are invited.

• **Historical View** category presents overview articles about historical sections from all areas of anatomy.

• **Terminology Zone** category is a platform for the articles which discuss some terminological controversies or opinions.

The categories above are peer-reviewed. They should include abstract and keywords. There are also categories including Letters to the Editor, Book Reviews, Abstracts, Obituary, News and Announcements which do not require a peer review process.

For detailed instructions concerning the submission of manuscripts, please refer to the Instructions to Authors.

### Subscription

Please send your order to Deomed Publishing, Gür Sok. No: 7/B Kadıköy, Istanbul, Turkey. e-mail: [aliko@deomed.com](mailto:aliko@deomed.com)

• **Annual rates:** Institutional 100 EUR, Individual 50 EUR (include postage and local VAT). Supplements are not included in the subscription rates.

Membership of the Turkish Society of Anatomy and Clinical Anatomy, TSACA includes a reduced subscription rate to this journal.

• **Change of address:** Please send to the publisher at least six weeks in advance, including both old and new addresses.

• **Cancellations:** Subscription cancellations will not be accepted after the first issue has been mailed.

The online version of this journal is available at [www.anatomy.org.tr](http://www.anatomy.org.tr)

### Advertising and Reprint Requests

Please direct to publisher. e-mail: [medya@deomed.com](mailto:medya@deomed.com)

### Printing and Binding

Birmat Press, Istanbul, Turkey, Phone: +90 212 629 05 59-60  
Printed in Turkey on acid-free paper (September 2017).

### Honorary Editor

**Doğan Akşit**, Ankara, Turkey

### Founding Editors

**Salih Murat Akkın**, Gaziantep, Turkey

**Hakan Hamdi Çelik**, Ankara, Turkey

### Former Editor-in-Chief &

#### Advising Editor

**Salih Murat Akkın**, Gaziantep, Turkey

### Editor-in-Chief

**Gülgün Şengül**, Izmir, Turkey

### Editors

**Nihal Apaydın**, Ankara, Turkey

**Kyung Ah Park**, Seoul, Korea

**George Paxinos**, Sydney, Australia

**Luis Puelles**, Murcia, Spain

**Mustafa F. Sargon**, Ankara, Turkey

**Ümit S. Şehirli**, Istanbul, Turkey

**Shane Tubbs**, Birmingham, AL, USA

**Emel Ulupınar**, Eskişehir, Turkey

### Associate Editors

**Vaclav Baca**, Prague, Czech Republic

**Çağatay Barut**, Istanbul, Turkey

**Jon Cornwall**, Dunedin, New Zealand

**Ayhan Cömert**, Ankara, Turkey

**Georg Feigl**, Graz, Austria

**Zeliha Kurtoğlu**, Mersin, Turkey

**Scott Lozanoff**, Honolulu, HI, USA

**Levent Sarıkçıoğlu**, Antalya, Turkey

**Cristian Stefan**, Boston, MA, USA

### Executive Board of Turkish Society of Anatomy and Clinical Anatomy

**Erdoğan Şendemir** (President)

**Emel Ulupınar** (Vice President)

**Ümit S. Şehirli** (Vice President)

**Esat Adigüzel** (Secretary General)

**Nihal Apaydın** (Treasurer)

**Gülgün Şengül** (Member)

**Ferruh Yücel** (Member)

### Scientific Advisory Board

**Peter H. Abrahams**  
Cambridge, UK

**Halil İbrahim Açar**  
Ankara, Turkey

**Esat Adigüzel**  
Denizli, Turkey

**Marian Adamkov**  
Martin, Slovakia

**Mustafa Aktekin**  
Istanbul, Turkey

**Serap Arbak**  
Istanbul, Turkey

**Mahindra Kumar Anand**  
Gujarat, India

**Doychin Angelov**  
Cologne, Germany

**Alp Bayramoğlu**  
Istanbul, Turkey

**Brion Benninger**  
Lebanon, OR, USA

**Susana Biasutto**  
Cordoba, Argentina

**Dragica Bobinac**  
Rijeka, Croatia

**David Bolender**  
Milwaukee, WI, USA

**Eric Brenner**  
Innsbruck, Austria

**Mustafa Büyükmumcu**  
Konya, Turkey

**Richard Halti Cabral**  
Sao Paulo, Brazil

**Safiye Çavdar**  
Istanbul, Turkey

**Katharina D'Herde**  
Ghent, Belgium

**Özlem Yılmaz**  
Izmir, Turkey

**Fabrice Duparc**  
Rouen, France

**Behice Durgun**  
Adana, Turkey

**İzzet Duyar**  
Istanbul, Turkey

**Mirela Eric**  
Novi Sad, Serbia

**Cumhur Ertekin**  
Izmir, Turkey

**Mete Ertürk**  
Izmir, Turkey

**Reha Erzurumlu**  
Baltimore, MD, USA

**Ali Fırat Esmer**  
Ankara, Turkey

**António José Gonçalves Ferreira**  
Lisboa, Portugal

**Quentin Fogg**  
Melbourne, Australia

**Christian Fontaine**  
Lille, France

**Rod Green**  
Bendigo, Australia

**Bruno Grignon**  
Nancy Cedex, France

**Nadir Gülekon**  
Ankara, Turkey

**Mürvet Hayran**  
Izmir, Turkey

**David Heylings**  
Norwich, UK

**Lazar Jeleu**  
Sofia, Bulgaria

**David Kachlik**  
Prague, Czech Republic

**Samet Kapakin**  
Erzurum, Turkey

**Ahmet Kağan Karabulut**  
Konya, Turkey

**Necdet Kocabıyık**  
Ankara, Turkey

**Cem Kopuz**  
Samsun, Turkey

**Mustafa Ayberk Kurt**  
Bursa, Turkey

**Piraye Kervancıoğlu**  
Gaziantep, Turkey

**Hee-Jin Kim**  
Seoul, Korea

**Marios Loukas**  
Grenada, West Indies

**Veronica Macchi**  
Padua, Italy

**Petru Matusz**  
Timisoara, Romania

**Bernard Moxham**  
Cardiff, Wales, UK

**Konstantinos Natsis**  
Thessaloniki, Greece

**Helen Nicholson**  
Dunedin, New Zealand

**Davut Özbağ**  
Malatya, Turkey

**P. Hande Özdinler**  
Chicago, IL, USA

**Adnan Öztürk**  
Istanbul, Turkey

**Mehmet Hakan Öztürk**  
Mersin, Turkey

**Friedrich Paulsen**  
Erlangen, Germany

**Wojciech Pawlina**  
Rochester, MN, USA

**Tuncay Veysel Peker**  
Ankara, Turkey

**Vid Persaud**  
Winnipeg, MB, Canada

**David Porta**  
Louisville, KY, USA

**Jose Ramon Sanudo**  
Madrid, Spain

**Tatsuo Sato**  
Tokyo, Japan

**Mohammadali M. Shoja**  
Birmingham, AL, USA

**Ahmet Sinav**  
Istanbul, Turkey

**Takis Skandalakis**  
Prague, Czech Republic

**Vildan Sümbüloğlu**  
Gaziantep, Turkey (*Biostatistics*)

**Muzaffer Şeker**  
Konya, Turkey

**Erdoğan Şendemir**  
Bursa, Turkey

**İbrahim Tekdemir**  
Ankara, Turkey

**Hironubu Tokuno**  
Tokyo, Japan

**Trifon Totlis**  
Thessaloniki, Greece

**Mehmet İbrahim Tuğlu**  
Manisa, Turkey

**Selçuk Tunalı**  
Ankara, Turkey

**Uğur Türe**  
Istanbul, Turkey

**Mehmet Üzel**  
Istanbul, Turkey

**Ivan Varga**  
Bratislava, Slovakia

**Tuncay Varol**  
Manisa, Turkey

**Charles Watson**  
Sydney, Australia

**Andreas H. Weiglein**  
Graz, Austria

**Bülent Yalçın**  
Ankara, Turkey

**M. Gazi Yaşargil**  
Istanbul, Turkey

**Hiroshi Yorifuji**  
Gunma, Japan

**Anatomy**, an international journal of experimental and clinical anatomy, is the official publication of the Turkish Society of Anatomy and Clinical Anatomy, TSACA. It is a peer-reviewed journal that publishes scientific articles in English. For a manuscript to be published in the journal, it should not be published previously in another journal or as full text in congress books and should be found relevant by the editorial board. Also, manuscripts submitted to *Anatomy* must not be under consideration by any other journal. Relevant manuscripts undergo conventional peer review procedure (at least three reviewers). For the publication of accepted manuscripts, author(s) should reveal to the Editor-in-Chief any conflict of interest and transfer the copyright to the Turkish Society of Anatomy and Clinical Anatomy, TSACA.

In the Materials and Methods section of the manuscripts where experimental studies on humans are presented, a statement that informed consent was obtained from each volunteer or patient after explanation of the procedures should be included. This section also should contain a statement that the investigation conforms with the principles outlined in the appropriate version of 1964 Declaration of Helsinki. For studies involving animals, all work must have been conducted according to applicable national and international guidelines. Prior approval must have been obtained for all protocols from the relevant author's institutional or other appropriate ethics committee, and the institution name and permit numbers must be provided at submission.

Anatomical terms used should comply with Terminologia Anatomica by FCAT (1998).

No publication cost is charged for the manuscripts but reprints and color printings are at authors' cost.

#### Preparation of manuscripts

During the preparation of the manuscripts, uniform requirements of the International Committee of Medical Journal Editors, a part of which is stated below, are valid (see ICMJE. Uniform requirements for manuscripts submitted to biomedical journals. Updated content is available at [www.icmje.org](http://www.icmje.org)). The manuscript should be typed double-spaced on one side of a 21x 29.7 cm (A4) blank sheet of paper. At the top, bottom and right and left sides of the pages a space of 2.5 cm should be left and all the pages should be numbered except for the title page.

Manuscripts should not exceed 15 pages (except for the title page). They must be accompanied by a cover letter signed by corresponding author and the Conflicts of Interest Disclosure Statement and Copyright Transfer Form signed by all authors. The contents of the manuscript (original articles and articles for Teaching Anatomy category) should include: 1- Title Page, 2- Abstract and Keywords, 3- Introduction, 4- Materials and Methods, 5- Results, 6- Discussion (Conclusion and/or Acknowledgement if necessary), 7- References

#### Title page

In all manuscripts the title of the manuscript should be written at the top and the full names and surnames and titles of the authors beneath. These should be followed with the affiliation of the author. Manuscripts with long titles are better accompanied underneath by a short version (maximum 80 characters) to be published as running head. In the title page the correspondence address and telephone, fax and e-mail should be written. At the bottom of this page, if present, funding sources supporting the work should be written with full names of all funding organizations and grant numbers. It should also be indicated in a separate line if the study has already been presented in a congress or likewise scientific meeting. Other information such as name and affiliation are not to be indicated in pages other than the title page.

#### Abstract

Abstract should be written after the title in 100–250 words. In original articles and articles prepared in IMRAD format for Teaching Anatomy category the abstract should be structured under sections Objectives, Methods, Results and Conclusion. Following the abstract at least 3 keywords should be added in alphabetical order separated by semicolons.

#### References

Authors should provide direct references to original research sources. References should be numbered consecutively in square brackets, according to the order in which they are first mentioned in the manuscript. They should follow the standards detailed in the NLM's Citing Medicine, 2nd edition (Citing medicine: the NLM style

guide for authors, editors, and publishers [Internet]. 2nd edition. Updated content is available at [www.ncbi.nlm.nih.gov/books/NBK7256](http://www.ncbi.nlm.nih.gov/books/NBK7256)). The names of all contributing authors should be listed, and should be in the order they appear in the original reference. The author is responsible for the accuracy and completeness of references. When necessary, a copy of a referred article can be requested from the author. Journal names should be abbreviated as in *Index Medicus*. Examples of main reference types are shown below:

- **Journal articles:** Author's name(s), article title, journal title (abbreviated), year of publication, volume number, inclusive pages

- *Standard journal article:* Sargon MF, Celik HH, Aksit MD, Karaagaoglu E. Quantitative analysis of myelinated axons of corpus callosum in the human brain. *Int J Neurosci* 2007;117:749–55.

- *Journal article with indication article published electronically before print:* Sengul G, Fu Y, Yu Y, Paxinos G. Spinal cord projections to the cerebellum in the mouse. *Brain Struct Funct Epub* 2014 Jul 10. DOI 10.1007/s00429-014-0840-7.

- **Books:** Author's name(s), book title, place of publication, publisher, year of publication, total pages (entire book) or inclusive pages (contribution to a book or chapter in a book)

- *Entire book:*

- *Standard entire book:* Sengul G, Watson C, Tanaka I, Paxinos G. Atlas of the spinal cord of the rat, mouse, marmoset, rhesus and human. San Diego (CA): Academic Press Elsevier; 2013. 360 p.

- *Book with organization as author:* Federative Committee of Anatomical Terminology (FCAT). Terminologia anatomica. Stuttgart: Thieme; 1998. 292 p.

- *Citation to a book on the Internet:* Bergman RA, Afifi AK, Miyauchi R. Illustrated encyclopedia of human anatomic variation. Opus I: muscular system [Internet]. [Revised on March 24, 2015] Available from: <http://www.anatomyatlases.org/AnatomicVariants/AnatomyHP.shtml>

- *Contribution to a book:*

- *Standard reference to a contributed chapter:* Potten CS, Wilson JW. Development of epithelial stem cell concepts. In: Lanza R, Gearhart J, Blau H, Melton D, Moore M, Pedersen R, Thomson J, West M, editors. Handbook of stem cell. Vol. 2, Adult and fetal. Amsterdam: Elsevier; 2004. p. 1–11.

- *Contributed section with editors:* Johnson D, Ellis H, Collins P, editors. Pectoral girdle and upper limb. In: Standring S, editor. Gray's anatomy: the anatomical basis of clinical practice. 29th ed. Edinburgh (Scotland): Elsevier Churchill Livingstone; 2005. p. 799–942.

- *Chapter in a book:*

- *Standard chapter in a book:* Doyle JR, Botte MJ. Surgical anatomy of the hand and upper extremity. Philadelphia (PA): Lippincott Williams and Wilkins; 2003. Chapter 10, Hand, Part 1, Palmar hand; p. 532–641.

#### Illustrations and tables

Illustrations and tables should be numbered in different categories in the manuscript and Roman numbers should not be used in numbering. Legends of the illustrations and tables should be added to the end of the manuscript as a separate page. Attention should be paid to the dimensions of the photographs to be proportional with 10x15 cm. Some abbreviations out of standards can be used in related illustrations and tables. In this case, abbreviation used should be explained in the legend. Figures and tables published previously can only be used when necessary for a comparison and only by giving reference after obtaining permission from the author(s) or the publisher (copyright holder).

#### Control list

- Length of the manuscript (max. 15 pages)
- Manuscript format (double space; one space before punctuation marks except for apostrophes)
- Title page (author names and affiliations; running head; correspondence)
- Abstract (100–250 words)
- Keywords (at least three)
- References (relevant to *Index Medicus*)
- Illustrations and tables (numbering; legends)
- Conflicts of Interest Disclosure Statement and Copyright Transfer Form
- Cover letter

# 18th National Anatomy Congress

## 25–27 September 2017, Abant, Turkey

### **Honorary Committee**

Prof. Dr. M. Emin Arat  
*Rector of Marmara University*  
Prof. Dr. Osman Hakan Gündüz  
*Dean of Medical Faculty of Marmara University*

### **Executive Committee of Turkish Society of Anatomy and Clinical Anatomy (TSACA-TAKAD)**

Prof. Dr. Erdoğan Şendemir  
Prof. Dr. Ümit S. Şehirli  
Prof. Dr. Emel Ulupınar  
Prof. Dr. Gülgün Şengül  
Prof. Dr. Esat Adıgüzel  
Prof. Dr. Nihal Apaydın  
Prof. Dr. Ferruh Yücel

### **Congress Co-Presidents**

Prof. Dr. Ümit S. Şehirli  
*Department of Anatomy, Faculty of Medicine, Marmara University, Istanbul, Turkey*  
Prof. Dr. Erdoğan Şendemir  
*Department of Anatomy, Faculty of Medicine, Uludağ University, Bursa, Turkey*

### **Congress Secretary**

Yrd. Doç. Dr. Ural Verimli  
*Department of Anatomy, Faculty of Medicine, Marmara University, Istanbul, Turkey*

### **Organizing Committee**

Prof. Dr. Ümit S. Şehirli  
Doç. Dr. Ömer Özdoğan  
Yrd. Doç. Dr. Ural Verimli  
Dr. Özlem Kirazlı  
Mazhar Özkan  
Sercan D. Yıldız  
Hatice Boracı

### **Scientific Committee**

All of the members of the "Turkish Society of Anatomy and Clinical Anatomy" are also members of the Scientific Committee of the Congress.



## Welcome Address of the Congress President

Anatomy 2017;11(Suppl 2):Sv ©2017 Turkish Society of Anatomy and Clinical Anatomy (TSACA)

Dear Colleagues,

18th National Anatomy Congress organized by Turkish Society of Anatomy and Clinical Anatomy (TSACA) will take place in Abant Palace Hotel, Abant, Bolu on the 25th to 27th of September 2017.

We have aimed at organizing a congress where the research conducted may be shared and scientific interactions may be taken to a more advanced level. We wish to see every one of our colleagues participating in anatomical research among us in our congress where opportunities to present a wide spectrum of anatomical studies from anatomy education to gross,

clinical and experimental anatomical research will sincerely be provided.

Apart from the scientific content of our congress where our huge family of Anatomy will be together, we believe our congress will consolidate our union and coalescence. We wish to meet you in one of our country's heavenly corners, in Abant, under an outstanding autumn sky, in search of science with its nature, in the nature.

Best regards,

**President of the Congress**

Prof. Dr. Ümit S. Şehirli





# 18th National Anatomy Congress

25–27 September 2017, Abant, Turkey

## 18. Ulusal Anatomi Kongresi

25–27 Eylül 2017, Abant, Türkiye

### Program

#### 25 Eylül 2017 Pazartesi

##### Salon A

15:30–16:00	<b>Açılış Konuşmaları ve Açılış Töreni</b>
16:00–17:00	<b>Açılış Konferansı</b> <b>Oturum Başkanları:</b> Prof. Dr. Salih Murat Akkın, Prof. Dr. Erdoğan Şendemir "Bu ne magnum evladım? – Foramen magnum hocam": Kişisel bir anatomi öyküsü Prof. Dr. Mehmet Bayramiçli
17:30–17:45	<b>Panel 1</b> <b>Oturum Başkanları:</b> Prof. Dr. Adnan Öztürk, Prof. Dr. Gülgün Şengül Hamse-i Şanizade Prof. Dr. Hakan Hamdi Çelik
17:45–18:15	Anatomiye adanmış bir beden: Cavit Cav Prof. Dr. Serap Şahinoğlu Kuş
	<b>Akşam Yemeği</b>

#### 26 Eylül 2017 Salı

##### Salon A

	<b>Sözlü Sunumlar (O-01–O-07)</b> <b>Oturum Başkanları:</b> Prof. Dr. Harun Ülger, Prof. Dr. Nigar Keleş
09:20–09:30	<b>O-01</b> Türkiye'deki beden bağışçılarının profili ve motivasyonları: İstanbul Üniversitesi deneyimi İlke Ali Gürses
09:30–09:40	<b>O-02</b> Eğitiminde kullanılan kadavra yaklaşım, ölü beden mahremiyeti ve etik I: Anatomi öğretim elemanlarının görüşleri Serdar Babacan
09:40–09:50	<b>O-03</b> Anatomi eğitiminde kullanılan kadavra yaklaşım, ölü beden mahremiyeti ve etik II: Uludağ Üniversitesi Tıp Fakültesi öğrencilerinin görüşleri Serdar Babacan
09:50–10:00	<b>O-04</b> Kadavra bağışında yeni yaklaşımlar: İnternet ve sosyal medya kullanımı Mazhar Özkan

10:00–10:10	O-05	Femoral troklear morfoloji ile ligamentum cruciatum anterius yırtığı ilişkisinin MR görüntüleri üzerinden değerlendirilmesi Sefa Işıklar
10:00–10:20	O-06	Tıp fakültesi öğrencilerinin benlik saygısı ve karar verme düzeylerinin anatomi ders başarısı üzerine etkisi Mehmet Emirzeoğlu
10:20–10:30	O-07	Kadavra bağıışı ile ilgili bir malpraktis olgusu Sedat Develi
10:30–10:45	<b>Wolters Kluwer</b>	
10:45–11:00	<b>Kahve Arası</b>	
11:00–12:00	<b>Panel 2</b> <b>Oturum Başkanları:</b> Prof. Dr. Kağan Karabulut, Prof. Dr. Ferruh Yücel Klinisyen bakış açısıyla madde bağıımlılıđı ve anatomik temelleri Prof. Dr. Arif Verimli	
12:00–13:00	<b>Öğle Yemeđi</b>	
13:00–13:30	<b>Panel 3: Laboratuvardan Kliniđe Parkinson Hastalıđı</b> <b>Oturum Başkanları:</b> Prof. Dr. Ayberk Kurt, Prof. Dr. Emel Ulupınar Basal çekirdeklerin anatomisi Prof. Dr. Ümit S. Şehirli	
13:30–14:00	Deneysel Parkinson modelleri Prof. Dr. Rezzan Gülhan	
14:00–14:30	Parkinson hastalıđı: Klinik bakış açısıyla Prof. Dr. Dilek Günal	
14:30–15:00	<b>Kahve Arası</b>	
15:00–15:10	<b>Sözlü Sunumlar (O-08–O-16)</b> <b>Oturum Başkanları:</b> Prof. Dr. Enis Uluçam, Prof. Dr. İhsaniye Coşkun	
15:00–15:10	O-08	Cinsiyet ve el tercihinin telencephalon morfolojisi üzerindeki etkilerinin difüzyon tensör görüntüleme yöntemi ile atlas temelli incelenmesi Güneş Aytaç
15:10–15:20	O-09	Her yönü ile plexus brachialis İsmihan İlknur Uysal
15:20–15:30	O-10	Sađlıklı bireylerde cerebellum hacminin yaş ve cinsiyete bađlı deđişiminin manyetik rezonans görüntüleriyle deđerlendirilmesi Sibel Ateşođlu
15:30–15:40	O-11	Müzisyenler ve müzisyen olmayanlar arasında serebral kortikal kalınlığın manyetik rezonans görüntüleme ile incelenmesi Niyazi Acer
15:40–15:50	O-12	Major depresif bozukluđu olan bireylerde beyin ventrikül hacimlerinin stereolojik yöntem ile deđerlendirilmesi Aslı Beril Karakaş
15:50–16:00	O-13	Corpus callosum multipl skleroz fare modelinde demiyelinizasyona yatkın bir alandır Serra Öztürk
16:00–16:10	O-14	Manyetik rezonans görüntülerinde karpal tünel sendromlu hastalarda nervus medianus alanının deđerlendirilmesi Gürsel Ak Güven
16:10–16:20	O-15	Sıçanda pedunculus cerebellaris superior ve pedunculus cerebellaris medius aracılıđıyla serebello-hipotalamik yollar Merve Özgür
16:20–16:30	O-16	Melatoninin üreme üzerine olan etkisi Yasemin Behram Kandemir
19:30	<b>Gala Yemeđi – Cenk Eren ile Türk Sanat Musikisi</b>	

**Salon B****Sözlü Sunumlar (O-17–O-24)****Oturum Başkanları:** Prof. Dr. Safiye Çavdar, Prof. Dr. Ufuk Bayram Şakul

09:20–09:30	<b>O-17</b>	Foramen sphenopalatina'nın sinir bloğu açısından morfolometrik değerlendirilmesi Sedat Develi
09:30–09:40	<b>O-18</b>	Donuk omuz anatomisi Burcu Erçakmak
09:40–09:50	<b>O-19</b>	İkinci ve dördüncü parmak oranının (2P:4P) tip 2 diabetes mellitus ile ilişkisi Ramazan Fazıl Akkoç
09:50–10:00	<b>O-20</b>	Articulatio cubiti'nin biyomekaniği ve valgus açısı Ceren Güneç Beşer
10:00–10:10	<b>O-21</b>	Bisfenol A'nın fetal kemik gelişimi üzerine teratojenik etkilerinin araştırılması Emre Atay
10:10–10:20	<b>O-22</b>	Akrilamitin 5RP7 fibroblast hücrelerindeki etkilerinin kaspaz ve anneksin V testleri, hücre siklus analizi, elektron ve konfokal mikroskopu ile değerlendirilmesi Sedat Kacar
10:20–10:30	<b>O-23</b>	Diş hekimliği fakültesi öğrencilerinin anatomi eğitimine bakış açıları Zümrüt Doğan
10:30–10:40	<b>O-24</b>	Cerrahi sonrası lumbal bölge kaslarının boyutlarındaki değişimin MRG ile incelenmesi Fatma Duman

10:40–11:00 **Kahve Arası**12:00–13:00 **Öğle Yemeği****Sözlü Sunumlar (O-25–O-30)****Oturum Başkanları:** Prof. Dr. Mehmet Emirzeoğlu, Prof. Dr. Hülya Gürbüz

13:00–13:10	<b>O-25</b>	Ol tışın çıkırttı Hüseyin Avni Balcıoğlu
13:10–13:20	<b>O-26</b>	Türk toplumundaki cartilago triticea prevalansının belirlenmesi Alper Vatansever
13:20–13:30	<b>O-27</b>	Sublingual varisler ile ilişkili faktörler: Tanımlayıcı klinik araştırma Nursel Akkaya
13:30–13:40	<b>O-28</b>	İnsan fetuslerinde latissimus dorsi'nin flep cerrahisi açısından morfolometrik özellikleri Orhan Beger
13:40–13:50	<b>O-29</b>	İnsan fetüslerinde üst ekstremite kas gelişiminin mikroskopik yöntem ile araştırılması Gizem Çizmeci
13:50–14:00	<b>O-30</b>	İnsan fetüslerinde lumbrikal kasların inervasyon paterni Betül Asena Kara

**Sözlü Sunum (O-31)****Oturum Başkanları:** Prof. Dr. Muzaffer Sindel, Prof. Dr. İlknur Arı

14:00–14:30	<b>O-31</b>	Sinir sisteminde yaşlılığa bağlı değişiklikler ve sağlıklı-mutlu yaşlanma Prof. Dr. Behice Durgun
-------------	-------------	------------------------------------------------------------------------------------------------------

14:30–15:00 **Kahve Arası****Sözlü Sunumlar (O-32–O-39)****Oturum Başkanları:** Prof. Dr. Nurettin Oğuz, Prof. Dr. Erdoğan Unur

15:00–15:20	<b>O-32</b>	Akılcı ilaç kullanımı Prof. Dr. Rezzan Gülhan
15:20–15:30	<b>O-33</b>	Polyesterizasyon Yahya Tahta

15:30–15:40	<b>O-34</b>	Ayağın inversiyon yaralanmalarında ligamentum talofibulare anterius ve ligamentum calcaneofibulare'nin fonksiyonel anatomik önemi ve klinik olarak değerlendirilmesi Selda Yıldız
15:40–15:50	<b>O-35</b>	Antropometrik vücut ölçümlerinin statik denge parametreleri üzerine etkisinin incelenmesi: Ön çalışma sonuçlarımız Ayfer Metin Telliöglü
15:50–16:00	<b>O-36</b>	Intercoccygeal açı ile coccyx tipleri ve cinsiyet arasındaki ilişki Engin Çiftcioğlu
16:00–16:10	<b>O-37</b>	Tibia distalinin intraosseöz kanülasyon teknikleri açısından değerlendirilmesi Sedat Develi
16:10–16:20	<b>O-38</b>	Sığır'da ve koçta testisi besleyen arteria testicularisin anatomisinin plastik enjeksiyon ve korrozyon metoduyla incelenmesi Yahya Tahta
16:20–16:30	<b>O-39</b>	Lumbar intervertebral disk hernili ve bel ağrılı hastaların karşılaştırmalı basit bir morfometrik analizi Seda Avnioğlu
19:30	<b>Gala Yemeği – Cenk Eren ile Türk Sanat Musikisi</b>	

## 27 Eylül 2017 Çarşamba

### Salon A

#### Sözlü Sunumlar (O-40–O-43)

**Oturum Başkanları:** Prof. Dr. Bikem Süzen, Prof. Dr. Ahmet Uzun

09:30–09:40	<b>O-40</b>	Mersin anatomi laboratuvarında formaldehit maruziyetini azaltma çabaları ve güncellenmiş spesifik havalandırma sistemi bileşenlerine ilişkin deneyimler Zeliha Kurtoğlu
09:40–09:50	<b>O-41</b>	Anatomide en sık kullanılan istatistiksel yöntemler Fikri Özdemir
09:50–10:00	<b>O-42</b>	Yardımcı sağlık personelinin "anatomi eğitimi"ne bakışının değerlendirilmesi Turgay Karataş
10:00–10:10	<b>O-43</b>	Ondokuz Mayıs Üniversitesi Tıp Fakültesi eğitimcilerin eğitimi kurslarına katılan öğretim üyelerinin eğitici yeterlikleri ve eğitsel gereksinimleri ile ilgili algıları Engin Çiftcioğlu

10:10–10:30 **Kahve Arası**

#### Sözlü Sunumlar (O-44–O-46)

**Oturum Başkanları:** Prof. Dr. Aslı Aktan İkiz, Prof. Dr. Oğuz Taşkınalp

10:30–10:50	<b>O-44</b>	Anatomi için biyomedikal, biyomedikal için anatomi Prof. Dr. Ahmet Usta
10:50–11:00	<b>O-45</b>	3 boyutlu yazıcılar anatomi eğitiminde kullanılabilir mi? Serkan Özgür
11:00–11:10	<b>O-46</b>	Cerrahi önemi olan varyasyonları içeren farklı temporal kemik tiplerinin modellenmesi ve 3 boyutlu yazıcılar aracılığı ile üretilmesi Mehmet Ali Güner

#### Sözlü Sunum (O-47)

**Oturum Başkanları:** Prof. Dr. İlknur Uysal, Prof. Dr. Ayşin Kale

11:10–11:40	<b>O-47</b>	Spinal precerebellar nucleus'lar: Yeni bir tanımlama Prof. Dr. Gülgün Şengül
-------------	-------------	---------------------------------------------------------------------------------

11:40–12:10 **Kapanış**

**Öğle Yemeği**

# Abstracts for the 18th National Anatomy Congress 25–27 September 2017, Abant, Turkey

Anatomy 2017;11(Suppl 2):S93–S153 ©2017 Turkish Society of Anatomy and Clinical Anatomy (TSACA)

## Opening Lecture (OL-1)

### OL-1

#### **“What magnum is this, son?” “Foramen magnum, sir”: a personal anatomy tale**

Bayramiçli M

*Marmara University, School of Medicine, Department of Plastic and Reconstructive Surgery, Istanbul, Turkey*

My first encounter with anatomy was through my mother’s 1939 print anatomy atlas. After many years, I entered the medical school and I studied anatomy with that 1939 print Sobotta Atlas of Anatomy. At that time I thought “ Nothing would change in anatomy anyways”. Through my studies as a medical student, being a surgeon was my whole idea and I realized the significance of solid anatomy knowledge on the path to be a prominent surgeon. Thereafter, I started Plastic and Reconstructive Surgery residency and I realized it was not enough to have a solid anatomy knowledge to be a successful surgeon, but also more than what is taught should be learned. I had the opportunity to perform dissections in Cerrahpaşa Medical School Anatomy Lab for 4 years by the courtesy of Prof. Dr. Orhan Kuran whom I always cherish with my deepest respect. This was one of the greatest opportunities of my career as a surgeon. Thanks to these studies, I had the chance to learn the surgical procedures which would be found very difficult to comprehend by others in my residency years. Furthermore, in my fresh years as a specialist, I managed to improve new flap models first in the literature thanks to my previous anatomy studies.

My specialty, Plastic and Reconstructive Surgery, is distinct from other surgical specialties at one major point: it is related to every part of the human body with no exceptions in age or gender. It does not deal with a limited anatomical region, organ or

system and it requires anatomical knowledge for every system and region. Furthermore, the anatomy background required to improve surgical techniques and mastery should be improved by the surgeon himself. In brief, my residency has been based on the anti-thesis of my concepts as a medical student and became: “Anatomy knowledge changes, improves and gets more and more detailed.....!”

The years of my residency training and the fresh years of being a specialist were the times when vast improvements of topographic anatomy took place. This was a period of change and progression when Ian Taylor proposed and solidified the angiosome concept and Radiological Anatomy studies were accelerating apart from topographic anatomy advances. The reflection of these changes to my clinical practice was progression of microsurgery to a very different dimension. While I was working in the US, I came across with another opportunity. I encountered a very different concept of research for the first time, thanks to my World-wide known supervisor Ian T. Jackson, both in clinical and laboratory studies which I had never seen in my homeland. The scientific products of this era resulted in scientific articles and books.

Following my return to Turkey, the determining aid to my clinical studies was anatomy again. Thanks to the hard working and productive members of Marmara University, School of Medicine, Anatomy Department, creating new concepts were made possible. But there was a very significant obstacle: Fresh cadavers..! A very difficult to access requirement. Furthermore, radiology was recognized as a very important asset for anatomical studies, but coordination was an issue.

In this period of time, I made a dear friend in Köln University via Prof. Dr. Salih Murat Akkın, to pursue fresh cadaver studies:

Prof. Dr. Jürgen Koebke, better with his beloved nickname Big Brother Koebke. A real friend, a very valued scientist and a brilliant teacher. Through the resources he provided, I was able to finalize a study concerning the venous anatomy of the mammarys. Afterwards, together with a massive Cerrahpaşa team, we visited Köln again and prepared a “flap dissection course” on fresh cadavers. The untimely loss of big brother Koepke inflicted a huge pain on us then.

My greatest love in my career has always been reconstructive microsurgery and the inseparable sibling of reconstructive microsurgery is always anatomy. As the years passed by, the reliance and rate of esthetic surgery in my surgical practice started to rise, but the significance of anatomy never evaded. We had several opportunities for organizing fresh cadaver courses under the umbrella of Esthetic and Plastic Surgery Association which I served as the president for a period. Four in Vienna University Medical School, Anatomy Department, two in Bahçeşehir University Medical School Laboratory, I had the opportunity to participate in the fresh cadaver courses as an organizer and a lecturer. Finally the fresh cadaver course organized by Turkish

Plastic Reconstructive and Esthetic Surgery Association which took place in Trakya University Medical School in Edirne, was added to the forementioned courses.

At this point we have reached today, clinical anatomy training is registered as the inseparable part of my clinical specialty, but anatomy education is not limited to this and should never be. Anatomy should not be programmed as a mere lecture to be passed in medical school training. Apart from the need for a much more detailed anatomical knowledge for surgical specialties, it is essential to implement anatomy training to certain surgical specialties and specialized surgical techniques. To pursue this figure, I have observed in my clinical practice that the necessity of actions to improve technical hardware and to enrich the curricular programs of anatomy education should immediately take place. This observation, to my understanding, is widely shared in the late years with my colleagues. To this extend, Marmara University School of Medicine is a fortunate institution and I hope to find more scopes, together with Prof. Dr. Ümit Şehirli, to implement anatomy education more into the clinical practice.

# Panel Sessions

(PS-1 — PS-6)

## Panel 1

### PS-1

#### Hamse-i Şanizade

Akşit MD<sup>1</sup>, Aldur MM<sup>2</sup>, Çelik HH<sup>2</sup>, Şeker M<sup>3</sup>

<sup>1</sup>Professor Emeritus, Department of Anatomy, Faculty of Medicine, Hacettepe University, Ankara, Turkey; <sup>2</sup>Department of Anatomy, Faculty of Medicine, Hacettepe University, Ankara, Turkey; <sup>3</sup>Department of Anatomy, Meram Faculty of Medicine, Necmettin Erbakan University, Konya, Turkey

Şanizade Atullah Mehmed Efendi was one of the most important scientists in the Ottoman Empire in the first half of the 19th century. He was educated in either the classical medrese (Süleymaniye) or in the school of engineering in Istanbul. He translated and authored numerous books on medicine, history, mathematics, literature and geography, rendering him one of the most important turning points of Ottoman-Turkish medicine on the path to modernization. He worked as a clinician and also as a doctrinaire. He became a pioneer in the establishment of modern medicine in our country with his solitary but courageous steps. His work Hamse-i Şanizade (Kanun-i Şanizade) (five books of Şanizade) contains anatomy (Miratü'l Ebdan fi Teşrih-i Azaü'l İnsan – Mirror of the Bodies in the Dissection of the Members of the Human Body), physiology, pathology, surgery and pharmacopoeia. The first three of these books were printed in the Ottoman Empire at the order of Sultan Mahmud II in Istanbul in 1820. This is accepted as the first printed medical book in Turkey. After the renaissance period, the most important scientist of the Turkish Empire, Şanizade Atullah Mehmet Efendi, is counterpart of Leonardo da Vinci in the West.

**Keywords:** anatomy, Hamse-i Şanizade, history

### PS-2

#### A body dedicated to anatomy: Cavit Cav

Şahinoğlu Kuş S

Department of Medical History and Ethics, Faculty of Medicine, Ankara University, Ankara, Turkey

A first in Ankara University, Medical faculty, Anatomy Department, the life of the national athlete and businessman, Cavit Cav, who donated his body to the Anatomy department, Ankara University for educational purposes is presented. The main reason to begin this study was the skeleton of Cavit Cav in Anatomy Department laboratory. Private meetings were held

with some members of the Anatomy department and Rahşan Fieber, Cavit Cav's daughter. Both information from the archives of the department as well as the autobiography given by his daughter were scrupulously examined. Information from his autobiography had been archived in the Anatomy Department and this was checked alongside the information his daughter had provided. Cavit Cav, who lived between 1905 and 1982, was a successful national athlete and businessman. He had given importance to science and had been contentious and entrepreneurial all his life long. Documents regarding his lifetime and body donation process have been obtained. In the last period of his life, he had donated his body to Ankara University Medical Faculty to contribute to medical education with his own will and wanted his skeleton be used for educational purposes as well. Throughout history, the bodies used for dissection have often been bodies of prisoners, orphans and similar who have been removed from society. But Cavit Cav was an exception, as he was a leading person whose contribution to the field of anatomy and medical education in Turkey was invaluable.

**Keywords:** anatomy, body donation, Cavit Cav

## Panel 2

### PS-3

#### Neuroanatomical basis of addiction from a clinician's point of view

Verimli A

Istanbul, Turkey

Reward is a key factor for driving incentive-based learning, appropriate responses to stimuli, and the development of goal-directed behavior. Reward circuitry is going to be summarized here in order to comprehend the basics of addiction since this complex circuitry forms a neural substrate for addiction and related disorders. Despite the drugs of abuse are structurally and functionally diverse and produce a variety of behavioral effects, they clearly modulate the brain reward system. Drugs of abuse, like all stimulations of the reward system, tend to activate the dopaminergic neurons projecting inside medial fore-brain bundle, stating the significance of connections among anatomical centers such as ventral striatum, ventral tegmental area (VTA) and septal area. These substances of abuse increase dopaminergic transmission from the VTA to the nucleus accumbens in acute effect, but, with chronic intake, the dopaminergic system is impaired. Dopamine D2 receptors are down-regulated, and dopamine function is reduced, particular-

ly in the ventral striatum. The result of dopamine receptor down-regulation is that natural rewards or stimuli become less effective possibly causing the depressive symptoms seen in withdrawal. It is very essential to understand the basic neuroanatomy and neurophysiology of addiction to have a solid background in clinical interventions to treat these patients. In this lecture, the basics of clinical point of view towards addiction will be taken into account from its neuroanatomical foundations and will be expanded to the concepts where these basic anatomical components serve us to explore clinical answers to this catastrophic disorder.

**Keywords:** addiction, clinics, neuroanatomy, neurophysiology, reward

### Panel 3

#### PS-4

##### Anatomy of basal ganglia

Şehirli ÜS

*Department of Anatomy, Faculty of Medicine, Marmara University, Istanbul, Turkey*

Basal ganglia are a collection of masses of gray matter situated within the each cerebral hemisphere. Corpus striatum, substantia nigra, subthalamic nucleus and ventral tegmental area are accepted as basal ganglia and related structures. The circuit of basal ganglia is important to understand the pathological process affecting these structures. The input nuclei of basal ganglia are caudate and putamen and the output nuclei are globus pallidus pars interna and substantia nigra. The basal ganglia circuit is divided into motor, limbic, oculomotor and association circuits to simplify the complex connections of the basal nuclei. Parkinson's disease is the one of the major clinical problems affecting basal ganglia circuit.

**Keywords:** anatomy, basal ganglion, Parkinson's disease

#### PS-5

##### Experimental models of Parkinson's disease

Gülhan R

*Department of Medical Pharmacology, Faculty of Medicine, Marmara University, Istanbul, Turkey*

Parkinson's disease (PD) is a progressive neurodegenerative disorder, affecting 1% of the population above the age of 65 and its etiology is still unknown. There is evidence for a role of both environmental and genetic factors. The characteristic pathology is the degeneration of dopamine neurons in substantia nigra pars compacta and loss of dopamine innervation in basal ganglia. Current treatments provide immediate and effec-

tive symptomatic relief, however, they don't stop underlying neurodegenerative processes. New potential treatments need to be developed to slow down the neurodegenerative process and further improve patients' quality of life. To address these issues different animal models are required although animal models of PD do not reproduce all the features of the human condition. Pharmacological models of PD were developed by using drugs such as reserpine, toxins that specifically targeted catecholaminergic neurons, such as 1-methyl-4-phenyl-1,2,3,6-tetrahydropyridine (MPTP), 6-hydroxydopamine (6-OHDA) and in last decades a pesticide called rotenone. More recent models employ transgenic animals with targeted genetic manipulations on alpha-synuclein, DJ-1, PINK1, Parkin, LRRK2 to simulate underlying mechanisms of genetic forms of PD. Each one of these models has its own advantages and limitations. Some are suitable for studying PD pathogenesis, while others are more relevant to test therapeutic treatments. In this talk, the most used PD models to understand the pathophysiology of Parkinson's disease and to develop new therapies will be discussed.

**Keywords:** experimental model, neurodegeneration, Parkinson's disease

#### PS-6

##### Parkinson's disease: clinical point of view

Günel D

*Department of Neurology, Faculty of Medicine, Marmara University, Istanbul, Turkey*

Parkinson's disease (PD) is a neurodegenerative disorder with evolving layers of complexity. It has long been characterized by classical motor features; rigidity, bradykinesia and rest tremor; associated with Lewy bodies and loss of dopaminergic neurons in substantia nigra. However, today we know that this syndrome starts with non-motor symptoms and motor symptoms appear at the third stage of neurodegeneration according to Braak's classification. PD pathology involves extensive regions of the nigrostriatum, various neurotransmitters and protein aggregates. The cause of the disease remains unknown, but the risk of developing PD is no longer viewed as primarily due to environmental factors. Instead, PD seems to result from a complicated interplay of genetic and environmental factors affecting numerous fundamental cellular processes. The complexity of PD makes the clinicians to unable making a definite diagnosis in the earliest stages of the disease. Furthermore there's no treatment that slows the neurodegenerative process. I will review mainly challenges in the correct diagnosis and different clinical subtypes of this inscrutable disease.

**Keywords:** diagnosis, motor, non-motor, neurodegeneration, Parkinson's disease



# Oral Presentations

(O-1 — O-47)

September 26, 2017

Hall A (09:20–10:30)

## O-1

### Profiles and motivations of whole body donors in Turkey: Istanbul University experience

Gürses İA<sup>1</sup>, Ertas A<sup>2</sup>, Gürtekin B<sup>3</sup>, Coşkun O<sup>1</sup>, Üzel M<sup>2</sup>, Gayretli Ö<sup>1</sup>, Demirci MS<sup>2</sup>

<sup>1</sup>Department of Anatomy, Istanbul Faculty of Medicine, Istanbul University, Istanbul, Turkey; <sup>2</sup>Department of Anatomy, Cerrahpaşa Faculty of Medicine, Istanbul University, Istanbul, Turkey; <sup>3</sup>Department of Biostatistics, Istanbul Faculty of Medicine, Istanbul University, Istanbul, Turkey

**Objective:** Profiling body donors gains importance for improving awareness campaigns. This study was aimed to profile donors who applied to body donation programs of Istanbul Faculty of Medicine and Cerrahpaşa Faculty of Medicine.

**Methods:** After obtaining Ethics Committee approval (date: 02.06.2014; no: 900), qualitative data was gathered via a survey. Donors who applied to both programs between January 2000 and July 2017 was included to the study. Metadata from the Turkish Statistical Institute was used for comparing demographic, educational, and marital data.

**Results:** Average donor age was 57.3 (±15.9). Compared with Turkey and Istanbul, frequencies for 65–69 age group (20% vs 4% and 3.1%;  $p < 0.05$ ,  $p < 0.05$ ) and higher-education graduates (49.7% vs 18.2% and 19.5%;  $p < 0.001$ ,  $p < 0.001$ ) were significantly higher, while frequencies for married individuals (42% vs 63.5% and 61.9%;  $p < 0.001$ ,  $p < 0.001$ ) were significantly lower among donors. Internet (28.3%), newspapers (25.3%), and television (23.1%) were the most preferred information sources. Donors allowed their health information to be available to public (55.2%) and students (39%). Similarly, they also allowed their personal information to be available to public (58.1%) and students (23.5%). Categorical evaluation revealed contribution to science / research (23.9%), will to be helpful (20.2%), and will to be useful (18.6%) were the major motivations to donate.

**Conclusion:** This study is the first to evaluate body donor profile in Turkey. We believe that our results will help increasing the effectiveness of donation campaign by determining a more appropriate audience and detect new audiences through subgroup analyses.

**Keywords:** anatomy education, body donation, donor motivation, donor profile, Turkey

## O-2

### Approach to cadaver used in anatomy education, dead body confidentiality and ethics I: opinions of anatomy academicians

Babacan S<sup>1</sup>, Kafa İM<sup>1</sup>, Erer Kafa S<sup>2</sup>

<sup>1</sup>Department of Anatomy, Faculty of Medicine, Uludağ University, Bursa, Turkey; <sup>2</sup>Department of Medical Ethics and History of Medicine, Faculty of Medicine, Uludağ University, Bursa, Turkey

**Objective:** Purpose of the current study, to evaluate the opinions on sharing cadaver images on social media, in terms of dead body confidentiality and medical ethics by getting opinions of anatomy academicians.

**Methods:** The study involved only anatomy academicians. A questionnaire, of 23 questions was prepared and approved by Uludağ University Medical Faculty Clinical Research Ethics Committee (04.07.2017–2017-10/33). The form was made accessible on internet with the link address <https://goo.gl/forms/dPbqVgoQDWpD9vDr1> Frequency distributions of the answers given to the questionnaires were taken from the system at the link address.

**Results:** In current study, 86 volunteers from 28 universities participated. 68.9% of the participants stated that they have been educated in ethics during undergraduate/graduate education. 97.6% of the participants reported a positive opinion and 2.4% had a negative opinion on “Human is a precious being. For this reason, the human body should be esteemed and respected when the person is alive and after its death”. 93% of the participants reported that they’re strongly agree and agree, 5.8% answered undecided and 1.2% do not agree to the question of “Sharing the images taken with cadaver on social media isn’t ethical.”

**Conclusion:** Cadaver privacy is a value that must be protected from the supply. The anatomists’ approach to the subject also manifests itself in student education. As foreseen in the answers to the questionnaire, the right to privacy of dead bodies has come out as a value to be respected.

**Keywords:** cadaver, medical ethics, dead body privacy, confidentiality

## O-3

### Approach to cadaver used in anatomy education, dead body confidentiality and ethics II: Uludağ University Faculty of Medicine Students' opinions

Babacan S<sup>1</sup>, Erer Kafa S<sup>2</sup>, Kafa İM<sup>1</sup>

<sup>1</sup>Department of Anatomy, Faculty of Medicine, Uludağ University, Bursa, Turkey; <sup>2</sup>Department of Medical Ethics and History of Medicine, Faculty of Medicine, Uludağ University, Bursa, Turkey

**Objective:** Value of cadaver for medical education; to learn structures belonging to human body and to work on anatomical formations by touching human body. It is important for the students to be sensitive on approaching towards cadavers and respect their privacy. The aim of the study is evaluating the opinions of the students attending Medicine Faculty of Uludağ University, on ethical point and raise the awareness among the students about approaching to cadaver and dead body privacy.

**Methods:** Our study was formed of students attending Medicine Faculty of Uludağ University. A questionnaire, consisting of 23 questions prepared by the researchers and approved by Uludağ University Medical Faculty Clinical Research Ethics Committee Decision (04.07.2017-2017-10/34), was used. The form has been made accessible on internet with the link address <https://goo.gl/forms/dPbqVgoQDWpD9vDr1>, the address was shared by participants. results of the questionnaires were taken from the system at the link address.

**Results:** 550 students participated to the study. 88.4% of participant expressed positive opinion and 5.3% of participants reported negative opinion, for the question of “although cadaver is a lifeless, you should respect its privacy”. 90.4% strongly agree or disagree with the article “memories of cadavers can be shared in social media”, 8.2% absolutely disagree or disagree.

**Conclusion:** The fact that the participants did not respond positively to questions about cadaver privacy and about sharing images in social media (11.6%, 9.6%, respectively) suggests that awareness on these issues should be increased.

**Keywords:** cadaver, medical ethics, dead body privacy, confidentiality

#### O-4

##### New approaches to cadaver donation: internet and social media use

Özkan M<sup>1</sup>, Sert G<sup>2</sup>

<sup>1</sup>Department of Anatomy, Faculty of Medicine, Marmara University, Istanbul, Turkey; <sup>2</sup>Department of History of Medicine and Ethics, Faculty of Medicine, Marmara University, Istanbul, Turkey

Cadaveric dissection is an inevitable and indispensable need for anatomy. The choice of obtaining the bodies changes from unclaimed ones to donated ones in recent years. However, because of social aspects and legal regulations, body donation is not sufficient in Turkey as it is in many countries. It is necessary to examine and implement body donation programs in successful countries (Riederer, 2016) or to launch new applications to obtain bodily material to use in training (undergraduate, PhD, specialty, etc.) and scientific research. With the recommendations shared by donors, a number of new methods that can be implemented in our country and their legal and ethical bases have been scrutinized by using the possibilities of today's technological and social developments. In the case presented, “Cadaver Donation Can Also Be Done”

Facebook group and Google Trends results in comparison of the level of awareness and interest about cadaver donation between Turkey the world are presented. And true reflections of the work are displayed. As a result, it is observed that the “cadaver donation” issue is under-treated in our country and it can be increased by using internet and social platforms. Especially in the age “Internet”, it is very important to organize and spread the use of the internet and especially social media in reaching our body donors. In this context, it is possible to consider the educational materials for donors, the sources from which they may obtain information, and even the minutes of the donation, as well as their evaluation processes (Baker, 2017).

**Keywords:** cadaver, internet, social media

#### O-5

##### Evaluation of the relationship between femoral trochlear morphology and anterior cruciate ligament tears on MR images

İşıklar S<sup>1</sup>, Özdemir S<sup>2</sup>, Gökalp G<sup>3</sup>

<sup>1</sup>Vocational School of Health Services, Medical Imaging Techniques Program, Uludağ University, Bursa, Turkey; <sup>2</sup>Department of Anatomy, Faculty of Medicine, Uludağ University, Bursa, Turkey; <sup>3</sup>Department of Radiology, Faculty of Medicine, Uludağ University, Bursa, Turkey

**Objective:** The aim of this study is to investigate whether femoral trochlear morphology has relationship with the anterior cruciate ligament (ACL) tear and bone morphology could be taken as a risk factor in clinical.

**Methods:** Our study was carried out on the knee MR images taken from accepted at the Clinical Research Ethics Committee of Uludağ University Faculty of Medicine dated 29.09.2015 and numbered 2015-17/19. Axial MR images of 94 patients were evaluated retrospectively. The ACL tears were identified at the knees of 42 patient. 52 patients who don't have any pathologies at knee were included the study as healthy control group. A total of 30 morphometric measurements were made from two different levels, proximal and distal, for femoral trochlea on axial knee MR images. The obtained data were evaluated by performing SPSS 22.0 software.

**Results:** The ACL tear group were found to be statistically different from control group in terms of sulcus angle, sulcus depth, trochlea lateral facet length (distal level), trochlear facet asymmetry, percentage of TEA length of femur lateral condyle height, percentage of TEA length of femur medial condyle height, lateral trochlear tilt angle, medial trochlear tilt angle, height of patellar joint and patellar trochlear overlap (p<0.05).

**Conclusion:** The morphological evaluation of femoral trochlea is an important point of alignment of knee joint. By the current study, the trochlear morphology could be accepted as risk factor for the anterior cruciate ligament injuries at knee.

**Keywords:** patellafemoral joint, trochlear morphology, anterior cruciate ligament tear, MR

**O-6****The effect of self-esteem and decision making on anatomy lesson success in faculty of medicine students**Ak Güven G<sup>1</sup>, Emirzeoğlu M<sup>2</sup>, Erkan İ<sup>3</sup>, Şener A<sup>1</sup><sup>1</sup>Vocational School of Health Services, Ondokuz Mayıs University, Samsun, Turkey; <sup>2</sup>Department of Anatomy, Faculty of Medicine, Ondokuz Mayıs University, Samsun, Turkey; <sup>3</sup>Department of Biostatistics and Medical Informatics, Faculty of Medicine, Ondokuz Mayıs University, Samsun, Turkey**Objective:** Knowledge of anatomical structures and their relationships with the diseases are very important for diagnosing and treating patients. In our study, we aimed to determine Self-Esteem and Decision Making Levels of students in medicine faculty and compare them with anatomy lesson success of students.**Methods:** We included 332 students (165 females and 167 males) in the Ondokuz Mayıs University Faculty of Medicine first and second classes, into our study. We get demographics of the students and opinions about medical doctor as a job. We used Self-Esteem Scale developed by Arıcağ (1999) and Decision Making Questionnaire translated into Turkish language by Deniz (2004). Both scale scores and theoretical and practical anatomy exam results of the participants analyzed.**Results:** The scores of Self-Esteem Scale were higher in males than females ( $p=0.004$ ). Students who like medical doctor as a job had higher theoretical exam points than who don't like ( $p=0.033$ ). We found no correlation between Decision Making Questionnaire scores and practical exam points ( $r=-0.071$   $p=0.197$ ) and theoretical exam points ( $r=-0.101$   $p=0.067$ ). On the other hand, there were negative weak correlation between Self-Esteem Scale scores and practical exam points ( $r=-0.203$   $p<0.001$ ) and theoretical exam points ( $r=-0.256$   $p<0.001$ ).**Conclusion:** Students who like medical doctor as a job are more successive than who don't like. We found that Self-Esteem Scale and Decision Making Questionnaire are not effective in the prediction of students' theoretical and practical anatomy exam results.**Keywords:** anatomy, anatomy lesson success, decision making, Self-Esteem**O-7****A malpractice case of cadaver donation**Develi M<sup>1</sup>, Develi S<sup>2</sup><sup>1</sup>Faculty of Law, Gaziantep University, Gaziantep, Turkey; <sup>2</sup>Department of Anatomy, University of Health Sciences, Gülhane Faculty of Medicine, Ankara, Turkey**Objective:** Until 2014, cadaver supply was made through donation in our country. With the amendment made in Law-No. 2238 in 2014, permission was granted to supply cadaver and pieces from abroad. It is emphasized cadaver should be used for education and scientific purposes in donation forms

given when cadaver donations are made. In this article, a review will be made on a case in USA.

**Methods:** In USA, cadaver donations are made through profit-oriented or non-profit-institutions. In 2015, a fraud investigation launched into profit-oriented cadaver donation agencies in many states. FBI informed families of donors of relevant institutions. However, wife of a person who donated himself as a cadaver later applied to donation institution to receive information about his body and was informed that he had undergone dissection and disarticulation. When information on disarticulation is requested, it is reported that the limbs are separated from body for extensive surgical examination. Wife stated that they were not informed about this issue, but it has been shown to her as a medical term in the form of the affirmation husband had signed. However, it was possible to determine which extremity belonged to her husband after DNA test.**Results:** Cadaveric donation in our country is very sensitive. Law-2238-Article-7 gives physicians obligation to provide information on donation. In order not to live legal problems, we think cadaver donation forms should be detailed as in surgical cases, but simple writing, marking of the organs and extremities separated from cadaver will solve many problems.**Keywords:** body donation, cadaver, cadaver donation form

---

**September 26, 2017****Hall A (15:00-16:30)**

---

**O-8****Investigation of hand preference and sex effects on telencephalon morphology via DTI-based parcellation method**Aytaç G<sup>1</sup>, Acer N<sup>2</sup>, Karaali K<sup>3</sup>, Gülkesen KH<sup>4</sup>, Sindel M<sup>1</sup><sup>1</sup>Department of Anatomy, Faculty of Medicine, Akdeniz University, Antalya, Turkey; <sup>2</sup>Department of Anatomy, Faculty of Medicine, Erciyes University, Kayseri, Turkey; <sup>3</sup>Department of Radiology, Faculty of Medicine, Akdeniz University, Antalya, Turkey; <sup>4</sup>Department of Biostatistics and Medical Informatics, Akdeniz University, Antalya, Turkey**Objective:** Cerebral hemispheres differ from each other. Some of these asymmetries are related to hand preference, language, complex motor skills, while others are related to less distinct cognitive functions. In this study, we aimed to investigate the effects of hand preference and sex on the telencephalon morphology by comparing the diffusion parameters of corticospinal tract (TCS) and posterior limb of internal capsule (CICP) with parcellation method.**Methods:** The study included 108 subjects (54 right, 54 left hand preference) in the age range 18-28 years and gender distribution was equal in two groups. 'Edinburgh handedness inventory' test was applied to determine hand preference. The raw data from the MRI was processed using MRI Studio image

processing program. Fractional anisotropy (FA) and mean diffusivity (MD) averages of TCS and C1CP were calculated for all subjects for both hemispheres. Differences among individual hemispheres and hand preference and sex were assessed.

**Results:** In both TCS and C1CP, high FA and low MD values were detected in the left hemisphere in all subjects regardless of hand preference and sex.

**Conclusion:** In our study, using DTG, the best in vivo method of examining white matter pathways, we compared diffusion parameters of some pathways. Until now, this comparison has not been done using the DTI parcellation method.

**Keywords:** diffusion tensor imaging, MRI studio, fractional anisotropy, hand preference

## O-9

### Brachial plexus with all aspects

Uysal İİ<sup>1</sup>, Şeker M<sup>1</sup>, Ünver Doğan N<sup>2</sup>

<sup>1</sup>Department of Anatomy, Meram Medical Faculty, Necmettin Erbakan University, Konya, Turkey; <sup>2</sup>Department of Anatomy, Faculty of Medicine, Selçuk University, Konya, Turkey

Brachial plexus is the focus of many departments of medicine and veterinary with its functional, anatomical and clinical features. In this study, it is aimed to evaluate with all the aspects of brachial plexus which is quite important for anatomy education and clinical anatomical studies. For this purpose, the literature and departmental experiences were reviewed. In our country, there are about 20 postgraduate theses on brachial plexus and its terminal branches. When the "brachial plexus" key word is written in the literature search, it is determined that there are about 30,000 articles. These articles concern the morphological features and variations of the brachial plexus and its branches, as well as obstetrical injuries and/or trauma-related injuries, blockage for pain treatment and/or before clinical approaches, and nerve transfers. The results of this study, designed to emphasize the importance of the brachial plexus, will be used to better understand and explain this structure.

**Keywords:** brachial plexus, learning, teaching

## O-10

### Assessment of age and sex-dependent changes of cerebellum volume in healthy individuals with magnetic resonance imaging

Ateşoğlu S<sup>1</sup>, Doğan Z<sup>1</sup>, Baykan AH<sup>2</sup>, Solgun S<sup>3</sup>, Özcan G<sup>2</sup>, Erbay F<sup>2</sup>, Aydın A<sup>1</sup>

<sup>1</sup>Department of Anatomy, Faculty of Medicine, Adiyaman University, Adiyaman, Turkey; <sup>2</sup>Department of Radiology, Faculty of Medicine, Adiyaman University, Adiyaman; <sup>3</sup>Department of Anatomy, Faculty of Medicine, İnönü University, Malatya

**Objective:** Cerebellum is a structure which ingrained in fossa cranii posterior and has a great role in contributing to the coordinations of motor functions, regulation of muscle tone, in motor

learning, and also precision and accurate timing. Our aim with this study is primarily to establish a cerebellum measurement scale based on age and sex.

**Methods:** The study was carried out with the approval of Adiyaman Clinical Research Ethics Board with the contributions of Adiyaman University Training and Research Hospital Radiology Department. Data were obtained retrospectively on images of 160 individuals (80 female and 80 male) using magnetic resonance imaging. Individuals included in the study were divided into groups of 10–19, 20–29, 30–39, 40–49, 50–59 and over 60 years old and all ages, the group consists of 10 women and 10 men totally 20 individuals. All statistical analyzes were done by SPSS program.

**Results:** Cerebellum volume averages and age groups; females (10–19) 139.23±11.73 males (10–19) 150.86±13.01, females (20–29) 131.12±15.90 males (20–29) 141.46±19.83, females (30–39) 135.94±17.15 males (30–39) 151.78±14.31, females (40–49) 132.29±14.99 males (40–49) 142.16±10.68, females (50–59) 138.67±17.20 males (50–59) 150.99±16.69, females (at the age of 60 and over) 133.29±17.13 males (at the age of 60 and over) 144.77±16.82. Statistically, a significant difference between cerebellum volumes of 10–19 years and 30–39 years has been found (p=0.04, p=0.038). Cerebellum volume average in females was 135.09±15.44, in males was 147.05±15.39. Ultimately, it was determined that the volumes of cerebellum in males are bigger than those of females.

**Conclusion:** Determining the volumes of brain parts in healthy individuals is also very important in assessing the aging process as well as contributing to the differentiation of normal and pathological conditions.

**Keywords:** cerebellar volume, MRI, age, gender

## O-11

### Examination of cerebral cortical thickness measurement using magnetic resonance imaging between musicians and non-musicians

Acer N<sup>1</sup>, Bastepe SG<sup>2</sup>, Zararsız G<sup>3</sup>, Değirmencioğlu L<sup>4</sup>

<sup>1</sup>Department of Anatomy, Faculty of Medicine, Erciyes University, Kayseri, Turkey; <sup>2</sup>The Peabody Conservatory, Johns Hopkins University, Baltimore, Maryland, USA; <sup>3</sup>Department of Biostatistics and Medical Informatics, Faculty of Medicine, Erciyes University, Kayseri, Turkey; <sup>4</sup>Department of Music, Faculty of Fine Arts, Erciyes University, Kayseri, Turkey

**Objective:** Musicianship requires a highly sophisticated, multimodal integration of sensory, motor, and cognitive tasks. Numerous neuroimaging studies have shown structural and functional changes resulting from musical training. Measuring the cortical thickness of the human cerebral cortex is of great interest in studies of both normal and abnormal neuroanatomy. Cortical thickness, total brain (TBV), grey matter (GM) and white matter (WM) volumes were measured CAT12 (Computational Anatomy Toolbox) "optimized VBM" procedure toolbox in Statistical Parametrical Mapping (SPM12).

**Methods:** The study included T1-weighted magnetic resonance imaging (MRI) of 6 musicians and non-musicians with 1.5T MRI system. We evaluated images using a magnetization prepared rapid gradient echo (MPRAGE) sequence with a slice thickness of 1 mm. Statistical differences were examined using correlation analyses accounting for spatial interpretations volume difference.

**Results:** It was observed that cortical thickness correlated with GM volume ( $r=0.639$ ,  $p<.05$ ).

**Conclusion:** Our results do not indicate statistically significant differences between musicians and non-musicians.

**Keywords:** magnetic resonance imaging, volumetric segmentation, Voxel Based Morphometry, cortical thickness.

## O-12

### Assessing the brain ventricles volume in patients with major depressive disorder using the stereological method

Karakaş AB<sup>1</sup>, Gönül AS<sup>2</sup>, Karaca Saygılı Ö<sup>3</sup>

<sup>1</sup>Department of Anatomy, Faculty of Medicine, Kafkas University, Kars, Turkey; <sup>2</sup>Department of Psychiatry, Faculty of Medicine, SoCAT Lab, Ege University, Izmir, Turkey; <sup>3</sup>Department of Anatomy, Faculty of Medicine, Balikesir University, Balikesir, Turkey

The aim of our study is to show the volume changes both in the brain and ventricles in patients diagnosed with major depressive disorder (MDD) and healthy individuals by using such stereological methods as Cavalieri and planimetry. This study has been carried out using the archived MR sections of 18 MDD patients and 18 healthy individuals who were screened in the Hospital of Ege University, between the dates of January 2008 and February 2011. In Cavalieri method, the volumes were calculated by putting a transparent square grid test ruler sheet on the brain MR sections. As for the planimetry method, however, it was done by tracing the borders of the related area by hand. According to Cavalieri method, in patients the total brain volume was determined to be  $1058.70 \pm 105.11$  cm<sup>3</sup>, total lateral ventricles volume was  $11.58 \pm 5.06$  cm<sup>3</sup>, third ventricle volume was  $0.76 \pm 0.53$  cm<sup>3</sup>, fourth ventricles volume was  $0.92 \pm 0.64$  cm<sup>3</sup>. In the control group was found  $1150.46 \pm 89.94$  cm<sup>3</sup>,  $9.38 \pm 2.94$  cm<sup>3</sup>,  $0.45 \pm 0.18$  cm<sup>3</sup>,  $0.87 \pm 0.25$  cm<sup>3</sup>, respectively. According to planimetry method, in patients the total brain volume was determined to be  $1041.61 \pm 106.60$  cm<sup>3</sup>, total lateral ventricles volume was  $11.63 \pm 5.23$  cm<sup>3</sup>, third ventricle volume was  $0.73 \pm 0.53$  cm<sup>3</sup>, fourth ventricles volume was  $0.93 \pm 0.30$  cm<sup>3</sup>. In the control group was found  $1127.56 \pm 92.90$  cm<sup>3</sup>,  $9.29 \pm 3.06$  cm<sup>3</sup>,  $0.44 \pm 0.19$  cm<sup>3</sup>,  $0.91 \pm 0.30$  cm<sup>3</sup>, respectively. In the end, statistically significant decrease was observed in the total brain volume in MDD patients, whereas meaningful increase was observed in the third ventricle volume. In the cases of prolonged illness and not using the drugs properly, it was observed that there was an increase in lateral ventricles and the third ventricle volume, and that specifically male patients were affected by this situation.

**Keywords:** lateral ventricle, major depressive disorder, magnetic resonance imaging, stereology, third ventricle

## O-13

### Corpus callosum is prone to demyelination in a mouse model of multiple sclerosis

Öztürk S<sup>1</sup>, Göksu AK<sup>2</sup>, Aytaç G<sup>1</sup>, Tanrıöver G<sup>2</sup>, Hatipoğlu B<sup>3</sup>, Derin N<sup>3</sup>, Sindel M<sup>1</sup>

<sup>1</sup>Department of Anatomy, Faculty of Medicine, Akdeniz University, Antalya, Turkey; <sup>2</sup>Department of Histology and Embryology, Faculty of Medicine, Akdeniz University, Antalya, Turkey; <sup>3</sup>Department of Biophysics, Faculty of Medicine, Akdeniz University, Antalya, Turkey

**Objective:** Demyelination is a generic pathological term simply describing the loss of normal myelin around axons in the central nervous system. Brain MRIs in multiple sclerosis (MS) shows demyelinating lesions in periventricular area, corpus callosum (CC) and brain stem. It is known that CC is affected from demyelination in MS. We aim to investigate the intensity of demyelination affects in corpus callosum.

**Methods:** In this study, we used C57BL/6 type mice. We have designed four groups, including demyelination/control and remyelination/control. Demyelination group was given 0.2 % cuprizone via gavage for 6 weeks. Remyelination group was given 0.2% cuprizone via gavage for 6 weeks and then these rats were fed with normal chow during 6 weeks. Control groups were fed with normal chow. Demyelination and remyelination groups behavioral tests were evaluated. We also evaluated the myelin basic protein (MBP) and glial fibrillary acidic protein (GFAP) expressions by using immunohistochemical techniques in CC of total brain tissues.

**Results:** Behavioral tests showed decreased locomotor activity in the demyelination group while it remained nearly normal in the remyelination group. We observed that GFAP increased and the expression of MBP decreased in total CC of demyelination group compared to the control and remyelination groups.

**Conclusion:** The effect of demyelination, which constitutes an important step in the pathogenesis of MS, in CC is shown histologically in this study. In the continuation of the current work, we believe that the examinations of central and peripheral formations can be used for new projects.

**Keywords:** demyelination, GFAP, MBP, multiple sclerosis

## O-14

### Evaluating of the median nerve section area on magnetic resonance imaging in patients with carpal tunnel syndrome

Ak Güven G<sup>1</sup>, Emirzeoğlu M<sup>2</sup>, Erkan İ<sup>3</sup>, Şahin B<sup>4</sup>

<sup>1</sup>Vocational School of Health Services, Ondokuz Mayıs University, Samsun, Turkey; <sup>2</sup>Department of Anatomy, Faculty of Medicine Ondokuz Mayıs University, Samsun, Turkey; <sup>3</sup>Department of Biostatistics & Medical Informatics, Faculty of Medicine Ondokuz Mayıs University, Samsun, Turkey; <sup>4</sup>Department of Anatomy, Faculty of Medicine, Karabük University, Karabük, Turkey

**Objective:** Carpal tunnel syndrome (CTS) is a neuropathy of the median nerve. The aim of this study is to compare the median nerve (MN) section area in patients with CTS and healthy individuals.

**Methods:** We included 42 females (30 patients, 16 controls) volunteers into our study. T1-weighted axial magnetic resonance images of 92 wrists were analyzed with ImageJ software. The MN section area of all wrists were measured at the level of entrance (proximal) and exit (distal) of the carpal tunnel and hook of hamate by using planimetry technique. These section areas were evaluated in 5 groups: 3 groups in regard to CTS severity in the affected wrist (mild, moderate, severe), 1 group was the unaffected wrist of patients and 1 group the wrists of controls.

**Results:** MN section area at the proximal level was  $23.58 \pm 5.05$  mm<sup>2</sup> for the patients with CTS and  $14.22 \pm 3.01$  cm<sup>2</sup> for the healthy individuals, the difference was significant ( $p < 0.05$ ). MN section area at the level of hamate hook was  $17.22 \pm 4.83$  mm<sup>2</sup> for the patients with CTS and  $11.38 \pm 2.35$  cm<sup>2</sup> for the healthy individuals, this difference was also significant ( $p < 0.05$ ). The best cut off value for diagnosing CTS was found to be 17.5 cm<sup>2</sup> at the proximal level. Sensitivity and specificity values were 90.0% and 84.4%.

**Conclusion:** Misdiagnosis of CTS cases with other diseases and inadequate diagnosis techniques may postpone the appropriate treatment of the patients. Evaluating MN section area at 3 different levels regarding cut off values may contribute to the diagnosis of CTS.

**Keywords:** carpal tunnel syndrome, median nerve, planimetry technique, section area

## O-15

### The cerebello-hypothalamic pathways via superior and middle cerebellar peduncle in the rat

Çavdar S<sup>1</sup>, Kuvvet Y<sup>1</sup>, Hacıoğlu Bay H<sup>2</sup>, Özgür M<sup>1</sup>

<sup>1</sup>Department of Anatomy, Koç University School of Medicine, Istanbul, Turkey; <sup>2</sup>Department of Anatomy, Marmara University School of Medicine, Istanbul, Turkey

**Objective:** The cerebellum has been regarded as an organ related to movement, primarily through its connections with the cortex. However, experimental and clinical studies have shown the involvement of the cerebellum with various visceral functions. The connections between the cerebellum and the hypothalamus has been well documented. The present study aims to define the cerebellar peduncle connecting to the hypothalamic nuclei to the cerebellum or vice versa.

**Methods:** 20 male albino rats received 20–50-nl pressure injections of either Fluoro-Gold (FG) or biotinylated dextran amine (BDA) tracer into the SCP, MCP and ICP. Following 7–10 days of survival period the animals were processed according to the related protocol for the two tracer used.

**Results:** The present study has shown that cerebellum is connected to the hypothalamus via both the superior (SCP) and the middle (MCP) but not the inferior (ICP) cerebellar peduncle. The SCP connects the deep cerebellar nuclei and the cerebellar cortex to the lateral, dorsomedial, paraventricular, preoptic and posterior hypothalamic nuclei. Whereas the MCP connects the deep cerebellar nuclei and the cerebellar cortex to the lateral, medial, pre and tuberomammillary nuclei, ventromedial and lateral hypothalamic nuclei. All connections between the cerebel-

lum and the hypothalamus were bilateral, moderate on the ipsilateral and sparse on the contralateral side.

**Conclusion:** These findings can be used in defining the neuronal circuit of various diseases involving the SCP and MCP.

**Keywords:** hypothalamus, cerebellar, connections, superior, middle cerebellar peduncle

## O-16

### Effect of melatonin on reproduction

Behram Kandemir Y<sup>1</sup>, Aydın Ç<sup>2</sup>, Görgişen G<sup>3</sup>

<sup>1</sup>Department of Anatomy, Faculty of Medicine, Akdeniz University, Antalya, Turkey; <sup>2</sup>Department of Nursing, Bucak School of Health, Mehmet Akif Ersoy University, Burdur, Turkey; <sup>3</sup>Department of Medical Biology, Faculty of Medicine, Yüzüncü Yıl University Van, Turkey

Mammalian Target of Rapamycin (mTOR) signaling pathway has important roles in the regulation of gonadotropin secretion, follicular development and ovulation. Recent studies have shown that melatonin affected the number or maturation of follicles in the ovary. The aim of this study was to investigate the effects of melatonin on mTOR expression and quantity of follicle in rat ovary. In the present study, a total of 45 female rats were randomly divided into three groups. Group 1; Control (C), Group 2: Vehicle (V) and Group 3; Melatonin (M). Melatonin was administered intraperitoneally at a dose of 50 mg/kg/day for 30 days in Melatonin group. Upon Western Blot and RT-PCR evaluations, we detected higher expression and activation of mTOR, P70S6K, PKC $\alpha$ , PCNA and higher numbers of primordial follicles in melatonin group compared with V and C group. In addition to this results, melatonin decreased oxidative stress markers, such as MDA and levels of antioxidative markers, such as CAT and GPx, were increased by melatonin in rat ovary. This study indicated that melatonin may have a significant protective effect on primordial follicles and increase the expression of mTOR and downstream components in rat ovary. Melatonin treatment may have a beneficial effect on fertility. (The present study was performed in accordance with the Akdeniz University Institutional Animal Care and Use Committee Policies for Animal Use under an approved animal. B.30.2.AKD.0.01.00.00/Hay. Den. Etik-384)

**Keywords:** infertility, melatonin, mTOR

---

September 26, 2017

Hall B (09:20–09:30)

---

## O-17

### Morphometric evaluation of foramen sphenopalatinum in terms of nerve block

Develi S

Department of Anatomy, University of Health Sciences, Gülhane Faculty of Medicine, Ankara, Turkey

**Objective:** Sphenopalatine foramen is the opening that connects pterygopalatine fossa to cavitas nasi. Pterygopalatine ganglion,

Maxillary nerve and artery are anatomical structures in this fossa. Since maxillary nerve innervates both nasal cavity and infraorbital region, pterygopalatine fossa is targeted for pain block. Lateral, infratemporal fossa approach is more invasive and risky which lies medial to mandibular ramus, the transnasal approach is considered easier and less invasive to block. In this study, it is aimed to describe morphometrically localization of sphenopalatine foramen according to nostrils and to make a description for pterygopalatine blocking in our population.

**Methods:** 5 cadavers (10-half-heads) and 18 skulls (36-sides) were examined. Location of sphenopalatine foramen was measured relative to nostrils. At what angle from nostrils, sphenopalatine foramen insertion was found to be more easily accessible. Vertical and horizontal dimensions of foramen were measured. Existence of accessory foramen was examined.

**Results:** Most common location was posterior of meatus nasi medius. Vertical and horizontal dimensions of foramen were  $4.7 \pm 3$  mm and  $6.3 \pm 2$  mm, respectively. The most common oval-shaped foramen was found. The accessory hole was not observed. The mean distance from the nostrils was found to be 6.7 cm and an average of  $40^\circ$ .

**Conclusion:** Pterygopalatine block is a frequent method in facial pain such as trigeminal neuralgia and in headaches such as migraine or post-dura-mater puncture. The most common method is inserting horizontally to the ground from the nostrils. We have shown that this method will not be successful in our population according to our findings.

**Keywords:** sphenopalatine foramen, pterygopalatine ganglion, nerve block

## O-18

### Anatomy of frozen shoulder

Erçakmak B<sup>1</sup>, Günenç Beşer C<sup>1</sup>, Demiryürek D<sup>1</sup>, Özsoy H<sup>2</sup>

<sup>1</sup>Department of Anatomy, Faculty of Medicine, Hacettepe University Ankara, Turkey; <sup>2</sup>Department Orthopaedics and Traumatology, Memorial Hospital, Ankara, Turkey

Frozen shoulder is a clinical diagnosis, characterized by extreme pain and stiffness with restrictions of movements at the glenohumeral joint in the presence of normal X-rays and anatomy. Regarding this, evaluation is hard and it frequently leads to misdiagnosis. The differential diagnosis includes rotator cuff tear, deltoid paresis, arthritis, locked posterior dislocation etc. Primary idiopathic frozen shoulder without a detectable underlying cause and secondary diabetic frozen shoulder which is seen in diabetic patients are the main types. Fibrotic inflammatory contracture related with thickening of the soft tissues is the underlying pathology. With clinical and radiologic corroborations, recent arthroscopic and cadaveric studies concluded that the affected rotator interval is playing an important role in restriction of glenohumeral joint movements. The rotator interval is a space located between the supraspinatus and subscapularis muscle tendons which includes coracohumeral ligament, superior glenohumeral ligament and parts of the joint capsule. It plays a key role in external rotation of

the arm. Since the assessment of pain is subjective and the limitation of external rotation is objective and pathognomonic, clinical severity is graded on reduced external rotation by more than 50%. Main innervation of the glenohumeral joint is supplied by subscapular, suprascapular, axillary and the lateral pectoral nerves. Treatment remains symptomatic for pain relief and inflammation suppression with NSAIDs, steroid injection, physiotherapy and nerve blocks. The purpose of this study is to review the anatomy of the frozen shoulder with respect to clinics and to mention the importance of differential diagnosis.

**Keywords:** frozen shoulder, anatomy, glenohumeral joint

## O-19

### The relationship between second to fourth digit ratio (2D:4D) and type 2 diabetes mellitus

Özkan G, Ögetürk M, Akkoç RF

Department of Anatomy, Faculty of Medicine, Firat University, Elazığ, Turkey

Diabetes mellitus is a chronic disease with a high morbidity rate. The most significant bodily characteristics that are thought to be influenced by prenatal sex hormone levels are second (2D) and fourth digit (4D) lengths. In this study it was aimed to reveal the relationship between finger measurements and ratios, which are thought to be determined by hormonal effects, and diabetes, a hormonal disease. This study was conducted with permission of Firat University Non-Interventional Research Ethics Committee dated 02.06.2015. A total of 400 people including 200 women and 200 men diagnosed with type 2 diabetes were included in the study. Palm width, palm length, 2D and 4D lengths were measured as anthropometric measurements. Hand indexes and 2D:4D ratios were calculated. When diabetes patients were evaluated by looking at body mass index values; men were overweight, and women were in the first degree obese class. While 2D values of female patients were shorter than control group, 4D was longer. 4D values of male patients were shorter than control group ( $p < 0.001$ ). When finger ratios are examined; It was determined that diabetic women had a smaller 2D:4D ratio compared to the control group and men with diabetes had a higher ratio ( $p < 0.001$ ). It can be concluded that 2D:4D ratio can be an important criterion which can contribute to the determination of risk of diabetes mellitus from the birth, and it can be said that it will enable people in risk group to live in more preventive way.

**Keywords:** 2D:4D ratio, type 2 diabetes mellitus, anthropometry, hand, digit

## O-20

### Biomechanics of the elbow and the valgus angulation

Günenç Beşer C<sup>1</sup>, Erçakmak B<sup>1</sup>, Demiryürek D<sup>1</sup>, Özsoy H<sup>2</sup>

<sup>1</sup>Department of Anatomy, Faculty of Medicine, Hacettepe University, Ankara, Turkey; <sup>2</sup>Department of Orthopaedics and Traumatology, Memorial Hospital, Ankara, Turkey

Elbow joint is a complex structure which is composed of three articulations with a common articular capsule. These three joints are together named as the trochoginglymoid joint. The flexion and extension of elbow and the pronation and supination of forearm can be performed around this joint. The biomechanical stability of the elbow joint is provided by the passive (bony structures, joints and ligaments) and active (muscles) stabilizers. The coronoid process, sigmoid notch, radial head and capitulum play an important role in stability by ensuring the osseous supply. Lateral collateral ligament is the main stabilizer of the humeroulnar joint to varus stress and the anterior band of medial collateral ligament is the primary stabilizer to valgus stress. The dynamic muscular forces provide the active stabilization. The carrying angle of the elbow is also an important parameter for stabilization, it is between the longitudinal axis of humerus and ulna in full extension. The average valgus angle is 11-14 in males and 13–16 in females. Recognizing the anatomy of the elbow, including the bony geometry, joints, ligaments and muscles and the knowledge of biomechanics are essentials for proper treatment of elbow disorders. Successful reconstruction depends on restoration of the anatomic contributors to stability. The purpose of this study is to review the anatomy and the biomechanics of the elbow joint and the valgus angulation in detail with respect to surgical treatments.

**Keywords:** elbow joint, valgus, biomechanics, lateral collateral ligament, anatomy

## O-21

### The investigation of theratogenic effects of bisphenol A on fetal bone development

Atay E<sup>1</sup>, Ertekin T<sup>2</sup>, Yılmaz H<sup>3</sup>, Susar H<sup>4</sup>, Al Ö<sup>4</sup>, Nisari M<sup>4</sup>, Yay A<sup>5</sup>, Unur E<sup>4</sup>, Özdamar S<sup>5</sup>, Yalçın B<sup>5</sup>

<sup>1</sup>Department of First and Emergency Aid, Niğde Zübeyde Hanım Vocational School, Niğde Ömer Halisdemir University, Niğde, Turkey;

<sup>2</sup>Department of Anatomy, Faculty of Medicine, Afyon Kocatepe University, Afyonkarahisar, Turkey; <sup>3</sup>Department of Therapy and Rehabilitation, Kozaklı Vocational School, Nevşehir Hacı Bektaş Veli University, Nevşehir, Turkey; <sup>4</sup>Department of Anatomy, Faculty of Medicine, Erciyes University, Kayseri, Turkey; <sup>5</sup>Department of Histology and Embryology, Faculty of Medicine, Erciyes University, Kayseri, Turkey

**Objective:** Bisphenol A (BPA), which has a wide use in the industry is one of the most produced chemicals in the world. In studies performed, BPA was identified in amniotic fluid, maternal and fetal plasma, placenta and mother's milk, fat tissue, semen, colostrum and saliva. The aim of research is to determine the rate of cartilage/bone that belongs to hindlimbs of fetus whose mothers exposed to BPA.

**Methods:** In this study, 16 adult pregnant female rats were used. Rats were divided into 4 groups; the control group, low, medium and high dose BPA groups. The fetus were removed out on the 20th day of pregnancy by cesarean. Skeletal system development of fetuses was examined with double and immunohistochemical staining (the tartrate resistant acid phosphatase (TRAP) and the alkaline phosphatase (AP) expressions) methods. The rate of bone-cartilage in hindlimb bones (femur, tibia, fibula) were determined with ImageJ program and data was analyzed using SPSS statistical software.

**Results:** While the most ossification rates of the femur, tibia and fibula were detected as 23.04%, 30.73%, 32.78% in the control group, the least ossification rates were detected as 17.75%, 20.90%, 24.32% in the high dose BPA group respectively. The differences among the control and experimental groups that related to TRAP and AP expressions of femur were determined statistically significant by using immunohistochemical staining (p=0.000).

**Conclusion:** The decrease in the ossification rate of examined bones was in a dose-dependent manner. For the study, Ethics Committee decision number of 15/103 dated on 12.08.2015 was taken.

**Keywords:** Bisphenol A, rat, double staining, immunohistochemical staining, bone development

## O-22

### Evaluation of the effects of acrylamide on 5RP7 fibroblast cells with caspase and annexin V tests, cell cycle analysis, electron and confocal microscopy

Kacar S<sup>1</sup>, Kutlu HM<sup>2</sup>, Şahintürk V<sup>1</sup>

<sup>1</sup>Department of Histology and Embryology, Faculty of Medicine, Eskişehir Osmangazi University, Eskişehir, Turkey; <sup>2</sup>Department of Biology, Faculty of Science, Anadolu University, Eskişehir, Turkey

**Objective:** Number of acrylamide related studies has increased considerably since 2002 when acrylamide was discovered in foods. Nerve cells are generally preferred in these studies. There are not enough studies about the effects of acrylamide on mesenchymal fibroblast cells. In this study, we sought to elaborate the effects of acrylamide on 5RP7 fibroblast cells.

**Methods:** In our study, toxic effects of different acrylamide concentrations on 5RP7 cells were examined by MTT assay. To determine the apoptosis in acrylamide treated and untreated 5RP7 cells, caspase 3/7 and annexin assays were performed and cell cycle analysis was done. Morphological evaluation was carried out by transmission electron and confocal microscopy.

**Results:** The viability of 5RP7 cells decreased with increasing acrylamide doses. IC50 and IC90 of acrylamide were detected as 4.25 and 10.98 mM. In caspase 3/7 test, total apoptosis percentages of control, IC50 and IC90 groups were determined as 4.65, 34.75 and 24.25 while dead cell percentages were 0.20, 0.20 and 40.30, respectively. In annexin V assay, total apoptotic percentages of control, IC50 and IC90 groups were found as 1.95, 11.50 and 52.90 while dead cell percentages were 4.35, 6.90 and 23.25, respectively. In cell cycle analysis, we detected a decrease in proliferating cell number and an increase in sub G1 phase cells with increasing acrylamide dose. In electron and confocal microscopy apoptotic bodies, membrane blebbing, vacuolization, nuclear condensation and disintegration were observed.

**Conclusion:** In 5RP7 cells, acrylamide activates the caspases 3/7, leads to apoptosis and inhibits cell proliferation in a dose-dependent manner.

**Keywords:** acrylamide, 5RP7 cells, annexin-V, caspase 3/7, cell cycle, microscopy



## O-23

**The perspectives of students in faculty of dentistry on anatomical education**Doğan Z<sup>1</sup>, Uludağ Ö<sup>2</sup>, Ateşoğlu S<sup>1</sup>, Üçkardeş F<sup>3</sup>, Aydın A<sup>1</sup><sup>1</sup>Department of Anatomy, Faculty of Medicine, Adiyaman University, Adiyaman, Turkey; <sup>2</sup>Department of Anaesthesiology and Reanimation, Faculty of Medicine, Adiyaman University Adiyaman, Turkey; <sup>3</sup>Department of Biostatistic, Faculty of Medicine, Adiyaman University, Adiyaman, Turkey

**Objective:** Anatomical education has great importance in faculties of dentistry as well as in medical faculties. Accurate and sufficient knowledge of anatomy is required to be also a good physician in dentistry which is a special and unique medical discipline. Knowledge of students' perspectives on anatomical education has great importance in the development of teaching and learning methods in the field of anatomy. In this study, it is aimed to evaluate the thoughts of first grade students in Adiyaman University Faculty of Dentistry about anatomical education and to reveal the contributions of teamwork and interactive education to the learning of the anatomy.

**Methods:** A total of 60 students were included in the study. The data were obtained by feed-back method using a survey consisting of 29 closed-ended questions. The questions of the survey are prepared to be answered with a 5 point Likert scale. The obtained data were analyzed with the SPSS 22.

**Results:** The students were most benefited from the lecture notes while they were studying the theoretical and practical parts of the anatomy. It was found that their satisfaction levels were 88.3% for theoretical part and 85.0% for practical part based on their anatomical education. Regarding the project papers, it was determined that 70% of them begin to show interest to anatomy. Moreover, those papers helped 91.7% to learn the anatomy of that subject and 73.4% to overcome the prejudice "it is difficult to study and understand anatomy".

**Conclusion:** We can argue that the available data are effective in developing educational alternatives related to anatomy, eliminating the existing deficiencies and helping the active participation of the students in their learning thanks to project papers. We also believe that it contributes to overcoming the prejudices of the students to the Anatomy.

**Keywords:** anatomical education, faculty of dentistry, feedback

## O-24

**Analysis of the change in the dimensions of the lumbar area muscles after surgery with MRI**Duman F<sup>1</sup>, Serarslan Y<sup>2</sup>, Öztürk F<sup>3</sup>, Yücekaya B<sup>1</sup><sup>1</sup>School of Physiotherapy and Rehabilitation, Mustafa Kemal University, Hatay, Turkey; <sup>2</sup>Department of Brain and Neurosurgery, Tayfur Ata Sökmen Faculty of Medicine, Mustafa Kemal University, Hatay, Turkey; <sup>3</sup>Department of Radiology Tayfur Ata Sökmen Faculty of Medicine, Mustafa Kemal University, Hatay, Turkey

**Objective:** In the study, the change in the dimensions of the lumbar area muscles in patients with chronic backache was ana-

lyzed with Magnetic Resonance Imaging (MRI) and the results were compared with the healthy individuals to determine the pre and post-surgery effects.

**Methods:** The study group consists of 28 individuals (13F-15M) with an age of 45.39±11.56 who had lumbar area surgery. The morphometric measurements of the lumbar area muscles between L2-S1 levels of these patients were taken through MRI which was taken prior to the surgery and with the purpose of follow-up 6-12 months after surgery. The control group consisted of the retrospective archive images of 37 individuals (18F-19M) with an age of 34.41±10.72 who had no lumbar pathology. In the axial lumbar MRI analysis, the cross-sections of m. multifidus, m. erector spinae and m. psoas major on both sides at the L2-3, L3-4, L4-5, L5-S1 intervertebral disc distance levels were measured with the "closed polygon" measurement technique (1.5 Tesla MR) (Ethical: dated 22/10/2015, No:4298783/05023).

**Results:** In the study group, it was determined that the L2-3 (p=0.017) and L4-5 (p=0.042) levels of the m. multifidus cross section on the right side and L2-3 (p=0.034), L4-5 (p=0.14), L5-S1 (p=0.027) levels and the L5-S1 (p=0.038) levels of the m. erector spinae cross section on the left side were determined to be significantly lower compared to the control group. When the measurements taken pre and post-surgery were compared, it was determined that the right side m. multifidus (p=0.038) and left side m. erector spinae (p=0.031) sectional area was significantly lower compared to pre-surgery at the L5-S1 level.

**Conclusion:** We determined the chronic backache causes atrophy in the lumbar area muscles. With the effect of inactivity, this atrophy was observed to continue in individuals.

**Keywords:** lumbar area muscles, atrophy, lumbar surgery, MRI

September 26, 2017

Hall B (13:00-16:30)

## O-25

**Ol Tışın Çıkrattı (He grinded his tooth)**

Balcıoğlu HA

Faculty of Dentistry, Istanbul University, Istanbul, Turkey

Tooth grinding is given as an example in three successive terms *çıkıradı*, *çıkıraştı* ve *çıkırttı* in *Divanü Lügati't Türk*. It is clearly understood from these examples that tooth grinding was very common even 1000 years ago. Bruxism defining tooth clenching and tooth grinding is an essential parameter in diagnosis and treatment planning in dental sciences and a threat to the stomatognathic system and leads to morphological changes in related structures. In this presentation, disorders that this habit lead and alterations on some anatomical structures will be discussed by means of images provided by various imaging methods.

**Keywords:** bruxism, temporomandibular joint, radiologic anatomy

O-26

**Prevalence of triticeous cartilage in Turkish population**

Vatansever A<sup>1</sup>, Demiryürek D<sup>1</sup>, Tatar İ<sup>1</sup>, Özgen B<sup>2</sup>

<sup>1</sup>Department of Anatomy, Faculty of Medicine, Hacettepe University, Ankara; <sup>2</sup>Department of Radiology, Faculty of Medicine, Hacettepe University, Ankara

In this study, prevalence of triticeous cartilage is investigated retrospectively by using CT (computed tomography) images in Turkish population. In our study, 368 women, 378 men, totally 746 patients who had CT angiography examination were evaluated. Presence and morphological properties of triticeous cartilage were examined and compared between genders. According to our results, 68.1% of patients has at least one triticeous cartilage. Prevalence of triticeous cartilage in men is higher than women in Turkish population and this result is statistically significant. Additionally, men have bigger size of triticeous than women according to morphological measurements such as length, width and volume. The most common observed shape of triticeous cartilage in Turkish population is oval shape with 42.5% ratio and the less common observed shape of triticeous cartilage is tear-shape, 2.8%. As a result of evaluation of ossification degree, we demonstrate that 29.3% of patients have cartilaginous type triticeous, 17% of patients have mild triticeous ossification, 26.7% of patients have moderate triticeous ossification and 27% of patients have marked triticeous ossification. Negative but statistically significant correlation between age and ossification degree is identified. Comparison of ossification degree to gender revealed no significance.

**Keywords:** larynx, triticeous cartilage, anatomy, CT angiography

O-27

**Factors related to sublingual varices: descriptive clinical study**

Ölmez D<sup>1</sup>, Akkaya N<sup>1</sup>, Özkan G<sup>2</sup>

<sup>1</sup>Department of Dentomaxillofacial Radiology, Faculty of Dentistry, Hacettepe University, Ankara, Turkey; <sup>2</sup>Department of Dentomaxillofacial Radiology, Faculty of Dentistry, Adnan Menderes University, Aydın, Turkey

**Objective:** Age is considered as an important etiological factor for the development of sublingual varices. In addition, it has been thought that some conditions such as systemic diseases, smoking, denture wearing may play a role in etiology. Aim of this study was to investigate relationship between sublingual varices and these conditions which are described as possible risk factors previously.

**Methods:** A total of 691 patients (470 females, 221 males) who attended for comprehensive clinical examination were included in the study. Age, systemic diseases, duration of disease, medication and its duration, history of chronic cough, leg varicosities, smoking status, denture wearing were recorded during the history taking. Sublingual varices classified as two categories: Stage 0 (few or none visible) and Stage 1: (moderate or severe). Tongue photographs were taken from a group of these patients. For the eval-

uation of intraobserver reliability, photographs rescored by the observer. Intraobserver reliability was evaluated by Kappa statistics. Pearson chi-square test was used for identification of possible risk factors, then logistic regression analysis was applied.

**Results:** Kappa value of intra-observer reliability was 0.91. Sublingual varices were significantly associated with age (OR: 1.08, p = 0.000), hypertension (OR: 2.3, p=0.007) and denture wearing (OR: 2.17, p=0.02).

**Conclusion:** Sublingual varices should be considered not only as physiological condition that can develop with aging but also condition that may be related denture wearing or as an intraoral finding indicating hypertension.

**Keywords:** early diagnosis, hypertension, sublingual varices, aging

O-28

**Morphometric properties of latissimus dorsi muscle in human fetuses for flap surgery**

Beger O<sup>1</sup>, Beger B<sup>2</sup>, Uzmansel D<sup>1</sup>, Erdoğan S<sup>3</sup>, Kurtoglu Z<sup>1</sup>

<sup>1</sup>Department of Anatomy, Faculty of Medicine, Mersin University, Mersin, Turkey; <sup>2</sup>Department of Pediatric Surgery, Faculty of Medicine, Yüzüncü Yıl University, Van, Turkey; <sup>3</sup>Department of Biostatistics, Faculty of Medicine, Mersin University, Mersin, Turkey

**Objective:** Although latissimus dorsi (LD) flaps are used extensively in a wide range of interventions, fetus studies on this subject are quite limited. This study aims to obtain detailed information about the morphometric structures of LD, thoracodorsal artery (TDA) and nerve (TDN).

**Methods:** The study was carried out on 50 formalin fixed human fetuses (22 male/28 female) with a mean gestational age of 24.5±4.7 (range 18–36) weeks, which were in the inventory of Anatomy Department of Mersin University Faculty of Medicine, by bilateral dissection. Surface area was calculated using digital image analysis software.

**Results:** Linear function of surface area was calculated as “y= -1767.532+114.582 × Age (weeks)”. LD attached directly to the posterior part of iliac crest in 59 of 100 sides meanwhile in the rest 41, it was attached by thoracolumbar fascia. TDA gave a branch to the serratus anterior in 96 cases and 2 branches in 4 cases. TDN passed through the superficial of TDA in 84 and deep of TDA in 16 samples. TDN had bifurcation in 93, trifurcation in 6 and tetrafurcation in 1 side.

**Conclusion:** The data obtained from this study can be beneficial, especially in neonate and early childhood surgeries. Linear function of LD surface area can be used to design the flap dimensions in newborn surgeries. A throughout knowledge about the branching pattern of TDN and its locational relation with TDA can be used to prevent possible complications during harvesting of LD flaps and TDN grafts.

**Keywords:** latissimus dorsi, thoracodorsal artery, thoracodorsal nerve, surface area, fetus.

**O-29****Investigation of upper extremity muscle development with microscopic method in human fetuses**

Malas MA<sup>1</sup>, Çizmeçi G<sup>1</sup>, Akyol Bahçeci S<sup>2</sup>, Ay Keselik G<sup>1</sup>, Erdoğan K<sup>1</sup>

<sup>1</sup>Department of Anatomy, Faculty of Medicine, Izmir Katip Çelebi University, Izmir, Turkey; <sup>2</sup>Department of Histology and Embryology, Faculty of Medicine, Izmir Katip Çelebi University, Izmir, Turkey

**Objective:** Most studies on muscle fiber development appear to have been made in animal or human fetuses after birth. Very few studies have examined the developmental parameters of the muscles of the intrauterine period. Most of the studies focus on the morphometric properties of various muscles. In our study, the developmental parameters of the upper extremity muscles in the fetal period were examined from the proximal to the distal in terms of average fiber count and parenchymal / stroma rates.

**Methods:** For this purpose, 17 sample of human fetuses without external anomalies were taken from m.deltoideus, m.biceps brachii and m.flexor carpi radialis muscles and the trends of upper extremity muscle development were assessed proximal to distally. The histological sections taken for the examination were measured using stereological method.

**Conclusion:** When we compare the average fiber count per week in all three muscle groups (M. deltoideus, M. biceps brachii and M. flexor carpi radialis); have followed an increasing trend in the progressive trimester of development from the first trimester. Paranchima / stroma ratio was lower in one and second trimester than in third trimester and full term. When 3 different muscle parenchyma / stroma ratios were evaluated, the highest rate was observed in M. deltoideus. M. biceps brachii and M. flexor carpi radialis were found near values. Increased knowledge of intrauterine period will provide useful information on the possible emergence of future diseases.

**Keywords:** muscle development, fetal development, M. deltoideus, M. biceps brachii, stroma, parenchyma

**O-30****Innervation pattern of lumbrical muscles of the foot in human fetuses**

Kara BA, Uzmannel D, Beger O

Department of Anatomy, Faculty of Medicine, Mersin University, Mersin, Turkey

**Objective:** The main objective of this study is to describe the innervation patterns of foot lumbrical muscles and its morphological properties in human fetuses. Another objective is to define the communicating branches between medial (MPN) and lateral (LPN) plantar nerves, which play a part in innervation of those muscles.

**Methods:** Thirty formalin-fixed fetuses (13 male–17 female) with a mean gestational age of 25.5±3.8 (range, 18–36) weeks

within the inventory of Mersin University Faculty of Medicine Anatomy Department were bilaterally dissected. Innervation pattern of lumbricals and the communicating branches between MPN and LPN were detected and photographed.

**Results:** No variations were seen within the lumbrical numbers. Out of 60, first lumbrical started directly from flexor digitorum longus tendon in 48 and flexor hallucis longus slips in addition to flexor digitorum longus tendon in 12 sides. 55 feet had classic innervation pattern of lumbricals while 5 had variations. No communicating branches were seen in 48 sides whereas 12 sides had connection.

**Conclusion:** This study classified innervation pattern of foot lumbricals and defined 2 new innervation types. During surgeries on foot and ankle region in neonatal and early childhood terms, awareness of the communicating branches between MPN and LPN and innervation of intrinsic muscles of the foot such as lumbricals might aid in preventing possible complications.

**Keywords:** muscles, medial plantar nerve, lateral plantar nerve, foot, fetus

**O-31****The changes in the human nervous system with age and the graceful aging**

Durgun B

Çukurova University, School of Medicine, Department of Anatomy, Adana, Turkey

**Objective** The purpose of this presentation is to review the age-related modifications which occur in the human nervous system and the effects of graceful ageing on these changes.

**Methods:** Rather than reviewing the bodies of literature, this review is focused selectively on empirical and theoretical works about the changes in the integration of the nervous system's functions that have yet not well-documented.

**Results:** The changes occur in the human nervous system with advancing age. These changes affect the processes and the integration of sensory-motor-cognitive functions. Thus, manual dexterity, eye-hand coordination, accuracy in reaching-aiming movement and reaction time reduce. Reaction time affects perception and memory as well as the soundness of various reflexes. The decline in the synthesis of catecholamines, dopamine and serotonin. impairs the processing of information and, sometimes, increase the risk of depression. Age is assumed to have a negative impact on cognitive skills, however, it has a positive impact on work performance. Therefore, older workers bring many benefits with them. Some of which include increased reliability, greater commitment and dedication to duty, decreased turnover and absenteeism, diversity of experience, orientation to detail, focusing and attentiveness.

**Conclusion:** Graceful ageing indicates the successful ageing that is achieved by the active social and cognitive engagement by improving cognition. Overall, strong evidence demonstrates

that compared to less active men and women, older adults who are physically active exhibit higher levels of functional health, a lower risk of falling, and better cognitive function, reduced risk of moderate and severe functional limitations.

**Keywords:** aging; graceful ageing; human nervous system; sensory- motor-cognitive functions

### **O-32**

#### **Rational drug use**

Gülhan R

*Department of Medical Pharmacology, Faculty of Medicine, Marmara University, Istanbul, Turkey*

According to estimates by the World Health Organization (WHO), more than 50% of medicines are prescribed, supplied or sold inappropriately. Half of all patients do not use their medication properly. For the first time in WHO's meeting in Kenya-Nairobi in 1985, drug use was assessed on a rational basis according to efficacy, safety, suitability and cost criteria. It is defined such as the rational use of drugs requires that patients receive medications appropriate to their clinical needs, in doses that meet their own individual requirements for an adequate period of time, and at the lowest cost to them and their community. The appropriate drug must be effective, and of acceptable quality and safety. The steps of rational drug use (RDU) can be summarized as defining the actual problem of the patient, defining the correct diagnosis by the physician, defining effective and reliable treatment with or without medication, evaluating the feasibility and cost of the treatment, the success of the treatment and evaluation of the drug's suitability for the patient. Current diagnostic and therapeutic guidelines should be used throughout this process. In order for the RDU process to be completed correctly, the patient and his/her relatives should be adequately informed about the treatment.

**Keywords:** diagnosis, rational drug use, treatment

### **O-33**

#### **Polyesterization**

Meker M<sup>1</sup>, Aycan K<sup>1</sup>, Tahta Y<sup>2</sup>, Öztürk M<sup>1</sup>, Atay E<sup>3</sup>

*<sup>1</sup>Department of Anatomy, Faculty of Medicine, Erciyes University, Kayseri, Turkey; <sup>2</sup>Training and Research Hospital, Niğde Ömer Halisdemir University, Niğde, Turkey; <sup>3</sup>Department of First and Emergency Aid, Niğde Zübeyde Hanım Vocational School, Niğde Ömer Halisdemir University, Niğde, Turkey*

Although there are many studies that, with the plastic injection is used to examine the structure of the vessels and hollow organs, we did not across that examined the anatomy of the template. Today, supply of cadavers that one of the greatest hardship and difficult experienced in the storage of cadavers available have increased their way and more valuable. While most modern method of plastination method of our time in the cadaver storage has some disadvantages in terms of cost and time. At our work we made organs work we have done to polyester made education and research materials. In our study, the high pressure of sheep kidney

was removed by injection molding of plastic. Buying sheep kidneys from mezbaan, after cleaning and purified from oil was cannulated vessels. Blood clots are washed with normal saline for intravenous operation fails cleaned. After that mixed from polyester is applied from the high pressure vessel for removal of the mold prepared polyester blend kidney. The negative effect was seen on the process that the bottlenecks in the process and incision. Injection molding process applied after the kidney was removed appropriated conditions are met. The resulting dry kidney molds sterile was moved. In this way the anatomy of kidney at anatomy laboratory findings were seen in the kidney could be used as training and research materials. Today the preservation of cadaver anatomy education is the biggest challenge, we believe that our study shed light on the new study.

**Keywords:** cadaver, kidney, anatomy models, polyester, injection

### **O-34**

#### **Clinical evaluation and functional anatomic importance of the ligamentum talofibulare anterius and ligamentum calcaneofibulare during injury of the inverted foot**

Yıldız S, Yalçın B

*Department of Anatomy, University of Health Sciences, Gülhane Faculty of Medicine, Ankara, Turkey*

Inversion injuries of the ankle are the most common sport injuries. Extreme inversion of the ankle effects frequently lateral ankle ligaments. Effected are especially the anterior talofibular and calcaneofibular ligaments. The aim of this study is to contribute to accurate evaluation of radiological investigations and more precise surgical interventions by clarifying the anatomic structure of the ligaments by considering their functional importance. In our study, length at the origin and width on the midpoint of the anterior talofibular ligament and calcaneofibular ligament, digits, length and width of the bands of ligamentum talofibulare anterius, digits, length width of the connector ligaments extending from the talus to calcaneus were measured on the forty six ankle junction. In addition, angle between these ligaments and angle between longitudinal axis of the fibula and both ligaments were measured. Relationship between determined variables, right and left sides variables were statistically analyzed. Furthermore, if any existing of the connector ligaments, ligamentum talofibulare anterius were classified. In diagnosis and treatment methods, clinical importance of anatomy of lateral collateral ligaments of the ankle especially ligamentum talofibulare anterius and ligamentum calcaneofibulare were frequently reported in the literature. Especially, angular measurements benefit in the determination of the ligament injury. Therefore knowledge about normal anatomic angles between each other and angles between longitudinal axis of the fibula and both ligaments were certainly important for the correct diagnose. During the surgical invention, length and width of the ligaments are necessary to determine quantity of ligament loss.

**Keywords:** ligamentum calcaneofibulare, ligamentum talofibulare anterius, inversion injury

**O-35****The effect of anthropometric body measurements on static balance parameters: preliminary study results**Metin Tellioglu A<sup>1</sup>, Aydın E<sup>2</sup>, İpek ED<sup>1</sup><sup>1</sup>Department of Anatomy, Faculty of Medicine, Adnan Menderes University, Aydın, Turkey; <sup>2</sup>Department of Physical Medicine and Rehabilitation, Faculty of Medicine, Adnan Menderes University, Aydın, Turkey

**Objective:** Balance is defined as the ability to maintain the standing position, to stabilize during voluntary movements and to react accordingly to external influences. Balance mechanism of the body is provided by the cooperation of the visual system, proprioceptive system and the vestibular system. The aim of this study is to investigate whether the body anthropometric measurements have an effect on the static balance parameters.

**Methods:** Permission was obtained from Adnan Menderes University Ethics Committee for the study (Protocol No: 2017/1192). A total of 59 healthy volunteers (23 females, 36 males aged 18–26 years) participated in the study and fifteen measurements were taken. Circumference measurements; head, chest, waist, hip circumference, width measurements; biacromial, bitorakanteric, biiliac, bimalleolar width, length measurements; upper extremity, arm, forearm, relative lower extremity, actual lower extremity, thigh and leg length. Static balance measurements of the volunteers were made on pressure platform with a total of 4096 sensors capable of measuring at a frequency of 300 Hz/cm<sup>2</sup> at size of 578×418 cm. Anteroposterior and mediolateral oscillations and total body oscillation were recorded. The relationship between anthropometric measurements and balance measurements was examined by Spearman correlation analysis.

**Results:** There was strong correlation between measurements of anteroposterior oscillation, bitrochanteric width ( $r=0.557$ ), right thigh length ( $r=0.456$ ), left thigh length ( $r=0.448$ ), right leg length ( $r=0.503$ ), left leg length ( $p<0.005$ ).

**Conclusion:** There is a correlation between anthropometric measurements and balance. There is a positive strong correlation between the leg length and the anteroposterior oscillation.

**Keywords:** anthropometry, body measurements, balance

**O-36****Relationship between intercoccygeal angle and coccyx types and gender**Çiftcioglu E<sup>1</sup>, Mıdık Ö<sup>2</sup><sup>1</sup>Department of Anatomy, Ondokuz Mayıs University, Samsun Turkey; <sup>2</sup>Department of Medical Education, Ondokuz Mayıs University, Samsun Turkey

**Objective:** The aim of this study is to evaluate intercoccygeal angle in asymptomatic adult patients, to investigate the relationship between intercoccygeal angle and coccyx types and sex.

**Methods:** 100 patients who had computerized tomography (CT) for different reasons and who did not have coccydynia were retrospectively analyzed. Intercoccygeal angle, lumbosacral angle

and coccyx types were investigated and evaluated statistically on CT images.

**Results:** In most cases (70%), 4 segments were noted (average  $3.92\pm0.72$ ). Lumbosacral angle varied from  $16.7^\circ$  to  $66.4^\circ$  (average  $41.38^\circ\pm12.66^\circ$ ), and intercoccygeal angle from  $11.5^\circ$  to  $95.6^\circ$  (average  $43.94^\circ\pm20.88^\circ$ ). The following types of coccyx (type's I–IV according to Postacchini and Massobrio classification) were observed in the study group: type I in 53%, type II 29%, type III 13%, and type IV 5% cases. Twenty-five females and 28 males had type I coccyx with mean intercoccygeal angle  $39.84^\circ\pm18.63$  and the difference of the angles between genders is statistically significant ( $p<0.05$ ). Among 29 patients (14 were females and 15 were males) with type 2 coccyx demonstrated mean intercoccygeal angle of  $50.35^\circ\pm19.57$ . Thirteen patients were shown to have type 3 coccyx and the mean intercoccygeal angle was  $63.68^\circ\pm13.88$ . The average intercoccygeal angle value of the 5 patients with type IV coccyx was  $47.16\pm10.19$ .

**Conclusion:** Our research could be useful to help together with clinical history, future studies of associations between idiopathic coccygodynia and coccyx morphology.

**Keywords:** coccyx, intercoccygeal angle, coccydynia, anatomy

**O-37****Assessment of intraosseous cannulation techniques of distal tibia**

Develi S

Department of Anatomy, University of Health Sciences, Gülhane Faculty of Medicine, Ankara, Turkey

**Objective:** Besides establishing airway and ventilation, securing intravascular access is crucial for patients who need emergency first aid. Peripheral intravenous catheter insertion can be difficult in some patients, especially with circulatory collapse or catheter insertion can be interrupted during transportation of the patient. Intraosseous needle placement provides a secured vascular access for administering fluids. Intraosseous cannulation is effective as intravenous route and can be inserted quickly. We aimed to evaluate the guidelines of Intraosseous techniques in dry bones of our population.

**Methods:** 73 dry Tibia were examined (35 left–38 right). All of the bones were belonged to Turkish adults. There was no pathology in the distal part of each tibia. According to guidelines of cannulation of distal tibia, insertion site is described as 2 cm above tip of medial malleolus. Insertions are done horizontally by manual catheters or intraosseous cannulation devices. We examined distal tibia in terms of nutrient forams, emissary veins, epiphysal plate levels and length for safe insertions.

**Results:** Mean length of malleolus medialis was found to be 23.64 mm. Horizontal length of distal tibia at the insertion level was found to be 39.57 mm.

**Conclusion:** Although our sample size is low, our results show that insertion site should be at least 3 cm above tip of malleolus medialis in Turkish population, in order not to cannulate intraarticular space. Most of the catheters used in Intraosseous

cannulation are 45 mm in length. Thus oblique insertion should be preferred than horizontal insertion in our population.

**Keywords:** distal tibia, interosseous cannulation, intravascular intervention

### **O-38**

#### **The investigation of anatomy of arteria testicularis in cattle and ram by plastic injection and corrosion method**

Tahta Y<sup>1</sup>, Aycan K<sup>2</sup>, Meker M<sup>2</sup>, Öztürk M<sup>2</sup>, Atay E<sup>3</sup>

<sup>1</sup>Training and Research Hospital, Niğde Ömer Halisdemir University, Niğde, Turkey; <sup>2</sup>Department of Anatomy, Faculty of Medicine, Erciyes University, Kayseri, Turkey; <sup>3</sup>Department of First and Emergency Aid, Niğde Zübeyde Hanım Vocational School, Niğde Ömer Halisdemir University, Niğde, Turkey

In recent years, there has been an increase in the using of radiographic methods in the examination of vessels. However, radiographic methods do not adequate to determination of the structural features, anastomoses and variations of vessels. In our study, we aimed to investigate anatomy of arteria testicularis in cattle and ram by plastic injection and corrosion method. In our study, 10 cattle and 10 rams were used. Before starting the injection procedure, the testes were carefully cleaned, paying attention to the vascular and parenchymal structure. Then arteria testicularis was cannulated and prepared for plastic injection. Polyester was injected into the testicular artery. The testes were kept at room temperature for 48–72 hours to solidify the polyester in the vessel. The obtained corrosion casts were examined macroscopically. The findings were photographed. It was determined that the terminal branches of the two cattle and four ram testes arteria testicularis involved in the study were not completely filled with plastic material. In 8 cattle and 6 rams included in the study, arteria testicularis was completely filled with plastic material. In general, in the corrosion casts of both species, the arterial testicularis showed very convoluted distribution in the funiculus spermaticus. In both species, when the arteria testicularis reaches the extremitas inferior of the arterial testis, two main branches are separated. These branches were observed to form a vascular network on the surface of tunica albuginea. As a result; although the course of the testicular artery in both species is similar, there are differences.

**Keywords:** testis, artery, plastic enjection, cattle, ram

### **O-39**

#### **A comparative morphometric basic analysis of patients with pure low back pain and lumbar intervertebral disc herniation**

Köksal V<sup>1</sup>, Avnioğlu S<sup>2</sup>, Atay E<sup>3</sup>, Ertekin T<sup>4</sup>, Yılmaz S<sup>5</sup>

<sup>1</sup>Department of Neurosurgery, Faculty of Medicine, Recep Tayyip Erdoğan University, Rize, Turkey; <sup>2</sup>Kahramanmaraş Health College, Kahramanmaraş Sütçü İmam University, Kahramanmaraş, Turkey; <sup>3</sup>Health Services Vocational School, Niğde Ömer Halisdemir University, Niğde, Turkey; <sup>4</sup>Department of Anatomy, Faculty of Medicine, Afyon Kocatepe University, Afyonkarahisar, Turkey; <sup>5</sup>Department of Anatomy, Faculty of Medicine, Bozok University, Yozgat, Turkey

**Objective:** Intervertebral Disk Degeneration (IVDD) is an inevitable result of our lives. Some authors have reported that the lumbar pain in our daily lives may change depending on IVDD, age, genetic origin, smoking, obesity and vertebral level. There are few morphometric MRI studies in the literature conducted on IVDD change between individuals. In this study, the issue of whether there was a difference between the group whose intervertebral disk integrity was disrupted and the group who only had pure lumbar pain in terms of degenerative change in the lumbar vertebra was investigated.

**Methods:** In our study, 10 patients who applied to Recep Tayyip Erdoğan University Hospital with the diagnosis of lumbar disk hernia and who were not operated among the patients applying with lumbar pain, and 10 control patients who did not have any lumbar disk hernia were included. The disk and vertebra volumes were evaluated with the Cavalieri Method in stereological terms.

**Results:** No differences were detected between the Patient and Control Groups in terms of vertebral body volume ( $p>0.05$ ). The differences between the Groups were statistically significant in terms of body front and rear measurements ( $p<0.05$ ). It was determined that the Control Group had higher values than the Patient Group. It was also determined that the body volume values increased with furthering age although it was not at a statistically significant level.

**Conclusion:** It is understood that intervertebral disk protects the vertebra corpus from receiving more degeneration.

**Keywords:** intravertebral disk degeneration, lomber disk, low back pain, stereology

---

**September 27, 2017**

**Hall A (09:30-11:40)**

---

### **O-40**

#### **Efforts to reduce formaldehyde exposure in Mersin Anatomy Laboratory and experiences on updated specific ventilation system components**

Kurtoğlu Z, Öztürk AH, Kara AB, Uzmansel D, Öztürk NC

Department of Anatomy, Faculty of Medicine, Mersin University, Mersin, Turkey

While the working conditions of the some laboratories, which carry intensive chemical or biological risks in Turkey are controlled by specific instructions, such a mechanism for anatomy laboratories has not yet been put into practice. However, anatomy laboratories are exposed to intense chemicals as much as pathology laboratories. This exposure affects both laboratory workers and large numbers of students. The purpose of this presentation is to draw attention to the possible weaknesses in designing laboratories in respect to “Occupational Health and Safety (OHS)” and to emphasize the need to create a culture for following the ways to reduce formaldehyde exposure at the anatomy departments. Upon our invitation, Anatomy Laboratory has

been audited by specialists from the Occupational Health and Safety Unit Mersin University. The weaknesses of the laboratory, necessity of improvement and recommendations was reported to the university administration. A study was conducted to overcome the formaldehyde exposure, which has been scored as “intolerable risk group” by OHS specialists: Possible sources of formaldehyde and specific working conditions were handled one by one. The large part of remediation works was completed by taking some laboratories having successful ventilation system as reference. With this presentation, it is planned to share experiences about the problems of our laboratory, the troubles encountered during the solution process of these problems and the specific equipments that have been acquired. It is also intended to emphasize the need for auditing mechanisms to control “Occupational Health and Safety” conditions in the anatomy laboratories of Turkey.

**Keywords:** anatomy laboratory, formaldehyde, occupational health and safety, ventilation

#### O-41

##### The most frequently used statistical methods in anatomy

Özdemir F<sup>1</sup>, Turgal E<sup>2</sup>, Gölpinar M<sup>3</sup>

<sup>1</sup>Department of Anatomy, Faculty of Medicine, Hitit University, Çorum, Turkey; <sup>2</sup>Department of Biostatistics, Faculty of Medicine, Hitit University, Çorum, Turkey; <sup>3</sup>Department of Anatomy, Faculty of Medicine, Ondokuz Mayıs University, Samsun, Turkey

In this study, we aimed to show the most frequently used statistical methods in anatomy studies, which test should be used in which study, and what the most common mistakes are. Before starting a study, number of subjects, patients or animals is required for the ethics committee application. For this, a power analysis should be done for the average subjects. After obtaining data in statistical calculation, if we are going to compare two independent groups, first we must evaluate whether they show a normal distribution; if the data is normally distributed, we must use independent t test, if not we must use Mann-Whitney U. If we compare two dependent groups and data is normally distributed, we must use paired t test, if not, we must use Wilcoxon paired sample two test. If the number of groups are more than two and data shows a normal distribution and homogeneity are achieved, the difference between the groups examined by ANOVA. If the normality is not provided, Kruskal-Wallis test is performed. Test Re-test method is used to determine the reliability of the same test in reliability studies when test form is applied to the same group at two different intervals. The most important mistakes for researchers are which test will be performed in the study. Dependent and independent variables can be qualitative, quantitative. These types effect the test pattern and are often confused with each other. The right test gives the right result so that the labor and time spent are not wasted.

**Keywords:** analysis, anatomy, statistics, method

#### O-42

##### The evaluation of healthcare practitioners overview of anatomy education

Karataş T<sup>1</sup>, Canpolat M<sup>2</sup>, Şenol D<sup>2</sup>, Özbağ D<sup>2</sup>

<sup>1</sup>Malatya Training and Research Hospital, Malatya, Turkey;

<sup>2</sup>Department of Anatomy, Faculty of Medicine, İnönü University, Malatya, Turkey

**Objective:** We aimed to evaluate the views of healthcare practitioners on the anatomy education they had during their training.

**Methods:** For our work, a questionnaire consisting of twelve questions was prepared. The questionnaire was applied to 417 volunteer healthcare practitioners. The participants were asked, whether or not they had received sufficient theoretical and practical training in anatomy. They were also asked whether their anatomical knowledge was adequate at present and their views on training on postgraduation anatomy. In addition to these questions, two more questions were asked to measure their anatomy knowledge. The information obtained was recorded and evaluated.

**Results:** Four hundred seventeen people attended our questionnaire. The 55.6% of the participants were nurses, 10.1% were midwives, 7% were health officers, 11.3% were radiology technicians, 1.9% were anesthesia technicians, 11.3% were laboratory technicians and 2.9% were physiotherapists. 45.3% of the participants stated that they had on adequate level of anatomy training, 54.7% did not have, 43.9% of them they felt their knowledge on anatomy was already adequate, 56.1% felt that they were inadequate, 80.6% stated that postgraduation anatomy training was necessary, 19.4% stated that postgraduation anatomy training was unnecessary. 80% of assistant health personnel answered both questions correctly and 5% answered both questions wrongly. 15% answered a question correctly.

**Conclusion:** As a result in the evaluation process of the questionnaire the majority of the participants did not have adequate anatomy training, their anatomical knowledge was inadequate and postgraduate anatomy training was necessary.

**Keywords:** anatomy, anatomy education, assistant health personnel

#### O-43

##### The perceptions of academic members participating in Ondokuz Mayıs University School of Medicine Faculty Development Courses about educational competencies and educational needs

Mıdık Ö<sup>1</sup>, Çiftcioglu E<sup>2</sup>

<sup>1</sup>Department of Medical Education, Faculty of Medicine, Ondokuz Mayıs University, Samsun Turkey; <sup>2</sup>Department of Anatomy, Faculty of Medicine, Ondokuz Mayıs University, Samsun Turkey

**Objective:** In this study, the perceptions of the academic members participating in the “Educator’s Education” Program were

examined regarding their educational competencies and their educational needs.

**Methods:** In the development of the evaluation tool, Heskett's educational competency titles were utilized. There are 101 items in the 3 outcome, 12 competency areas. Frequency, percentage distributions for quantitative descriptive data, and chikare analysis for comparative data were used.

**Results:** Since 2011, there have been seven courses with 131 participants. The response rate of the questionnaire was 58% (76/131) and 67.1% were male. While there is equal participation from internal and surgical fields (40.8%), the number of faculty members participating in basic science fields is 18.4%. Instructors find themselves 'less well' in terms of competencies. Among the topics that they do not know are teleconferencing, video and education, distance education are the most frequently mentioned topics. Educators working in surgical sciences need less training than other teaching professors in basic and internal sciences. Women represent more educational needs than men.

**Conclusion:** Instructors working in basic sciences say that they need education even if they find themselves adequately. The faculty members working in the surgical sciences have topics that they do not express as necessity even if they find them at a low level. This can be attributed to the fact that the interest in the training is low or that it is not an instructor task or it cannot be trained in the titles mentioned.

**Keywords:** medical education, educational needs, educator's education

#### **O-44**

##### **Biomedicine for anatomy, anatomy for biomedicine**

Usta A

*Faculty of Health Sciences, Üsküdar University, Istanbul, Turkey*

21st century has been evaluated as the biomedical era. Although biomedical sciences comprise many non-medical disciplines, these have to eventually aim to serve for benefit of human health. Knowing about gross or microscopic level human body structure has become a necessity for not only physician but also other biomedical professionals. Anatomy, as a medical basic science discipline, has very explicit contribution to biomedical areas, at the same time, a reverse influence as a matter of course has come along. While this reverse interaction has found a prompt space in anatomy education, anatomists have also obtained some new valuable biomedical technical tools to use in their research.

**Keywords:** anatomy, biomedicine, education, research

#### **O-45**

##### **Can 3D printers be used in anatomy education?**

Özgür S

*Department of Anatomy, Celal Bayar University, School of Medicine, Manisa, Turkey*

**Objective:** When we looked at the routine of anatomy education up to now, we see that it has gone through many different periods. Especially recently, it is observed that these changes have followed technological developments. With "Industry 4.0" defined in 2011, the production of materials all over the world has been switched to cost-effective, achievable, and less environment friendly production models. Parallel to this approach, the use of 3D printers instead of machines using shavings has become widespread. With a wide variety of versions, the most popular and available of these commercial printers are those making models by draining a plastic filament from a thin hot tip called "Fused Filament Deposition". For this purpose, we carried out this study to see whether or not actual bone chips can be replicated.

**Methods:** In our study, 3 different femoral virtual objects created by photogrammetry method in 3D, from one of the previous studies, were used. The virtual objects were sliced with the Simplfy3d program and were printed with 2 different brands of (TEVO Little Monster and Prusa MK2s) 3 dimensional printers using PLA plastic at a ratio of 1/2. Length measurements on actual bones and bones obtained were compared proportionally with each other to calculate the changes.

**Results:** It is observed that the measured values showed a dimensional variation of less than 0.5% between real bones and 3D printed bones, and the analyses show that they can be copied as good as the real ones.

**Conclusion:** It is seen that 3 dimensional printers can be used for model printing and bones can be printed proportionally. With the widespread use of such technologies, it is possible to develop low-cost materials that can meet the needs of students.

**Keywords:** 3 dimensional printer, anatomy education, anatomical model

#### **O-46**

##### **Modeling and building of different temporal bone types containing variations with surgical importance by 3-dimensional (3D) printers**

Güner MA

*Department of Anatomy, Faculty of Medicine, Ankara University, Ankara, Turkey*

Temporal bone and its surroundings are a region where surgical treatments are frequently applied. It is important to note the anatomical boundaries and formations of this region as well as in all surgical procedures in order to minimize the complication rates. For performing effective surgical applications, it is necessary to define the anatomical structures correctly and to know the possible variations. Many variations have been described, such as the Koerner's septum, dura mater or facial nerve canal dehiscence and narrow antrum, which are important in temporal bone surgery. However, the mentioned variations are not emphasized enough in classical textbooks. Therefore, there is a lack of material that can be used in the related surgical training. For this reason, we introduced a project related with the normal and the



variational anatomy of the temporal bone and its structures that have the surgical importance. Firstly, the normal anatomy was compiled and modeled in the software environment via tomography images and after that these variations were redesigned. A model with normal anatomy were printed with transparent material so that the structures inside the bone could be observed from the obtained images. For this reason, it is also possible to build the surgical field with the 3D printers and to make the surgical planning from the patient's images before performing the surgery by the obtained models and modeling method which will be developed in a similar manner.

**Keywords:** temporal bone, 3D, surgical planning, variation

#### O-47

##### Spinal precerebellar nuclei: a new description

Şengül G

*Department of Anatomy, Faculty of Medicine, Ege University, Izmir, Turkey*

**Objective:** Projections from the spinal cord to the cerebellum have been investigated using degeneration techniques, autoradiography and anterograde and retrograde tracing methods in experimental animals and by observing degeneration in the human. Most of these projections are classically considered to be

mainly from scattered neurons in the deep dorsal horn and spinal laminae VI-VIII, except for the dorsal nucleus (of Clarke).

**Methods:** However, we have described with retrograde tracing studies in the mouse (Sengul et al., 2015) and also with staining techniques in our rat, mouse, monkey and human spinal cord atlases (Sengul et al., 2013) that, indeed, there are other spinal precerebellar nuclei organized as columns similar to the dorsal nucleus, throughout the length of the spinal cord.

**Results:** With this new description, the spinal precerebellar nuclei are organized as follows: the central cervical nucleus is in the cervical, dorsal nucleus in the thoracic and upper lumbar segments, the newly described lumbar precerebellar nucleus and the lumbar border precerebellar cells in the lumbar segments, and the sacral precerebellar nucleus in the sacral and coccygeal segments (formerly described as Stilling's sacral nucleus in the sacral segments).

**Conclusion:** Retrograde tracing in the mouse has shown that except for the central cervical nucleus which has a predominant projection to the contralateral cerebellum, the other four spinal precerebellar nuclei all have mainly ipsilateral projections to the cerebellar cortex. The majority of spinocerebellar projections were to the vermis. All five precerebellar cell columns projected to both anterior and posterior parts of the cerebellar cortex.

**Keywords:** dorsal nucleus, precerebellar nucleus, projection, spinal cord

## Poster Presentations

(P-1 — P-115)

### P-1

#### Medical students' perception of cadaver images in anatomy education and scientific research

Gürses İA<sup>1</sup>, Coşkun O<sup>1</sup>, Gürtekin B<sup>2</sup>, Gayretli Ö<sup>1</sup>, Kale A<sup>1</sup>, Öztürk A<sup>1</sup>

<sup>1</sup>Department of Anatomy, Istanbul Faculty of Medicine, Istanbul University, Istanbul, Turkey; <sup>2</sup>Department of Biostatistics, Istanbul Faculty of Medicine, Istanbul University, Istanbul, Turkey

**Objective:** Fast implementation of technological developments, such as digital photographs and videos, in education and research gave birth to new ethical obstacles. We aimed to outline medical students' perception on the acquisition, use, and distribution of cadaver images.

**Methods:** After obtaining ethical approval (date: 25.05.2016; number: 677), qualitative data from students were collected via an online survey. We asked the students to evaluate the use of cadaver images by the anatomy department (AD) and by students themselves.

**Results:** Nine-hundred-and-forty students participated to the study. Students agreed that the AD should use images in research (median: 5), theses (median: 5), and presentations (median: 5). They agreed that the AD should use images to produce lecture notes (median: 5), atlases (median: 5), and educational videos (median: 5). For research (75.5%) and education (72.9%), permissions from the donors should be acquired prior their death. Their opinions varied regarding student acquired images. They agreed that using and sharing these images without donor consent was unacceptable (median: 1). They were unsure about images from unclaimed cadavers (median: 3). They agreed that student acquired images could be considered as educational material (median: 4). They also agreed that some situations allowed the use of these images, such as inadequate lecture notes (median: 4), cadaver / student ratio (median: 4), wish to get high grades (median: 4), and wish to become a better physician (median: 4).

**Conclusion:** It is apparent that factors like student expectations and number of cadavers utilized affects students' ethical boundaries regarding cadaver images.

**Keywords:** anatomy education, cadaver images, ethics, photographs, videos

### P-2

#### Current cadaver sources in Turkey and status of anatomy departments as information sources on the internet

Gürses İA, Coşkun O, Öztürk A

Department of Anatomy, Istanbul Faculty of Medicine, Istanbul University, Istanbul, Turkey

**Objective:** In Turkey, cadavers are acquired by obtaining donated, unclaimed, autopsied, and imported bodies, the process of which is regulated under Act 2238. The difficulties in body procurement gradually led to these diverse applications. We aimed to outline cadaver sources in anatomy departments and their effectiveness.

**Methods:** Each department was approached by phone and invited to the study. Official websites of each department was investigated regarding any information on body donation or National Body Donation Campaign. IRB approval (date: 01.03.2016; number: 311) was obtained.

**Results:** Fifty-two departments responded to our survey. Unclaimed cadavers (84.8%) were the major source for anatomy departments which was followed by donated (50%) and imported cadavers (39.1%). Foundation based universities were more likely to import cadavers (10/41 vs 8/11; p=0.008). Departments in cities with significantly higher City Based Gross Domestic Product measures (21.652% vs 36.680%, p=0.041), frequencies for mid- or high-school graduates (30.4% vs 31.3%, p=0.041), and frequencies for under- or post-graduates (13.1% vs 15.8%, p=0.24) could procure donated cadavers. Reasons for using unclaimed cadavers were education (45.9%), unclaimed cadavers being the only source (24.3%), and receiving inadequate donations (21.6%). Nine (12.2%) departments provided information regarding body donation on their websites.

**Conclusion:** Body procurement remains as a serious problem in Turkey. It is apparent that current legislature does not provide a sufficient cadaver inflow. Similarly, anatomy departments' effectiveness in public awareness on body donation and support in the National Body Donation Campaign seems questionable.

**Keywords:** body donation, body procurement, cadaver, gross anatomy education, import of bodies, unclaimed bodies

### P-3

#### Survey of medical students of Kocaeli University to assess their knowledge and attitudes to anatomy dissection, brain death and donation

Bamaç B<sup>1</sup>, Yener MD<sup>1</sup>, Çolak T<sup>1</sup>, Taşdemir R<sup>1</sup>, Aksu E<sup>1</sup>, Güzelordu D<sup>1</sup>, Sivri İ<sup>1</sup>, Örs A<sup>1</sup>, Çolak S<sup>2</sup>

<sup>1</sup>Department of Anatomy, Faculty of Medicine, Kocaeli University, Kocaeli, Turkey; <sup>2</sup>Department of Sports Management, School of Physical Education and Sport, Kocaeli, Turkey

**Objective:** Cadaver and organ donation issues are very important for medical education and treatment of chronic diseases. In this survey study we aimed to evaluate the effect of anatomy

laboratory education on the knowledge, attitudes and behaviors of medical students' organ and cadaver donation.

**Methods:** Our study was carried out between 2015–2016 and 2016–2017 academic year students of Kocaeli University Faculty of Medicine. A total of 166 students completed the survey. The questions in the questionnaire directed to the students were designed to evaluate their attitudes to organ donation and their knowledge about cadaver.

**Results:** When the obtained data were evaluated, it was observed that the anatomy laboratory training caused changes in the attitudes of medical students on cadaver and organ donation. 38.6% (n= 64) of the students answered “yes” to the question of “Would you like to donate your organs when brain death takes place?”. This rate increased to 54.8% (n=91) in the following year (p<0.05). Likewise, 31.9% (n=53) of the students answered “yes” to the question of “Do you want to donate the organs of any of the family members when brain death occurs? This rate increased to 44.8% (n=73) in the following year (p<0.05).

**Conclusion:** As a result, anatomy laboratory studies changed students' attitudes towards cadaver and organ donation. Given the responsibilities and duties of health workers in this regard, the promotion of this level has a critical prescription for increasing the quality of community health and health education.

**Keywords:** anatomy education, cadaver donation, organ donation

#### P-4

##### Evaluating the *in vivo* anatomy of the thyroid isthmus on computed tomography images

Türkay R<sup>1</sup>, Dural AC<sup>2</sup>, Gürses İA<sup>3</sup>, İnci E<sup>1</sup>, Nalbant M<sup>1</sup>, Alış H<sup>2</sup>, Öztürk A<sup>3</sup>

<sup>1</sup>Department of Radiology, Bakırköy Dr Sadi Konuk Training and Research Hospital, Istanbul, Turkey; <sup>2</sup>Department of General Surgery, Bakırköy Dr Sadi Konuk Training and Research Hospital, Istanbul, Turkey; <sup>3</sup>Department of Anatomy, Istanbul Faculty of Medicine, Istanbul University, Istanbul, Turkey

**Objective:** The anatomy of the thyroid isthmus is quite variable. Additionally, results of previous studies rely either on pathologic surgical specimens or cadaveric specimens with no medical history. This study aims to investigate the *in-vivo* radiologic anatomy of the thyroid isthmus on individuals without thyroid diseases.

**Methods:** The anatomy of isthmus was evaluated on 120 individuals (60 women, 60 men) with computed tomography. Isthmus width, height, and the distances between the lower ends of thyroid and cricoid cartilages to the upper and lower borders of the isthmus were evaluated on reformed sagittal images.

**Results:** The isthmus was present in all cases. Average isthmus width and height were 4.6±1.5 mm and 15.6±3.6 mm, respectively. No significant differences were present for width (p=0.71) and height (p=0.37) between sexes. Average distance from the thyroid cartilage to upper and lower borders of the isthmus were 22.1±5.2 mm and 37.7±6.8 mm, respectively. The differences among sexes were not significant for both distances

(p=0.46 and p=0.92). Average distance from the cricoid cartilage to upper and lower borders of the isthmus were 7.1±3.6 mm and 22.5±5.8 mm, respectively. Both distances were significantly greater in women (p=0.01 and p=0.02).

**Conclusion:** The results of our study based on *in-vivo* radiologic images and individuals with no thyroid pathology differs from existing literature.

**Keywords:** anatomy, isthmus, thyroid gland

#### P-5

##### Frequency of accessory sacroiliac joints

Develi S, Yıldız S

Department of Anatomy, University of Health Sciences, Gülhane Faculty of Medicine, Ankara, Turkey

**Objective:** Art. sacroiliaca is the synovial joint between os sacrum and os ilium through the facies auricularis of the both bones. All forces and body weight is transmitted to the pelvis and lower extremity via this synovial joint. Since the early nineteenth century, accessory sacroiliac joints were also described as false joints. Accessory joints are observed dorsal to the true synovial joint and suggested to be associated with low back pain. We aimed to investigate the frequency and locations of the accessory sacroiliac joints in our population.

**Methods:** 24 dry os sacrum were included in the study. Age and sex of the os sacrum were unknown. Existence of accessory joint surfaces were examined. Location and number of the accessory joints were noted and photographed.

**Results:** In 5 of 24 os sacrum, accessory joints were observed. All accessory joint surfaces were posterior to facies articularis. In two sacrum accessory joints were bilateral. In one sacrum two accessory joints were observed on the same side. Superior one was located inferior to tuberositas sacralis, inferior one was located on the crista sacralis lateralis. Also sacralization was observed in this sample.

**Conclusion:** Etiology is unknown and unclear that it is a congenital or acquired condition. In a study upon east Africans, accessory joints are found significantly more in females and it was supposed to be associated with low-back-carrying load (babies). As one of the low back pain cause we aimed to raise awareness about this variation.

**Keywords:** accessory sacroiliac joint, lateral sacral crest, sacral tuberosity

#### P-6

##### Morphometric evaluation of piriform aperture, choana and nasal bone in dry skulls

Aydın Kabakçı AD<sup>1</sup>, Akın D<sup>1</sup>, Alpa Ş<sup>2</sup>, Büyükmumcu M<sup>1</sup>, Yılmaz MT<sup>1</sup>

<sup>1</sup>Department of Anatomy, Meram Faculty of Medicine, Necmettin Erbakan University, Konya, Turkey; <sup>2</sup>Department of Anatomy, Faculty of Medicine, KTO Karatay University, Konya, Turkey

**Objective:** Piriform aperture and nasal bone are important structures that contribute to the formation of the nose. Both anatomic structures shows differences according to ethnic groups and gender. For this reason, it is used to determinate sex in science branches such as anthropology and forensic medicine. In this study, it was planned to examination of piriform aperture, nasal bone and choana as morphometrically.

**Methods:** The study was carried out on 83 skulls of bone collections in Necmettin Erbakan University Anatomy Laboratory and Karatay University Anatomy Laboratory. Digital caliper was used. Piriform aperture was classified into 7 types as 1) Pear shape, 2) Reverse heart shape, 3) Rhomboid shape, 4) Drop shape, 5) Elipsoid shape, 6) Trapezoid shape, 7) Round shape. And also nasal bone was classified into 8 subtypes. Choana width and height were measured as bilaterally.

**Results:** As a result, it was determined that the most common type of piriform aperture was type 5 (elipsoid shape, 21–25.3%) and the least most common type was type 7 (round shape, 4–4.8%). Nasal bone forms were categorized into 8 subtypes. Type 1 (narrowing from the edges to the midline, angulation at the lower part of the bone, bone mid thickness greater than 4 mm) was determined as the most common observed shape. Choana mean width and height were determined as 13.5 mm and 25.8 mm respectively.

**Conclusion:** We believe that obtained datas from our study will constitute a morphometric data set and will be useful in a wide range of fields from forensic science

**Keywords:** piriform aperture, nasal bone, morphometry

## P-7

### Typing and morphometric analysis of the pterion on human skull

Akın D<sup>1</sup>, Aydın Kabakçı AD<sup>1</sup>, Çınar Ş<sup>2</sup>, Büyükmümcu M<sup>1</sup>, Yılmaz MT<sup>1</sup>

<sup>1</sup>Department of Anatomy, Meram Faculty of Medicine, Necmettin Erbakan University, Konya, Turkey; <sup>2</sup>Department of Anatomy, Faculty of Medicine, KTO Karatay University, Konya, Turkey

**Objective:** The pterion is a H letter shaped, small but also an important anatomic marking spot appeared on intersection of the frontal, parietal, temporal and sphenoid bones on temporal fossa. This spot is adjacent to some important formations such as anterior branch of the medial meningeal artery, left Broca's motor speech area, insula and the lateral sulcus (silvian sulcus). The present study focused on typing of the perion and morphometric measurements between the pterion and surrounding important anatomic spots.

**Methods:** The present study was performed with pterion typing of 107 craniums (totally 214 sides including the right and left sides) within Anatomy Laboratories of Necmettin Erbakan University, Meram Faculty of Medicine and KTO Karatay University Faculty. Distance between the pterion and some

important spots was measured through a digital caliper in millimeter. The pterion was classified in 7 types including sphenoparietal, frontotemporal, stellate, epipteric, wormian bone and 2 different types (frontoparietal and frontoparietosphenoid) which have not been identified before.

**Results:** The rates of the types were sphenoparietal type by 55.60%, epipteric type by 3.73%, stellate type by 2.33%, frontotemporal type by 0.4%, wormian type by 5.14%, frontoparietal type by 8.87% and frontoparietosphenoid type by 23.83%. Furthermore, a slight and moderate association was detected between many parameters measured in the present study.

**Conclusion:** Morphometric characteristics of the pterion was detected in detail by the present study. Moreover, the knowledge on typing would serve as an important guide for surgical planning and procedures and may contribute to further anthropological studies.

**Keywords:** pterion, morphometric, cranium

## P-8

### Morphometry of sacral hiatus

Develi S

Department of Anatomy, University of Health Sciences, Gülhane Faculty of Medicine, Faculty of Medicine, Ankara, Turkey

**Objective:** Sacrum is formed by the fusion of sacral vertebrae and forms the fixed part of vertebral column. On the dorsal aspect of the sacrum, sacral hiatus is seen as an opening at the end of the posterior wall of the sacral canal. Shape and size of the sacral hiatus is important in terms of caudal epidural block which is generally used in urinary, gynecologic or obstetric procedures. Thus variations of the hiatus is of importance for surgical procedures. In this study our aim was to evaluate the morphometry and variations of the sacral hiatus in the samples of our population.

**Methods:** 24 dry sacrums were included in the study. Age and sex of the os sacrums were unknown. Shape and level of the sacral hiatus were examined and photographed. Length and width of the hiatus were measured.

**Results:** Mean length and width of the hiatus were 13.4 mm and 10.1 mm respectively. Anteroposterior distance of the hiatus was found to be 3.4 mm. Level of the hiatus was at the 5th sacral vertebra in the 79.1% of the samples. In 20.9% of the samples it was at the level of the 4th sacral vertebra. Most common observed shape was the Inverted U. Inverted V, Dumbbell and irregular shapes were also observed.

**Conclusion:** Although sample size is low, our findings show that shape and size of the sacral hiatus varies. It is important to understand these variations in terms of surgical interventions, especially caudal epidural anesthesia.

**Keywords:** sacral canal, sacral cornu, sacral hiatus

**P-9****Localization of middle meningeal artery and its main branches in cranium**

Kendir S

*Department of Anatomy, Faculty of Medicine, Ankara University, Ankara, Turkey*

**Objective:** The objective of this study is to define the exact localization of middle meningeal artery and its branches on the inner side of the skull in reference to easily definable bony landmarks in order to contribute neurosurgical applications.

**Methods:** This study was conducted on 10 cadaveric heads fixed with 10% formaldehyde. The scalp and all the muscular and connective tissue was dissected and removed. The bones of the skull were also removed except the cranial sutures and important morphometric landmarks. The localization middle meningeal artery and its branches was measured in reference to certain bony landmarks. The measurements were done by a digital caliper and the mean values were calculated.

**Results:** The results of the measurements were evaluated bilaterally in order to localize the middle meningeal artery and its branches (Mma) by taking the zygomatic arch (Za) as a reference point. Accordingly; Mma (point A)-Za (depth): 1.88 cm, 2.19 cm on the right and left side, Mma (point A)-Za (anterior border): 2.71 cm, 2.52 cm on the right and left side, Mma (point A)-Za (posterior border): 2.46 cm, 2.82 cm on the right and left side, Mma (point B)-Za (height): 1.18 cm, 1.36 cm on the right and left side.

**Conclusion:** The results of this study will help estimating the exact localization of the middle meningeal artery and its branches before the operation. This may also help decreasing the complications related with the arterial injury and may also help planning the treatment of artery derived clinical conditions.

**Keywords:** anatomy, middle meningeal artery, morphometry

**P-10****Frequency of sacralization**

Develi S, Erçikti N

*Department of Anatomy, University of Health Sciences, Gülhane Faculty of Medicine, Ankara, Turkey*

**Objective:** Congenital skeletal anomalies of vertebral column is seen commonly. Skeletal anomalies in the lumbosacral region is called lumbosacral transitional vertebrae (LSTV). This clinical condition includes both lumbarization and sacralization. LSTV is the one most common causes of low back pain and strain. Existence of these variations may affect the movement and posture of the influenced individuals. In this study our aim was to evaluate sacralization patterns in the samples of our population.

**Methods:** 24 dry sacrums were included in the study. Age and sex of the os sacrums were unknown. Existence of sacralization was examined. Fusion defect patterns has been noted.

**Results:** In 4 of 24 sacrums, sacralization has been observed. In two samples, complete fusion has been noted. Partial fusion was found in two samples. Incomplete fusion of lamina and inferior articular processes were observed in other samples. Classification of LSTV is controversial. Castellivi classification is one of the most common used classification systems and it depends on radiological appearance. In most of the studies radiological appearance has been used for classification. In less used classification appearance of the S1-S2 disk is been used.

**Conclusion:** Although sample size is low, our findings show that sacralization is not rare variation among our population. We think a detailed knowledge about LSTV is important about the biomechanics of the lumbosacral region. Thus it will provide a comprehensive approach to differential diagnosis and management of low-back pains.

**Keywords:** lumbal 5th vertebra, lumbosacral transition, sacralization

**P-11****Variation of median nerve formation: case report**

Develi S, Kocabıyık N

*Department of Anatomy, University of Health Sciences, Gülhane Faculty of Medicine, Ankara, Turkey*

**Objective:** Variations of the branches of the brachial plexus are clinically important. A detailed knowledge of these variations will provide proper clinical evaluation and surgical approaches, and better understanding of unusual symptoms. In this text, we aimed to report an abnormal formation of the median nerve with three roots.

**Methods:** During routine dissection of a 78-years-old Caucasian male cadaver for medical education, unusual formation of the median nerve was observed. Median nerve is formed by three roots, two were coming from lateral fascicle, one from medial fascicle. Median nerve was formed lateral to axillary artery. Other branches of the brachial plexus were normal. Diameter of the proximal lateral root was small and has a high origin from the lateral fascicle. Diameter of the distal lateral root was bigger and it was branching from the lateral fascicle at the same level of medial root of median nerve.

**Conclusion:** Normally, median nerve is formed by two roots coming from medial and lateral fascicles of the brachial plexus. These two roots fuses and forms the median nerve, anterior or lateral to the 3rd part of axillary artery. But variations in the formation of the median nerve is common. Most common variation is formation by three roots. In this type of variation, extra root is usually comes from the lateral fascicle. Also one root or four root variations has also been reported. Knowledge of these variations is essential for clinicians interested in axillary fossa such as anesthesiologists, radiologists, surgeons or electromyographers.

**Keywords:** median nerve, lateral root of median nerve, medial root of median nerve

## P-12

### Trifurcation of tibial nerve: case report

Develi S

*Department of Anatomy, University of Health Sciences, Gülhane Faculty of Medicine, Ankara, Turkey*

**Objective:** Heel pain is one of the most common complaints which a podiatrist can encounter. Though most of these complaints are linked to plantar fasciitis, it is important to differentiate heel pain without numbness. First branch of n.plantaris lateralis innervates m. abductor digiti minimi. Heel pain, may be associated with impingement of this nerve which is also called Baxter nerve, deep to abductor hallucis muscle. In this text, we aimed to report a trifurcation of tibial nerve which may be prone to entrapment.

**Methods:** During routine dissection of a male Caucasian cadaver, unusual branching pattern of tibial nerve has been observed under the flexor retinaculum. Within the tarsal tunnel, tibial nerve was dividing into three branches. Lateral and medial plantar nerves were coursing as usual but the extra branch was coursing to lateral and deep to the first muscle layer of foot. Also, the posterior tibial artery was dividing into three branches as tibial nerve.

**Conclusion:** Normally, tibial nerve gives the medial and lateral plantar nerve branches within the tarsal tunnel. Most of the fibers of the medial plantar nerve are sensorial and innervate the majority of the plantar skin. In the plantar region, lateral plantar nerve gives deep and superficial branches after innervating quadratus plantae and abductor digiti minimi muscles. Since it is a motor branch, in the entrapment of the nerve, no numbness is seen and it is differentiated from other nerve entrapments. In this case, we aimed to raise awareness of a rare variation of tibial nerve.

**Keywords:** lateral plantar nerve, deep branch, superficial branch, tibial nerve

## P-13

### A variation of thyroid gland: case report

Develi S

*Department of Anatomy, University of Health Sciences, Gülhane Faculty of Medicine, Ankara, Turkey*

**Objective:** The thyroid gland is an endocrine gland located anteriorly in the neck. The gland is formed by 2 lobes connected by a median isthmus which overlies the second to fourth tracheal rings. The isthmus is encountered during routine tracheotomy and must be retracted. Occasionally, isthmus is absent, and the gland exists as 2 distinct lobes. In this text, we report a case of a thyroid gland without an isthmus and abnormal attachment of anterior suspensory ligament.

**Methods:** During routine dissection of a 78-years-old male Caucasian cadaver, thyroid gland was found to be formed by two distinct lobes. Isthmus of the gland was absent. Anterior

suspensory ligament was attaching to first tracheal ring. Cricothyroid artery was emerging from glandular branches of superior thyroid artery. Posterior suspensory ligament (Ligament of Berry) was in the normal position.

**Conclusion:** The thyroid gland is covered by the middle layer of deep cervical fascia, which attaches it firmly to the laryngoskeleton. The anterior suspensory ligament extends from the superior-medial aspect of the lobes of thyroid gland and attaches to the cricoid and thyroid cartilage. The posteromedial aspect of the gland is attached to the lower part of the cricoid cartilage, first and second tracheal ring, by the posterior suspensory ligament. Recurrent laryngeal nerve usually courses deep to the Berry ligament and it should be overlooked during thyroidectomies. According to our case, in the absence of isthmus, anterior suspensory ligament is located more posterior and inferiorly than usual position which may be mistaken as Berry ligament.

**Keywords:** thyroid gland, isthmus of thyroid gland, suspensory ligament of thyroid gland

## P-14

### Evaluation of the accessory and sesamoid bones in the foot

Değermenci M<sup>1</sup>, Uçar İ<sup>2</sup>, Ertekin T<sup>3</sup>, Yılmaz S<sup>4</sup>, Unur E<sup>1</sup>, Bağcı Uzun G<sup>5</sup>

*<sup>1</sup>Department of Anatomy, Faculty of Medicine, Erciyes University, Kayseri, Turkey; <sup>2</sup>Department of Physical Therapy and Rehabilitation, Ahi Evran University, Kırşehir, Turkey; <sup>3</sup>Department of Anatomy, Faculty of Medicine, Afyon Kocatepe University, Afyon, Turkey; <sup>4</sup>Department of Anatomy, Faculty of Medicine, Bozok University, Yozgat, Turkey; <sup>5</sup>Department of First Aid, Kapadokya Vocational School, Nevşehir, Turkey*

**Objective:** The accessory bones (ABs) are developmental variations in the skeletal system. These bones may be separated from or close to the actual bone. The sesamoid bones (SBs) which in the foot are close to joints and usually embedded within a tendon. The SBs' functions are to raise their mechanic effects and protect tendons. In our study, the types, numbers and bilateral states of the ABs and SBs in the foot were investigated retrospectively, in order to contribute to the literature.

**Methods:** This study was conducted as retrospectively on 3D Computed Tomography images of 69 individuals (46 males, 23 females) among 11–79 years (mean 38.06) applied to Erciyes University. The ABs and SBs were evaluated in the images inspected.

**Results:** The 29 right, 29 left foot and 11 bilateral feet were evaluated in our study and the AB was found in 38 (55.1%) of 69 cases. The most common AB in our study was accessory navicular bone in 16 (23.18%) of 69 cases. Addition to this, 12 trigonum bones (17.39%) and 10 peroneum bones (14.49%) were determined. We found SB in the feet of all individuals except the left foot of an individual and the most common SB was found at the level of the proximal interphalangeal joint of

the thumb, 40 (100%) on the right and 39 (97.5%) on the left.

**Conclusion:** The data that we have obtained is consistent with the literature and we think that these results can be used as a reference by clinicians and anatomists.

**Keywords:** sesamoid bones, accessory bones, computed tomography (CT)

## P-15

### Effect of acrylamide on the cell cycle of C6 glioblastoma cells

Kacar S<sup>1</sup>, Kutlu HM<sup>2</sup>, Şahintürk V<sup>1</sup>

<sup>1</sup>Department of Histology and Embryology, Faculty of Medicine, Eskişehir Osmangazi University, Eskişehir, Turkey; <sup>2</sup>Department of Biology, Faculty of Science, Anadolu University, Eskişehir, Turkey

**Objective:** Acrylamide is a chemical substance, to which is exposed while working in some business lines and via certain foods, and particularly effective on nervous system. The goal of this study was to determine the effect of different acrylamide concentrations on the cell cycle of C6 glioblastoma cells.

**Methods:** In our study, acrylamide-untreated control cells and C6 cells treated with acrylamide at three different inhibition concentrations (IC50, IC75 and IC90) were compared. For this purpose, the above-mentioned doses of acrylamide were applied to C6 cells, incubated at 37°C with 5% CO<sub>2</sub>, for 24 hours, after which the cells were detached and G0/G1, S, G2/M phases of cell cycle were analyzed using the cell cycle assay.

**Results:** As the acrylamide concentration increased, the cell percentages in sub G1 phase increase proportionally. The cell percentages in S phase was the highest in the IC50 group. The cell percentages in G2/M phase were similar among control, IC50 and IC75 groups. The cell percentages of G0/G1, S and G2/M phases in the IC90 group showed an apparent decline compared to other groups.

**Conclusion:** Acrylamide retains C6 cells in S phase at its IC50 dose and in sub G1 phase at its IC75 and IC90 doses, thus inhibiting the proliferation of these cells.

**Keywords:** acrylamide, C6 glioblastoma cells, cell cycle

## P-16

### Effect of acrylamide mitochondrial potentials of 5RP7 fibroblast cells

Kacar S<sup>1</sup>, Kutlu HM<sup>2</sup>, Şahintürk V<sup>1</sup>

<sup>1</sup>Department of Histology and Embryology, Faculty of Medicine, Eskişehir Osmangazi University, Eskişehir, Turkey; <sup>2</sup>Department of Biology Faculty of Science, Anadolu University, Eskişehir, Turkey

**Objective:** The importance of acrylamide, to which we have exposed in many areas, has been increasing day by day with its discovery in the foods. The damage of mitochondrion, known to be the energy center of the cell, directly affects the cell via-

bility. In this study, we aimed to ascertain how acrylamide affects 5RP7 fibroblast cells by investigating its effects on mitochondrial membrane potential of these cells.

**Methods:** In our study, the previously determined inhibition concentrations (IC50 and IC90) of acrylamide for the 5RP7 cells were used. Briefly, IC50 and IC90 concentrations of acrylamide were applied to 5RP7 cells kept in an incubator at 37°C with 5% CO<sub>2</sub>. After 24 hours, the cultured cells were detached with 5 min treatment of 0.25% trypsin-1 mM EDTA and incubated in the mitopotential working solution for 20 min following centrifugation. Then, they were analyzed adding a dead cell marker 5-AAD and the acrylamide treated/untreated 5RP7 cells were compared.

**Results:** The cell viability as 10.10%, 52.55% and 90.80%, dead cell percentages as 7.45%, 45.65% and 87.50% and depolarized cell percentages as 1.75%, 1.80% and 2.40%. were respectively found in the control, IC50 and IC90 groups.

**Conclusion:** In acrylamide-treated 5RP7 cells, depending on the increasing dose, cell viability decreases and depolarized cell ratio increases. This suggests that acrylamide kills 5RP7 cells in a dose dependent way disrupting the mitochondrial membrane.

**Keywords:** acrylamide, 5RP7 cells, mitochondrial potential

## P-17

### Effects of acrylamide on MCF-7 human breast adenocarcinoma cells

Kacar S<sup>1</sup>, Kutlu HM<sup>2</sup>, Şahintürk V<sup>1</sup>

<sup>1</sup>Department of Histology and Embryology, Faculty of Medicine, Eskişehir Osmangazi University, Eskişehir, Turkey; <sup>2</sup>Department of Biology Faculty of Science, Anadolu University, Eskişehir, Turkey

**Objective:** In this study, it was aimed to investigate the effects of acrylamide, which is readily soluble in water and can disperse to organs rapidly once taken into the body, on MCF-7 cells.

**Methods:** Cells were cultured with medium containing 10% FBS and 1% penicillin-streptomycin in an incubator at 37°C with 5% CO<sub>2</sub>. Sufficiently confluent cells were harvested, seeded on 96-well plates and exposed to acrylamide concentrations ranging 1 to 15 mM. After 24 hours, cells were incubated with 20 µl of MTT for 4 hours, then MTT and medium were discarded. The plate was read at 570 nm in the ELISA reader in 5 minutes after adding 100 µl of DMSO to the wells.

**Results:** The viability of MCF-7 cells did not show a significant decrease at the concentrations of 0-3 mM acrylamide, but was significantly decreased at the concentrations of 4-8 mM and the IC50 concentration of acrylamide for the MCF-7 cells was determined as 6.4 mM.

**Conclusion:** Acrylamide decreases the viability of MCF-7 cells in a dose-dependent manner.

**Keywords:** acrylamide, MCF-7 cells, MTT assay

**P-18**

**The effect of amount and type of media and solutions used in cell culture studies on absorbance values**

Kacar S<sup>1</sup>, Kutlu HM<sup>2</sup>, Sahinturk V<sup>1</sup>

<sup>1</sup>Department of Histology and Embryology, Faculty of Medicine, Eskişehir Osmangazi University, Eskişehir, Turkey; <sup>2</sup>Department of Biology, Faculty of Science, Anadolu University, Eskişehir, Turkey

**Objective:** Media are indispensable for cell culture. Different media according to cell types was developed and is still being developed. The contents of the media are adjusted according to cell requirements. In our study, we aimed to investigate the effects of interplay between MTT and media and PBS solutions in two different amounts, used in cell culture studies, on ELISA absorbance values.

**Methods:** In our study, eighteen groups were created with/without MTT including four different ready-to-use media DMEM, DMEM-F12, EMEM and RPMI, PBS, D-PBS, MTT, distilled water and empty wells. In both groups, both 100 and 200 µl of the solutions were tested. The absorbance values at 570 nm were measured by ELISA reader before adding MTT and after incubation at 37°C with 5% CO<sub>2</sub> for 0, 15, 30, 60, 90 and 120 min following MTT adding.

**Results:** Similar results were obtained in each examined time period in PBS, D-PBS, distilled water and MTT groups with and without MTT. MTT adding generally increased absorbance values in all types of media. However, there was a decrease in the absorbance value of all the media depending on the elapsing time. In DMEM and RPMI medium, the amount of two-fold medium increased the absorbance by almost two-fold. In DMEM-F12 and EMEM medium, this change was between 1.5 and three fold.

**Conclusion:** The interaction between media and MTT/other chemicals used in cell culture studies should be pre-analyzed and ELISA reader should be optimized to avoid possible false readings, preventing test results to be influenced.

**Keywords:** medium, ELISA reader, MTT, cell culture

**P-19**

**Assessment of gender difference in visual cephalometric analysis applied to Class I individuals: a preliminary study**

Karaca Bozdağ Z<sup>1</sup>, Kürkçüoğlu A<sup>2</sup>, Üstüdal Güney A<sup>3</sup>, Çam Y<sup>3</sup>, Oğuz Ö<sup>4</sup>

<sup>1</sup>Department of Anatomy, Faculty of Medicine, Istanbul Yeni Yüzyıl University, Istanbul, Turkey; <sup>2</sup>Department of Anatomy, Faculty of Medicine, Başkent University, Ankara, Turkey; <sup>3</sup>Department of Orthodonty, Faculty of Dentistry, Çukurova University, Adana, Turkey; <sup>4</sup>Department of Anatomy, Faculty of Medicine, Çukurova University, Adana, Turkey

**Objective:** Cephalometric analyzes play an important role in determining the individual's skeletal and dental structure, soft

tissue and their relationship to each other. Visual cephalometric analyzes are primarily based on determining the fitness between mid-face and maxilla, then positioning the mandible relative to the midface. Thus, as in the other cephalometric analyzes, changes related to the treatment and development of the current state of the individual are determined. In the study we aimed to reveal sex-related changes of four different angles and compare them with the norm.

**Methods:** This study was performed on right lateral cephalometric views of 80 healthy (40 woman, 40 man) Turkish individuals in Anatolia aged 21-71, with skeletal Class I malocclusion (ANB=2.19±1.43). In all images, angles formed by long axis of the upper cutting tooth and palatal plan (U1/PP); the long axis of the lower cutting tooth and mandibular plan (A1/MP); the long axes of the lower and upper cutting teeth (U1/A1); the palatal plan and mandibular plan (PP/MP) were analyzed.

**Results:** The PP/MP value of women was found to be significantly higher than men's (p<0.01), while no significant difference was found between the U1/PP, A1/MP and U1/A1. Statistically significant negative correlations were found between correlations of all angular measurements in both genders (p<0.05).

**Conclusion:** As a result, gender should also be considered as another factor beside the knowledge of angles of U1/PP, A1/MP, U1/A1 and PP/MP in orthodontic diagnosis and treatment planning. Our work continues by increasing the number of data.

**Keywords:** visual cephalometric analysis, maxillomandibular relationship, Class I malocclusion

**P-20**

**Evaluation of somatotype effects on Mallampati score and anthropometric measurements in geriatric patients**

Toy Ş<sup>1</sup>, Özbağ D<sup>2</sup>, Şenol D<sup>2</sup>, Gülhaş N<sup>3</sup>

<sup>1</sup>Department of Physical Medicine and Rehabilitation, Turgut Özal Medicine Center, İnönü University Malatya, Turkey; <sup>2</sup>Department of Anatomy, Faculty of Medicine, İnönü University, Malatya, Turkey; <sup>3</sup>Department of Anesthesiology and Reanimation, Faculty of Medicine, İnönü University, Malatya, Turkey

**Objective:** In this study, we aimed to determine whether somatotypes is a determining factor in difficult intubation in geriatric patients who underwent anthropometric measurements with Modified Mallampati Classification.

**Methods:** The study is approved by the Malatya Clinical Research Ethics Committee (19.04.2017) 80 patients who were scheduled to undergo elective surgery under general anaesthesia, fell into Group 1-2 according to ASA (American Society of Anesthesiologist) criteria. Patients were between the ages of 65–87. Demographic data and mallampati scores of patients were recorded. Thyromental, sternomental, hyomental distances, mandibular distance, upper lip bite test, neck circumference,



chest measurements were measured during the anthropometric measurements. Some anthropometric measurements were taken to determine somatotypes using the Carter and Heath method. Somatotype calculations were performed using the “Somatotype for Windows 1.2.6 Trial Version” program.

**Results:** Four distinct somatotypes were defined. There is no statistically significant difference in demographic data between male and female patients. There was a significant difference in all of the anthropometric measurements except chest measurement between the mallampati groups ( $p < 0.05$ ). Different somatotypes affected the anthropometric measurements and the mallampati score.

**Conclusion:** Our study is the first study to examine the association of Mallampati classification with anthropometric measurements as well as somatotype, which is used to predetermine difficult intubation. We think that, our work will provide guidance for anatomists, anesthesiologist and otorynolaryngologist.

**Keywords:** anthropometry, modified mallampati classification, somatotypes, difficult intubation

#### P-21

##### Lumbar facet anatomy among Turkish population: a preliminary study

Sağlam L, Tosunoğlu E, Çandır BN, Gürses İA, Kale A

Department of Anatomy, Istanbul Faculty of Medicine, Istanbul University, Istanbul, Turkey

**Objective:** It is known that facet anatomy is correlated with lumbar pathologies. Nevertheless, studies in the literature are limited to foreign populations. With this study, we aimed to investigate facet morphology and morphometry on lumbar vertebrae of a Turkish population and create an updated database.

**Methods:** Fifty vertebrae with no information of age, sex, and vertebral level from the osteology collection of Istanbul Faculty of Medicine Department of Anatomy were evaluated after obtaining Ethics Committee approval (Date: 30.06.2017; Number: 818). Facet shape was classified as C, J, and Flat. Facet angles were measured with ImageJ software. Facet height and width were also measured.

**Results:** Facet shape frequencies were C (32%), J (48%), and Flat (20%) for the right and C (26%), J (44%), and Flat (30%) for the left sides. Average facet heights were  $14 \pm 2.7$  mm and  $14.1 \pm 2.7$  mm for right and left sides, respectively ( $p = 0.65$ ). Average facet widths were  $13.4 \pm 2.3$  mm and  $13.6 \pm 2.2$  mm for right and left sides, respectively ( $p = 0.41$ ). Average facet angles were  $35.6^\circ \pm 12.6^\circ$  and  $35.6^\circ \pm 11.6^\circ$  for right and left sides, respectively ( $p = 0.99$ ). The vertebrae had no-asymmetry on 50%, mild tropism on 34%, and severe tropism on 16%.

**Conclusion:** With this study, we gathered preliminary data on facet anatomy that is correlated with pathologies causes back pain. By expanding these results, we believe it should be possible to provide detailed data that reflects Turkish population.

**Keywords:** facet asymmetry, facet joint, morphometry, tropism, Turkish population

#### P-22

##### Comparison of the advantages and disadvantages of anthropometric measurement methods: direct anthropometry, 2D photogrammetry and 3D stereophotogrammetry

Uzun A, Akça Z, Gölpinar M, Özel M

Department of Anatomy, Faculty of Medicine Ondokuz Mayıs University, Samsun, Turkey

**Objective:** Anthropometry has created significant values for researchers interested in the dimensions of the human body over the years. Therefore, numerous anthropometric studies have been performed in the process from past to present. Since the development of technology, various anthropometric methods have been developed. In the present study, we evaluated direct anthropometry, 2D photogrammetry and 3D stereophotogrammetry from anthropometric measurement methods according to literature.

**Methods:** Pubmed database was used to search for relevant articles using the following words: stereophotogrammetry, photogrammetry, direct anthropometry, anthropometric technique. We evaluated to anatomical studies that compared the different anthropometric techniques each other. In addition, the advantages and disadvantages of these methods were compared with each other.

**Results:** Direct anthropometry method is a reliable, inexpensive and has a large database. However it has some disadvantages such as time consuming, requires cooperation and some landmarks can change with movement during direct measurement. The advantages of 2D photogrammetry are rapid acquisition, archival capabilities, simplicity, low cost, and noninvasiveness. But it can't maneuver on images for evaluation and identifying some landmarks is difficult. 3D stereophotogrammetry can be rotate 3D images and facilitated determining of anthropometric landmarks.

**Conclusion:** Each technique has some advantages and disadvantages to obtain anthropometric data in anthropometric studies. Finally, 3D stereo method is a better way to determine anthropometric landmarks and repeat measurements at any time than direct anthropometry and 2D photogrammetry.

**Keywords:** direct anthropometry, 2D photogrammetry, 3D stereophotogrammetry

#### P-23

##### Thoughts on anatomy training of the vocational high school students

Çinpolat B, Özcan F

Vocational School of Health Services, Altınbaş University, Istanbul, Turkey

**Objective:** In addition to medical faculties and health schools/colleges in Turkey, there are vocational school of health services providing health education at associate degree

level. In these schools, besides vocational courses, anatomy lesson which is one of indispensable lessons of health education is also taught. The aim of this study is to contribute to enhance the effectivity of anatomy education.

**Methods:** The study was carried out with the participation of 212 volunteers who attended Altınbaş University Vocational School of health services and completed basic anatomy course. No personal information was collected from the participants for the confidentiality of replies. Statistical analyzes of the results were made using the SPSS program and Office 2010 Excel.

**Results:** Participants reported a positive opinion about these items: 88% about the necessity of anatomy education, 71% about “I am interested in anatomy lesson”, 87% about “Anatomy lessons should be practiced”, 76% about “Clinical knowledge should be given more in the course content”, 89% about “I think my anatomy education will make a significant contribution to my professional life”.

**Conclusion:** Participants reported that anatomical training was necessary it had a motivating role in the training process and it was effective to understand other lessons. We believe that transferring the training of the anatomy with application-oriented and clinical information will increase the efficiency of the course. In our research it will be contributed to the development of the educator and given education, and it can be an example in terms of other courses.

**Keywords:** anatomy education, student opinions, evaluation

#### **P-24**

##### **Type B interrupted aortic arch: case report**

Fazlıoğulları Z<sup>1</sup>, Ünver Doğan N<sup>1</sup>, Sevindik B<sup>1</sup>, Seher N<sup>2</sup>, Karabulut AK<sup>1</sup>

<sup>1</sup>Department of Anatomy, Faculty of Medicine, Selçuk University, Konya, Turkey; <sup>2</sup>Department of Radiology, Faculty of Medicine, Selçuk University, Konya, Turkey

Interrupted aortic arch is a rare, fatal, congenital cardiac anomaly characterized by the presence of a segmental atresia between the descending and ascending aorta. Three types, A, B, and C are defined in the relevant literature. In type A, the interruption is distal to left subclavian artery. Whereas the interruption is in type B between left common carotid artery and left subclavian artery, in type C it is between left common carotid artery and right common carotid artery. Interrupted aortic arch is present to 98% with other cardiovascular anomalies. The most commonly reported anomaly is ventricular septal defect. Echocardiography of a male baby at the 5th postnatal day referring to Selçuk University Medical Faculty revealed; type B interrupted aortic arch starting from distal truncus brachiocephalicus, perimembranous inlet ventricular septal defect, bicuspid aorta, patent ductus arteriosus, secundum atrial septal defect, and aortic annulus hypoplasia. Computed tomography angiography revealed interruption between left common carotid artery and left subclavian artery. The symptoms in interrupted aortic arch anomaly are generally severe and as stated in the present case study emerge at an early period. Early

diagnosis of utmost importance as the mean death time is reported as 4–10 days in untreated patients. The present case study highlights the importance of radiologic imaging methods in the early diagnosis and treatment of aortic arch anomaly and accompanying other cardiovascular anomalies.

**Keywords:** interrupted aortic arch, type B, BT angiography, variation

#### **P-25**

##### **Clinical importance of insertion variations of palmaris longus muscle: case report**

Uslu Aİ<sup>1</sup>, Demirel BM<sup>1</sup>, Cankuş MC<sup>2</sup>, Akkın SM<sup>1</sup>

<sup>1</sup>Department of Anatomy, School of Medicine, SANKO University, Gaziantep, Turkey; <sup>2</sup>Department of Orthopaedics and Traumatology, School of Medicine, SANKO University, Gaziantep, Turkey

As it is harvested as a tendon graft in various surgical procedures, the palmaris longus muscle is one of the most variable muscles in the human body. During our routine dissection, we observed an insertion variation of this muscle on a female 61-year-old cadaver. On the left forearm, the palmaris longus tendon bifurcated into lateral and medial divisions. The lateral division was attached to flexor retinaculum, thenar fascia and continued further to the apex of the palmar aponeurosis. Besides, the medial division merged into the hypothenar fascia and attaching to pisiform bone and hook of hamate bone while passing superficially to the Guyon's canal. On the right forearm, the palmaris longus muscle was absent. Whereas the flexor carpi radialis muscle was giving a thin branch, which was splitting into three areas as palmar aponeurosis, flexor retinaculum and thenar fascia. This type of a case should be taken into consideration from the point of view of surgical approaches.

**Keywords:** anatomical variations, anomalous insertions, palmaris longus muscle

#### **P-26**

##### **Bilateral variations of musculus palmaris longus: case report**

Demirel BM<sup>1</sup>, Uslu Aİ<sup>1</sup>, Cankuş MC<sup>2</sup>, Akkın SM<sup>1</sup>

<sup>1</sup>Department of Anatomy, School of Medicine, SANKO University, Gaziantep, Turkey; <sup>2</sup>Department of Orthopaedics and Traumatology, School of Medicine, SANKO University, Gaziantep, Turkey

During our routine dissections, we observed musculus palmaris longus variation bilaterally on an 87-year-old female cadaver. It has two bellies and tendons separately on the left upper extremity and on the right upper limb its tendon was separated into three splits before inserting to the palmar aponeurosis. On the left upper extremity, tendon of the muscle on the ulnar side was inserting to flexor retinaculum and hypothenar fascia and a tendon split arising from ulnar tendon was joining with the tendon on the radial side and inserting to palmar aponeurosis and thenar fascia. On the right upper extremity a three-split tendon was inserting to pal-

mar aponeurosis, thenar and hypothenar fasciae. We think that our findings may be important in terms of clinical aspect.

**Keywords:** palmaris longus muscle, tendo, variation, insertion

## P-27

### Assesment of vertebral osteophytes using computed tomography

Polat M<sup>1</sup>, Karabulut AK<sup>1</sup>, Fazhoğulları Z<sup>1</sup>, Ünver Doğan N<sup>1</sup>, Paksoy Y<sup>2</sup>

<sup>1</sup>Department of Anatomy, Selçuk University, Faculty of Medicine, Konya, Turkey; <sup>2</sup>Department of Radiology, Selçuk University, Faculty of Medicine, Konya, Turkey

Osteophytes is exostosis in any part of skeleton and can have various shapes. Especially with age, osteophytes is seen in the spine and can be found in different proportions in males and females. The aim of this study was to compare the anatomical settlements with varieties of vertebral osteophyte based on age and gender. This study were performed retrospectively on computed tomography of 198 patients (101 men, 97 women) were admitted to the Radiology Department. Ethical approval (2016/192) was given by the Ethics Committee of Selçuk University. Images of adults aged 18 and older was observed on sagittal, axial and coronal plane. Osteophytes was evaluated that according to vertebral column section, anatomic location, types and length of osteophytes were measured. All data collected was assessed using t and Pearson's chi-square tests. The average age of patients was found to be 52.7. Osteophytes were seen in all age groups of 61 years and older. The men had more osteophytes (%56.9) than women in lumbal region. C5 (%36.4) in the cervical spine, T9 (%12.8) and T10 (%12.8) in the thoracic spine and L4 (%25) in the lomber spine had more osteophytes than other levels. There was anterior claw type osteophytes in the cervical and lumbal regions (%80-%78.9) and anterior fusion type osteophyte in thoracic spine (%97.2). Compared the total values of length, the men had higher (6.49±2.09 mm) values than women (5.90±2.08 mm) and results were statically significant. Rates and anatomical locations of osteophytes were found to be different related to age and gender.

**Keywords:** osteophyte, vertebra, computed tomography

## P-28

### The effect of basic demographic data on walking pattern in elderly people

Uluçam E<sup>1</sup>, Taştekin N<sup>2</sup>, Parlak M<sup>1</sup>, Yılmaz Kayatekin AZ<sup>1</sup>, Çıkılmaz S<sup>1</sup>, Bozer C<sup>1</sup>

<sup>1</sup>Department of Anatomy, Faculty of Medicine, Department of Anatomy, Edirne, Turkey; <sup>2</sup>Department of Physical Therapy and Rehabilitation, Faculty of Medicine, Edirne, Turkey

**Objective:** The main features that will affect the walking pattern in elderly individuals are demographic data such as height, weight, body mass index, plantar area. Therefore, the determination of the standard values of these data should be examined for the effect of deviations. In our study, we aimed to deter-

mine the effect of basic demographic data on walking patterns independently of other parameters in elderly individuals and to compare this with younger individuals.

**Methods:** Ethical approval was obtained from the Scientific Research Ethics Committee of the Faculty of Medicine of Trakya University (TÜTF-BAEK 2015/110). 120 volunteers, half of these individuals was aged 70-79 and the other half was aged 18-25, were included in the study. Walking patterns of subjects were determined using force platform (Zebris, FDM System Type FDM 3.5) and WinFDM computer program.

**Results:** There was moderate correlation between height and foot rotation angle ( $r=0.354$ ,  $p<0.0001$ ). There was negative relationship between age and half-step length ( $r=-0.736$ ,  $p<0.0001$ ). As age increased, the walking speed decreased ( $r=-0.735$ ,  $p<0.0001$ ).

**Conclusion:** As a result, changes in almost all parameters of walking pattern in elderly individuals are detected. Identification of these parameters and taking precautions can be used to remove the negative consequences of the musculoskeletal system problems in the elderly.

**Keywords:** gait analysis, force platform, elderly people

## P-29

### Sectional observation of carpal canal structures in unilateral carpal tunnel syndrome events using magnetic resonance imaging

Acer N<sup>1</sup>, Gülaçtı MM<sup>2</sup>, Demirel A<sup>3</sup>

<sup>1</sup>Department of Anatomy, Faculty of Medicine, Erciyes University, Kayseri, Turkey; <sup>2</sup>Institute of Health Sciences, Erciyes University, Kayseri, Turkey; <sup>3</sup>Bingöl State Hospital, Bingöl, Turkey

**Objective:** Carpal Tunnel Syndrome (CTS) is the most common peripheral nerve entrapment syndrome and its cause is mostly idiopathic. In this study, it is aimed to compare cross sectional areas of the structures passing through CC in the MR images of both wrists of the patients with unilateral Carpal Tunnel Syndrome.

**Methods:** In this present study, 16 female patients are included who applied to Kahramanmaraş Sutcu Imam University (KSU) Clinic of Physical Therapy and Rehabilitation (CPTR) with the complaints of power loss on hands and paresthesia and who are diagnosed to have unilateral idiopathic carpal tunnel syndrome (CTS) as a result of their past stories, physical examinations and electromyography (EMG). Analyze12.0 is used to measure median nerve (MN) cross sectional areas of structures in CC with MR images.

**Results:** When cross sectional area of ill side and cross sectional area of fit side was compared, the value of ill side was found as (20.90±6.12 mm<sup>2</sup>) and the value of fit side as (18.18±3.80 mm<sup>2</sup>) which means it is bigger than the fit side. And also when the tendons in CC were compared; cross sectional area of CC in ill side was found as (264.91±68.55 mm<sup>2</sup>) and value of fit side was found as (257.42±66.30 mm<sup>2</sup>) which means ill side is bigger than the fit side. All these findings provide a significant difference ( $p\leq 0.05$ ).

**Conclusion:** All these findings support other studies on CTS. Also, it is expected that these findings will contribute to the future studies and clinics.

**Keywords:** median nerve, idiopathic, canalis carpi, cross sectional area

### P-30

#### The biometric parameters of the hand surface in young adults

Nteli Chatzioglou G, Pinar Y

*Department of Anatomy, Faculty of Medicine, Ege University, Izmir, Turkey*

**Objective:** We tried to reveal the morphometry of the hand with superficial parameters by considering its kinesiology, anatomy and functions.

**Methods:** We use this information in many areas, from prosthetic and robot hand design to 3D modelling and glove design.

**Results:** According to the results of the measured parameters; the average of finger lengths in hand are; 49.51±5.53 mm for thumb finger, 63.89±4.1 mm for index finger, 70.70±5.25 mm for middle finger, 65.53±4.8 mm, ring finger and 53.35±4.32 mm for fingernail finger. Length difference between fingers when the hand is in extender and maximum adduction positions are 56.14±6.16 mm for between the thumb and the index finger, 10.70±4.09 mm for between the index finger and the middle finger, 10.85±1.42 mm for between the middle finger and the ring finger and 25.63±2.74 mm for between the ring finger and the little finger. Other results found like this; Average of radial deviation angle: 65.19±8.2°, average of ulnar deviation angle: 51.21±9.6°. The average of the angle defined as grasping / gripping angle was measured as 49.13±5.76°. Averages of the angles between the fingers when they are positioned to the maximum abduction are 53.37±6.54° between the thumb and the index finger; 17.18±2.59° for between the index finger and the middle finger, 14.27±2.32° for between the middle finger and the ring finger and 32.12±6.98° for between the ring finger and the little finger.

**Conclusion:** It was confirmed that various features of participants such as sex, birth, age, height, place of, dominant hand preference, dominant hand preference when writing and social activity attendance status affected the averages of the parameters and the metric results.

**Keywords:** hand biomechanics, hand modelling, human hand biometry

### P-31

#### A case report of inferior concha bullosa

Güray B, Ünsal G, Özcan İ, Balcıoğlu HA

*Faculty of Dentistry, Istanbul University, Istanbul, Turkey*

Nasal conchae, also known as turbinates, are curved bony elements, which segment nasal cavity into four different volumes.

There are three or four types of turbinates as inferior, middle, superior and in some cases supreme turbinate. By increasing the surface area, nasal conchae humidify, warm and filter the air. Among the nasal conchae, inferior nasal concha is the largest turbinate and has the biggest role in airflow direction. Pneumatization of nasal conchae, also known as concha bullosa, is a common clinical condition in which air cells formation presents in one of the nasal conchae. Pneumatization of middle and superior conchae are relatively common but the pneumatization of inferior conchae are rare to encounter. In this case report, a 19-years-old male patient suffering from an intermittent headache is presented. In CT scan concha bullosa formation in middle left and inferior left conchae were seen with mucosal thickening in left maxillary sinus.

**Keywords:** concha bullosa, concha nasalis inferior, cbct

### P-32

#### Evaluation of satisfaction levels for anatomy education in secondary school students

Özdemir F<sup>1</sup>, Turgal E<sup>2</sup>, Gölpinar M<sup>3</sup>

*<sup>1</sup>Department of Anatomy, Faculty of Medicine, Hitit University, Çorum, Turkey; <sup>2</sup>Department of Biostatistics, Faculty of Medicine, Hitit University, Çorum, Turkey; <sup>3</sup>Department of Anatomy, Faculty of Medicine, Ondokuz Mayıs University, Samsun, Turkey*

**Objective:** The aim of the present study is to describe and compare the satisfaction levels of the anatomy education in July 2017 Child University education program of Hitit University students who completed 5th, 6th, 7th grade classes.

**Methods:** The questionnaire had 21 questions and 5 options were used. The present study was included 56 (42 males, 14 females) students and (4–10 years), (25–11 years), (16–12 years) and (11–13 years). In data analysis, questionnaire items were divided groups into gender, age and graduating classes. The permission of the ethics committee of Hitit University was obtained on 11th July, 2017 at 2017050.

**Results:** Our results revealed that male students' average scores were 87.66±14.02 and female students' 90.14±8.27. There were no significant differences in male and females (p>0.05). The age of students at 10 years was 77.50±16.76; 11 years 89.64±12.92; 12 years 87.81±9.47 and for 13 years 89.81±15.10. There were no statistically significant difference in four groups (p>0.05). From the groups formed according to the classes graduate; students who finished 5th grade 87.45±13.94; 6th class 89.52±10.26; 7th 88±16.85 and there were no statistically significant difference in four groups (p>0.05).

**Conclusion:** As a result of our study, it was seen that most of the students were satisfied with the education given, attracted attention, effective in choosing profession, and the time passed was not wasted.

**Keywords:** anatomy, children, education, satisfaction

**P-33****Determination and classification of cutaneous innervation of dorsum of the foot in fetal cadavers**Candan B<sup>1</sup>, Albay S<sup>2</sup><sup>1</sup>Department of Anatomy, Faculty of Medicine, Alanya Alaaddin Keykubat University, Antalya, Turkey; <sup>2</sup>Department of Anatomy, Faculty of Medicine, Süleyman Demirel University, Isparta, Turkey**Objective:** The aim of this study is to determine of cutaneous innervation of dorsum of the foot (CIDF) on fetal cadavers.**Methods:** In this study 200 limbs from 100 embalmed fetuses (54 male and 46 female) were studied in Anatomy Laboratory. Contributions of medial, lateral and intermediate dorsal cutaneous nerves (MDCN, LDCN and IDCN) of the foot were determined.**Results:** CIDF was classified into five Types. Type I (75%) in which MDCN was innervated medial side of the foot, I. and II. digits, IDCN innervated III. IV. and V. digits and LDCN was innervated the lateral side of the foot. Type II (21%) in which MDCN innervated medial side of the foot, I. II. and III. digits, IDCN innervated IV. and V. digits and LDCN was innervated the lateral side of the foot. In Type III (1.5%) in which saphenous nerve innervated medial side of the foot and I. digit, MDCN innervated II. and III. digits, IDCN innervated IV. and V. digits and LDCN was innervated the lateral side of the foot. Type IV (1.5%) is similar to Type I but there was a connection between the MDCN and IDCN on the dorsum of the foot. Type V (1%) in which MDCN innervated medial side of the foot, I., II., III. and IV. digits, sural nerve innervated V. digit and lateral side of the foot and there was no IDCN.**Conclusion:** The present study has revealed a new classification for CIDF.**Keywords:** fetus, superficial fibular nerve, medial cutaneous dorsal nerve**P-34****Anatomic location of motor nerve entry point of terminal branches of common fibular nerve in fetal cadavers**Candan B<sup>1</sup>, Albay S<sup>2</sup><sup>1</sup>Department of Anatomy, Faculty of Medicine, Alanya Alaaddin Keykubat University, Antalya, Turkey; <sup>2</sup>Department of Anatomy, Faculty of Medicine, Süleyman Demirel University, Isparta, Turkey**Objective:** The aim of this study is to determine the morphologic description and location of the common fibular nerve (CFN) and anatomic location of the motor nerve entry point (MEP) of the terminal branches of CFN which innervates the anterior and lateral muscles of the leg using anatomic dissection method on fetal cadavers.**Methods:** In this study 200 limbs from 100 embalmed fetuses (54 male and 46 female) were studied in Department of Anatomy Laboratory. Location of CFN and MEP of its terminal branches were seen by dissection. The distances from bifurcation level of CFN to lateral malleolus and lateral epicondyle

were measured. Distances between MEP of the anterior and lateral muscles of the leg and lateral malleolus were measured.

**Results:** We found that all parameters increase with age during the fetal period ( $p < 0.05$ ). Parameters do not show any significant differences between sexes ( $p > 0.05$ ). When the number of MEP of the anterior and lateral muscles of the leg evaluated they found to be different.**Conclusion:** The present study has revealed that the location of CFN and location of the MEP of the terminal branches of CFN during the fetal period. We hope that present results can be considered as providing some useful findings for clinical studies.**Keywords:** fetus, common fibular nerve, motor nerve point**P-35****Multidisciplinary anatomy publications between 2006–2016 in Turkey**

Yıldız Yılmaz M, Coşkun İ

Department of Anatomy, Faculty of Medicine, Uludağ University, Bursa, Turkey

**Objective:** At the present time, interdisciplinary dialogues and multidisciplinary studies are essential of contemporary science for the academic information exchange, scientific and social relationships. In our study, we aimed to reveal the data of the multidisciplinary scientific publications in the field of anatomy.**Methods:** TÜBİTAK - Ulakbim and Web of Science (ISI) databases have examined national and international multidisciplinary publications which have been published in the last 10 years and one of the authors is anatomist. The fields and ratios by year, publication numbers, classification of publications, citation rates and journals were determined.**Results:** The most published categories are radiologic anatomy and surgery and there is an excess of reviews and cases in the classification of publications. Surgical and Radiologic Anatomy is journal the most published. Interdisciplinary studies provides skills like teamwork, finding answers together, habits of different thought systems. Besides increasing the value of researches, cooperation also brings different professional qualifications. Undergraduate and graduate programs should be given on multidisciplinary basic.**Keywords:** anatomy, multidisciplinary, publication**P-36****Experimental neural tube development model in chick embryos**Ertekin T<sup>1</sup>, Turamanlar O<sup>1</sup>, Aslan E<sup>2</sup>, Güzel H<sup>1</sup>, Bilir A<sup>1</sup>, Demirkan İ<sup>3</sup>, Ertekin A<sup>4</sup><sup>1</sup>Department of Anatomy, Faculty of Medicine, Afyon Kocatepe University, Afyonkarahisar, Turkey; <sup>2</sup>Department of Histology and Embryology, Faculty of Medicine, Afyon Kocatepe University, Afyonkarahisar, Turkey; <sup>3</sup>Department of Surgery, Faculty of Medicine, Afyon Kocatepe University, Afyonkarahisar, Turkey; <sup>4</sup>Department of Emergency, Faculty of Veterinary Medicine, Afyon Kocatepe University, Afyonkarahisar, Turkey

**Objective:** Chick embryos are a generally used model for fetal program in gann developmental biology studies because of their simplicity and similarity to early stage human embryos. The early chick embryos are quite sensitive to external pharmacologic drugs and potential teratogens. Studies that investigated neural tube development in chick embryo model only concentrated closure defect of neural tube. There is no study evaluated somite number, crown-rump length and head length. The aim of our study was to investigate healthy chick embryo development with using the above mentioned parameters at 48 and 72 hours.

**Methods:** Fertile eggs were incubated at 37.5°C and 75% relative humidity. At this stage, the eggs were divided into two groups. Eggs in Group A and group B were opened at the 48th and 72nd hour (stage twelfth and twentieth of development according to Hamburger and Hamilton) respectively. The embryos were evaluated morphologically and histopathologically.

**Results:** The somite number and crown-rump length were significantly different between two groups ( $p < 0.001$ ). In group B (mean somite number:  $36.4 \pm 3.596$ , mean crown-rump length:  $759.7 \pm 102.441$ ), these parameters were increased compared to group A (mean somite number:  $14.3 \pm 1.766$ , mean crown-rump length:  $496.7 \pm 85.717$ ).

**Conclusion:** This chick embryo model corresponds to the early stage of spinal cord development in human embryology and our results would be helpful to examine the effects of different teratogens on the developmental anomalies of the neuronal process.

**Keywords:** chick embryo, neural tube, development, somite

### P-37

#### Foramen ovale

Büyükkertan M<sup>1</sup>, Uysal Ö<sup>2</sup>, Balcıoğlu HA<sup>1</sup>

<sup>1</sup>Faculty of Dentistry, Istanbul University, Istanbul, Turkey; <sup>2</sup>Department of Biostatistics, Bezmialem University, Istanbul, Turkey

**Objective:** Foramen ovale, pterygospinous process, pterygospinous foramen, pterygoalar foramen, sella turcica bridging, caroticoclinoid foramen and foramen vesalius were investigated in dry skulls belonging to the anatomy laboratory at Istanbul University Faculty of Dentistry.

**Methods:** These clinically important anatomical structures were evaluated morphometrically.

**Results:** The long axis of foramen ovale was found to be 7 mm and the width as 3.8 mm. 26 bilateral and 8 unilateral pterygospinous process were evaluated. The average sizes of these process were found to be 2.3 mm. Posterior process of the sphenoid spine was found to be 19.8 mm. A bilateral and two unilateral foramen vesalius were evaluated. Foramen vesalius had an incidence of 21%. It was bilaterally found 16% and unilaterally 5%. A bilateral caroticoclinoid foramen and a bridging was observed.

**Conclusion:** We believe the results of the present study will add to the literature of anatomical sciences and the clinical disciplines studying on these structures.

**Keywords:** foramen ovale, pterygospinous process, pterygospinous foramen, pterygoalar foramen

### P-38

#### Evaluation of quantitative computational techniques used in the determination of facial soft tissue asymmetry

Özsoy U

Department of Anatomy, Faculty of Medicine, Akdeniz University, Antalya, Turkey

**Objective:** The correct measurement of facial soft tissue asymmetry is important for substantial surgical outcomes. For this purpose, different formulas are used. The aim of our study is to compare these formulas and determine their reliability.

**Methods:** The ethics committee of clinical research (Akdeniz University) provided ethical approval for the present investigation (approval no. 70904504/143). Facial soft tissue asymmetry analyses were performed on the 3-dimensional images of 23 men, 28 women acquired by a 3D handheld scanner. A generated mirror image of a facial mask was superimposed on the original mask. The root mean square (RMS), mean absolute deviation (MAD), and mean signed distance (MSD) values were calculated between the original and mirror images.

**Results:** The amount of asymmetry calculated by using formula RMS was  $0.95 \pm 0.29$  mm, MAD  $0.72 \pm 0.22$  mm, and MSD  $-0.04 \pm 0.05$  mm. While the correlation between RMS and MAD ( $r = 0.98$ ) was high, the correlation between MSD and RMS ( $r = -0.26$ ) or MAD was low ( $r = -0.25$ ). The coefficient of variation value among the measurements indicating low variability was very similar for the RMS (30%) and MAD (30%). In contrast, the CV value was significantly higher for the MSD (133%) ( $p < .05$ ).

**Conclusion:** It has been determined that RMS and MAD can be used in place of each other in facial soft tissue asymmetry analysis. In addition, we think that MSD is important in terms of giving information about the direction of asymmetry, even if it is not in the measurement of asymmetry.

**Keywords:** facial soft tissue asymmetry, RMS, MAD, MSD

### P-39

#### Three dimensional analyses of external nose area and volume in healthy subjects

Süzen LB, Özsoy U

Department of Anatomy, Faculty of Medicine, Akdeniz University, Antalya, Turkey

**Objective:** The external nose is one of facial structures that continue to enlarge and modify throughout life. Knowledge of the normal nasal shape and dimensions is necessary for detection of abnormalities caused by genetic and acquired factors, surgical reconstructions and forensic investigations. Estimation method of nasal volume and area of nose is important to produce sufficiently accurate estimates. Various methods, and different geometric approximations were used for the estimation of nasal volume and area. The aim of the present study is to

develop an objective and precise method in order to assess nasal volume and area.

**Methods:** The ethics committee of clinical research (Akdeniz University) provided ethical approval for the present investigation (approval no. 70904504/143). We performed 3D face scanning with a hand-held structured light scanner on 10 males and 10 females healthy volunteers. All the volunteers were of white ethnic origin. They had no history of an underlying craniofacial diagnosis or trauma and had not undergone any previous surgical or orthodontic treatment.

**Results:** The nasal area was calculated in males as  $41 \pm 4$  cm<sup>2</sup> and in females as  $36 \pm 2$  cm<sup>2</sup> and the nasal volume was in males as  $25 \pm 5$  cm<sup>3</sup> and in females as  $20 \pm 3$  cm<sup>3</sup>. Both area and volume measurements were significantly higher in males than the females ( $p < .05$ ).

**Conclusion:** Our study indicates that 3D scanning is easy and precise method in measuring nasal area and volume. This method can be performed in the other regions of the body.

**Keywords:** nasal volume, nasal area, three-dimensional scanning

#### P-40

##### Fusion between the 11th and 12th ribs: a case report

Çevirgen F<sup>1</sup>, Karaca L<sup>2</sup>, Şenol D<sup>1</sup>, Çetin A<sup>1</sup>, Özbağ D<sup>1</sup>

<sup>1</sup>Department of Anatomy, Faculty of Medicine, İnönü University, Malatya, Turkey; <sup>2</sup>Department of Radiology, Faculty of Medicine, İnönü University, Malatya, Turkey

**Objective:** When the anatomic structures of ribs are examined, a great number of congenital and acquired anomalies can be found. Since the known variations are not clinically significant, they are generally found coincidentally either during examination or in chest x-ray. Anomalies seen in the number, size, mineralization or shape of ribs can be regional or pervasive. This study is about a fusion shaped anomaly between 11st and 12nd ribs, which was not seen before in the literature review we conducted.

**Methods:** This case was found in a 25-year-old patient who referred to İnönü University, Faculty of Medicine, Urology Polyclinic with a complaint of side pain. As a result of the tomography, fusion was found between unilateral right side 11 and 12nd ribs. Fusion was found to be between the free tips of ribs.

**Conclusion:** Rib fusions are rarely seen (0.3%). Although they are generally seen between the 1st and 2nd ribs, they have also been reported to occur between other ribs, too. Fusion between ribs can occur on the anterior or posterior parts of ribs. Fusion between two ribs can occur wholly or partially. When it is associated with segmentation defects developmentally, vertebral anomalies can accompany fusion of the rib. Detailed literature review conducted did not reveal any mention of such a variation between 11th and 12nd ribs.

**Keywords:** 11 and 12nd ribs, fusion, variation

#### P-41

##### Microscopic examination of vessel wall changes caused by transient occlusion procedures in human saphenous vein

Bilişli E<sup>1</sup>, Denli Yalvaç Ş<sup>2</sup>, Cumbul A<sup>3</sup>, Uslu U<sup>4</sup>, Söztutar E<sup>1</sup>, Balak N<sup>5</sup>

<sup>1</sup>Department of Anatomy, Faculty of Medicine, Yeditepe University Istanbul, Turkey; <sup>2</sup>Department of Cardiovascular Surgery, Faculty of Medicine, Medeniyet University, Istanbul, Turkey; <sup>3</sup>Department of Histology and Embryology, Faculty of Medicine, Yeditepe University Istanbul, Turkey; <sup>4</sup>Department of Histology and Embryology, Faculty of Medicine, Medeniyet University, Istanbul, Turkey; <sup>5</sup>Department of Neurosurgery, Üsküdar State Hospital, Istanbul, Turkey

**Objective:** The external cross-clamp application and endoluminal balloon technique have been reported as alternate vascular occlusion methods. In the current study, any damage to vessel wall, which might be caused by occlusion after the application of external clamp or endoluminal balloon, was examined histopathologically and the changes on the same vessel segment were compared within themselves to eliminate histological differences between different vessels.

**Methods:** Five to eight cm long segments of great saphenous vein were harvested in each of the patients undergoing phlebectomy for treatment of varicose vein. In each specimen, one end of the vein piece at a distance of 1 cm was occluded with an external cross-clamp for 5 minutes (C) and the other end similarly by an endoluminal balloon (B). The middle sections of veins, not occluded by any means, were taken as a control group (Co). The vessel samples were embedded in paraffin. Stained sections of 5 µm-thick samples were examined with Stereo Investigator software.

**Results:** In endoluminal balloon applied group there was a pronounced endothelial damage and hemorrhage clearly seen in Hematoxylin-Eosin staining. This was not seen in control and external clamp applied groups. The thickness of tunica intima of saphenous vein significantly attenuated endoluminal balloon applied group. The thickness of tunica adventitia of vein was statistically higher than the control group.

**Conclusion:** Both endoluminal balloon and external clamp techniques have harmful effects in the vein wall.

**Keywords:** great saphenous vein, external clamp, endoluminal balloon, histology, microscopy

#### P-42

##### Anatomical variations of hepatic arteries: an analysis by multidetector CT angiography

Karacan K<sup>1</sup>, Karacan A<sup>2</sup>, Akcaalan M<sup>1</sup>, Özkaya BA<sup>3</sup>

<sup>1</sup>Department of Anatomy, Faculty of Medicine, Sakarya University, Sakarya, Turkey; <sup>2</sup>Department of Radiology, Faculty of Medicine, Sakarya University, Sakarya, Turkey; <sup>3</sup>Faculty of Medicine, Sakarya University, Sakarya, Turkey

**Objective:** Hepatic artery variations are important in artery anastomosis of liver transplantations in terms of planning and

application levels of surgery and radiological operations like avoiding vascular injuries in other hepatic surgery involvement. Hepatic artery variations are also supporting the value of detailed preoperative diagnostic radiological investigations abdominal surgical technical operations. They effect directly the success of the operational involvements. The aim of this study is to examine the anatomical variations that occur in the coeliac trunk-hepatic arterial system using by multidetector computer tomography (CT) angiography.

**Methods:** In our study, patients who underwent CT angiography of the coeliac trunk and its branches for various reasons in Sakarya University Training Research Hospital Department of Radiology, from December 2016 through February 2017 were investigated 88 patients were evaluated in the study (46 males-42 females).

**Results:** Our anatomical findings were classified according to Michels's classification. The hepatic arteries had a normal anatomy (Type I) in 70.45% of patients. The most common hepatic artery variations in our series were accessory left hepatic artery (Type V, 13.64%), replaced right hepatic artery (Type III, 6.81%) and replaced left hepatic artery (Type II, 4.55%). Also, we found type VIII and X in 1.14% of patients.

**Conclusion:** Surgeons who are responsible of hepatobiliary surgery should be aware of their hepatic artery anatomy and able to be acquainted with the multiple variants for safe surgery and low morbidity. The arterial patterns are essential in planning and performance for all surgical and radiological processes in the upper abdomen. Therefore, knowing variations of hepatic artery is highly important in liver operations.

**Keywords:** hepatic artery, liver, variation

#### **P-43**

##### **An overview of craniofacial anthropometric measurements in medical sciences**

Akça Z, Gölpinar M, Özel M, Uzun A

*Department of Anatomy, Faculty of Medicine, Ondokuz Mayıs University, Samsun, Turkey*

**Objective:** Craniofacial anthropometry is an objective technique based on a series of measurements and proportions of craniofacial region. It facilitate for the characterization of phenotypic variation among people and quantification of dysmorphology. Craniofacial landmarks play crucial role for getting accurate craniofacial anthropometric data. The aim of this study is to provide a broad overview of landmarks and parameters used in craniofacial anthropometry.

**Methods:** The literature was reviewed to summarize the most commonly used craniofacial landmarks in craniofacial anthropometry. Craniofacial parameters were also summarized according to literature.

**Results:** A total of 47 standard landmarks have been identified for measurement of craniofacial region in anthropometric

studies according to literature. A total of 132 linear and angular craniofacial parameters have been also identified to evaluate the craniofacial morphology. Each landmark and parameters provide important data for evaluation of morphological changes in craniofacial region.

**Conclusion:** Craniofacial anthropometric data plays an important role in monitoring the growth and development. In addition, values obtained from these parameters are also important for identification and quantification of syndromic clinical features, treatment planning, monitoring of operative outcomes. Craniofacial landmarks are very important for getting accurate measurements. Therefore, proper knowledge of the craniofacial landmarks and parameters are essential for craniofacial anthropometry measurements.

**Keywords:** craniofacial anthropometry, landmark, morphometry

#### **P-44**

##### **Sex estimation from morphometric measurements of the anatomical structures of talus**

Öz N, Karakoyun ZN, Süzen LB

*Department of Anatomy, Faculty of Medicine, Akdeniz University, Antalya, Turkey*

**Objective:** The aim of this present study is to use the obtained data from morphometric measurements of the anatomical structures of talus in sex estimation.

**Methods:** In our study, fifty tali (25 right and 25 left tali) of unknown sex/gender in Akdeniz University Faculty of Medicine, Department of Anatomy Laboratory were used. Bones with deformity were excluded from the study. Length of talus, length of facies articularis calcanea posterior (LFACP) and breadth of facies articularis calcanea posterior (BFACP) was measured with digital caliper. The mean of length of talus, LFACP and BFACP were calculated. Values above the mean were considered male and values below the mean were considered female.

**Results:** The mean of length of right and left tali was measured as 57.51 mm and 57.98 mm, respectively. The mean of right and left LFACP was measured 31.25 mm and 32.07 mm, respectively. The mean of right and left BFACP was measured 20.87 mm and 20.88 mm, respectively. According to the mean of length of talus 25 women, 25 men were found. According to the mean of LFACP 27 women, 23 men were found. According to the mean of BFACP 26 women, 24 men were found.

**Conclusion:** We think that morphometrical measurements of talus can give an idea in sex estimation and in determining the anthropological differences of populations by looking at the results obtained from measurements.

**Keywords:** talus, morphometrical measurement, sex estimation



## P-45

**Anatomy of lateral epicondylitis and importance of physiotherapy and rehabilitation in multiple treatment**Çalışgan E<sup>1</sup>, Şenol D<sup>2</sup>, Çevirgen F<sup>2</sup>, Özbağ D<sup>2</sup><sup>1</sup>Department of Physical Therapy and Rehabilitation, Health High School, Kahramanmaraş Sütçü İmam University, Kahramanmaraş, Turkey;<sup>2</sup>Department of Anatomy, Faculty of Medicine, İnönü University, Malatya, Turkey

**Objective:** The goal of this review is highlighting anatomy of lateral epicondylitis and importance of physiotherapy and rehabilitation in multiple treatment.

**Methods:** 112 articles and medical journals were scanned for this review article.

**Results:** Lateral epicondylitis symptoms are reduced hand functions, decreasing grip strength and pinching strength. The primary etiologic factor is believed to be the overload of the aponeurosis of the attachment site of the joint external muscles. Internal stress on tendon fibers due to overuse of the tendons increases with time and causes pain. Ligamentum collaterale radiale and anulus radii strain, angio fibroblastichyperplasia and muscular hypersellurate occur in the acute phase. Primer pathologic changes occur in the proximal musculotendinous adhesion site of extensor carpi radialis brevis (ECRB).

**Conclusion:** The accepted theory today is that of ECRB which is sometimes the process that leads to small tears of the extensor digitorum communis muscle and starts with overuse injuries. In the treatment of lateral epicondylitis, ESWT (Extracorporeal Shock Wave Therapy) and High Density Laser Therapy are additionally used in addition to conventional therapy. Laser therapy is included in 5 sessions a week for 3 weeks, ESWT treatment is 3 sessions of per week, use of local corticosteroids and bandage. Treatment of chronic lateral epicondylitis includes 20 min of hot pack for resolving scars, 5 of ultrasound, 20 min of TENS (Transcutaneous Electrical Nerve Stimulation) application plus on additional 5 min of deep friction massage.

**Keywords:** lateral epicondylitis, extensor muscle, laser, shock wave therapy

## P-46

**Morphometric evaluation of trigeminal nerve and Meckel cave**Şen S<sup>1</sup>, Bilgin SŞ<sup>2</sup>, Atasever A<sup>1</sup><sup>1</sup>Department of Anatomy, Faculty of Medicine, Istanbul Medipol University, Istanbul, Turkey; <sup>2</sup>Department of Radiology, Istanbul Medipol University, Medipol Mega Hospital, Istanbul, Turkey

**Objective:** This study aimed to evaluate the theories about trigeminal neuralgia predisposition with respect to the morphological characteristics of the trigeminal nerve and the Meckel cave among age groups, sex and lateralization. This retrospective study included 120 (62 males, 58 female) healthy individuals over age of 20 who had no previous or current cranial pathology.

**Methods:** Ethics committee approval was obtained with decision 294 of Medipol University Non-Interventional Clinical Researches Ethics Committee dated 25.05.2016. Before the study, ethics committee approval was obtained with the decision of Ethics Clinical Prevention Clinical Investigation Ethics Committee of Faculty of Medicine dated 25.05.2016 and numbered 294. According to age ranges, individuals were evaluated in four groups as 20-29 years, 30-39 years, 40-49 years, 50 years and over. Besides the long and short axis lengths and the diameter of nervus trigeminus, long and short axis lengths of Meckel cave, as well as the trigeminal-pons angle were measured using 3D bFFE sequence with 3T MRI on the right and left sides.

**Results:** It was observed that the long axis (mean 0.79±0.20 cm on the right, 0.86±0.28 cm on the left, p<0.05) and short axis (mean 0.36±0.10 cm on the right and 0.41±0.17 cm, p<0.05) lengths of nervus trigeminus were shorter on the right side in comparison to the left. Moreover, in males the long axis length of Meckel cave was higher on both the right and left sides compared to females (p<0.05).

**Keywords:** trigeminal ganglion, aging, trigeminal nerve, trigeminal neuralgia, morphometry

## P-47

**Coccygeal retroversion: a case report**Yılmaz Kayatekin AZ<sup>1</sup>, Kayatekin O<sup>2</sup>, Uluçam E<sup>1</sup>, Taşkınıalp O<sup>1</sup><sup>1</sup>Department of Anatomy, Faculty of Medicine, Trakya University, Edirne, Turkey; <sup>2</sup>Orthopedics and Traumatology Clinic, Edirne Sultan 1. Murat State Hospital, Edirne, Turkey

**Objective:** Coccygeal curvature angle is measured between the vertical axes of the first and last coccygeal vertebrae. Coccyx types are classified into four groups by measurement of coccygeal curvature angle, in the literature. However, a rare coccygeal angulation, that is not included in this classification is backwards. This type of angulation is called “coccygeal retroversion”. Coccydynia is a very common symptom, which describes pain at the inferior tip of spine and takes time to treat. Movements such as sitting, standing up, or walking change the severity and character of the pain. The one third part of the cases are traumatic, while the other one third part are idiopathic. Coccygeal retroversion is also among the causes of coccydynia.

**Methods:** There was no trauma story of a 20 years old female patient who complained of recurrent coccydynia in Edirne State Hospital. It was found that angulation of coccyx bone was pointing backwards as seen on radiography.

**Results:** Coccygeal retroversion was reported in the literature in symptomatic and asymptomatic individuals. The authors of these studies suggest incorporating these retroverted coccyges into the coccygeal curvature classification as the fifth type. It is important to understand the morphometric and anatomic structure of the bone since coccydynia treatment extends surgically to removal of

coccyx. In this respect, studies that investigate coccygeal anatomy in larger populations may contribute to medical practice.

**Keywords:** coccyx, coccygeal retroversion, coccydina

#### P-48

##### The effects of formaldehyde inhalation on the myeloperoxidase and hydroxyproline levels in the rats

Taşdemir R<sup>1</sup>, Acar E<sup>2</sup>, Çolak T<sup>1</sup>, Yener MD<sup>1</sup>, Eraldemir FC<sup>2</sup>, Maral Kır H<sup>2</sup>, Bamaç B<sup>1</sup>

<sup>1</sup>Department of Anatomy, Faculty of Medicine, Kocaeli University, Kocaeli, Turkey; <sup>2</sup>Department of Biochemistry, Faculty of Medicine, Kocaeli University, Kocaeli, Turkey

**Objective:** Formaldehyde is a toxic chemical which is frequently used in the health sector, especially in pathology and anatomy as well as industrial sectors such as textiles, wood and cosmetics. We aimed to investigate the effect of formaldehyde inhalation on heart and aorta in relation to the levels of Myeloperoxidase enzyme and Hydroxyproline aminoacid. Our study was approved by Kocaeli University Animal Experiments Local Ethics Committee, dated 10/20/2016 and number 6/1 – 2016.

**Methods:** 24 Wistar Albino female rats were used in the study. The first 8 animals were identified as control group. The second group was exposed to an average of 1 ppm low-dose and the last group was exposed to high-dose FA inhalation of 10 ppm on average. At the end of experiment the animals were sacrificed, their bloods, hearts and aortas were removed. ELISA technique was used for identification of myeloperoxidase enzyme and hydroxyproline aminoacid.

**Results:** Statistical evaluation revealed a significant difference between the control and low dose FA group ( $p<0.05$ ) for hydroxyproline and myeloperoxidase levels in aorta. When Myeloperoxidase levels were examined in serum, there was a significant difference between the control group and both the groups exposed to low and high dose FA ( $p<0.05$ ).

**Conclusion:** Considering the negative effects of FA on living tissues, oxidative stress is shown as a crucial factor of emergence of these effects. During the formation of oxidative stress, selected and measured enzymes and aminoacids may have an important role for understanding cellular damage from FA, inhibiting negative effects, shedding light on these mechanisms.

**Keywords:** formaldehyde, hydroxyproline, myeloperoxidase, rat

#### P-49

##### Nervus terminalis “the 13th cranial nerve”

Babacan S, Yıldız Yılmaz M, Kafa İM

Department of Anatomy, Faculty of Medicine, Uludağ University, Bursa, Turkey

The early discovery and naming of known cranial nerves began at 2nd century by Claude Galen. In 1778, Samuel Sömmering classified these nerves as currently known. Later, Felix Pinkus discovered a different nerve “New Nerve” in 1884. This “13th cranial nerve”

was named as “Cranial Nerve 0” by some authors because of its rostral location according to other cranial nerves. The name of “Nervus terminalis (NT)” was also given by William Locy, in 1905, because of its relationship with “Lamina terminalis”. J.B Johnston identified the presence of NT in human embryo in 1905 and NT was identified in adults by Charles Brookover in 1914. The route of NT includes, trigonum olfactorium; inferior surface of gyrus rectus, lateral side of crista galli and medial side of tractus olfactorius, in appearance of thin bands as unmyelinated fibers. Nervus terminalis, which has proximal connections with stria olfactoria and lamina terminalis, distributes branches at the level of organum vomeronasale after getting into nasal cavity by passing through cribriform palate. It was noticed, some fibers have relationships with adjacent blood vessels. As the results of studies on NT which the function of it is still unknown, it was postulated, the luteinizing hormone-releasing hormone, serve as a neuromodulator rather than a simple hormone, was secreted by activity of NT. Demski et al put forth that NT is a chemosensory pathway related with pheromones.

**Keywords:** 13th cranial nerve, nervus terminalis, cranial nerve “0”

#### P-50

##### Compliance of lumbar facet morphology

Çandır BN<sup>1</sup>, Sağlam L<sup>1</sup>, Tosunoğlu E<sup>1</sup>, Gürtekin B<sup>2</sup>, Gürses İA<sup>1</sup>, Öztürk A<sup>1</sup>

<sup>1</sup>Department of Anatomy, Istanbul Faculty of Medicine, Istanbul University, Istanbul, Turkey; <sup>2</sup>Department of Biostatistics, Istanbul Faculty of Medicine, Istanbul University, Istanbul, Turkey

**Objective:** Facet anatomy, especially facet tropism, is strongly associated with lumbar osteoarthritis and disc herniation. Nevertheless, studies on the relationship of facet anatomy and tropism with vertebral levels are scarce. We aimed to investigate facet anatomy and vertebral compliance among vertebrae with known levels.

**Methods:** After obtaining Ethics Committee approval (Number: 819, Date: 30.06.2017), 10 skeletons from the osteology collection of Istanbul Faculty of Medicine Department of Anatomy was used. Facet morphology, articulating facet compliance, facet angle, and tropism was evaluated.

**Results:** Fifty vertebrae with no record of age and sex were evaluated. On the right side, C (18%), J (40%), and Flat (42%) facet morphology was present. On the left side, C (14%), J (42%), and Flat (44%) facet morphology was present. Facet angle was  $34.6\pm 9.9^\circ$  and  $37.1\pm 9.3^\circ$  for right and left sides, respectively ( $p=0.027$ ). There were no tropism in 62%, mild tropism in 30%, and severe tropism in 8% of the vertebrae. When compared, there were no significant relationship for facet morphology with tropism degree ( $p=0.75$ ) and vertebral level ( $p=0.30$ ). Additionally, there were no inconformity among articulating facets ( $p=0.29$ ).

**Conclusion:** Although there were no significant correlation between facet tropism and morphology, we observed a signifi-

cant difference in facet angles. We propose further studies should be performed that investigate the affects of rotational vertebral pathologies (ie. scoliosis) on facet anatomy.

**Keywords:** facet anatomy, faset angulation, facet joint morphology, tropism, vertebra

## P-51

### The effect of formaldehyde inhalation on pancreas tissue in rats

Aksu E<sup>1</sup>, Acar E<sup>2</sup>, Çolak T<sup>1</sup>, Taşdemir R<sup>1</sup>, Maral Kır H<sup>2</sup>, Eraldemir FC<sup>2</sup>, Güzelordu D<sup>1</sup>, Sivri İ<sup>1</sup>, Bamaç B<sup>1</sup>

<sup>1</sup>Department of Anatomy, Faculty of Medicine, Kocaeli University, Kocaeli, Turkey; <sup>2</sup>Department of Biochemistry, Faculty of Medicine, Kocaeli University, Kocaeli, Turkey

**Objective:** Formaldehyde is a highly toxic chemical substance that is used widely in industrial fields. Because it is also used in anatomy laboratories for storing tissues and preserving the cadavers, anatomists are closely related with it. There were studies about negative effects of formaldehyde on human health in the past.

**Methods:** We aimed to determine the effect of formaldehyde exposure on pancreas tissue, in terms of TNF- $\alpha$ , IL-1 $\beta$  and insulin/glucagon levels with Elisa method. For our study, the approval was taken from Kocaeli University Animal Testing Local Ethics Council on 20.10.2016 with 6/1 – 2016 number. 24 Wistar albino female rats were used in this study. First group (n=8) was the control group. The second group (n=8) was the low level formaldehyde (mean: 1 ppm) exposure testing group. The third group (n=8) was the high level formaldehyde (mean: 10 ppm) testing group. The rats in the testing groups were inhaled formaldehyde in a testing cabine during 12 weeks totally, five times a week, four hours a day. After the test, the rats were sacrificed and then their pancreases were taken. With Elisa method, TNF- $\alpha$ , IL-1 $\beta$ , insulin and glucagon levels on pancreas tissues were investigated. The results were analyzed statistically with SPSS for Windows v20 package program.

**Results:** Although there was increase in the means of the results between the control and testing group, that wasn't a significant difference.

**Conclusion:** We think that both in serum and molecular level advanced analysis should be made for exploring the effect of formaldehyde.

**Keywords:** formaldehyde, glucagon, IL-1 $\beta$ , insulin, pancreas, TNF- $\alpha$

## P-52

### The mystery of nervus terminalis (terminal nerve)

Yıldız S<sup>1</sup>, Kocabıyık N<sup>1</sup>, Cömert A<sup>2</sup>, Ozan H<sup>3</sup>

<sup>1</sup>Department of Anatomy, University of Health Sciences, Gülhane Faculty of Medicine, Ankara, Turkey; <sup>2</sup>Department of Anatomy, Faculty of Medicine, Ankara University, Ankara, Turkey; <sup>3</sup>Department of Anatomy, Faculty of Medicine, Ufuk University, Ankara, Turkey

**Objective:** Cranial Nerve Zero was first discovered by German Scientist Gustav Fritsch in 1878 in brain of sharks. After that scientists found this nerve in whales. It was first found in humans in 1913. The nerve is referred to as the nervus terminalis because in species initially examined its fibers were seen entering brain in the region of the lamina terminalis. Aim of this study is to emphasize that cranial nerve 0 to reveal morphological characteristics and should be a part of the anatomy education.

**Methods:** Initially it was confused to be associated with olfactory nerves i.e. extra lobular olfactory projections. After further investigations, it was found that cranial nerve zero is not connected to olfactory bulb. The nerve projects to medial and lateral septic nuclei and preoptic areas which are involved in sexual behavior of animals.

**Results:** Nervus terminalis lies bilaterally as a plexus of unmyelinated peripheral nerve fascicles in subarachnoid space covering gyrus rectus of orbital surface of frontal lobe. The plexus in the region of cribiform plate of ethmoid courses posteriorly to vicinity of olfactory trigone, medial olfactory region and lamina terminalis. As compared to human adults, it is very prominent in infants and fetuses.

**Conclusion:** Several studies in cell and molecular biology have demonstrated significant role of Nervus terminalis in release of luteinizing releasing luteinizing hormone (LHRH) and is therefore thought to play role in reproductive behavior. Consequently, the human anatomy as well to specify the functional significance of this neural anatomy education and we think that should be considered.

**Keywords:** cranial nerve zero, nervus terminalis, terminal nerve

## P-53

### Posterior interosseous nerve syndrome (PINS) originating from lipoma of the proximal radius: a case report

Yıldırım FB<sup>1</sup>, Ögüt E<sup>1</sup>, Özsoy U<sup>1</sup>, Yıldırım A<sup>2</sup>

<sup>1</sup>Department of Anatomy, Faculty of Medicine, Akdeniz University, Antalya, Turkey; <sup>2</sup>Department of Orthopaedics and Traumatology, Manavgat Private Medical Center, Antalya, Turkey

A 68-year old man applied with history of progressive weakness of the left hand. Enlarging lump on lower posterolateral aspect of the left antecubital fossa for last 2 weeks. Physical examinations and diagnostics revealed that deeply embedded mass with capsules, soft tissue solitary lump was palpable on left antecubital fossa. Axial T1, T2 PD, sagittal T2 PD, coronal T1, T2 PD sections from proximal radius (4.5x3x2 cm dimensions) lump was observed which was uniform lobulated, lesion with fat-isointense and liquid intensity in elbow joint and extending posterolaterally to the anterior of radius. Fluid intensities were observed in joint space. Total degeneration of the left distal radial nerve was detected, partial degeneration of left ulnar nerve was observed. DSAP amplitude was not obtained in the left radial nerve and decreasing velocity of sensory was observed in the left ulnar

nerve. The patient underwent surgical excision of the lump with decompression of the posterior interosseous nerve (PIN) in the radial tunnel. An anterior approach was performed including subperiosteal dissection beginning proximal to the lateral epicondyle and continuing interval between the biceps and brachioradialis muscles. On pathological examination, peripheral fat were consistent with the diagnosis of lipoma. If surgery is delayed, fibrosis of the forearm muscles may occur. Surgical operation resulted in optimal functional recovery of the left hand. Patient applying with hand drop with intact wrist extension and intact sensations, should be first suspected of having posterior interosseous nerve syndrome (PINS) and a careful research for possible etiology in the cubital fossa.

**Keywords:** posterior interosseous nerve syndrome, intramuscular lipoma, lipoma

#### P-54

##### The incidence of bipartite zygomatic bones types

Öğüt E, Yıldırım FB

Department of Anatomy, Faculty of Medicine, Akdeniz University, Antalya, Turkey

**Objective:** The zygomatic bone is sometimes divided into two or three parts with vertical, oblique or horizontal sutures. It was called as “os japonicum or os ainoicum” because it was observed more in eastern asia than the other populations. For this reason we aimed to determine the incidence of bipartite zygoma’s types in dry skulls and zygomatic bones.

**Methods:** In this study both sides of 120 dry skulls and 50 zygomatic bones were examined with macroscopically. All the skulls and the bones were obtained from the Department of Anatomy, Faculty of Medicine, Akdeniz University. The presence, incidence and subtypes of bipartite zygomatic bones were assessed.

**Results:** Two bipartite zygomatic bone out of 120 dry skulls showing the incidence of %1.6 on both side and also bipartite zygoma was present in 6 out of 50 zygomatic bones. Total of 8 (%2.75) were observed bipartite in 290 zygomatic bones. When the data was statistically analysed, it was observed that the incidences of type IV (%3.3) were significantly higher than type I (%1.7), III (%1.7) and VII (%1.6) ( $p < 0.05$ ). No other subtypes were observed in the skulls.

**Conclusion:** it is very important for maxillofacial surgeons to learn information and carefully observation about bipartite zygoma during surgical operation.

**Keywords:** bipartite zygomatic bone, osteology, zygomatic bone

#### P-55

##### Is there a correlation between the lingula and coronoid process types of mandible?

Öğüt E, Yıldırım FB

Department of Anatomy, Faculty of Medicine, Akdeniz University, Antalya, Turkey

**Objective:** We aimed to analyze the frequency and correlation between the coronoid process of the mandibula (PCM) and the lingula mandibula (LM) by determining their types.

**Methods:** 100 dry adult human mandibles were evaluated with unknown age and gender to determine the relationship between the types of LM and PCM. The quantitative variables were the distances between the LM and PCM. The qualitative variables were the types of the LM and the PCM. SPSS software (version 20.0) was used for all statistical analyses and p-value less than 0.05 was considered statistically significant.

**Results:** Truncated type of LM were the most observed type on 43 (47%) the left and 41 (45%) right side. Triangular type of PCM were the most observed type 55 (60%) on the left and 55 (60%) right side. Truncated type of LM was the most common 28 (65%) regardless of types of PCM. Nodular and round type of LM was more seen when the mix type of PCM existed on the right side. No differences were found between the distances of PCM and LM on both side ( $p > 0.05$ ).

**Conclusion:** It is obligatory to know the morphology of the lingula and processus coronoideus mandibula in order to preserve important anatomical structures during maxillofacial surgery. In this studies parameters may help the surgeon to facilitate the preservation of anatomic structures and reduce the risk of injury.

**Keywords:** lingula of mandible, coronoid process of mandible, maxillofacial surgery

#### P-56

##### Gray and white matter in attention deficit and hyperactivity disorder by voxel-based morphometry

Yılmaz S<sup>1</sup>, Çayan D<sup>2</sup>, Acer N<sup>3</sup>, Doğan M<sup>4</sup>, Per H<sup>5</sup>, Özmen S<sup>6</sup>

<sup>1</sup>Department of Anatomy, Faculty of Medicine, Bozok University, Yozgat, Turkey; <sup>2</sup>Niğde Zübeyde Hanım School of Health, Niğde Ömer Halisdemir University, Niğde, Turkey; <sup>3</sup>Department of Anatomy, Faculty of Medicine, Erciyes University, Kayseri, Turkey; <sup>4</sup>Department of Radiology, Edirne Sultan 1. Murat Public Hospital, Edirne, Turkey; <sup>5</sup>Department of Child Neurology, Faculty of Medicine, Erciyes University, Kayseri, Turkey; <sup>6</sup>Department of Child Psychiatry, Faculty of Medicine, Erciyes University, Kayseri, Turkey

**Objective:** Attention-deficit/hyperactivity disorder (ADHD) is a common neurodevelopmental disorder affecting between 3% and 5% of children and young persons. It is characterized by pervasive and developmentally inappropriate levels of inattention, impulsivity, and hyperactivity and wide-ranging behavioral and cognitive impairments, including deficits in working memory, inhibitory control, and altered motivational style. Gray and white matter volume deficits have been reported in many structural magnetic resonance imaging (MRI) studies of (ADHD); however, there is a paucity of structural MRI studies of children with ADHD.

**Methods:** Eight adults children with ADHD and 8 healthy control subjects compared whole brain volume had an MRI on a 1.5T Siemens scanner. Analyses were carried out by VBM-

SPM. Voxel-based morphometry is a method for detecting group differences in the density or volume of brain matter. We identified brain areas that differed between participants with ADHD and controls.

**Results:** ADHD children had significantly smaller gray matter volumes in parts of these regions in medial frontal gyrus, Brodman areas 6-8-9-10, white matter volumes significantly decrease in limbic lobe, cingulate gyrus and posterior cingulate.

**Conclusion:** The findings suggest that children with ADHD show brain structural changes in some regions. Future studies should address these questions by studying the effects of substance use and medications on the brain in ADHD individuals.

**Keywords:** MRI, voxel based morphometry, ADHD, brain volume

### P-57

#### Examination of the temporomandibular joint in terms of morphological and clinical anatomy

Vatansever A<sup>1</sup>, Demiryürek D<sup>2</sup>

<sup>1</sup>Department of Anatomy, Faculty of Medicine, Balıkesir University, Balıkesir, Turkey; <sup>2</sup>Department of Anatomy, Faculty of Medicine, Hacettepe University, Ankara

**Objective:** Temporomandibular joint is the one of the important joint with significant function in the head region. This joint is exposed to strong pressure, especially during the chewing movements and pathologies of the joint are common. Temporomandibular joint disorders are occurred with severe pain. Recent studies focused on the development of treatment methods for temporomandibular disorders. The increase number of researches on prosthesis implantations especially for the condylar process increases the importance of the neighbourhood relations of it with other anatomical structures in this region.

**Methods:** We researched that relations of structures which contribute to the temporomandibular joint in 61 patients computed tomographic images.

**Results:** We measured the vertical distance between the deepest point of the mandibular fossa and the highest point of head of mandibula bilaterally in coronal sections, latero-medial length of the condylar process, and between medial border on the condylar process and the carotid canal in axial sections. Then we have compared these data between age and gender. According to our results, the average distance between mandibular fossa and head of the mandibula was 2.91 mm, the average diameter of the condylar process was 17.66 mm, and between carotid canal and the medial border of the condylar process was 9.27 mm.

**Conclusion:** The condylar process, a moving part of the temporomandibular joint, an important joint in the head region, has a great importance for surgical treatment and reconstruction, as well as functional anatomy and proximity to the important anatomic structures in the region.

**Keywords:** temporomandibular joint, condylar process, head of mandible, mandibular fossa

### P-58

#### Anatomy of the Gantzer muscle and its importance in nerve entrapments at the proximal forearm

Tosunoğlu E, Çandır BN, Sağlam L, Gürses İA, Kale A

Department of Anatomy, Istanbul Faculty of Medicine, Istanbul University, Istanbul, Turkey

**Objective:** Kiloh-Nevin Syndrome is rare and characterized with anterior interosseous nerve (AIN) entrapment at the proximal forearm. Gantzer muscle, which is an accessory head of flexor pollicis longus (FPL) or flexor digitorum profundus (FDP) muscles, is considered as a potential pathology for entrapment. Although its frequency is reported relatively high, detailed anatomy of the muscle is scarcely studied. We aimed to investigate the presence, topographical relations, morphology and morphometry of Gantzer muscle.

**Methods:** Fifty forearms were dissected at the Istanbul Faculty of Medicine Department of Anatomy following IRB approval (Number: 809; Date: 29.06.2017). After evaluating the presence and morphology of the muscle, the distances between the inter-epicondylar line to AIN branching point and AIN crossing were measured.

**Results:** Gantzer muscle frequency was 66%. The muscle terminated at the FPL in 16 (51.6%), the FDP in 9 (29%), and both FPL and FDP in 6 (19.4%) forearms. The AIN branched at an average distance of 51.1±8 mm and 45±10 mm from the inter-epicondylar line on the right and left sides, respectively. The muscle crossed the AIN at an average distance of 82±9 mm and 73.7±6.3 mm from the inter-epicondylar line on the right and left sides, respectively.

**Conclusion:** Detailed knowledge on the anatomy of the Gantzer muscle and exact location of possible AIN entrapment is of importance to hand surgeons and anatomists.

**Keywords:** anterior interosseous nerve, Gantzer muscle, Kiloh-Nevin syndrome, nerve entrapment

### P-59

#### Perceptions of cadavers in physiotherapy students and approaches to use of cadavers for physiotherapy education

Bilir A<sup>1</sup>, Ertekin T<sup>1</sup>, Turamanlar O<sup>1</sup>, Erbay H<sup>2</sup>, Güzel H<sup>1</sup>

<sup>1</sup>Department of Anatomy, Faculty of Medicine, Afyon Kocatepe University, Afyonkarahisar, Turkey; <sup>2</sup>Department of History of Medicine and Ethics, Faculty of Medicine, Afyon Kocatepe University, Afyonkarahisar, Turkey

**Objective:** We aimed to determine how Physiotherapy students perceive cadavers and what kind of approach they have adopted for use cadavers and how cadavers education have changed their feelings and emotions in anatomy education. Data form that consist twelve expression was used for determining of students' perception about cadavers.

**Methods:** Fifty students (100forms) (%62 female) were participated in research. Most of participants have adopted expression before the cadaver education was “Dead human bodies shown in public areas without educational purposes affect cadaver donation adversely.” (4.52±0.79). While they have adopted after the cadavers education was “Human is valuable asset. Therefore; value and respect must be given to the human body. While person was both alive or after death” (4.60±0.93).

**Results:** When the questionnaire data (before and after) were compared, statistically significant differences were found in expression of “Dead human bodies shown in public areas without educational purposes affect cadaver donation adversely” (p=0.037) and “3D modeling or working on the human models is more useful than studying on cadavers in anatomy education” (p=0.005). It was observed that the number of participations was decreased for the first expression and in contrast with increased for the second expression.

**Conclusion:** Physiotherapy students regard to cadavers for in terms of human aspect and value and attribute to him/her special value in terms of contribute to education. Students who were studying on cadavers in anatomy education tend to see cadaver as an education a material. We thought that these results could be help to shape and improve the anatomy education.

**Keywords:** anatomy, physiotherapy students, cadaver, perception of students, ethic

## P-60

### Medial circumflex femoral artery origin variations

Keven A<sup>1</sup>, Öztürk S<sup>2</sup>, Aytaç G<sup>2</sup>, Sindel M<sup>2</sup>

<sup>1</sup>Department of Radiology, Faculty of Medicine, Akdeniz University, Antalya, Turkey; <sup>2</sup>Department of Anatomy, Faculty of Medicine, Akdeniz University, Antalya, Turkey

**Objective:** Medial circumflex femoral artery (MCFA) is a branch of the deep femoral artery (DFA) which is important for blood supplying the caput femoris and fossa trochanterica. Knowledge of MCFA variations are important in order to avoid injuries that may occur during surgeries or angiography procedures applied to this region. The purpose of this study is to evaluate MCFA origin variations and it's distance from the inguinal ligament.

**Methods:** Twenty patients 16-79 (mean 53.7) aged with bilateral lower extremity computerized tomography angiography (CTA) in the Akdeniz University Department of Radiology were included in the study. A new generation 128-section multislice CT device was used in the peripheral BTA. Multiplanar reconstruction, maximum intensity projection and 3D volume rendering images are obtained from source images. MCFA's origin variations and it's distance from the inguinal ligament were evaluated. MCFA origins were classified according to the literature and their rates were determined.

**Results:** MCFA was originated from deep femoral artery (DFA) with 65% percentage (Type 1), from femoral artery

(FA) with 25% percentage (Type 2), FA from DFA level with 5% percentage (Type 3), from both FA and DFA with 5% percentage (Type 5b). Type 4 and type 5a variations were not encountered. The distance MCFA to the midpoint of inguinal ligament was measured as 4.7±1.17 cm.

**Conclusion:** The most common origin of the MCFA was from the DFA, consistent with the literature. However, it has been observed that the MCFA can vary greatly with regards to it's origin. Therefore, knowledge of MCFA's origin, variations and distance to the inguinal ligament are important during surgical operations, catheterization and angiographic approaches.

**Keywords:** medial circumflex femoral artery, deep femoral artery, angiography, variation

## P-61

### Variations of the origin of the deep femoral artery

Keven A<sup>1</sup>, Öztürk S<sup>2</sup>, Aytaç G<sup>2</sup>, Sindel M<sup>2</sup>

<sup>1</sup>Department of Radiology, Faculty of Medicine, Akdeniz University, Antalya, Turkey; <sup>2</sup>Department of Anatomy, Faculty of Medicine, Akdeniz University, Antalya, Turkey

**Objective:** Deep femoral artery (DFA) which is important for blood supplying the lower extremity is also important during surgical procedures to be applied to the femoral region as far as angiographic procedures. The aim of this study is to evaluate the DFA's origin from the femoral artery (FA), it's distance to the inguinal ligament and measurable length of the DFA.

**Methods:** Twenty patients 16-79 (mean 53.7) aged with bilateral lower extremity computerized tomography angiography (CTA) in the Akdeniz University Department of Radiology, were included in the study. A new generation 128-section multislice CT device was used in the peripheral BTA. Multiplanar reconstruction, maximum intensity projection and 3D volume rendering images are obtained from source images. DFA origin areas (posterior, anterior, posterolateral, lateral, medial) and it's distance to the inguinal ligament are evaluated from this images.

**Results:** The APF mostly originated from the posterior (47.5%) or posterolateral aspect of the FA (47.5%). 12 of these posterior origins were right, 7 were left; 11 of posterolateral origins were left, 8 were right. Anterior, medial and lateral origins were detected only in 1 case. The mean distance of DFA origin to the midpoint of inguinal ligament was 5±1.2 cm in right, 3.76±1.53 cm in left for male; 4.67±0.72 cm in right and 4.2±1.1 cm in left for female. Measurable length of the DFA was found 20.5±3.62 cm in right, 20.1±2.2 cm in left for male; 17.41±2.95 cm in right and 18±1.63cm in left for female.

**Conclusion:** Knowledge of the DFA's origin and it's distance from the inguinal ligament will provide the physician to define the vascular anatomy prior to invasive procedures and to avoid iatrogenic injuries.

**Keywords:** deep femoral artery, angiography, variation

**P-62****Relation between the renal fascia and vascular structures**

Develi S, Yalçın B

*Department of Anatomy, University of Health Sciences, Gülhane Faculty of Medicine, Ankara, Turkey*

**Objective:** Renal fascia is a pouch derived from extraperitoneal connective tissue that contains the kidneys, the suprarenal glands, the renal vessels and perirenal fat. Anterior layer of renal fascia of the right and left sides joins across the midline in close relationship to the renal aa. and vv.; renal fascia encapsulates the inferior vena cava and aorta at the level of origin of the renal vessels, according to anatomy and radiology textbooks. On the other hand surgery textbooks suggest that anterior layer does not continue with opposite site. Our aim was to reveal the continuation of anterior layer and examine the relation between vascular structures, especially anterior branches of abdominal aorta.

**Methods:** 11 adult cadavers were examined. (10 male, 1 female). Age of the cadavers was unknown. Renal fascia, its anterior and posterior layers were examined on the both sides. Continuation of layers and relationship between vascular structures were revealed.

**Results:** Anterior layer was found to be continued with the opposite side. Anterior branches of abdominal aorta were piercing the fascia and fatty pad in front of it, before entering mesenterium. In of the samples anterior layer was found to be fibrous than other samples.

**Conclusion:** Mesenteric ischemia is not an uncommon clinical condition. Major etiological factor is atherosclerosis but other extra luminal causes such tumoral compression can be seen. We think that renal fascia especially more fibrotic forms can also compress the anterior branches of abdominal aorta and can cause ischemia.

**Keywords:** abdominal aorta, mesenteric ischemia, renal fascia

**P-63****Incidence and distribution of sesamoid bones in the hand**

Akkoc RF, Şap O, Ögetürk M

*Department of Anatomy, Faculty of Medicine, Firat University, Elazığ, Turkey*

**Objective:** Sesamoid bones are usually small and oval shaped bones with varying shapes and sizes which are embedded in certain tendons that are very close to the bones and joints on the palmar and plantar joint surfaces. Their traumatic and degenerative injuries are frequently encountered. Therefore, determining the distribution characteristics of sesamoid bones in the hand will not only provide anatomic information but also aid in understanding the pathological conditions of the hand including these bones.

**Methods:** The PA hand x-rays, which were taken with the focus film distance of 100–110 cm by Firat University Hospital

Radiology Department, of a total of 700 adults including 231 male and 469 female were evaluated retrospectively.

**Results:** In the present study, the presence of sesamoid bone in I. metacarpal (MC) bone was detected to be 100% in both males and females in both right and left hand. It was detected at the rates of 68.4% in males and 66.3% in females in the II. MC. Its distribution in hands was as 67.8% in the right hand and 66.2% in the left hand. In the first phalanx proximalis, sesamoid bones were detected at the rate of 54.6% in males and 49.5% in females. Of them, 49.0% were in the right hand and 46.7% in the left hand. At the same time, other MC bones and phalanx bones were evaluated as well.

**Conclusion:** Knowing the detailed anatomy of sesamoid bones will increase the early and accurate diagnosis of diseases associated with sesamoids in radiological examinations.

**Keywords:** sesamoid, hand, X-ray

**P-64****Importance of the internal acoustic meatus in neuro-otological surgery**

Şekerci R, Ögüt E, Keleş Çelik N

*Department of Anatomy, Faculty of Medicine, Akdeniz University, Antalya, Turkey*

**Objective:** Internal acoustic meatus (IAM) is a basic landmark in various neuro-otological surgeries. Knowledge the anatomy of IAM is important to prevent from damage of neurovascular structures around there during the surgery. The aim of present study is to describe the morphometry of IAM with respect to neurovascular structures passing with postero-inferior surface of temporal bone.

**Methods:** 120 dry temporal bones (61 male and 59 female) were examined for the study. The shape of IAM was evaluated and the dimensions of IAM were measured and distance from sigmoid sulcus, jugular foramen, superior petrosal sulcus were calculated in millimeters using by digital calliper.

**Results:** 43 (%35.8) IAM was elliptical and 77 (%64.1) round in shape. Round shape more common than elliptical on both side [32 (%26.6) in the left 39 (%32.5) right]. The average length and width of internal acoustic meatus was 6.64 mm (female/6.59, male/6.68) and 4.31 mm (female/4.26, male/ 4.36). The average distance from IAM to superior petrosal sulcus 7.13 mm (female/7.07, male/7.19), jugular foramen 8.62 mm (female/8.36, male/8.86), sigmoid sulcus 19.88 mm (female/19.39, male/20.31) respectively.

**Conclusion:** The data obtained from this study reveals that results of reducing the damage of neurovascular structures during neuro-otological surgery on internal acoustic meatus.

**Keywords:** neuro-otological surgery, temporal bone, internal acoustic meatus

**P-65**

**Investigation of value of the metacarpal index in healthy adult and geriatric people admitted to Firat University Hospital**

Şap O<sup>1</sup>, Kavaklı A<sup>1</sup>, Yıldırım H<sup>2</sup>

<sup>1</sup>Department of Anatomy, Faculty of Medicine, Firat University, Elazığ, Turkey; <sup>2</sup>Department of Radiology, Faculty of Medicine, Firat University, Elazığ, Turkey

**Objective:** Metacarpal Index, which used for the diagnosis of marfan syndrome, has been recognized as a simple, cheap and objective method. In this study, it was aimed to evaluate the MI values the connection between genders and the progressive age in healthy adults and geriatric people.

**Methods:** Right hand X-Ray images of healthy adult and geriatric patients over 25 years of age without any skeletal disorder or hand pathology applied to the Firat University Radiology Department. Gender and age groups were created, with of 1000 patients. 200 patients were randomly selected for each age groups using the Enlil Pacs software, which calibrated for hospital automation, and the mean MI values were measured and calculated in the computer environment.

**Results:** When compared with gender groups, the average MI values in total gender and intra group gender are higher in females than males. Also t test and correlation calculations supported this. The average values of MI in age groups are gradually decreasing for both sexes with age. Especially between 25–34 age group and 55–64 age group with 25–34 age group and 65+ age group was found significant difference. No statistic significant difference was found between the other age groups.

**Conclusion:** As a result, the normal MI values tend to decrease as age progresses, especially after the age of 40 in women after menopause and similarly in men after andropause due to deficiency of mineral which occurred in bones. We conclude that this decline may be linked with osteoporosis.

**Keywords:** metacarpal index, radiography, geriatrics

**P-66**

**The course of infraorbital canal in maxillary sinus**

Bahşi İ<sup>1</sup>, Orhan M<sup>1</sup>, Kervancıoğlu P<sup>1</sup>, Yalçın ED<sup>2</sup>

<sup>1</sup>Department of Anatomy, Faculty of Medicine, Gaziantep University, Gaziantep, Turkey; <sup>2</sup>Department of Dentomaxillofacial Radiology, Faculty of Dentistry, Gaziantep University, Gaziantep, Turkey

**Objective:** The aim of this study is to determine the course of infraorbital canal in maxillary sinus.

**Methods:** Permission was obtained from the Clinical Research Ethics Committee at Gaziantep University prior to the study (Decision no. 2016/72). Images of 150 cases (75 females and 75 males) between the ages of 18–65 were retrospectively reviewed by the Planmeca Romexis (Planmeca, Helsinki, Finland) software by randomly selecting the images of the individuals who had no pathology in the CBCT and who were admitted to the Dentistry

Faculty at Gaziantep University for any reason. In these images, the morphology of infraorbital canal was examined.

**Results:** A total of 150 infraorbital canals were evaluated and 21 (7%) of them were observed as in the maxillary sinus, of which 6 were bilateral and 9 were unilateral (5 on the left and 4 on the right).

**Conclusion:** In the literature, a few publications reported case reports of the course of infraorbital canal in the maxillary sinus. In three different publications, it was reported that this variation was 12.5%, 12.3% and 10.8%, respectively. In our study, this variation was found to be 7%. Variations, in which the infraorbital canal is in the maxillary sinus, should be considered in surgical procedures. In the presence of cases in which the infraorbital canal is in the maxillary sinus, as the orbit moves away from its floor, damage to the infraorbital vein nerve pouch may be less visible in orbital floor fractures.

**Keywords:** CBCT, maxillary sinus, infraorbital canal

**P-67**

**Evaluation of pterygopalatine fossa and greater palatine canal by using cone-beam computed tomography (CBCT)**

Bahşi İ<sup>1</sup>, Orhan M<sup>1</sup>, Kervancıoğlu P<sup>1</sup>, Yalçın ED<sup>2</sup>

<sup>1</sup>Department of Anatomy, Faculty of Medicine, Gaziantep University, Gaziantep, Turkey; <sup>2</sup>Department of Dentomaxillofacial Radiology, Faculty of Dentistry, Gaziantep University, Gaziantep, Turkey

**Objective:** The aim of this study is to evaluate the morphology of pterygopalatine fossa, greater palatine canal, and lesser palatine canal.

**Methods:** Permission was obtained from the Ethics Committee prior to the study (Decision no. 2016/72). Images of 150 cases were retrospectively reviewed by the Planmeca Romexis software by randomly selecting the images of the individuals who had no pathology in the CBCT and who were admitted to the Dentistry Faculty at Gaziantep University for any reason.

**Results:** It was found that the distance between the greater palatine foramen and the pterygoid canal was (28.20±3.36 mm), the distance between the pterygoid canal and the inferior orbital fissure (9.00±2.62 mm), the distance between the beginning of lesser palatine canal and the greater palatine foramen (13.28±2.97 mm), the angle between the greater palatine canal axis and the pterygopalatine fossa axis (150.12±9.27°), the angle between the horizontal plane and the greater palatine canal axis (65.55±6.45°), and the angle between the sagittal plane and the greater palatine canal axis (15.32±7.00°). In the comparison of these parameters by sex, there was a statistically significant difference in the distance between the greater palatine foramen and the pterygoid canal (p=0.001), the distance between the pterygoid canal and the inferior orbital fissure (p=0.001), the distance between the lesser palatine canal origin and the greater palatine foramen (p=0.001).



**Conclusion:** The findings are thought to contribute to the literature for the maxillary anesthesia, especially in the pterygopalatine fossa via the greater palatine canal, and reduce the complication risk.

**Keywords:** CBCT, pterygopalatine fossa, greater palatine canal, lesser palatine canal

#### P-68

##### Researching of the preventive effectiveness of boric acid and fish oil from menhaden (omega-3) in a model of heart attack changes in ECG rats

Karimkhani H<sup>1</sup>, Özkoç M<sup>2</sup>, Shojaolsadati P<sup>3</sup>, Uzun K<sup>4</sup>, Burukoğlu D<sup>5</sup>, Kanbak G<sup>2</sup>

<sup>1</sup>Department of Biochemistry, School of Medicine, Istanbul Medipol University, Istanbul, Turkey; <sup>2</sup>Department of Biochemistry, School of Medicine, Eskişehir Osmangazi University, Eskişehir, Turkey; <sup>3</sup>Department of Anatomy, School of Medicine, Istanbul Medipol University, Istanbul, Turkey; <sup>4</sup>Department of Physiology, School of Medicine, Eskişehir Osmangazi University, Eskişehir, Turkey; <sup>5</sup>Department of Histology and Embryology, School of Medicine, Eskişehir Osmangazi University Eskişehir, Turkey

**Objective:** Ischemic heart disease, the leading cause of mortality and morbidity in the world, is often referred to as coronary artery disease, because coronary arteries often become narrowed or obstructed by atheromatous plaque. Cardiovascular diseases are main causes of death in developed and developing countries. The most common cardiovascular disease is myocardial infarction (MI). MI is irreversible myocardial cell damage and necrosis from the prolonged ischemia resulting from inadequate tissue perfusion.

**Methods:** Male Sprague-Dawley rats were used in our study. Rats Control, MI, MI+Boric acid, MI+Omega-3 and MI+Boric acid+Omega-3 groups were divided into 5 groups consisting of 10 rats. For the control group, 2 ml of saline; 100 mg/kg/day for boric acid groups and 800 mg/kg/day for Omega-3 groups were given by gavage for 28 days. Isoproterenol-HCl (ISO) was administered subcutaneously at a dose of 200 mg/kg twice daily for 24 hours on the last two days (26 and 27 days) of the application of Boric acid and/or Omega-3 for the MI model. Twelve hours after the second ISO dose, the rats were anesthetized. In the anesthetized rats, ECG measurements were made using spontaneous respiration, computerized Biopar Brand MP100 Model Data Evaluation and Recording System, and D-II records were used.

**Results:** In the ECG, ST wave ( $p < 0.001$ ) and heart rate ( $p < 0.001$ ) were higher than MI group in the control group. When these results were compared with the MI group, results of MI+Boric acid, MI+Omega-3 and MI+Boric acid+Omega-3 groups were improved.

**Conclusion:** Omega-3, Boric acid, and their combined application resulted in significantly reduced cellular damage of MI.

**Keywords:** boric acid, ECG, heart attack, Omega-3

#### P-69

##### Bilateral double renal artery: case report

Karacan K<sup>1</sup>, Karacan A<sup>2</sup>, Akcaalan M<sup>1</sup>, Erdoğan M<sup>1</sup>

<sup>1</sup>Department of Anatomy, Sakarya University, Sakarya, Turkey;

<sup>2</sup>Department of Radiology, Sakarya University, Sakarya, Turkey

**Objective:** Both renal arteries collect 20% of the cardiac output to support organs that consists of less than 1% of total body weight. Renal arteries branch laterally from the aorta below the origin of the superior mesenteric artery (SMA). While the right renal artery is longer and often higher; the left renal artery is a little lower. 70% of the cases include a single renal artery to each kidney. Renal artery variations are the quite common in artery variations. There is a strong relationship between variations of renal arteries and embryological improvement of vessels.

**Methods:** A 48 years old woman who complained of chest pain and applied to the Sakarya Training and Research Hospital was scanned by thoraco-abdominal CT angiography.

**Results:** Bilateral double renal artery was determined in the patient. Right superior renal artery was below 10 mm of SMA and was around 2.05 mm. Right inferior renal artery was below 33 mm of SMA and was around 6.8 mm. Left superior renal artery was below 12 mm of SMA and was around 2.82 mm, left inferior renal artery was below 22 mm of SMA and around 6.11 mm.

**Conclusion:** Variations of renal arteries are quite essential in diagnose and treatment of renal trauma or transplantation, renovascular hypertension, renal artery embolization, angioplasty or vascular reconstruction for congenital and acquired lesions, surgery for abdominal aortic aneurysm and conservative or radical renal surgery. Awareness of the variations of renal arteries improves sensibility and reduce morbidity connected to surgical and interventional processes.

**Keywords:** renal artery, variation, thoraco-abdominal CT angiography

#### P-70

##### Evaluation of the effects of acute copper-oxide nanoparticle (CuO-NP) consumption in the rat kidney: stereologic and biochemical assessment

Shojaolsadati P<sup>1</sup>, Karimkhani H<sup>2</sup>, Yücel F<sup>3</sup>, Şakul U<sup>1</sup>

<sup>1</sup>Department of Anatomy, Faculty of Medicine, Istanbul Medipol University, Istanbul, Turkey; <sup>2</sup>Department of Biochemistry, Faculty of Medicine, Istanbul Medipol University, Istanbul, Turkey; <sup>3</sup>Department of Anatomy, Faculty of Medicine, Eskişehir Osmangazi University, Eskişehir, Turkey

**Objective:** Kidney diseases are a common cause of death nowadays. At the same time, consumption of the copper oxide nanoparticle (CuO-NP) causes damage kidney. In this study CuO-NP, the cell damage that may occur in the rat kidney after consumption and the mechanism of this damage will be investigated.

**Methods:** CuO-NP are used in many different sectors and for different targets. It has been determined that CuO-NP are distributed in the organs and tissues of animals and cause certain structural changes. According to the results of recent studies, the kidney is one of the target organs for the CuO-NP entering the body from any pathway. Again according to some studies findings, CuO-NP showed toxic response in renal tissue. However, the underlying mechanism of apoptosis in kidney due to exposure to CuO-NP is unclear.

**Results:** In this study, saline was administered to the control group and CuO-NP was administered to the experimental group once daily for 5 days. Animals were decapitated 24 hours after the last gavage. Kidney tissues were stained with H&E and histopathologically examined and compared with light microscopy. The levels of MDA, CAT, NO, TNF- $\alpha$  and IL-6 levels were measured. In the experiment, 40 6–8 week old Wistar Albino male rats were divided into 2 groups. 1. Control (n=20), 2. CuO-NP (200 mg/kg) (n=20).

**Conclusion:** As a result of the experiments carried out in this study, we aimed to explain the morphological and histopathological changes of the cells after CuO-NP exposure and the underlying mechanism of these changes.

**Keywords:** copper oxide nanoparticle (CuO-NP), kidney, free radical, stereology

#### P-71

##### Comparison of the cun values of Turkish population with the other populations

Bozer C, Erpek S

Department of Anatomy, Faculty of Medicine, Trakya University, Edirne, Turkey

**Objective:** Since early populations, humans needed a standard measurement system for the body dimensions. In China, jade rulers were used for the standardization. The rulers were made of 23 mm intervals. The 23 mm interval equals approximately to the width of the interphalangeal joint of the thumb (art. interphalangea pollicis). This unit is called “cun”.

**Methods:** Additionally, the width of the index and middle finger, measured at the level of the proximal interphalangeal joint of the index finger (1.5 cun), the width of the index, middle and ring finger, measured at the level of the proximal interphalangeal joint of the index finger (2 cun), the width of all four fingers, measured at the level of the proximal inter-phalangeal joint of the index finger (3 cun) were measured.

**Results:** In this study, the consistency of the cun measurement system to the young Turkish adults was investigated. 110 subjects (55 male, 55 female) were included in this study.

**Conclusion:** The mean value of 1 cun was measured 19.32 mm in this study. The mean value of 1 cun was reported as 19.48 mm by Chao et al., 19.70 mm by Gu et al., 17.5 mm by Coyle et al. and 22.9 mm by Park et al. Furthermore, Coyle et al. have measured the 1.5 and 3 cun values of the subjects. There was

no difference between the cun values of the right and left sides of the subjects.

**Keywords:** acupuncture, cun, measurement, comparison

#### P-72

##### What can the golden ratio tell us about face beauty?

Taşkınalp O, Yılmaz A

Department of Anatomy, Faculty of Medicine, Trakya University, Edirne, Turkey

You could see the golden ratio in many kinds of art like music, painting, architecture and sculpture. The golden ratio is widely known in the art and is also well known in the profession of plastic surgery. The Golden Ratio appears in the human face, as demonstrated in a many studies. Stephen Marquardt focuses on human facial beauty in his work. Dr. Marquardt has conducted surveys to define the differences in beauty between cultures. He also analyzed the human face from ancient times to the modern day. The definition of facial beauty is based on dynamic assumptions. It should not be forgotten that it varies depending on various factors. Many factors such as nose, eyes, eyebrows, cheeks, chin and lips need to be evaluated to describe facial beauty. All these studies show us which the golden ratio how and important marker on beauty. And it's conspicuous that the golden ratio will be a spotlight with a gradual increase.

**Keywords:** golden ratio, face, nose

#### P-73

##### Pancreas redundancy: a case report

Şenol D<sup>1</sup>, Çevirgen F<sup>1</sup>, Karaca L<sup>2</sup>, Canbolat M<sup>1</sup>, Özbağ D<sup>1</sup>

<sup>1</sup>Department of Anatomy, Faculty of Medicine, İnönü University, Malatya, Turkey; <sup>2</sup>Department of Radiology, Faculty of Medicine, İnönü University, Malatya, Turkey

**Objective:** Pancreas is secondarily retroperitoneal and it is along the posterior abdominal wall, in front of columna vertebralis at the level of L2 vertebrae. It is soft, yellowish-slightly red in color, 12–15 cm long, 3 cm wide, 1–1.5 cm thick and 70–100 g. The purpose of this study is to present the presence of normal big pancreas.

**Case:** The case was identified in a 67-year-old male patient who came to İnönü University Turgut Özal Medical Center Urology Polyclinic in 2017 with a complaint of urinary burning and who was diagnosed with a primary diagnosis of benign prostatic hyperplasia. The patient's CT showed that the pancreas was bigger than the normal. Lobulations which were thought to be variational were seen in the tail part of the pancreas. The pancreas, which starts from the lateral wall of the abdomen forms a fold on the frontal part of the left kidney, extends to the left from the front of the left renal veins and ends by forming lobulations.

**Conclusion:** Pancreas has a great number of variations and anomalies. However, anomalies which are seen in clinic and which cause problems are rare. Ectopic pancreas, pancreatic agenesis, dorsal or ventral partial pancreatic agenesis, annular pancreas, pancreas divisum and ductal anomalies can be listed among congenital development anomalies of the pancreas. Defining the morphological/shape type and subtype variations of the body and tail of pancreas can prevent misinterpretations as pancreas tumor in tomographies.

**Keywords:** pancreas, variation, tomography

#### P-74

##### Absence of left portal vein: a case report

Çevirgen F<sup>1</sup>, Karaca L<sup>2</sup>, Şenol D<sup>1</sup>, Çuğlan S<sup>1</sup>, Köse E<sup>1</sup>, Özbağ D<sup>1</sup>

<sup>1</sup>Department of Anatomy, Faculty of Medicine, İnönü University, Malatya, Turkey; <sup>2</sup>Department of Radiology, Faculty of Medicine, İnönü University, Malatya, Turkey

**Objective:** Portal vein (PV) is responsible for the functional circulation of the liver. It collects the venous blood of the part of digestive tract below diaphragm, pancreas, spleen, extrahepatic biliary system, peritoneum and abdominal lymph nodes to the liver as 1–1.2 liters per minute. Anatomic variations of the portal vein can be seen in 20% of the cases. The purpose of this study is to have information about the absence of left portal vein as a consequence of congenital agenesis, which is a rare variation.

**Case:** The case was identified in a 28-year-old female patient who referred to İnönü University Turgut Özal Medical Center Urology Polyclinic with a complaint of abdominal pain. The patient's computerized tomography showed that she did not have left portal vein (congenital agenesis). The left lobe of the liver was found to have hypoplastic appearance.

**Conclusion:** It is very important especially in living donor liver transplantation (LDLT) to know the vascular structure of the liver's left lobe well. In adult LDLT, right lobe (RL) is preferred since it provides greater graft volume. In variations seen mostly in the right PV, the absence of the left portal vein generally results in portal trifurcation. However, absence of the left portal vein as a consequence of congenital agenesis is a very rare. PV variations cause problems in operations and especially since absence of PV as a result of congenital agenesis puts the life of the donor in danger, it is not preferred in LDLT.

**Keywords:** left portal vein, congenital agenesis, liver transplantation

#### P-75

##### Is there any effect of the seasonal changes on pituitary gland morphometry?

Turamanlar O<sup>1</sup>, Horata E<sup>2</sup>, Özer Gökaslan Ç<sup>3</sup>, Ertekin T<sup>1</sup>

<sup>1</sup>Department of Anatomy, Faculty of Medicine, Afyon Kocatepe University, Afyonkarahisar, Turkey; <sup>2</sup>Ataturk Health Services Vocational School, Afyon Kocatepe University, Afyonkarahisar, Turkey; <sup>3</sup>Department of Radiology, Faculty of Medicine, Afyon Kocatepe University, Afyonkarahisar, Turkey

**Objective:** Adaptation to seasonal changes is important for survival in all living things. In the literature, the articles examining the effects of seasonal changes on the pituitary gland is very few. However, it is known that the pituitary gland volume may vary in neuroendocrine and psychiatric diseases. In our study, we aimed to determine whether there was a change in the pituitary gland volume on MR images taken during the summer and winter seasons.

**Methods:** Afyon Kocatepe University Clinical Research Ethics Board confirmed our study dated 07.07.2017 and numbered 2017/7-199. In the same year, pituitary volume measurements were made on images of 29 male subjects aged between 18 and 65 years who had brain MR scans for any reason during the summer and winter.

**Results:** We determined that the increase in the pituitary gland volumes in the summer months was statistically significant compared to the winter. There was statistically insignificant increasing in pituitary gland height and transverse diameter in summer months.

**Conclusion:** The effects of the seasons on hormones and hence on glands are known. There are studies in the literature that examine the effects of different clinical situations on hormonal glands. However, we could not reach enough studies to examine the effects of the seasonal return on the pituitary gland morphometry. The results of our study showed that the pituitary gland volume increases in summer. We believe that this information will lead to clinicians working in the field of endocrinology and pituitary.

**Keywords:** pituitary, seasonal change, morphometry

#### P-76

##### An unusual variation of brachial plexus

Erdoğan K, Özen KE, Yarar B, Çizmeci G, Ay Keselik G, Malas MA

Department of Anatomy, Faculty of Medicine, Izmir Katip Çelebi University, Izmir, Turkey

**Objective:** Knowledge of brachial plexus anatomy is quite important for numerous invasive treatments such as surgical operations requiring deep neck dissection and regional anesthesia applications. In this case report, it is aimed to demonstrate an unusual brachial plexus variation.

**Methods:** During routine dissection in our laboratory we observed variations in the formation of trunks and cords on the right brachial plexus of embalmed 61 years old male cadaver.

**Results:** On the right brachial plexus of the cadaver Upper, middle and lower trunks were formed by ventral rami of C4-C5, C6-C7 and C8-T1, respectively. Posterior cord was formed by union of posterior division of upper and middle trunks. Lower trunk continued as medial cord as a whole by the reason that is not divided into anterior and posterior divisions. Furthermore medial cord didn't give a branch as medial root of the median nerve also ulnar and median nerves were arising together.

**Conclusion:** The knowledge of anatomy and variations of brachial plexus which is vulnerable in traumas and surgical procedures, would be beneficial to physicians during diagnostic and treatment steps.

**Keywords:** brachial plexus, fasciculus variation, truncus variation

#### P-77

##### **A case report of the accessory tendon of the extensor carpi radialis longus muscle**

Erdoğan K, Özen KE, Yazar B, Çizmeci G, Ay Keselik G, Malas MA

*Department of Anatomy, Faculty of Medicine, Izmir Katip Çelebi University, Izmir, Turkey*

**Objective:** Musculus Extensor Carpi Radialis Longus (MECRL) originates from the crista supracondylaris lateralis, epicondylus lateralis and septum intermusculare brachii laterale on the humerus and inserts on the proximal part of the dorsal side of the 2nd metacarpal bone. In this study, we detected an accessory tendon of the muscle. We aimed to raise awareness of the Plastic and Reconstructive and Orthopedic surgeons about this accessory tendon of Musculus Extensor Carpi Radialis Longus which can be used in tendon transfer or graft.

**Methods:** During the routine dissection a unilateral accessory tendon of MECRL was observed. Muscle and its tendons were dissected and separated from other muscles and the end of tendon was detected.

**Results:** The accessory tendon of the MECRL was observed on the left forearm a 65 years old male cadaver. The belly of muscle inserts on the proximal third of forearm and two separate tendons started from here. The accessory tendon was thinner than the main tendon and it lied over the main tendon. These two tendons passed deep into the abductor pollicis longus muscle, extensor pollicis brevis muscle and extensor retinaculum. These tendons fused just before the insertion and it attached to the proximally of the dorsal side of the second metacarpal bone.

**Conclusion:** We believe that awareness of the accessory tendon of the ECRL muscle will be beneficial in terms of graft or tendon transfer performed during plastic, reconstructive and orthopedic surgery.

**Keywords:** extensor carpi radialis longus muscle, graft, tendon transfer

#### P-78

##### **Morphometric comparison of different caput radii types**

Şenol D, Çavuş E, Çevirgen F, Arpacı F, Özbağ D

*Department of Anatomy, Faculty of Medicine, İnönü University, Malatya, Turkey*

**Objective:** Knowing the shape and size of the radius head is necessary for the construction of radial head prosthesis. Radial

head and neck fractures form 1.7–5.4% of all radius fractures. Instable and displaced radial head fractures are almost always seen with a complex injury. The purpose of this study is to find out how proximal and distal morphometric measurements differ in different caput radii (CR) types.

**Methods:** 27 dry radial bones in Inonu University Department of Anatomy were included in the study. After the types of radius were found, morphometric measurements were made with caliper. The parameters measured were determined as the length of radius, the height, transverse diameter and anterior-posterior diameter of CR, tuberositas radii transverse diameter and height, length and transverse diameter of incisura ulnaris.

**Results:** The results of CR typing showed that 13 bones had irregular, 8 bones had oval and 7 bones had round type. Average radius length was calculated as 207.99±21.97 mm; the height of CR was 9.45±1.68 mm, transverse diameter was 19.94±3.15 mm, anterior-posterior diameter was 20.20±3.09 mm; transverse diameter of tuberositas radii was 12.07±1.3 mm and height was 25.36±2.78 mm; the height of incisura ulnaris was 13.86±1.56 mm and transverse diameter was 5.27±0.8 mm. According to the results of Kruskal Wallis analysis, no statistically significant difference was found between CR types ( $p>0.05$ ).

**Conclusion:** We believe that this study will be useful for orthopedic surgery in the making of proximal and distal radius prosthesis and it will provide a resource for future studies.

**Keywords:** caput radii, dry bone, morphometry

#### P-79

##### **Determination of pterion types in human skull and the assessment of morphometric measurements**

Bozdağ M<sup>1</sup>, Altunsoy S<sup>1</sup>, GÜldoğan B<sup>1</sup>, Tokmak KM<sup>1</sup>, Albulut NB<sup>1</sup>, Özdemir Ş<sup>1</sup>, Akpınar B<sup>1</sup>, Bağlam MB<sup>1</sup>, Özden F<sup>1</sup>, Erdem A<sup>1</sup>, Şenol D<sup>2</sup>, Özbağ D<sup>2</sup>

*<sup>1</sup>Faculty of Medicine, İnönü University, Malatya, Turkey; <sup>2</sup>Department of Anatomy, Faculty of Medicine, İnönü University, Malatya, Turkey*

**Objective:** Pterion is defined as the region where the frontal, parietal, temporal and sphenoid join together. In addition to pterion being used in removing some tumors in brain surgery, pterional approach is also used in interventions to a.meningea media and a.carotis interna and in various diseases such as traumatic optical neuropathy. The purpose of the study is to find out pterion types and to show the distance of pterion to some anatomical points.

**Methods:** 20 skulls in the anatomy laboratory of İnönü University were examined for bilateral pterion typing and their measurements were made. Measurement points were as follows: the distance between the center of pterion to the frontal side of sutura frontozygomata, to the upper side of sutura temporozygomata, to arcus zygomaticus, to the base of fossa mandibularis, to spina supraneaica, to asterion, to the lowest side of mastoid process, to inion point, to glabella point.

**Results:** 3 different pterion types were obtained from 40 pterions. These were Epipteretic (in 9 skulls), Frontoparietal (in 8 skulls) and Sphenoparietal (in 23 skulls). According to the results of Kruskal Wallis Analysis, no statistically significant difference was found between the measurements of different pterion types ( $p>0.05$ ).

**Conclusion:** We believe that the data found by us on pterion typing and localization should be taken into consideration in surgical procedures. We are of the opinion that this study will be a resource in the field of anatomy, anthropology, forensic science, neurosurgery and maxillofacial surgery.

**Keywords:** pterion, morphometry, epipteretic, frontoparietal, sphenoparietal

## P-80

### Estimation of the treatment type for the patients with chronic rotator cuff syndrome by radial-basis artificial neural networks

Köse E<sup>1</sup>, Çiftçi R<sup>1</sup>, Çolak C<sup>2</sup>, Çuğlan S<sup>1</sup>, Özbağ D<sup>1</sup>

<sup>1</sup>Department of Anatomy, Faculty of Medicine, İnönü University, Malatya, Turkey; <sup>2</sup>Department of Biostatistics and Medical Informatics, Faculty of Medicine, İnönü University, Malatya, Turkey

**Objective:** In this study, it was aimed to estimate the treatment type (routine physiotherapy methods and additionally kinesio-taping banding therapy) for the patients with chronic rotator cuff syndrome by radial basis function artificial neural networks (RBFANN).

**Methods:** This study was performed over 92 patients with chronic rotator cuff syndrome. The patients were randomly divided into two groups: the first group received routine physiotherapeutic techniques (TENS, US, hotpack) five days a week for three consecutive weeks whereas the second group received kinesio-taping technique twice a week in addition to routine physiotherapeutic techniques five days a week for three consecutive weeks. Every patient was evaluated by DASH scale, SF-36 scale, VAS and BECK depression inventory before and after treatment. RBFANN was used to estimate the treatment type for the patients with chronic rotator cuff syndrome.

**Results:** The sum of squared error values of RBFANN was calculated as 7.691 for the training data set and 2.391 for the testing data set. The area under the ROC curve was obtained as 0.936. The most important factors associated with treatment type were found as; VAS AT, DASH BT and application time.

**Conclusion:** RBFANN estimated successfully the treatment type for the patients with chronic rotator cuff syndrome, and the related factors were arranged according to the importance levels. This study was supported by İnönü University Scientific Research Projects Unit

**Keywords:** Kinesio-taping treatment, chronic rotator cuff syndrome, radial basis function artificial neural network

## P-81

### Morphological caecum types in human fetal cadavers

Aydın Kabakçı AD, Akın D, Büyükmumcu M, Çiçekcibaşı AE, Yılmaz MT

Department of Anatomy, Meram Medicine Faculty, Necmettin Erbakan University, Konya, Turkey

**Objective:** Caecum is the large blind sac at proximal end of the large intestine. Shape changes of caecum occur with birth. Having knowledge about variations in caecum shape is important for surgeons during surgeries. The aim of this study is to investigate the growing of the caecum in human fetuses and classify shapes of the caecum.

**Methods:** 24 male and 36 female externally normal-looking fetal cadavers were studied between 13–40 weeks. The length and width of caecum and ileocaecal junction height was measured in all fetuses. The caecum shapes were subdivided into 8 types. And also the opening aspect of ileum into caecum was classified into 7 types.

**Results:** Most common shape of caecum was found conical type (type 1–50%). And other types were determined that right slightly enlarged type (type 3–18.3%), left slightly enlarged type (type 2–13.3%), absent type a (type 0–6.7%), equal sized type (type 4–3.3%), exaggerated type to the left (type 6–1.7%), absent type b (type 7–1.7%), exaggerated type to the right (type 8–1.7%) respectively. It was noticed that ileum was entered into the caecum from its medial aspect ( $n=39$ , 65%). This study showed that the comparison of ileocaecal junction height between male and female fetuses was statistically significant ( $p$  value=0.035).

**Conclusion:** In accordance with the development of caecum, we found that most common shape of caecum was conical type in 2nd trimesters. We believed that these variations will be helpful for performing various abdominal surgeries.

**Keywords:** caecum, variation, morphology, fetal cadaver

## P-82

### Anatomical characteristics of tuberculum pharyngeum and its gender-related change

Çeri NG<sup>1</sup>, Şahmelikoğlu AG<sup>1</sup>, Cantas F<sup>2</sup>

<sup>1</sup>Department of Anatomy, Faculty of Medicine, Adnan Menderes University, Aydın, Turkey; <sup>2</sup>Department of Biostatistics, Faculty of Medicine, Adnan Menderes University, Aydın, Turkey

**Objective:** Craniovertebral surgical procedures and transcondylar approach (TCA) have recently gained importance and provide a shorter and direct route to access ventral lesions in the brainstem. Tuberculum pharyngeum is an important structure located at the center of the anatomical formations in cranium.

**Methods:** This study was performed in 64 skulls (22 females, 42 males). We measured the distances between the width of tuberculum pharyngeum in pars basilaris (Pars\_Basilaris) and

the distances between tuberculum pharyngeum and opisthion (Tphr\_OP), basion (Tphr\_B), protuberentia occipitalis externa (Tphr\_POE), condylus occipitalis (Tphr\_CO), canalis caroticus (Tphr\_CC), processus styloideus (Tphr\_PS), foramen stylomastoideum (Tphr\_FSM), processus mastioideus (Tphr\_PM), ala vomeris (Tphr\_Ala), crista chonalis vomeris (Tphr\_Ala). In addition to whether there is a difference between male and female, whether double-sided measurements, right or left, were checked for symmetry characteristics.

**Results:** The distance between Tphr\_OP, Tphr\_CO, Tphr\_POE, Tphr\_PS, Tphr\_FSM and Tphr\_PM was statistically significant in males ( $p < 0.05$ ). There was no significant difference in genders between Tphr\_B, Tphr\_Ala, Tphr\_Ala and width of pars basilaris in relation to tuberculum pharyngeum ( $p > 0.05$ ). In males and females, Tphr\_Ala, Tphr\_CO anterior part, Tphr\_CC, Tphr\_PS, Tphr\_PM and Tphr\_FSM exhibits symmetrical features whereas tuberculum pharyngeum and condylus occipitalis shows symmetrical features in the middle and posterior distances in males. Measurements of tuberculum pharyngeum and condylus occipitalis mid and posterior distance were seen as acidimetric in women.

**Conclusion:** The results we have found may help guide surgeons during craniocervical surgical procedures.

**Keywords:** tuberculum pharyngeum, condylus occipitalis, canalis caroticus

### P-83

#### Examination of inclinations in spine at childhood and adolescence stage

Tokpınar A<sup>1</sup>, Ülger H<sup>2</sup>, Yılmaz S<sup>3</sup>, Acer N<sup>2</sup>, Ertekin T<sup>4</sup>, Görkem SB<sup>5</sup>

<sup>1</sup>Kapadokya University, Nevşehir; <sup>2</sup>Department of Anatomy, Faculty of Medicine, Erciyes University, Kayseri, Turkey; <sup>3</sup>Department of Anatomy, Faculty of Medicine, Bozok University, Yozgat, Turkey; <sup>4</sup>Department of Anatomy, Faculty of Medicine, Afyon Kocatepe University, Afyonkarahisar, Turkey; <sup>5</sup>Department of Radiology, Faculty of Medicine, Erciyes University, Kayseri, Turkey

**Objective:** Spine is not a straight column. It figures a convexity towards the front of the spine (lordosis) at cervical and lumbar areas in adults. It also figures a convexity towards the back of the spine (kyphosis) at thoracic and sacral spine area. Known of the sagittal plane curvatures of the spine developed during childhood and adolescence has been investigated in order to contribute to the clinic and other work done in this area.

**Methods:** In this study, lateral radiographs of 731 children between 1-16 years old were examined and their cervical lordosis, thoracic kyphosis and lumbar lordosis angles were measured with Cobb method using ImageJ program for every age group.

**Results:** In this study calculated cervical lordosis angles in 1-16 years old children were found  $20.51^\circ \pm 6.11$ . It has been observed that cervical angle value decrease with age. The mean thoracic kyphosis angle measurement was found  $28.71^\circ \pm 6.99$ .

Lumbar lordosis angle was measured  $28.08^\circ \pm 7.39$ . Thoracic kyphosis and lumbar lordosis angle values increase with age.

**Conclusion:** When we compare our study results with literature values, cervical lordosis values were similar but lumbar lordosis values were lower. In a result, we think that knowing sagittal plane inclinations developing in childhood and adolescence stages will contribute determination of pathologies earlier. We also hope that it will contribute clinical stages and other studies in this field.

**Keywords:** spine, radiography, kyphosis, lordosis

### P-84

#### Bronchus segmentalis basalis anteromedialis?

Bayko S, Yarkan İS, Kutoğlu T

Department of Anatomy, Faculty of Medicine, Istanbul Medeniyet University, Istanbul, Turkey

The airways are followed by anatomical structures called lobar bronchus, segmental bronchus, lobular bronchiole, terminal bronchiole, respiratory bronchiole, alveolar duct, alveolar sac and pulmonary alveolus after principal bronchus and these structures show a certain distribution in the lung lobes. The right (2 lobes) and left (3 lobes) lungs are anatomically dissimilar, and lung segments distributed within the lobes are particularly variable for the upper segments, while lung segments distributed within the inferior lobe are similar in terms of Anatomy Terminology. However, when comparing Turkish and foreign anatomy textbooks, medial basal segmental bronchus (s7) and anterior basal segmental bronchus (s8) belonging to inferior lobe were described as separate structures in Turkish books (10%); in foreign books it is said that these structures are mostly together. Since the plastic anatomy models used in the anatomy training are also foreign origin and the s7 and s8 are shown together, it is possible that the medical students reading the Turkish textbooks and having anatomy training in Turkey are confused when they see the plastic anatomy models and foreign books. Furthermore, when the studies were examined, it was seen that both segments were mentioned together and separately. In conclusion, because medial basal segmental bronchus (s7) and anterior basal segmental bronchus (s8) mostly appear as a single structure, we suggest the name of “bronchus segmentalis basalis anteromedialis” for this structure.

**Keywords:** medial basal segmental bronchus, lungs, anatomy

### P-85

#### Two different “molar”s

Yarkan İS, Bayko S, Kutoğlu T

Department of Anatomy, Faculty of Medicine, Istanbul Medeniyet University, Istanbul, Turkey

We consider during Anatomy education there might be a situation that cause misunderstanding in tooth identification. In

'Terminologia Anatomica' (TA) during identification for 'süt dişleri' (Turkish-T); 'dentes decidui (Latin -L-), primary dentition (English -E-), deciduous teeth-E-' and for 'daimi dişler-T-'; 'dentes permanentes-L-, secondary dentition-E-, permanent teeth-E-' terms are used. In English textbooks primary/deciduous molar-E-, secondary /permanent molar-E-'terms're used. In Turkish Dentistry textbooks 'süt azı dişi-T-, küçük azı dişi-T-, büyük azı dişi-T-' terms're used. In every half jaw there're 5 teeth; which makes a total of 20 deciduous teeth. During "mixed dentition" along with primary teeth also permanent teeth appear in mouth. So in every half jaw there're 3 molar teeth which makes a total of 24 teeth. The use of the term 'dens molaris' in Latin may cause confusion because it does not define the teeth in terms of the deciduous/permanent tooth. In addition, it is difficult for the students to understand the anatomical training of the permanent molar teeth-E- don't have deciduous tooth precursors and the fact that the permanent premolar teeth-E- (dens premolaris-L-) precursors are deciduous molar teeth-E-. As a term "dens molaris decidui" can be used in education as equal to deciduous molar tooth and also "dens molaris permanentes" as equal to permanent molar tooth. And also it should be emphasized "dens molaris decidui" is not the precursor of "dens molaris permanentes". Perhaps a completely different name should be set out to clarify that deciduous and permanent "molar" are not continuation of each other

**Keywords:** molar tooth, primary dentition, secondary dentition, deciduous molar

#### P-86

##### Comparison of the advantages and disadvantages of medical imaging techniques for the evaluation of anatomical structures

Gölpınar M, Akça Z, Özel M, Uzun A

Department of Anatomy, Faculty of Medicine, Ondokuz Mayıs University, Samsun, Turkey

**Objective:** Since the discovery of x-rays, many new imaging techniques have been developed over the last 50 years include radiography, ultrasonography, computed tomography and magnetic resonance imaging. Imaging techniques allow doctor and researchers to evaluate anatomical structures in human body. In the present study, we aimed to compare the primary advantages and disadvantages of radiography, ultrasound, computed tomography and magnetic resonance imaging for the evaluation of anatomical structures.

**Methods:** Primary advantages and disadvantages of four different imaging techniques (radiography, ultrasound, computed tomography and magnetic resonance imaging) for investigation of anatomical structures were evaluated and compared each other according to literature.

**Results:** Radiography can be useful a quick overview of skeletal structures. But the quality of the obtained images was poor. A major benefit of ultrasound is that it does not expose patients to ionizing radiation. However, it is not suitable to scan

intraabdominal and retroperitoneal organs due to severe artifacts. The computed tomography imaging quality of the skeletal system was good but it carries the serious risks of exposing the patient to ionizing radiation. Magnetic resonance imaging provides excellent anatomic detail of soft tissues.

**Conclusion:** Computed tomography and magnetic resonance imaging have a superior image quality and also allow the three-dimensional reconstruction of complex anatomical structures in comparison to ultrasound and radiography. The knowledge of advantages and disadvantages of each imaging technique can help researchers for choosing appropriate imaging technique for evaluation of anatomical structures.

**Keywords:** computed tomography, magnetic resonance imaging, radiography, ultrasound

#### P-87

##### The anatomic analysis of the orbita and the surrounding structures concerning endoscopic surgery using computed tomography scans

Açar C<sup>1</sup>, Büyükmumcu M<sup>1</sup>, Güler İ<sup>2</sup>

<sup>1</sup>Department of Anatomy, Meram Faculty of Medicine, Necmettin Erbakan University, Konya, Turkey; <sup>2</sup>Department of Radiology, Faculty of Medicine, Selçuk University, Konya, Turkey

**Objective:** Many orbital pathologies and fractures alter the orbital volume and wall area. We investigated the morphometry of the orbital cavity and intraorbital structures and their relationship with the variations of the lamina orbitalis (LO) concerning endoscopic approaches.

**Methods:** This retrospective study was approved by local Ethics Committee with a number 2016/539 and performed using 100 orbital CT images. These results were compared according to age, sex, and laterality by using SPSS 22.0 and differences were accepted significant if  $p < 0.05$ .

**Results:** The diameters of the rectus muscles and nervus opticus were significantly greater in men than women and the distances between intraorbital structures and LO were increased with age ( $p < 0.05$ ). We reported that the mean area of the orbital entrance, medial and floor wall were 12.46 cm<sup>2</sup>, 7.2 cm<sup>2</sup> and 6.89 cm<sup>2</sup>, respectively. The mean orbital cavity depth and volume were 46.3 mm and 19.29 cm<sup>3</sup>. The orbital width and height were measured as 39.2 mm and 35.9 mm. For medial wall the anterior and posterior LO heights and angles were found as 17.4 mm, 147.88° and 9.6 mm, 152.72°, respectively. All measurements except angles tended to increase with aging and greater in men ( $p < 0.05$ ) but, no statistically significant difference was observed with respect to lateralization. LO variations according to inferior nasal turbinate attachment were categorized as Type A, 80.5 % (161/200); Type B, 16 % (32/200); Type C, 3.5 % (7/200).

**Conclusion:** These results can allow to diagnose the orbital pathologies and to choose the type of surgical approach.

**Keywords:** endoscopic approach, lamina orbitalis, morphometry, orbital wall area

P-88

**Volume of sella turcica in healthy children aged 10–18 years**

Uçar İ<sup>1</sup>, Değermenci M<sup>2</sup>, Ertekin T<sup>3</sup>, Yılmaz S<sup>4</sup>, Unur E<sup>2</sup>, Uzun GB<sup>5</sup>

<sup>1</sup>Department of Physical Therapy and Rehabilitation, Ahi Evran University, Kırşehir, Turkey; <sup>2</sup>Department of Anatomy, Faculty of Medicine, Erciyes University, Kayseri, Turkey; <sup>3</sup>Department of Anatomy, Faculty of Medicine, Afyon Kocatepe University, Afyon, Turkey; <sup>4</sup>Department of Anatomy, Faculty of Medicine, Bozok University, Yozgat, Turkey; <sup>5</sup>Department of First Aid and Emergency, Cappadocia Vocational College, Nevşehir, Turkey

**Objective:** Sella turcica (ST) is a name given to an anatomical structure which is located in the fossa cranii media and containing the pituitary gland. The development and changes in dimensions of this important structure are associated with different anomalies and syndromes in literature. Therefore, knowing the normal development of ST and its dimensions can play an important role in early diagnosis of some diseases. The purpose of this study was to measure sellaturcica's volume in 10–18 years of healthy children by using Cavalieri principle and to serve as a reference for further studies.

**Methods:** This study was performed retrospectively on sagittal scan computer to mography images taken from 180 individuals (89 male, 91 female) aged between 10–18 age group who had been admitted to Erciyes University Medical Faculty. ST volumes were measured by using Cavalieri method on received images.

**Results:** The ST volume average was measured as 2.77 mm<sup>3</sup> in the 10 age while it was 3.03 mm<sup>3</sup> in the 18 age group. Volumes of both males and females demonstrates a clear rise in ST on an age related basis. But the data we have obtained showed that there was no significant difference between the ST volumes of males and females (p>0.05).

**Conclusion:** These data could be used by clinicians as a reference in the assessment of a child presenting with cranial dysmorphology or pituitary gland anomalies.

**Keywords:** Sella Turcica's volume, stereology, computed tomography

P-89

**Topographic anatomical and morphometric properties of the pituitary gland**

Uzun ND<sup>1</sup>, Göçmen Mas N<sup>1</sup>, Durmaz MO<sup>2</sup>, Yonguç GN<sup>1</sup>, Kalemci O<sup>3</sup>, Karabekir HS<sup>3</sup>

<sup>1</sup>Department of Anatomy, Faculty of Medicine, Dokuz Eylül University, İzmir, Turkey; <sup>2</sup>Department of Neurosurgery, Bozyaka Training and Research Hospital, İzmir, Turkey; <sup>3</sup>Department of Neurosurgery, Faculty of Medicine, Dokuz Eylül University, İzmir, Turkey

**Objective:** Location and its nearby structures of pituitary gland are important in pituitary surgery. Knowing the detailed anatomy of these structures is fundamental in planning safe

surgical methods. In our study, we aimed to reveal the topographic, anatomic and morphometric properties of pituitary gland.

**Methods:** An ethics committee was approved for the anatomy PhD program 'Investigation of topographic anatomical and morphometric properties of the pituitary gland' at Dokuz Eylül University Medical Faculty on working on cadavers. Dissections and measurements were made on the six cadaver was done in Anatomy Laboratory of the Dokuz Eylül University. The measurements between the specified points were made with an electronic caliper capable of measuring the millimeter to a precision of 1/100. The weight of the pituitary gland was measured with a precision scale of 0.01 gr.

**Results:** Pituitary gland was dissected with appropriate anatomic dissection techniques. Sagittal and transverse diameters and weight of the pituitary gland; length and diameter of infundibulum; distance between infundibulum-optic canal, distance between tuberculum sellae- dorsum sellae, depth of hypophyseal fossa, sagittal and transverse lengths of hypophyseal fossa and were measured. Despite the presence of infundibulum in one of the six cadavers, pituitary gland was not detected and was evaluated as empty sella.

**Conclusion:** It is important to know the morphological and morphometric properties of hypophyseal fossa and pituitary gland for the safety of planned surgical operations in this region.

**Keywords:** pituitary gland, cadaver, infundibulum

P-90

**Localization and morphometric analysis of foramen infraorbitalis in dry skulls**

Alpa S<sup>1</sup>, Aydın Kabakçı AD<sup>2</sup>, Akın D<sup>2</sup>, Şeker M<sup>2</sup>

<sup>1</sup>Department of Anatomy, Faculty of Medicine, KTO Karatay University, Konya, Turkey; <sup>2</sup>Department of Anatomy, Meram Faculty of Medicine, Necmettin Erbakan University, Konya, Turkey

All parts of the human bone skeleton have different anthropometric data according to race-sex-age. When all these factors are taken into account, it's seen how important it's to obtain the normal values of the properties of different skeletal structures in the populations. This study, we performed morphometric measurements by examining for. infraorbitale and for. infraorbitalis accessorius. Measurements were taken on 84 dry skulls of unknown age and sex in the bone collection of KTO Karatay University and Necmettin Erbakan University, Medical Faculty, Departments of Anatomy. The measurement results are displayed on the right and left respectively; vertical diameter of for. infraorbitalis was 4.2±0.1 and 5.06±0.4 mm, transverse diameter of for. infraorbitalis is 3.4±0.1 and 3.5±0.1 mm, closest distance of for. infraorbitalis to apertura piriformis was 17.5±0.2 and 16.6±0.3 mm, distance of for. infraorbitalis to margo infraorbitalis is 6.7±0.2 and 7.9±0.2 mm, closest distance of for. infraorbitalis to arcus alveolaris superior was 28.7±0.6 and 29.9±0.6 mm,



closest distance of for. infraorbitalis to the sutura zygomatico-maxillaris was  $7.9 \pm 0.4$  and  $8.4 \pm 0.4$  mm. We were evaluated lateral, bilateral variations of for. infraorbitalis accesorius; Localization of for. infraorbitalis accesorius according to for. infraorbitalis. As a result of the statistical evaluation, it was observed that there was a significant difference between the closest distances of the right and left foramen infraorbital ( $p=0.001$ ). Knowledge of the position of the IOF is very useful to dentists as well as to head and neck surgeons for both diagnostic and clinical procedures. Therefore, we think that the data obtained in the study will contribute.

**Keywords:** infraorbitale foramen, accessory foramina, infraorbital nerve

### P-91

#### Footprint analysis of female young adults in Turkish population

Özel M<sup>1</sup>, Gölpinar M<sup>1</sup>, Uzun A<sup>1</sup>, Özdemir F<sup>2</sup>, Nahir M<sup>1</sup>, Altunsoy E<sup>1</sup>, Erkan İ<sup>3</sup>, Akça Z<sup>1</sup>

<sup>1</sup>Department of Anatomy, Faculty of Medicine, Ondokuz Mayıs University, Samsun, Turkey; <sup>2</sup>Department of Anatomy, Faculty of Medicine, Hitit University, Çorum, Turkey; <sup>3</sup>Department of Biostatistics and Medical Informatics, Faculty of Medicine, Ondokuz Mayıs University, Samsun, Turkey

**Objective:** The human foot is formed by numerous bones and joints. It is the part of lower limb below ankle on which we stand, walk and run. Besides, it plays critical role in gait. The aim of the present study is to obtain anthropometric data for evaluation of the morphometry of foot in female young adults.

**Methods:** A total of thirty-eight female young adults, with no known musculoskeletal impairments, whose ages range between 18 and 25 years were included in the study. Footprints were obtained from both the feet of each individuals after taking informed consent. Five length measurements i.e. T1, T2, T3, T4 and T5 were measured on both the footprints of each individuals using international standards. The lengths of footprint were measured using ImageJ software. The data were statistically analyzed using SPSS 21. (Ethics Committee number: 2016/244)

**Results:** The length of footprint range from  $19.29 \pm 9.7\%$  cm to  $22.87 \pm 11.5\%$  cm. In the right foot, the longest and shortest toe length was T2 and T5, respectively. In the left foot, the longest and shortest toe length was T1 and T5 respectively. There was significant difference between T3 lengths and average length of T1 and T5 in both right and left feet ( $p \leq 0.05$ ).

**Conclusion:** Obtained data in the present study will be helpful in planning and designing footwears for female young adults. It may also be used as a database for the quantitative description of foot morphology in female young population.

**Keywords:** female, footprints, morphometry, Turkish population, young adult

### P-92

#### Evaluation of sella turcica's morphological relation with fossa crania media

Uzun ND<sup>1</sup>, Yonguç GN<sup>1</sup>, Durmaz MO<sup>2</sup>, Karabekir HS<sup>3</sup>, Göçmen Mas N<sup>1</sup>

<sup>1</sup>Department of Anatomy, Faculty of Medicine, Dokuz Eylül University, Izmir, Turkey; <sup>2</sup>Department of Neurosurgery, Bozyaka Training and Research Hospital, Izmir, Turkey; <sup>3</sup>Department of Neurosurgery, Faculty of Medicine, Dokuz Eylül University, Izmir, Turkey

**Objective:** The morphometric and topographic evaluation of the skull base is very important for surgeons and especially for neurosurgeons. It is important to know the skull base morphometry in craniovertebral connection disorders, fossa crania media tumors, pituitary surgery and other important pathologies. In this study, we intend to identify reliable landmarks for the basis of cranium and to help standardize certain dimensions. To determine the correct location of the anatomy of ventral clivus and adjacent structures especially in transphenoid surgery, to contribute to the correct restriction of radiotherapy to patients which have fossa crania media tumors; Identification of possible cuts or damages during surgery, and the determination of the mean distances that will help to establish safe distances in the surgical approach.

**Methods:** Measurements were made on 25 cranium in the Anatomy Department of Dokuz Eylül University Medical School. Cranium's gender and ethnicity are not known but adult according to 3rd molar teeth. Measurements between the specified points were provided with an electronic caliper capable of measuring the millimeter to a precision of 1/100.

**Results:** Morphometric measurements of the bony structures which are between the fossa crania media and sella turcica (foramen ovale, foramen spinosum, foramen lacerum, etc.) were evaluated bilaterally.

**Conclusion:** While we believe that our morphometric and topographic evaluations will be guide to surgeons and radiologists, wider series and multicentre studies should be done.

**Keywords:** fossa crania media, Sella Turcica, morphometry

### P-93

#### What has changed in anatomical research from 80s to today?

Tekin B, Yüzbaşıoğlu N

Department of Human Anatomy, Faculty of Medicine, Istanbul Medipol University, Istanbul, Turkey

Although the importance of human anatomy was recognised by the doctors that lived in ancient times, as the dissection process was found beyond the pale, no rapid improvement was recorded and this situation continued the same way for a long time. We can easily say science of anatomy and other sciences go hand in hand with the technology. Despite making dramatic progress in learning and understanding of "Human Anatomy" which is one of the

most important branches in the development of medicine history and modern medicine, it still carries many deficiencies. In our study, inspection of various international anatomy journals from past to present and change in anatomical researches and revealing latest trends are aimed. In this article, studies published in five important anatomy journal of Science Citation Index (SCI) Expanded were scanned and study fields were classified. It is observed that before 2000, excluding Anatomical Record, in all journals, cadaver and morphometry studies were more commonly used methods than the other methods. After 2000, only in Clinical Anatomy and Surgical and Radiologic Anatomy journals while cadaver and morphology studies were detected at the highest level, in other studies this popularity gave its place to cellular and molecular level studies. It was detected that studies carried out using radiological methods, showed increase in all journals after 2000 when compared to the studies carried out before 2000. We believe that this classification plays a great role in understanding the direction of anatomy science and shaping the researchers.

**Keywords:** anatomy, scientific publications, SCI, web of science

#### P-94

##### **Cartilage of the femoral condyle surface area and volume calculation in osteoarthritis patients**

Ünalıms D<sup>1</sup>, Acer N<sup>1</sup>, Yılmaz S<sup>2</sup>, Doğan S<sup>3</sup>, Demir H<sup>4</sup>

<sup>1</sup>Department of Anatomy, Faculty of Medicine, Erciyes University, Kayseri, Turkey; <sup>2</sup>Department of Anatomy, Faculty of Medicine, Bozok University, Yozgat, Turkey; <sup>3</sup>Department of Radiology, Faculty of Medicine, Erciyes University, Kayseri, Turkey; <sup>4</sup>Department of Physiatry, Faculty of Medicine, Erciyes University, Kayseri, Turkey

**Objective:** Osteoarthritis especially load-bearing joints is seen as progressive, non-inflammatory, degenerative, and chronic disease. Knee joint cartilage in osteoarthritis patients there are several studies that measured the volume and surface area. However, in these studies different methods were used.

**Methods:** Our study of 12 patients with osteoarthritis of the knee and healthy individuals control group consists of 13 persons. In our study, magnetic resonance imaging (MRI) planimetry with ruler and quadratic method of stereological methods on the field of the femoral condyle cartilage volume and surface area measurements have been carried out.

**Results:** The total cartilage volume measurements of the control group was 14.5-14.6 cm<sup>3</sup>, in the patient group, 7-7.4 cm<sup>3</sup> was calculated. The surface area of cartilage in the control group average 9.7 cm<sup>2</sup>, 6.7 cm<sup>2</sup> in the patient group was calculated. Between groups statistical comparison of the values in the patient group decreased significantly compared with the control group, it was found that.

**Conclusion:** All these statistical results the survey results in comparison with the average value to be close to each other and demonstrate the validity of our method.

**Keywords:** knee osteoarthritis, stereology, MRG

#### P-95

##### **Evaluation of foramen mandibulae localization through three dimensional computed tomography in pediatric population**

Eryiğit Ö<sup>1</sup>, Turamanlar O<sup>1</sup>, Ünal M<sup>2</sup>, Kaçar E<sup>3</sup>

<sup>1</sup>Department of Anatomy, Faculty of Medicine, Afyon Kocatepe University, Afyonkarahisar, Turkey; <sup>2</sup>Department of Pedodontics, Faculty of Dentistry, Afyon Kocatepe University, Afyonkarahisar, Turkey; <sup>3</sup>Department of Radiology, Faculty of Medicine, Afyon Kocatepe University, Afyonkarahisar, Turkey

**Objective:** The purpose of our study is to evaluate the location of the foramen mandibulae according to age, gender and location (right / left) using three dimensional computerized tomography in living persons in the pediatric population.

**Methods:** This descriptive study included 102 patients with a mean age of 9.09 (±2.54) who underwent cranium CT for any reason in the Department of Radiology of Afyon Kocatepe University. Averages and standard deviations of the parameters examined were determined. Gender (female/male) and regional (right/left) comparisons of the obtained data were statistically evaluated and the age-related collaterals of the parameters were evaluated.

**Results:** D2 measurement (distance between the lower edge of the mandible and the incisal mandible) was 34.8±4.4 mm, with a mean of 13.4±2.2 mm between the FM and the incisal mandible transverse distance) was 9.1±1.8 mm, D4 measurement (mandibular anteroposterior diameter) was 24±2.4 mm. There was no significant difference between male-female and right-left comparisons (p>0.005). There was positive correlation between age D1, D2, D3, D4 measurements and D3/D4 and D2/D4 ratios. There was negative correlation between age and D1/D2 ratio.

**Conclusion:** Foramen mandibulae have certain age-related changes, and longitudinal anatomical studies are needed to confirm these differences. In mandibular anesthesia, where the foramen mandibulae localization is to be known accurately in the pediatric population, it is of great importance to reduce anesthetic complications.

**Keywords:** foramen mandibulae, pediatric population, three-dimensional computed tomography

#### P-96

##### **Commonly used anthropometric measurements and parameters of hand in sex determination: a literature review**

Özel M, Gölpinar M, Uzun A, Akça Z

Department of Anatomy, Faculty of Medicine, Ondokuz Mayıs University, Samsun, Turkey

**Objective:** Determination of sex is an important issue to establish the identity of individual for anthropologists. Despite of two biological sexes exist in human, sex determination from

skeletons is difficult. To solve this problem many studies have been done on different nations and populations from skeletal and fragmentary remains. Especially skull and pelvis commonly used skeleton parts by forensic anthropologists. Apart of this, sex estimation from extremities become increasingly more important where there is separated or amputated hands from the body. We reviewed the literature to determine the commonly used parameters and anthropometric measurements of hand in sex determination.

**Methods:** Pubmed database was used to search for relevant articles using to following words: sex determination, gender determination, sex estimation, sex assessment. We summarized commonly used anthropometric measurements and parameters of hand in sex determination according to the literature.

**Results:** Hand breadth, hand length, palm length, third finger length and index finger to ring finger ratio are most commonly used anthropometric measurements of hand. And there are indices derived from hand measurements. These indices are hand index (shape index=hand breadth\*100/ hand length), digit index (third finger length\*100/ hand length) and palm index (hand breadth\*100/palm length).

**Conclusion:** Anthropometric measurements of hand are cost-effective, non-invasive and simple tool in determination of sex. When DNA technology, skull and pelvis can't be used, anthropometric measurements can be used alternatively to determine the sex.

**Keywords:** anthropometric measurements, determination of sex, hand anthropometry

#### P-97

##### Overview of commonly used parameters in footprint analysis

Özel M, Gölpinar M, Uzun A, Akça Z

*Department of Anatomy, Faculty of Medicine, Ondokuz Mayıs University, Samsun, Turkey*

**Objective:** The human foot is the important region affected by anatomical variations in the entire human body. It has complex structure for shock absorption, supporting body weight and propelling the body forward in walking and running. Footwear plays an important role in protecting the foot. It may also cause foot deformity if it is not suitable for foot. Footprint parameters and footprint analysis is commonly used to determine the flatfoot, foot asymmetry and any abnormality. We reviewed the literature to determine the most commonly used footprint parameters in footprint analysis.

**Methods:** Pubmed database was used to search for relevant articles using to following words: footprint analysis, flatfoot, analyse of footprint. We summarized commonly used footprint measurements and parameters in analysis of footprint according to the literature.

**Results:** Clarke's angle (CA), Chippaux-Smirak index (CSI) and Staheli index (SI) are most commonly used footprint parameters in analysing of foot. CA is angle between the first

line that joins the more internal point of the forefoot and the more internal point of the rearfoot, with the second line, that joins the more internal point of the forefoot with the deeper part of the footprint. CSI is the minimal distance in the mid-foot region divided by the maximal distance in the forefoot region. SI is the ratio between the smallest length of the mid-foot and the largest length of the heel.

**Conclusion:** Footprint analysis is objective, simple, low-cost, readily available and non-invasive technique that can be used to evaluate the foot anatomy.

**Keywords:** foot, footprint analysis, footprint parameters

#### P-98

##### The effects of the materials used for anatomy education of medical students on the quality of learning

Keleş P<sup>1</sup>, Örs CH<sup>1</sup>, Malkoç İ<sup>2</sup>, Gedik HT<sup>2</sup>, Kara A<sup>3</sup>

*<sup>1</sup>Department of Anatomy, Faculty of Medicine, Health Sciences University, Istanbul, Turkey; <sup>2</sup>Department of Anatomy, Faculty of Medicine, Atatürk University, Erzurum, Turkey; <sup>3</sup>Department of Internal Medicine, Faculty of Medicine, Atatürk University, Erzurum, Turkey*

In medical schools, different materials are used for anatomy education. In some universities, anatomic models and cadaver are used together for education. In others, only anatomic models or only cadavers are used. This study is made to find out which method is the most efficient way to teach anatomy. For this purpose, the students of second grade of Atatürk University Faculty of Medicine, divided into two groups randomly. For three months, anatomic models used for training of first group. Cadaver and models are used together for second group. At the end of three months we compared the anatomy notes of students in the two groups. There was no statistical difference between the groups. However, according to the survey, to study on cadavers has motivating effect on students.

**Keywords:** anatomy, cadaver, anatomic model

#### P-99

##### Evaluation of the measurements taken from the upper extremity in students who play and don't play basketball

Şener OA<sup>1</sup>, Alpa S<sup>2</sup>

*<sup>1</sup>Department of Physical Education and Sport, Faculty of Sport Sciences, Selçuk University, Konya, Turkey; <sup>2</sup>Department of Anatomy, Faculty of Medicine, KTO Karatay University, Konya, Turkey*

Medical science aiming for human health, should evaluate the human together with the socio-cultural environment to achieve this purpose. Effect of sportive exercises on body proportions has always been a subject of research. In this study, measurements were taken from the upper extremities of 200 middle school students who mean age range of 11±1.08 (sportsman) – 11±0.8 (non-sportsman), playing and don't playing basketball. The average height and weight ratio of students who did and did not do sports

were 153.5±12.9–149.2±8.1 cm and 46.7±12.04–43.08±12.9 kg respectively. In the right and left upper limbs of the students who sportsman; Arm length 28.4±3.1–28.4±3.01 cm, forearm length 24.1±2.4–24.1±2.4 cm, hand length 15.9±1.8–15.9±1.6 cm, arm circumference 23.2±3.9–23.0±3.8 cm, circumference of forearm 20.8±2.5–20.6±2.5 cm, hand width was 7.8±0.8–7.9±0.8 cm. In the right and left upper limbs of the students who non-sportsman; Arm length 26.8±2.5–26.6±2.4 cm, forearm length 23.3±2.1–23.3±2.0 cm, hand length 16.0±1.5–16.2±1.5 cm, arm circumference 22.4±3.5–22.4±3.5 cm, circumference of forearm 19.4±2.5–19.4±2.5 cm, hand width was 7.6±0.9–7.7±0.9 cm. The results of the biacromial and bideltoid width measurements were 28.8±3.8 and 37.6±4.4, respectively. As a result of the evaluation; when the measurements taken from the right-left extremities were compared on sportsman, between arm circumference (p=0.02) was found difference; when the measurements taken from the right-left arm length (p=0.001) and the right-left hand length (p=0.02) was found difference.

**Keywords:** anthropometry, basketball, upper extremity

#### P-100

##### An anatomical study for approaches to the foramen ovale

Boduç E, Öztürk L

Department of Anatomy, Faculty of Medicine, Ege University, Izmir, Turkey

**Objective:** Foramen ovale is a hole located in the sphenoid bone, posterior and lateral to the foramen rotundum. The well known anatomy of the foramen ovale and associated structures is important for percutaneous and surgical interventions to the foramen ovale. Therefore, it is thought that the anatomical studies explaining the relation of the location of the foramen ovale with the surrounding structures with quantitative datas can be shed light on the attempts to be made.

**Methods:** In this study, foramen ovale was examined in 100 craniums and 40 skull base.

**Results:** In the measurements made, the short diameter measurement of total foramen ovale on the right sides was 2.72±1.18 (max-min: 6.01–0.54) on average and the long diameter measurement was calculated as 6.56±1.57 (max-min: 10.48–2.68) on average. The short diameter measurement of total foramen ovale on the left sides was 2.66±1.09 (max-min: 5.82–0.7) on average and the long diameter measurement was calculated as 6.56±1.59 (max-min: 12.69–3.06) on average. It was observed that the foramen ovale in right and left side of each of the 140 bones exhibited asymmetrical placement in 76 (54.28%). In addition to these, the distances of each foramen ovale to foramen spinosum, foramen acusticus externus, and the anterior and posterior roots of arcus zygomaticus were calculated.

**Conclusion:** In literature, it has been reported that percutaneous interventions made in the foramen ovale can cause serious complications. The anatomy of the foramen ovale and surrounding structures settled in the fossa infratemporalis must be

prevailed prior before the approaches to be performed. For this reason, in this study, the relationship between the foramen ovale and some anatomical structures that guide the surgical interventions was tried to be revealed with quantitative datas.

**Keywords:** foramen ovale, cranium, fossa infratemporalis

#### P-101

##### Morphometric measurements of patella and discriminative analysis in the determination of gender

İşiklar S<sup>1</sup>, Babacan S<sup>2</sup>, Özdemir S<sup>2</sup>

<sup>1</sup>Vocational School of Health Services, Medical Imaging Techniques Program, Uludağ University, Bursa, Turkey; <sup>2</sup>Department of Anatomy, Faculty of Medicine, Uludağ University, Bursa, Turkey

**Objective:** The patella, which is the largest sesamoid bone in the body, is located within the musculus quadriceps femoris tendon. Gender determination of bone measurements is important for anthropology, anatomy and forensic science. Reliability and usability of gender determination of morphometric measurements from patella, which are important elements of index extensor mechanism, constitute the subject of this research.

**Methods:** Our study was carried out on the knee MR images taken from accepted at the Clinical Research Ethics Committee of Uludağ University Faculty of Medicine dated 29.09.2015 and numbered 2015–17/19. Our study was carried out using MR images of 211 individuals, 99 of whom were female and 105 were male (mean age: 44.94±15.69, age range: 19–83 years). Based on the relevant morphometric measurements, discriminant analysis was performed to discriminate between sexes. Statistical analyzes were performed in the IBM SPSS Statistics 22 package program.

**Results:** Patellar angle, patellar width, patellar thickness, patellar lateral facet width, patellar medial facet width, lateral/medial facet ratio were found to be statistically significant difference between men and women in all variables (p<0.05). Model were obtained with the help of discriminant analysis as follows:  $Di = -17.846 + 0.011 (\text{patellar angle}) + 0.227 (\text{patellar width}) - 0.001 (\text{patellar thickness}) + 0.061 (\text{patella lateral facet width}) + 0.156 (\text{patella medial facet width}) + 1.319 (\text{lateral/medial facet ratio})$ . Correct classification rate of data in the study of obtained discriminant function was determined 70%.

**Conclusion:** In this study, it was tried to develop a discriminant function which can be used for gender discrimination by using morphometric values obtained from patella.

**Keywords:** patella, morphometry, sex determination, MR

#### P-102

##### Calculation of cut-off values of Staheli and Chippaux-Smirak indices in Turkish population

Sakalli G, Özgür S, Köker S, Varol T

Department of Anatomy, Faculty of Medicine, Celal Bayar University, Manisa, Turkey

**Objective:** Studies continued for more than a century on footprints have now settled certain standards in which measurements of various indices and areas are carried out. Measurements with direct scales such as Staheli and Chippaux-Smirak are preferred because, even if foot arch index gives significant information about the changes of foot arch as pes planus and pes cavus, it is difficult to calculate and is not giving sufficient information about anatomy. It was aimed in this study to calculate the cut-off values of the Staheli and Chippaux-Smirak indices for pes planus diagnosis.

**Methods:** For this purpose, the ethical committee approval was obtained from the Local Ethical Committee of Celal Bayar University Faculty of Medicine. Right footprint of 120 participants with body mass index 19–25, no orthopedic surgery, no health problems, in the age range of 18–40 years, were obtained by static measurement method called ink pad. Arch indices, staheli and Chippaux-Smirak indices were measured. Individuals with foot arch index above 0.26 were accepted as pes planus as in the literature. The data were evaluated using the SPSS 15 program.

**Results:** The mean age of the participants was 28.2±3.2, and the mean body mass index was 22.4±1.8. 41 individuals were found with the foot arch index above 0.26. For the Staheli index if the cut-off value was taken as >0.632, the sensitivity was determined as 87.3% and specificity was 65.8%; for the Chippaux-Smirak index, if the cut-off value was taken as >0.374, the sensitivity was 86.8% and the specificity was 68.3%.

**Conclusion:** It is believed that forresplants diagnosis, the use of values we calculated together with the various cut off values for the Staheli indices and the Chippaux-Smirak indices in the literature in future studies, will produce better results for our society.

**Keywords:** Chippaux-Smirak index, foot arch, pes planus, Staheli index

### P-103

#### Prevalence and distribution of fabella in Turkish subjects: a radiographic study

Eğerci ÖF<sup>1</sup>, Köse Ö<sup>2</sup>, Turan A<sup>2</sup>, Kılıçaslan ÖF<sup>2</sup>, Şekerci R<sup>3</sup>, Keleş Çelik N<sup>3</sup>

<sup>1</sup>Department of Orthopedics and Traumatology, Elmadağ State Hospital, Ankara, Turkey; <sup>2</sup>Department of Orthopedics and Traumatology, Antalya Training and Research Hospital, Antalya, Turkey; <sup>3</sup>Department of Anatomy, Faculty of Medicine, Akdeniz University, Antalya, Turkey

**Objective:** The purpose of this study is to examine the plain knee radiographs in Turkish subjects in order to determine the prevalence of fabella and analyze the differences between age, gender, laterality and its symmetry pattern.

**Methods:** Bilateral antero-posterior and lateral knee radiographs of 500 patients (250 male and 250 female subjects, 1000 knee radiographs) were randomly selected from the clinical database and retrospectively evaluated. Data on patient age, gender, and knee laterality (right-left) were evaluated from

hospital records. The differences between the sesamoid bones at a particular location and the side, sex and age groups were analyzed.

**Results:** The overall prevalence of the fabella (unilateral or bilateral) was 22.8% (114 subjects). The fabella was present unilaterally in 38 subjects (7.6%), while it was present bilaterally in 76 subjects (15.2 %). The prevalence of fabella was similar between the body sides. Prevalence of fabella between genders (unilateral or bilateral cases) and age groups was similar.

**Conclusion:** We examined the prevalence, symmetry pattern, age and gender differences in Turkish population. It is the first study performed on Turkish population with the largest sample in current literature. Prevalence of fabella is found to be 22.8% which is quite similar with other Caucasian ethnic populations.

**Keywords:** fabella, sesamoid bone, radiograph

### P-104

#### Anthropometric analysis of the facial soft tissue morphology in Turkish population: a pilot study

Hizay A, Özsoy U

Department of Anatomy, Faculty of Medicine, Akdeniz University, Antalya, Turkey

**Objective:** Facial anthropometric analysis is important for planning cosmetic and reconstructive facial surgery. In this study, multiple measurements of the facial soft tissue were performed on Turkish population to provide facial anthropometric profile. Additionally, we compared our results with published data by Farkas et al. in Turkish population.

**Methods:** Ethical approval was obtained from the Ethics Committee of Clinical Research of Akdeniz University (approval number 70904504/143). The study group consist of 20 (10 male and 10 female) healthy individual. The facial soft tissue of the subjects was scanned with a three-dimensional handheld scanner. The linear measurements and asymmetry analyses were performed by using thirteen anthropometric landmarks.

**Results:** Intercanthal, outer canthal width, nasal height-nasal width, nasal bridge length, maximal facial height, were significantly smaller in females than males (p<0.05). Comparison of asymmetry index demonstrated that all faces were symmetric and there were no significant differences between sex. The type of the face was hyperleptoprosop in 17 out of 20 and leptoprosop in 3 out of 20. Maximal facial height and intercanthal width significantly greater in our study when compared with Farkas's data (p<0.05).

**Conclusion:** The results of this study showed that there is significant difference between our study and Farkas's results in Turkish population. Future study should be done with larger cohorts in order to demonstrate more detailed facial profile of Turkish population. Such data will provide satisfactory surgical outcomes providing an aesthetically harmonic appearance.

**Keywords:** facial soft tissue, morphology, three-dimensional analysis

### P-105

#### Ultrastructural research on the effect of melatonin on damage in rat bulbus olfactorius after chronic cellulosic thinner inhalation

Önder M<sup>1</sup>, Güreş Eİ<sup>2</sup>, Gürçay S<sup>1</sup>, Oğuz N<sup>1</sup>, Oğuz Yolcular B<sup>3</sup>

<sup>1</sup>Department of Anatomy, Faculty of Medicine, Akdeniz University Antalya, Turkey; <sup>2</sup>Department of Medical Pathology, Faculty of Medicine, Akdeniz University, Antalya, Turkey; <sup>3</sup>Department of Biostatistics and Medical Informatics, Faculty of Medicine, Akdeniz University, Antalya, Turkey

**Objective:** To investigate the ultrastructural effect of melatonin on the damage caused by chronic inhalation of cellulosic thinner in rat bulb olfactorius.

**Methods:** Research ventilation was performed in special glass cages at constant temperature and pressure. In our study, 30 male Wistar rats of the genus *Rattus norvegicus* weighing 400–450 gr were used. The rats were divided into 3 groups. Groups; Control group and thinner receiving group, and thinner and melatonin receiving group. Ten rats were housed in each group and the rats were inoculated with thinner inhalation in glass cages with air ventilation for 1 hour, twice a day for 6 weeks. The most commonly used cellulosic thinner was used in the study. Inhalation concentrations of solvents in the thinner composition sprayed with a millipore pump at constant pressure into the cage were measured twice daily with a Dräger gas detector (Drägerwerk, Germany). The obtained sections were made suitable for electron microscopic analysis.

**Results:** At the end of the experiment, the TEM analyzes of the olfactorius tissue of the bulbus were as follows: Control Group: While the density of the cytoplasm was observed normally, abundant amounts of mitochondria were reported. Endoplasmic reticulum and ribosomes have normal structure. Thinner Inhalation Group: Nuclear membrane deterioration, ribosome, reduction in mitochondrial numbers and endoplasmic reticulum are not selected. Vacuolization and dense basilar cells were found. Thinner + Melatonin receiving group: A slight condensation was observed in the oval nucleus, while a slight decrease in the density of cytoplasm was reported. Nuclear membrane has a major non-deterioration and reduction and deterioration in the endoplasmic reticulum.

**Conclusion:** After thinner inhalation, bulbus olfactorius has been damaged, and it has been detected at the ultrastructural level that melatonin is inhibited against this injury.

**Keywords:** thinner, olfactory bulb, inhalation, ultrastructural

### P-106

#### Testicular torsion associated with indirect inguinal hernia: a case report

Karakas AB, Akbulut Y

Department of Anatomy, Faculty of Medicine, Kafkas University, Kars, Turkey

**Objective:** Inguinal hernia, that seen in the clinic and generally between 3–8% in men (75–85%) is one of common types of hernia. In the indirect type, the hernial sac doesn't enter the scrotum while entering the deep hole, reaching the scrotum, and is located above the inguinal ligament. Testicular torsion is a condition in which the spermatic cord is a traumatic or idiopathic condition that requires immediate medical intervention.

**Case:** A 70-year-old male cadaver had abdominal dissection was detected left indirect inguinal hernia who had been fixed at the Anatomy Department, University of Kafkas. The examination prior to dissection, hypertrophy was observed in the right scrotal sac of the cadaver, and atrophy was observed in the left scrotal sac. Testicular torsion was also observed on the side of the indirect inguinal hernia. The total length of the left and right testis and epididymis of the cadaver was 40.41 mm and 38.12 mm respectively, and the testis width was measured as 19.15 mm and 21.12 mm, respectively. Ileum which was in the hernial sac, was measured as 48.72 mm.

**Conclusion:** In this case, the detected indirect inguinal hernia acquired and observed testicular torsion occurring in the side as the hernia. As a result, almost each pelvic organ in the inguinal hernia can be located within the hernia sac, and it is thought that, besides the position and type of hernia, the testicular torsion can be seen in the surgical procedures to be performed and this results will be beneficial for both clinically and surgically planned operations.

**Keywords:** cadaver dissection, indirect inguinal hernia, testicular torsion

### P-107

#### Morphological investigation of the size and location of foramen infraorbitale

Aslan D<sup>1</sup>, Ay H<sup>1</sup>, Akbaş Y<sup>1</sup>, Cömert A<sup>2</sup>, Özden H<sup>1</sup>

<sup>1</sup>Department of Anatomy, Faculty of Medicine, Eskişehir Osmangazi University, Eskişehir, Turkey; <sup>2</sup>Department of Anatomy, Faculty of Medicine, Ankara University, Ankara, Turkey

**Objective:** Detailed information about the possible anatomical and morphometric variations of the infraorbital foramen (IOF), especially the safe and successful delivery of regional anesthesia, is of great importance for safe surgery of the region. Therefore, the distances of the relevant anatomical structures must be known precisely.

**Methods:** In this study, the placement of foramen infraorbitale on 21 skulls was shown morphometrically. In this study, “foramen infraorbitale” was used on both sides of 21 uninjured adult skulls. These skulls were obtained from the Anatomy laboratories of Eskişehir Osmangazi University Faculty of Medicine and Ankara University Faculty of Medicine. Calipers with 0.1 mm precision were used in the measurements. The distances of the foramen infraorbitale to orbital lower border (IOF-OAS), facial midline (IOF-YOH) and foramen supraorbitale (IOF-SOF), foramen supraorbitale's distance to the midline of the

face (SOF-(CIOF) were measured, and mean values and standard deviation values were calculated. The distance between the IOF-OAS and the IOF-OAS in the foramen infraorbitale measured was  $0.733 \text{ mm} \pm 0.14 \text{ mm}$ , the distance between IOF-YOH is  $2.54 \text{ mm} \pm 0.24 \text{ mm}$ , the distance between SOF and YOH is  $2.57 \text{ mm} \pm 0.30 \text{ mm}$ ,  $4.37 \text{ mm} \pm 0.31 \text{ mm}$ , CIOF  $0.5 \text{ mm} \pm 0.11 \text{ mm}$ .

**Conclusion:** The data obtained are expected to help reduce the risk of complications and malpractice that may arise as dentists and surgeons will help define the area of operation.

**Keywords:** infraorbital foramen, morphometry, anatomy

### P-108

#### Morphological analysis of foramen magnum in terms of size and shape

Ortadeveci A<sup>1</sup>, Öz S<sup>2</sup>, Güner MA<sup>3</sup>, Güner M<sup>1</sup>, Yücel F<sup>1</sup>, Özden H<sup>1</sup>

<sup>1</sup>Department of Anatomy, Faculty of Medicine, Eskişehir Osmangazi University, Eskişehir, Turkey; <sup>2</sup>Health Services Vocational High School, Eskişehir Osmangazi University, Eskişehir, Turkey; <sup>3</sup>Department of Anatomy Faculty of Medicine, Ankara University, Ankara, Turkey

**Objective:** Foramen magnum (FM) is a wide opening at the base of the occipital bone and through which vital preventive structures pass. Due to these important structures, clinical practice in the region requires microsurgical approach. Therefore, the dimensions of the relevant anatomical structures must be known precisely. In this study, it was aimed to show morphologically the differences that can be seen in the dimensions of “foramen magnum”.

**Methods:** In this study, 32 skulls and occipital bone, which are undamaged, were used. These skulls and bones were obtained from the Anatomy laboratories of Eskişehir Osmangazi University Faculty of Medicine and Ankara University Faculty of Medicine. Calipers with 0.1 mm precision are used in the measurements. Foramen magnum's anterior-posterior diameter (basion-opisthion-AP), transverse diameter (TR), foramen magnum index (FMI) obtained by TR division of AP, a steep cut from the condylus occipitalis oblique 1 and oblique 2 diameters and the distance from opisthion toinion (O-I) and the distance from opisthion to confluence sinuum (OC) were measured and mean values were determined.

**Results:** The mean AP distance was measured as  $35.54 (\pm 2.28)$  mm in 32 measured foramen magnum. The average of the transverse diameters was  $30.52 (\pm 2.60)$  mm. The mean values of oblique 1 and oblique 2 diameters were  $28.88 (\pm 2.69)$  mm and  $28.99 (\pm 2.82)$  mm, respectively. The mean O-C distance was  $40.36 (\pm 4.76)$  mm, while the O-I distance average was  $47.79 (\pm 6.27)$  mm.

**Conclusion:** The fact that the AP distance is longer than the transverse distance suggests that FM has an oval-like structure.

**Keywords:** foramen magnum, microsurgery, morphology

### P-109

#### A study on the anatomy and topography of the jugular foramen

Güner M<sup>1</sup>, Ulupınar E<sup>1</sup>, Ortadeveci A<sup>1</sup>, Ay H<sup>1</sup>, Tekdemir İ<sup>2</sup>, Özden H<sup>1</sup>

<sup>1</sup>Department of Anatomy, Faculty of Medicine, Eskişehir Osmangazi University, Eskişehir, Turkey; <sup>2</sup>Department of Anatomy, Faculty of Medicine, Ankara University, Ankara, Turkey

**Objective:** Jugular foramen is a very important anatomical opening formed by the occipital and temporal bones, through which the ninth, tenth and eleventh cranial nerves, glomus jugulare and jugular veins pass. These structures have vital importance. Malignancy and such pathologies devastate structures in this region by invading. Microsurgery techniques is used in the surgery of this region. Therefore, the surgeon working in this area should know the anatomy of this area's very well. In this study, we aimed that investigate this region's topography and anatomy.

**Methods:** We used nineteen dry cranium bones for this study. All bones were obtained from Departments of Anatomy, Faculty of Medicine, Eskişehir Osmangazi University and Ankara University. It was measured jugular foramina's length, width, depth and distance from stylomastoid foramina. We used digital vernier caliper for this study.

**Results:** The mean length, width, depth and distance from stylomastoid foramina of the jugular foramen were  $9.02 \pm 0.38$  mm,  $15.39 \pm 0.62$  mm,  $12.03 \pm 0.65$  mm,  $4.67 \pm 0.21$  mm on the right side and  $8.93 \pm 0.55$  mm,  $15.58 \pm 0.52$  mm,  $12.25 \pm 0.53$  mm,  $4.55 \pm 0.15$  mm on the left side.

**Conclusion:** The aim of this study was to provide information about anatomy and topography of Jugular foramen for surgeons and researchers.

**Keywords:** jugular foramen, length, width, depth, stylomastoid foramen

### P-110

#### Morphometric investigation of occipital condyle

Akbaş Y<sup>1</sup>, Öz S<sup>2</sup>, Aslan D<sup>1</sup>, Açar Hİ<sup>3</sup>, Özden H<sup>1</sup>

<sup>1</sup>Department of Anatomy, Faculty of Medicine, Eskişehir Osmangazi University, Eskişehir, Turkey; <sup>2</sup>Department of Vocational School of Health Services, Eskişehir Osmangazi University, Eskişehir, Turkey; <sup>3</sup>Department of Anatomy, Faculty of Medicine, Ankara University, Ankara, Turkey

**Objective:** Occipital condyle is an important structure that is jointed with cervical 1st vertebra (atlas) on both sides of foramen magnum at the base of occipital bone. In the surgery of the region, it is critical to know the relationship between the shape of condylus occipitalis and the vital structures in the region. In this study, we aimed to provide detailed information about the anatomy of region for the surgeons and researchers.

**Methods:** This study was performed on 40 cranium and occipital bone. These bones were obtained from ESOGÜ Faculty of

Medicine and A.Ü. Faculty of Medicine Anatomy laboratories. Digital calipers with 0.1 mm sensitivity are used in the measurements. Occipital condyle was evaluated for shape, length, width, thickness. Anterior and posterior intercondylar distances were also measured. The presence of condylar canal was determined as a percentage.

**Results:** In the 40 measured occipital condyles, the mean lengths were  $24.3 \pm 2.6$  mm on the right,  $24.2 \pm 3.1$  mm on the left; width averages  $13.4 \pm 1.4$  mm on the right,  $13.5 \pm 1.7$  mm on the left; the mean thicknesses were  $8.9 \pm 1.1$  mm on the right and  $8.6 \pm 1.1$  mm on the left. In addition, the mean distance between the anterior intercondylar space and the posterior intercondylar space was calculated as  $19 \pm 3$  mm and  $39.1 \pm 3.8$  mm, respectively. The presence of condylar canal was 87.5% on the right side and 85% on the left side.

**Conclusion:** Especially, in craniovertebral junction surgery, it will be helpful to know the anatomy of the occipital condyle.

**Keywords:** craniovertebral junction, occipital condyle, transcondylar surgery

#### P-111

##### Cortical, subcortical and brain stem connections of the cerebellum via the superior and middle cerebellar peduncle

Çavdar S<sup>1</sup>, Özgür M<sup>1</sup>, Kuvvet Y<sup>1</sup>, Bay H<sup>2</sup>

<sup>1</sup>Department of Anatomy, Koç University School of Medicine, Istanbul, Turkey; <sup>2</sup>Department of Anatomy, Marmara University School of Medicine, Istanbul, Turkey

**Objective:** The role cerebellum in coordination of somatic motor activity has been studied in detailed in various species. However, experimental and clinical studies have shown the involvement of the cerebellum with various visceral and cognitive functions via its vast connections with the central nervous system. The present study aims to define the cortical and subcortical and brain stem connections of the cerebellum via the superior (SCP) and middle (MCP) cerebellar peduncle using biotinylated dextran amine (BDA) and Fluoro-Gold (FG) tracer in Wistar albino rats.

**Methods:** 14 male albino rats received 20–50-nl pressure injections of either Fluoro-Gold (FG) or biotinylated dextran amine (BDA) tracer into the SCP and MCP. Following 7–10 days of survival period, the animals were processed according to the related protocol for the two tracer used. Labelled cells and axons were documented using light and fluorescence microscope.

**Results:** The SCP connected cerebellum to the insular and infralimbic cortices whereas, MCP addition to the insular cortex, it also connected cerebellum to the rhinal, primary sensory, piriform and auditory cortices. Both SCP and MCP carries afferent and efferent fibers to the thalamic nuclei. The SCP and MCP carried efferent fibers from the cerebellum to the ventral (lateral, anterior), posterior and central thalamic nuclei

and received afferents from the ventromedial, parafascicular thalamic nuclei. The SCP and the MCP carries fibers from specific hypothalamic nuclei to the cerebellum. The SCP conveys afferents from the lateral, dorsomedial, paraventricular and posterior hypothalamic nuclei to the cerebellum, whereas MCP conveys afferents from mammillary ventromedial, and lateral hypothalamic nuclei. The SCP connects cerebellum to basal ganglia (ventral pallidum and clastrum) and limbic structures (amygdaloid nuclei and bed nucleus of stria terminalis), however, the MCP have no connections with basal ganglia or limbic structures. Both the SCP and MCP densely connects cerebellum to various brainstem structures.

**Conclusion:** Attaining the knowledge of the afferent and efferent connections of the SCP and MCP is important for the diagnosis of lesions in the MCP and SCP and would deepen current understanding of the neuronal circuit of various diseases or lesions involving the SCP and MCP.

**Keywords:** superior cerebellar peduncle, middle cerebellar peduncle, connections

#### P-112

##### Walking pattern in rats: methods comparison

Kökeç Y, Sarıkcıoğlu L

Department of Anatomy, Faculty of Medicine, Akdeniz University, Antalya, Turkey

Analyzes used to evaluate the sciatic nerve regeneration have been well documented in the literature. Among these analyzes sciatic function index is widely known analysis method. Although it has first described by De Medinaceli, some modifications in the index formula has also been done. First modification was done by Carlton and Goldberg, the second by Bain et al. In the present study we discussed the available formulas and video based motion analysis in term of future perspective. Advantages and disadvantages of the video based motion analysis have also been reviewed.

#### P-113

##### Morphometric evaluation of the supratrochlear foramen

Oğuz N<sup>1</sup>, Gürçay S<sup>1</sup>, Önder M<sup>1</sup>, Akçal MA<sup>2</sup>, Oğuz Yolcular B<sup>3</sup>, Sindel M<sup>1</sup>

<sup>1</sup>Department of Anatomy, Faculty of Medicine, Akdeniz University, Antalya, Turkey; <sup>2</sup>Orthopedics and Traumatology Clinic, Atatürk State Hospital, Antalya, Turkey; <sup>3</sup>Department of Biostatistics and Medical Informatics, Faculty of Medicine, Akdeniz University, Antalya, Turkey

**Objective:** This study aims to describe its prevalence and morphometry in relation to its shape and size and distance from epicondyles and clinical perspective.

**Methods:** In our study, we used 25 left and 25 right humerus without distal tip damage from Department Of Anatomy



Laboratory, Akdeniz University Faculty Of Medicine, Antalya. The transverse and vertical diameter of supratrochlear foramen and its distance from lateral epicondyl, medial epicondyl and inferior line were measured with MicroscribeG2X. Descriptive analysis was applied to dataset and the results were presented as mean±standard deviation. Two mean difference tests were used to compare the right and left supratrochlear foramen values of the variables. Data were processed and analyzed with SPSS (Statistical Package for Social Sciences) version 20.0. and a p-value greater than 0.05 was considered statistically significant.

**Results:** The transverse and vertical diameter of supratrochlear foramen and its distance from lateral epicondyl, medial epicondyl and inferior line were measured of 25 right and 25 left humerus and data were processed and analyzed.

**Conclusion:** The data obtained as a result of the measurements will lead to surgical interventions to the trochlear and supracondylar fractures.

**Keywords:** distal humerus, supracondylar fracture, supracondylar foramen, trochlea humeri

#### P-114

##### Skermanella aerolata contamination at formalin-fixed cadavers

Güncü MM<sup>1</sup>, Özkan M<sup>2</sup>, Aksu B<sup>1</sup>, Yıldız SD<sup>2</sup>, Şehirli ÜS<sup>2</sup>

*Department of Medical Microbiology, Faculty of Medicine, Marmara University, Istanbul, Turkey; <sup>2</sup>Department of Anatomy, Faculty of Medicine, Marmara University, Istanbul, Turkey*

**Objective:** The most commonly used chemical substances for cadaver fixation and the control of microorganism contamination are formalin, ethanol and phenol. However, microorganisms such as bacteria, fungi and parasites can develop contamination on cadavers. In this case, characterization of bacterial isolate causing cadaver contamination in cadaver room of the Anatomy department and formaldehyde sensitivity of the bacteria were investigated.

**Methods:** Whitish occurrences were noted in the soft tissues and the open spongy ends of the bones of the cadaver, which were stored in the formalin tank. Modeled on suspicion of microorganisms breeding, sheep blood agar cultivation was done. After 72 hours of incubation, pure breeding colonies were examined with Gram stain. 16S rDNA sequence analysis of the isolate was done because the protein profile was not found in the database of MALDI-TOF MS. In order to determine the bactericidal disinfectant sensitivity, the disinfectant activity of the solution from the cadaver tank, 5% formaldehyde and 0.055% Ortho-phthalaldehyde (OPA) solutions after 15 min and 8 h exposure was examined.

**Results:** The bacteria had gram negative bacillus morphology. The obtained 16s rDNA sequence was compared with the gene

bank database and it was determined that it showed 99% similarity (Genbank No. JX841089) with *Skermanella aerolata*. In the disinfectant activity study, it was observed that the bacterium could only grow 15 minutes in the sample taken from the tank, and there was no reproduction after 15 minutes and 8 hours incubation in the other solutions tested.

**Conclusion:** *Skermanella aerolata* was isolated from air in South Korea initially in 2007. It is described as an environmental microorganism in Gram-negative staining, moving and facultative anaerobic structure.

**Keywords:** cadaver, formaline, *Skermanella aerolata*

#### P-115

##### Variational course of the musculocutaneous nerve: case report

Boracı H<sup>1</sup>, İsmailoğlu A<sup>2</sup>, Yıldız SD<sup>1</sup>, Kirazlı Ö<sup>1</sup>, Şehirli ÜS<sup>1</sup>

*<sup>1</sup>Department of Anatomy, Faculty of Medicine, Marmara University, Istanbul, Turkey; <sup>2</sup>Department of Anatomy, Faculty of Medicine, Acibadem University, Istanbul, Turkey*

**Objective:** Brachial plexus is a network of the nerves that innervates the upper extremity region, muscles. The anterior divisions of the middle and superior trunk establish the lateral cord and the lateral cord gives a branch as a terminal branch which is called musculocutaneous nerve. The musculocutaneous nerve is composed of C5-C6 spinal nerves and may show lots of variations while proceeding.

**Case:** During the routine dissection session in anatomy lab, a male cadaver was dissected. On the right upper extremity, the lateral cord gave two branches. The first and small one continued laterally by piercing the coracobrachialis muscle and lateral branch of median nerve got united with the medial branch of median nerve. Then, the lateral branch separated from the median nerve. The nerve traveled along the arm anteromedially passing above the axillary artery however the venous drainage of brachial vein into axillary vein appeared between the lateral and medial branch of median nerve.

**Conclusion:** Lots of studies have been shown related to the course of musculocutaneous nerve. Radunovic et al classified into 6 groups regarding to the variational course of the nerve. On the other hand, in 2016, Hayashi et al described as 5 groups according to relation of median and musculocutaneous nerve while giving branches to muscles. The variation that we mentioned above could be placed to the 4th group which may be seen rarely. In the literature, different types and classifications of variations were reported in order to ease the surgical approach and application of the related anatomical area.

**Keywords:** musculocutaneous nerve, median nerve, coracobrachialis muscle, axillary vein, brachial plexus

# 18th National Anatomy Congress

## 25–27 September 2017, Abant, Turkey

<b>A</b>			
Acar E	P-48, P-51	Bağlam MB	P-79
Acer N	O-8, O-11, P-29, P-56, P-83, P-94	Bahşi İ	P-66, P-67
Açar G	P-87	Balak N	P-41
Açar Hİ	P-110	Balcıoğlu HA	O-25, P-31, P-37
Ak Güven G	O-6, O-14	Bamaç B	P-3, P-48, P-51
Akbaş Y	P-107, P-110	Bastepe SG	O-11
Akbulut Y	P-106	Bay H	P-111
Akcaalan M	P-42, P-69	Baykan AH	O-10
Akça Z	P-22, P-43, P-86, P-91, P-96, P-97	Bayko S	P-84, P-85
Akçal MA	P-113	Bayramiçli M	OL-1
Akın D	P-6, P-7, P-81, P-90	Beger B	O-28
Akkaya N	O-27	Beger O	O-28, O-30
Akkın SM	P-25, P-26	Behram Kandemir Y	O-16
Akkoç RF	O-19, P-63	Bilgin SŞ	P-46
Akpınar B	P-79	Bilir A	P-36, P-59
Aksu B	P-115	Bilişli E	P-41
Aksu E	P-3, P-51	Boduç E	P-100
Akşit MD	PS-1	Boracı H	P-116
Akyol Bahçeci S	O-29	Bozdağ M	P-79
Al Ö	O-21	Bozer C	P-28, P-71
Albay S	P-33, P-34	Burukoğlu D	P-68
Albulut NB	P-79	Büyükkertan M	P-37
Aldur MM	PS-1	Büyükmumcu M	P-6, P-7, P-81, P-87
Alış H	P-4		
Alpa Ş	P-6, P-90, P-98	<b>C-Ç</b>	
Altunsoy E	P-91	Canbolat M	P-73
Altunsoy S	P-79	Candan B	P-33, P-34
Arpacı F	P-78	Cankuş MC	P-25, P-26
Aslan D	P-107, P-110	Canpolat M	O-42
Aslan E	P-36	Cantas F	P-82
Atasever A	P-46	Coşkun İ	P-35
Atay E	O-21, O-33, O-38, O-39	Coşkun O	O-1, P-1, P-2
Ateşoğlu S	O-10, O-23	Cömert A	P-52, P-107
Avnioğlu S	O-39	Cumbul A	P-41
Ay H	P-107, P-109	Çalışgan E	P-45
Ay Keselik G	O-29, P-76, P-77	Çam Y	P-19
Aycan K	O-33, O-38	Çandır BN	P-21, P-50, P-58
Aydın A	O-10, O-23	Çavdar S	O-15, P-111
Aydın Ç	O-16	Çavuş F	P-78
Aydın E	O-35	Çayan D	P-56
Aydın Kabakçı AD	P-6, P-7, P-81, P-90	Çelik HH	PS-1
Aytaç G	O-8, O-13, P-60, P-61	Çeri NG	P-82
		Çetin A	P-40
		Çevirgen F	P-40, P-45, P-73, P-74, P-78
		Çıkmaz S	P-28
		Çiçekcibaşı AE	P-81
		Çiftcioğlu E	O-36, O-43
		Çiftçi R	P-80
<b>B</b>			
Babacan S	O-2, O-3, P-101 P-49		
Bağcı Uzun G5	P-14		

- Çinar Ş P-7  
Çinpolat B P-23  
Çizmecici G O-29, P-76, P-77  
Çolak C P-80  
Çolak S P-3  
Çolak T P-3, P-48, P-51  
Çuğlan S P-74, P-80
- D**  
Değermenci M P-14, P-88  
Değirmencioğlu L O-11  
Demir H P-94  
Demirci MS O-1  
Demirel A P-29  
Demirel BM P-25, P-26  
Demirkan İ P-36  
Demiryürek D O-18, O-20, O-26, P-57  
Denli Yalvaç Ş P-41  
Derin N O-13  
Develi M O-7  
Develi S O-7, O-17, O-37, P-5, P-8, P-10, P-11, P-12, P-13, P-62  
Doğan M P-56  
Doğan S P-94  
Doğan Z O-10, O-23  
Duman F O-24  
Dural AC P-4  
Durgun B O-31  
Durmaz MO P-89, P-92
- E**  
Eğerci ÖF P-103  
Emirzeoğlu M O-6, O-14  
Eraldemir FC P-48, P-51  
Erbay F O-10  
Erbay H P-59  
Ercıktı N P-10  
Erçakmak B O-18, O-20  
Erdem A P-79  
Erdoğan K O-29, P-76, P-77  
Erdoğan M P-69  
Erdoğan S O-28  
Erer Kafa S O-2, O-3  
Erkan İ O-6, O-14, P-91  
Erpek S P-71  
Ertaş A O-1  
Ertekin A P-36  
Ertekin T O-21, O-39, P-14, P-36, P-59, P-75, P-83, P-88  
Eryiğit Ö P-95
- F**  
Fazlıoğulları Z P-24, P-27
- G**  
Gayretli Ö O-1, P-1  
Gedik HT P-98  
Göçmen Mas N P-89, P-92  
Gökalp G O-5
- Göksu AK O-13  
Gölpınar M O-41, P-22, P-32, P-86, P-91, P-96, P-97, P-43  
Gönül AS O-12  
Görgişen G O-16  
Görkem SB P-83  
Gülaçtı MM P-29  
Güldoğan B P-79  
Güler İ P-87  
Gülhan R PS-5, O-32  
Gülhaş N P-20  
Gülkesen KH O-8  
Günal D PS-6  
Güncü MM P-115  
Güneç Beşer C O-18, O-20  
Güner M P-108, P-109  
Güner MA O-46, P-108  
Güray B P-31  
Gürçay S P-113, P-114  
Gürer Eİ P-105, P-114  
Gürses İA O-1, P-1, P-2, P-4, P-21, P-50, P-58  
Gürtekin B O-1, P-1, P-50  
Güzel H P-36, P-59  
Güzelordu D P-3, P-51
- H**  
Hacıoğlu Bay H O-15  
Hatipoğlu B O-13  
Hizay A P-104  
Horata E P-75
- I-İ**  
Işıklar S O-5, P-101  
İnci E P-4  
İpek ED O-35  
İsmailoğlu A P-116
- K**  
Kacar S O-22, P-15, P-16, P-17, P-18  
Kaçar E P-95  
Kafa İM O-2, O-3, P-49  
Kale A P-1, P-21, P-58  
Kalemci O P-89  
Kanbak G P-68  
Kara A P-98  
Kara AB O-40  
Kara BA O-30  
Karaali K O-8  
Karabekir HS P-89, P-92  
Karabulut AK P-24, P-27  
Karaca Bozdağ Z P-19  
Karaca L P-40, P-73, P-74  
Karaca Saygılı Ö O-12  
Karacan A P-42, P-69  
Karacan K P-42, P-69  
Karakaş AB O-12, P-106  
Karakoyun ZN P-44  
Karatay T O-42  
Karimkhani H P-68, P-70

**S156 18th National Anatomy Congress, 25–27 September 2017, Abant, Turkey**

Kavaklı A	P-65	Özden H	P-107, P-108, P-109, P-110
Kayatekin O	P-47	Özel M	P-22, P-43, P-86, P-91, P-96, P-97
Keleş Çelik N	P-64, P-103	Özen KE	P-76, P-77
Keleş P	P-98	Özer Gökaslan Ç	P-75
Kendir S	P-9	Özgen B	O-26
Kervancıoğlu P	P-66, P-67	Özgür M	O-15, P-111
Keven A	P-60, P-61	Özgür S	O-45, P-102
Kılıçaslan ÖF	P-103	Özkan G	O-19, O-27
Kirazlı Ö	P-116	Özkan M	O-4, P-115
Kocabıyık N	P-11, P-52	Özkaya BA	P-42
Köker S	P-102	Özkoç M	P-68
Kökez Y	P-112	Özmen S	P-56
Köksal V	O-39	Özsoy H	O-18, O-20
Köse E	P-74, P-80	Özsoy U	P-38, P-39, P-53, P-104
Köse Ö	P-103	Öztürk A	P-1, P-2, P-4, P-50
Kurtoğlu Z	O-28, O-40	Öztürk AH	O-40
Kutlu HM	O-22, P-15, P-16, P-17, P-18	Öztürk F	O-24
Kutoğlu T	P-84, P-85	Öztürk L	P-100
Kuvvet Y	O-15, P-111	Öztürk M	O-33, O-38
Kürkçüoğlu A	P-19	Öztürk NC	O-40
		Öztürk S	O-13, P-60, P-61
<b>M</b>		<b>P</b>	
Malas MA	O-29, P-76, P-77	Paksoy Y	P-27
Malkoç İ	P-98	Parlak M	P-28
Maral Kır H	P-48, P-51	Per H	P-56
Meker M	O-33, O-38	Pınar Y	P-30
Metin Tellioglu A	O-35	Polat M	P-27
Mıdık Ö	O-36, O-43		
<b>N</b>		<b>S-Ş</b>	
Nahir M	P-91	Sağlam L	P-21, P-50, P-58
Nalbant M	P-4	Sahinturk V	O-22, P-18
Nisari M	O-21	Sakalli G	P-102
Nteli Chatzioglou G	P-30	Sarıkoğlu L	P-112
		Seher N	P-24
<b>O-Ö</b>		Serarslan Y	O-24
Oğuz N	P-113, P-114	Sert G	O-4
Oğuz Ö	P-19	Sevindik B	P-24
Oğuz Yolcular B	P-105, P-113, P-114	Shojaolsadati P	P-68, P-70
Orhan M	P-66, P-67	Sindel M	O-8, O-13, P-60, P-61, P-113
Ortadeveci A	P-108, P-109	Sivri İ	P-3, P-51
Ozan H	P-52	Solgun S	O-10
Ögetürk M	O-19, P-63	Söztutar E	P-41
Öğüt E	P-53, P-54, P-55, P-64	Susar H	O-21
Ölmez D	O-27	Süzen LB	P-39, P-44
Önder M	P-105, P-113, P-114	Şahin B	O-14
Örs A	P-3	Şahinoğlu Kuş S	PS-2
Örs CH	P-98	Şahintürk V	P-15, P-16, P-17
Öz N	P-44	Şahmelikoğlu AG	P-82
Öz S	P-108, P-110	Şakul U	P-70
Özbağ D	O-42, P-20, P-40, P-45, P-73, P-74, P-78, P-79, P-80	Şap O	P-63, P-65
Özcan F	P-23	Şehirli ÜS	PS-4, P-115, P-116
Özcan G	O-10	Şeker M	PS-1, O-9, P-90
Özcan İ	P-31	Şekerci R	P-64, P-103
Özdamar S	O-21	Şen S	P-46
Özdemir F	O-41, P-32, P-91	Şener A	O-6
Özdemir S	O-5, P-101	Şener OA	P-98
Özdemir Ş	P-79	Şengül G	O-47
Özden F	P-79	Şenol D	O-42, P-20, P-40, P-45, P-73, P-74, P-78, P-79

<b>T</b>			
Tahta Y	O-33, O-38	Ünalmiş D	P-94
Tanrıöver G	O-13	Ünsal G	P-31
Taşdemir R	P-3, P-48, P-51	Ünver Doğan N	O-9, P-24, P-27
Taşkınalp O	P-47, P-72	Üstdal Güney A	P-19
Taştekin N	P-28	Üzel M	O-1
Tatar İ	O-26	<b>V</b>	
Tekdemir İ	P-109	Varol T	P-102
Tekin B	P-93	Vatanserver A	O-26, P-57
Tokmak KM	P-79	Verimli A	PS-3
Tokpınar A	P-83	<b>Y</b>	
Tosunoğlu E	P-21, P-50, P-58	Yalçın B	O-21, O-34, P-62
Toy Ş	P-20	Yalçın ED	P-66, P-67
Turamanlar O	P-36, P-59, P-75, P-95	Yarar B	P-76, P-77
Turan A	P-103	Yarkan İS	P-84, P-85
Turgal E	O-41, P-32	Yay A	O-21
Türkay R	P-4	Yener MD	P-3, P-48
<b>U-Ü</b>		Yıldırım A	P-53
Uçar İ	P-14, P-88	Yıldırım FB	P-53, P-54, P-55
Uluçam E	P-28, P-47	Yıldırım H	P-65
Uludağ Ö	O-23	Yıldız S	O-34, P-5, P-52
Ulupınar E	P-109	Yıldız SD	P-115, P-116
Unur E	O-21, P-14, P-88	Yıldız Yılmaz M	P-35, P-49
Uslu Aİ	P-25, P-26	Yılmaz A	P-72
Uslu U	P-41	Yılmaz H	O-21
Usta A	O-44	Yılmaz MT	P-6, P-7, P-81
Uysal İİ	O-9	Yılmaz S	O-39, P-14, P-83, P-88, P-94
Uysal Ö	P-37	Yilmazer Kayatekin AZ	P-28, P-47
Uzmansel D	O-28, O-30, O-40	Yılmaz S	P-56
Uzun A	P-22, P-43, P-86, P-91, P-96, P-97	Yonguç GN	P-89, P-92
Uzun GB	P-88	Yücekaya B	O-24
Uzun ND	P-89, P-92	Yücel F	P-70, P-108
Uzuner K	P-68	Yüzbaşıoğlu N	P-93
Üçkardeş F	O-23	<b>Z</b>	
Ülger H	P-83	Zararsız G	O-11
Ünal M	P-95		





---

## Table of Contents

---

Volume 11 / Supplement 2 / September 2017

### Editorial

Welcome Address of the Congress President Ümit S. Şehirli	v
--------------------------------------------------------------	---

### 18th National Anatomy Congress

Program Schedule	vii
------------------	-----

### Abstracts

Opening Lecture	S93
Panel Sessions	S95
Oral Presentations	S97
Poster Presentations	S114
Author Index	S154