

Letter to Editor

## A Case of Penile Hair Ring in a Young Bull

İbrahim Akın

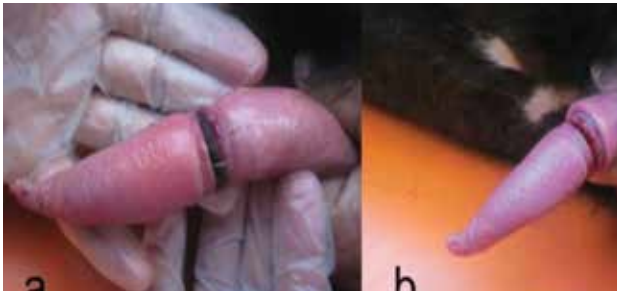
Department of Surgery, Faculty of Veterinary Medicine, Adnan Menderes University, 09016 Aydın, Turkey

Dear Editor,

Penile hair ring occasionally entrapped around the penis in bulls. The latter situation may be resolved spontaneously or strangulated and damaged the penis (Desrochers et al., 1995; Gilbert, 2004; Schuler et al., 2008). It may muddle up with preputial and penile injuries, tumors or other male reproductive disorders (Jean, 1995, Schuler et al., 2008). Although, some of penile and preputial hair ring cases resolved spontaneously, treatment depends on the judgment of surgeon, they can be sutured or not (Gilbert, 2004).

The 6 months old, native breed bull was referred with a hemorrhagic discharge complaint through preputium.

At clinical examination, no bloody discharge was observed. The young bull was lied in right lateral recumbency. The penis was pulled out from the preputium and a penile hair ring was noticed (Picture 1 a). After removal of the penile hair ring (Picture 1 b), there is around 0.3 mm deep ring lesion on the penis. Nitrofurazone (Furacine®Eczacıbaşı) and extract of Centella Asiatica (Madedassol®Bayer) were applied on to the lesion, and administered daily for 10 days. After 2 months later, as being informed by the owner on phone call, the bull was slaughtered for a Muslim festival for sacrifices. This meant that the bull was completely cured, so it could be sacrificed for Muslim festival.



**Figure 1.** Penil hair ring (a), after removal of the hair ring (b).

A penile hair ring case was rarely seen in large animals. In this case, we did not need suture. Sharing this exemplary case was evaluated as valuable with its easy treatment.

The author suggested sharing the present case and its national treatment for establishing treatment outcomes for similar cases.

## References

- St Jean G. Male reproductive surgery. Clin North Am Food Anim Pract. 11(1):55-93, 1995.
- Desrochers A, St-Jean G, Anderson DE. Surgical management of preputial injuries in bulls:51 cases (1986-1994). Can Vet J. 36:553-556, 1995
- Gilbert OR. Preputial Surgery. In: Farm animal Surgery. Ed: Susan Fubini, Norm Ducharme. Saunders, St. Louis, Missouri, 2004. Pp. 376. ISBN: 0-7216-90-62-9.
- Schuler, G., Richterich, P., Hoffmann, B. Severe balanitis and penile prolapse in a Scottish Highland bull due to an ingrown hair ring. Tierärztliche Praxis Ausgabe Grosstiere Nutztiere. 36 (6): 385-388, 2008.