



# Veterinary Journal of Kastamonu University



eISSN: 2822-4922

YEAR: 2022

VOLUME: 1

ISSUE: 2

## Veterinary Journal of Kastamonu University

Published twice a year

E-ISSN 2822-4922

### Editorial Board

#### Editor-in Chief

Dr. Musa TATAR

#### Co Editors in Chief

Dr. Tarık ŞAFAK

Dr. Gülşah GÜNGÖREN

#### Section Editors

Dr. Özgür KAYNAR

Dr. Elçin GÜNAYDIN

Dr. Elif DOĞAN

Dr. Yasin AKKEMİK

Dr. Murat POLAT

#### Typesetting Editor

Dr. Selda DURAN YELKEN

#### Language Editors

Dr. Mustafa HİTİT

Dr. Veysel DOĞAN

#### Statistics Editor

Dr. Kenan Çağrı TÜMER

#### Layout Editor

Stüleyman YÜKSEL

#### Journal Secretary

Dr. Mübeccel ATELGE

#### Correspondence

Kastamonu Üniversitesi, Veteriner Fakültesi, Kuzeykent Kampüsü, 37150-Kastamonu/TÜRKİYE

Tel: +90 366 280 5112,

E mail: vetjournal@kastamonu.edu.tr

#### URL:

<https://veteriner.kastamonu.edu.tr/index.php/tr/dergi>

<https://dergipark.org.tr/tr/pub/vetjku>

Publication Type: Common periodicals and peer-reviewed

© Veterinary Journal of Kastamonu University

All rights reserved. All or part of this Journal, or some or all of the scientific studies in the Journal, cannot be reproduced or published electronically, mechanically, by photocopy, or by any recording system without the written permission of the Dean of the Faculty of Veterinary Medicine of Kastamonu University.

### Advisory Board

Dr. Abdullah KAYA, Wisconsin State University, United States of America

Dr. Ali RİŞVANLI, Kyrgyzstan-Turkey Manas University, Kyrgyzstan

Dr. Alparslan COŞKUN, Sivas Cumhuriyet University, Türkiye

Dr. Arabela Viana, Universidade Federal de Viçosa, Brezilya

Dr. Arlindo Moura, Universidade Federal do Ceará, Brezilya

Dr. Barış Atlay USLU, Sivas Cumhuriyet University, Türkiye

Dr. Beste DEMİRCİ, Kastamonu University, Türkiye

Dr. Ejaz AHMAD, Bahauddin Zakariya University, Pakistan

Dr. Elçin GÜNAYDIN, Kastamonu University, Türkiye

Dr. Elif DOĞAN, Kastamonu University, Türkiye

Dr. Emrah Hicazi AKSU, Kastamonu University, Türkiye

Dr. Erdogan MEMİLİ, Prairie View A&M Uni., United States of America

Dr. Fırat DOĞAN, Hatay Mustafa Kemal University, Türkiye

Dr. Funda TERZİ, Kastamonu University, Türkiye

Dr. Hakan ÖNER, Burdur Mehmet Akif Ersoy University, Türkiye

Dr. H. Abdırashit NAZİRBEKOVİCH, Osh State University, Kyrgyzstan

Dr. Hasan ALKAN, Selçuk University, Türkiye

Dr. Hüseyin Serkan EROL, Kastamonu University, Türkiye

Dr. Kenan Çağrı TÜMER, Kastamonu University, Türkiye

Dr. Mehmet CAN, Balıkesir University, Türkiye

Dr. Mehmet Cemal ADIGÜZEL, Atatürk University, Türkiye

Dr. Mehmet KÖSE, Dicle University, Türkiye

Dr. Mehmet Saltuk ARIKAN, Fırat University, Türkiye

Dr. Mitra Mazinani, Washington State University, United States of America

Dr. Murat POLAT, Kastamonu University, Türkiye

Dr. Musa TATAR, Kastamonu University, Türkiye

Dr. Mustafa HİTİT, Kastamonu University, Türkiye

Dr. Mübeccel ATELGE, Kastamonu University, Türkiye

Dr. Mücahit KAHRAMAN, Harran University, Türkiye

Dr. Naseer A. Kutchy, St. George's University, Grenada

Dr. Onur CEYLAN, Selçuk University, Türkiye

Dr. Orhan ÇORUM, Hatay Mustafa Kemal University, Türkiye

Dr. Osman Sabri KESBİÇ, Kastamonu University, Türkiye

Dr. Özgür KAYNAR, Kastamonu University, Türkiye

Dr. Özlem DURNA AYDIN, Dicle University, Türkiye

Dr. Ruslan SALIKOV, Kyrgyzstan-Turkey Manas University, Kyrgyzstan

Dr. Sanan RAZA, University of Veterinary & Animal Sciences, Pakistan

Dr. Shamimul Hasan, Mississippi State University, USA

Dr. Sinan KANDIR, Çukurova University, Türkiye

Dr. Tarık ŞAFAK, Kastamonu University, Türkiye

Dr. Uğur ÖZENTÜRK, Atatürk University, Türkiye

Dr. Umair AHSAN, Burdur Mehmet Akif Ersoy University, Türkiye

Dr. Zafer BULUT, Dokuz Eylül University, Türkiye

Dr. Zahid NASEER, Pir Mehr Ali Shah Arid Agriculture University, Pakistan

**Veterinary Journal of Kastamonu University**

**Volume: 1 • Issue 2 • 2022**

Published 31.12.2022

**CONTENTS**

**Research Article**

Morphometric examination of glandula lacrimalis of Hamdani sheep by computed tomography  
**Barış Can GÜZEL, İsmail DEMİRCİOĞLU** **1**

The effect of pentoxifylline administration at different doses on hematological and biochemical parameters in sheep  
**Duygu Durna ÇORUM, Orhan ÇORUM, Ayşe ER, Kamil ÜNEY** **10**

**Case Report**

Diaphragmatic hernia and its treatment in a stray dog  
**Cihan GÜNAY, Eren POLAT, Aydın SAĞLIYAN** **17**

A case of cystic mammary adenocarcinoma in rabbit  
**Gözde OKUYUCU, Zafer ÖZYILDIZ, Volkan İPEK** **25**

**Review**

The microbiota of humans and animals and its relationship with the use of functional foods  
**Ayşegül DEMİRCİOĞLU, Muhammed DEMİRCİOĞLU, Migena GJONI GÜNDEMİR** **32**

Current classification of Peribunyaviridae family: genetic diversity and contributing factors  
**İlker ŞAHİNKESEN, Fırat DOĞAN, Seval BİLGE DAĞALP** **42**

## Morphometric examination of glandula lacrimalis of Hamdani sheep by computed tomography

Barış Can GÜZEL<sup>1,a,\*</sup>, İsmail DEMİRCİOĞLU<sup>2,b</sup>

<sup>1</sup>Firat University, Faculty of Veterinary Medicine, Department of Anatomy, Elazığ, Türkiye; <sup>2</sup>Harran University, Faculty of Veterinary Medicine, Department of Anatomy, Şanlıurfa, Türkiye.

<sup>a</sup>ORCID: <https://orcid.org/0000-0002-2504-120X>; <sup>b</sup>ORCID: <https://orcid.org/0000-0002-0724-3019>

\*Corresponding author: bcguzel@hotmail.com

Received 08.11.2022 - Accepted 07.12.2022 - Published 31.12.2022

**Abstract:** This study was carried out to obtain morphometric measurements of glandula lacrimalis of Hamdani sheep on computed tomography (CT) images and to determine the biometric differences of these measurement values in terms of both homotypic variations and sexual dimorphism. In the study, CT images of glandula lacrimalis obtained from 10 adult healthy Hamdani sheep, containing five males and five females were used. Morphometric measurements were taken from the transversal, sagittal and dorsal sections of the right and left glandula lacrimalis. Statistical analysis was performed for morphometric values. In the morphometric examinations, the mean length, width, and height values for both the right and left glandula lacrimalis were found to be  $15.71 \pm 0.17$  mm,  $9.39 \pm 0.9$  mm,  $4.84 \pm 0.5$  mm, respectively, for male Hamdani sheep; in females, these values were determined as  $13.80 \pm 0.37$  mm,  $8.40 \pm 0.5$  mm and  $4.14 \pm 0.67$  mm, respectively. As a result, statistical gender differences in the measurement parameters of glandula lacrimalis of adult Hamdani sheep were determined using computed tomography images.

**Keywords:** Computed tomography, glandula lacrimalis, Hamdani sheep.

### Hamdani koyunlarının glandula lacrimalis'inin bilgisayarlı tomografi ile morfometrik incelenmesi

**Özet:** Bu çalışma, Hamdani koyunlarının glandula lacrimalis'in bilgisayarlı tomografi (BT) görüntüleri üzerinden morfometrik ölçülerini elde etmek ve bu ölçüm değerlerinin hem homotipik varyasyonlar hem de seksüel dimorfizm bakımından biyometrik farklılıklarını belirlemek amacıyla yapıldı. Çalışmada beş erkek, beş dişi olmak üzere toplamda 10 adet erişkin sağlıklı Hamdani koyunu'nun glandula lacrimalis'ine ait BT görüntüsü kullanıldı. Sağ ve sol glandula lacrimalis'e ait transversal, sagittal ve dorsal kesitlerden morfometrik ölçümler alındı. Morfometrik değerlerin istatistiksel analizi yapıldı. Yapılan morfometrik incelemelerde sağ ve sol glandula lacrimalis'e ait ortalama uzunluk, genişlik, yükseklik değerlerinin erkek Hamdani koyunlarda en yüksek ölçü sırasıyla ortalama  $15,71 \pm 0,17$  mm,  $9,39 \pm 0,9$  mm,  $4,84 \pm 0,5$  mm; dişilerde ise, bu değerler sırasıyla ortalama  $13,80 \pm 0,37$  mm,  $8,40 \pm 0,5$  mm,  $4,14 \pm 0,67$  mm olarak belirlendi. Sonuç olarak, erişkin Hamdani koyunlarının glandula lacrimalis'e ait ölçüm parametrelerinin istatistiksel olarak cinsiyetler arasındaki farklılıkları bilgisayarlı tomografi görüntüleri kullanılarak tespit edildi.

**Anahtar kelimeler:** Bilgisayarlı tomografi, glandula lacrimalis, Hamdani koyunu.

### Introduction

Hamdani sheep is a locally bred breed in the Eastern and Southeastern Anatolia region, albeit small in number (Öztürk, 1998). Hamdani sheep, which originate from Iran, have a very

high adaptation to the harsh conditions of nature (Abdul-Rahman & Al-Barzinjy, 2007; Bingöl & Bingöl, 2015). Computed tomography (CT) is based on the cross-sectional examination of the object with X-rays (Baykal & Oyar, 2003; Capello & Cauduro, 2008; Tuncel, 2007). In computed tomography, sections are obtained by rotating the tube and detector around the object (Kaya et al., 1997). Combining sections and creating a 3D model is called reconstruction. It is used to create treatment protocols in 3D images obtained and to visualize irregular structures and organs in pathological cases and anatomy (Saritaş, 2015; Verhoff et al., 2008). While it provides operational contributions such as calculating bone volume, implant positions, and bone angles before surgical procedures, computerized tomography also provides high-resolution soft tissue images (Siu et al., 2010). Apparatus lacrimalis is the anatomical structure that plays a role in the formation of tear secretion and the transmission of the secretion in mammals. This structure consists of five main parts. It consists of glandula lacrimalis, ductuli excretorii, canaliculus lacrimalis, saccus lacrimalis and ductus nasolacrimalis (König & Liebich, 2014; Demiraslan & Dayan, 2021). Glandula lacrimalis is located on the upper and outer sides of the eyeball. The fluid secreted in all mammals except pigs is substantial (Dyce & Wensing, 2010).

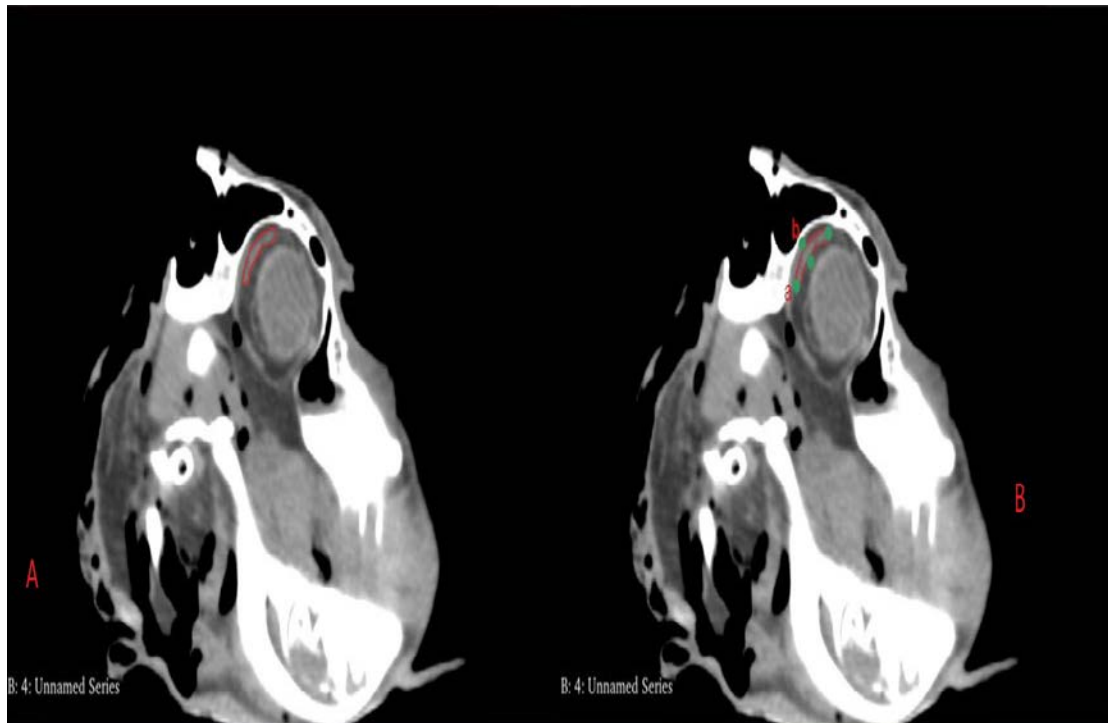
This study was carried out to obtain morphometric measurements of the glandula lacrimalis of Hamdani sheep on computed tomography images and to reveal the differences between the sexes and other species of the obtained values.

### **Materials and Methods**

Hamdani heads (five female, five male) obtained from slaughterhouses in Şırnak, Türkiye used in our study. In order to obtain CT images of the glandula lacrimalis of the Hamdani sheep, the total heads were placed in the device in an upright and symmetrical manner. The heads were scanned with a 64-detector multi-slice Siemens computer tomography device, 80 kV, 200 MA, 639 mGY, 0.625 mm section thickness. The resulting images were saved in DICOM (Digital Imaging and Communication in Medicine) format. The obtained sections were transferred to 3D-Slicer (5.02) software. Morphometric measurements were taken from the transversal, sagittal and dorsal sections of the right and left glandula lacrimalis using electronic calipers. The definitions and abbreviations of the selection points of these measurement parameters used are presented in Table 1. Measurement points on the glandula lacrimalis are presented in Figures 1, 2, and 3. SPSS 22.0 program was used in our study. An independent t-test was used to reveal statistical differences between males and females, and the Pearson correlation technique was used to examine the correlation between all measurement points.

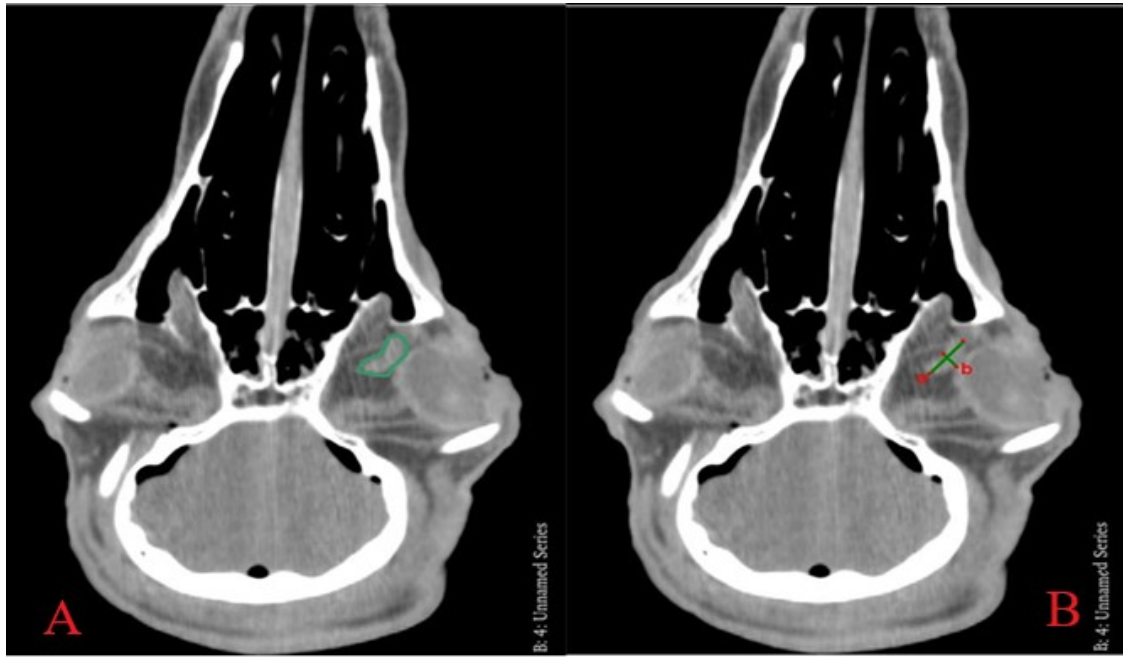
**Table 1.** Measurement points and abbreviations of glandula lacrimalis.

Direction	Description	Abbreviation
Transversal	Length: From the most lateral end of the GI gland to the most medial end	TL
	Height: Most dorsal to most ventral at widest point	TH
Dorsal	Length: distance from the most lateral end of the gland to its most medial end	DL
	Width: distance from cranial edge to caudal edge at the widest point perpendicular to length in the same image	DW
Sagittal	Width: distance from cranial edge to caudal edge at the widest point perpendicular to Height in the same image	SW
	Height: Distance from the most dorsal edge of the gland to the most ventral edge	SH

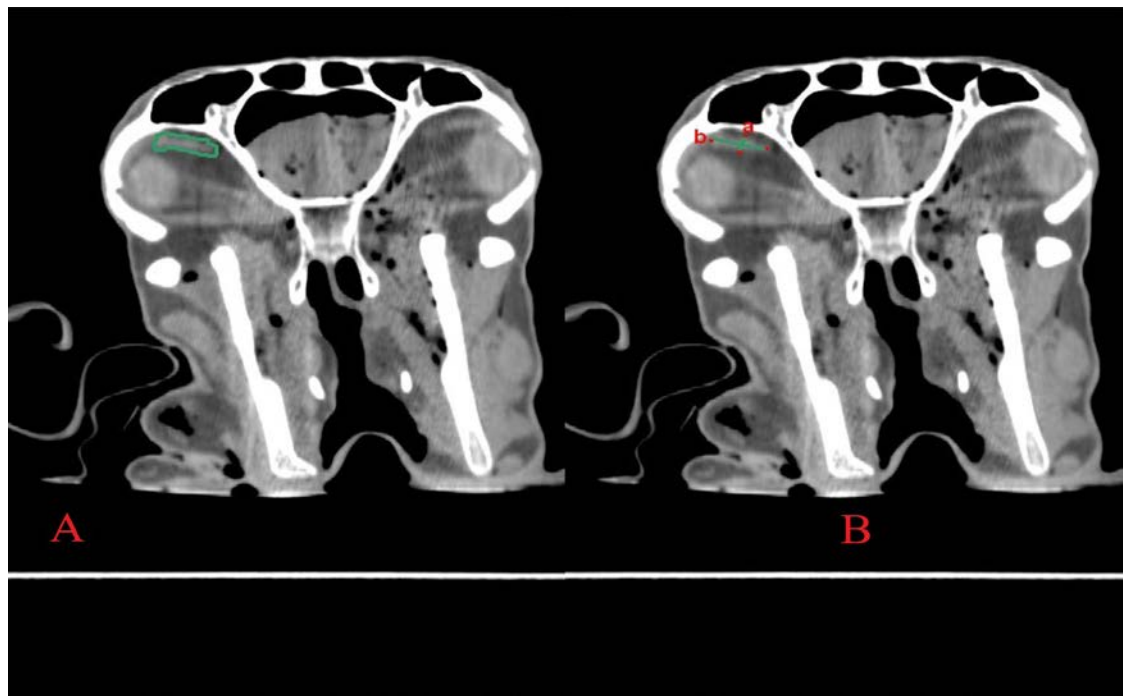


**Figure 1.** A: Outline of the glandula lacrimalis in a transversal view in Hamdani sheep. B: Measurement points of the glandula lacrimalis in the Hamdani sheep in the transversal view. a: Transversal Height, b: Transversal Length.





**Figure 2.** A: dorsal outline of the glandula lacrimalis in Hamdani sheep. B: Measurement points of glandula lacrimalis in the dorsal view in Hamdani sheep. a: Dorsal Length, b: Dorsal Width.



**Figure 3.** A: Sagittal view outline of glandula lacrimalis in Hamdani sheep. B: Measurement points of glandula lacrimalis in the dorsal view in Hamdani sheep. a: Sagittal Width, b: Sagittal Height.

## Results

Statistical differences between the sexes of the measurement points of Hamdani sheep are given in Table 2 and Table 3. Correlation values between measurements are given in Table 4. When the tables are examined, it has been determined that the glandula lacrimalis of males

is larger than that of females. When the right and left glandula lacrimalis measurements of male Hamdani sheep were examined, it was seen that the dorsal width (DW) was  $9.39 \pm 0.9$  mm on the right and  $9.38 \pm 0.20$  mm on the left, the sagittal Height was  $4.84 \pm 0.5$  mm on the right and  $4.40 \pm 0.20$  mm on the left, and it was found to be statistically significant ( $P < 0.05$ ). When the right and left glandula lacrimalis measurements of female Hamdani sheep were examined, dorsal length (DL) was  $14.14 \pm 0.20$  units on the right and  $14.42 \pm 0.78$  mm on the left, dorsal width (DW) was  $8.25 \pm 0.17$  mm on the right and  $8.40 \pm 0.05$  mm on the left ( $P < 0.01$ ). Sagittal Height was measured as  $3.10 \pm 0.8$  mm on the right and  $4.14 \pm 0.6$  mm on the left, and it was found to be statistically significant ( $P < 0.05$ ). When the correlation table is examined, there is a strong positive correlation between the measurement parameters TH-TL, DW-TL, DW-TH, SW-TL, SW-TH, SW-DL, and SW-DW ( $P < 0.01$ ). There was a positive correlation between DL-TL, DL-TW, DW-DL, and SW-SH measurement parameters ( $P < 0.05$ ).

**Table 2.** Descriptive statistics and homotypic variations of biometric parameters of glandula lacrimalis according to male Hamdani sheep obtained using computed tomography images.

	Direction	N	Mean (mm)	Standard Deviation	P
<b>TL</b>	Right	5	15.71	0.17	NS
	Left	5	15.55	0.30	
<b>TH</b>	Right	5	4.75	0.15	NS
	Left	5	4.57	0.12	
<b>DL</b>	Right	5	15.47	0.04	NS
	Left	5	15.32	0.22	
<b>DW</b>	Right	5	9.39	0.09	*
	Left	5	9.38	0.20	
<b>SH</b>	Right	5	4.84	0.05	*
	Left	5	4.40	0.20	
<b>SW</b>	Right	5	9.68	0.23	NS
	Left	5	9.47	0.25	

TL: Transversal Length, TH: Transversal Height, DL: Dorsal Length, DW: Dorsal Width, SH: Sagittal Height, SW: Sagittal Width.

\*:  $P < 0.05$ , NS: No Significant.



**Table 3.** Descriptive statistics of biometric parameters of glandula lacrimalis according to female Hamdani ewes obtained using computed tomography images.

	Direction	N	Mean	Standard Deviation	P
<b>TL</b>	Right	5	13.77	0.56	NS
	Left	5	13.80	0.38	
<b>TH</b>	Right	5	3.27	0.40	NS
	Left	5	3.25	0.07	
<b>DL</b>	Right	5	14.14	0.21	***
	Left	5	14.42	0.78	
<b>DW</b>	Right	5	8.25	0.17	**
	Left	5	8.40	0.06	
<b>SH</b>	Right	5	3.10	0.08	*
	Left	5	4.14	0.67	
<b>SW</b>	Right	5	8.24	0.18	NS
	Left	5	8.44	0.17	

TL: Transversal Length, TH: Transversal Height, DL: Dorsal Length, DW: Dorsal Width, SH: Sagittal Height, SW: Sagittal Width.

\*: P<0.05, \*\*: P<0.01, \*\*\*P<0.001, NS: No Significant.

**Table 4.** Correlation between biometric measurement points in Hamdani sheep.

	TL	TU	DL	DW	SH	SW
<b>TL</b>	1					
<b>TU</b>	0.92**	1				
<b>DL</b>	0.73*	0.78*	1			
<b>DW</b>	0.88**	0.92**	0.76*	1		
<b>SH</b>	0.57	0.54	0.49	0.59	1	
<b>SW</b>	0.89**	0.88**	0.80**	0.91**	0.70*	1

TL: Transversal Length, TH: Transversal Height, DL: Dorsal Length, DW: Dorsal Width, SH: Sagittal Height, SW: Sagittal Width.

Green: P<0.01, Yellow: P<0.05, Red: P>0.05.

### Discussion

This is the first study to determine the morphometric measurement values of right and left glandula lacrimalis in female and male animals using computed tomography in Hamdani sheep. Measurement values of glandula lacrimalis have been evaluated in many studies in terms of sexual dimorphism and homotypic variations in many mammals (Cabral et al., 2005; Gedar et al., 2018; Güngör and Urfalıoğlu, 2019; Nawaz et al., 2020; Park et al., 2016; Zwingenberger et al., 2014). In the study, it was determined that the morphometric values of glandula lacrimalis

of Hamdani sheep were higher in males than in females. In addition, when the measurement parameters are examined in terms of homotypic variations, it has been determined that the right side glandula lacrimalis measurement values are generally higher than the left side. In the study conducted by Demircioğlu & Yılmaz (2019) on Awassi sheep, it was observed that the right bulbus oculi were larger at some measurement points, while the left bulbus oculi were larger at some measurement points.

Yılmaz (2021), in his study on Van cats, reported that glandula lacrimalis is larger in males than females, and the right gland is larger than the left gland. Abdelbaset-Ismail et al., (2022) found that while the total length was  $16.09 \pm 1.6$  mm in ultrasound, it was  $25.1 \pm 3.9$  mm in macro measurement in his study, in which he compared the ultrasonographic images and macroscopic measurements of the glaucoma of donkeys. In the study, it was observed that the transversal length was  $15.80 \pm 0.37$  mm at the highest and the highest dorsal length was  $15.47 \pm 0.04$  mm. When studies were compared, it was seen that donkeys had a larger glandula lacrimalis than Hamdani sheep in ultrasound and macroscopic measurements. Alsafy, (2010) found that the length in camels, donkeys, and goats was 1.7-1.9 cm, 2.5-2.8 cm in goats, and 3.2 cm in donkeys. When the Hamdani sheep were examined, it was seen that while they were close to the camel, they were smaller than the glandula lacrimalis lengths of the goats and donkeys. Zwingenberger et al. (2014), in the study of dogs, reported the length as  $11.61 \pm 1.98$  mm in gross anatomical measurement and  $9.35 \pm 2.34$  mm in computerized tomography measurement, with measurements taken on macro-anatomical and computerized tomography images. Glandula lacrimalis of Hamdani sheep was found to have a larger gland than dogs in measurements taken from both males and females on computed tomography images. Abdalla et al. (1970) reported the transversal length as 40 mm and the sagittal width as 20 mm in their study on humped camels. It was seen that the transversal length and sagittal width measurements of males in Hamdani sheep were smaller than those of humped camels.

### **Conclusion**

As a result, the statistical differences between the sexes of the measurement parameters were taken from the glandula lacrimalis of Hamdani sheep on computed tomography images were revealed. This study will contribute to the studies on anatomical, pathological and surgical clinical sciences of sheep.

### **Financial Support**

This research received no grant from any funding agency/sector.

## Ethical Statement

This study was performed with the permission of the Experimental Animals Local Ethics Committee in Harran University with 2022/002/05 dated 28/03/2022 approval number.

## Conflict of Interest

The authors declared that there is no conflict of interest.

## References

- Abdalla, O., Fahmy, M.F.A., & Arnautovic, I. (1970). Anatomical study of the lacrimal apparatus of the one-humped camel. *Acta Anatomica*, 75(4), 638-650. <https://doi.org/10.1159/000143474>
- Abdelbaset-Ismail, A., Aref, M., Ezzeldein, S., Eisa, E., Gugjoo, M.B., Abdelaal, A., & Abd El Raouf, M. (2022). Ultrasound, dacryocystorhinography and morphological examination of normal eye and lacrimal apparatus of the donkey (*Equus asinus*). *Animals*, 12(2), 132. <https://doi.org/10.3390/ani12020132>
- Abdul-Rahman, F.Y., & Al-Barzinjy, Y.M.S. (2007). A study on the relationship between body weight and body dimensions of lambs at weaning and selection of Hamdani ewes for milk production. *Mesopotamia Journal of Agriculture*, 35(1), 58-67. <https://doi.org/10.33899/magrj.2007.26459>
- Kaya, T., Adapınar, B., & Özkan, R. (1997). *Temel Radyoloji Tekniği*. Nobel Kitabevi.
- Alsafy, M.A. (2010). Comparative morphological studies on the lacrimal apparatus of one humped camel, goat and donkey. *Journal of Applied Biological Sciences*, 4, 49-53. <https://doi.org/10.1159/000143474>
- Baykal, B., & Oyar O. (2003). *Tıbbi Görüntüleme Fiziği*. Rekmay Ltd Şti.
- Bingöl, E., & Bingöl, M. (2015). The growth of lambs and body measurement traits of Hamdani ewes. *Yüzüncü Yıl Üniversitesi Tarım Bilimleri Dergisi*, 25(2), 200-206.
- Capello, V., & Cauduro, A. (2008). Clinical technique: Application of computed tomography for diagnosis of dental disease in the rabbit, guinea pig and chinchilla. *Journal of Exotic Pet Medicine*, 17, 93-101. <https://doi.org/10.1053/j.jepm.2008.03.006>
- Cabral, V., Laus, J.L., Dagli, M., Pereira, G.T., Talieri, I.C., Monteiro, E., & Mamede, F.V. (2005). Canine lacrimal and third eyelid superficial glands macroscopic and morphometric characteristics. *Ciencia Rural*, 35, 391-397. <https://doi.org/10.1590/S0103-84782005000200023>
- Demiraslan, Y., & Dayan, O. (2021). *Veteriner Sistemik Anatomi*. Nobel Kitabevi.
- Demircioğlu, İ., & Yılmaz, B. (2019). İvesi Koyunlarda (*Ovis aries*) bulbus oculinin makroanatomik ve morfometrik yapısı. *Dicle Üniversitesi Veteriner Fakültesi Dergisi*, 12(2), 108-111.
- Dyce, K.M., & Wensing, C.J.G. (2010). *Veterinary Anatomy*. Elsevier.
- Gedar-Totuk, O.M., Kalkay, A.B., Kabadayı, K., Demir, M.K., & Barut, C. (2018). Evaluation of lacrimal gland dimensions with MR imaging in a Turkish population sample. *International Journal of Morphology*, 36, 1431-1438.
- Güngör, G., & Urfalioğlu, S. (2019). Assessment of lacrimal gland volume with computed tomography in a Turkish population. *Black Sea Journal of Health Science*, 2, 5-8.
- König, H.E., & Liebich, H.G. (2014). *Veterinary Anatomy of Domestic Mammals*. Thieme.
- Nawaz, S., Lal, S., Butt, R., Ali, M., Shahani, B., & Dadlani, A. (2020). Computed tomography evaluation of normal lacrimal gland dimensions in the adult Pakistani population. *Cureus*, 12(3), e7393. <https://doi.org/10.7759/cureus.7393>
- Öztürk Y (1998): *Van ve yöresinde Hamdani koyunlarının verikleri ve morfolojik özelliklerinin araştırılması*. Doktora Tezi. Yüzüncü Yıl Üniversitesi Sağlık Bilimleri Enstitüsü, Van.
- Park, S.A., Taylor, K.T., Zwingerberger, A.L., Reilly, C.M., Toupadakis, C.A., Marfurt, C.F., Good, K.L., & Murphy, C.J. (2016). Gross anatomy and morphometric evaluation of the canine lacrimal and third eyelid glands. *Veterinary Ophthalmology*, 19, 230-236. <https://doi.org/10.1111/vop.12288>
- Sarıtaş, M.Z. (2015). *Adli tıp uygulamalarında 3D (üç boyutlu) teknolojinin kullanımı*. Doktora Tezi. Pamukkale Üniversitesi Sağlık Bilimleri Enstitüsü, Pamukkale.
- Siu, A.S.C., Chu, F.C.S., Li, T.K.L., Chow, T.W., & Deng, F. (2010). Imaging modalities for preoperative assessment in dental implant therapy: An overview. *Hong Kong Dental Journal*, 7, 23-30.
- Tuncel, E. (2007). *Klinik Radyoloji: Radyolojik Yöntemler*. (2nd ed.). Nobel & Güneş Tıp Kitabevi.

- Verhoff, M.A., Ramsthaler, F., Krähahn, J., Deml, U., Gille, R. J., Grabherr, S., Michael, J.T., & Kreutz, K. (2008). Digital forensic osteology possibilities in cooperation with the Virtopsy® project. *Forensic Science International*, 174, 152-156. <https://doi.org/10.1016/j.forsciint.2007.03.017>
- Yılmaz, O. (2021). Morphometric examination of the lacrimal gland from computed tomography images in Van cats. *Atatürk Üniversitesi Veteriner Bilimleri Dergisi*, 16(1), 16-24.
- Zwingenberger, A.L., Park, S.A., Murphy, C.J., (2014). Computed tomographic imaging characteristics of the normal canine lacrimal glands. *BMC Veterinary Research*, 10, 116. <https://doi.org/10.1186/1746-6148-10-116>

## The effect of pentoxifylline administration at different doses on hematological and biochemical parameters in sheep

Duygu DURNA CORUM<sup>1,a,\*</sup>, Orhan CORUM<sup>1,b</sup>, Ayse ER<sup>2,c</sup>, Kamil UNEY<sup>2,d</sup>

<sup>1</sup>Hatay Mustafa Kemal University, Faculty of Veterinary Medicine, Department of Pharmacology and Toxicology, Hatay, Türkiye; Selçuk University, Faculty of Veterinary Medicine, Department of Pharmacology and Toxicology, Konya, Türkiye.

<sup>a</sup>ORCID: <https://orcid.org/0000-0003-1567-991X>; <sup>b</sup>ORCID: <https://orcid.org/0000-0003-3168-2510>; <sup>c</sup>ORCID: <https://orcid.org/0000-0002-6900-0055>; <sup>d</sup>ORCID: <https://orcid.org/0000-0002-8674-4873>

\*Corresponding author: [ddurnacorun@gmail.com](mailto:ddurnacorun@gmail.com)

Received 23.11.2022 - Accepted 30.12.2022 - Published 31.12.2022

**Abstract:** The aim of the present study was to determine the effect of administration of single increasing doses of pentoxifylline on biochemical and hematological parameters in sheep. The study was carried out on six healthy Merino sheep. Pentoxifylline was given to sheep intravenously at doses of 10, 20, and 40 mg/kg. Blood samples were taken from the jugular vein before (0 hour) and after (12 hour) pentoxifylline administration. Biochemical parameters such as creatine kinase, albumin, blood urea nitrogen, creatinine, alkaline phosphatase, aspartate aminotransferase, alanine aminotransferase, gamma glutamyltransferase, cholesterol, triglyceride, total bilirubin and total protein were measured in autoanalyzer. Hematological parameters such as hemoglobin, hematocrit, platelet, red blood cells and white blood cells were determined in blood cell counter. Hematological parameters did not alter between the groups, although it was found that the hematocrit value in 20 mg/kg dosage group dropped. There were no significant changes in biochemical values following administration of the pentoxifylline at all dose level. These results show that pentoxifylline does not cause significant changes in biochemical and hematological parameters in sheep after intravenous administration at different doses. However, the safety study on pentoxifylline is also necessary for multiple ascending doses in sheep.

**Keywords:** Biochemical, hematological, sheep, pentoxifylline.

### Koyunlarda farklı dozlarda pentoksifilin uygulamasının hematolojik ve biyokimyasal parametreler üzerine etkisi

**Özet:** Bu araştırmanın amacı, koyunlarda artan tek doz pentoksifilin uygulamasının hematolojik ve biyokimyasal değerler üzerine etkisini belirlemektir. Araştırma 6 baş sağlıklı Merinos koyun üzerinde gerçekleştirildi. Pentoksifilin koyunlara 10, 20 ve 40 mg/kg dozlarında intravenöz olarak uygulandı. Kan örnekleri pentoksifilin uygulaması öncesi (0. saat) ve uygulama sonrası 12. saatte juguler venden alındı. Kreatin kinaz, albümin, kan üre nitrojen, kreatinin, alkalın fosfataz, aspartat aminotransferaz, alanin aminotransferaz, gama-glutamil transpeptidaz, kolesterol, trigliserit, total bilirubin ve total protein gibi biyokimyasal parametreler otoanalizör cihazında ölçüldü. Hemoglobin, hematokrit, trombosit, alyuvar ve akyuvar gibi hematolojik parametreler ise kan hücresi sayım cihazında belirlendi. Hematolojik parametrelerde gruplar arasında fark bulunmazken, 20 mg/kg doz grubunda hematokrit değerinin düştüğü belirlendi. Tüm doz gruplarında pentoksifilin uygulaması sonrası biyokimyasal parametrelerde önemli bir değişiklik görülmedi. Bu sonuçlar, farklı dozlarda intravenöz yolla uygulama sonrası pentoksifilin koyunlarda hematolojik ve biyokimyasal parametrelerde önemli değişikliklere neden olmadığını göstermektedir. Bununla birlikte, koyunlarda çoklu artan dozlar içinde pentoksifilin güvenlik çalışmalarının yapılması gereklidir.

**Anahtar kelimeler:** Biyokimyasal, hematolojik, koyun, pentoksifilin.

## Introduction

Pentoxifylline is a non-selective phosphodiesterase inhibitor used especially in the treatment of circulatory disorders (Uney et al., 2019). Pentoxifylline is preferred in circulatory disorders because it reduces the viscosity of the blood and provides oxygenation of peripheral tissues. In addition, it has anti-inflammatory and antioxidant effects (Corum et al., 2018; Sezik et al., 2020). Pentoxifylline is recommended for the treatment of lameness, vasculitis, collagen disorders, endotoxemia, septicemia, diabetic disorders and cancer in humans (Corum et al., 2019; Samlaska & Winfield, 1994). It has been reported that pentoxifylline can be used in the veterinary field in cases such as vasculitis, atopic dermatitis, dermatomyositis, contact allergy and systemic lupus erythematosus in dogs, cutaneous vasculitis in horses, laminitis, endometritis-placentitis, septicemia in foals, and vasculitis, laminitis, endometritis-placentitis in cattle (Sykes & Papich, 2014; Uney et al., 2019).

Although pentoxifylline is not approved in sheep, it has been used extra-label at different doses (10 to 60 mg/kg) in conditions such as septic shock, endotoxemia, preeclampsia, and bronchopulmonary injury (Chalmeh et al., 2016; Ogura et al., 1994; Sigurdsson & Youssef, 1993; Tálosi et al., 2001). In extra-label use, adverse effects should be assessed for effective and safe use of drugs. Biochemical and hematological parameters may be relevant in assessing adverse drug effects (Corum et al., 2015; Corum et al., 2016). However, no information was found about the effect of pentoxifylline on biochemical and hematological values in sheep. This study was conducted to assess the effect of pentoxifylline on biochemical and hematological parameters in sheep following a single intravenous injection of 10, 20, and 40 mg/kg.

## Materials and Methods

**Animals:** The investigation was conducted on six female Merino sheep ( $57 \pm 4$  kg of body weight and  $1.6 \pm 0.3$  years old) defined to be healthy by general clinical examination, biochemistry panel, and complete blood count. All animals were housed in individual pens throughout the study and were fed with commercial feed, and water was given *ad-libitum*. The experiment was approved by The Ethics Committee of the Faculty of Veterinary Medicine (University of Selcuk, Konya, Turkiye).

**Experimental design:** The study consisted of three periods with a 15-day washout period between treatments according to the crossover design. For drug administration to sheep, the analytical standard of pentoxifylline (Tokyo Chemical Industry, Europe) was dissolved with physiological saline (50 mg/mL). Pentoxifylline was administered to sheep via rapid intravenous (1 min) bolus injection at doses of 10, 20 and 40 mg/kg. Blood samples were collected into gel-containing tubes for biochemical analyses (3 mL) and into EDTA-containing

tubes for hematological analyses (2 mL) through jugular venipuncture (jugular vein) prior to pentoxifylline administration (0 h, control) and at 12 h after the pentoxifylline administration. Hematological parameters were analyzed immediately after taking blood samples. The blood samples collected for biochemical analyzes were centrifuged at 4.000 x g for 10 minutes, and the serum samples obtained were stored at  $-80^{\circ}\text{C}$  until the time of analysis. During the investigation, animals were also clinically observed.

**Hematological and biochemical analyzes:** The hemocell counter (Auto Hematology Analyzer, Shenzhen Mindray Bio-Medical Electronics, BC-2800, China) measured hematological characteristics such as hemoglobin, hematocrit, platelet, red blood cell (RBC) and white blood cell (WBC). Autoanalyzers (ILab-300 bioMerieux Diagnostics, Milan, Italy) were used to measure biochemical values such as creatine kinase (CK), albumin, blood urea nitrogen (BUN), creatinine, alkaline phosphatase (ALP), aspartate aminotransferase (AST), alanine aminotransferase (ALT), gamma glutamyltransferase (GGT), cholesterol, triglyceride, total bilirubin (TBIL) and total protein (TP).

**Statistical analysis:** Hematological and biochemical parameters were presented as mean $\pm$ SD. Shapiro-Wilk and Levene tests were used to determine the homogeneity and normality of the data distribution. The paired-t test was used to statistical analysis within the group. For the evaluation between groups, one-way analysis of variance (ANOVA) and post hoc Tukey tests were used. SPSS 19.0. (IBM Corp, Armonk, NY) statistics program was used for the statistical analysis. Statistical significance was considered as  $P < 0.05$ .

## Results

No clinical adverse effects were observed in animals in the 10 and 20 mg/kg dose groups. In the 40 mg/kg dose group, tachycardia and hypersalivation were observed and the animals were agitated for approximately 4 hours. Hematological and biochemical parameters in sheep following intravenous administrations of pentoxifylline at different doses are presented in Table 1 and Table 2, respectively. There was no difference in biochemical parameters (BUN, creatinine, albumin, ALT, ALP, AST, cholesterol, CK, GGT, TBIL, TP, and triglyceride) in the in-group and between-group comparisons ( $P > 0.05$ ). While there was no difference between the groups in hematological parameters ( $P > 0.05$ ), it was determined that the hematocrit value decreased in the 20 mg/kg dose group ( $P < 0.05$ ).



**Table 1.** Hematological parameters in sheep (n=6) following single intravenous administrations of pentoxifylline at doses of 10, 20 and 40 mg /kg (mean  $\pm$  SD).

Parameters	10 mg/kg		20 mg/kg		40 mg/kg	
	0 h	12 h	0 h	12 h	0 h	12 h
WBC (*10 <sup>9</sup> /L)	7.15 $\pm$ 0.76	7.68 $\pm$ 1.09	7.29 $\pm$ 1.13	7.40 $\pm$ 1.06	7.48 $\pm$ 1.05	7.28 $\pm$ 1.33
RBC (*10 <sup>12</sup> /L)	11.29 $\pm$ 1.65	11.62 $\pm$ 1.45	10.99 $\pm$ 0.89	11.07 $\pm$ 0.84	10.69 $\pm$ 0.98	11.63 $\pm$ 1.73
HGB (g/dL)	10.12 $\pm$ 1.73	10.23 $\pm$ 1.34	11.17 $\pm$ 1.25	10.40 $\pm$ 1.00	9.52 $\pm$ 1.17	10.02 $\pm$ 1.79
HCT (%)	31.77 $\pm$ 4.64	32.87 $\pm$ 4.21	38.50 $\pm$ 3.15	31.45 $\pm$ 3.28*	30.53 $\pm$ 4.37	31.80 $\pm$ 3.75
Platelet (*10 <sup>9</sup> /L)	240.17 $\pm$ 51.57	257.33 $\pm$ 51.15	238.00 $\pm$ 42.31	243.17 $\pm$ 37.08	239.50 $\pm$ 31.73	246.33 $\pm$ 43.79

\*; The value is statistically different from the 0 h in the same group.

WBC; white blood cells, RBC; red blood cells, HGB; hemoglobin, HCT; hematocrit.

**Table 2.** Biochemical parameters in sheep (n=6) following single intravenous administrations of pentoxifylline at doses of 10, 20 and 40 mg/kg (mean  $\pm$  SD).

Parameters	10 mg/kg		20 mg/kg		40 mg/kg	
	0 h	12 h	0 h	12 h	0 h	12 h
ALB (g/dL)	3.44 $\pm$ 0.30	3.40 $\pm$ 0.29	3.54 $\pm$ 0.27	3.51 $\pm$ 0.41	3.57 $\pm$ 0.41	3.40 $\pm$ 0.36
ALP (U/L)	147.67 $\pm$ 32.72	156.83 $\pm$ 29.69	159.33 $\pm$ 17.10	159.83 $\pm$ 12.67	146.00 $\pm$ 34.09	164.17 $\pm$ 30.86
ALT (U/L)	16.50 $\pm$ 3.56	16.67 $\pm$ 2.66	16.17 $\pm$ 3.31	16.00 $\pm$ 2.53	17.50 $\pm$ 2.59	15.33 $\pm$ 3.88
AST (U/L)	151.50 $\pm$ 38.38	151.50 $\pm$ 35.19	139.17 $\pm$ 46.76	145.83 $\pm$ 39.46	146.67 $\pm$ 46.07	154.83 $\pm$ 33.44
BUN (mg/dL)	21.93 $\pm$ 3.33	20.78 $\pm$ 2.58	20.73 $\pm$ 2.05	20.68 $\pm$ 3.49	21.25 $\pm$ 3.11	21.17 $\pm$ 3.22
CHOL (mg/dL)	52.83 $\pm$ 8.80	53.00 $\pm$ 9.19	50.17 $\pm$ 8.68	50.83 $\pm$ 9.60	53.50 $\pm$ 7.42	54.00 $\pm$ 8.29
CK (U/L)	168.67 $\pm$ 38.30	169.67 $\pm$ 22.21	176.67 $\pm$ 38.26	178.83 $\pm$ 32.36	177.83 $\pm$ 32.39	187.00 $\pm$ 36.52
CRE (mg/dL)	0.70 $\pm$ 0.10	0.70 $\pm$ 0.12	0.70 $\pm$ 0.12	0.69 $\pm$ 0.11	0.75 $\pm$ 0.10	0.73 $\pm$ 0.12
GGT (U/L)	57.50 $\pm$ 6.09	57.17 $\pm$ 7.33	57.17 $\pm$ 8.13	59.00 $\pm$ 7.67	59.50 $\pm$ 9.71	59.17 $\pm$ 7.19
TBIL (mg/dL)	0.09 $\pm$ 0.04	0.07 $\pm$ 0.03	0.08 $\pm$ 0.04	0.07 $\pm$ 0.05	0.09 $\pm$ 0.07	0.06 $\pm$ 0.04
TP (g/dL)	6.57 $\pm$ 0.25	6.58 $\pm$ 0.26	6.46 $\pm$ 0.34	6.55 $\pm$ 0.33	6.73 $\pm$ 0.35	6.71 $\pm$ 0.22
TRIG (mg/dL)	15.17 $\pm$ 4.62	18.00 $\pm$ 2.37	16.67 $\pm$ 4.80	18.00 $\pm$ 3.29	19.17 $\pm$ 4.07	18.17 $\pm$ 3.37

ALB; albumin, ALP; alkaline phosphatase, ALT; alanine aminotransferase, AST; aspartate aminotransferase, BUN; blood urea nitrogen, CHOL; cholesterol, CK; creatine kinase, CRE; creatinine, GGT; gamma glutamyltransferase, TBIL; total bilirubin, TP; total protein, TRIG; triglyceride.

## Discussion

Pentoxifylline is used in human and veterinary medicine to promote microcirculation and to provide peripheral oxygenation (Sezik et al., 2020). In experimental studies in sheep, pentoxifylline was used in the dose range of 10-60 mg/kg (Chalmeh et al., 2016; Ogura et al., 1994; Sigurdsson & Youssef, 1993; Tálosi et al., 2001). However, the use of drugs in increased doses may cause adverse effects. Biochemical and hematological values are used to judge the effects of medications on physiological and pathological states (Corum et al., 2022). The biochemical values (BUN, creatinine, albumin, ALT, ALP, AST, cholesterol, CK, GGT, TBIL, TP, and triglyceride) indicate the functionality of the kidney, liver, muscle, heart, and lipid metabolism. Hematological parameters (hemoglobin, WBC, RBC, hematocrit, and platelet) reflect fluid-electrolyte balance situation and bone-marrow functions (Kerr, 2002a; Kerr, 2002b; Turgut, 2000).

In this study, when different dose groups of pentoxifylline were compared, there was no difference in hematological parameters. In the in-group comparison, it was seen that the hematocrit value decreased in the 20 mg/kg dose group. However, this change was within the reference values specified in merino sheep (Lepherd et al., 2009). Similarly, oral (30 mg/kg) and intravenous (8 mg/kg) administration of pentoxifylline did not cause any change in hematological parameters in dogs (Rees et al., 2003). Intravenous administration of pentoxifylline (10, 20 and 40 mg/kg) in goats caused changes in WBC and hemoglobin (Coskun et al., 2022). It has been reported that pentoxifylline increases the level of hemoglobin in hemodialysis-induced anemia by suppressing the production of pro-inflammatory cytokines, which inhibit the efficacy of erythropoietin (Cooper et al., 2004; Shahbazian et al., 2017). It also increased the value of hematocrit in humans (Antunes et al., 2008; Golbasi et al., 2003).

Intravenous administration of pentoxifylline (10, 20 and 40 mg/kg doses) to sheep did not cause any difference in biochemical parameters. It has been reported that there was no difference in biochemical parameters following intravenous administration of pentoxifylline at a dose of 10 mg/kg to cattle and 8.5 mg/kg to horses (Liska et al., 2006; Uney et al. 2019). However, administration of pentoxifylline at a 10, 20 and 40 mg/kg doses to goats caused significant changes in biochemical (BUN, ALT, AST, TP, GGT, creatinine, albumin) values (Coskun et al., 2022). In addition, pentoxifylline decreased AST, ALT, and GGT levels in non-dyslipidemic and non-alcoholic human with fatty liver disease, and BUN and creatinine values in male rats (Cioboată et al., 2017; El-Haggar & Mostafa 2015; Jalili et al., 2019).

While no clinical side effects were observed at 10 and 20 mg/kg doses of pentoxifylline in sheep, tachycardia and hypersalivation and transient agitation were observed at 40 mg/kg doses. The rapid (1 min) intravenous bolus injection of pentoxifylline at 40 mg/kg dose may

cause these side effects. In goats, administration of pentoxifylline at the same dose and route did not cause any clinical changes (Coskun et al., 2022). Pentoxifylline caused transient hypersalivation and discomfort in cattle (10 mg/kg, intravenous), increased heart rate, sweating, and fasciculations in muscles in horses (8.5 mg/kg, intravenous), and deep respiration, eye closing, and lethargy in chickens (100 mg/kg, intravenous and oral) (De Boever et al. 2005, Liska et al., 2006, Uney et al., 2019).

### **Conclusion**

This study showed that pentoxifylline did not cause significant changes in biochemical and hematological values in sheep after intravenous administration at 10, 20 and 40 mg/kg doses. However, pentoxifylline caused clinical adverse effects at 40 mg/kg doses. Therefore, the slow bolus injection (>1 min) or continuous infusion of pentoxifylline at 40 mg/kg dose would likely decrease these adverse effects. However, in sheep, the safety study on pentoxifylline is also necessary for multiple ascending doses as pentoxifylline is often used in repeated doses.

### **Financial Support**

This research received no grant from any funding agency/sector.

### **Ethics Statement**

This study was confirmed by the Ethics Committee of the Faculty of Veterinary Medicine of Selcuk University (Konya/Türkiye) (2015/07).

### **Conflict of Interest**

The authors declared that there is no conflict of interest.

### **Acknowledgements**

The study was presented in the form of abstract as poster presentation in the 1th International Congress on Advances in Veterinary Sciences & Technics, August 25-29, 2016.

### **References**

- Antunes, S.A., Teixeira, M.C.B., & Júnior, A.G. (2008). Pentoxifylline effects on the resistant anemia to erythropoietin in hemodialysis patients. *Revista Brasileira de Hematologia e Hemoterapia*, 30(4), 303-308.
- Chalmeh, A., Rahmani Shahraki, A., Heidari, S.M., Badié, K., Paurjafar, M., Nazifi, S., & Zamiri, M.J. (2016). The comparative efficacy of tyloxapol versus pentoxifylline against induced acute phase response in an ovine experimental endotoxemia model. *Inflammopharmacology*, 24, 59-64.
- Cioboată, R., Găman, A., Trașcă, D., Ungureanu, A., Docea, A.O., Tomescu, P., Gherghina, F., Arsene, A.L., Badiu, C., Tsatsakis, A.M., Spandidos, D.A., Drakoulis, N., & Călina, D. (2017). Pharmacological

- management of non-alcoholic fatty liver disease: Atorvastatin versus pentoxifylline. *Experimental and Therapeutic Medicine*, 13, 2375-2381.
- Cooper, A., Mikhail, A., Lethbridge, M.W., Kemeny, D.M., & Macdougall, I.C. (2004). Pentoxifylline improves hemoglobin levels in patients with erythropoietin-resistant anemia in renal failure. *Journal of the American Society of Nephrology*, 15, 1877-1882.
- Corum, O., Corum, D.D., Atik, O., Er, A., & Uney, K. (2019). Pharmacokinetics of pentoxifylline and its 5-hydroxyhexyl metabolite after intravenous administration of increasing doses to sheep. *American Journal of Veterinary Research*, 80(7), 702-708.
- Corum, O., Dik, B., Bahcivan, E., Eser, H., Er, A., & Yazar, E. (2016). Cardiac safety of gamithromycin in ewes. *Eurasian Journal of Veterinary Sciences*, 32, 242-245.
- Corum, O., Er, A., Dik, B., Eser, H., Bahcivan, E., & Yazar, E. (2015). Determination of the safety of tulathromycin in sheep. *Eurasian Journal of Veterinary Sciences*, 31(3), 152-157.
- Corum, O., Ozdemir, O., Hitit, M., Corum, D.D., Coskun, D., & Er, A. (2018). Pentoxifylline may restore kanamycin-induced renal damage in rats. *Acta Scientiae Veterinariae*, 46(1), 1-7.
- Corum, O., Uney, K., Er, A., & Durna Corum, D., (2022). The effect of cefquinome on hematological and biochemical parameters following repeated subcutaneous administrations in sheep. *Veterinary Journal of Kastamonu University*, 1(1), 1-7.
- Coskun, D., Cetin, G., & Corum, O. (2022). Effect of ascending doses of pentoxifylline administration on biochemical and hematological parameters in goats. *Kocatepe Veterinary Journal*, 15(1), 63-68.
- De Boever, S., Baert, K., De Backer, P., & Croubels, S. (2005). Pharmacokinetics and oral bioavailability of pentoxifylline in broiler chickens. *Journal of Veterinary Pharmacology and Therapeutics*, 28(6), 575-580.
- El-Haggag, S.M., & Mostafa, T.M. (2015). Comparative clinical study between the effect of fenofibrate alone and its combination with pentoxifylline on biochemical parameters and liver stiffness in patients with non-alcoholic fatty liver disease. *Hepatology International*, 9, 471-479.
- Golbasi, I., Turkay, C., Timuragaoglu, A., Ozdem, S.S., Belgi, A., Akbas, H., & Bayezid, O. (2003). The effect of pentoxifylline on haemolysis in patients with double cardiac prosthetic valves. *Acta Cardiologica*, 58(5), 379-383.
- Jalili, C., Moradi, D., Roshankhah, S., & Salahshoor, M.R. (2019). Effect of pentoxifylline on kidney damage induced by nitrosamine in male rats. *Research in Pharmaceutical Sciences*, 14(1), 64-73.
- Kerr, M.G. (2002a). Clinical biochemistry. In: John Wiley & Sons (Ed.), *Veterinary laboratory medicine*, (2nd ed., pp: 50-198). Blackwell Science.
- Kerr, M.G. (2002b). Haematology, In: John Wiley & Sons (Ed.), *Veterinary Laboratory Medicine*, (2nd ed., pp: 1-68). Blackwell Science.
- Lepherd, M.L., Canfield, P.J., Hunt, G.B., Bosward, K.L. (2009). Haematological, biochemical and selected acute phase protein reference intervals for weaned female Merino lambs. *Australian Veterinary Journal*, 87(1), 5-11.
- Liska, D.A., Akucewich, L.H., Marsella, R., Maxwell, L.K., Barbara, J.E., & Cole, C.A. (2006). Pharmacokinetics of pentoxifylline and its 5-hydroxyhexyl metabolite after oral and intravenous administration of pentoxifylline to healthy adult horses. *American Journal of Veterinary Research*, 67(9), 1621-1627.
- Ogura, H., Cioffi, W.G., Okerberg, C.V., Johnson, A.A., Guzman, R.F., Mason, A.D., & Pruitt, B.A. (1994). The effects of pentoxifylline on pulmonary function following smoke inhalation. *Journal of Surgical Research*, 56, 242-250.
- Rees, C.A., Boothe, D.M., Boeckh, A., Wilkie, S., Esparza, T., & Green, R. (2003). Dosing regimen and hematologic effects of pentoxifylline and its active metabolites in normal dogs. *Veterinary Therapeutics: Research in Applied Veterinary Medicine*, 4(2), 188-196.
- Samlaska, C.P., & Winfield, E.A. (1994). Pentoxifylline. *Journal of the American Academy of Dermatology*, 30(4), 603-621.
- Sezik, M., Koker, A., Ozmen, O., Halıguur, M., Kasıkcı, D., Aydoğan, A., & Ozatik, O. (2020). Antenatal pentoxifylline therapy to prevent endotoxin induced fetal injury in the preterm goat model. *Turkish Journal Of Obstetrics And Gynecology*, 17, 259-269.
- Shahbazian, H., Ghorbani, A., Zafar-Mohtashami, A., Balali, A., AleAli, A., & Lashkarara, G.R. (2017). Administration of pentoxifylline to improve anemia of hemodialysis patients. *Journal of Renal Injury Prevention*, 6(1), 61-64.
- Sigurdsson, G.H., & Youssef, H. (1993). Effects of pentoxifylline on hemodynamics, gas exchange and multiple organ platelet sequestration in experimental endotoxic shock. *Acta Anaesthesiol Scand*, 37, 396-403.
- Sykes, J.E., & Papich, M.G. (2014). Antiviral and immunomodulatory drugs. In: J.E. Sykes. (Ed.), *Canine and feline infectious diseases*. (1st ed., pp.54-65). Saunders.
- Tálosi, G., Németh, I., & Pintér, S. (2001). Inhibitory effects of methylxanthines on the preeclamptic-like symptoms in ewes. *European Journal of Obstetrics & Gynecology and Reproductive Biology*, 99, 25-32.
- Turgut, K. (2000). Liver tests. In: *Veterinary Clinic Laboratory Diagnosis*, (1st ed., pp.202-257). Bahcivanlar Press.
- Uney, K., Tras, B., Corum, O., Yildiz, R., & Maden, M. (2019). Pharmacokinetics of pentoxifylline and its 5-hydroxyhexyl metabolite following intravenous administration in cattle. *Tropical Animal Health and Production*, 51(2), 435-441.

## Diaphragmatic hernia and its treatment in a stray dog

Cihan GÜNAY<sup>1,a</sup>, Eren POLAT<sup>1,b,\*</sup>, Aydın SAĞLIYAN<sup>1,c</sup>

<sup>1</sup>Firat University, Faculty of Veterinary Medicine, Department of Surgery, Elazığ, Türkiye.

<sup>a</sup>ORCID: <https://orcid.org/0000-0002-0476-6164>; <sup>b</sup>ORCID: <https://orcid.org/0000-0002-3999-1310>; <sup>c</sup>ORCID: <https://orcid.org/0000-0002-8226-0740>

\*Corresponding author: [erenpolat@firat.edu.tr](mailto:erenpolat@firat.edu.tr)

Received 01.10.2022 - Accepted 02.12.2022 - Published 31.12.2022

**Abstract:** In this case report, it was aimed to share a case of diaphragmatic hernia and its treatment in a 5-month-old female stray dog. In the clinical examination of the patient, dyspnea and ecchymosis in the mucous membranes were detected, while the diaphragm border was not clearly seen in the radiographic examination. The dog was diagnosed with diaphragmatic hernia. It was determined that the dog who underwent herniorrhaphy operation recovered rapidly in the postoperative period.

**Keywords:** Canine, diaphragmatic hernia, dyspnea, herniorrhaphy, trauma.

### Bir sokak köpeğinde diyafram fıtığı ve tedavisi

**Özet:** Bu olgu sunumunda, 5 aylık, dişi bir sokak köpeğinde karşılaşılan diyafram fıtığı olgusu ve tedavisinin paylaşılması amaçlandı. Hastanın klinik muayenesinde dispne ve mukozalarda ekimoz tespit edilirken, radyografik muayenesinde diyafram sınırının belirgin şekilde görülmediği belirlendi. Köpeğe diyafram fıtığı teşhisi konuldu. Herniorafi operasyonu yapılan köpeğin postoperatif dönemde hızla iyileştiği belirlendi.

**Anahtar kelimeler:** Köpek, diyafram fıtığı, dispne, herniorafi, travma.

### Introduction

Diaphragmatic hernia is a health problem with a high mortality rate in which abdominal organs pass into the chest cavity due to ruptures in the diaphragm tissue. Diaphragmatic hernia, which is mostly caused by trauma, causes important clinical symptoms (Radlinsky & Fossum, 2013; Hunt & Johnson, 2012; Ozer et al., 2007; Park & Lee, 2018; Yaygingul et al., 2019; Zamirbekova et al., 2020). The center of the diaphragm, which has a musculotendinous structure, is more durable than its peripheral parts. Therefore, abnormal openings on the diaphragm mostly occur in the region of attachment of the diaphragm to the ribs (Zamirbekova et al., 2020).

Although diaphragmatic hernia can occur congenitally in cats and dogs, it mostly occurs due to blunt trauma (Radlinsky & Fossum, 2013; Hyun, 2004; Yaygingul et al., 2019; Zamirbekova et al., 2020). Diaphragmatic hernias are caused by 85% traumatic reasons, 5-10% congenital, 10-15% unknown reasons (Park & Lee, 2018). The most frequently herniated organs in diaphragmatic hernia cases are liver (64-82%), stomach (47-56%), omentum (26-

44%) and pancreas (4-8%). In hernias formed on the left side of the diaphragm, mostly stomach, spleen and small intestines pass into the chest cavity. In hernias that occur on the right side of the diaphragm, mostly the liver, small intestine and pancreas pass into the chest cavity (Zamirbekova et al., 2020).

In cases of diaphragmatic hernia, the severity of the symptoms may differ according to the condition of the organs displaced into the thorax. The most obvious clinical finding in patients with diaphragmatic hernia is respiratory depression due to pressure on the lungs. Cats and dogs with dyspnea and exercise intolerance due to respiratory depression usually take a dog-sitting position in order to reduce the pressure on their lungs. In cases where the stomach and intestines pass into the thorax, digestive system symptoms such as loss of appetite, vomiting, diarrhea, constipation can also be seen. On physical examination, muffled heart sounds and decreased lung sounds are detected on auscultation of the thorax, while abdominal palpation may reveal that the organs are not in the abdominal cavity. The most common laboratory findings in diaphragmatic hernia in cats and dogs are increased alanine aminotransferase activity and serum calcium concentration (Burns et al., 2013; Nikiphorou et al., 2016).

Direct and indirect radiography is required for the definitive diagnosis of diaphragmatic hernia. The most prominent radiographic findings are the absence of the diaphragm line, the silhouetted appearance of the heart, the displacement of the lungs, the presence of abdominal organs and gas in the chest cavity (Burns et al., 2013; Hyun, 2004; Nikiphorou et al., 2016; Ozer et al., 2007).

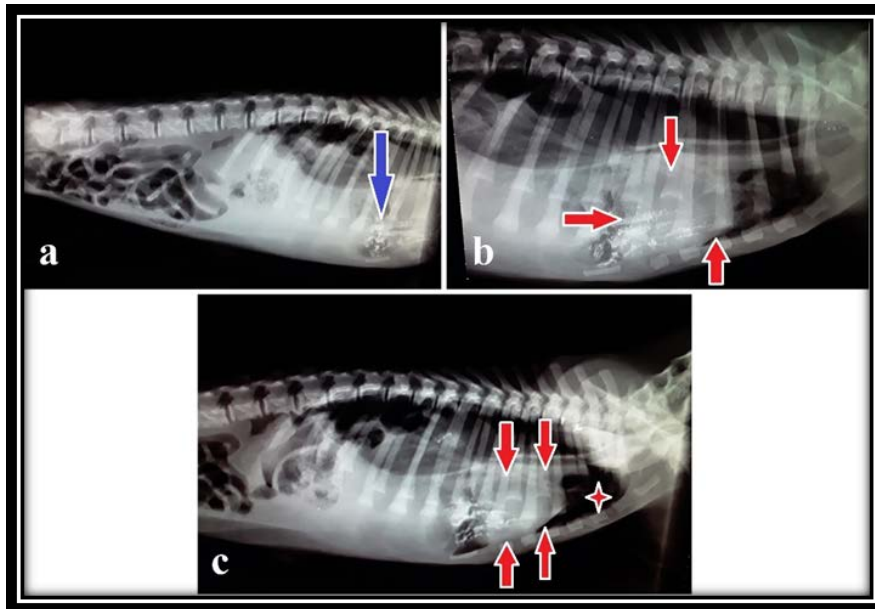
The only treatment for diaphragmatic hernias is surgery (Park & Lee, 2018; Randall, 2018; Yaygingul et al., 2019). In diaphragmatic hernia operations, first of all, the herniated organs are slowly taken back into the abdominal cavities. Then, the damage to the diaphragm is repaired with simple continuous sutures using absorbable and non-absorbable suture materials. In order to create negative air pressure in the thorax, the lungs are completely filled with air before the last suture is applied (Ozer et al., 2007).

In this case report, it was aimed to contribute to the literature and clinician veterinarians by giving information about the diagnosis, treatment and postoperative prognosis of a diaphragmatic hernia case encountered in a crossbred stray dog brought with the complaint of post-traumatic respiratory depression.

### Case Description

In this case report, a 5-month-old female and cross breed dog, who was brought to Firat University Animal Hospital Surgery Department with the complaint of respiratory distress after trauma (traffic accident), was discussed.

In the inspection examination, respiratory distress and ecchymosis of the mucous membranes were determined in the dog. It was determined that abdominal organs could not be detected in the abdominal cavity on palpation, and heart and lung sounds decreased on auscultation of the thorax. In addition, bowel sounds were detected on auscultation of the thorax. After clinical examinations, it was suspected that the dog had a diaphragmatic hernia. For the definitive diagnosis, thorax and abdomen radiographs of the dog were requested. In the radiographs taken in the LL position, it was determined that the diaphragm line could not be seen (Figure 1-a, b, c), the heart was seen in silhouette (Figure 1-b,c), and the abdominal organs were located in the thorax (Figure1-a). However, the presence of free air in the thorax was detected in the radiographic examination (Figure 1-c). Thus, the patient was definitively diagnosed with diaphragmatic hernia.



**Figure 1.** Direct radiography of the thorax and abdomen in the LL position: the diaphragm line cannot be seen (a,b,c), the view of the digestive system contents inside the thorax (blue arrow) (a), the silhouette view of the heart (red arrow) (b,c), free air in the thorax (star) (c).

It was decided to take the dog, which was diagnosed with diaphragmatic hernia, to urgent operation. First of all, the large area from the half of the sternum to the pubis was prepared for the operation. After the preparations were completed, induction was achieved by

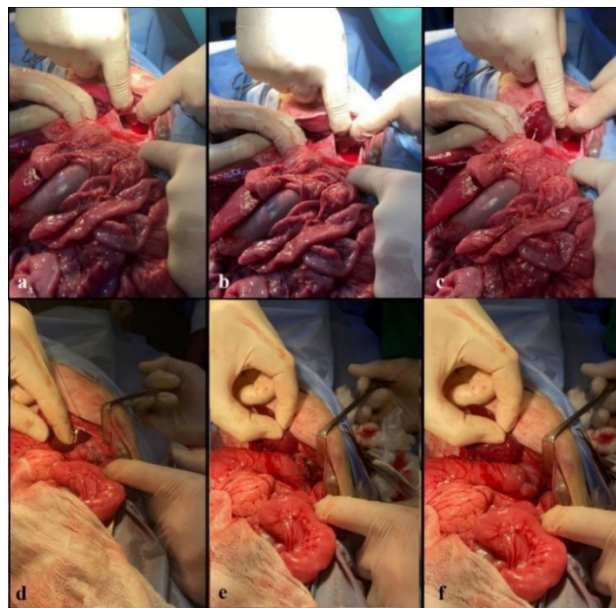


intravenous administration of propofol at a dose of 4 mg/kg to the dog with diaphragmatic hernia. Afterwards, the patient was placed under inhalation anesthesia with isoflurane by placing an endotracheal tube (6 mm diameter, cuffed).

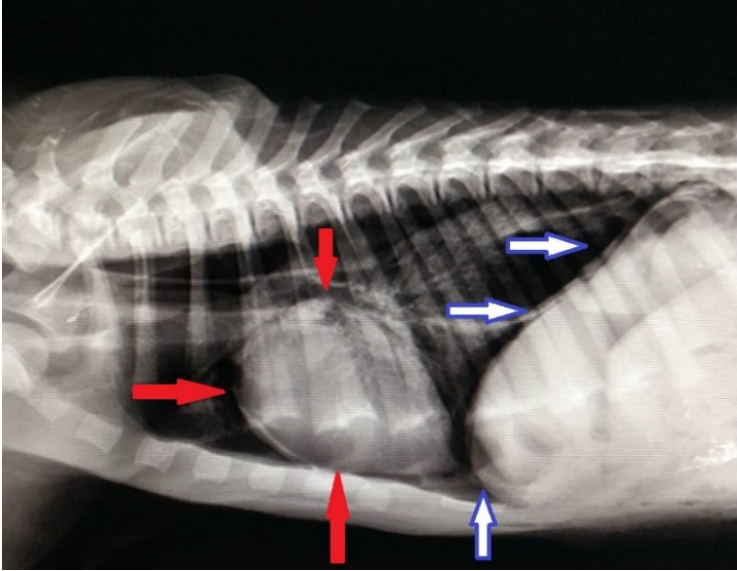
A median incision was made in the anesthetized dog, and the abdominal cavity was entered. In the examination of the abdominal organs by inspection and palpation, it was determined that the stomach, spleen, duodenum and jejunum were herniated through the opening on the left side of the diaphragm. After the reduction of the herniated organs into the abdomen with slow movements, the diaphragm was started to be repaired by suturing with reverdin sutures (Vicryl, USP:2-0) (Figure 2).

To reduce the risk of pulmonary edema, the lungs were fully inflated before the final suture was applied to the diaphragm. In the postoperative radiograph, it was determined that the diaphragm line and the heart were clearly seen (Figure 3).

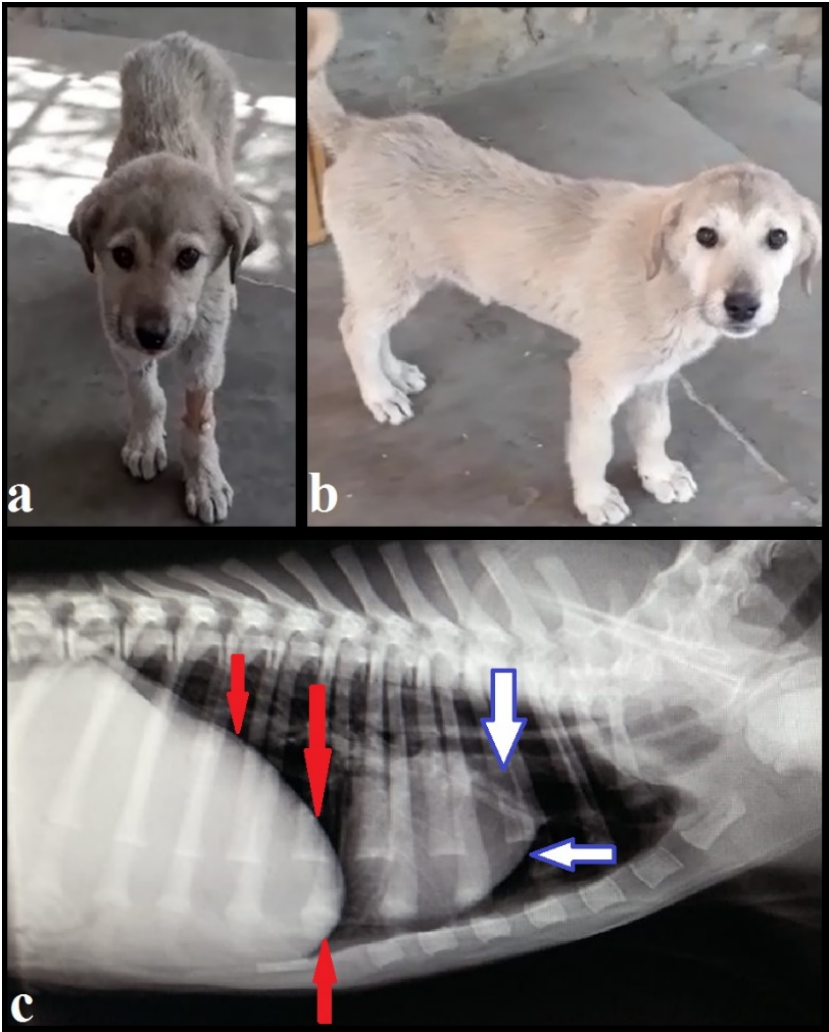
In the postoperative period, oxygen support was provided to the patient for 24 hours. In addition, amoxicillin-clavunic acid (Synulox, Zoetis, Italy) at a dose of 8.75 mg/kg was administered intramuscularly for 7 days. In the postoperative period, meloxicam (Bavet meloksikam, Bavet, Istanbul) was administered subcutaneously at a dose of 0.2 mg/kg for pain management. In the clinical and radiological examinations performed on the 15th, 30th and 60th days after the operation, it was determined that the general condition of the patient was good and there was no respiratory problem (Figure 4).



**Figure 2.** Abnormal opening formed by the left side of the diaphragm, diaphragmatic hernia (a, b, c), closure of the opening in the diaphragm, herniorrhaphy (d, e, f).



**Figure 3.** Postoperative radiographic findings; image of the heart (red arrows) and the diaphragm line (blue-white arrows).



**Figure 4.** Postoperative 15th day (a) and 30th day (b) image of the patient, postoperative 15th day thorax radiograph of the patient (c), diaphragm line (red arrows), heart (blue-white arrows).

## Discussion

Diaphragmatic hernia is a health problem with a high mortality rate in cats and dogs caused by congenital (5-10%) and traumatic (85%) causes. The cause of 10-15% of diaphragmatic hernias is unknown (Radlinsky & Fossum, 2013; Park & Lee, 2018; Zamirbekova et al. 2020). It is thought that the diaphragmatic hernia formed in the stray dog, which is the subject of this case report, was formed due to the trauma that occurred as a result of the traffic accident three days ago.

Liver, stomach, omentum and pancreas are among the organs that are most displaced towards the thoracic cavity in cases of diaphragmatic hernia. Hernias on the left side of the diaphragm mostly herniate the stomach, spleen and small intestines, while hernias on the right side of the diaphragm herniate the liver, small intestines and pancreas (Hyun, 2004; Zamirbekova et al., 2020). In the study of Zamirbekova et al. (2020), it was reported that liver (81%), stomach (43%), small intestine (35%), omentum (13%) and pancreas (13%) were the most herniated organs in diaphragmatic hernia cases in cats and dogs. Hyun (2004), on the other hand, reported that the liver (65%), stomach (95%), and small intestine (50%) were the most herniated organs in hernias on the left side of the diaphragm. In this case report, it was determined that the stomach, spleen, duodenum, and jejunum of the dog, which had a hernia on the left side of the diaphragm, were displaced into the thorax.

The most common clinical findings in diaphragmatic hernia cases are dyspnea and exercise intolerance due to respiratory depression. The muffled heart and lung sounds during auscultation of the thorax are among the most important clinical examination indicators (Burns et al., 2013; Nikiphorou et al., 2016; Park & Lee, 2018; Zamirbekova et al., 2020). In the study of Park & Lee (2018), reported moderate dyspnea and lethargy complaints in a two-month-old cat with diaphragmatic hernia. In the same study, they reported that during auscultation of the thorax, heart sounds were heard clearly from the right side and muffled from the left side. In this case report, dyspnea and ecchymoses on the mucous membranes were detected in the clinical examination of the dog. In addition, it was determined that lung and heart sounds could not be heard clearly and bowel sounds were heard during auscultation of the thorax. In diaphragmatic hernias, digestive system symptoms such as diarrhea, constipation, vomiting, loss of appetite can also be seen, depending on the herniated organs and their condition (Burns et al., 2013; Nikiphorou et al., 2016). In this case report, it was determined that the dog with diaphragmatic hernia did not have any digestive system symptoms.

Radiographic examinations are very important for the definitive diagnosis of diaphragmatic hernias. The most prominent radiographic findings are the absence of the

diaphragm line, the silhouetted appearance of the heart, the displacement of the lungs, the presence of abdominal organs and gas in the chest cavity (Burns et al., 2013; Hyun, 2004; Nikiphorou et al., 2016; Ozer et al., 2007). In the study of Hyun (2004), reported that in cats and dogs with diaphragmatic hernia, the heart was displaced in 70%, there was a gas mass originating from the stomach and intestines in the thorax in 73%, and the abdominal organs were displaced cranially in 97%. In this study, in the radiographic examination of the dog, the absence of the diaphragm line, the silhouetted image of the heart, the presence of intestinal contents and free air in the thorax facilitated the diagnosis of diaphragmatic hernia. In addition, in this case report, it was found that the apex part of the heart of the dog diagnosed with diaphragmatic hernia was displaced cranially.

The only treatment for diaphragmatic hernias is surgery. Pre-anesthetics that will not cause respiratory depression due to possible dyspnea should be used (Park & Lee, 2018; Randall, 2018; Yaygingul et al., 2019). Park & Lee (2018), reported that they achieved induction by intravenous administration of 8 mg/kg of propofol before the operation of a two-month-old cat with diaphragmatic hernia. In this case report, 4 mg/kg of propofol was administered intravenously to the dog for induction before the operation. Similar to the other study after induction, isoflurane anesthesia was administered via intermittent positive pressure ventilation.

In diaphragmatic hernia operations, in cases of collapsed lungs and/or pneumothorax, a chest tube can be placed in the lateral chest wall to evacuate free air (Tobias, 2017). In the case report, it was decided that there was no need for chest tube placement, since collapse did not occur in the lungs. However, in order to evacuate the small amount of free air accumulated in the chest cavity, the lungs were expected to be fully inflated before the last suture was placed on the diaphragm.

In diaphragmatic hernias, hypoventilation, shock, multi-organ failure and heart arrhythmias can cause death in the preoperative period (Boudrieau & Muir, 1987). In the intraoperative period, during the induction phase, delayed intubation and failure to control ventilation can result in death (Bednarski, 1986). In the postoperative period, the first 24 hours is the most critical period (Radlinsky & Fossum, 2013). The prognosis after the operation in diaphragmatic hernias is quite good. The survival rate in dogs is 81-87.5%, while the survival rate in cats is 86-97% (Burns et al., 2013; Nikiphorou et al., 2016). In this case report, it was determined that the prognosis of the dog that was operated for diaphragmatic hernia was good.

## Conclusion

As a result, it was concluded that diaphragmatic hernia is a health problem that causes important clinical symptoms in cats and dogs and has a high mortality rate if not treated. Contrary to this situation, it is very important to have a very high postoperative survival rate. In this study, it was aimed to contribute to the literature and our colleagues by sharing the diagnosis and treatment stages of a stray dog with diaphragmatic hernia.

## Financial Support

This research received no grant from any funding agency/sector.

## Ethical Statement

This study does not present any ethical concerns.

## Conflict of Interest

The authors declared that there is no conflict of interest.

## References

- Bednarski, R. M. (1986). Diaphragmatic hernia: Anesthetic considerations. *Veterinary Medicine and Surgery*, 1(3), 256-258.
- Boudrieau, S.J., & Muir, W.W. (1987). Pathophysiology of traumatic diaphragmatic hernia in dogs. *Compendium on Continuing Education for the Practising Veterinarian*, 9(4), 379-385.
- Burns, C. G., Bergh, M. S., & McLoughlin, M. A. (2013). Surgical and nonsurgical treatment of peritoneopericardial diaphragmatic hernia in dogs and cats: 58 cases (1999-2008). *Journal of the American Veterinary Medical Association*, 242(5), 643-650. <https://doi.org/10.2460/javma.242.5.643>
- Hunt, G. B., & Johnson, K. A. (2012). Diaphragmatic Hernias. In: *Veterinary Surgery: Small Animal* (pp. 1380-1390). Elsevier Saunders.
- Hyun, C. (2004). Radiographic diagnosis of diaphragmatic hernia: Review of 60 cases in dogs and cats. *Journal Veterinary Sciences*, 5(2), 157-162. <https://doi.org/10.4142/jvs.2004.5.2.157>
- Nikiphorou, X., Chioti, R., Patsikas, M.N., & Papazoglou, L.G. (2016). Peritoneopericardial diaphragmatic hernia in the dog and cat. *Journal Hellenic Veterinary Medicine Society*, 67(3), 189-194. <https://doi.org/10.12681/jhvms.15638>
- Ozer, K., Guzel, O., Devecioglu, Y., & Aksoy, O. (2007). Diaphragmatic hernia in cats: 44 cases. *Medycyna Weterynaryjna*, 63(12), 1564-1567.
- Park, S., & Lee, J.M. (2018). Diaphragmatic hernia in a two-month old cat. *Journal of Veterinary Clinics*, 35(5), 237-239. <https://doi.org/10.17555/jvc.2018.10.35.5.237>
- Radlinsky, M. G., & Fossum, T. W. (2013). Perineal hernias. In: *Small Animal Surgery* (4th ed., pp.568-573). Mosby Elsevier.
- Randall, E. K. (2018). Canine and feline diaphragm. In: *Textbook of Veterinary Diagnostic Radiology* (pp. 633-648). WB Saunders.
- Tobias, K.M. (2017). *Manual of Small Animal Soft Tissue Surgery*. John Willey & Sons.
- Yaygingul, R., Bozkan, Z., Bilgen Sen, Z., Kibar Kurt, B., & Belge, A. (2019). Traumatic diaphragmatic hernia in cats: A retrospective study of 15 cases (2016-2017). *Kocatepe Veterinary Journal*, 12(2), 205-212. <https://doi.org/10.30607/kvj.493594>
- Zamirbekova, N., Uzunlu, E.O., & Arıcan, M. (2020). Kedi ve köpeklerde travmatik hernia diyafrenmatika: 40 olgu. *Bozok Veterinary Sciences*, 1(1), 7-12.

## A case of cystic mammary adenocarcinoma in rabbit

Gözde OKUYUCU<sup>1,a,\*</sup>, Zafer ÖZYILDIZ<sup>2,b</sup>, Volkan İPEK<sup>2,c</sup>

<sup>1</sup>Mehmet Akif Ersoy University, Institute of Health Sciences, Burdur, Türkiye; <sup>2</sup>Mehmet Akif Ersoy University, Faculty of Veterinary Medicine, Department of Pathology, Burdur, Türkiye.

<sup>a</sup>ORCID: <https://orcid.org/0000-0001-5433-3271>; <sup>b</sup>ORCID: <https://orcid.org/0000-0001-5874-7797>; <sup>c</sup>ORCID: <https://orcid.org/0000-0002-6009-9191>

\*Corresponding author: [gozdeokuyucu97@gmail.com](mailto:gozdeokuyucu97@gmail.com)

Received 02.11.2022 - Accepted 19.12.2022 - Published 31.12.2022

**Abstract:** Mammary adenocarcinomas are a type of malignant tumor frequently encountered in domestic animals. It is rarely seen in rabbits, most often in cats and dogs. In recent years, cases of mammary tumors in domestic rabbits have been increasing. Cases such as adenosquamous carcinomas, anaplastic carcinomas, carcinomas in situ, spindle cell carcinomas and carcinosarcomas have also been reported, most commonly in rabbits, along with variants of invasive adenocarcinomas. In this case, a biopsy sample taken from the mammary region of a 6-year-old female hybrid rabbit was examined histopathologically and immunohistochemically. As a result of the examinations, histopathologically, a large number of neoplastic cells with features of malignancy were found in the breast tissue. Cystic formations filled with proteinous material of varying sizes were found in the neoplastic tissue. Anti-cytokeratin and anti-vimentin expressions of neoplastic cells were observed in immunohistochemical findings. A diagnosis of mammary cystadenocarcinoma was made in the presence of histopathological and immunohistochemical findings. According to the authors' knowledge, the cyst adenocarcinoma variant is rarely encountered among mammary tumors observed in rabbits.

**Keywords:** Cyst adenocarcinoma, mammary, rabbit.

### Bir tavşanda kistik meme adenokarsinomu olgusu

**Özet:** Meme adenokarsinomları evcil hayvanlarda sıklıkla karşılaşılan kötü huylu bir tümör çeşididir. En çok kedi ve köpeklerde görülmekte olup, tavşanlarda nadiren bildirilmektedir. Son yıllarda evcil tavşanlarda meme tümörünün teşhisi de giderek artmaktadır. Tavşanlarda en yaygın olarak invaziv adenokarsinomların çeşitleri ile birlikte bazı adenoskuamöz karsinomlar, anaplastik karsinomlar, in situ karsinomlar ve mekik hücreli karsinom ve karsinosarkom gibi olgular bildirilmiştir. Bu olguda ise 6 yaşlı, dişi, melez bir tavşanın meme bölgesinden alınan biyopsi örneği histopatolojik ve immunohistokimyasal olarak incelendi. Yapılan incelemeler sonucunda histopatolojik olarak meme dokusunda çok sayıda belirgin derecede anizositozis, anizokaryozis, makronükleoli ve polinükleoluslarla birlikte gözlenen neoplastik hücrelere rastlandı. Neoplastik hücrelerin yüksek mitotik aktiviteye sahip olduğu görüldü. Neoplastik doku içerisinde farklı büyüklüklerde proteinöz materyal ile dolu kistik oluşumlara rastlandı. İmmunohistokimyasal olarak neoplastik hücrelerde hem anti-sitokeratin hem de anti-vimentin pozitifliği gözlemlendi. Histopatolojik ve immunohistokimyasal bulgular eşliğinde kitleye kist adenokarsinom tanısı konuldu. Kist adenokarsinom varyantı yazarların bilgisine göre tavşanlarda gözlenen meme tümörleri içerisinde oldukça nadir olarak karşılaşılmaktadır.

**Anahtar kelimeler:** Kist adenokarsinom, meme, tavşan.

## Introduction

Mammary gland tumors are the second most common type of tumor in female dogs after skin tumors. In cats, the most common site of tumors is the mammary glands, apart from the cutaneous, lymphoid, and hematopoietic tissues. Mammary gland tumors are rare in other pet species (Jubb et al., 2012). In domestic rabbits (*Oryctolagus cuniculus*), mammary gland neoplasia has been reported relatively less frequently than in cats and dogs. Spontaneous mammary tumors in rabbits are often associated with uterine hyperplasia or adenocarcinomas. Therefore, it is thought that there is a relationship between these conditions (Walter et al., 2010).

Mammary carcinomas are subclassified as adenocarcinomas, solid carcinomas, spindle cell carcinomas, anaplastic carcinomas, squamous cell carcinomas, and mucinous carcinomas. The most frequently reported histological types are adenocarcinomas (Baum & Hewicker-Trautwein, 2015). Adenocarcinomas are classified as solid, papillary, cystic, comedo, follicular, tubular, and trabecular (Baum, 2021), based on the appearance of the glandular tissues formed by the cells that form the tumor, or as mucinous and colloid based on the characteristics of the substance secreted by the cells that form the tumor (Hüdaverdi & Kıran, 2005). Mammary gland adenocarcinomas in rabbits were found to be tubular, papillary, solid, and tubulopapillary in appearance. Cystic forms, as well as tubular and papillary formations, have been documented in a few cases (Schöniger et al., 2014; Sikoski et al., 2008). At least 70% of mammary tumors identified in rabbits are malignant and may metastasize to the lung, liver, kidney, pancreas, adrenal gland, ovary, bone marrow, and regional lymph nodes (Schöniger et al., 2014).

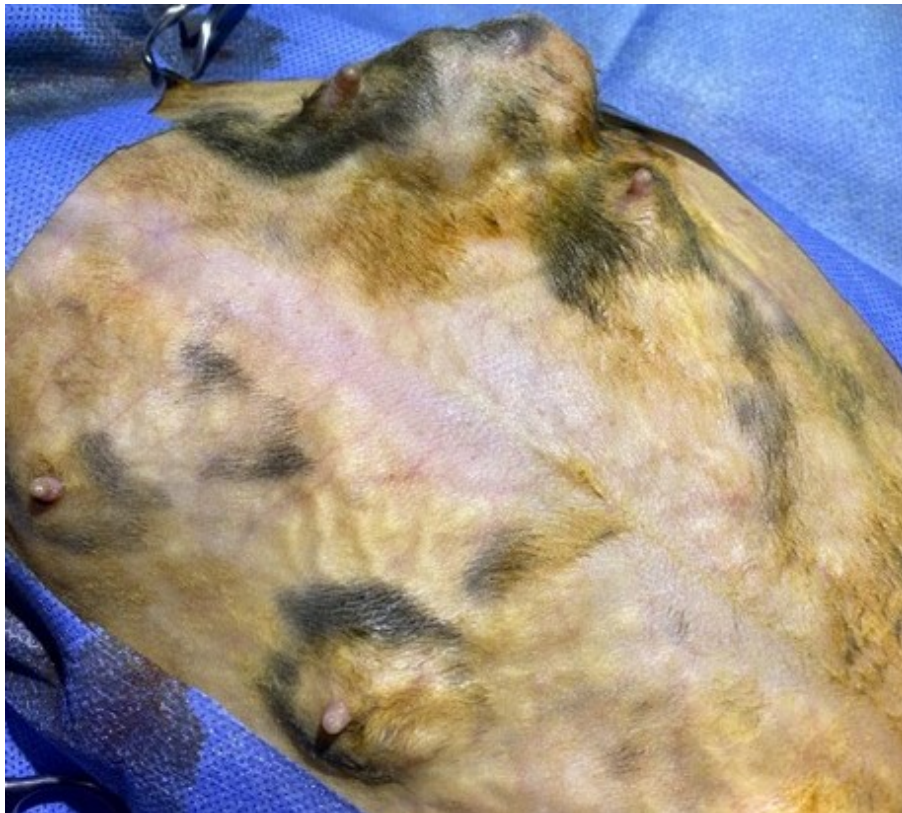In this case report, cystic mammary adenocarcinoma, which is uncommon in rabbits, was examined histopathologically and immunohistochemically.

## Case Description

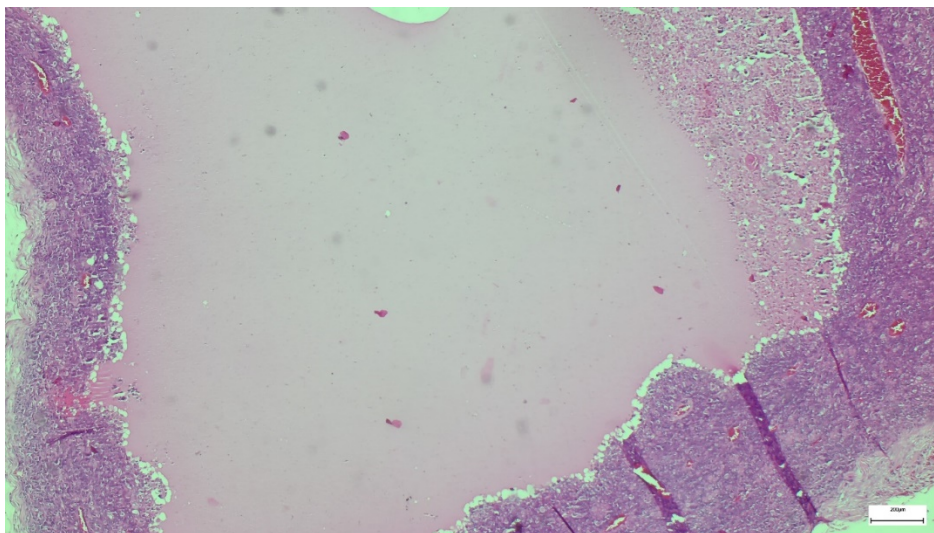
The case material is a biopsy sample taken from the thoracic mammary region of a 6-year-old female hybrid rabbit (Figure 1). The mass was approximately 5x4x3 (cm) in size. Macroscopically, the mass was firm in consistency and the cross-sectional surface was homogeneous. Following standard follow-up procedures, the biopsy sample was fixed in a 10% formaldehyde solution, embedded in paraffin, and cut into five micrometer-thick sections (Leica RM 2155) for examination under a light microscope. Cystic formations of various sizes filled with proteinous substances were found in the mammary tissue during the microscopic examination (Figure 2). In the neoplastic regions, cells with numerous polymorphisms were observed. These cells displayed several mitotic figures with distinct anisocytosis, anisokaryosis, macronucleoli, and multinucleoli (Figure 3). Additionally, in the immunohistochemical



examination, the sections were stained with the Avidin-Biotin Peroxidase Complex method. Vimentin (Dako, clone Vim 3B4, 1:200 dilution) and cytokeratin (Dako, clone AE1-AE3, 1:100 dilution) were used as primary antibodies. 3,3'-Diaminobenzidine (DAB) was used as chromogen, and counterstaining was made with Mayer hematoxylin. Neoplastic cells were positive for both antibodies (Figure 4-5).

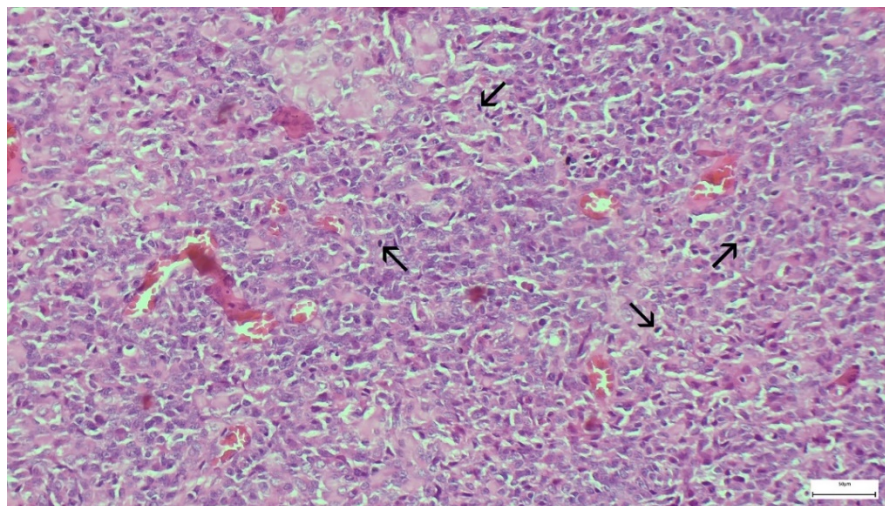


**Figure 1:** Bilateral tumoral formations in the thoracic and abdominal mammary glands

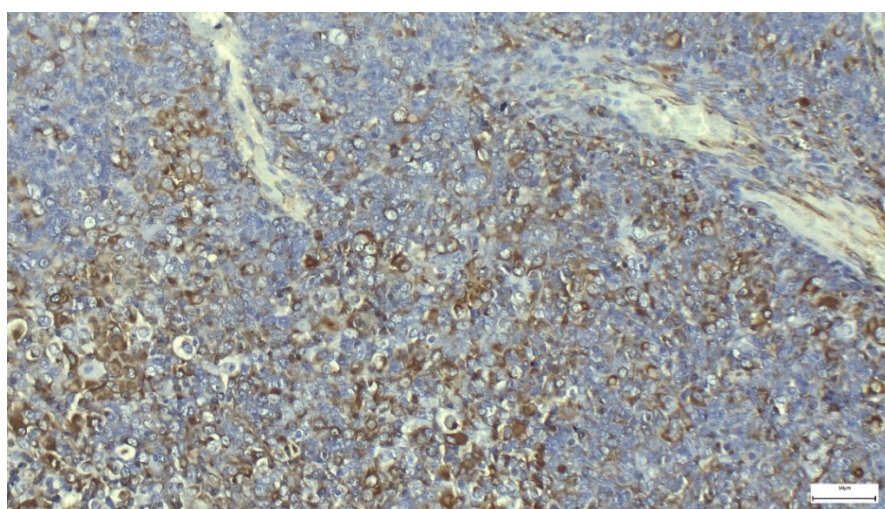


**Figure 2:** Cystic formation filled with proteinous material in the mammary gland tissue, H&E, Bar: 200 µm.

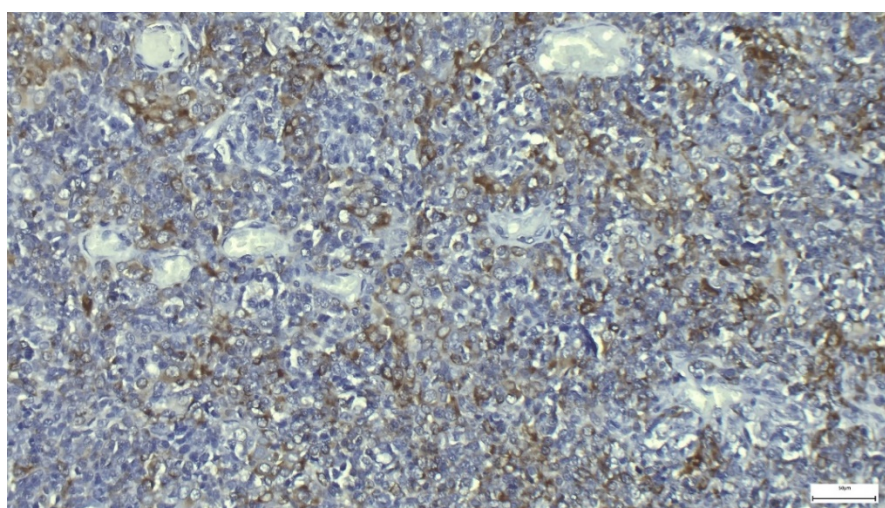




**Figure 3:** Multiple mitotic figures (arrows), with solid neoplastic growth areas showing distinct features of malignancy. H&E, Bar: 50  $\mu$ m.



**Figure 4:** Anti-vimentin positivity in neoplastic cells, DAB, Bar: 50  $\mu$ m.



**Figure 5:** Anti-cytokeratin positivity in neoplastic cells, DAB, Bar: 50  $\mu$ m.

## **Discussion**

In rabbits, mammary tumors can develop at any age, with a mean of 4.9 to 5.5 years and a range of 8 months to 14 years (Sikoski et al., 2008). Additionally, according to Schöniger et al. (2014), all rabbits with mammary tumors of known sex are female or neutered females. The rabbit in our case was also 6 years old and female, which was compatible with the literature. In a study conducted by Bertram et al. (2021) on rabbits, metastasis was found in 12 necropsy cases of malignant mammary tumors and tissue samples to the lung in five cases, the liver in two cases, the regional lymph node in one case, and the spleen in one case. In our case, the presence of metastasis could not be determined because radiography and necropsy could not be performed.

It has been reported that the majority of rabbit mammary tumors are carcinomas (Schöniger et al., 2014; Baum and Hewicker-Trautwein, 2015; Degner et al., 2018). According to the study of Bertram et al. (2021), the most common tumor growth patterns are simple adenoma/carcinoma, intraductal papillary adenoma/carcinoma, and comedocarcinoma. Schöniger et al. (2014) also stated tubular, solid, and cystic growth patterns in their study. They also reported that tumors with some cystic cavities are filled with proteinaceous material. Previous studies have shown that in addition to cystic formations in tumors, tumor cells reproduce in a tubular or papillary fashion. In this present case, however, cystic formations were seen together with solid growth of epithelial tumor cells. Furthermore, the cystic formations were filled with proteinous material.

Cytoplasmic lipid droplets are frequently found in the luminal epithelial cells of normal and hyperplastic mammary glands, epithelial tumor cells, and cystic lesions (Baum & Hewicker-Trautwein, 2015; Degner et al., 2018). Due to the high fat content of rabbit milk, their presence is likely also related to lactation activity (Maertens et al., 2006). In our study, it was noted that mammary gland epithelial tumor cells showed solid growth; cell shapes varied from cuboidal to polygonal cells, but there were no vacuoles in the cytoplasm of the cells. In addition, Baum & Hewicker-Trautwein (2015) suggested that rabbit mammary carcinomas have a wide spectrum of mitotic activity, ranging from 0-36 mitotic figures at x100 high magnification. In the presented case, 4-5 mitotic activities were observed in the x100 magnification area.

Immunohistochemistry is an important method for the diagnosis of neoplasms. The diagnosis of neoplasms has been facilitated by revealing the existence of a wide variety of antibodies and using antibodies that bind to cell-specific proteins. Since all epithelial cells contain cytokeratin and all mesenchymal cells contain vimentin, cytokeratin and vimentin are

the most commonly used intermediate filaments (Jubb et al., 2012). Cytokeratin antibody has been found to be positive in the squamous and columnar epithelial cytoplasm of the skin, cervix, colon, esophagus, small intestine, and stomach, as well as in epithelial tumors (Listrom & Dalton, 1987). The vimentin antibody has been shown to strongly stain fibrocytes, lipocytes, smooth muscle cells, vascular endothelial cells, sweat, and salivary gland myoepithelial cells. However, positivity has also been reported in epithelial tumors (such as adenocarcinomas, cholangiocarcinomas) when the tumor is poorly differentiated (Azumi & Battifora, 1987). This condition is called the “epithelial-mesenchymal transition” and is a complex process involved in embryonic development, wound healing, and carcinogenesis. During this process, epithelial cells lose their defining features and acquire mesenchymal features. With the epithelial-mesenchymal transition, the cells move away from their normal structure and allow it to pass through blood and lymphatic vessels to invade different organs. Therefore, it has been seen as a cause of metastasis and tumor invasiveness (Cervantes-Arias et al., 2013; Raposo-Ferreira et al., 2018). In our case, cytokeratin positivity confirms epithelial origin, while vimentin positivity supports the presence of epithelial-mesenchymal transition and/or malignancy increase.

### **Conclusion**

To the authors' knowledge, the cyst adenocarcinoma variant is extremely rare among mammary tumors in rabbits, and this case report may contribute to understanding the histopathology of this tumor in rabbits.

### **Financial Support**

This research received no grant from any funding agency/sector.

### **Ethical Statement**

This study does not present any ethical concerns.

### **Conflict of Interest**

The authors declared that there is no conflict of interest.

### **Acknowledgements**

This case report was presented as a summary text at the 3th International Young Researchers Student Congress on 09-11 December 2021 Burdur, Türkiye.

## References

- Azumi, N., & Battifora, H. (1987). The distribution of vimentin and keratin in epithelial and nonepithelial neoplasms: a comprehensive immunohistochemical formalin and alcohol-fixed tumors. *American Journal of Clinical Pathology*, 88(3), 286-296. <https://doi.org/10.1093/ajcp/88.3.286>
- Baum, B., & Hewicker-Trautwein, M. (2015). Classification and epidemiology of mammary tumors in pet rabbits (*Oryctolagus cuniculus*). *Journal of Comparative Pathology*, 152(4), 291-298. <https://doi.org/10.1016/j.jcpa.2015.01.009>
- Baum, B. (2021). Not just uterine adenocarcinoma-neoplastic and non-neoplastic masses in domestic pet rabbits (*Oryctolagus cuniculus*): a review. *Veterinary Pathology*, 58(5), 890-900. <https://doi.org/10.1177/03009858211002190>
- Bertram, C. A., Bertram, B., Bartel, A., Ewringmann, A., Fragoso-Garcia, M. A., Erickson, N. A., Müller, K., & Klopffleisch, R. (2021). Neoplasia and tumor-like lesions in pet rabbits (*Oryctolagus cuniculus*): A retrospective analysis of cases between 1995 and 2019. *Veterinary Pathology*, 58(5), 901-911. <https://doi.org/10.1177/0300985820973460>
- Cervantes-Arias, A., Pang, L. Y., & Argyle, D. J. (2013). Epithelial-mesenchymal transition as a fundamental mechanism underlying the cancer phenotype. *Veterinary and Comparative Oncology*, 11(3), 169-184. <https://doi.org/10.1111/j.14765829.2011.00313.x>
- Degner, S., Schoon, H. A., Laik-Schandelmaier, C., Aupperle-Lellbach, H., & Schöniger, S. (2018). Estrogen receptor- $\alpha$  and progesterone receptor expression in mammary proliferative lesions of female pet rabbits. *Veterinary Pathology*, 55, 838-848. <https://doi.org/10.1177/0300985818788611>
- Hüdaverdi, E., & Kiran M. M. (2005). *Veteriner onkoloji*. Damla Ofset.
- Jubb, K.V.F., Kennedy, P.C., & Palmer, N. (2012). Pathology of domestic animals. In: R.A. Foster, & M.G. Maxie (Ed.), *Pathology of the Mammas* (pp.451- 464). Academic Press.
- Listrom, M. B., & Dalton, L.W. (1987). Comparison of keratin monoclonal antibodies MAK-6, AE1: AE3, and CAM-5.2., *American Journal of Clinical Pathology*, 88(3), 297-301. <https://doi.org/10.1093/ajcp/88.3.297>
- Maertens, L., Lebas, F., & Szendrő, Z.S. (2006). Rabbit milk: A review of quantity, quality and non-dietary affecting factors. *World Rabbit Science*, 14, 205-230. <https://doi.org/10.4995/wrs.2006.565>
- Raposo-Ferreira, T. M., Brisson, B. K., Durham, A. C., Laufer-Amorim, R., Kristiansen, V., Puré, E., Volk, S. V., & Sorenmo, K. (2018). Characteristics of the epithelial-mesenchymal transition in primary and paired metastatic canine mammary carcinomas. *Veterinary Pathology*, 55(5), 622-633. <https://doi.org/10.1177/0300985818776054>
- Schöniger, S., Horn, L. C., & Schoon, H. A. (2014). Tumors and tumor-like lesions in the mammary gland of 24 pet rabbits: A histomorphological and immunohistochemical characterization. *Veterinary Pathology*, 51, 569-580. <https://doi.org/10.1177/0300985813497486>
- Sikoski, P., Trybus, J., Cline, J. M., Muhammad, F. S., Eckhoff, A., Tan, J., Lockard, M., Jolley, T., Britt, S., & Kock, N. D. (2008). Cystic mammary adenocarcinoma associated with a prolactin-secreting pituitary adenoma in a New Zealand white rabbit (*Oryctolagus cuniculus*). *Comparative Medicine*, 58, 297-300.
- Walter, B., Poth T., Bohmer E., Braun, J., & Matis, U. (2010). Uterine disorders in 59 rabbits. *Veterinary Record*, 166(8), 230-233. <https://doi.org/10.1136/vr.b4749>

## The microbiota of humans and animals and its relationship with the use of functional foods

Ayşegül DEMİRCİOĞLU<sup>1,a,\*</sup>, Muhammed DEMİRCİOĞLU<sup>2,b</sup>, Migena GJONİ  
GÜNDEMİR<sup>3,c</sup>

<sup>1</sup>Bursa Uludağ University, Institute of Health Sciences, Bursa, Türkiye; <sup>2</sup>Selçuk University, Institute of Health Sciences, Konya, Türkiye; <sup>3</sup>Istanbul University-Cerrahpasa, Institute of Graduate Studies, Istanbul, Türkiye.

<sup>a</sup>ORCID: <https://orcid.org/0000-0002-5121-2631>; <sup>b</sup>ORCID: <https://orcid.org/0000-0001-8082-8630>; <sup>c</sup>ORCID: <https://orcid.org/0000-0002-6342-6063>

\*Corresponding author: aysegulertekinn@hotmail.com

Received 07.10.2022 - Accepted 12.12.2022 - Published 31.12.2022

**Abstract:** In human and animal body, especially in the gastrointestinal tract, there are many microorganisms that coexist in a mutually beneficial relationship with the host. The main function of the intestinal microbiome is to ferment indigestible substrates and short-chain fatty acids, etc. to inhibit the proliferation of pathogens, among other functions. For example, by increasing beneficial microorganisms that produce important antimicrobial metabolites. The gut microbiota can prevent the colonization of pathogens through the mechanism of colonization resistance. Antibiotic exposure to the gut microbiome can trigger the response that affects colonization resistance. This review provides an overview of the gut microbiome and the effects of antibiotic therapy on pathogen and disease colonization, the relationship between diet and microbiota, and the use of functional foods.

**Keywords:** Functional food, microbiota, probiotic-prebiotic.

### İnsan ve hayvanlarda mikrobiyota ve fonksiyonel gıdaların kullanımı ile ilişkisi

**Özet:** İnsan ve hayvan vücudunda, özellikle de mide-bağırsak sisteminde, konakçı ile karşılıklı olarak yararlı bir ilişki içinde birlikte gelişen birçok mikroorganizma bulunmaktadır. Bağırsak mikrobiyomunun ana rolü, sindirilemeyen substratların fermentasyonu ve diğer işlevlerin yanı sıra patojenlerin çoğalmasını engellemek için kısa zincirli yağ asitleri vb. gibi önemli antimikrobiyal metabolitler üreten faydalı mikroorganizmaların artmasıdır. Bağırsak mikrobiyotası, kolonizasyon direnci mekanizması yoluyla patojen kolonizasyonunu önleyebilir. Bağırsak mikrobiyomunu antibiyotik maruziyetine bırakmak, bağırsak kolonizasyon direncini etkileyen yanıtı tetikleyebilir. Bu derlemede, bağırsak mikrobiyomu ve antibiyotik tedavisinin patojen kolonizasyonu ve hastalıkları üzerindeki etkilerine, diyetin mikrobiyota ile ilişkisine ve fonksiyonel gıdaların kullanımına yönelik genel bir bakış sunulmaktadır.

**Anahtar kelimeler:** Fonksiyonel gıda, mikrobiyata, probiyotik-prebiyotik.

### Introduction

Humans live in a biosphere where microorganisms have existed for 3.8 million years and have influenced the biosphere for 10 thousand years. Over the same period, we have also been influencing the microorganisms that make up our internal biosphere, i.e., our microbiota (Lederberg & McCray, 2001). Ecological communities formed by commensal, symbiotic, and

pathogenic microorganisms found in various parts of the human body used to be referred to as normal body flora but are now called the "microbiota". The term microbiome refers to the sum of genomes of microorganisms living in an ecological niche (Köroğlu, 2017). The human microbiota is mainly composed of bacteria, viruses, fungi, and many eukaryotic microorganisms (Tuğ et al., 2002). It is reported that the bacterial genome in the human body is ~ 150 times larger than the human genome (Cénié et al., 2014; Walker & Lawley, 2013). This combination of human and microbial genomes is referred to as the "hologenome". In addition, it is reported that the number of microorganisms in the human body is ten times greater than the number of human cells, as they also have advantages in terms of their genome (Belkaid & Hand, 2014). Most of the human microbiota has occupied in the digestive system, skin, urogenital system, and respiratory system. The digestive system provides the most suitable environment for microorganisms to colonize due to its large surface area and abundance of nutrients. For this reason, the colon alone is reported to contain more than 70% of the microorganisms in our bodies (Whitman et al., 1998).

The relationship among microorganisms and between microorganisms and hosts is studied through microbiome studies. The Microbiome Project, launched in 2007 with 300 volunteers, aimed to determine all microorganisms in the human body and to investigate whether changes in the microbiome can be associated with the disease (Tuğ et al., 2002). The gastrointestinal microbiota more than 1500 species of microorganisms. The two dominant bacterial phyla Firmicutes and Bacteroides make about 90% of the gut microbiota of a healthy adult person, with lesser amounts of other phyla like Actinobacteria (mostly *Bifidobacterium*), Proteobacteria, Fusobacteria, and Verrucomicrobia (Kamada et al., 2013; Qin et al., 2010).

The microbiome has some protective, metabolic, and structural effects. These protective effects are the removal of pathogenic microorganisms, competition with food, competition with receptors and the production of antimicrobial factors. Their structural effects are strengthening the mucosal barrier, induction of IgA, tightening the tight junctions, and developing the immune system. Its metabolic effects are control of epithelial cell differentiation and proliferation, metabolism of dietary carcinogens, synthesis of vitamins, epithelial-derived fermentation of indigestible food residues, and lowering pH (Hansen et al., 2015).

***Relationship of microbiota with diseases:*** The bacteria in the microbiota contain a certain amount of beneficial and harmful bacteria. When the ratio between beneficial and harmful bacteria decreases, a pathological process called "microbial dysbiosis" begins. The healthy microbiota is called eubiosis (Whitman et al., 1998). The microbiota plays an important role in many bodily functions, including homeostasis, metabolism, the production of minerals



and vitamins, the formation of some endocrine stimulation, the prevention of the colonization of some pathogenic microorganisms, the regulation of immune reactions, and the metabolism of xenobiotic substances (Barko et al., 2018; Nicholson et al., 2012). The microbiota also plays a critical role in the immune system's maturation, distinguishing between commensal and pathogenic bacteria and fostering tolerance and immunity to own and foreign antigens. The immunological balance of the mucosa has essential tasks, such as the correct differentiation between billions of harmless microorganisms and rare pathogenic invasive microorganisms. The immune system attempts to directly prevent pathogen colonization through local and generally systemic inflammatory responses (Barko et al., 2018).

Some microorganisms that live with us in the gastrointestinal tract are recognized by M cells and dendritic cells in the epithelium. These stimulate the maturation of T lymphocytes by turning into Regulatory T cells (Treg) cells that secrete cytokines that control the immune system and have an anti-inflammatory function. Lymphocytes, one of the most critical cells in our immune system, stimulate epithelial cells to secrete defensin-like substances with antimicrobial activity (Belkaid & Naik, 2013). In people with dysbiosis, the structure of the mucus layer deteriorates with the decrease in the diversity of the microbiota or the deterioration of the balance of the microbial composition in the intestinal contents and the composition of the microbiota and, consequently, the metabolism of the microbiome. This results in a deterioration of the functions of the mucus layer that are very beneficial to the host, such as maintaining the microbial composition in the gut and preventing colonization by pathogenic microorganisms (Haller, 2018). It has been reported to play a very influential role in gut microbial composition, digestive system peristalsis, and intestinal epithelial function (Björkstén et al., 2001; Vrieze et al., 2010). The bidirectional relationship between the gut microbiota and immune system development and function involves multiple interactions in homeostasis and disease states. At the same time, the immune system regulates the maintenance of the basic features of the relationship between the host and the symbiotic microbiota. In a genetically susceptible host, imbalances in the interactions between the microbiota and the immune system are thought to influence the pathogenesis of many immunological diseases (Shi et al., 2017).

***Effects of antibiotics on microbiota:*** One of the most important factors affecting the microbiota is the use of antibiotics. Antibiotics not only have specific toxicity to the target pathogen, but they also affect the microbiota. The beta-lactam and fluoroquinolone group antibiotics are among the antibiotics that have the most effects on the microbiota due to their frequent use. On the other hand, combined effects on the microbiome often occur due to their frequent use for combined therapy applications (Panda et al., 2014). In one study, it was found

that after a 7-day application of clindamycin, the Bacteroides phyla in the microbiota did not return to its normal composition even after two years (Jernberg et al., 2007).

According to the Canine Microbiota Dysbiosis Index data from the College of Texas, it has been reported that although the gut microbiota returns to its previous composition within a few weeks after antibiotic administration in many dogs, this process takes a long time in some animals (Suchodolski et al., 2016).

**Microbiota interaction in animals and humans:** The gastrointestinal tract is the most important habitat for the microbiota of humans and other animal species. The microbiota of the mammalian digestive tract is diverse and complex, consisting of many interdependent and noncompeting species. The composition of the microbiota varies throughout the gastrointestinal tract. It has been observed that anaerobic bacterial groups dominate in distal sections, whereas aerobic and anaerobic bacteria are more evenly distributed in proximal sections (Simpson et al., 2002; Suchodolski et al., 2008). Cats and dogs have a relatively simple gastrointestinal tract compared to humans and livestock (Eckburg et al., 2005; Ley et al., 2008). In a study using bacterial culture techniques from canine gastric biopsies, the number of bacteria in the stomach was  $10^6$  cfu/g and it was found that the most abundant indices belonged to the Proteobacteria phylum (99.6%). In addition, only a few (0.3%) indices belonging to the phylum Firmicutes were found (Benno et al., 1992; Garcia-Mazcorro et al., 2012).

It is reported that the part with the greatest similarity in the microbiota of humans and animals living together is the skin and hair regions. Microbiologically, studies have shown that the skin microbiota of adults is more similar to the microbiota of their dog or dogs than to that of other dogs. People with dogs share more common bacterial phylotypes than people without dogs (Song et al., 2013). The taxa that share the most significant similarity between dogs and their owners are the Betaproteobacteria (Methylophilaceae), the Actinobacteria, and the Acidobacteria pylotype (Lauber et al., 2009).

It has been observed that the microbiota of the digestive system benefits the host through many mechanisms. Commensal bacteria in the digestive tract form a temporary defense barrier against pathogens. They aid in the digestion of nutrients, provide important metabolites for the host, and have important functions in modulating the host's immune system (Suchodolski, 2011).

The idea that pets are beneficial to human health was first introduced in 1989 by David Strachan, who attributed the risk of allergic disease to a highly hygienic environment (Strachan, 1989). With further evidence that dysbiosis of the gut microbiome in infancy is associated with the development of allergic disease, this view has been revised as the microbiota hypothesis

(Ezell et al., 2013; Hesselmar et al., 1999; Litonjua et al., 2002; Lodge et al., 2012; Nermes et al., 2013; Ownby et al., 2002; Wold, 1998). In a pilot study including 24 newborns, it was discovered that 3-month-old infants who were around dogs had increased gut microbial richness and variety, as well as more *Bifidobacterium pseudolongum*, an important marker of the transition from animal to human (Azad et al., 2013; Lodge et al., 2012; Nermes et al., 2013). Additionally, *Alistipies*, *Pseudomonas*, *Slackia*, *Subdoligranulum*, the bacterial group *Eubacterium coprostanoligenes*, and *Barnesiella* were not discovered in the gut microbiota of dogs in a study comparing the gut microbiota of wild wolves and domestic dogs to evaluate the domestication of dogs and their coexistence with humans. This indicates that, unlike their wild ancestors, the microbiota of style of living and human influence. In parallel, the same study found that the *Dorea*, *Parabacteroides*, *Streptococcus* family and, Bacteriodales, and Clostridiales phylum, which are not found in wild wolves, are found in humans and domestic dogs (Alessandri et al., 2019).

According to the researches, most of the studies on respiratory microbiota have been conducted on humans. Information on the composition of the respiratory microbiota in domestic animals sharing the same environment as humans seems to be rather limited. A recently developed PCR-based algorithm called the "dysbiosis index" is a tool that veterinarians can use to measure gut dysbiosis and can be used to monitor disease progression and response to treatment (AlShawaqfeh et al., 2017).

In recent studies, Proteobacteria, Firmicutes, and Actinobacteria phylum have been identified in the respiratory tract microbiota of dogs, and these data in healthy dogs have been determined to be important for understanding the role of microbial communities in infectious and non-infectious inflammatory respiratory diseases (Ericsson et al., 2016). No study has yet documented the composition of a healthy respiratory microbiota composition in cats yet (Vientós-Plotts et al., 2017). In microbiota studies in dogs, it was determined that the bacterial and fungal communities in the microbiota of animals with atopic dermatitis have been found to be less diverse than in healthy animals. Similar to humans, the different skin areas in each dog are surrounded by a diverse and unique microbiota, with significant individual differences in different dogs and different regions and higher microbial diversity in hairy areas than on mucosal surfaces (i.e. lips, nose, ear, and conjunctiva). The nostril and conjunctiva contained the lowest microbial density, whereas the axillary region and dorsal part of the nose had the highest microbial diversity. The dominant phyla on all these surfaces were Proteobacteria, Firmicutes, Actinobacteria, and Bacteroidetes (Rodrigues-Hoffmann et al., 2020).

**Microbiota-diet relationship:** It is well known that nutrient composition or dietary content significantly affects gastrointestinal function, microbiota composition, and bacterial metabolites in the gut (Grześkowiak et al., 2015). Some carbohydrate ingredients are not enzymatically digested in the small intestine or not be absorbed in the upper gastrointestinal tract, but are fermented by the gut microbiota and represent the main source of energy and carbon for the gut microbiota. These indigestible carbohydrates (mostly fibers) are called prebiotics and increase the activity of beneficial microorganisms in the gut microbiota. Prebiotics; consist of soybeans, inulin, unrefined wheat, raw oats, fructans, polydextrose, fructooligosaccharides, galactooligosaccharides, xylooligosaccharides, and arabinooligosaccharides (Pandey et al., 2015). Regardless of the specific bacteria, prebiotics have been reported to increase lactic acid bacteria and beneficial bacteria, and whole grain products have beneficial effects on the gut microbiota due to their high fiber content (Halmos et al., 2015).

Fava et al. (2013) studied the effects of dietary fat content on the gut microbiota and found that a low-fat diet increased bifidobacteria density, resulting in a decrease in fasting glucose and total cholesterol. On the other hand, it was found that feeding monounsaturated fatty acids had no effect on bacterial gene richness but decreased total bacterial load and LDL cholesterol.

**Probiotics used as functional food:** Functional foods; these are foods and food ingredients that provide additional benefits to human physiology and metabolic functions beyond meeting basic nutrient needs, thus protecting against disease and enabling healthier living. In addition, these foods are defined as foods that can be consumed in the form of food in the daily diet, do not contain synthetic compounds, and have health- and wellness-promoting properties (Erbaş, 2006). For a food to be functional, it must contain factors such as bioactive compounds, probiotic microorganisms, and prebiotic substances, and these factors must reach the right part of the body in sufficient quantities (Dayısoylu et al., 2014). Probiotics are also defined as "live microorganisms that, when ingested in sufficient quantities, improve the properties of the body's microflora and positively affect the health of the host". For a product define as a probiotic, it must be resistant to gastric acid and bile acids, survive in the digestive tract, adhere to the intestinal epithelium, adapt to the microbiota, colonize in the digestive tract, secrete antimicrobial substances (such as bacteriocin), be nonpathogenic and toxic, and have a positive effect on host health. It must have beneficial effects and be stable and viable during production and storage (FAO/WHO, 2002).

Although many microorganisms are used as probiotics, the most commonly used group of microorganisms are the bacteria belonging to the genera *Lactobacillus* and *Bifidobacterium*.

In addition, some other bacterial species, yeast and mold species are also used for probiotic production (Uymaz, 2010; Yılmaz, 2004). The most commonly produced probiotic products are yogurt and fermented milk drinks. In recent years, probiotic cultures are added to the composition of fermented milk products in addition to the classic yogurt starters, which give the product additional physiological effects and higher nutritional value (Canbulat & Ozcan, 2015). Nowadays, different methods are used for probiotic cultures to settle in the host digestive system and become resistant to harmful factors that could prevent them from maintaining their viability. Among these methods, the selection of acid-resistant and bile-resistant strains, the use of oxygen-tight packaging, two-stage fermentation, stress adaptation, the addition of peptide- and amino acid-containing micronutrients, and microencapsulation are commonly preferred (Martín et al., 2015; Pradeep Prasanna & Charalampopoulos, 2018).

### **Conclusion**

Studies have shown that proper manipulation of the microbiota contributes to the treatment of some diseases, and it seems that the potential therapeutic efficacy of prebiotics and probiotics (a symbiotic combination) is being elucidated day by day. The mechanisms underlying the prevention of colonization of the gut by pathogens by the gut microbiota are controversial due to the lack of detailed mechanisms and direct evidence. A better understanding of how the commensal microbiota interacts with the host is essential to determine the pathogenic and pathophysiological aspects of disease and developing more effective therapeutic agents. On the other hand, the complex structure of the microbiota, its functions, and its effects on the organism have only recently been explored and considered in veterinary medicine. Existing studies on microbiota indicate that microbiota research in veterinary medicine has an important counterpart in the fields of health and economics. Future research projects in microbiome-based disease diagnosis, prognosis monitoring, prophylaxis, and treatment have the potential to revolutionize current disease prevention and treatment measures.

### **Financial Support**

This research received no grant from any funding agency/sector.

### **Ethical Statement**

This study does not present any ethical concerns.

## Conflict of Interest

The authors declared that there is no conflict of interest.

## References

- Alessandri, G., Milani, C., Mancabelli, L., Mangifesta, M., Lugli, G.A., Viappiani, A., Duranti, S., Turrone, F., Ossiprandi, M.C., van, Sinderen, D., & Ventura, M. (2019). Metagenomic dissection of the canine gut microbiota: insights into taxonomic, metabolic and nutritional features. *Environmental Microbiology*, *21*, 1331-1343. <https://doi.org/10.1111/1462-2920.14540>
- AlShawaqfeh, M.K., Wajid, B., Minamoto, Y., Markel, M., Lidbury, J.A., Steiner, J.M., Serpedin, E., & Suchodolski, J.S. (2017). A dysbiosis index to assess microbial changes in fecal samples of dogs with chronic inflammatory enteropathy. *FEMS Microbiology Ecology*, *1*, 93. <https://doi.org/10.1093/femsec/fix136>
- Azad, M.B., Konya, T., Maughan, H., Guttman, D.S., Field, C.J., Sears, M.R., Becker, A.B., Scott, J.A., Kozyrskyj, A.L. (2013). Infant gut microbiota and the hygiene hypothesis of allergic disease: impact of household pets and siblings on microbiota composition and diversity. *Allergy, Asthma & Clinical Immunology*, *9*, 15. <https://doi.org/10.1186/1710-1492-9-15>
- Barko, P.C., McMichael, M.A., Swanson, K.S., & Williams D.A. (2018). The gastrointestinal microbiome: a review. *Journal of veterinary internal medicine*, *32*(1), 9-25. <https://doi.org/10.1111/jvim.14875>
- Belkaid, Y., & Hand, T.W. (2014). Role of the microbiota in immunity and inflammation. *Cell*, *157*, 121-141. <https://doi.org/10.1016/j.cell.2014.03.011>
- Belkaid, Y., & Naik, S. (2013). Compartmentalized and systemic control of tissue immunity by commensals. *Nature Immunology*, *14*(7), 646-653. <https://doi.org/10.1038/ni.2604>
- Benno, Y., Nakao, H., Uchida, K., & Mitsuoka, T. (1992). Impact of the advances in age on the gastrointestinal microflora of beagle dogs. *The Journal of Veterinary Medical Science*, *54*, 703-706. <https://doi.org/10.1292/jvms.54.703>
- Björkstén, B., Sepp, E., Julge, K., Voor T., & Mikelsaar, M. (2001). Allergy development and the intestinal microflora during the first year of life. *Journal of Allergy and Clinical Immunology*, *108*, 516-520. <https://doi.org/10.1067/mai.2001.118130>
- Canbulat, Z., & Ozcan, T. (2015). Effects of short-chain and longchain inulin on the quality of probiotic yogurt containing *Lactobacillus rhamnosus*. *Journal of Food Processing and Preservation*, *39*(6), 1251-1260. <https://doi.org/10.1111/jfpp.12343>
- Cénit, M.C., Matzaraki, V., Tigchelaar, E. F., & Zhernakova, A. (2014). Rapidly expanding knowledge on the role of the gut microbiome in health and disease. *Biochimica et Biophysica Acta (BBA)-Molecular Basis of Disease*, *1842*(10), 1981-1992. <https://doi.org/10.1016/j.bbadis.2014.05.023>
- Dayısoylu, K.S., Gezginç, Y., & Cingöz, A. (2014). Fonksiyonel gıda mı, fonksiyonel bileşen mi? Gıdalarda fonksiyonellik. *Gıda*, *39*(1), 57-62. <https://doi.org/10.5505/gida.03511>
- Eckburg, P.B., Bik, E.M., Bernstein, C.N., Purdom, E., Dethlefsen, L., Sargent, M., Gill, S.R., Nelson, K.E., & Relman, D.A. (2005). Diversity of the human intestinal microbial flora. *Science*, *308*, 1635-1638. <https://doi.org/10.1126/science.1110591>
- Erbaş, M. (2006): *Yeni bir gıda grubu olarak fonksiyonel gıdalar*. 791-794. In: Türkiye 9. Gıda Kongresi, 24-26 Mayıs 2006, Bolu, Türkiye.
- Ericsson, A.C., Personett, A.R., Grobman, M.E., Rindt, H., & Reinero, C.R. (2016). Composition and predicted metabolic capacity of upper and lower airway microbiota of healthy dogs in relation to the fecal microbiota. *PLoS One*, *11*(5), e0154646. <https://doi.org/10.1371/journal.pone.0154646>
- Ezell, J.M., Wegienka, G., Havstad, S., Ownby, D.R., Johnson, C.C., & Zoratti, E.M. (2013). Across-sectional analysis of pet-specific immunoglobulin E sensitization and allergic symptomatology and household pet keeping in a birth cohort population. *Allergy Asthma*, *34*, 504-510. <https://doi.org/10.2500/aap.2013.34.3698>
- FAO/WHO. (2002). *Guidelines for the evaluation of probiotics in food*. FAO/WHO Working Group.
- Fava, F., Gitau, R., Griffin, B., Gibson, G., Tuohy, K., & Lovegrove, J. (2013). The type and quantity of dietary fat and carbohydrate alter faecal microbiome and short-chain fatty acid excretion in a metabolic syndrome 'at risk' population. *International Journal of Obesity*, *37*(2), 216. <https://doi.org/10.1038/ijo.2012.33>
- Garcia-Mazcorro, J.F., Suchodolski, J.S., Jones, K.R., Clark, Price, S.C., Dowd, S.E., Minamoto, Y., Markel, M., Steiner, J.M., & Dossin, O. (2012). Effect of the proton pump inhibitor omeprazole on the gastrointestinal bacterial microbiota of healthy dogs. *FEMS Microbiology Ecology*, *80*, 642-636. <https://doi.org/10.1111/j.1574-6941.2012.01331.x>

- Grześkowiak, Ł., Endo, A., Beasley, S., & Salminen, S. (2015). Microbiota and probiotics in canine and feline welfare. *Anaerobe*, 34, 14-23. <https://doi.org/10.1016/j.anaerobe.2015.04.002>
- Haller, D. (2018). *The gut microbiome in health and disease*. Springer.
- Halmos, E.P., Christophersen, C.T., Bird, A.R., Shepherd, S.J., Gibson, P.R., & Muir, J.G. (2015). Diets that differ in their FODMAP content alter the colonic luminal microenvironment. *Gut*, 64(1), 93-100. <https://doi.org/10.1136/gutjnl-2014-307264>
- Hansen, T.H., Gobel, R.J., Hansen, T., & Pedersen, O. (2015). The gut microbiome in cardio-metabolic health. *Genome Medicine*, 7(1), 33. <https://doi.org/10.1186/s13073-015-0157-z>
- Hesselmar, B., Aberg, N., Aberg, B., Eriksson, B., & Bjorksten, B., (1999). Does early exposure to cat or dog protect against later allergy development? *Clinical & Experimental Allergy*, 29, 611-617. <https://doi.org/10.1046/j.1365-2222.1999.00534.x>
- Jernberg, C., Löfmark, S., Edlund, C., & Jansson, J.K. (2007). Long-term ecological impacts of antibiotic administration on the human intestinal microbiota. *The ISME Journal*, 1, 56-66. <https://doi.org/10.1038/ismej.2007.3>
- Kamada, N., Chen, G. Y, Inohara N., & Núñez G. (2013). Control of pathogens and pathobionts by the gut microbiota. *Nature immunology*, 14(7), 685-690. <https://doi.org/10.1038/ni.2608>
- Köroğlu, M. (2017). Mikrobiyota çalışmalarında örnek alımı ve DNA izolasyonu. *Journal of Biotechnology and Strategic Health Research*, 1, 50-55.
- Lauber, C.L., Hamady, M., Knight, R., & Fierer, N. (2009). Pyrosequencing-based assessment of soil pH as a predictor of soil bacterial community structure at the continental scale. *Applied and Environmental Microbiology*, 75, 5111-5120. <https://doi.org/10.1128/AEM.00335-09>
- Lederberg, J., & McCray, A. T. (2001). Ome Sweet Omics--A genealogical treasury of words. *The Scientist*, 15(7), 8-8.
- Ley, R.E., Hamady, M., Lozupone, C., Turnbaugh, P.J., Ramey, R.R., Bircher, J.S., Schlegel, M.L., Tucker, T.A., Schrenzel, M.D., Knight, R., & Gordon, J.I. (2008). Evolution of mammals and their gut microbes. *Science* 320, 1647-1651. <https://doi.org/10.1126/science.1155725>
- Litonjua, A.A., Milton, D.K., Celedon, J.C., Ryan, L., Weiss, S.T., & Gold, D.R. (2002). A longitudinal analysis of wheezing in young children: the independent effects of early life exposure to house dust endotoxin, allergens, and pets. *The Journal of Allergy and Clinical Immunology*, 110, 736-742. <https://doi.org/10.1067/mai.2002.128948>
- Lodge, C.J., Allen, K.J., Lowe, A.J., Hill, D.J., Hosking, C.S., Abramson, M.J., & Dharmage, S.C. (2012). Perinatal cat and dog exposure and the risk of asthma and allergy in the urban environment: a systematic review of longitudinal studies. *Clinical and Developmental Immunology*, 176484. <https://doi.org/10.1155/2012/176484>
- Martín, M.J., Lara-Villoslada, F., Ruiz, M.A., & Morales, M.E. (2015). Microencapsulation of bacteria: A review of different technologies and their impact on the probiotic effects. *Innovative Food Science and Emerging Technologies*, 27, 15-25. <https://doi.org/10.1016/j.ifset.2014.09.010>
- Nermes, M., Niinivirta, K., Nylund, L., Laitinen, K., Matomaki, J., Salminen, S., & Isolauri, E. (2013). Perinatal pet exposure, faecal microbiota, and wheezy bronchitis: is there a connection?. *ISRN Allergy*, 827934. <https://doi.org/10.1155/2013/827934>
- Nicholson, J.K., Holmes, E., Kinross, J., Burcelin, R., Gibson, G., Jia, W., & Pettersson, S. (2012). Host-gut microbiota metabolic interactions. *Science*, 336(6086), 1262-1267. <https://doi.org/10.1126/science.1223813>
- Ownby D.R., Johnson C.C., & Peterson E.L. (2002). Exposure to dogs and cats in the first year of life and risk of allergic sensitization at 6 to 7 years of age. *JAMA*, 288, 963-972. <https://doi.org/10.1001/jama.288.8.963>
- Panda, S., El Khader, I., Casellas, F., López Vivancos, J., García Cors, M., Santiago, A., Cuenca, S., Guarner, F., & Manichanh, C. (2014). Short-term effect of antibiotics on human gut microbiota. *PLoS One*, 9, e95476. <https://doi.org/10.1371/journal.pone.0095476>
- Pandey, K.R., Naik, S.R., & Vakil, B.V. (2015). Probiotics, prebiotics and synbiotics-a review. *Journal of Food Science and Technology*, 52(12), 7577-7587. <https://doi.org/10.1007/s13197-015-1921-1>
- Pradeep Prasanna, P.H., & Charalampopoulos, D. (2018). Encapsulation in an alginate-goats' milkulin matrix improves survival of probiotic Bifidobacterium in simulated gastrointestinal conditions and goats' milk yoghurt. *International Journal of Dairy Technology*, 72(1), 132-141. <https://doi.org/10.1111/1471-0307.12568>
- Qin J., Li R., Raes J., Arumugam M., Burgdorf K.S., Manichanh C., Nielsen T., Pons N., Levenez F., Yamada T., Mende D.R., Li J., Xu J., Li S., Li D., Cao J., Wang B., Liang H., Zheng H., Xie Y., Tap J., Lepage P., Bertalan M., Batto J.M., Hansen T., Le Paslier D., Linneberg A., Nielsen H.B., Pelletier E., Renault P., Sicheritz-Ponten T., Turner K., Zhu H., Yu C., Li S., Jian M., Zhou Y., Li Y., Zhang X., Li S., Qin N., Yang H., Wang J., Brunak S., Doré J., Guarner F., Kristiansen K., Pedersen O., Parkhill J., Weissenbach J.; MetaHIT Consortium, Bork P., Ehrlich S.D., & Wang J. (2010). A human gut

- microbial gene catalogue established by metagenomic sequencing. *Nature*, 464(7285), 59-65.  
<https://doi.org/10.1038/nature08821>
- Rodrigues Hoffmann, A., Patterson, A.P., Diesel, A., Lawhon, S.D., Hoai J.L., Stephenson, C. E., Mansell, J., Steiner, J.M., Scot E.D., Olivry, T., & Suchodolski, J.S. (2014). The skin microbiome in healthy and allergic dogs. *PLoS One*, 9, e83197. <https://doi.org/10.1371/journal.pone.0083197>
- Shi, N., Li, N., Duan, X., & Niu, H. (2017). Interaction between the gut microbiome and mucosal immune system. *Military Medical Research*, 4(1), 1-7. <https://doi.org/10.1186/s40779-017-0122-9>
- Simpson, J.M., Martineau, B., Jones, W.E., Ballam, J.M., & Mackie, R.I. (2002). Characterization of fecal bacterial populations in canines: effects of age, breed and dietary fiber. *Microbial Ecology*, 44, 186-197. <https://doi.org/10.1007/s00248-002-0001-z>
- Song, S.J., Lauber, C., Costello, E.K., Lozupone, C.A., Humphrey, G., Berg-Lyons, D., Caporaso, J.G., Knights, D., Clemente, J.C., Nakielny, S., Gordon, J.I., Fierer, N., & Knight, R. (2013). Cohabiting family members share microbiota with one another and with their dogs. *Elife*, 16, e00458. <https://doi.org/10.7554/eLife.00458>
- Strachan, D.P. (1989). Hay fever, hygiene, and household size. *BMJ*, 299, 1259-1260. <https://doi.org/10.1136/bmj.299.6710.1259>
- Suchodolski, J.S., Olson, E., Honneffer, J.B., Guard, B., Blake, A., AlShawaqfeh, M., Steiner, J.M., Barr, J., & Gaschen, F. (2016). Effects of a hydrolyzed protein diet and metronidazole on the fecal microbiome and metabolome in healthy dogs. *Journal of Veterinary Internal Medicine*, 30, 1455.
- Suchodolski, J.S., Camacho, J., & Steiner, J.M. (2008). Analysis of bacterial diversity in the canine duodenum, jejunum, ileum, and colon by comparative 16S rRNA gene analysis. *FEMS Microbiology Ecology*, 66, 567-578. doi: 10.1111/j.1574-6941.2008.00521.x
- Suchodolski, J.S. (2011). Companion animals symposium: microbes and gastrointestinal health of dogs and cats. *Journal of Animal Science*, 89, 1520-1530. <https://doi.org/10.2527/jas.2010-3377>
- Tuğ, A., Hancı, İ.H., & Balseven, A. (2002). İnsan genom projesi: Umut mu, kabus mu? *Sürekli Tıp Eğitimi Dergisi*, 11, 56-57.
- Uymaz, B. (2010). Probiyotikler ve kullanım alanları. *Pamukkale Üniversitesi Mühendislik Bilimleri Dergisi*, 16(1), 95-104.
- Vientós-Plotts, A.I., Ericsson, A.C., Rindt, H., Grobman, M.E., Graham, A., Bishop, K., Cohn, L.A., & Reinero, C.R. (2017). Dynamic changes of the respiratory microbiota and its relationship to fecal and blood microbiota in healthy young cats. *PLoS One*, 9, e0173818. <https://doi.org/10.1371/journal.pone.0173818>
- Vrieze, A., Holleman, F., Zoetendal, E.G., de Vos, W.M, Hoekstra, J.B., & Nieuwdorp, M. (2010). The environment within: how gut microbiota may influence metabolism and body composition. *Diabetologia*, 53, 606-613. <https://doi.org/10.1007/s00125-010-1662-7>
- Walker, A.W., & Lawley, T.D. (2013). Therapeutic modulation of intestinal dysbiosis. *Pharmacological Research*, 69, 75-86. <https://doi.org/10.1016/j.phrs.2012.09.008>
- Whitman, W.B., Coleman, D.C., & Wiebe, W.J. (1998). Prokaryotes: the unseen majority. *Proceedings of the National Academy of Sciences*, 95, 6578-6583.
- Wold, A.E. (1998). The hygiene hypothesis revised: is the rising frequency of allergy due to changes in the intestinal flora? *Allergy*, 53, 20-25. <https://doi.org/10.1111/j.1398-9995.1998.tb04953.x>
- Yılmaz, M. (2004). Prebiyotik ve probiyotikler. *Güncel Pediatri*, 2, 142-145.



## Current classification of *Peribunyaviridae* family: genetic diversity and contributing factors

İlker ŞAHİNKESEN<sup>1,a</sup>, Fırat DOĞAN<sup>2,b</sup>, Seval BİLGE DAĞALP<sup>3,c,\*</sup>

<sup>1</sup>Ankara University, The Graduate School of Health Sciences, Department of Virology, Ankara, Türkiye; <sup>2</sup>Hatay Mustafa Kemal University, Faculty of Veterinary Medicine, Department of Virology, Hatay, Türkiye; <sup>3</sup>Ankara University, Faculty of Veterinary Medicine, Department of Virology, Ankara, Türkiye.

<sup>a</sup>ORCID: <https://orcid.org/0000-0002-1915-6908>; <sup>b</sup>ORCID: <https://orcid.org/0000-0001-8656-3645>,

<sup>c</sup>ORCID: <https://orcid.org/0000-0002-1166-721X>

\*Corresponding author: [dagalp@ankara.edu.tr](mailto:dagalp@ankara.edu.tr)

Received 02.09.2022 - Accepted 13.12.2022 - Published 31.12.2022

**Abstract:** The first detection of Bunyamwera virus in 1943 and many other antigenically related viruses identified in the following years led to the formal establishment of the *Bunyaviridae* family in 1975. This family became the *Bunyavirales* order in 2017 following proposals submitted to International Committee on Taxonomy of Viruses when the establishment of the *Peribunyaviridae* family was also approved for the *Orthobunyavirus* and *Herbertvirus* genera. The *Peribunyaviridae* family includes the *Orthobunyavirus*, *Herbertvirus*, *Pacuvirus*, and *Shangavirus* genera. Many types of viruses within this family can infect humans, mammals, plants, and insects. However, many of these viruses are transmitted by arthropod vectors without requiring mammals for their viability, which propose that Peribunyaviruses might have initially evolved as viruses that only infect insects. The leading factors contributing to genetic diversity in the *Peribunyaviridae* family are mutations and genetic reassortment. Mutations are generally detected in the M segment, which encodes the surface glycoproteins that enable viruses to avoid the immune response.

**Keywords:** Classification, genetic reassortment, mutation, *Peribunyaviridae*.

### *Peribunyaviridae* ailesinin güncel olarak sınıflandırılması: genetik çeşitlilik ve etki eden faktörler

**Özet:** İlk olarak 1943 yılında Bunyamwera virusu tespit edilmesi ve sonraki yıllarında pek çok serolojik olarak ilişkili virusun bulunması ile birlikte, 1975 yılında kurulan *Bunyaviridae* ailesi 2017 yılında *Uluslararası Virus Taksonomi Komitesi (International Committee on Taxonomy of Viruses)*'ne sunulan öneriler neticesinde *Bunyavirales* takımına yükseltilmiştir. Yine bu tarihten itibaren *Orthobunyavirus* ve *Herbertvirus* genusları için *Peribunyaviridae* ailesinin kurulması onaylanmıştır. *Peribunyaviridae* ailesi içinde *Orthobunyavirus*, *Herbertvirus*, *Pacuvirus* ve *Shangavirus* genusları bulunmaktadır. Bu aile içinde insan, memeli, bitki ve insektleri enfekte etme özelliğine sahip pek çok virus türü mevcuttur. Ailedeki pek çok virusun arthropod vektörlerle aktarılması ve virusların devamlılığı için memelilere ihtiyaç duymaması sonucu, bu virusların ilk başta sadece arthropodları enfekte eden viruslardan evrimleştiği düşünülmektedir. *Peribunyaviridae* ailesindeki genetik çeşitliliğe katkıda bulunan faktörlerin başında mutasyonlar ve genetik reassortment gelmektedir. Bazı araştırmacılar tarafından bu ailedeki çoğu virusun genetik reassortment yoluyla oluştuğu düşünülmektedir. Mutasyonlara ise en çok yüzey glikoproteinleri kodlayan M segmentinde rastlanılmakta ve bu sayede viruslar immün yanıtından kaçabilmektedir.

**Anahtar kelimeler:** Sınıflandırma, genetik reassortment, mutasyon, *Peribunyaviridae*.

## **Introduction**

The history of the classification of viruses is not as old as virus discovery. While Beijerinck was the first to detect a virus in 1898, viruses were not classified by virologists until the 1920s. The first system was generally based on pathological features. However the plant viruses were classified according to host reaction and differential host species using a binomial-trinomial nomenclature based on the name of the infected plant (Holmes, 1939). Detailed virus classification began only after the invention of the electron microscope in the 1950s. Hundreds of new viruses were then quickly discovered using this technology. Virologists at the International Microbiology Congress, held in Moscow in 1966, established the International Committee on Nomenclature of Viruses (ICNV) to develop a globally recognized nomenclature and taxonomy system for all viruses that detected so far. In 1974, this was later renamed the International Committee on Taxonomy of Viruses (ICTV) and accepted as an official organization in matters related to the nomenclature and taxonomy of viruses (Fauquet, 1999).

Viruses in the order *Bunyvirales* were named after Bunyamweravirus (BUNV), isolated from *Aedes* species in Uganda's Semliki forests during yellow fever research in 1943. Within 25 years, many other antigenically related viruses had been detected in laboratories in India, South America, and Africa (Rosenberg et al., 2013), which were first classified as Bunyamwera supergroup viruses. However, following advanced biochemical and structural analyzes, they were regrouped as the *Bunyaviridae* family in 1975 (Vaheri et al., 2013).

After further studies, the ICTV approved the promotion of the *Bunyaviridae* family to the *Bunyvirales* order. *Bunyaviridae* included five established genera of trisegmented negative-strand RNA viruses (*Hantavirus*, *Nairovirus*, *Orthobunyavirus*, *Phlebovirus*, and *Tospovirus*). Almost half of the currently known bunyaviruses have not been or cannot be assigned to these five genus based on established classification criteria. Besides, novel viruses have recently been discovered that cluster with classical trisegmented bunyaviruses in phylogenetic analyses of all their proteins, yet are bisegmented (e.g., Wūhàn millipede virus 2, South Bay virus) (Li et al., 2015; Tokarz et al., 2014). Lastly, in a large number of plant viruses with more than three genomic segments, currently members of the unassigned genera Emaravirus and Tenuivirus, have long been referred to as clearly "bunyavirus-like" based on the clustering of encoded proteins with bunyavirus proteins (Elebaino et al., 2009; van Poelwijk et al., 1997).

The ICTV Bunyaviridae study group assured to take initial steps to clarify this taxonomic confusion in 2016. A thorough reconsideration/review of the "bunyavirus-like supergroup" was agreed upon a series of Taxonomic proposals: first, to classify recently

unassigned viruses to existing genera; second, to establish novel genera to assign typical bunyaviruses that cannot be assigned to the existing five genera (Junglen, 2016); third, to accept Tenuiviruses and Emaraviruses as official members of the bunyavirus supergroup; terminally, to reorganize the family taxonomically to adequately reflect the relationships of the various now included and classified bunyaviruses while at the same time establishing taxonomic “room” for further revisions in 2017.

This work demonstrated that the existing *Bunyaviridae* family should be upgraded to the *Bunyavirales* in order to reflect the evolutionary relationships of various bunyaviruses within a broader taxonomic framework in a better way. The phylogenetic analysis of the S, M, and L (small, medium, and large) segments of Bunyaviruses indicated that the genera within the *Bunyaviridae* should be reclassified as families. The creation of the *Bunyavirales* order also required a family for the remaining two genera (*Herbivirus* and *Orthobunyavirus*). This family was named *Peribunyaviridae* (ICTV, 2017).

When classifying viruses within the *Bunyavirales* order, S, M, and L segments open reading frame (ORF) full-length products (respectively nucleocapsid protein, surface glycoproteins, and RNA-dependent RNA polymerase [RdRp]) are analyzed separately with multiple sequence alignment (MAFFT) and classified according to their similarities. As a result, the *Pacuvirus* genus was added to the *Peribunyaviridae* family (Piet et al., 2018).

**Classification of the *Peribunyaviridae* family:** According to the latest ICTV taxonomy data, there are 12 families in the *Bunyavirales* order, with four genera (*Orthobunyavirus*, *Herbivirus*, *Pacuvirus*, and *Shangavirus*) and 97 species in the *Peribunyaviridae* family (Table 1). Most of the *Peribunyaviridae* are transmitted by arthropod vectors, such as midges, mosquitoes, ticks and sandflies (Hughes et al., 2020). Most viruses in this group infect mammals, while the others infect only arthropods. Infection usually occurs during feeding by a blood-sucking arthropod. Arthropods can be persistently infected.

The infections that viruses in this family cause vary by virus type (Hughes et al., 2020). The most important species in the *Peribunyaviridae* family for veterinary medicine belong to the *Orthobunyavirus* genus. Many of them are transmitted by vectors that can cross the placental barrier in economically valuable animals and cause clinical symptoms, such as abortion, congenital anomalies, and stillbirths (Table 2).

**Table 1.** Comparison of former and current *Bunyaviridae* family classification (ICTV, 2020).

Former classification		Recent classification	
<u>Family:</u> <i>Bunyaviridae</i>	<u>Order:</u> <i>Bunyavirales</i>	<u>Family:</u> <i>Arenaviridae</i>	
<u>Genus:</u> <i>Hantavirus</i>		<i>Cruliviridae</i>	
<i>Nairovirus</i>		<i>Fimoviridae</i>	<u>Genus</u>
<i>Orthobunyavirus</i>		<i>Hantaviridae</i>	
<i>Phlebovirus</i>		<i>Leishbuviridae</i>	
<i>Tospovirus</i>		<i>Mypoviridae</i>	
		<i>Nairoviridae</i>	
		<i>Peribunyaviridae</i>	
		<i>Phasmaviridae</i>	
		<i>Phenuiviridae</i>	
		<i>Tospoviridae</i>	
		<i>Wupedeviridae</i>	

**Table 2.** *Peribunyaviridae* family members and the diseases that they cause (Amroun et al., 2017).

Family	Genus	Species	Diseases	Vector	Host	Geographical distribution
<i>Peribunyaviridae</i>	<i>Orthobunyavirus</i>	Schmallenberg orthobunyavirus	Abortion, foetal malformation, stillbirth	<i>Culicoides spp.</i>	Cattle, sheep, goat	Europe
	<i>Orthobunyavirus</i>	Akabane orthobunyavirus	Abortion, Congenital abnormalities	<i>Culicoides spp.</i>	Cattle, sheep, goat	Africa, Asia, Australia
	<i>Orthobunyavirus</i>	Bunyamwera orthobunyavirus	Fever, headache, rash, rarely CNS diseases	Mosquito	Primary human	Africa, Asia, Australia
	<i>Orthobunyavirus</i>	Aino orthobunyavirus	Abortion, foetal malformation, stillbirth	<i>Culicoides spp.</i>	Cattle, Sheep, goat, horse Just ab +	Australia, Japan, Ethiopia, Israel
	<i>Orthobunyavirus</i>	Peaton Orthobunyavirus	Abortion, foetal malformation, stillbirth	<i>Culicoides spp.</i>	Cattle, sheep, goat, horse pig, cat, dog	Japan, Australia, Israel

Infection begins when the virus enters the body via the bite of infected arthropod. The virus first targets striated muscles, causing a high level of viremia due to replication. Then, the virus spreads to organs and can cross the blood-brain barrier to reach its main target – neurons (Taylor et al., 2014). Central nervous system (CNS) infection is age-dependent, with younger animals being more susceptible than adults. For example, malformed lambs and calves born from animals infected with the Schmallenberg virus (SBV) have high levels of viral antigens in their brain tissue. Analogous findings have been reported for other peribunyaviruses with teratogenic effects (Varela et al., 2013). The genus with the most species is *Orthobunyavirus*, with 88, including important mammal pathogens (ICTV, 2020), some of which are listed in Table 3.

**Table 3.** The classification of the *Peribunyaviridae* (ICTV, 2020).

Genus	Species	Viruses
<i>Herbevirus</i>	Herbert herbevirus	Herbert virus (HEBV)
<i>Herbevirus</i>	Kibale herbevirus	Kibale virus (KIBV)
<i>Herbevirus</i>	Tai herbevirus	Tai virus (TAIV)
<i>Pacuvirus</i>	Pacui pacuvirus	Pacui virus (PACV)
<i>Pacuvirus</i>	Rio Preto da Eva pacuvirus	Rio Preto da Eva virus (RPEV)
<i>Pacuvirus</i>	Tapirape pacuvirus	Tapirapé virus (TAPV)
<i>Shangavirus</i>	Insect shangavirus	Shuāngào insect virus 1 (SgIV-1)
<i>Orthobunyavirus</i>	Acara orthobunyavirus	Acará virus (ACAV) Moriche virus (MORV)
<i>Orthobunyavirus</i>	Aino orthobunyavirus	Aino virus (AINOV)
<i>Orthobunyavirus</i>	Akabane orthobunyavirus	Akabane virus (AKAV) Tinaroo virus (TINV) Yaba-7 virus (Y7V)
<i>Orthobunyavirus</i>	Anopheles A orthobunyavirus	Anopheles A virus (ANAV) Arumateua virus (ARTV = ARMTV) Caraipé virus (CPEV = CRPV) Las Maloyas virus (LMV) Lukuni virus (LUKV) Trombetas virus (TRMV) Tucuruí virus (TUCV = TUCRV)
<i>Orthobunyavirus</i>	Anopheles B orthobunyavirus	Anopheles B virus (ANBV) Boracéia virus (BORV)
<i>Orthobunyavirus</i>	Bunyamwera orthobunyavirus	Bunyamwera virus (BUNV) Germiston virus (GERV) Lokern virus (LOKV) Mboké virus (MBOV) Ngari virus (NRIV) Northway virus (NORV) Santa Rosa virus (SARV) Shokwe virus (SHOV) Stanfeld virus (STAV) Xingu virus (XINV)
<i>Orthobunyavirus</i>	Cache Valley orthobunyavirus	Cache Valley virus (CVV) Cholul virus (CHLV) Tlacotalpan virus (TLAV)
<i>Orthobunyavirus</i>	California encephalitis orthobunyavirus	California encephalitis virus (CEV)
<i>Orthobunyavirus</i>	Gamboa orthobunyavirus	Morro Bay virus (MBV) Brus Laguna virus (BLAV) Calchaquí virus (CQIV) Gamboa virus (GAMV) Pueblo Viejo virus (PVV) Soberanía virus (SOBV)
<i>Orthobunyavirus</i>	Guama orthobunyavirus	Ananindeua virus (ANUV) Guamá virus (GMAV) Mahogany Hammock virus (MHV) Moju virus (MOJUV)
<i>Orthobunyavirus</i>	Kaeng Khoi orthobunyavirus	Kaeng Khoi virus (KKV)
<i>Orthobunyavirus</i>	La Crosse orthobunyavirus	La Crosse virus (LACV)
<i>Orthobunyavirus</i>	Leanyer orthobunyavirus	Leanyer virus (LEAV)

**Table 3 continued.** The classification of the *Peribunyaviridae* (ICTV, 2020).

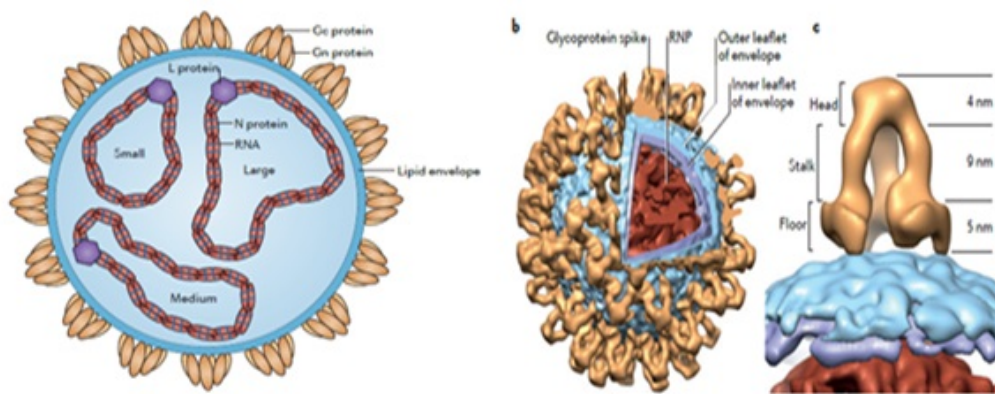
<i>Orthobunyavirus</i>	Oropouche orthobunyavirus	Iquitos virus (IQTV) Madre de Dios virus (MDDV) Oropouche virus (OROV) Perdões virus (PDEV) Pintupo virus (PINTV)
<i>Orthobunyavirus</i>	Peaton orthobunyavirus	Peaton virus (PEAV)
<i>Orthobunyavirus</i>	Schmallenberg orthobunyavirus	Douglas virus (DOUV) Sathuperi virus (SATV) Schmallenberg virus (SBV) Shamonda virus (SHAV)
<i>Orthobunyavirus</i>	Simbu orthobunyavirus	Para virus (PARAV) Simbu virus (SIMV)

Orthobunyaviruses are divided into more than 18 serogroups based upon the presence/absence or degree of serological cross-reactions using various analyses, such as hemagglutination inhibition (HI), complement fixation (CF) and neutralization assays (Calisher et al., 1983). These serogroups are Anopheles A, Anopheles B, Bakau, Gamboa, Guamá, Capim, Mapputta, Tete, Koongol, Turlock, Group C, Koongol, Nyando, Bwamba, California, Bunyamwera, Minatitlan, Simbu, Olifanstlei, Patois, Wyeomyia (Wikipedia, 2020). Within the Orthobunyavirus, the most important species for veterinary medicine are in the Simbu serogroup, particularly Akabane (AKAV), Aino (AINOV), Douglas (DOUV), Peaton (PEAV), Sabo (SABOV), Sango (SANV), Sathuperi (SATV), Schmallenberg (SBV), Shamonda (SHAV), Shuni (SHUV), and Simbuvirus (SIMV). Although some of these viruses, such as AKAV, SBV, AINOV, and PEAV, progress asymptotically in ripe sheep, cattle, and goats, they cause various CNS symptoms in fetuses infected in the second trimester of pregnancy, including arthrogryposis, torticollis, hydranencephaly, and scoliosis. Although these viruses can cause abortion throughout pregnancy, they most commonly occur in the first trimester. As the immune system develops during the last trimester of pregnancy, offspring infected at this point are usually born healthy (Uchida et al., 2000).

**Genomic features:** Members of the *Peribunyaviridae* family contain an enveloped, negative-sense, and segmented RNA genome. These segments are Small (S), Medium (M) and Large (L), each of which encodes a different protein (Elliott, 2014). The most variable segment is M, which encodes the surface glycoproteins, whereas the most stable segment is S (Wernike et al., 2015).

Peribunyaviruses encode four structural proteins. The surface glycoproteins (Gn and Gc), N (nucleocapsid) and L (viral RdRp) integral proteins. Electron microscopic images proves that purified virions have from pleomorphic to spherical particles nearly 90 nm in diameter, a

pair of membrane envelopes, and pointed spikes predicted to be glycoproteins. Virions have an average diameter of  $108 \pm 8$  nm and are pleomorphic. The glycoprotein spikes are about 18 nm long, projecting from their membranes. The spikes consist of trimers of Gn-Gc proteins with a tripod-like formation on the viral surface (Obijeski et al., 1976). Figure 1 shows the Virion structure of Peribunyavirus (Bowden et al., 2013).



**Figure 1.** Virion structure of Peribunyavirus. a: Schematic diagram of orthobunyavirus virion. Segments of orthobunyaviruses (S, M, L) are encapsulated via the N protein to form RdRp-associated Ribonucleoprotein (RNP) complexes. RNPs are packaged in a lipid envelope originating from the host cell Golgi complex modified by the addition of viral glycoprotein Gn and Gc. b: Cross-sectional model of Bunyamwera virus (BUNV) virion. c: Structure of glycoproteins on the envelope surface of peribunyaviruses. This structure consists of two interrelated proteins: the floor region adjacent to the envelope and the head region distal to the envelope. These two protein contacts are separated from each other by a stalk region (Bowden et al., 2013).

**Genome organization:** The terminal nucleotides at the 3' and 5' ends of each segment are species-specific. They form a panhandle structure that functions as a promoter for both the replication and transcription of each segment (Barr et al., 2003). In spite of the length of each coding region and the size of the encoded proteins are conserved between different Peribunyaviruses, the length and sequence of UTRs are different. Also, UTRs are required for the genomic RNA encapsulation by the N protein, termination of mRNA transcription, and packaging of RNPs into virions. (Kohl et al., 2006). The integral sequences deletion in UTRs of BUNV causes mistakes in virus attenuation and replication and eliminates its cytopathic effect (CPE) in mammalian cells. However, the mechanism has not been elucidated yet, so further studies are required (Mazel-Sanchez & Elliot., 2012).

To translate genomic RNA segments (with negative polarity), they must first transcribe into positive polarity mRNA, which occurs instantly after infection. The S segment encodes the N protein, while the M segment encodes surface glycoproteins Gc and Gn, and the L segment encodes RdRp. (Elliott & Blakqori, 2011). Glycoproteins are encoded as a precursor polyprotein, including the non-structural protein NSm. The coding sequence of the M segment

mRNA is Gn-NSm-Gc, which is simultaneously translated by host proteases to produce these three proteins (Fazakerley et al., 1988). The S segment of most orthobunyviruses encodes a second non-structural protein, NSs, translated from the same mRNA within the N protein-coding sequence while using an alternative AUG initiation codon (Fuller et al., 1983). Some Peribunyaviruses produce small amounts of NSs, while others even lack the gene region responsible for the production of this protein (Mohamed et al., 2009).

***Structural and non-structural Peribunyavirus proteins:***

***L protein:*** The L protein is the RdRp responsible for catalyzing both transcription and replication. The L protein amino-terminal domains contain an endonuclease domain that separates capped oligonucleotides from the 5' ends of the host mRNAs and is then used to initiate viral mRNA synthesis. That feature, called as 'cap snatching,' has been defined in the transcription of influenza viruses. In Peribunyaviruses, however, it occurs in the cytoplasm (Patterson et al., 1984; Reguera et al., 2010). L protein is the primary classification protein in the *Bunyvirales* order.

***Gn-Gc proteins:*** The two proteins are type I integral membrane proteins and modified by N-linked glycosylation. Gn and Gc form heterodimers in the endoplasmic reticulum. Their carriage to the Golgi complex leans on the target signal, found in the transmembrane domain of Gn in Peribunyavirus. When only Gc is expressed, it remains in the endoplasmic reticulum, that proves it needs Gn to bud from the Golgi apparatus. (Shi et al., 2004). Gc appears to have a class II fusion area. In BUNV, residue mutations around the fusion peptide in Gc dramatically reduce membrane fusion, whereas deletion of the Gc ectodomain N-terminal domain has only minimally affected virus replication (Shi et al., 2009).

The Gc surface glycoprotein N-terminal variable region is extremely immunological and the main target region of neutralizing antibodies (Hellert et al., 2019). Wernike et al. (2021) developed a triplex ELISA based on the Gc proteins of SBV, AKAV, and SHUV. Compared to the neutralization test, which is the gold standard for diagnosing Simbu serogroup viruses, the respective specificities were 84.56%, 94.68%, and 89.39%, while the respective sensitivities were 89.08%, 69.44%, and 84.91%. Although these proteins are diagnostically important, their reliability is questionable since they have many variable regions.

Recently, inactive-live attenuated vaccines have been applied in endemic areas for SBV control. Since these vaccines do not differentiate vaccinated from infected animals (DIVA), Endalew et al. (2019) developed a subunit vaccine containing SBV surface glycoproteins. However, these vaccines were ineffective after challenging infection and unable to prevent viremia or disease.



***N protein:*** N protein is a highly immunogenic protein that is the main protein produced by the infected cell. N protein encapsulates genomic-antigenomic RNA. The region that generates the signal for encapsulation is located at the 5'end. N protein also interacts with Gc, Gn, and RdRp (Shi et al., 2006).

Since an antibody response occurs in every infection against the N protein, and the S segment encoding this protein is the most conserved region in the viral genome, ELISA kits, which have been used in diagnosis and surveillance programs since 2013, have been developed based on this protein (Bréard et al., 2013).

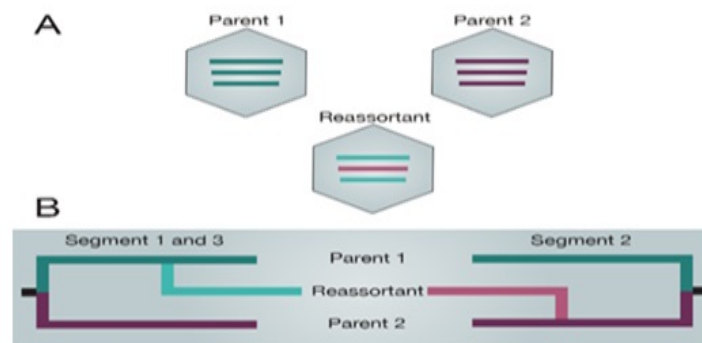
***Non-structural proteins:*** Peribunyaviruses often encode one or two non-structural proteins. The BUNV NSm protein is localized in the Golgi apparatus independently of other viral proteins and interacts with the C terminus of the Gc protein (Nakitare & Elliott, 1993). This suggests that NSm may have functions like budding and virus release related to the localization of virion particles close to the maturation zone (Lappin et al., 1994). Also, electron microscopy has demonstrated that infected cells contain new tubular structures containing cellular proteins and NSm protein. Although the NSm protein is not necessary for virus viability, the viruses with deleted NSm protein grow more slowly and have lower titers than field strains (Shi et al., 2006).

Most Peribunyaviruses encode another 10kDa non-structural protein (NSs). Unlike the N protein, the amino acid sequence of NSs are disposed to vary more among distinct Peribunyaviruses and is localized to both cytoplasm and nucleus (Thomas et al., 2004). Although the NSs protein is not essential for viral replication, this protein contributes to viral pathogenesis by playing a role in vector/host immune system interactions. The NSs protein has also been associated with apoptosis (Eifan et al., 2013). They also inhibit cellular translation in mammalian cell cultures as deletion mutants with this protein removed cannot stop cellular translation. However, NSs do not effect on protein synthesis in mosquito cell cultures (Elliott et al., 2013).

***Genetic reassortment:*** Similar to all negative-sense RNA viruses, Peribunyavirus RdRp lacks a proofreading function, leading to significant genetic heterogeneity in virus populations. Moreover, the reassortment of the genome segments observed during the co-infection of viruses belonging to the same family increases genetic diversity since they have a segmented genome. During co-infection with two different Peribunyaviruses, new reassortant viruses can occur with six distinct possibilities to those identified with parental viruses. However, there are some conditions for genomic reassortment. In particular, reassortment can only occur between closely related viruses (within the same serogroup). For Bunyamwera (BUNV) serogroup viruses, the

S and L segments appear to be genetically linked, hence commonly transmitted in pairs, whereas no such link has been observed between viruses in the California serogroup (Iroegbu & Pringle, 1981; Urquidi & Bishop, 1992).

Genetic reassortment is more frequent in arthropod vectors because, by sucking blood from different vertebrate hosts, such vectors make co-infection with two distinct Peribunyavirus species far more likely. The phenotypes of reassortant viruses vary (Beaty et al., 1983) because reassortment generally occurs in the M segment, which encodes surface glycoproteins (Figure 2). The vectors that transfer these viruses also vary. For example, if a new vector is different biologically (e.g., blood-sucking from distinct animal species), new viruses may be introduced to other hosts (Beaty et al., 1981). An instance of a phenotypic mutation is the Ngari virus. This newly formed virus is a reassortant virus with the S and L segments of BUNV but the Batai virus (BATV) M segment. BUNV and BATV only infect humans and cause febrile illness, whereas the Ngari virus is related with severe hemorrhagic disease (Briese et al., 2006).



**Figure 2.** Peribunyaviruses genome reassortment (Vijaykrishna et al., 2015).

Table 4 shows from which virus the genome segments of various Peribunyaviruses originated from and cited the relevant studies. Most peribunyaviruses are thought to result from genomic reassortment. For example, the M segment of the SBV is thought to originate from the Sathuperi virus and Douglas virus meanwhile, the S and L segments are taken from the Shamonda virus (Yanase et al., 2012).

**Table 4.** Possible genome segment organization of the heterotypic reassortant *Bunyavirales* order (Briese, 2013).

Family / Serogroup	Virus	S segment	M segment	L segment	Reference
Grup C	Itaqui	S <sub>CARV</sub>	M <sub>ORIV</sub>	L <sub>NA</sub>	Nunes et al. (2005)
Simbu	Iquitos	S <sub>OROV</sub>	M <sub>unique</sub>	L <sub>OROV</sub>	Aguilar et al. (2011)
Simbu	Aino B7974	S <sub>PEAV CSIRO110</sub>	M <sub>AINOV</sub>	L <sub>PEAVCSIRO110</sub>	Yanase et al. (2010)
Simbu	Shamonda	S <sub>SATV/DOUV</sub>	M <sub>Y7V</sub>	L <sub>{SATV/DOUV}</sub>	Goller et al. (2012)
Simbu	Schmallenberg	S <sub>{SHAV(SATV)}</sub>	M <sub>{(SATV/DOUV)}</sub>	L <sub>{SHAV/SATV}</sub>	Yanase et al. (2012)
Bunyamwera	Ngari	S <sub>BUNV</sub>	M <sub>BATV</sub>	L <sub>BUNV</sub>	Gerrard et al.(2004)
Bunyamwera	Macaua	S <sub>unique</sub>	M <sub>{(TAlAV/WYOV)}</sub>	L <sub>unique</sub>	Chowdhary et al.(2012)
Bunyamwera	Tucunduba	S <sub>TAlAV</sub>	M <sub>WYOV</sub>	L <sub>TAlAV</sub>	Chowdhary et al. (2012)
Bunyamwera	Cholul	S <sub>CVV</sub>	M <sub>POTV/KRIV</sub>	L <sub>{POTV/CVV}</sub>	Blitvich et al. (2012)
Phlebovirus	Granada	S <sub>MASV</sub>	M <sub>unique</sub>	L <sub>MASV</sub>	Collao et al. (2010)

Goller et al. (2012) compared the nucleotide sequences of SBV segments and the amino acid similarities of the proteins encoded by these segments with those in other Peribunyaviruses. The N gene nucleotide sequence was furthest from Oropouche virus (OROV) (67.8% and 67.9% aa) and closest to SHAV (97.7% and 100% aa). The L gene nucleotide sequence was furthest from OROV (60.4% and 57.4% aa) and closest to SHAV (92.9% and 98.4% aa). The M gene nucleotide sequence was closest to SATV (82.1% and 90.1% aa) and furthest from SHAV (48.2% and 36.5% aa). In general, the nucleotide sequence of the M gene region of SHAV is not similar to other Simbu serogroup viruses. For example, it is 45.6% similar to OROV on a nucleotide basis and 33.4% as aa, 55% similar to Sangovirus on a nucleotide basis and 47.9% as aa. These results prove that SHAV inherited its M segment from another virus and indicating that SATV and SBV can be classified under the same species since they are closely related.

***The life cycle of the peribunyaviruses in vectors:*** Most Peribunyaviruses are transmitted by mosquitoes and Culicoides as vectors, while Kaeng Khoi Orthobunyavirus is transmitted by bed bugs. Generally, peribunyaviruses are transmitted by one or very few arthropod vectors, even in regions with a wide variety of vector and virus species and a tight connection between vector and virus (Beaty & Calisher, 1991). Contrary to the generally persistent infection of arthropod cells, peribunyavirus infection of vertebrate cells causes a lytic

infection. The cellular interactions between the virus and the host that allow viral replication without damaging the vector are not known, even though persistent infection studies of mosquito cell cultures conducted with many Orthobunyaviruses have provided some data on the infection mechanism (Borucki et al., 2002). More specifically, the production of defective particles created by the L segment, the encapsulation of the mRNA formed by the S segment, and the self-restriction of the N protein contribute to viral persistence. In infected mosquito cells, transient morphological changes and widespread phyllopod-like structures occur in the cell in the early stages of infection. Furthermore, in virus-infected mosquito cells, the virus passes from cell to cell without damaging the cell membrane (Szemieli et al., 2012).

Female arthropods acquire the virus during blood-sucking from infected hosts. Infected arthropods vary their feeding behavior, such as sucking blood from different host species (Reese et al., 2009). Arthropods are persistently and systematically infected. Vertical (transovarial) transmission has also been reported in some peribunyavirus infections. Transovarial transmission is an significant mechanism for the survival of some peribunyaviruses, especially during the winter months. Many peribunyaviruses are transmitted by arthropod vectors and do not require mammals for their viability. This propose that they initially evolved as the viruses that only infect insects. The recent confirmation of this is that viruses isolated from different biting midge species (such as Herbert virus-Herbert associated viruses) do not replicate in vertebrate cells and are phylogenetically classified as Peribunyavirus (Hughes et al., 2020).

***The mechanism for evading innate immunity in vertebrate cells:*** The foreign molecules known as pathogen-associated molecular patterns (PAMPs) are identified by Pattern recognition receptors (PRRs). In the case of viruses, these pathogen-related molecules include different forms of nucleic acids, such as dsRNA and 5' triphosphorylated RNA. Melanoma differentiation-associated protein 5 (MDA5) and retinoic acid-inducible gene I (RIG-I) which are RNA helicases recognize these foreign molecules intracellularly (Randall & Goodbourn, 2008). The linking of an RNA ligand to these PRRs activates the signal chain that stimulates the expression of several transcription factors [nuclear factor- $\kappa$ B (NF-  $\kappa$ B), IFN regulatory factor 3 (IRF3)] and cyclic AMP-dependent transcription factor (ATF2). This stimulates interferon-(IFN $\beta$ ) transcription which causes to the upregulation of hundreds of IFN-induced genes (ISG) (Schoggins & Rice, 2011). Recently, RIGI was reported to recognize the La Crosse encephalitis virus (LACV) nucleocapsid containing 5' triphosphate and terminal panhandle, and recognition precedes transcription. This situation shows that the innate immune response is triggered at the first stage of infection, namely, after viral entry (Weber et al., 2013). There is minimal information about that the antiviral activities of most ISG products but but they

presumably restrict the viral replication at the many stages. For example, MxA protein binds to the newly synthesized N protein and inhibits LACV and BUNV replication, which blocks replication. Interferon (IFN) released from mammalian cells is extremely potent in controlling virus replication. The cause of the replication restriction of Orthobunyaviruses in cells pretreated with IFN has been reported. NSs proteins of BUNV, LACV, and SBV reduce IFN release in mammalian cells (Carlton-Smith & Elliott, 2012).

Hofmann et al. (2015) demonstrated the genetic stability of SBV by comparing the nucleotide sequence of the field isolate identified during the Swiss epidemic in 2012 with SBV isolates in GenBank. They found 101 mutations, mostly randomly distributed along the L and M segments, specifically in sequence between nucleotides 2100 and 2300 of the M segment and nucleotide 2000 of the L segment. The S segments were conserved, while changes in the amino acid level were seen in the highly variable region at the center of the M segment. In contrast, mutations in the L segment did not change amino acid sequences. Coupeau et al. (2013) demonstrated that the greatest genomic variability in viruses isolated during the SBV epidemic in Belgium was in the region encoding the N-terminal domain of the Gc protein in the M segment (1394–2562 nucleotide sequences). They concluded that mutations in the Gc protein might help the virus evade the immune response. Given that this protein is highly immunological and stimulates the neutralizing antibody response in the host when its structure changes, the virus can evade the immune response because previously formed antibodies cannot fully recognize the new structure.

### **Conclusion**

The classification of viruses is constantly changing due to the detection of new viruses, mutations that change amino acid levels, and genetic reassortment in segmented viruses as new viruses are formed. The most important factor contributing to the genetic diversity of Peribunyaviruses is genetic reassortment, which is observed in most segmented viruses. Segment reassortment usually takes place in arthropods co-infected with two distinct peribunyaviruses. As in all viruses, another factor contributing to genetic diversity is mutations. Most mutations in Peribunyaviruses occur in the M segment, particularly in the highly variable region of the Gc surface glycoprotein coding sequence, which helps the virus evade the immune response.

### **Financial Support**

This research received no grant from any funding agency/sector.

## Ethical Statement

This study does not present any ethical concerns.

## Conflict of Interest

The authors declared that there is no conflict of interest.

## References

- Aguilar, P. V., Barrett, A. D., Saeed, M. F., Watts, D. M., Russell, K., Guevara, C., & Kochel, T. J. (2011). Iquitos virus: a novel reassortant *Orthobunyavirus* associated with human illness in Peru. *Plos Neglected Tropical Diseases*, 5(9), e1315. <https://doi.org/10.1371/journal.pntd.0001315>
- Amroun, A., Priet, S., de Lamballerie, X., & Quérat, G. (2017). *Bunyaviridae* RdRps: structure, motifs, and RNA synthesis machinery. *Critical Reviews in Microbiology*, 43(6), 753-778. <https://doi.org/10.1080/1040841X.2017.1307805>
- Barr, J. N., Elliott, R. M., Dunn, E. F., & Wertz, G. W. (2003). Segment-specific terminal sequences of Bunyamwera bunyavirus regulate genome replication. *Virology*, 311, 326–338. [https://doi.org/10.1016/S0042-6822\(03\)00130-2](https://doi.org/10.1016/S0042-6822(03)00130-2)
- Beaty, B. J., Bishop, D. H., Gay, M., & Fuller, F. (1983). Interference between bunyaviruses in *Aedes triseriatus* mosquitoes. *Virology*, 127, 83-90. [https://doi.org/10.1016/0042-6822\(83\)90373-2](https://doi.org/10.1016/0042-6822(83)90373-2)
- Beaty, B. J., Holterman, M., Tabachnick, W., Shope, R. E., Rozhon, E. J., & Bishop, D. H. (1981). Molecular basis of bunyavirus transmission by mosquitoes: role of the middle-sized RNA segment. *Science*, 211(4489), 1433-1435. <https://doi.org/10.1126/science.6781068>
- Beaty, B., & Calisher, C. (1991). *Bunyaviridae* - natural history. *Current Topics in Microbiology and Immunology*, 169, 27-78. [https://doi.org/10.1007/978-3-642-76018-1\\_2](https://doi.org/10.1007/978-3-642-76018-1_2)
- Blitvich, B. J., Saiyasombat, R., Dorman, K. S., Garcia-Rejon, J. E., Farfan-Ale, J. A., & Lorono-Pino, M. A. (2012). Sequence and phylogenetic data indicate that an orthobunyavirus recently detected in the Yucatan Peninsula of Mexico is a novel reassortant of Potosi and Cache Valley viruses. *Archives of Virology*, 157(6), 1199-1204.
- Borucki, M. K., Kempf, B. J., Blitvich, B. J., Blair, C. D., & Beaty, B. J. (2002). La Crosse virus: Replication in vertebrate and invertebrate hosts. *Microbes and Infection*, 4, 341–350. [https://doi.org/10.1016/S1286-4579\(02\)01547-2](https://doi.org/10.1016/S1286-4579(02)01547-2)
- Bowden, T. A., Bitto, D., McLees, A., Yeromonahos, C., Elliott, R. M., & Huiskonen, J. T. (2013). Orthobunyavirus ultrastructure and the curious tripodal glycoprotein spike. *PLoS Pathogens*, 9(5), e1003374. <https://doi.org/10.1371/journal.ppat.1003374>
- Bréard, E., Lara, E., Comtet, L., Viarouge, C., Doceul, V., Desprat, A., & Zientara, S. (2013). Validation of a commercially available indirect ELISA using a nucleocapside recombinant protein for detection of Schmallenberg virus antibodies. *Plos One*, 8(1), e53446. <https://doi.org/10.1371/journal.pone.0053446>
- Briese, T., Bird, B., Kapoor, V., Nichol, S. T., & Lipkin, W. I. (2006). Batai and Ngari viruses: M segment reassortment and association with severe febrile disease outbreaks in East Africa. *Journal of Virology*, 80, 5627-5630. <https://doi.org/10.1128/JVI.02448-05>
- Briese, T., Calisher, C. H., & Higgs, S. (2013). Viruses of the family *Bunyaviridae*: Are all available isolates reassortants?. *Virology*, 446(1-2), 207-216. <https://doi.org/10.1016/j.virol.2013.07.030>
- Calisher, C.H. (1983). Taxonomy, classification, and geographic distribution of californica serogroup bunyaviruses. *Progress in Clinical and Biological Research*, 123, 1-16.
- Carlton-Smith, C., & Elliott, R. M. (2012). Viperin, MTAP44 and protein kinase R contribute to the interferon-induced inhibition of Bunyamwera orthobunyavirus replication. *Journal of Virology*, 86, 11548-11557. <https://doi.org/10.1128/JVI.01773-12>
- Chowdhary, R., Street, C., da Rosa, A. T., Nunes, M. R., Tee, K. K., Hutchison, S. K., & Briese, T. (2012). Genetic characterization of the Wyeomyia group of orthobunyaviruses and their phylogenetic relationships. *Journal of General Virology*, 93(5), 1023-1034. <https://doi.org/10.1099/vir.0.039479-0>
- Collao, X., Palacios, G., de Ory, F., Sanbonmatsu, S., Pérez-Ruiz, M., Navarro, J. M., & Sánchez-Seco, M. P. (2010). Granada virus: a natural phlebovirus reassortant of the sandfly fever Naples serocomplex with low seroprevalence in humans. *The American Journal of Tropical Medicine and Hygiene*, 83(4), 760. <https://doi.org/10.4269/ajtmh.2010.09-0697>

- Coupeau, D., Clain, F., Wiggers, L., Kirschvink, N., & Muylkens, B. (2013). In vivo and in vitro identification of a hypervariable region in Schmallenberg virus. *Journal of General Virology*, *94*, 1168-1174. <https://doi.org/10.1099/vir.0.051821-0>
- Eifan, S., Schnettler, E., Dietrich, I., Kohl, A., & Blomstrom, A. L. (2013). Non-structural proteins of arthropod-borne bunyaviruses: Roles and functions. *Viruses*, *5*, 2447-2468. <https://doi.org/10.3390/v5102447>
- Elbeaino, T., Digiario, M., & Martelli, G.P. (2009). Complete nucleotide sequence of four RNA segments of fig mosaic virus. *Archives of Virology*, *154*, 1719-1727.
- Elliott, R. M., & Blakqori, G. (2011). *Bunyaviridae*. In: A. Plyusnin, R. M. Elliott. (Ed.) *Molecular and cellular biology*. (pp.1-39). Caister Academic Press.
- Elliott, R. M., Blakqori, G., van Knippenberg, I. C., Koudriakova, E., Li, P., McLees, A., & Szemiel, A. M. (2013). Establishment of a reverse genetics system for Schmallenberg virus, a newly emerged orthobunyavirus in Europe. *The Journal Of General Virology*, *94*(4), 851. <https://doi.org/10.1099/vir.0.049981-0>
- Elliott, R.M. (2014). Orthobunyaviruses: Recent genetic and structural insights. *Nature Reviews Microbiology*, *12*(10), 673-685.
- Endalew, A. D., Faburay, B., Trujillo, J. D., Gaudreault, N. N., Davis, A. S., Shivanna, V., & Richt, J. A. (2019). Immunogenicity and efficacy of Schmallenberg virus envelope glycoprotein subunit vaccines. *Journal of Veterinary Science*, *20*(6), e58. <https://doi.org/10.4142/jvs.2019.20.e58>
- Fauquet, C. M. (1999). Taxonomy, classification and nomenclature of viruses. *Encyclopedia of Virology*, 1730. <https://doi.org/10.1006/rwvi.1999.0277>
- Fazakerley, J. K., Gonzalez-Scarano, F., Strickler, J., Dietzschold, B., Karush, F., & Nathanson, N. (1988). Organization of the middle RNA segment of snowshoe hare Bunyavirus. *Virology*, *167*(2), 422-432. [https://doi.org/10.1016/0042-6822\(88\)90104-3](https://doi.org/10.1016/0042-6822(88)90104-3)
- Fuller, F., Bhowan, A. S., & Bishop, D. H. (1983). Bunyavirus nucleoprotein, N, and a non-structural protein, NSS, are coded by overlapping reading frames in the S RNA. *Journal of General Virology*, *64*, 1705-1714. <https://doi.org/10.1099/0022-1317-64-8-1705>
- Gerrard, S. R., Li, L., Barrett, A. D., & Nichol, S. T. (2004). Ngari virus is a Bunyamwera virus reassortant that can be associated with large outbreaks of hemorrhagic fever in Africa. *Journal of Virology*, *78*(16), 8922-8926. <https://doi.org/10.1128/JVI.78.16.8922-8926.2004>
- Goller, K.V., Höper, D., Schirmer, H., Mettenleiter, T.C., & Beer, M. (2012). Schmallenberg virus as possible ancestor of Shamonda virus. *Emerging Infectious Diseases*, *18*, 1644-1646. <https://doi.org/10.3201/eid1810.120835>
- Hellert, J., Aebischer, A., Wernike, K., Haouz, A., Brocchi, E., Reiche, S., & Rey, F. A. (2019). Orthobunyavirus spike architecture and recognition by neutralizing antibodies. *Nature Communications*, *10*(1), 1-14.
- Hofmann, M. A., Mader, M., Flückiger, F., & Renzullo, S. (2015). Genetic stability of Schmallenberg virus in vivo during an epidemic, and in vitro, when passaged in the highly susceptible porcine SK-6 cell line. *Veterinary Microbiology*, *176*(1-2), 97-108. <https://doi.org/10.1016/j.vetmic.2015.01.010>
- Holmes, F.O. (1939). Proposal for extension of the binomial system of nomenclature to include viruses. *Phytopathology*, *29*, 431-436.
- Hughes, H.R., Adkins, S., Alkhovskiy, S., Beer, M., Blair, C., Calisher, C.H., Drebot, M., Lambert, A.J., de Souza, W.M., Marklewitz, M., Nunes, M.R.T., Shi, X., & ICTV Report Consortium (2020). ICTV Virus Taxonomy Profile: *Peribunyaviridae*. *Journal of General Virology*, *101*(1) 1-2. <https://doi.org/10.1099/jgv.0.001365>
- ICTV (2017). Available at <https://talk.ictvonline.org/taxonomy/>. (Accessed 01.11.2020).
- ICTV (2020). Available at <https://talk.ictvonline.org/taxonomy/>. (Accessed 01.12.2020).
- Iroegbu, C. U., & Pringle, C. R. (1981). Genetic interactions among viruses of the Bunyamwera complex. *Journal of Virology*, *37*, 383-394. <https://doi.org/10.1128/jvi.37.1.383-394.1981>
- Junglen, S. (2016). Evolutionary origin of pathogenic arthropod-borne viruses – a case study in the family Bunyaviridae. *Archives of Virology*, *154*, 1719-1727. <https://doi.org/10.1016/j.cois.2016.05.017>
- Kohl, A., Lowen, A. C., Leonard, V. H. J., & Elliott, R. M. (2006). Genetic elements regulating packaging of the Bunyamwera orthobunyavirus genome. *Journal of General Virology*, *87*, 177-187. <https://doi.org/10.1099/vir.0.81227-0>
- Kolakofsky, D., Bellocq, C., & Raju, R. (1987). The translational requirement for La Crosse virus S-mRNA synthesis. *Cold Spring Harbor Symposia on Quantitative Biology*, *52*, 373-379. <https://doi.org/10.1101/SQB.1987.052.01.043>
- Lappin, D. F., Nakitare, G. W., Palfreyman, J. W., & Elliott, R. M. (1994). Localisation of Bunyamwera bunyavirus G1 glycoprotein to the Golgi requires association with G2 but not NSm. *Journal of General Virology*, *75*, 3441-3451. <https://doi.org/10.1099/0022-1317-75-12-3441>

- Li, C.X., Shi, M., Tian, J.H., Lin, X.D., Kang, Y.J., Chen, L.J., Qin, X.C., Xu, J., Holmes, E.C., & Zhang, Y.Z. (2015). Unprecedented genomic diversity of RNA viruses in arthropods reveals the ancestry of negative-sense RNA viruses. *Elife*, 4, e05378. <https://doi.org/10.7554/eLife.05378>
- Mazel-Sanchez, B. & Elliott, R. M. (2012). Attenuation of Bunyamwera orthobunyavirus replication by targeted mutagenesis of genomic UTRs and creation of viable viruses with minimal genome segments. *Journal of Virology*, 86, 13672-13678. <https://doi.org/10.1128/JVI.02253-12>
- Mohamed, M., McLees, A., & Elliott, R. M. (2009). Viruses in the Anopheles A, Anopheles B, and Tete serogroups in the Orthobunyavirus genus (family *Bunyaviridae*) do not encode an NSs protein. *Journal of Virology*, 83, 7612-7618. <https://doi.org/10.1128/JVI.02080-08>
- Nakitare, G. W., & Elliott, R. M. (1993). Expression of the Bunyamwera virus M genome segment and intracellular localisation of NSm. *Virology*, 195, 511-520. <https://doi.org/10.1006/viro.1993.1402>
- Nunes, M. R., Travassos da Rosa, A. P., Weaver, S. C., Tesh, R. B., & Vasconcelos, P. F. (2005). Molecular epidemiology of group C viruses (*Bunyaviridae*, *Orthobunyavirus*) isolated in the Americas. *Journal of Virology*, 79(16), 10561-10570. <https://doi.org/10.1128/JVI.79.16.10561-10570.2005>
- Obijeski, J. F., Bishop, D. H., Murphy, F. A., & Palmer, E. L. (1976). Structural proteins of La Crosse virus. *Journal of Virology*, 19, 985-997. <https://doi.org/10.1128/jvi.19.3.985-997.1976>
- Patterson, J. L., Holloway, B., & Kolakofsky, D. (1984). La Crosse virions contain a primer-stimulated RNA polymerase and a methylated cap-dependent endonuclease. *Journal of Virology*, 52, 215-222. <https://doi.org/10.1128/jvi.52.1.215-222.1984>
- Piet, R., Kalil, B., McLennan, T., Porteous, R., Czielesky, K., Herbison, A.E. (2018). Dominant neuropeptide cotransmission in kisspeptin-GABA regulation of GnRH neuron firing driving ovulation. *Journal of Neuroscience*. 38, 6310-6322. <https://doi.org/10.1523/JNEUROSCI.0658-18>
- Randall, R. E., & Goodbourn, S. (2008). Interferons and viruses: an interplay between induction, signalling, antiviral responses and virus countermeasures. *Journal of General Virology*, 89, 1-47. <https://doi.org/10.1099/vir.0.83391-0>
- Reese, S. M., Beaty, M. K., Gabitzsch, E. S., Blair, C. D., & Beaty, B. J. (2009). *Aedes triseriatus* females transovarially infected with La Crosse virus mate more efficiently than uninfected mosquitoes. *Journal of Medical Entomology*, 46, 1152-1158. <https://doi.org/10.1603/033.046.0524>
- Reguera, J., Weber, F., & Cusack, S. (2010). *Bunyaviridae* RNA polymerases (L-protein) have an N-terminal, influenza-like endonuclease domain, essential for viral cap-dependent transcription. *PLoS Pathogens*, 6, e1001101. <https://doi.org/10.1371/journal.ppat.1001101>
- Rosenberg, R., Johansson, M. A., Powers, A. M., & Miller, B. R. (2013). Search strategy has influenced the discovery rate of human viruses. *Proceedings of the National Academy of Sciences*, 110, 13961-13964. <https://doi.org/10.1073/pnas.1307243110>
- Schoggins, J. W., & Rice, C. M. (2011). Interferon-stimulated genes and their antiviral effector functions. *Current Opinion in Virology*, 1, 519-525. <https://doi.org/10.1016/j.coviro.2011.10.008>
- Shi, X., Goli, J., Clark, G., Brauburger, K., & Elliott, R. M. (2009). Functional analysis of the Bunyamwera orthobunyavirus Gc glycoprotein. *The Journal of General Virology*, 90, 2483-2492. <https://doi.org/10.1099/vir.0.013540-0>
- Shi, X., Kohl, A., Léonard, V. H., Li, P., McLees, A., & Elliott, R. M. (2006). Requirement of the N-terminal region of orthobunyavirus nonstructural protein NSm for virus assembly and morphogenesis. *Journal of Virology*, 80(16), 8089-8099. <https://doi.org/10.1128/JVI.00579-06>
- Shi, X., Lappin, D. F., & Elliott, R. M. (2004). Mapping the Golgi targeting and retention signal of Bunyamwera virus glycoproteins. *Journal of General Virology*, 78, 10793-10802. <https://doi.org/10.1128/JVI.78.19.10793-10802.2004>
- Szemieli, A. M., Failloux, A. B., & Elliott, R. M. (2012). Role of Bunyamwera orthobunyavirus NSs protein in infection of mosquito cells. *PLOS Neglected Tropical Diseases*, 6, e1823. <https://doi.org/10.1371/journal.pntd.0001823>
- Taylor, K. G., & Peterson, K. E. (2014). Innate immune response to La Crosse virus infection. *Journal of Neurovirology*, 20, 150-156.
- Thomas, D., Blakqori, G., Wagner, V., Banholzer, M., Kessler, N., Elliott, R. M., & Weber, F. (2004). Inhibition of RNA polymerase II phosphorylation by a viral interferon antagonist. *Journal of Biological Chemistry*, 279(30), 31471-31477. <https://doi.org/10.1074/jbc.M400938200>
- Tokarz, R., Williams, S.H., Sameroff, S., Sanchez, L.M, Jain, K., & Lipkin, W.I. (2014). Virome analysis of *Amblyomma americanum*, *Dermacentor variabilis*, and *Ixodes scapularis* ticks reveals novel highly divergent vertebrate and invertebrate viruses. *Journal of Virology*, 88, 11480-11492. <https://doi.org/10.1128/JVI.01858-14>
- Uchida, K., Murakami, T., Sueyoshi, M., Tsuda, T., Inai, K., Acorda, J.A., & Tateyama, S. (2000). Detection of Akabane viral antigens in spontaneous lymphohistiocytic encephalomyelitis in cattle. *Journal of Veterinary Diagnostic Investigation*, 12(6), 518-524. <https://doi.org/10.1177/104063870001200605>



- Urquidi, V., & Bishop, D. H. (1992). Non-random reassortment between the tripartite RNA genomes of La Crosse and snowshoe hare viruses. *Journal of General Virology*, 73, 2255-2265. <https://doi.org/10.1099/0022-1317-73-9-2255>
- Vaheri, A., Strandin, T., Hepojoki, J., Sironen, T., Henttonen, H., Mäkelä, S., & Mustonen, J. (2013). Uncovering the mysteries of hantavirus infections. *Nature Reviews Microbiology*, 11(8), 539-550.
- Van Poelwijk, F., Prins, M., & Goldbach, R. (1997). Completion of the impatiens necrotic spot virus genome sequence and genetic comparison of the L proteins within the family *Bunyaviridae*. *Journal of General Virology*, 78(3), 543-546. <https://doi.org/10.1099/0022-1317-78-3-543>
- Varela, M., Schnettler, E., Caporale, M., Murgia, C., Barry, G., McFarlane, M., & Palmarini, M. (2013). Schmallenberg virus pathogenesis, tropism and interaction with the innate immune system of the host. *PLoS Pathogenes*, 9(1), e1003133. <https://doi.org/10.1371/journal.ppat.1003133>
- Weber, M., Gawanbacht, A., Habjan, M., Rang, A., Borner, C., Schmidt, A. M., Veitinger, S., Jacob, R., Devignot, S., Kochs, G., García-Sastre, A., & Weber, F. (2013). Incoming RNA virus nucleocapsids containing a 5'-triphosphorylated genome activate RIG-I and antiviral signaling. *Cell Host & Microbe*, 13(3), 336-346. <https://doi.org/10.1016/j.chom.2013.01.012>
- Wernike, K., Aebischer, A., Sick, F., Szillat, K. P., & Beer, M. (2021). Differentiation of Antibodies against Selected Simbu Serogroup Viruses by a Glycoprotein Gc-Based Triplex ELISA. *Veterinary Sciences*, 8(1), 12. <https://doi.org/10.3390/vetsci8010012>
- Wernike, K., Hoffmann, B., Conraths, F. J., & Beer, M. (2015). Schmallenberg virus recurrence, Germany, 2014. *Emerging Infectious Diseases*, 21(7), 1202. <https://doi.org/10.3201/eid2107.150180>
- Vijaykrishna, D., Mukerji, R., & Smith, G.J.D. (2015). RNA Virus Reassortment: An Evolutionary Mechanism for Host Jumps and Immune Evasion. *PLoS Pathog*, 11(7): e1004902. <https://doi.org/10.1371/journal.ppat.1004902>
- Wikipedia (2020). Available at <https://en.wikipedia.org/wiki/Orthobunyavirus>. (Accessed 31.12.2020).
- Yanase, T., Aizawa, M., Kato, T., Yamakawa, M., Shirafuji, H., & Tsuda, T. (2010). Genetic characterization of Aino and Peaton virus field isolates reveals a genetic reassortment between these viruses in nature. *Virus Research*, 153(1), 1-7. <https://doi.org/10.1016/j.virusres.2010.06.020>
- Yanase, T., Kato, T., Aizawa, M., Shuto, Y., Shirafuji, H., Yamakawa, M., & Tsuda, T. (2012). Genetic reassortment between Sathuperi and Shamonda viruses of the genus Orthobunyavirus in nature: implications for their genetic relationship to Schmallenberg virus. *Archives of Virology*, 157(8), 1611-1616.