

# APIC 2019 Meeting

,

*Advanced Peripheral Interventions Course*  
*Acute Stroke Intervention Course*

*21-23 February Kayseri*



# Carotid Artery Endarterectomy without Shunting and with Primary Repair

Erhan Kaya, Omer Isik

*Private Pendik Regional Hospital, Department of Cardiovascular Surgery, Istanbul, Turkey*

## INTRODUCTION

Surgical endarterectomy is recommended as the first choice in the treatment of carotid artery stenosis. Shunt application for continuity of cerebral perfusion and closure of arteriotomy with primary repair or patchplasty during surgery is varied according to clinical experience. In this article, we are reporting our experience of primary repair without shunting.

## METHODS

Patients who underwent surgery for carotid artery stenosis in our clinic between 01.02.2018-30.11.018 were retrospectively analysed. Patients undergoing selective carotid artery endarterectomy were included in the study. Patients who underwent simultaneous coronary artery surgery were excluded from the study. We evaluated the perioperative and postoperative one-month follow-up of the patients.

## RESULTS

Carotid endarterectomy was performed in 27 patients during the study period. The mean age of the patients was  $70.8 \pm 9$  and 19 (70.4%) were male. All operations were performed without shunt and primary repair. The mean clamping time was  $6.7 \pm 0.9$  minutes. In the postoperative follow up, there were hoarseness and difficulty in swallowing in 1 patient; and hemiparesis and dysarthria in 1 patient. All symptoms were disappeared within 2 weeks. There was no mortality during the hospitalization and postoperative one month follow-up.

## DISCUSSION

During the surgery of the carotid artery, shunting and patchplasty techniques increase the duration of surgery and manipulation. Rapid endarterectomy and primary repair of the arteriotomy might be performed safely in the experienced centers with acceptable postoperative outcomes.

## Keywords

Endarterectomy, Carotid stenosis, Primary repair, Patchplasty

# Removal of Broken Hydrophilic Diagnostic Catheter In The Carotid Artery

Hakkı Şimşek, Aziz Karabulut, Barış Acun

Department of Cardiology, Dicle University, Diyarbakır, Turkey

## INTRODUCTION

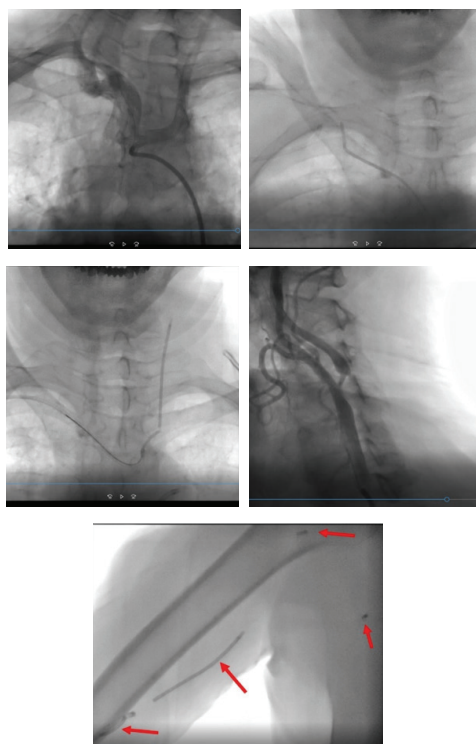
We aimed to present a case of the removal of broken hydrophilic diagnostic catheter in the carotid artery

## CASE PRESENTATION

76 years old male patient was admitted our hospital. He had a TIA twenty days ago. DM and HT were present in his medical history. Physical examination was normal ECG showed nonspecific changes available. Echocardiography showed that LVEF was 55% and mild mitral insufficiency. In doppler USG 90% stenosis was detected in the left ICA proximal and right carotid vessel had no important stenosis. As angiography revealed 80% stenosis in proximal ICA, we decided to perform endovascular intervention. Due to the bovine arc, 0.035 wires were requested to be sent to the carotid artery with the support of hydrophilic diagnostic catheter. Although the wire was sent several times, the diagnostic catheter could not be advanced sufficiently into the carotid artery and the distal part of the catheter was broken in the main carotid artery. Any neurological symptoms did not develop in the patient.

## RESULTS

While trying to remove the broken part of the catheter with a snare by entering through the left brachial artery, the catheter was broken off each time where it was caught and divided into 5 different parts. Parts were captured by snare. The neurological status of patient was stable during management of complication. The left carotid system was selectively visualized by the brachial route and 80% stenosis was detected in the ICA.



## DISCUSSION

Before we perform endovascular carotid artery intervention, we should check carotid artery anatomy properly. We should have information about variant of aortic arch. In unsuitable anatomies, we should consider the complication risk and no to be insistent. Especially hydrophilic guiding catheters should not be reused overmuch.

## Keywords

carotid artery, complication, hidrophilic catheter



# Akut İskemik İnmenin Endovasküler Tedavisi Ve Serebral Kollateral Dolaşım

Recep Baydemir<sup>1</sup>, Özlem Aykaç<sup>2</sup>, Atilla Özcan Özdemir<sup>2</sup>

<sup>1</sup> Department of Neurology, Erciyes University, Kayseri, Turkey

<sup>2</sup> Department of Neurology, Eskişehir Osmangazi University, Eskişehir, Turkey

## GİRİŞ-AMAÇ

Akut iskemik inmenin endovasküler tedavisi son yayınlanan randomize kontrollü çalışmalar ile (MR CLEAN, ESCAPE, REVASCAT, SWIFT PRIME, ve EXTEND IA) standart tedavi haline gelmiştir. İşlemin başarısı zaman bağımlıdır. Ancak, yeterli kollaterallerin varlığı bu tedavinin etkisini potansiyalize eden en önemli faktörlerden biridir. Akut anterior iskemik inme nedeniyle endovasküler tedavi uygulanan ve farklı kollateral dolaşımı olan iki olguyu literatür eşliğinde sunuyoruz.

## OLGU 1

Altı saat önce sol tarafında kuvvet kaybı gelişmesi üzerine getirilen 54 yaşındaki erkek hastanın geliş muayenesinde; bilinç uykuya meyilli, konuşması ağır dizartrikti. Kas gücü sol ekstremitede üstte 0/5, alt ekstremitede ise 1/5'ti. NIHSS skoru 16 olarak değerlendirildi. Bilgisayarlı tomografi anjiyografide (BTA) sağ orta serebral arter(MCA) M1 segmenti oklüde izlendi. Ancak kollateral dolaşım skoru düşüktü. İlk anamneze göre 2 saatlik olarak değerlendirilen hasta nöroanjiyografi suiteine alındı. İki pass yapılarak Thrombolysis in cerebral infarction skoru (TICI) 3 rekanalizasyon sağlandı.Takiplerinde klinik düzelme izlenmedi. Kontrol nörogörüntülemesinde yaygın ödem ve orta hatta şift izlendi. Hastaya dekompresif cerrahi uygulandı. Gelişinin 6. gününde hasta eksitus oldu.

## OLGU 2

74 yaşında kadın hasta, bir saat önce gelişen konuşma bozukluğu ve solda kuvvet kaybı nedeniyle getirildi. Özgeçmişinde hipertansiyon ve atrial fibrilasyon olan hastanın nörolojik muayenesi; şuur açık, sağa zorlu baş

deviasyonu, sol santral fasial paralizi, solda kas gücü üstte 0/5, altta 2/5'ti. NIHSS skoru 14 olarak değerlendirildi. BTA'da sağ MCA M1 segmenti oklüde izlendi. Kollateral skoru iyi idi. Endovasküler tedaviye alındı. Üç pass yapılarak TICI 2b rekanalizasyon sağlandı. İşlem sonrası 24. saatte yapılan nörolojik muayenesi normaldi. Medikal tedavisi düzenlenerek taburcu edildi

## TARTIŞMA

Proksimal damar oklüzyonuna bağlı akut iskemik inmede erken revaskülarizasyon sağlanamadığında mortalite ve morbidite oranı oldukça yüksektir. Yeni gelişen teknolojik cihazlarla rekanalizasyon oldukça etkili bir şekilde sağlanmaktadır. Çalışmalarda %80'lere varan revaskülarizasyon oranlarına rağmen iyi klinik sonuçların aynı oranda olmadığı görülmektedir. Başarılı revaskülarizasyona rağmen yeterli perfüzyonun sağlanamamasının en önemli nedenlerinden biri kollateral dolaşımın durumudur. Kollateral skoru akut iskemik inmenin endovasküler tedavisinde prognozu etkileyen önemli faktörlerdendir. Çalışmalar, endovasküler tedavi öncesi iyi kollateral skorunun, işlem sonrası fonksiyonel bağımsızlıkla güçlü bir ilişkinin olduğunu göstermektedir. MR CLEAN ve IMS 3 çalışmalarında da kollateral skoru kötü hasta grubunda semptomatik hemoraji oranı ve üçüncü ay modifiye rankin skoru (mRS) yüksek bulunmuştur. Kollateral dolaşım, uygun zaman penceresi dışında gelen endovasküler tedavi düşünülen hastalarda tedaviye karar vermekte bir faktör olarak değerlendirilebilir.

## Anahtar Kelimeler

stroke, endovascular, collateral

## Perkütan Stentleme Tekniği ile Tedavi Edilen Komplike Karotis Arter Darlığı Olgusu

Faruk Ertaş, Halit Acet, Tuncay Güzel, Bayram Arslan, Raif Kılıç, Barış Acun, Nizamettin Toprak

Department of Cardiology, Dicle University, Diyarbakır, Turkey

### OLGU

Hipertansiyon, 30 paket/yıl sigara ve iki ay önce SVO geçirme öyküsü olan 58 yaşında erkek hasta; dış merkezde çekilen Karotis Doppler USG'de bilateral karotis darlıkları olması üzerine yapılan karotis anjiyografisinde sol internal karotis arter (İKA) total tıkalı ve sağ İKA'da %90, darlıklar saptandı (Resim 1A ve B Video1). Hastanın sol İKA'sının tıkalı olması, sağ İKA'da ciddi darlık saptanması nedeniyle sağ tarafa girişim yapılması planlandı. Hastaya uygun antiagregan ve antikoagülanla premedikasyon yapıldı. 8F guiding kateterle sağ CCA'ye oturuldu. Sağ İKA'deki darlığın distaline spider Fx distal koruma cihazı yerleştirildi. Sağ İKA'deki lezyona direkt olarak 10-7-40 mm Protege RX stent kendiliğinden genişleyebilen stent lezyonu kaplay-

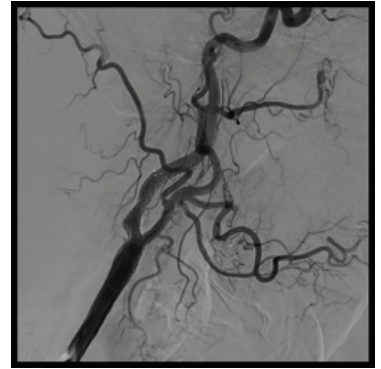
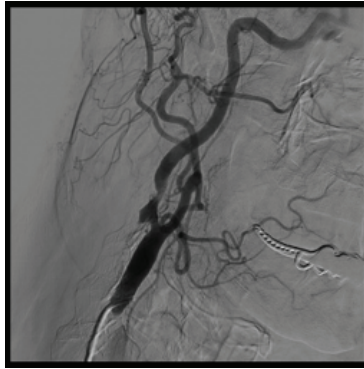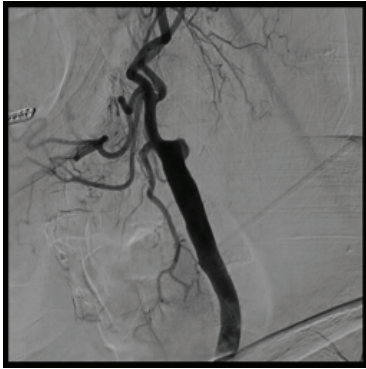acak şekilde yerleştirildi. Komplikasyon gelişmedi, İşlem başarılı olarak sonlandırıldı. (Resim 2, Video 2), bir gün sonra hasta taburcu edildi.

### TARTIŞMA VE SONUÇ

Cerrahi olarak yüksek riskli semptomatik, bilateral internal karotis arterlerde ciddi darlığı olan hastalarda ve perkütan stentleme cerrahiye iyi bir alternatiftir. Olgumuz buna iyi bir örnek teşkil etmektedir.

### Anahtar Kelimeler

Karotis Arter hastalığı, periferik arter hastalığı, Perkütan stentleme, İskemik serebrovasküler oklüzyon



# Is Treatment Modality Clear In Intracranial Arterial Dissection?

Özcan Kocatürk<sup>1</sup>, Fatih Güngören<sup>2</sup>

<sup>1</sup> Department of Neurology Harran University, Şanlıurfa, Turkey

<sup>2</sup> Department of Cardiology Harran University, Şanlıurfa, Turkey

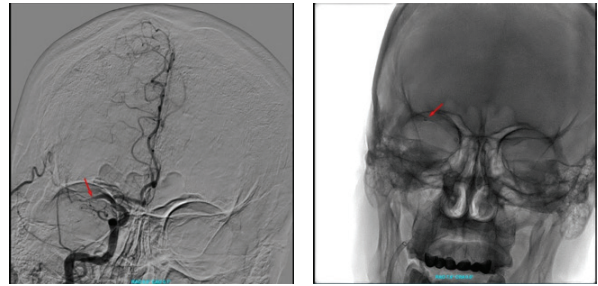
## INTRODUCTION

In the acute treatment of ischemic strokes, the role of endovascular techniques are rapidly increasing. Among the endovascular techniques, the stent implantation is rarely preferred choice of modality. Primary stenting in acute ischemic stroke is considered as salvage procedures in case of failure of other methods of mechanical recanalization. In this presentation, we want to describe a case of acute ischemic stroke caused by middle cerebral artery (MCA) dissection.

## CASE REPORT

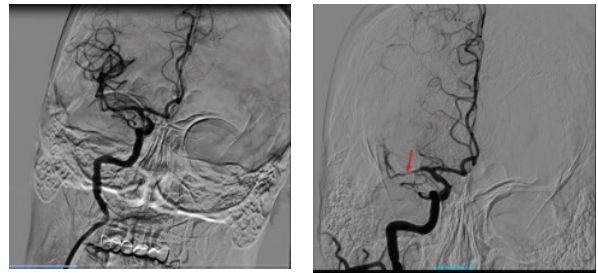
A 69 years old man was brought to our emergency department with sudden onset left sided weakness and dysarthria. The arrival time of the patient into our hospital was 2 hours later after the beginning of the symptoms. On admission, his neurological examination revealed that he had a decrease unconsciousness, dysarthria, and conjugated eye deviation to the right and left hemiplegic. His initial National Institute of Health Stroke Scale (NIHSS) score was 20. According to those findings, right MCA occlusion was thought and additional imaging procedures were performed immediately. Noncontrast Computer tomography (CT) of brain revealed no evidence of cerebral hemorrhage. A revascularization therapy was suitable for the patient and intravenous recombinant tissue plasminogen activator (tPA) was started immediately. After the administration tPA patient was taken to catheter laboratory for endovascular treatment. Angiography revealed sudden cutoff in the M1 segment of right middle cerebral artery with very limited collateral filling (figure 1). Thrombus aspiration procedure was done by using ace64 reperfu-

sion catheter (figure 2).



Angiography revealed sudden cutoff in the Thrombus aspiration procedure was M1 segment of right middle cerebral artery done by using ace64 reperfusion catheter

After thrombus aspiration the vessel recanalized (figure 3) but a few minutes later occluded again (figure 4).

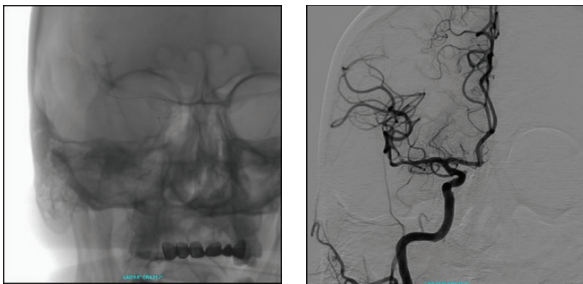


After thrombus aspiration the vessel recanalized  
A few minutes later MCA occluded again

OP-05

Hazy image is thought to be arterial dissection or stenosis (figure 5).

After three failed attempts of aspiration, 2.0x15 mm coronary balloon inflated (figure 6) and than 3.0x24 mm intracranial atlas stent was deployed at proximal right MCA (figure 7). At the final image, superior division of MCA thrombi was seen and intravascular tirofiban was given (figure 8).



The intervention was terminated approximately 4 hours after symptom onset. The patient was admitted to the intensive care unit. Dual platelet inhibition with a clopidogrel (300mg for loading and 75 mg/day thereafter) and ASA (100mg) was initiated in the same day. Cranial CT scan 24 hours after recanalization revealed diffuse hypodense areas and very small hemorrhage in the right hemisphere.

### CONCLUSION

Cerebral arterial dissection is a serious disease characterized by acute onset. Treatment modality of intracranial arterial dissection is unclear. Rapid and precise diagnosis enables appropriate treatment and good prognosis.

### Keywords

ischemic stroke, middle cerebral artery, dissection

## Can Neutrophil To Lymphocyte Ratio Be Associated with Stroke Territory?

Ozcan Kocaturk<sup>1</sup>, Feyzullah Besli<sup>2</sup>, Fatih Gungoren<sup>2</sup>, Mehtap Kocaturk<sup>1</sup>, Zulkif Tanriverdi<sup>2</sup>

<sup>1</sup> Department of Neurology Harran University, Şanlıurfa, Turkey

<sup>2</sup> Department of Cardiology Harran University, Şanlıurfa, Turkey

### INTRODUCTION

Stroke therapy options have focused on limiting the infarct volume. Neutrophil to lymphocyte ratio (NLR) can be valuable to detect the patients that required intensive treatment at early stage by predicting infarct volume. The aim of this study is to evaluate the relationship between NLR and infarct volume according to the stroke territory, and to determine the prognostic value of NLR for predicting 3-month mortality in acute ischemic stroke (AIS) patients.

### CASE REPORT

A total of 107 patients with AIS were enrolled and followed up 3 months in terms of mortality. Study population was divided into two groups according to the stroke territory: anterior circulating stroke (ACS) and posterior circulating stroke (PCS). All patients underwent magnetic resonance imaging. The complete blood count and venous blood samples were obtained from the patients on admission to the emergency department.

### RESULTS

There were no difference between ACS and PCS groups regarding baseline characteristics and co-morbid diseases. Also, C-reactive protein and NLR were similar between two groups. In correlation analyses, infarct volume was significantly correlated with CRP and NLR in ACS ( $r = 0.350$ ,  $p = 0.001$  and  $r = 0.482$ ,  $p \leq 0.001$ ,

respectively), but not correlated with infarct volume in PCS. Also, NLR was correlated with NIHHS in only ACS group ( $r = 0.326$ ,  $p = 0.002$ ). The 3-month mortality rate was 20.6% in study population. Patients in dead group were significantly older ( $p = 0.024$ ) and had higher CRP level ( $p = 0.004$ ), higher NLR level ( $p < 0.001$ ), and higher frequency of AF ( $p = 0.002$ ) compared to patients in surviving group. Multivariate analysis showed that NLR was the only independent predictor of 3-month mortality (OR 1.186, 95% CI 1.032–1.363,  $p = 0.016$ ). ROC curve analysis was used to detect the sensitivity and specificity of the NLR for predicting 3-month mortality. NLR  $\geq 4.7$  predicted 3-month mortality with a specificity of 76.5%, sensitivity of 63.6%, positive predictive value of 41.2%, and negative predictive value of 89%.

### CONCLUSION

NLR is significantly correlated with ACS infarct volume, whereas not correlated with PCS infarct volume. In addition, it is an independent predictor of 3-month mortality in AIS patients. Therefore, it may guide the physician deciding the necessity of endovascular intervention particularly in ACS patients.

### Keywords

Acute ischemic stroke, Infarct volume, Stroke territory, Neutrophil to lymphocyte ratio, Mortality



OP-06

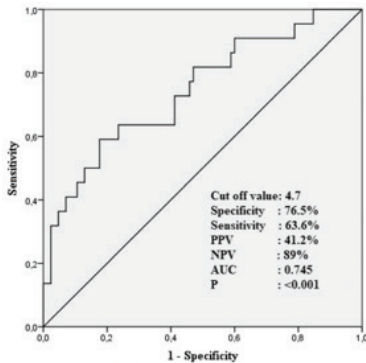


Fig. 1 ROC curve of neutrophil to lymphocyte ratio  $\geq 4.7$  for predicting 3-month mortality. PPV positive predictive value, NPV negative predictive value

ROC curve of neutrophil to lymphocyte ratio  $\geq 4.7$  for predicting 3-month mortality. PPV positive predictive value, NPV negative predictive value

	All patients (n = 107)	Anterior circulation stroke (n = 84)	Posterior circulation stroke (n = 23)	p
Creatinine (mg/dL)	0.8 (0.7–1.08)	0.83 (0.7–1.07)	0.8 (0.68–1.1)	0.692
Total cholesterol (mg/dL)	181 (154–201)	179 (151–194)	195 (162–211)	0.066
LDL cholesterol (mg/dL)	110 (91–121)	110 (90–119)	110 (91–134)	0.695
HDL cholesterol (mg/dL)	38 (31–42)	38 (31–42)	38 (31–44)	0.875
Triglyceride (mg/dL)	158 (104–192)	155 (102–174)	164 (132–306)	0.084
Hemoglobin (g/dL)	13.2 $\pm$ 1.8	13.2 $\pm$ 1.9	13.4 $\pm$ 2.1	0.709
Platelet count ( $10^9/mm^3$ )	259 (216–316)	262 (217–315)	256 (214–322)	0.991
White blood cell count ( $10^9/mL$ )	10.9 $\pm$ 3.1	11.0 $\pm$ 3.2	10.7 $\pm$ 2.8	0.740
Neutrophil count ( $10^9/mL$ )	7.5 (5.6–9.6)	7.5 (5.8–9.7)	7 (5.3–9.6)	0.527
Lymphocyte count ( $10^9/mL$ )	2.1 (1.3–2.8)	2.09 (1.31–2.67)	2.1 (1.30–2.90)	0.973
Neutrophil to lymphocyte ratio	3.68 (2.34–5.07)	3.68 (2.32–5.28)	3.68 (2.36–5.08)	0.818
Mean platelet volume (fL)	7.6 $\pm$ 1.4	7.7 $\pm$ 1.4	7.5 $\pm$ 1.4	0.496
Red cell distribution width	12.8 $\pm$ 1.8	12.6 $\pm$ 1.7	13.5 $\pm$ 2.1	0.058
CRP (mg/dL)	1.2 (0.58–1.86)	1.24 (0.58–1.89)	0.7 (0.4–1.8)	0.497

Parametric variables are expressed as mean  $\pm$  SD, and nonparametric variables are expressed as median (interquartile range) LDL low-density lipoprotein, HDL high-density lipoprotein, CRP C reactive protein

Comparison of laboratory parameters of patients with anterior and posterior circulation stroke

		NIHSS	ASPECTS	NLR	CRP	MPV	RDW
ACS infarct volume	r	0.609	0.742	0.482	0.350	-0.150	0.098
	p	<0.001	<0.001	<0.001	0.001	0.173	0.377
PCS infarct volume	r	0.593	-	0.186	0.276	-0.050	0.371
	p	0.003	-	0.396	0.202	0.822	0.082

ACS anterior circulation stroke, PCS posterior circulation stroke, NIHSS National Institutes of Health Stroke Scale, ASPECTS Alberta Stroke Program Early CT Score, NLR neutrophil to lymphocyte ratio, CRP C reactive protein, MPV mean platelet volume, RDW red cell distribution width

The correlation of anterior and posterior infarct volumes with clinical scores and laboratory parameters

	Univariate			Multivariate		
	OR	95% CI	p	OR	95% CI	p
Age	1.049	1.008–1.092	0.019	1.015	0.971–1.061	0.515
Male gender	1.874	0.723–4.855	0.196			
Hypertension	1.528	0.591–3.950	0.382			
Diabetes mellitus	0.729	0.272–1.955	0.530			
Heart failure	0.366	0.057–2.338	0.288			
Atrial fibrillation	6.144	1.810–20.858	0.004	2.426	0.574–10.261	0.228
NIHSS	1.082	0.990–1.183	0.082	1.025	0.927–1.134	0.628
Stroke territory	1.295	0.391–4.291	0.672			
Therapy strategy	0.913	0.297–2.813	0.875			
Infarct volume	0.994	0.980–1.008	0.388			
CRP	2.345	1.248–4.408	0.008	2.046	0.991–4.221	0.053
NLR	1.245	1.090–1.421	0.001	1.186	1.032–1.363	0.016

OR odds ratio, CI confidence interval, NIHSS National Institutes of Health Stroke Scale, CRP C reactive protein, NLR neutrophil to lymphocyte ratio,  $P < 0.05$  was considered as statistically significant

Univariate and multivariate logistic regression analyses showing the independent predictors of 3-month mortality

	Surviving patients (n = 85)	Dead patients (n = 22)	p
Age (years)	65 (52–73)	68.5 (64.7–79)	0.024
Male gender, n (%)	48 (56.5)	9 (40.9)	0.192
Diabetes mellitus, n (%)	25 (29.4)	8 (36.4)	0.529
Hypertension, n (%)	55 (64.7)	12 (54.5)	0.380
Hyperlipidemia, n (%)	30 (35)	8 (34.7)	0.785
Heart failure, n (%)	3 (3.5)	2 (9.1)	0.271
Atrial fibrillation, n (%)	6 (7.1)	7 (31.8)	0.002
Therapy strategy, n (%)			0.621
Endovascular/thrombolytic	18 (21.2)	5 (22.7)	
Anti-aggregant only	67 (78.8)	17 (77.3)	
Stroke territory, n (%)			
Anterior circulation stroke	66 (77.6)	18 (81.8)	
Posterior circulation stroke	19 (22.4)	4 (18.2)	0.671
NIHSS	9 (6–15)	13 (8–16)	0.072
Infarct volume, cm <sup>3</sup>	4.27 (0.23–17.8)	5.86 (0.46–21.5)	0.697
CRP	1 (0.5–1.75)	1.84 (1.12–2.15)	0.004
NLR	3.04 (2.09–4.6)	5.3 (3.5–10.1)	<0.001
MPV	7.4 (6.9–8.4)	7.4 (6.8–8.0)	0.579
RDW	12.3 (11.3–13.4)	12.9 (12–14.6)	0.061

NIHSS National Institutes of Health Stroke Scale, CRP C reactive protein, NLR neutrophil to lymphocyte ratio, MPV mean platelet volume, RDW red cell distribution width,  $P < 0.05$  was considered as statistically significant

Comparison of clinical, demographic, and laboratory features in surviving and dead patients

# Our Experience with Transradial Access For Carotid Artery Stenting

Zafer Kucuksu

<sup>1</sup> Department of Neurology Harran University, Şanlıurfa, Turkey

<sup>2</sup> Department of Cardiology Harran University, Şanlıurfa, Turkey

## INTRODUCTION

Carotid artery stenting is the most popular way to treat carotid artery disease. Our study reports our experience using the transradial artery access for carotid artery stenting.

## CASE REPORT

A prospective study on symptomatic severe carotid artery stenosis was performed on 11 patients with cerebral protection using transradial artery access. We just used right transradial access. The right or left CCA is cannulated with an 6f right judkins catheter or 5f vertebral catheter with 0.035 hydrophilic guidewire.

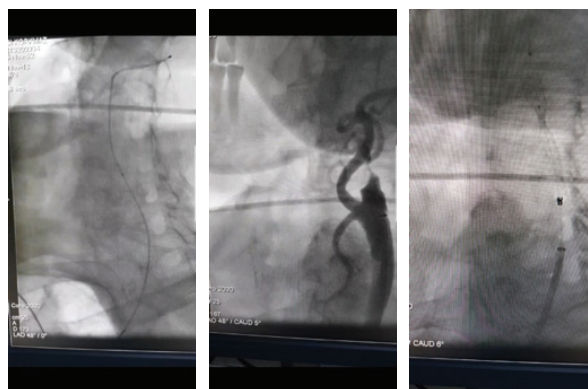
The catheter is then advanced just proximal to the carotid bifurcation and an Amplatz Super Stiff (Boston Scientific) wire is positioned in the external carotid artery to provide support for the subsequent sheath exchange.

The selected guiding sheath is then advanced over the stiff wire just proximal to the carotid bulb. We use a 6F 90-cm hydrophilic guide sheath; either a Terumo Destination Sheath.

We used at all patient Spyder FX embolic protection device and we prefer to use the Protege RX Carotid Stent (Medtronic)

## RESULTS

Procedural success was achieved in 10 patients (90%). There occurred a failure in a patient with a right side carotid lesion and Type 1 arch. There was not a radial artery spasm and occlusion. Post procedural stroke rate was 0%. All patients were mobilized in 2 hours after intervention and were discharged the following day.



0.035 stiff wire in external carotid artery

Carotid angiography with 90 cm 6f destination sheath

Carotid stenting

## CONCLUSION

Transradial access is safe and highly achievable for carotid artery intervention. Furthermore, it is more comfortable than transfemoral artery access for patients

## Keywords

Transradial access, carotid artery stent, carotid stenosis

# Single Center Experiences and Clinical Outcomes of Carotid Artery Stenting

Feyzullah Besli<sup>1</sup>, Ozcan Kocaturk<sup>2</sup>, Fatih Gungoren<sup>1</sup>, Zulkif Tanriverdi<sup>1</sup>, M. Begenc Tascanov<sup>1</sup>

<sup>1</sup> Department of Cardiology, Harran University, Sanliurfa, Turkey

<sup>2</sup> Department of Neurology, Harran University, Sanliurfa, Turkey

## BACKGROUND

Carotid artery stenting (CAS) is a relatively newly developed technique that includes various instruments (open or closed cell stents and protection device as well as special wires and catheters) as an alternative to carotid endarterectomy (CEA) for carotid revascularization. Although CAS procedures is performing commonly in experienced centers worldwide, peri-procedure complications tend to be higher than CEA. In this study, we aimed to present our CAS experiences and peri-procedure

## METHODS

A total of 113 patients that scheduled for CAS were investigated retrospectively between January 01, 2016 and December 31, 2018 in Harran University. Basal characteristic and clinical outcomes of the patient were recorded from hospital digital archive system. Periprocedural and 30-day clinical outcomes were defined as follows: transient ischemic attack, minor and major stroke, hyperperfusion syndrome, myocardial infarction and 30-day mortality.

## RESULTS

Mean age of the study group was  $71.6 \pm 7.8$  with a 64.6% gender male. Majority of patients were symptomatic carotid stenosis (79.6%). Hypertension was present in 77.9%, diabetes mellitus in 33.6%, hyperlipidemia in 39.8, smoking in 28.4% and history of coronary artery disease in 24.8%. Procedure success rate was 96.5% (109/113). Open cell self expandable stent was used for all patient. Protection device was used in 86 (78.9%) pa-

tients. The mean degree of stenosis was  $88.2\% \pm 9.0\%$  and mean length of lesion was  $22.9 \pm 6.8$  mm, whereas stent diameter and length were  $7.1 \pm 0.6$  mm and  $38.2 \pm 13.3$ , respectively. Peri-procedure complications rate was 5.3% (major stroke:1, minor stroke: 2, transient ischemic attack:1, hyperperfusion syndrome:1, 30-day mortality:1).

## CONCLUSION

CAS is alternative treatment to CEA for carotid artery revascularization. It can be performed effectively and safely in experienced center.

## Keywords

Carotid artery stenting, Protection device, Dilatation



**Table 1.** Basal demographic and clinic features of the patients

Variables	(n = 113)
Age, years	71.6 ± 7.8
Male gender, n (%)	73 (64.6)
Body mass index (kg/m <sup>2</sup> )	26.5 ± 2.3
Symptomatic carotid stenosis, n (%)	90 (79.6)
Asymptomatic carotid stenosis, n (%)	23 (20.4)
Intervention day for symptomatic patients	10.9 ± 7.2 (0-30)
Systolic blood pressure (mm Hg)	132.4 ± 17.8
Diastolic blood pressure (mm Hg)	71.4 ± 9.6
Risk factors, n (%)	
Hypertension	88 (77.9)
Diabetes mellitus	38 (33.6)
Hyperlipidemia	45 (39.8)
Current smoker	32 (28.4)
Coronary artery disease	28 (24.8)

**Table 2.** Procedural characteristics of the study group

Variables	(n = 113)
Procedure success rate, n (%)	109 (96.5)
Lesion localization, n (%)	
Right internal carotid artery	46 (40.7)
Left internal carotid artery	67 (59.3)
Degree of stenosis, %	88.2 ± 9.0
Length of lesion, mm	22.9 ± 6.8
Protection device, n (%)	
Proximal protection	82 (75.2)
Distal protection	4 (3.7)
None	23 (21.1)
Dilatation, n (%)	
Only pre-dilatation	32 (29.4)
Only post-dilatation	33 (30.3)
Pre and post-dilatation	19 (17.4)
Without dilatation	25 (22.9)
Stent diameter, mm	7.1 ± 0.6
Stent length, mm	38.2 ± 13.3

**Table 3.** Peri-procedural and 30-day outcomes of the study group

Complications	(n = 6) (5.3%)
Major stroke, n	1
Minor stroke, n	2
Transient ischemic attack, n	1
Myocardial infarction, n	0
Hyperperfusion syndrome, n	1
30 day mortality, n	1

# Complications Of Stent Stripping During Subclavian Chronic Total Occlusion Intervention

Hakkı Şimşek, Ahmet Ferhat Kaya, Mesut Oktay, Ali Evsen

*Department of Cardiology, Dicle University, Diyarbakır, Turkey*

## INTRIDUCTION

In this study, we aimed to present the complications of stent stripping during subclavian chronic total occlusion intervention

## METHODS

80 years old patient with NYHA 2 was admitted to the hospital with blurred vision. His has %90 stenosis on the Right Internal Carotid Artery and %80 stenosis on Left Carotid Internal Artery by Doppler USG. Smoking and hypertensi were risk factors.

## RESULTS

A Sheat was inserted into the right femoral artery for carotid artery angiography but 0.038 guideline wire was unable to proceed. When the opaque material injection into the distal of right main iliac artery, we found that it was occluded. After that, another sheath was insert into the left femoral artery but 0.038 inch guidewire unable to proceed. When the contrast agent injected we found that left main iliac artery was subtotally occluded.

An attempt was made to open the left iliac lesion with a retrograde approach but guidewire was subintimal advanced, could not fall into the true lumen. It was decided taht to proceed the intervention by subclavian approach later. One month later, the guidewire sent through the brachal artery however guidewire was unable to proceed also. When opaque material injected, total occlusion was detected in the distal of the left subclavian artery. Dissection of the iliac artery showed a great amelioration of left femoral artery images before.

Chronic total occlusion was crossed with 0.035 hydrophilic wire in microcatheter support and lesion was predilated with 4x40 mm balloon. After the implantation of a 6.0x40 mm balloon expandable stent we noticed that the majority of the stent was stripped from the balloon and unopened in the axillary artery. Unopened stent states were dilated with a 4.0x80 mm balloon. 5.0x40 mm stent was placed in lesion area. Stent balloon in the axillary region was slightly over dilated from 6 atm. Then it was dilated with 7.0x80 mm balloon. Blood flow in teh Left Internal Mammary Artery and vertebral artery were not affected. No problem was detected in the subclavian and axillary blood flow.

The left iliac artery was dilated with balloons 4 and 6 mm in diameter, dissection not observed. In the other session, the procedure was ended for simultaneous stenting of the right and left iliac arteries.

## Keywords

chronic total occlusion, subclavian artery, stent stripping

OP-05

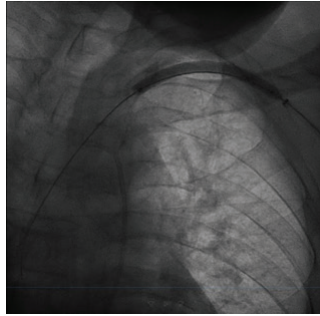


figure1

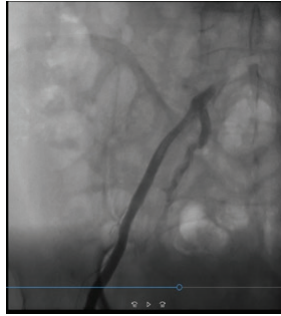


figure2

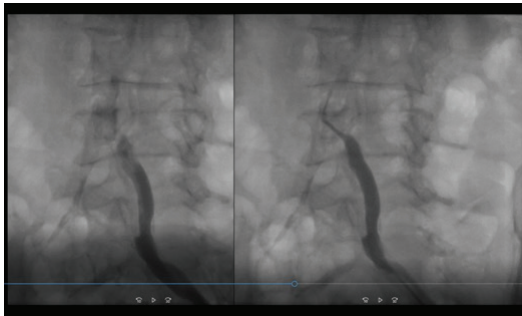

figure3

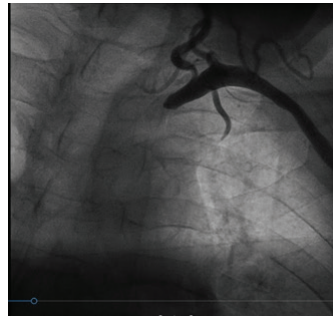


figure4

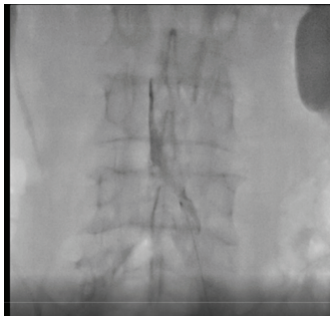

figure5

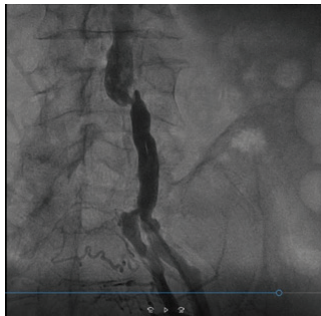

figure6

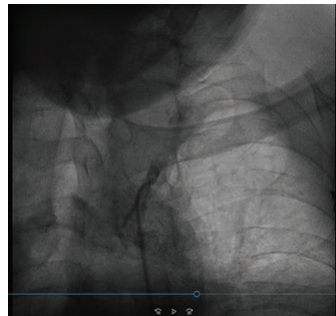

figure7

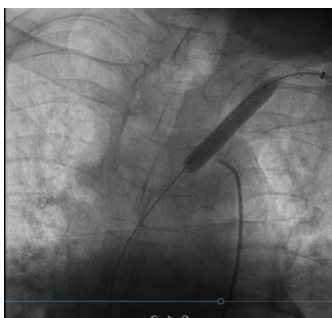


figure8

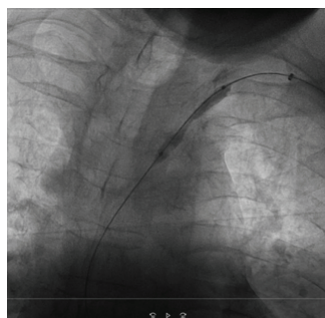


figure9

## Uzun Kronik Total Stentiçi SFA Darlığına Perkütan Girişim

Halit Acet, Faruk Ertaş, Bayram Arslan, Tuncay Güzel, Raif Kılıç, M. Sait Coşkun, Hasan Kaya

Department of Cardiology, Dicle University, Diyarbakır, Turkey

### OLGU

Tip 2 DM, 35 paket/yıl sigara öyküsü mevcut olan 69 yaşında erkek hasta, 1 yıl önce Sol SFA'ya stent takılmış. Hasta iki taraflı alt extremite de kladikasyo ( Fontan 3, Rutherford 4 semptomlu) şikâyeti ile merkezimize başvurdu. Merkezimizde yapılan DSA'da sağ SFA proximalde % 100 total tıkalı darlık, sol SFA ostealden itibaren stent sonrasına distale kadar total tıkalı idi (Resim 1, Video 1). Konsey kararı ile hastaya mevcut seansta önce sol sonra da sağ SFA'ya perkütan girişim kararı alındı. İşlemi gerçekleştirmek amacıyla sağ femoral artere 7F 65 cm sheat girildi. Daha sonra 0.035 135 cm mikrokater desteği 0.035 hidrofilik tel, 0.018 teller ile darlık geçilemeyince 0.035 135 cm mikrokater desteği ve 0.035 hidrofilik ZİP marka telin arka ucu ile total darlığın proksimal kısmı delinerek lezyon tıkalı stent segmentine kadar geçildi, sonrasında mikrokater desteği ve hidrofilik tel ile darlık geçildi. Darlık distalinden

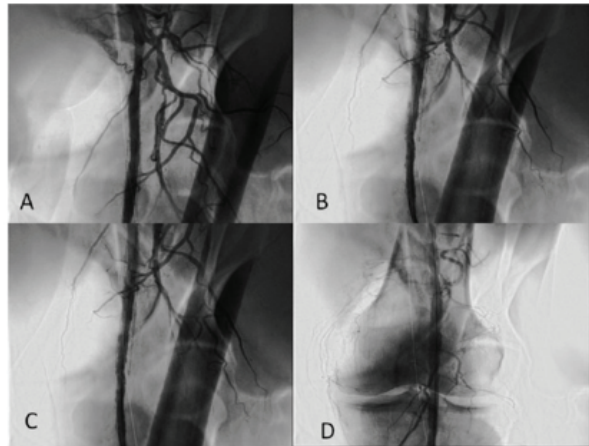
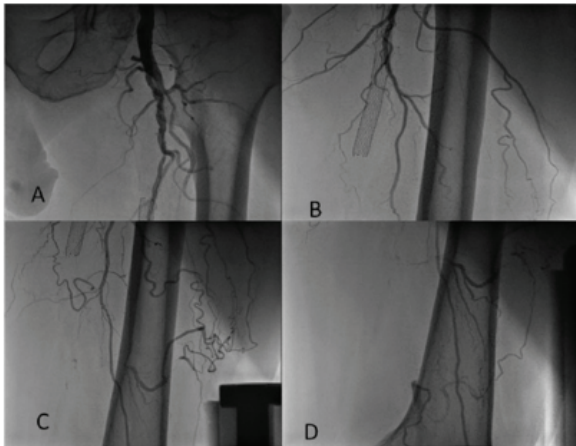
proksimal kısmına kadar proximaline 4.0x80 mm balon ile predilatasyon yapıldı. Sonrasında distale 4.0x100 mm 2 adet, mid kısma 5.0x120 mm ve en proksimale de 6.0x150 mm ilaçlı balonlar ile 3'er dk. şişirildi. Tam açıklık sağlandı (Resim 2, Video 2).

### TARTIŞMA ve SONUÇ

Uzun sert kronik total stentiçi SFA lezyonları tecrübe gerektiren işlemler olup standart perifer girişim malzemeleriyle lezyon bazen geçilememektedir. Bu gibi durumlarda çok önerilmezse de ve tehlikeli bir durum olsa da darlık 0.35 hidrofilik telin arka kısmı ile proksimal kısmı geçilerek işlem başarı şansını artırmaktadır. Olgumuz buna iyi bir örnek teşkil etmektedir.

### Keywords

kronik total oklüzyon, periferik arter hastalığı, SFA, stentiçi darlık, perkütan girişim



## Succesful Endovascular Therapy of a Patient with Leriche Syndrome: A Case Report

Irfan Veysel Düzen

*Department of Cardiology, Gaziantep University, Gaziantep, Turkey*

### INTRODUCTION

Aortoiliac occlusive disease, also known as Leriche syndrome, is a form of central artery disease involving the occlusion of the abdominal aorta as it transitions into the common iliac arteries. According to Aorto-iliac Occlusive Disease (AIOD) classification by the Trans Atlantic Inter-Society Consensus (TASC II), Leriche Syndrome belongs to type D lesions, for which surgery is the treatment of choice. However, with increasing experience, technical skill and improved endovascular equipment, there's an increasing tendency to perform endovascular treatment. We present succesful endovascular treatment of a patient with Leriche syndrome here.

### TOOLS and METHOD

A 60 year old man was admitted to emergency room with acute inferior myocardial infarction. He was taken to the coronary angiogram immediately. After two attempts from left and right femoral approach it was seen that the wire couldn't be advanced through common femoral artery and radial coronary angiogram and primary PTCA was performed. After primary PTCA it was seen that distal abdominal aorta is totally occluded after renal arteries branched out. (Figure 1). He was consulted to cardiovascular surgery for operation but the patient rejected surgery and we decided to make percutaneous treatment of aortoiliac disease.

### RESULTS

We prepared bi-directional approach sites via the bi-femoral arteries and left brachial artery. We passed

the totally occluded site of aortoiliac segment with antegrade approach by using stiff guidewire, we could re-enter to the true lumen at the level of common iliac arteries and changed the stiff guidewire into 300cm V18 guidewire (Figure 2). Multiple pre-dilatations were performed with various sizes of balloons in common iliac arteries and aorta. After predilatations, 9x100 mm graft stent and 9x57mm balloon expandable stents were implanted to aorta, left and right common iliac artery respectively. (Figure 3) The stents were postdilated with kissing balloons (Figure 4). The patient was discharged next day with advice, to stop smoking and exercise. He was advised to continue dual antiplatelets aspirin, ticagrelor and statin. On follow-up, after three months claudication was disappeared and 3D CT scan showed well deployed patent stents extending from abdominal aorta to the bilateral iliac arteries. (Figure 5 and Figure 6)

### DISCUSSION

The treatment for Leriche Syndrome is surgery according to TASCII classification. Although primary patency rates are better in surgery group secondary patency rates are similar between endovascular group and surgery group in Leriche Syndrome. Increasing experience in percutaneous therapy and advancing technology give rise to more patients treated with endovascular approach. Leriche syndrome is usually associated with other medical comorbidities and life expectancy is lower in this group patient. Endovascular treatment can be preferable for these patients because of lower complication rates and perioperative mortality than surgery.



OP-12

Keywords:

leriche syndrome, endovascular treatment, aortoiliac disease

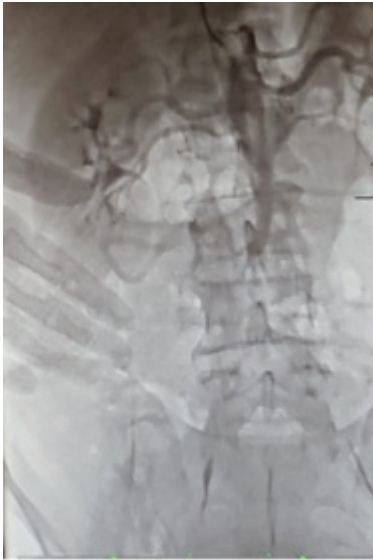


Figure 1: Angiogram shows distal occlusion of abdominal aorta after renal arteries branch out

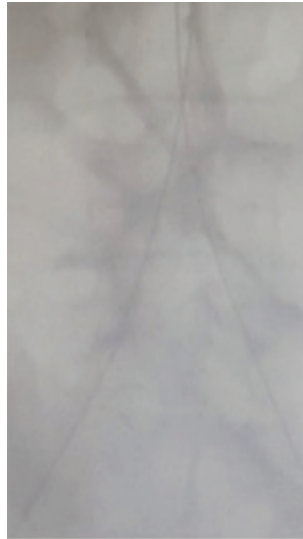


Figure2:Occlusion is crossed by hydrophilic wires

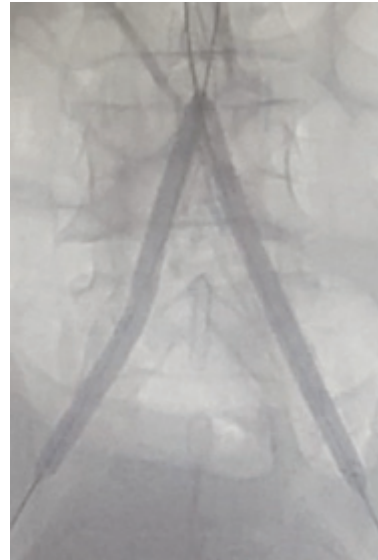


Figure3: A 9mm (57 mm) and a 9mm (70 mm) stent were inserted from the right common iliac artery and advanced to the aorta. Also, a 6 mm (57 mm) and a 9 mm (70 mm) stent were inserted in the left iliac artery from the left common iliac artery and advanced to the aorta.

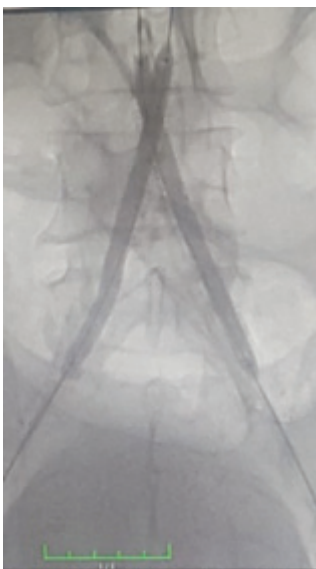

Figure 4: The postdilatation of the bilateral stents was performed simultaneously with two balloons

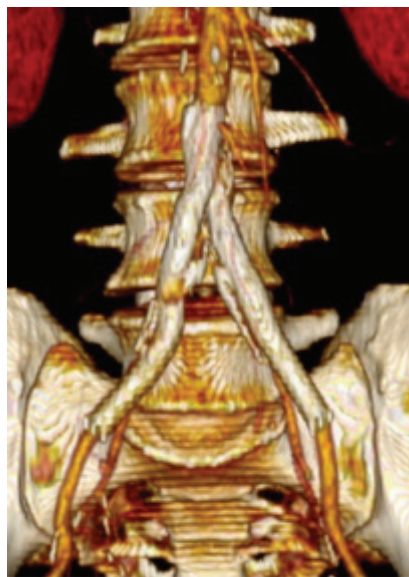


Figure5:After three months 3D-CT scan shows patency and well deployed stents

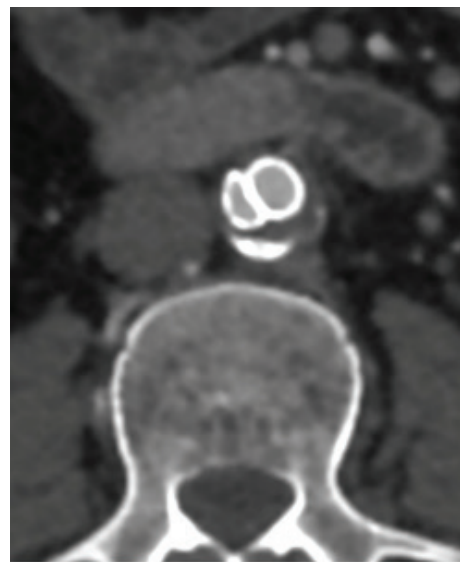


Figure 6:CT scan shows patency of well deployed stents

# Billateral Kronik Total SFA ve Popliteal Arter Lezyonlarına Aterektomi Eşliğinde Başarılı Perkütan Girişim

Faruk Ertaş, Halit Acet, Tuncay Güzel, Bayram Arslan, Raif Kılıç, Barış Acun, Nizamettin Toprak

Department of Cardiology, Dicle University, Diyarbakir, Turkey

## OLGU

85 yaşında erkek hasta bilateral alt ekstremité kladikasyon (Fontan 3, Rutherford 4 semptomlu) şikâyeti ile merkezimize başvurdu. Dış merkezde yapılan alt ekstremité doppler ultrasonografide Billateral SFA'da kritik darlık saptanmış ve DSA önerilmiş. Merkezimizde yapılan DSA'da sol ana femoral arterde %60 darlık, sol SFA mid bölgede %100 total tıkalı. Popliteal arter mid bölgeden %100 total tıkalıydı. Sağ SFA popliteal arter distal kısmına kadar %100 tıkalı, (Resim 1, Video 1). Konsey kararı ile hastaya perkütan girişim kararı alındı. Önce sağ SFA, sonra Sol SFA'ya girişim planlandı.

## İŞLEM AŞAMALARI

İşlemi gerçekleştirmek amacıyla sağ femoral artere 6F 65 cm sheat girildi. Daha sonra 0,035 260 cm hidrofilik tel, 0,018 300 cm tel ile lezyon geçildi. SFA daki darlığa 4,0x40 mm balon ve distale 6,0x120 mm ve 6,0x150 mm ilaçlı balonlarla 3 dk şişirildi, proximal bölgeye 7,0x120 mm ilaçlı balon ile 3 dk şişirildi. Popliteal arter ve dizaltına 3,0x120 mm ve 2,0x150 mm balonlarla dilatasyon yapıldı (Resim 2) sol SFA ve Popliteal arterde akım sağlandı. İşlem sonlandırıldı. 10 gün sonra sağ SFA'ya girişim yapıldı.

## İŞLEM AŞAMALARI

İşlemi gerçekleştirmek amacıyla sol femoral artere 7F 65 cm sheat girildi. Daha sonra 0,035 135 cm mikrokater desteğiyle 0,035 260 cm cordis marka hidrofilik tel, 0,035 180 cm cook marka Roadrunner tel, 0,018 300 cm abbot marka command tel, 0,018 300 cm medtronic marka pointer teller ile lezyon geçilemey-

ince 0,035 180 cm cook marka Roadrunner tellin arka kısmı ve mikrokater desteğiyle lezyonun proksimal kısmı geçildi daha sonra Roadrunner tel ve mikrokater desteğiyle lezyon distalinmden sağlam segmentte düşüldü. 0,018 300 cm tel üzerinden distalden proksimale doğru darlığa 4,0x80 mm balon ile predilatasyon yapıldı (Resim 3A-B) Lezyonun kalsifik ve sert olması ve tam açılmaması nedeniyle proksimalden distale doğru Phoenix 1,88mmx135 cm Aterektomi cihazıyla aterektomi yapıldı. (Resim 3 C-D) distale 4,0x100 mm mid kısma ve 5,0x100 mm, proksimalede 6,0x100 mm ilaçlı balonlarla 3 dk şişirildi sağ SFA ve Popliteal arterde akım sağlandı. İşlem komplikasyonsuz olarak sonlandırıldı. (Resim 4, Video 2)

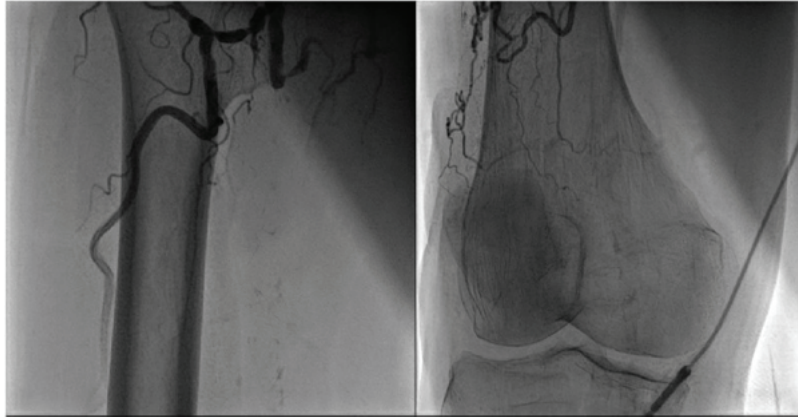
## TARTIŞMA VE SONUÇ

Kalsifik uzun SFA lezyonları komplikasyona yol açabilen tecrübe gerektiren işlemlerdir. Bu tarz lezyonlarda özellikli teller ve aterektomi cihazı kullanılması başarı oranını artırmaktadır. Olgumuz buna iyi bir örnektir.

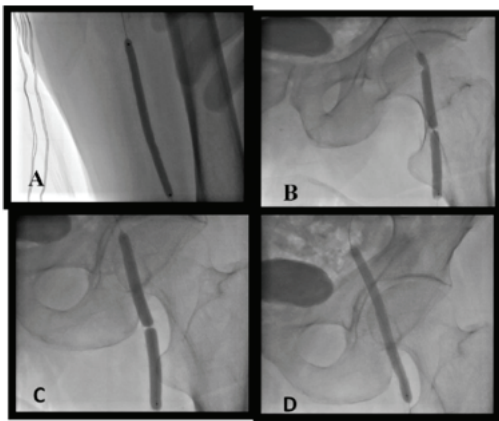
## Keywords

kronik total oklüzyon, periferik arter hastalığı, SFA, Aterektomi

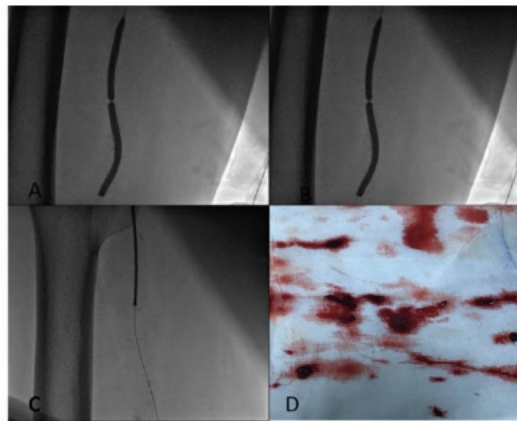
OP-13



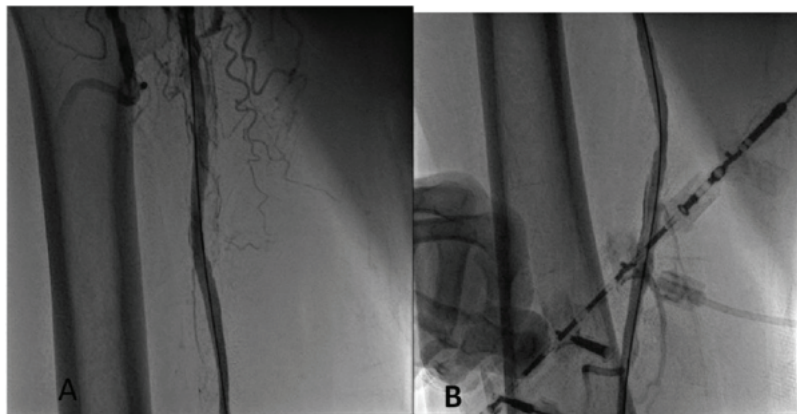
Resim 1



Resim 2



Resim 3



Resim 4



## Percutaneous Treatment of Deep Vein Thrombosis

Salih Şahinkuş

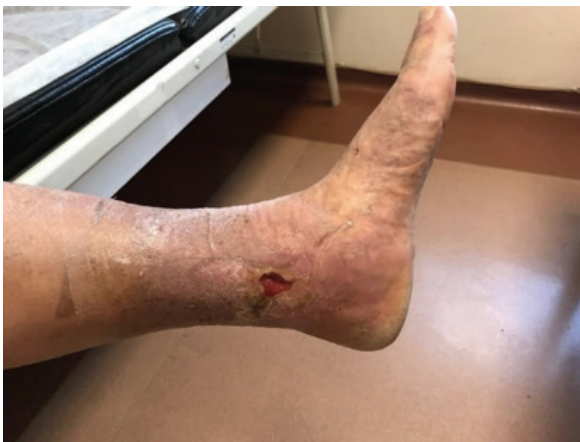### OLGU

Lower limb deep vein thrombosis (DVT) is the third most common cardiovascular disease after coronary artery disease and stroke, also with an incidence of 1/1000 in adults. Acute pulmonary embolism can occur after DVT. DVT can block the vessel lumen and lead to venous congestion. The main symptoms are; pain, edema, cutaneous colour changes and ulceration. The standart treatment of DVT includes anticoagulation therapy and compression stocking. Endovascular treatment strategies included mechanical thrombectomy, thrombolytic therapy, balloon angioplasty and stent implantation. Here we want to present a case report that we treated with additional balloon angioplasty and catheter direct-

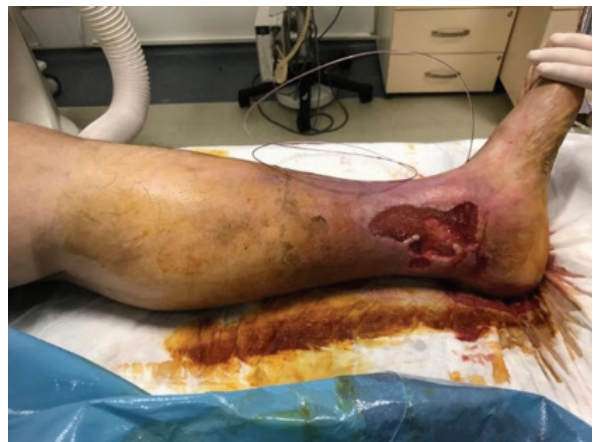ed thrombolytic therapy. 60 year old male patient complained of leg pain and skin ulceration. Popliteal vein thrombosis was found by the doppler ultrasonography. He was taken to the catheter laboratory. Balloon angioplasty was used in the popliteal and superficial femoral veins. Catheter directed 5 mg i.v. bolus alteplase therapy and following 24 hour alteplase infusion (1mg/h) was given to the patient. 2 weeks later, the patients cutaneous lesion and doppler ultrasonography measures were well recovered.

### Keywords

venous thrombosis, percutaneous treatment, balloon angioplasty



Lesion before treatment



Lesion after balloon angioplasty of the opliteal and superficial femoral veins

# Kissing Stent For Treatment of Persistent Retroperitoneal Hemorrhage Following Endovascular Treatment of Right Iliac Artery Chronic Total Occlusion

Beytullah Cakal, Irfan Barutcu, Aydın Yıldırım, Bilal Boztosun

Department of Cardiology, Istanbul Medipol University

## OLGU

Retroperitoneal hemorrhage is an infrequent but potentially fatal complication of peripheral interventions. CT angiography (CTA) is a helpful tool in treatment planning even in emergent hemodynamic instability caused by retroperitoneal hemorrhage. Active hemorrhage detected in CTA predicts failure of conservative treatment; need for early intervention. Negative contrast media extravasation does not always exclude active bleeding and is not evidence for stoppage of bleeding, because the ruptured region may have a low bleeding rate. We present a retroperitoneal hemorrhage case following right iliac artery chronic total occlusion

intervention which persisted due to multiple blood transfusions treated with aortoiliac stenting. Although bleeding site was not adequately delineated with either CTA and conventional angiography, we thought possible distal aortic rupture caused expanding left sided retroperitoneal hematoma. We successfully treated the patient with kissing aortoiliac stenting. The patient hemodynamic status improved well after the procedure and discharged in good clinical status.

## Keywords

retroperitoneal hemorrhage, aortoiliac stenting, computed tomographic angiography

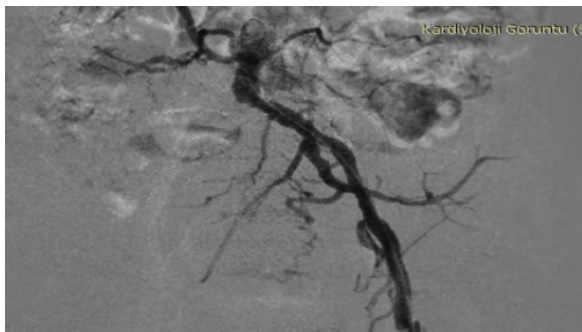


Figure 1 Right CIA % 100 CTO

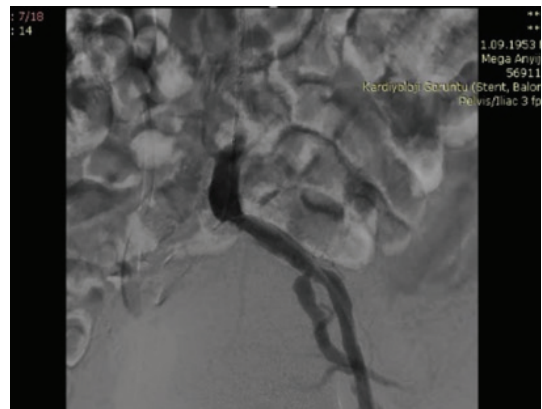


Figure 2. 7F Shuttle; Approach from Right

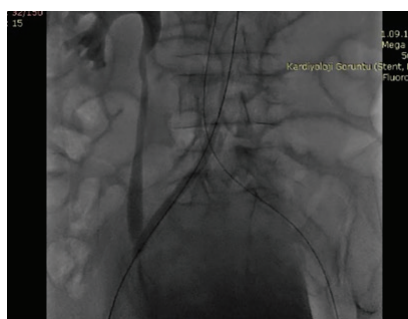


Figure 3 6\*80\*130 cm Admiral Extreme PTA to CIA CTO

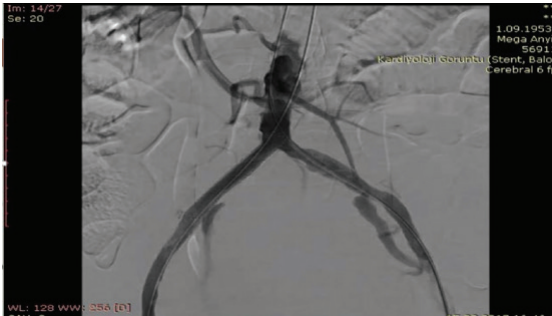

Figure 4 Right CIA 8\*57 mm EV3 Visi Pro

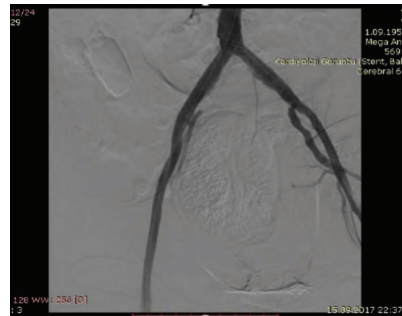

Figure 6 Angiography after 6 \* 100 mm Gore Viabahn graft stent to right CIA overlapped with previous stent

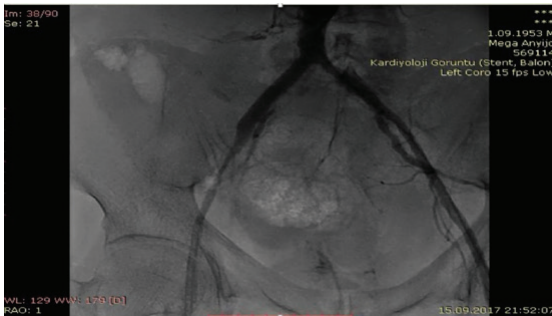


Figure 5 Hemorrhagic shock findings; PAG following 3 hrs post procedure Possible Right EIA rupture caused retroperitoneal hemorrhage

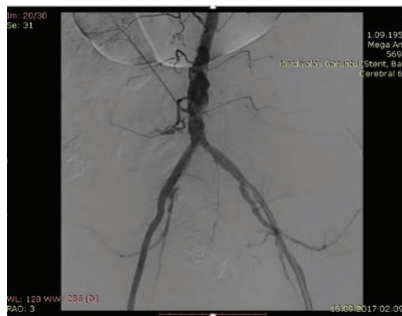

Figure 7 Control PAG 5 hours later No extravasation detected

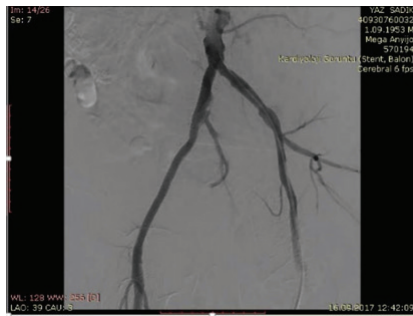

Figure 8 The patient was intubated, inotropes were administered, blood transfusion was still replaced; control PAG was repeated for the second time revealing no extravasation

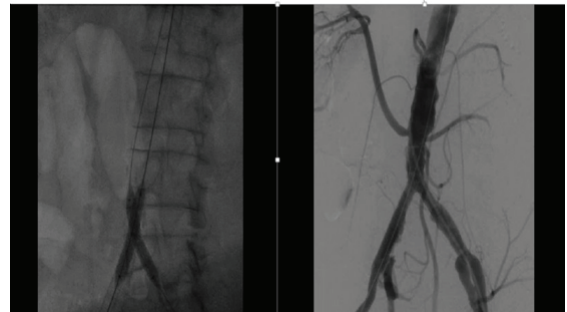

Figure 9 Since left sided retroperitoneal hematoma increased detected with control CTA, possible site for hemorrhage was thought as distal abdominal aorta so bilateral kissing stent technique for aortoiliac bifurcation was planned. Advanta 8\*38\*120 mm, 8\*38\*120 mm kissing stents were implanted for aortic bifurcation. After aortoiliac kissing stent, hemoglobin levels increased during followup. One day later after the procedure he was extubated and transferred CCU. The patient recovered well on following days and discharged

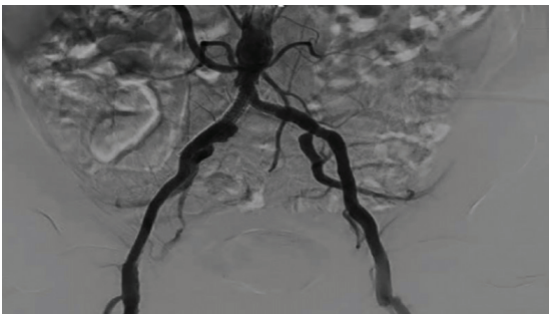


Figure 10 First year peripheral angiography with good stent patency of the aortoiliac kissing stents

# Recurrent Central and Peripheral Venous Occlusion and Recurrent Successful Intervention at the arm having the fistula in a dialysis Patient

**Yakup Balaban**

*VM Medicalpark Kocaeli Hospital*

## BACKGROUND

In patients which having the dialysis, venous occlusion and stenosis can make it difficult to perform dialysis besides the swelling in the same extremity

## CASE PRESENTATION

A 74-year-old female patient presented to our clinic with swelling on the right arm and severe pain in the left shoulder and arm during dialysis. The patient was taken to intervention when each swelling of same arm and occurrence of painful dialysis. Venous angiography was performed by entering the upper extremity vein on the same side each time. The lesions of the subclavian vein and cephalic vein were successfully intervened four times.

## DISCUSSION

In patients with central venous occlusion, additional occlusions may also be present in the peripheral parts

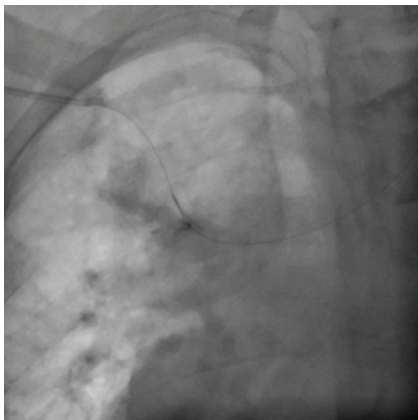
of the same extremity veins. Peripheral venous occlusions may be missed if that is focused to central venous intervention although the central stenosis is resolved as in our case, the problem can persist. For this purpose, percutaneous intervention can be performed through the upper extremity; balloon and stent may be applied. The operation can be repeated when the problem is repeated.

## CONCLUSION

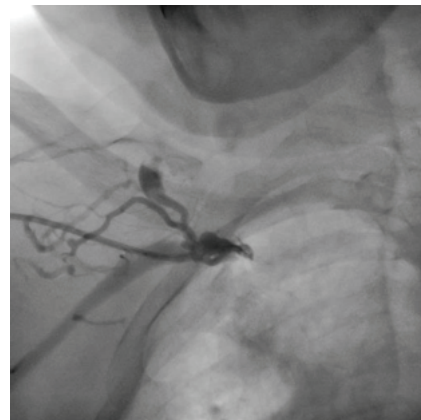
in dialysis patients with venous stenosis and occlusion; the swelling of the upper extremity veins and its interfere to dialysis application is a correctable problem

## Keywords

Dialysis, Arteriovenous fistulas, venous occlusion, percutaneous venous interventions

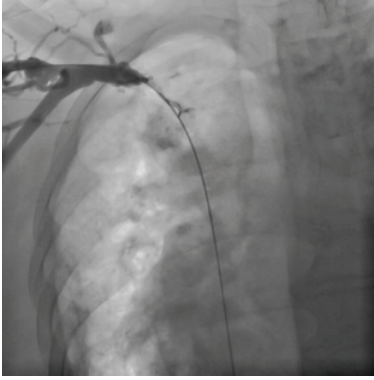


1. işlem ilk görüntü

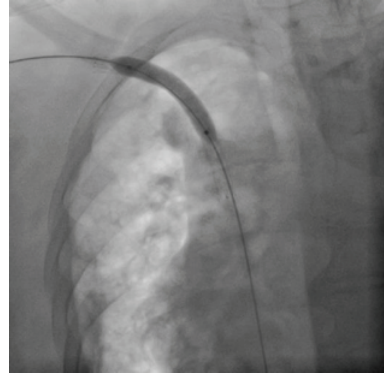


gerçek lumende olduğumuzu delik balon ile göstermek

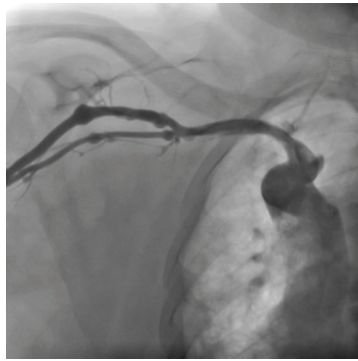



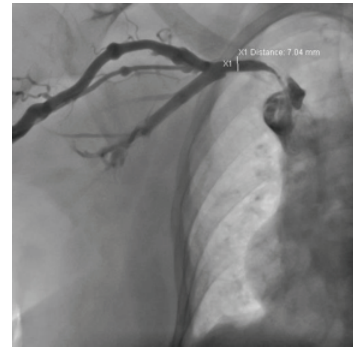
1.5 mm koroner balon sonrası



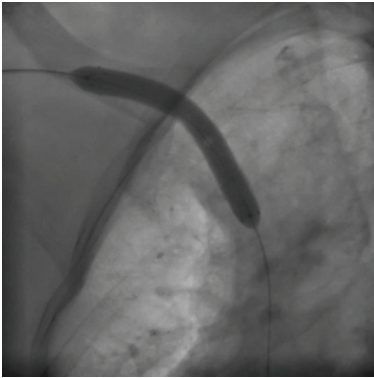PTA



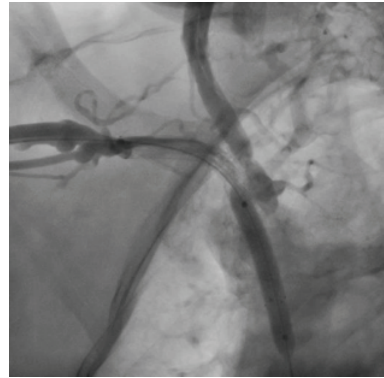
1. işlem son hali



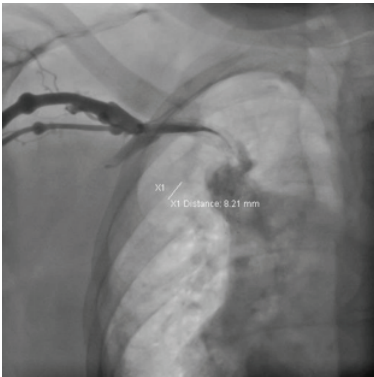
2. işlem ilk görüntü



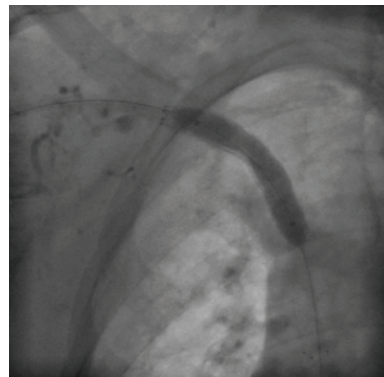
Balon



2. işlem son hali



3. işlem ilk görüntü



3. işlem PTA

## Percutaneous Treatment of 11 Patients with Acute Mesenteric Stenosis/Occlusion: A Single Center Experience

Yusuf Can, Harun Kılıç, Ibrahim Kocayığit, Murat Aksoy, Salih Şahinkuş, Ramazan Akdemir

*Department of Cardiology, University of Sakarya*

### INTRODUCTION

Acute mesenteric ischemia is a relatively high mortal condition, resulting in ischemia, cellular damage and necrosis as a result of sudden cessation of the intestines. Although it is rare, in-hospital mortality is still very high and could reach up to 93%. Most of the acute mesenteric ischemia is caused by mesenteric arterial embolism (50%) and mesenteric arterial thrombosis (15–25%). We assessed the efficiency and reliability of endovascular treatment in acute thromboocclusion of the superior mesenteric artery.

### TOOL AND METHODS

We aimed to present 11 cases diagnosed with acute mesenteric stenosis/occlusion treated percutaneously. The 6-Fr sheath was inserted into the femoral artery and the superior mesenteric artery were visualized with the 6-Fr diagnostic catheter. 8-Fr sheath was replaced in the femoral artery after the culprit lesion was identified. Then the 7-Fr / 8-Fr RDC, JR-4 or IMA guiding catheter was placed in the superior mesenteric artery ostium. Thrombus aspiration was performed manually by a 6-Fr guiding catheter with a 50 cc syringe. Balloon angioplasty was performed when thrombus aspiration failed. A stent was implanted when dissection occurred after balloon angioplasty or if there was a stenosis of 50% or more with atherosclerotic plaque.

### RESULTS

A total of 11 patients (7 male and 4 female) underwent endovascular treatment. 9 patients had total occlusion and 2 patients had severe stenosis. According to the

etiology, 9 patients had embolism in the main body of SMA and 2 patients had ostial stenosis/occlusion due to thrombosis. Seven of the patients with embolism had atrial fibrillation. No patients underwent thrombolytic therapy due to the risk of bleeding. Balloon angioplasty was performed in all patients, thrombus aspiration in 9 patients and stent implantation in 4 patients. Stent was implanted in two patients after balloon angioplasty due to the dissection and in two patients because of ostial lesion and 50% stenosis after balloon angioplasty. The in-hospital mortality rate was 18.1% (2/11) and these two patients had intestinal necrosis at presentation. The remain of the patients were discharged uneventfully. No death was observed in the 1-month follow-up of these patients.

### DISCUSSION

As a result, percutaneous endovascular treatment in acute superior mesenteric artery stenosis / occlusion is an effective and reliable method especially in patients without intestinal necrosis and these results should be supported by randomized controlled trials.

### Keywords

acute mesenteric thromboemboli, superior mesenteric artery, percutaneous treatment, dialysis application is a correctable problem

## A Patient Who Underwent 3-Vessel PCI and Left Common Iliac PTA During Same Hospitalization

Sefa Ünal, Mustafa Karanfil

Department of Cardiology, Sbiü, Turkey Yuksek Ihtisas Hospital

A 47-year-old male patient admitted to our hospital with acute anterior myocardial infarction. A primary PCI was planned by placing a sheath to left femoral artery. The guide wire could not be advanced from the proximal left iliac artery. The left iliac artery was seen to be totally occluded and the procedure was continued from the right femoral artery. Primary PCI was performed after CAG to 99% occluded LAD. 2 days after the initial procedure direct stent implantation was performed on critical stenoses in RCA and Cx. He described an intermittent claudication of the left leg and underwent CT angiography for left iliac artery evaluation and CT revealed total occlusion of left iliac artery and distal filling with collaterals. (figure 1). Left iliac PTA was planned in the same hospitalization as the patient had normal kidney functions and claudication.

Sheaths were inserted to left brachial artery and the left femoral artery. Totally occluded iliac lesion was crossed from the left brachial artery by destination sheath, trail-blazer microcatheter and 0.035 poseidone hydrophilic wire (figure 2), by tip injection the wire was found to be in the distal true lumen. The lesion was then predilated to by 6.0 x 60 mm evercross balloon (figure 3). 12 x 60 mm fluency plus vascular self expandable graft stent was implanted to the lesion and postdilated by 11x40mm balloon (figure 4). The patient was discharged 1 day later. The patient was asymptomatic in terms of coronary and peripheral artery disease at the first and sixth month follow-up.

### Keywords

3-vessel PCI, iliac PTA, same hospitalisation

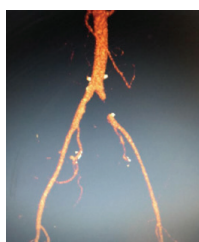


Figure 1

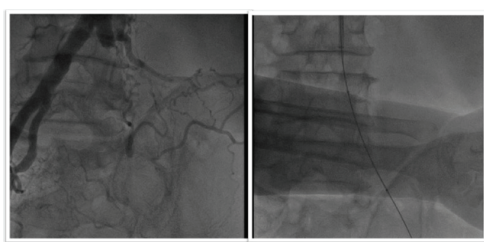


Figure 2

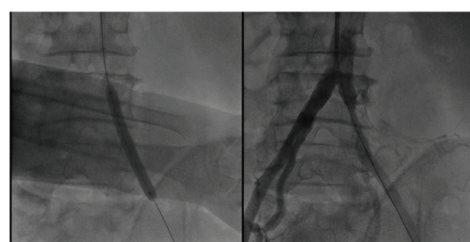


Figure 3

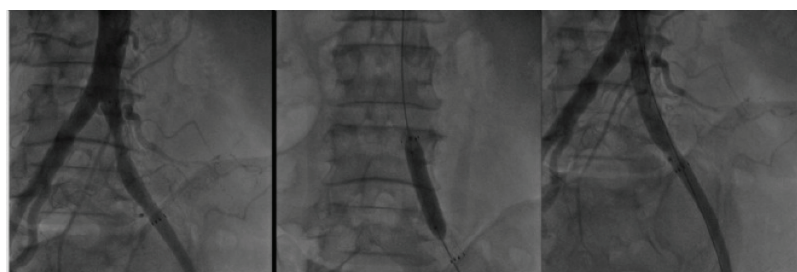


Figure 4

## Inadequate Balloon Dilatation of Iliofemoral Stenosis Like An Hour-Glass

Mehmet Cosgun, Yilmaz Gunes, Isa Sincer, Kemalettin Erdem

*Bolu Abant Izzet Baysal University Medical Faculty Hospital*

66 years old male was describing intermittent claudication in both legs. He has history of mitral valve replacement in 2015, aortobifemoral bypass operation with 9/18 mm Dacron graft in 2017 and left main-circumflex coronary stent within same year. After abnormal findings on Doppler ultrasound examination angiography was performed. Grafts were not visible and there were significant stenosis at iliofemoral levels bilaterally (Figure 1,2). After consultation with cardiovascular surgery percutaneous intervention was planned following days. Through left brachial artery a 6f 90 cm destination sheath was placed towards abdominal aorta. Left side lesions were dilated with 7x40 and 9x60 mm balloons. Although proximal and distal parts of balloons over dilated mid part were not opened like an hour-glass (Figure 3,4). A 5x20 mm noncompliant coronary balloon was dilated at high pressures (Figure 5). However the result was not satisfactory (Figure 6). The same scenario recurred at the right side also (Figure 7,8,9,10). Cardiovascular surgeon was invited to catheter lab to discuss

about the possible effect of previous operation on the present issue, as far as the surgeon recalled the vessels were thickened and solid at iliofemoral junctions. Intervention was hold with the decision of reoperation. Dacron grafts were occluded with fresh clot. After embolectomy with fogarty catheter endarterectomy was planned for severely fibrotic and narrowed CFA distal to anastomosis. However, CFA lesion was assessed like a stone and endarterectomy was unsuccessful. Therefore, distal parts of grafts were anastomosed to superficial femoral arteries bilaterally.

This was a difficult case of inadequate balloon dilatation explained by too tight stenosis as a consequence of severely fibrotic native vessel wall.

### Keywords

balloon, stenosis, severely fibrotic, inadequate dilatation

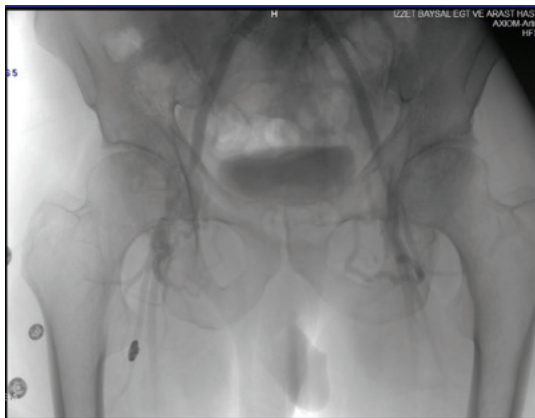


Figure 1

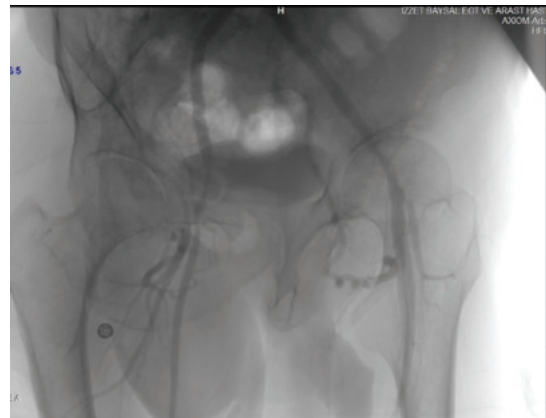


Figure 2



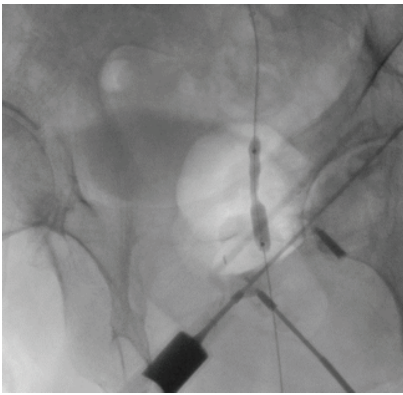


Figure 3

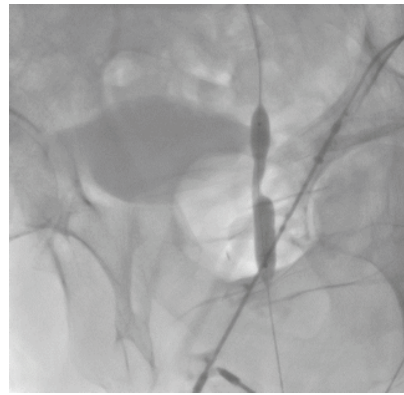


Figure 4

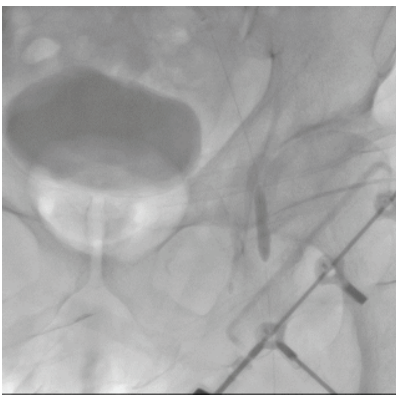


Figure 5

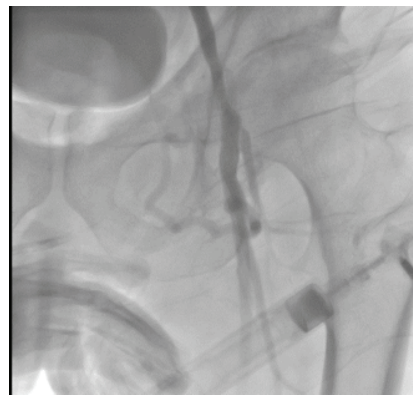

Figure 6

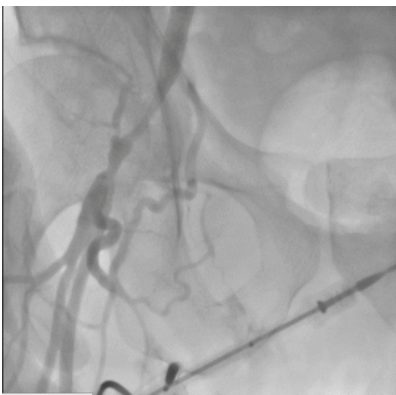


Figure 7

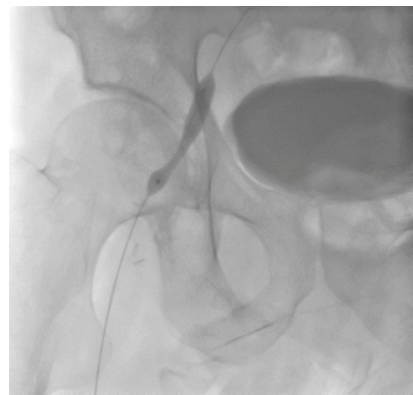


Figure 8

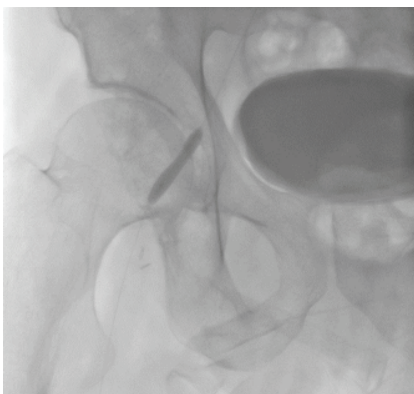


Figure 9

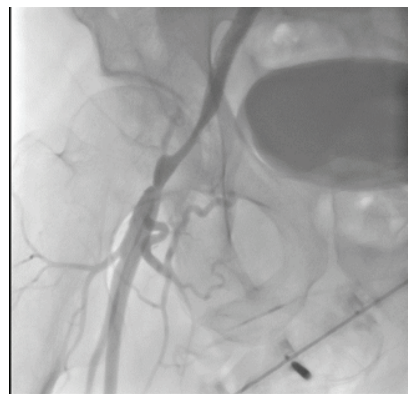


Figure 10

## Percutaneous Treatment of A Peripheral Total Occlusion Disease

Hakan Cakir

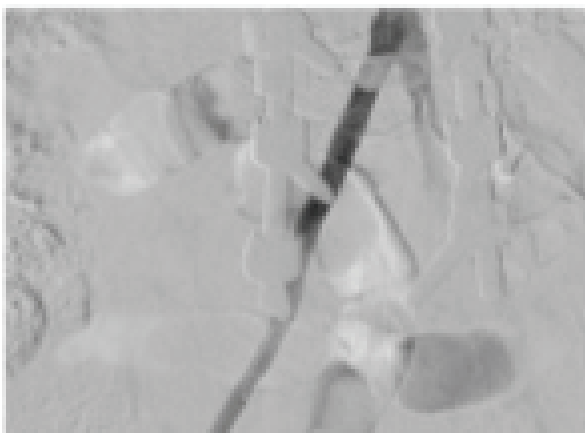
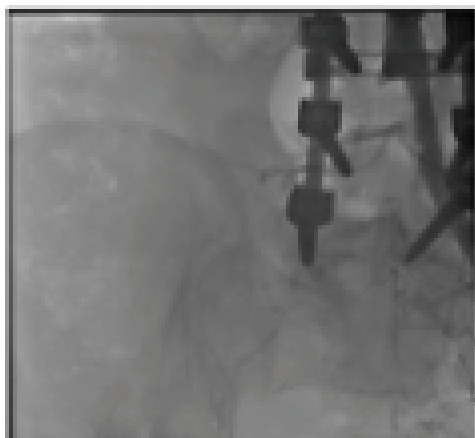
*Department of Cardiology, Bursa Education and Research Hospital, Health Sciences University*

A 55-year-old male patient was admitted to our hospital with the complaints of disabling right hip and leg pain with minimal exertion. Peripheral angiography revealed a chronic total occlusion of approximately 17 cm long, beginning from the right common iliac artery ostium. Considering his severe comorbidities, the patient was scheduled for an endovascular approach. An initial attempt was planned to cross the CTO via an antegrade approach from the left brachial artery. After obtaining left brachial access, a 90 cm destination sheath was advanced into the distal abdominal aortic bifurcation. Using an 0.018-inch guidewire (Halberd; Asahi Intec CO., LTD., Nagoya, Aichi, Japan) and an 0.035-inch microcatheter (Minnie; Teleflex, USA), wire escalation technique was attempted to cross the left iliac CTO, but was unsuccessful. Then 0.018-inch guidewire was exchanged for a 0.035 inch hydrophilic stiff (Poseidon; APR Medtech., LTD., United Kingdom)

guidewire. Using a loop wire technique, CTO lesion was crossed successfully. The 0.035-inch guidewire was exchanged for a 0.018-inch 360 cm guidewire and the common and external iliac and proximal common femoral arteries were dilated with a 5.0× 100 mm PTA catheter. Next, 7.0 mm x 100 mm self-expandable and 9.0 mm x 59 mm balloon-expandable stents were deployed in an overlapping fashion. Subsequent angiography demonstrated excellent flow and no significant residual stenosis within the treated vessel segment. Strong palpable pulses were noted at right groin at the completion of the procedure. At one-month follow-up, the patient had dramatically improved symptoms and capacity to ambulate.

### Keywords

chronic total occlusion, peripheral artery disease, stent



## The Successful Intervention of Totally Occluded Right Common Iliac Artery

**Şeref Kul, Mustafa Adem Tatlısu, Ömer Faruk Baycan, Yusuf Yılmaz, Fatma Betül Özcan, Kenan Demircioğlu, Mustafa Çalışkan**

*Department of Cardiology, Istanbul Medeniyet University, Istanbul, Turkey*

A 57-year-old male presented to our outpatient clinic with a 100m-claudication over the past 3 months, who was on cilostazol and acetylsalicylic acid for 2 years. He had a 60-pack-year smoking history. His past medical history included coronary artery disease and a drug-eluting stent was implanted in the right coronary artery 2 months ago. He underwent digital subtraction imaging (DSA) and it revealed totally occluded right common iliac artery at the ostium (Figure 1). We decided to intervene the lesion with an antegrade approach from the left brachial artery. We passed the lesion with knuckle-wire (0.035 F) technique and the 8x80 mm self-expanding iliac stent was deployed after balloon (6x69 mm) dilatation. The balloon-expandable

iliac stent was deployed in telescoping fashion, which covered the ostium of the right common iliac artery (Figure 2). Post-dilatation was performed with 9x38 mm balloon. There was not any dissection or residual thrombi at the end of the procedure. For the osteal iliac lesions, the antegrade approach is commonly preferred method due to the good support and relatively lower risk of dissection of the iliac arteries. Most of the time, there is no need for the second access site for the retrograde approach.

### **Keywords**

Antegrade approach, osteal iliac occlusion, peripheral intervention

# Percutaneous Revascularisation of The Left Common Iliac Artery Via Retrograde Approach: A Challenging Case Report

Ahmet Genç, Çağın Mustafa Üreyen, Şakir Arslan

Department of Cardiology, University of Health Sciences Antalya Training and Research Hospital, Antalya, Turkey

## INTRODUCTION

The prevalence of peripheral arterial disease (PAD) is increasing globally, impairing quality of life and increasing the risk of cardiovascular mortality. Chronic total occlusions (CTOs) of the peripheral vasculature exist in 40-70% of patients with critical limb ischemia. However, successful percutaneous intervention in an effort to restore blood flow to ischemic tissues in CTOs is low.

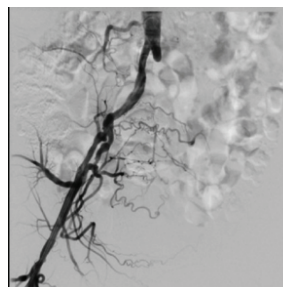
## CASE

A 61-year-old male patient was referred to our clinic from cardiovascular surgery outpatient clinic with a known CTO of the left common iliac artery, which resulted in a lifestyle-limiting claudication (Fontaine class IIb). He's been smoking 1 pack of cigarettes for 40 years. He had a myocardial infarction 5 years ago and underwent a coronary stent implantation. He had hypertension and hyperlipidemia. Physical examination revealed a heart rate of 70 bpm and a blood pressure of 130/70 mmHg. Moreover, the pulses on the left leg were not palpable.

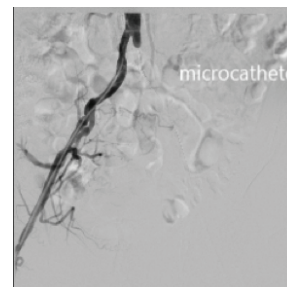
Two 6-French sheaths were inserted into the right and left common femoral arteries. A pig tail catheter was utilized for angiography. Diagnostic peripheral angiography confirmed a 5cm long occlusion within the left common iliac artery (Figure 1).

A 5F microcatheter was advanced over a 0.018 hydrophilic coated wire (v18 boston scientific) to the distal cap via the left entry site and the hydrophilic wire pen-

etrated the lesion up to the proximal cap. Furthermore, we advanced the microcatheter up to the proximal cap but we cannot still penetrate the proximal cap (Figure 2).

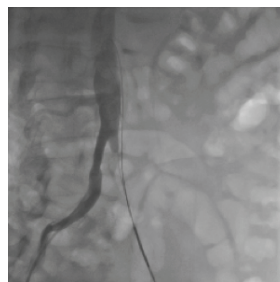


Diagnostic DSA



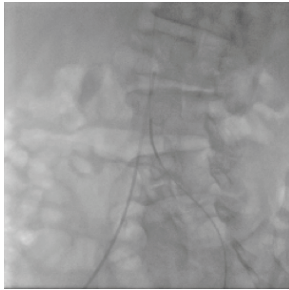
Penetration of lesion

Thereafter, we used a 0.018 wire (HI-TORQUE CONNECT 250T) in order to reenter the lumen of the distal aorta. Despite all the efforts, we failed and the wire was constantly advanced subintimally (Figure 3).



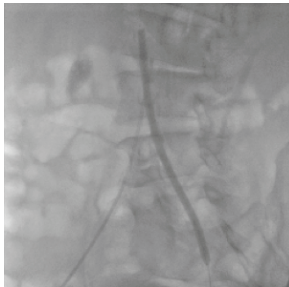
Subintimal course of guidewire

After all of these efforts, we changed the wire with a hydrophilic coated straight tip 0.035 (Radifocus® Guidewire M Stiff type) then we were able to reenter to the distal aortic lumen and then we advanced the microcatheter over the wire and ensured the expansion of the lumen (Figure 4).



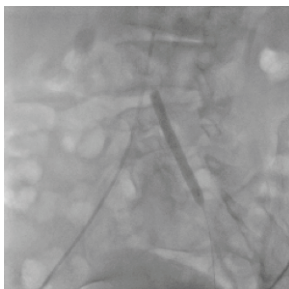
Expansion of the lumen by microcatheter

Afterwards, balloon angioplasty of the common iliac artery was performed with a 6.0 mm x 150 mm Balloon and inflated up to 8 atmospheres (atm)( Figure 5).

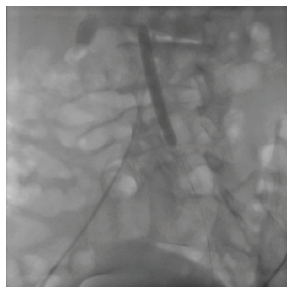


Balloon angioplasty

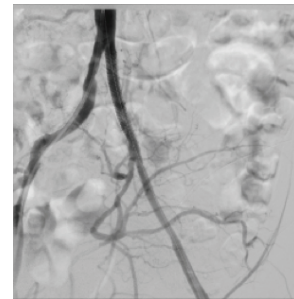
A 8.0mm x 59mm balloon expandable stent (OMNI-LINK ELITE. Abbott vascular) was then delivered and deployed across the lesion at 6 atm. At last, postdilatation was performed to the distal segment of the stent and baloon inflated to 10 atm. (Figure 6,7). Final angiography showed an excellent result without an evidence of dissection or perforation (Figure 8). The patient was discharged the next day and has been well on the follow-up with complete resolution of his claudication symptoms.



Stent implantation



Postdilatation



Final DSA

### CONCLUSION

Chronic total occlusions of the common iliac artery can be successfully revascularized via retrograde approach with appropriate wires and catheters as well as with a proper arterial access site.

### Keywords

Retrograde approach, CTO, Revascularisation, Common iliac artery



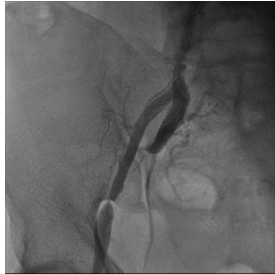
## Aynı Seansta Sağ, Total Sol İliak Arter ve Sağ Femoral Arter Darlığına Başarılı Perkütan Girişim

Faruk Ertaş, Halit Acet, Tuncay Güzel, Bayram Arslan, Raif Kılıç, Barış Acun, Nizamettin Toprak

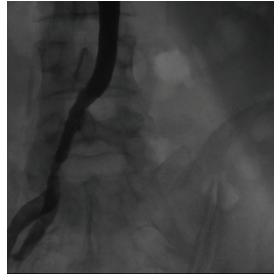
Department of Cardiology, Dicle University, Turkey

### OLGU

45 yaşında erkek hasta bilinen koroner arter hastalığı mevcut olup, sağ ve sol ayağında kladikasyo ( Fontan 3, Rutherford 4 semptomlu) şikayeti ile merkezimize başvurdu. Dış merkezde yapılan alt ekstremité doppler ultrasonunda billateral iliak arterlerde kritik darlık saptanmış ve DSA önerilmiş. Merkezimizde yapılan DSA'da sağ eksternal iliak arterde %95 darlık, sol iliak arter ostealden SFA ostealine kadar total tıkalı izlendi (Resim 1A ve B, Video 1). Konsey kararı ile hastaya perkütan girişim kararı alındı.



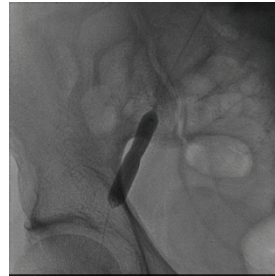
Resim 1A Sağ Eksternal İliak Arter Darlığı



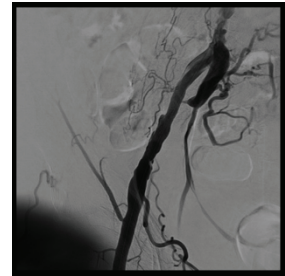
Resim 1B Sol İliak Arter Darlığı

İşlem aşamaları: İşlemi gerçekleştirmek amacıyla sol brakial artere 7F 90 cm sheat girildi. Daha sonra 0,035 260 cm hidrofilik tel ile sağ iliak arterdeki lezyon geçildi. 4,5x40 ve 5,0x60 mm balon ile dilate edildi, açıklık sağlandı (Resim 1C ve D). Daha sonra sol iliak arter 0,018 Pointer tel, ve 0,018 300 cm Nitrex ve 0,035x135 cm mikrokateter desteğiyle darlık geçildi. 4,0x150 ve 5,0x100 balonlar ile predilatasyon yapıldı (Resim 2A ve B) Sol iliak arter ostealine 9,0x57 mm balon expandable ve distale 8,0x150 mm self expandable stent yerleştiril-

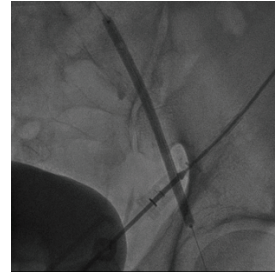
di. Ardından 7,0x100 mm balon ile postdilatasyon yapıldı. Optimal açıklık sağlanarak işlem sonlandırıldı. (Resim 3A ve B Video 2)



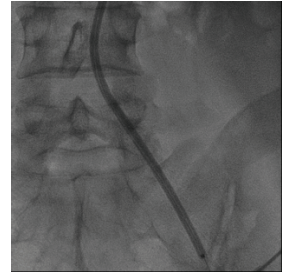
Resim 1C Sağ Eksternal İliak Artere Balon



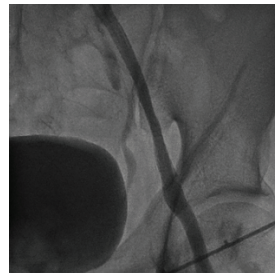
Resim 1D Sağ Eksternal İliak Artere Balon Sonrası



Resim 2A



Resim 2B



Sol İliak Arter İşlem Sonrası Görüntü

### TARTIŐMA VE SONUÇ

İliyak arter oklüzyonlarına aynı seansta müdahale etmek tecrübe gerektiren ve komplikasyonlara açık girişimlerdir. Bu tarz lezyonlarda eşzamanlı brakiyal girişim yapılması, delici özelliđi yüksek olan tellerin kullanılması başarı şansını arttırmaktadır. Olgumuz buna iyi bir örnek teşkil etmektedir.

### Keywords

kronik total oklüzyon, periferik arter hastalığı, iliak arter

# Billateral Aorto-İliak Arter Lezyonlarına Antegrad Girişimle Başarılı Perkütan Revaskularizasyon

Halit Acet, Faruk Ertaş, Bayram Arslan, Tuncay Güzel, Raif Kılıç,  
Mehmet Sait Coşkun, Hasan Kaya

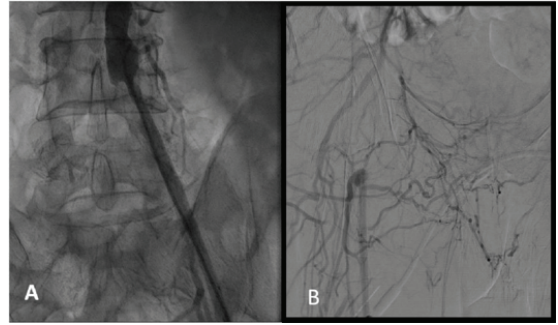
Department of Cardiology, Dicle University, Diyarbakır, Turkey

## OLGU

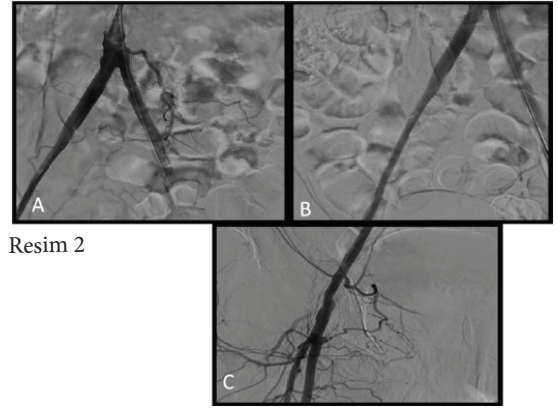
Bir yıl önce kladikasyo tarifleyen hasta 1 yıl önce dış merkezde Femoro-femoral by-pass yapılmış, hasta son 2 aydır kladikasyo (Fontan 2b, Rutherford sınıf 3) tarifliyor. Hastaya yapılan periferik anjiyosunda sağ iliak arter femoral arter başına kadar total tıkalı sol iliak arter ostealde ise %70 darlık mevcuttu (Resim 1, Video 1). Hastaya konsey kararıyla perkütan girişim kararı alındı.

## İŞLEM AŞAMALARI

İşlem gerçekleştirmek amacıyla sol femoral arterlere 8F 25 cm sheat takıldı. Eşzamanlı sol brakial artere 7F 90 cm uzun sheat yerleştirildi. brakialden 0.35x135 cm mikrokater desteğiyle 0.018x210 cm Pointer marka tel, 0.035 260 cm hidrofilik tel ile darlık geçilemeyince, hidrofilik telin arka kısmı ile sağ iliak osteal total darlık kısmı penetre edildi. Sonrasında 0.035 260 cm hidrofilik tel ve mikrokater desteğiyle darlık distaline sağ SFA'ya gelindi, daha sonra mikrokater içinden 0.018 300 cm Nitrex marka tel ile değişim yapıldı. Sol femoral arterdeki sheat üzerinden de 0.035 260 cm hidrofilik tel ile sol osteal iliak lezyon geçildi. Öncelikle sol brakial arter üzerinden sağ iliak darlık 5.0x60 mm balon ile predilate edildi. Daha sonra aortaya taşıyacak şekilde sağ iliak artere 8.0x37 mm balon expendable stent, sol iliak artere de 8.0x37 mm balon expandanle stent eş zamanlı şişirildi. Aynı stentlerin balonlarıyla flaring yapıldı. Daha sonra sağ iliak arter geri kalan darlığı kaplayacak şekilde sağ femoral arter başına kadar uzanan lezyona 6.0x100 mm balon ile dilate edildi. Optimal sonuç elde edildi. (Resim 2, Video 2)



Resim 1



Resim 2

## TARTIŞMA VE SONUÇ

İliak arterlerin kronik total oklüzyonları tecrübe gerektiren ve komplikasyonlara açık girişimlerdir. Eşzamanlı aortadaki darlıkların varlığı işlem riskini daha da artırmaktadır. Bu tarz aortoiliak ve kronik lezyonlarda eşzamanlı brakial girişim yapılması, hidrofilik tellerin arka kısmı bazen tehlikeli olsada proksimal kep kısmının delinmesi için kullanılması başarı şansını artırmaktadır. Vakamız buna iyi bir örnek teşkil etmektedir.



## A Case of Iliac Stent in a Patient with Old Type 3 Aortic Dissection

Çağlar Alp, Taner Sarak

Department of Cardiology, Kırıkkale University, Kirikkale, Turkey

### INTRODUCTION

Endovascular treatment in peripheral arterial diseases is frequently used in clinical practice. The development of high-tech equipment and the increased experience of the operators allow the intervention of complex lesions. We present a case with chronic dissection in the abdominal aorta and a total occlusion of the iliac ostium.

### CASE

A 70-year-old male patient presented to our clinic with the complaint of claudication and pain in his left hip (fontaine IIb). In the examination, amplitudes of the left dorsalis pedis artery, left tibialis posterior artery and popliteal artery pulses were low. Left ankle brachial index was 0.3. In his medical history; he was admitted to the emergency department with a complaint of back pain 3 months ago, and Type 3 aortic dissection was detected (Figure 1) then medical follow-up decision had been taken. Peripheral angiography was performed due to ongoing leg pain. Angiography showed dissection of the left iliac artery ostium and 100% occlusion (Figure 2). We decided to intervene into the occluded lesion. We tried to cross the lesion with crossover from right side but we could not. We placed a sheath into the left femoral artery, first we tried to cross the lesion with 0.014 wires with micro-catheter support but we could not. Then we used 0,035 hydrophilic wire and crossed the lesion. We would like to confirm that the wire is in the aortic lumen because of the presence of aortic dissection in the patient and the iliac ostium being dissected. For this purpose, we placed a ima catheter over the 0,035 mm wire and directed to the wire toward the right femoral region. Then we externalised to the wire from right catheter (Figure3). So we confirmed that the wire

is in the aortic lumen we deployed to the lesion 9x57 mm balloon expandable stent. Finally iliac artery flow restored (Figure 4).

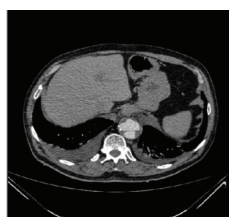


Figure 1  
Aortic dissection at T 12 level

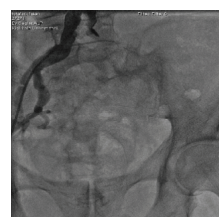


Figure 2  
Left Iliac Osteal Lesion

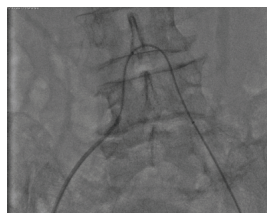


Figure 3  
Crossover image of 0.035 wire

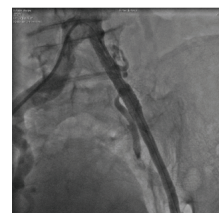

Figure 4  
Post stenting image

### CONCLUSION

In total iliac lesions, percutaneous transluminal angioplasty may be performed by femoral antegrade (crossover), retrograde or brachial route. In these lesions it is important to confirm that the distal end of the wire is in the true lumen after the lesion has been passed. To confirm this, end injection can be made from the microcatheter. Or blood supply and pressure monitoring from the microcatheter may be guiding. Another method to show that, it is not in the subintimal area, touching with the other pubic-guided pigtail to the tip of the wire in the aorta. As in our case, externalizing the wire from the other groin is another method, it also gives good support for the stenting.

### Keywords

total iliac lesions, Aortic dissection, iliac stenting

# Novel Balloon Tamponade Technique for Superficial Femoral Artery Perforation

Suat Görmel, Murat Çelik

Department of Cardiology, Gülhane Training and Research Hospital, Ankara, Türkiye

## INTRODUCTION

Perforations along the superficial femoral artery (SFA) can occur from a variety of causes; if unrecognized or mismanaged, they can result in significant morbidity and even mortality. We report the occurrence of a SFA perforation and successful management in a patient with discussing its etiologies, clinical impact, and treatments.

## CASE PRESENTATION

An 74-year-old man without a prior history of peripheral artery disease before presented for evaluation of bilateral hip and groin pain. Subsequent peripheral CT angiogram demonstrated right superficial iliac artery mid segment 15 cm length occlusion and left common iliac artery proximal stenosis. We decided to perform SFA balloon angioplasty firstly using contralateral crossover technique and than to stent ipsilateral retrograde left common iliac artery with the aim of avoiding possible stent related complications. However while crossing the lesion in the SFA antegradely with the support of the microcatheter and exchange-length wire we noticed a mild wire induced proximal perforation with frank extravasation on angiogram. Just then we tried to control the bleeding with a balloon tamponade for a few minutes and achieved to stop. After consulting with cardiovascular surgeons we agreed on proceeding. We successfully deployed three self-expandable overlapping stents in the mid segment SFA lesion after predilatation with appropriate sized balloon and a balloon-expandable stent in the left common iliac artery proximal stenosis with a very good angiographic result. The patient's hip and groin symptoms resolved follow-

ing the procedure, and he discharged the next day.

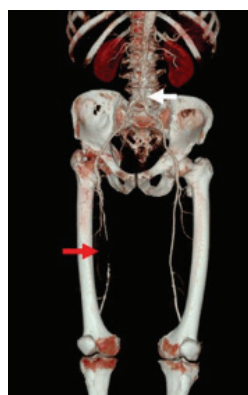

Figure 1 Computed tomography demonstrating the left proximal common iliac stenosis (white arrow) and right mid segment superficial femoral artery occlusion (red arrow).

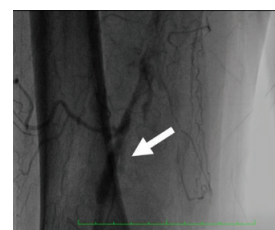


Figure 2 Peripheral angiogram demonstrating the extravasation due to the wire induced perforation (white arrow).femoral artery occlusion (red arrow).

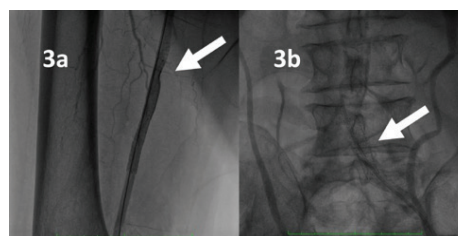


Figure 3 Peripheral angiograms showing right SFA (3a) and left common iliac (3b) stents

## CONCLUSION

This case illustrates an uncommon but clinically relevant, occurrence of SFA perforation and successful treatment.

## Keywords

percutaneous revascularization, perforation, peripheral vascular disease

# The Successful Treatment of The Superficial Femoral Artery Occlusion With Self-Expanding Stent

Ömer Faruk Baycan, Mustafa Adem Tatlısu, Şeref Kul, Yusuf Yılmaz, Fatma Betül Özcan,  
Mustafa Çalışkan

*Department of Cardiology, Istanbul Medeniyet University, Istanbul, Turkey*

## INTRODUCTION

A 67-year-old male presented to the our outpatient clinic with a 50m-claudication over the past 6 months, who was on cilostazol and clopidogrel for 2 years. He had a 40-pack-year smoking history. His past medical history included diabetes mellitus and he was on insulin treatment. He underwent digital subtraction imaging (DSA) and it revealed totally occluded left superficial femoral artery (SFA) at the level of bifurcation with deep femoral artery (Figure 1). We decided to intervene the lesion by using the contralateral approach from the right femoral artery. We passed the lesion with a 0.018 F hydrophilic wire, then the proximal and mid-level of SFA were dilated with 5x80 mm balloon. The control DSA showed dissection of the mid-SFA. The lesion was dilated with 6x80 mm drug-eluting balloon for 5-min.

We decided to deploy a self-expanding stent (7x100 mm) due to the fact that the dissection remained after the second angioplasty (Figure 2). The dissection of SFA at the level of bifurcation with deep femoral artery was seen and we did not intervene this lesion because of the good distal flow of the SFA and to protect the flow of deep femoral artery (Figure 3). The contralateral approach is commonly used for SFA lesions for adequate support. Most of the time, there is no need for stent deployment for SFA lesions unless there is a dissection that compromises the distal flow.

## Keywords

Peripheral intervention, self-expanding stent, superficial femoral artery

# Hybrid Approach In Thrombotic Critical Hand Ischemia

Erhan Saraçođlu

## BACKGROUND AND AIM

Critical hand ischemia represents a complex medical problem for even the experienced clinician. The rarity of hand ischemia, the small caliber of the distal vasculature, and the limited surgical options available for treatment all compound the difficulty of intervention. Percutaneous transluminal angioplasty (PTA) is now considered a first-line therapy for above-the-elbow artery disease while there are few data regarding the treatment of below-the-elbow (BTE) arteries. The aim of this study is to review the current literature on BTE vessel and early outcomes and comparison of three different treatment options; 1)standard embolectomy 2) standard endovascular angioplasty and 3) endovascular angioplasty approach including catheter-based thrombolysis plus iloprost

## METHODS

A prospective review of 14 patients treated with standard embolectomy (group-1), 11 patients treated with angioplasty (group-2) and 12 patients treated with endovascular angioplasty approach including catheter-based thrombolysis plus iloprost (group-3) was performed. Procedural success, procedural durations, patency estimates, complications, amputation rates and permanent disability were compared and analyzed

## RESULTS

When the standard embolectomy(group-1) and standard endovascular angioplasty group (group-2), was compared with endovascular angioplasty approach including catheter-based thrombolysis plus iloprost group(group-3). Amputation rates and permanent disability were similar in group 1 and group 2 and higher than group 3( $p<0.001$ ). But procedure duration and bleeding was significantly increased in group-3 ( $p<0.001$ ).

## CONCLUSIONS

Endovascular angioplasty including catheter-based thrombolysis plus iloprost treatment of below-the-elbow arteries is effective than the standard embolectomy or standard endovascular angioplasty in patients with critical hand ischemia, with an elevated immediate technical success and satisfactory clinical results

## Keywords

Critical hand ischemia, below-the-elbow arteries, Thrombolytics, Thrombolysis

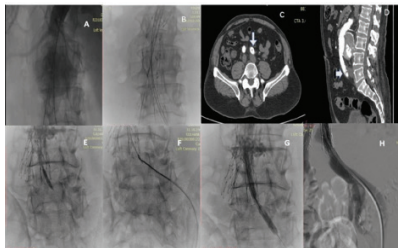
## Successful Percutaneous Treatment of Severe Left Common Iliac Stenosis Due To The N-BCA Embolization After Endoleak Closure

Atila Iyisoy, Ömer Faruk Keskin

Gülhane Training and Research Hospital

In previous reports using of n-BCA has been described in the treatment of type 1 endoleak after abdominal endovascular aneurysm repair. The most feared complication of this procedure nontargeted embolization into arterial circulation and catheters being glued to the graft. In our case, we retrieved the catheter successfully but n-BCA embolized left iliac artery and cause severe stenosis. We report a case that percutaneous successful angioplasty and stent implantation of left common iliac artery due to the n-BCA material which was embolized to the left iliac artery, which is a fearful complication.

A 69-year-old man who presented to our clinic an 63x61,5 mm asymptomatic saccular aneurysm of the abdominal aorta (Fig 1A ). Aneurysm was treated percutaneously with an AFX Endovascular AAA System (Endologix, USA) (Fig 1B).



A type 1A endoleak was noticed during the procedure. So we decided to treat the endoleak with n-butyl-2-cyanoacrylate (n-BCA) embolization during procedure. A solution n-BCA and 50% iohexol contrast agent was prepared and was injected slowly through the pigtail catheter which was still in the aneurysm sac under the graft stent to the site of the endoleak where proximal edge of the stent graft. Subsequently, the catheter was withdrawn under the graft stent. At the end of the pro-

cedure, we noticed a moving part of solution but later it was immobil so we finished the procedure. On clinical follow-up,the patient had a great problem during walking within short distance because of feeling severe pain at his left leg. On the examination, we could not get the left lower extremity pulses including femoral artery. CT tomographic angiography showed severe stenosis of left common iliac artery probably due to the trombus material (Fig 1C,1D). We decided to perform percutaneous intervention. A 0,014 inch hi torque 40 floppy guidewire was advanced using Judkins 6Fr diagnostic right coronary catheter via right common femoral artery approach and lesion was crossed but the balloon could not be advanced due to narrow iliac angulation because of the metallic graft material. We crossed the lesion via right brachial artery using 0,014 inch hi torque 40 floppy guidewire through the right coronary catheter and then we performed angioplasty with 3,5x20 mm Invader PTCA balloon several times (Fig 1E). We crossed the lesion with the 0,035 guidewire via right brachial artery, so we used a snare to catch the 0,035 guidewire via left femoral artery retrogradely. The wire removed from left femoral sheath (Fig 1F). First, we performed angioplasty over 0,035 guidewire with a 7x30 mm periferic balloon and then we implanted a 12x30 balloon expandable stent and then angiographic result was excellent (Fig 1G, 1H). On clinical follow, his left lower extremity pulses were taken strongly. The embolized n-BCA material, very though material, was treated successfully percutaneously.

Keywords: periferic intervention,n-BCA embolization,endoleak closure



# Step By Step Recanalization of The Long Segment In-Stent Total Occlusion of Superficial Femoral Artery

Fehmi Kaçmaz

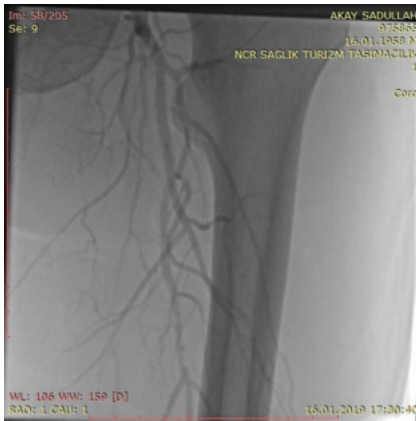
Cardiology, NCR International Hospital, Gaziantep, Turkey

60 years-old male patient admitted to our hospital with complaint of left foot wound and pain. On his history, stent deployment of superficial femoral artery 2 years ago was recorded. he was operated due to foot wound by plastic and reconstruction surgeon 3 months ago but because of unhealing wound Doppler-ultrasound has been performed and total occlusion of ostial part of left superficial femoral artery has been detected. On physical examination, no pulse found on blow the knee arteries. Angiography was performed and total occlusion at the ostial part of superficial femoral artery was detected. On angiography nearly 340 mm of total occlusion segment including in-stent part was calculated. Angioplasty was planned. Firstly, 7-F 65 cm long sheath was introduced to right superficial femoral artery. Then, 0.035 inch hydrophilic staright tip 260 cm wire with 0.035 inch support catheter was used to cross the total segment. After crossing the total occlusion. Af-

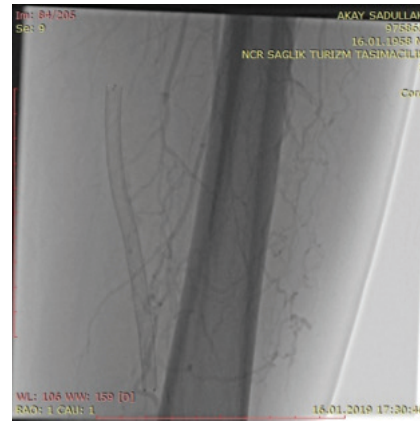ter crossing the total segment guide wire was delivered to posterior tibial artery. However, support catheter could not advanced over the hydrophilic wire. Firstrly, we thought that we crossed stent struts not allowing to cross the support catheter instent part of lesion. When we controlled the stent struts on zoom image we suered that the wire was int stent lümen. so, we changed the hydrophilic wire with extra support wire(supra core) then we colud crossed instent part of lesion with support catheter. After tip injection, we saw that we were in true lumen. Then, 3.0x120 mm, 6.0x120 and 6.0x100 mm balloons were used. On last angiogram, good result was obtained and procedure was finalized.

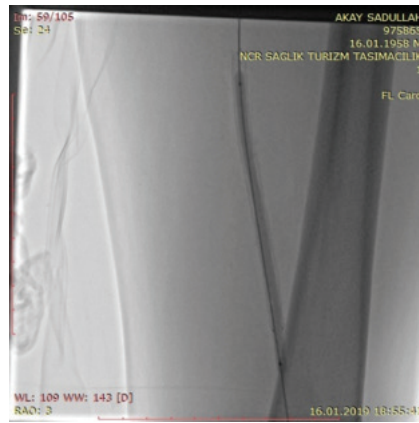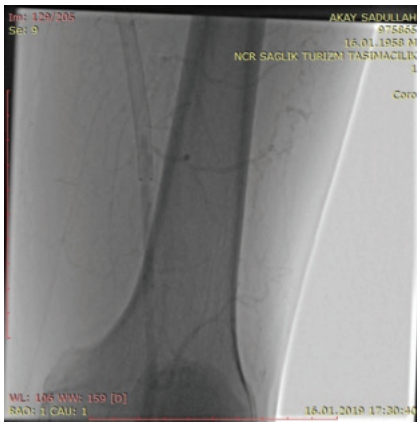## Keywords

in-stent, long, total occlusion, succesful angioplasty

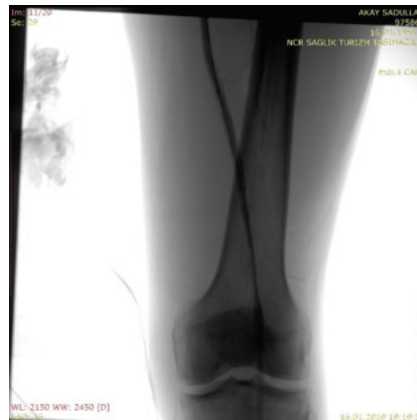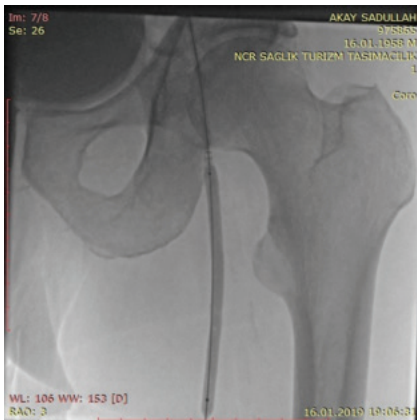


Before angioplasty

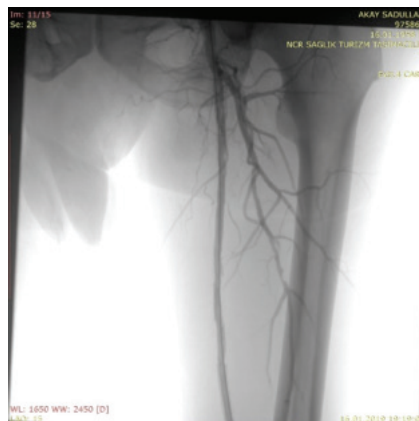




BALLON



BALLON



post-angioplasty

# Above-The-Knee Percutaneous Peripheral Arterial Interventions Experience İn Selcuk University Hospital

Bulent Behlul Altunkeser, Abdullah Tuncez

Department of Cardiology, Selcuk University, Konya, Turkey

## AIM

Advances in endovascular therapies during the past decade have broadened the options for treating peripheral arterial disease (PAD) percutaneously. Percutaneous interventions offers a lower risk of alternative compared to surgery in many patients with multiple comorbidities. Aim of the present study is to evaluate the procedural features and results of above-the-knee percutaneous transluminal angioplasty in our center. METHODS: All patients undergoing above-the-knee percutaneous transluminal angioplasty from September 2014 to January 2019 were retrospectively evaluated. Interventional procedural data were obtained from hospital records.

## RESULTS

There were 68 (66.44±10.54 years, %89.7 male) patients underwent above-the-knee percutaneous transluminal angioplasty. 11 (% 16.2) patients have also below-the-knee PAD. Baseline clinical characteristics and comorbidities of the study population are showed in table 1. Procedural and material features are seen in table 2. Our procedural success was %94.1. Any mortality wasn't seen in periprocedural period.

## CONCLUSION

Percutaneous interventions for the management of periper arterial disease are performed with high procedural success in our center. Appropriate patients should be evaluated for percutaneous intervention.

## Keywords

peripheral arterial disease, percutaneous interventions, Above-the-Knee PAD

**Table 1. Baseline characteristics of the study population (n=68)**

Age, years	66.44±10.54
Sex, male, n (%)	61 (89.7)
Coronary artery disease, n (%)	44 (64.7)
Hypertension, n (%)	44 (64.7)
Diabetes mellitus, n (%)	27 (39.7)
Smoking, n (%)	45 (66.2)
Concomitant below-the-knee PAD, n (%)	11 (16.2)

**Table 2. Procedural and material features of the study population (n=68)**

Number of patients undergoing stent deployment, n (%)	48 (70.6)
Number of stents per patient	1.37±1.43
Number of patients used balloon expandable, n (%)	20 (29.4)
Number of balloon expandable stent per patient	0.41±0.72
Number of patients used self expandable, n (%)	35 (51.5)
Number of self expandable stent per patient	0.93±1.27
In patients undergoing stent deployment	
-Length of stent per patient, mm	153.81±137.53
-Diameter of stent, mm	8.32±1.34
Number of patients used conventional balloon, n (%)	57 (83.8)
Mean number of conventional balloon per patient	2.29±2.22
In patients used conventional balloon	
-Length of conventional balloon per patient, mm	217.96±193.54
-Mean diameter of conventional balloon, mm	6.34±1.54
Number of patients used drug-coated balloons, n (%)	31 (45.6)
Mean number of drug-coated balloons per patient	1.16±1.71
In patients used drug-coated balloon	
-Length of drug-coated balloon per patient, mm	261.29±182.72
-Mean diameter of drug-coated balloon, mm	6.33±2.11
Access site	
Ipsilateral femoral, n (%)	32 (47.1)
Contralateral femoral, n (%)	22 (32.4)
Brachial, n (%)	6 (8.8)
Ipsilateral + Contralateral femoral, n (%)	1 (1.5)
Contralateral femoral + Brachial, n (%)	5 (7.4)
Ipsilateral femoral + Brachial, n (%)	2 (2.9)
Intervention location	
Common iliac artery, n (%)	27 (39.7)
External iliac artery, n (%)	20 (29.4)
Common femoral artery, n (%)	8 (11.8)
Profunda femoral artery, n (%)	1 (1.5)
Superficial femoral artery, n (%)	39 (57.4)
Graft intervention, n (%)	6 (8.8)
Atherectomy, n (%)	3 (4.4)
Thrombus aspiration, n (%)	7 (10.3)
Fibrinolytic therapy, n (%)	3 (4.4)
Procedural success, n (%)	64 (94.1)

## Catheter Directed Intraarterial Thrombolysis For Lower Extremity Arterial Occlusions

Yilmaz Gunes, Isa Sincer, Emrah Erdal, Oguz Kayabasi

*Bolu Abant Izzet Baysal University Medical Faculty Hospital Cardiology Department*

### AIM

Use of catheter-directed thrombolysis (CDT) has been widely increased. Compared to surgical embolectomy it may achieve complete clot removal and establishment of patency for inaccessible small vessels, potentially with limited intimal injury. The main limitations include failure to achieve complete lysis, prolonged time to revascularization and the occurrence of hemorrhagic complications.

### RESULTS

During year 2018 we have performed catheter directed thrombolysis to 28 patients in our clinic. 19 patients were presented with acute thrombotic limb ischemia. 9 patients had undergone CDT due to thrombus formation triggered during management of chronic peripheral occlusions during peripheral angioplasty (PTA) intervention.

After a selective intraarterial bolus injection of 5-10 mg dose of recombinant tissue-type plasminogen activator (tPA) a continuous infusion for 24 hours is continued at 1.0 -2.0 mg//h (recently we use 1 mg/h protocol) using a multisided port catheter passed through the thrombus (or a microcatheter in some instances). Anticoagulation was managed with intravenous heparin or s.c enoxaparin. Success of treatment was evaluated with clinical judgment or control angiography. Success was accepted on clinical basis in one patient without control angiography. All the remaining patients had control angiography. Clinical judgment (loss of pain, warming of foot and fingers, restoration of pulses) was predictive for successful lysis of thrombus in most of the patients.

### CONCLUSION

Acute presentation was managed with first tPA in 8 cases and first fragmentation with PTA followed by tPA in 11 cases. CDT was unsuccessful in 4 acute embolic patients who had severe underlying atherosclerotic disease and severe below the knee lesions with poor run off. First tPA was able to achieve complete resolution of thrombus burden in 3 patients. 3 patients having tPA infusion were undergone PTA for residual stenosis. In 2 patients with unsuccessful tPA infusion following PTA was able to restore perfusion. tPA infusion following fragmentation with PTA was successful in all of the patients with complete or near complete resolution of thrombus burden. 4 of those patients were managed with repeat PTA for underlying atherosclerotic disease.

Of the 9 patients developing thrombus burden during PTA intervention for chronic occlusions tPA was successful for lysis of thrombus and restoration of perfusion in 3 patients. Among remaining 6 patients one was managed with stenting, two had undergone amputation and 3 were followed with medication. of the 2 patients developing intracranial hemorrhage one was died and one was followed without neurological deficit.

### CONCLUSION:

Catheter directed intraarterial thrombolysis using continuous infusion with a relatively low dose of tPA is an effective and safe first-line treatment in cases presenting with acute limb ischemia and selected cases after peripheral interventions.

### Keywords

limb ischemia, catheter directed thrombolysis, tPAAbove-the-Knee PAD

# Results of 16 Months of Experience in Endovascular Treatment of Peripheral Artery Disease

Levent Altınay, Elif Coşkun

Department of Cardiovascular Surgery, Zonguldak Bülent Ecevit University, Zonguldak, Turkey

## AIM

Endovascular treatment of peripheral artery disease (PAD) is a common method recently. It becomes more common as the technology develops. Herein we represent our results of 16 months of experience in endovascular treatment of PAD and report our cases who were undergone surgery.

## TOOLS AND METHOD

Between June 2017 – December 2018, 110 patients were undergone for endovascular treatment because of PAD and 130 endovascular interventions were performed in these patients in our center. The data were collected retrospectively. The first intervention modality, the second intervention modality if present, the time of patency after the first intervention were noted.

## RESULTS

Nine (8%) patients were undergone re-interventions for re-stenosis. Seven (77%) were male and 2 (23%) were female. Mean age was  $65,44 \pm 16,33$  years, mean body mass index (BMI) was  $31,72 \pm 7,99$  kg/m<sup>2</sup>. Two (23%) patients had hypertension, 3 (30%) patients had hyperlipidemia, 7 (77%) patients were smokers, 5 (55%) patients had diabetes, 3 (30%) patients had coronary artery disease and one (11%) of them was undergone coronary artery bypass graft surgery. In 7 (77%) patients the primary interventions were percutaneous balloon angioplasty (PTA) and stent implantation. In 2 (23%) of the patients, the primary interventions were only PTA. Mean follow-up time was  $7,9 \pm 7,49$  months. In 3 (30%) of these patients, the secondary endovascular treatment did not succeed and they were undergone surgery as follows: left femoral – posterior tibial artery bypass was

performed in 1, right axillary-femoral artery bypass was performed in 1 and minor extremity amputation was performed in 1 patient. The restenosis was successfully cured in the other patients with PTA and stent implantation. Mean stent diameter was  $6,92 \pm 1,0$  mm, mean stent length was  $87,50 \pm 26,67$  mm, mean PTA diameter was  $5,88 \pm 1,09$  mm and mean PTA length was  $98 \pm 35,09$  mm.

## DISCUSSION

We had restenosis in 9 (8%) of 110 patients. And open surgery was needed in 3 (30%) of these patients and one of these patients was undergone minor extremity amputation. This patient was presented with critical limb ischemia and tissue gangrene was already present in distal of his lower extremity and the endovascular intervention was performed to lower the amputation line. As the technology advances, more patients with more severe PADs are being referred for endovascular interventions. Open surgery is reserved for unsuccessful endovascular treatments or for the patients who are not eligible for any endovascular intervention.

We think that although endovascular treatment is easy to perform with very good patency rates, open surgery will be the helping hand that we can always trust.

## Keywords

Peripheral artery disease, open surgery, restenosis, endovascular treatment.



# The First Patient Experience of Our Clinic Suited The Peripheral Arterial Disease Arm of The COMPASS® Trial

Koray Demirtaş, Idris Yakut, Mustafa Karanfil, Ahmet Akdi, Sefa Ünal,  
Çağrı Yayla, Ahmet Göktuğ Ertem

*Kardiyoloji Kliniği Sağlık Bilimleri Üniversitesi Ankara Türkiye Yüksek İhtisas Eğitim Araştırma Hast.*

A 75-year-old female patient with a history of multiple peripheral (below the knee intervention) ballooning and stenting was admitted to our clinic with critical leg ischemia. She was diabetic, hypertensive and already in the compensated heart failure clinic with decreased left ventricular ejection fraction (EF:38%). Three months prior to her admission to our hospital, femoral artery stenting extending to the left iliac artery and at the same session drug-coated peripheral balloon to the anterior tibial artery (ATA) were applied at another institution. One month after these procedures, the peripheral balloon was performed again at a second different center due to increased leg pain. However, leg ulcers continued to increase. The patient admitted our clinic with painful critical leg ischemia requiring morphine treatment (Figure 1). The most significant symptoms were muscle pain and effort limitation related to leg ischemia. Doppler Ultrasonography showed no flow in the left anterior tibial artery.

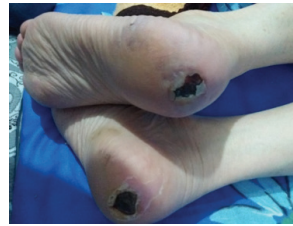
After re-evaluating the patient, we decided to take her back to a new peripheral intervention. During the procedure left anterior femoral artery cannulated antegradely. Anterior tibial artery was wired through the thumb artery (Figure 2). ATA was first predilated with drug free balloons. Then multiple dilatations were performed with drug-coated balloons. The final angiogram showed no dissection and the ATA was open till the fingertip (figures 3,4). On discharge, Rivaroxaban 2.5 mg 2 times a day and Clopidogrel 75 mg once daily were prescribed similar to the treatment design in the peripheral arterial disease arm of COMPASS trial.

After these procedures and medication the foot ulcers

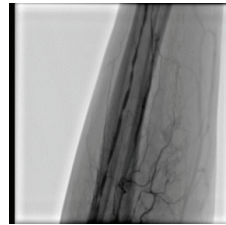
were significantly reduced with the help of wound care at the second month control (Figure 5). With Doppler Ultrasonography, ATA was reported to be open.

## Keywords

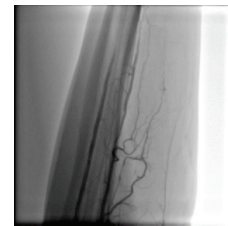
peripheral artery disease, below the knee intervention, peripheral drug coating ballooning, rivaroxaban



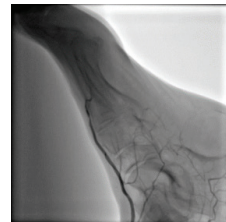
Pre-procedural Foot ulcers with necrotic debris



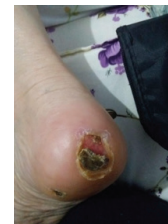Before balloon multiple lesions in anterior tibial artery.



Two months after the procedure; healing of foot ulcers



Final angiogram after two sets of peripheral ballooning dorsalis pedis artery



Two months after the procedure; healing of foot ulcers

# Management of Main Iliac Stent Thrombosis in Acute Period

Salih Kilic, Erhan Saracoglu

Doctor Ersin Arslan Research and Training Hospital, Department of Cardiology

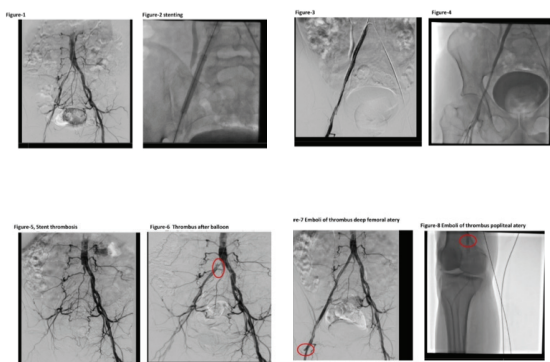
## BACKGROUND

Although early stent thrombosis is not frequent after main iliac artery (MIA) stenting, it carries high risk of leg amputation and requires rapidly intervention. However, there are different approaches to intervention.

## CASE

56 year old male patients admitted to cardiology outpatient clinic with progressive increasing claudication. In color doppler ultrasonography monophasic flow has reported in main femoral artery (FA). Digital substrate angiography (DSA) was performed from the left FA and showed 95% stenosis in ostial right main iliac artery (MIA). Lesion wired and after pre-dilatation with 6.0\*80 mm balloon, 8.0\*57 mm balloon expandable greft stent and 7.0\*40 mm balon expandable stent implanted from ostial of right MIA (Figure 1-4). Patient discharged with clopidogrel 75mg/day and 100mg/ day. Two week after procedure he admitted to hospital with complaint of acute right leg pain, numbness and bruising on the right toes. In the patient who was not taking any medication, DSA was performed with suspicion of acute stent thrombosis. Right MIA was observed totally occluded from ostial. Lesion wired and dilateted with 7.0\*100 balloon. After dilatation mobile thrombus was observed in ostail MIA. Thromboaspiration was performed via right judkins (6F) catheter. In the control images the thrombus in the MIA was resolved significantly however, the deep FA and popliteal artery occluded due to embolic thrombus (Figures 5-8). As a result of this, we dediced to follow patient with medical therapy. 300mg aspirin, 300mg clopidogrel loaded and low glycoprotein IIb / IIIa inhibitor infusion (12.5 mg tirofiban /24h) were started. Low molecular

weight heparin (1 mg/kg) started after tirofiban infusion finished and continued till seven days. In the 3th day of follow-up pulse of distal artery was palpable and symptoms of patient relieved. Patients discharged with 75mg/day aspirin and 75mg/day clopidogrel. In the control ultrasonography that performed two weeks later normal flow pattern was observed in distal arteries. .



## CONCLUSION

In our patient who developed critical leg ischemia following acute stent thrombosis; thrombus burden was reduced by post-thromboaspiration and then resolved with tirofiban infusion together with dual antiplatelet therapy and low molecular weight heparin.rust.

## Keywords

Stent thrombosis, thromboaspiration, tirofiban infusion

# TAVI Sonrası Beşinci Günde İliyak Arter Ruptürünün Perkütan Tedavisi

Mustafa Öztürk

Department of Cardiology, University of Health Sciences,  
Erzurum Education and Research Hospital, Erzurum, Turkey

71 yaş kadın hasta akut pulmoner ödem (PÖ) tablosunda kliniğimize başvurdu. Hipertansiyon ve ileri evre KOAH öyküsü olan hastanın çekilen elektrokardiyogram normal sinüs ritmi olup klinik ve laboratuvar değerlendirme sonucu miyokard infarktüs düşünülmüdü. Yapılan transtorasik ekokardiyografide ejeksiyon fraksiyonu %25, sol ventrikül (LV) global hipokinezi, LV çapları normal (54/36 mm), sol atrium hafif dilate (42 mm), İleri aort darlığı (AD) (Mx VEL: 4,9 m/s MxG:90 mmHg MnG:51mmHg AVA:0,7 cm<sup>2</sup>), sol ventrikül hipertrofisi, hafif mitral yetmezlik, orta triküspit yetmezliği, pulmoner hipertansiyon (sPAB:70 mmHg) izlendi. Hastanın ileri AD ve PÖ açısından maksimal medikal tedavisi düzenlendi. Klinik rahatlama sağlandıktan sonra kalp-damar cerrahi ile AD açısından konsülte edilen hastada konsey kararı ile TAVI (transfemoral aortik valv implantation) planlandı. (Logistic Euroscore: %33,85).

Radial yoldan yapılan koroner anjiyografide nonkritik lezyonlar izlendi ve medikal takip kararı alındı. Hasta 02/12/2016'da TAVI için katater laboratuvarına alındı. Periferik vasküler giriş için Prostar kullanıldı. 20 mm balon ile valvüloplasti sonrası 23 mm Edwards Saphien XT kapak implante edildi (Figür-1A). Komplikasyon olmadı. İşlem sonrası alınan perifer anjiyografi görüntülerde iliac arter intakt olarak değerlendirildi (Figür -1B). Koroner yoğun bakım takiplerinde hemodinamisi stabil seyreden ve ek şikayeti olmayan hasta takip ve tedavisinin devamı için 48 saat sonra kardiyo-loji servisine alındı.

Hastanın TAVI sonrası 5. günde (07/12/2016) ani başlayan karın ağrısı, hipotansiyon, soğuk ve soluk terleme şikayeti oldu. Çekilen kontrastlı pelvik ve abdomen tomografide rectus kasında 7,5\*6 cm ebatlarında,

mesaneyi ve pelvik ansları deviyeye eden retroperitoneal 13,5\*7,5 cm ebatlarında aktif kanama izlendi (Figür-2). Hasta acil şartlarda katater laboratuvarına alındı. Sol femoral arterden ponksiyon yapıldı. Yapılan perifer anjiyografide sol external iliac arter proksimalinde ruptür olduğu izlendi (Figür-1C). Önce 7,0\*37 mm balon expandable vascular covered stent implante edildi. Extravazasyonun devam ettiği izlendi. Ardından 9,0\*58 mm balon expandable vascular covered stent implante edildi. Kontrol görüntülerde extravazasyonun olmadığı izlendi (Figür-1D). Kanama kontrolü sağlanan hastanın hemodinamisi stabilleşti. Takiplerinde ek problemi olmayan hasta şifa ile taburcu edildi.

## TARTIŞMA

Perkütan kapatma cihazları kullanımı ile hasta konforunda artış ve hastaların yatış süresinde belirgin kısalma olmuştur. Ancak vakamızda olduğu gibi arteriel komplikasyonlar geç dönemde de gözükabilir. Bu nedenle işlem sonrası takiplerin daha dikkatli yapılması ve hastaların yeterli süre takip edilmesi gerekmektedir.. Ayrıca katater laboratuvarında olası komplikasyonlar için yeterli donanımın bulunması işlem başarısının artırılması ve mortalite-morbiditenin azaltılması için önemlidir.

## Keywords

TAVI, geç vasküler komplikasyon, kanama

# Three Cases of Ischemic Stroke Who Underwent Trombectomy During The Use of Novel Oral Anticoagulants

Türkan Acar<sup>1</sup>, Bilgehan Atılgan Acar<sup>1</sup>, Harun Kılıç<sup>2</sup>, Aysel Milanlıoğlu<sup>3</sup>, Ramazan Akdemir<sup>2</sup>

<sup>1</sup> Sakarya University Medical Faculty, Department of Neurology, Sakarya, Turkey

<sup>2</sup> Sakarya University Medical Faculty, Department of Cardiology, Sakarya, Turkey

<sup>3</sup> Van Yüzüncüyıl University Medical Faculty, Department of Neurology, Van, Turkey

## INTRODUCTION

Although the efficacy of warfarin has been demonstrated in the treatment of AF, the use of suboptimal and low utilization rates has led to the development of new oral anticoagulants (NOACs) for stroke prophylaxis in AF patients.

## CASE ONE

A 67-year-old male patient with Rivaroxaban 20 mg use per daily presented with right middle cerebral artery (MCA) M1 occlusion in 3 hours of onset. Initial NIHSS was 15 while initial mRS was 4. IV tPA is not given to the patient due the use of NOAC in the last 24 hours. The patient was underwent mechanical thrombectomy after neuroimaging. The patient was discharged at 24 hours after postoperatively with apiababan 5 mg twice daily.

## CASE TWO

68-year-old female patient with Dabigatran 150 mg use twice daily was admitted to emergency department with left MCA M2 occlusion. Initial NIHSS was 19 with an initial mRS: 4. She did not receive IV tPA due the use of NOAC within the last 24 hours. The patient underwent mechanical thrombectomy after neuroimaging. After the procedure, the patient was discharged with apiababan 5 mg twice daily.

## CASE THREE

A 80-year-old female patient using Apiksaban 5 mg twice daily was admitted to the emergency department with a diagnose of left MCA M1 occlusion. Initial NIHSS was 24 while initial mRS was 4. She was not given IV tPA due the use of YOAC within last 24 hours. The patient underwent mechanical thrombectomy after neuroimaging. NIHSS

was 22 and mRS was 4 after 24 hours and she was followed up with ASA 150 mg per daily due to wide infarction.

## DISCUSSION

In studies with NOACs, they are all showed non-inferiority compared to Vitamin K antagonists. In all, NOACs are related a significant reduction in the risk of hemorrhagic stroke and intracranial hemorrhage, also are shown not to lead a significant increase in the risk of major bleeding compared to warfarine. However, it is difficult to say which one of among those NOACs is far superior due to the lack of heterogeneous clinical studies comparing each other. In this case, in the light of the available data, certain factors related to the patient may guide the choice of NOACs. On the other hand, new generation anticoagulants come into prominence in patients who have frequent INR fluctuations or are not eligible for warfarin treatment. There is no clear evidence for the efficacy and safety of NOACs in patients with effective INR control, but in patients with frequent INR fluctuations or not suitable for warfarin treatment NOACs are prominent. New generation oral anticoagulants may be safer in patients with increased risk of intracranial hemorrhage, while warfarin may be safer in the presence of gastrointestinal bleeding.

## RESULT

We believe that considering the patients' comorbid conditions while choosing NOACs in AF induced embolic prophylaxis will decrease the risk of cardioembolic stroke

## Keywords

Stroke, NOACs, Trombectomy

# Interatrial Conduction Properties Among Patients With ST-Segment Elevation Myocardial Infarction

Gokhan Altunbas

Gaziantep University School of Medicine Department of Cardiology

## OBJECTIVE

The most significant clinical association of interatrial block (IAB) was found with increased risk of atrial fibrillation and ischemic stroke. In this study, we sought to evaluate P wave duration and interatrial block in patients presented with acute ST-segment-elevation myocardial infarction (STEMI) who underwent primary percutaneous coronary intervention (PCI).

## METHODS

We performed a retrospective analysis of patients presented with acute STEMI who underwent emergent PCI. Follow-up electrocardiograms were obtained from electronic database system. Echocardiographic data were also obtained from electronic patient records. Electrocardiographic measurements were performed using SEMA Workstation 3.8.1 (Schiller AG).

## RESULTS

Primary analysis included 200 consecutive patients with STEMI. However, there were 20 in-hospital deaths and 83 patients were lost to follow-up. Remaining 97 patients (80 male, 17 female) were included in the final analysis. Mean age was 57,02 12,18 years. There were 48 patients with anterior STEMI and 49 patients with inferior STEMI. Mean duration of follow-up was 11 months and ECGs at the end of the follow up revealed that the frequency of partial and advanced IAB were 13,2% and 7,7% respectively. Statistical analysis showed that neither P wave duration nor IAB showed significant association with the infarct related artery lesion localization. Also, the degree of systolic dysfunction was not associated with IAB. Only male gender and left atrial diameter had significant positive correlation with

P wave duration.

Table 1. Baseline characteristics of the patients

Mean age (years)	57,02±12,18
Gender	Male: 80
	Female: 17
EF (%)	50,63±10
P wave duration (ms)	112,81±16,92
LA diameter (mm)	36,98±5,83
Lesion localization	LAD: 48
	Cx: 19
	RCA: 30

Table 2. The mean±standard deviation values of electrocardiographic P wave duration of the patients based on culprit lesion localization

	Cx (n:19)	LAD (n:45)	RCA (n:30)	p
P wave duration (ms)	112,26±15,26	114,71±19,18	110,93±14,32	0,92

## CONCLUSION

IAB was not rare in patients with a history of acute coronary syndrome. The infarct related artery does not seem to have a significant correlation with interatrial conduction.

## Keywords

interatrial block, acute coronary syndrome, electrocardiography



## “Comparison of Echocardiographic Parameters In First Trimester Obese and Non-Obese Women

Veciha Özlem Bozkaya<sup>1</sup>, Zeynep Aslı Kaplan<sup>2</sup>

<sup>1</sup> Department of Cardiology, Zekai Tahir Burak Women's Health Education and Research Hospital, Ankara, Turkey

<sup>2</sup> Department of Obstetrics and Gynecology, Zekai Tahir Burak Women's Health Education and Research Hospital, Ankara, Turkey

### INTRODUCTION

The physiological changes during pregnancy may shade the signs and symptoms of an underlying heart disease. In this study we aimed to analyze the echocardiographic parameters of obese and non-obese pregnant women.

### MATERIAL-METHOD

The study was conducted between March 2017 and March 2018, in Zekai Tahir Burak Women's Health and Research Hospital. 517 pregnant women in first trimester of pregnancy, who attended to antenatal polyclinic for routine pregnancy follow-up were enrolled in this study. Followed by routine pregnancy examination, patients underwent electrocardiography (EKG) and transthoracic echocardiography (TTE) examination. The patients were divided into two groups according to body mass index (BMI): non-obese (BMI < 29.9) (n = 440); and obese (BMI ≥ 30) (n = 77).

### RESULTS

In this study, cardiovascular disease (CVD) incidence in pregnant women was 7.4%. Mean age was; 27.4 years; systolic and diastolic blood pressure were higher in obese women compared to non-obese. E' values were higher among non-obese compared to obese women. E/Ea ratio was higher in obese group compared to non-obese group. Obese women had increased right atrial EDD, left ventricular end-diastolic diameter (EDD) and left atrial EDD compared to non-obese women. The rate of structural cardiac anomalies between obese and non-obese women were similar. Among non-obese women, the structural cardiac anomalies which were detected on TTE were atrial septal defect (ASD)(n=3); rheumatismal heart disease (RHD)

(n=12); mitral valve prolapsus (n=16); patent foramen ovale (n=2); situs inversus (n=1), mild pulmonary regurgitation (PR)(n=13), mild aortic regurgitation (AR)(n=8); moderate AR (n=1), mild mitral regurgitation (n=46); severe MR (n=1); atrial septal aneurysm (ASA)(n=32) Among obese women the structural cardiac anomalies which were detected on TTE were; RHD(n=3), PFO(n=2), patent ductus arteriosus (PDA)(n=1), ASA(n=2), ASD (n=2), mild AR(N=2), mild MR(n=6), moderate MR (n=1), mild PR (n=5), moderate pulmonary stenosis (PS) (n=1).(Table1). ASA was the most common structural cardiac anomaly among the whole study population (n=34, %6.58). The most common cardiac disease was MVP among all CVD. Incidence of rheumatismal heart disease was also higher than congenital cardiac anomalies, similar with developing countries.

### CONCLUSION

As obesity is an independent risk factor of maternal mortality and morbidity during pregnancy, it deserves extra attention for detailed cardiac screening at the beginning of pregnancy. Detailed echocardiographic examination will lead us to determine which patients will need more attention during follow-up for CVD during pregnancy. This study would help to develop follow-up of protocols for pregnant women with cardiac structural anomalies and to analyze the cardiac risks associated with obesity during pregnancy.

### Keywords

Pregnancy, obesity, transthoracic echocardiography

## The Level Of SCUBE1 In Patient with Critical Limb Ischemia

Salih Kilic

Doctor Ersin Arslan Research and Training Hospita, Department of Cardiology, Gaziantep, Turkey

### BACKGROUND AND AIM

SCUBE1 [signal peptide-CUB (complement C1r/C1s)-EGF (epidermal growth factor)-like domain-containing protein 1] might function as a novel platelet-endothelial adhesion molecule and play pathological roles in cardiovascular biology. The most common cause of PAD is atherosclerosis, implying that the risk factors for PAD are similar to those for other atherosclerotic vascular disease. Critical limb ischemia is associated with poor results regarding minor or major lower limb amputations with devastating psychological effects and a negative impact on patient survival. In present study we aimed to evaluated whether SCUBE1 level is associated with critical limb ischemia in patients with PAD.

### METHODS

Between January 2016 to December 2018 76 consecutive patients diagnosed with PAD with angiography were conducted to study. Patients were divided into two groups according to the Rutherford classification; Group-1 (class 1,2,3), Group-2 (class 4,5,6). Patient baseline characteristics laboratuary parameters, and SCUB1 level were recorded at the time of angiography.

### RESULTS

Patients baseline chracteristics and laboratory parameters are summarized in Table-1. There were no significant differences between groups in term of traditional cardiovascular risk factors; hypertension, diabetes mellitus, hyperlipidemia, and smoking. However, in the both groups majority of patients has hypertension, diabetes mellitus, history of coronary artery disease and smoking. Mean systolic and diastolic blood pressure level were higher in Group-2 than Group-1 and in both

groups the mean level were higher than recommended level. Mean level of LDL-cholesterol level were significantly higher in Group-2 than Group-1. Also, mean level of SCUBE1 was higher in Group-2 than Group-1 ( $117 \pm 45.4$  ng/ml vs.  $83.9 \pm 40.4$  ng/ml;  $p=0.001$ )(Figure). The other laboratory parameters were similar between groups.

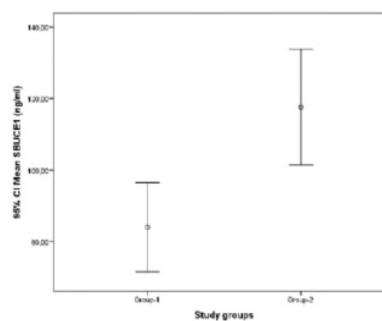


Figure. SCUBE1 level in study groups.

### DISCUSSION

In present study showed that the level of SCUBE1 is higher in patient with critical limb ischemia. The SCUBE1 might contribute to acute critical limb ischemia via thrombus activation and aggregation. To the our best knowledge, there were no previous study that show the relationship between SBUCE1 level and critical limb ischemia. In our study population SCUBE1 level is significantly higher than other patients with PAD. However, our study group is small and it needs to confirm in other studies with high number patients.

### Keywords

Critical limb ischemia, platelet-endothelial adhesion molecule, atherosclerosis

# Low Serum Bilirubin Levels Associate with Subclinical Atherosclerosis in Patients with Obstructive Sleep Apnea

Hakan Duman<sup>1</sup>, Songül Özyurt<sup>2</sup>

<sup>1</sup> Department of Cardiology, Faculty of Medicine, Recep Tayyip Erdoğan University, Rize, Turkey

<sup>2</sup> Department of Chest Diseases, Faculty of Medicine, Recep Tayyip Erdoğan University, Rize, Turkey

## INTRODUCTION

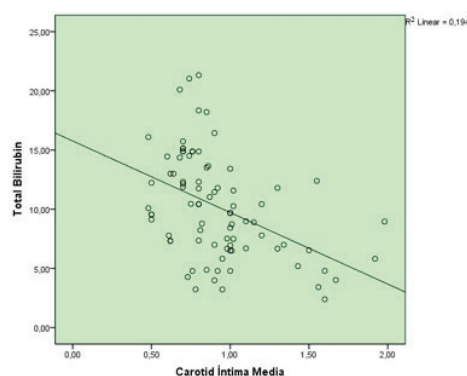
Obstructive Sleep Apnea (OSA) is a chronic, progressive disease which can cause cardiovascular complications and atherosclerosis. We evaluated the relationship between serum bilirubin levels and carotid intima-media thickness (cIMT), as a surrogate marker of subclinical atherosclerosis, in patients with OSA.

## METHODS

We enrolled 84 consecutive patients with OSA. The patients underwent ultrasonography, polysomnography and echocardiography. Blood samples were obtained from all of the subjects, which were used for biochemical comparisons. The patients were divided into groups according to cIMT values (<0.9 vs >0.9 mm).

## RESULTS

The patient population consisted of 84 OSA patients (mean age 54.2 ± 8.0 years; 62.9% male). The OSA patients with cIMT ≥ 0.9 had significantly elevated high-sensitive C-reactive protein (hsCRP), Oxygen desaturation index (ODI), apnea hypopnea index (AHI) and significantly lower total and indirect bilirubin levels. Multivariate regression analyses revealed Total bilirubin, hsCRP and AHI were the independent predictors of subclinical atherosclerosis. There was a negative correlation between total bilirubin and cIMT (Figure 1).



Bilirubin values according to the thickness of carotid intima-media thickness

## DISCUSSION

We have showed a study a relationship between subclinical atherosclerosis and total bilirubin levels in OSA patients. The present study revealed a negative correlation between total bilirubin and cIMT. Total bilirubin, AHI and hsCRP was found to be an independent risk factor for subclinical atherosclerosis. Simple measures such as total bilirubin may provide predictive information regarding the risk of cardiovascular disease in patients with OSA.

## Keywords

bilirubin, obstructive sleep apnea, carotid intima-media thickness, antioxidant

# Yaygın EKG Depresyonu İle Prezente Olan Sol Ana Koroner Arter Darlığının TAP Stentleme İle Başarılı Tedavisi

Uğur Aksu, Kamuran Kalkan

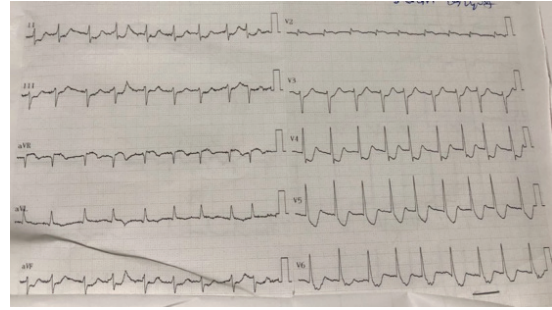
Bölge Eğitim Araştırma Hastanesi, Kardiyoloji Kliniği, Erzurum

## GİRİŞ VE AMAÇ

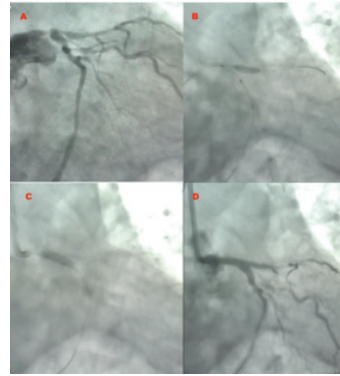
Kritik Sol Ana Koroner Hastalığı oldukça yüksek mortalite ve morbidite ile seyreder. Ayrıca tedavisi de özellik arzeder. Bu sunumda, ileri yaşlı bir hastada yaygın EKG bulguları başvuran bir Ana Koroner Olgusu ve tedavi sonucu sunulması amaçlanmıştır.

## OLGU SUNUMU

86 yaşında erkek hasta yeni başlayan göğüs ağrısı ile acil servise başvurdu. Bakılan EKG de yaygın ST depresyonu ve aVR derivasyonunda ST elevasyonu tespit edildi (Resim-1). Ekokardiyografide global hipokinezi tespit edilen hastaya Akut koroner sendrom ön tanısıyla acil koroner anjiyografi planlandı. Hastaya sağ femoral yoldan Judkins tekniği ile yapılan koroner anjiyografide sol ana koroner arter distal ucunda %99 lezyon (Resim-2A) ve devamında LAD ve CX arterinde multipl kritik lezyonlar tespit edildi. Hastaya CABG kabul etmemesi üzerine girişim planlandı. LAD ve CX guidewire ile geçildikten ve predilate edildikten sonra CX arterin daha dominant olması ve LAD midde CTO izlenmesi üzerine LMCA dan CX'e 3\*20 DES ve sonrasında 3.5\*15 NC uygulandı. Sonrasında LAD rewire edildi ve 1\*12 saphire II balon ile predilate edildi. ve TAP stentleme ile LAD ye DES implante edildi. Final kissing (Resim-2B) ve LMCA'ya POT (Resim-2C) yapılarak TIMI III akım sağlandığının görülmesi üzerine (Resim-2D) işleme son verildi. LAD ve CX arterinin diğer damarları için başka seansta staged PCI planlanarak işleme son verildi.



Yaygın ST depresyonu ve aVR elevasyonu



Koroner anjiyografi ve girişim basamakları

## SONUÇ VE TARTIŞMA

Perkütan koroner girişim akut koroner sendromlarda köşe taşıdır ve LMCA lezyonlarında artmış komorbid durumlar nedeniyle CABG'ye iyi bir alternatiftir. LMCA lezyonlarında hastanın hemodinamik ve klinik durumu göz önünde bulunmak koşuluyla kompleks girişim yöntemleri tercih edilmelidir.

## Keywords

miyokardiyal enfarktüs, perkütan girişim, bifurkasyon stentleme

## Single Center Atrial Septal Defect Closure Experiences

Feyzullah Besli, Zulkif Tanriverdi, Fatih Gungoren, Mustafa Begenc Tascanov

*Department of Cardiology, Harran University, Sanliurfa, Turkey*

### INTRODUCTION

Atrial septal defect (ASD) is the most common congenital anomaly in adults. Transcatheter treatment of ASD is the first therapeutic choice by the improvement in interventional techniques with lower complication rates. Major complications of this procedure include device embolization, pericardial effusion with or without tamponade, endocarditis and device thrombus. In this study, we aimed to present our experiences of percutaneous ASD closure in a single center.

### METHODS

Between January 2017 – January 2019, patients with ASD in whom transcatheter closure was performed were investigated retrospectively. All patients assessed extensively that included laboratory tests, electrocardiogram and echocardiography. Closure of ASD was performed under local anesthesia and with intraprocedural Transesophageal Echocardiography. Basal demographic characteristics, major complication rate and used devices were recorded.

### RESULTS

A total of 23 patients were treated and followed for 1 month in our center. Mean age of the study population was  $28.7 \pm 10.9$  (minimum: 17 years, maximum: 52 years) with

a 69.6% (16 patients) of females. Most common symptoms of the patients were palpitation and then dispne. The mean diameter of defect size was  $19.7 \pm 6.3$  milimeter. Percutaneous closure was performed to all patients with a suitable ASD device. Minimal pericardial effusion was occurred in one patient and successfully recovered with medical therapy. Device embolization was developed in three patients, all of them treated successfully (left ventricle, descenden aorta and iliac artery). Devices that embolized to left ventricle and descenden aorta were removed out with a snare, whereas device that embolized to iliac artery jailed with a peripheral balloon expandable stent. Minor complications including inflammatory reactions, cardiac arrhythmias, and femoral access site complication were not observed in any patient.

### CONCLUSION

Percutaneous closure of ASD is a safer, more effective and relatively easier intervention than surgical closure. Therefore, it should be performed as the first treatment choice for suitable patients.

### Keywords

Atrial septal defect, Congenital anomaly, Percutaneous closure



# Acute Anterior Myocardial Infarction Due To Coronary Slow flow In Patient With Rheumatoid Arthritis

Hakan Duman, Hüseyin Durak

Department of Cardiology, Faculty of Medicine, Recep Tayyip Erdoğan University, Rize, Turkey

## INTRODUCTION

Coronary slow flow phenomenon is an angiographic phenomenon which opacification of the vessel is delayed without obstructive epicardial coronary artery disease. In this case we reported a 75 years old man with a diagnosis of rheumatoid arthritis and severe anterior myocardial infarction whom coronary angiography revealed a severe coronary slow flow in the left descending coronary artery.

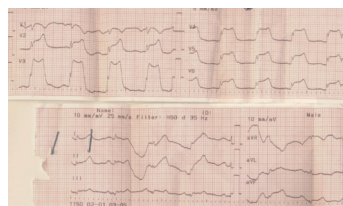
## METHODS

75 years old man patients with no known coronary artery disease was admitted to the emergency department for the pressure sensation pain which was behind the sternum and spreaded both arms. His electrocardiography revealed st segment elevation in V1-V6 deviations and He was referred to our clinic with the diagnosis of acute anterior myocardial infarction (Figure 1). The patient had a history of rheumatoid arthritis and he was not taking regular medication. Initial physical examination revealed blood pressure of 120/80 mmHg, respiratory rate of 22/min and a pulse rate of 70/min. Coronary angiography was performed in the catheter laboratory immediately. coronary angiography showed severe slow flow in the left anterior descending coronary artery, no stenosis, and no slow flow in other coronary arteries and branches (Figure 2). On follow up visits troponin I level up to 7.8 mg/L., a two-dimensional echocardiogram showed anterior wall hypokinesia and ejection fraction was 42%, LDL cholesterol 82 mg/dL, C-Reagent protein 15 mg/L, white blood cell count  $8 \times 10^3/\mu\text{L}$  measured.

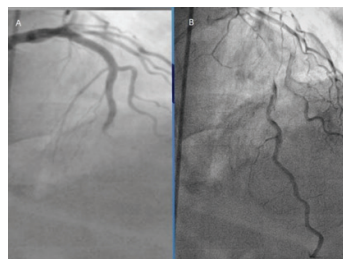
## RESULTS

The patient was diagnosed as st elevation myocardial

infarction due to coronary slow flow. The patient who have good clinical condition and no recurrent chest pain, was consulted with the rheumatology clinic. Lenflunamid 100 mg loading, 20 mg 1x1 maintenance, acetylsalicylic acid 100 mg 1x1, klopidoğrel 75 mg 1x1, ramipril 5 mg 1x1, atorvastatin 40 mg 1x1, isasorbid mono nitrat 50 mg 1x1, metoprolol 50 mg 1x1 was prescribed and discharged.



The ECG of the patient during his first referral to the emergency department. ECG shows significant ST segment elevation in leads V1-6.



Left circumflex, Diagonal and septal arteries are filled, but the distal of the left anterior descending artery is still not full. B: Filling of the left anterior descending coronary artery. No obstruction was detected in the coronary arteries.

## DISCUSSION

Rheumatoid arthritis is a disease with systemic inflammation. coronary slow flow is a non-obstructive coronary event that may be associated with endothelial dysfunction and inflammation, which may rarely lead to acute coronary syndrome. we would like to emphasize that other non-obstetric causes should be considered in addition to atherosclerosis acute coronary syndrome in rheumatoid arthritis patients

## Keywords

Slow-flow phenomenon, Acute anterior wall myocardial infarction, Rheumatoid arthritis

# Clinical Outcomes at In Hospital and One-Year After Treatment of Arteriovenous Hemodialysis Fistulas With Percutaneous Transluminal Angioplasty

Mustafa Ahmet Huyut

*Yeni Yuzyil University Hospital Gaziosmanpasa- Bati Bahat Hospital*

## BACKGROUND AND AIM

Treatment of arteriovenous fistulas with percutaneous balloon angioplasty is safe and effective at short term follow up. The current study aims to investigate the clinical outcomes at in hospital and 12 months after treatment of arteriovenous hemodialysis fistulas with percutaneous balloon angioplasty.

## METHODS

Twenty one patients (11 men; mean age 65,61  $\pm$ 7,47 years), who underwent successful recanalization of brachial arteriovenous fistulae stenosis, were recruited in this study from July 2016 to January 2018 (16 brachio-cephalic, 5 ulno-basilic distal AVF). After achieving haemodynamic success (<30% residual stenosis) procedure was stopped. The follow-up intervals were 3, 6 and 12 months. Clinical endpoints analyzed, included the composite of all-cause death, hemodialysis insufficiency due to restenosis and acute thrombosis of fistula.

## RESULTS

Five consecutive patients were (all-cause) death (23,8 %), fistula dysfunction recurred in three patients (14,28 %), PTA was repeated in two patients (9,52 %) and one patient referred to surgery (4,76 %) at a median FU time of

340 days. No thrombosis was observed. One-year primary patency was 85,72%  $\pm$ 3,24. Under no access-induced distal ischemia occurred during follow-up.

## CONCLUSIONS

Treatment of arteriovenous fistulas with percutaneous balloon angioplasty was safe and effective in the treatment of hemodialysis fistulae with acceptable restenosis at mid-term follow-up.

## Keywords

Arteriovenous fistula, balloon angioplasty, dialysis, hemodialysis.

# The Relationship Between The Erectile Dysfunction and The Clinical and Angiographic Severity of Peripheral Arterial Disease

Seçkin Dereli

Ordu State Hospital, ORDU

## BACKGROUND

The increasing prevalence of peripheral arterial diseases (PAD) is one of the important causes of cardiovascular morbidity and mortality worldwide and is an important health burden for our country. Erectile dysfunction (ED) shares common pathways and risk factors with vascular diseases; the relationship between ED and PAD was previously demonstrated by different studies. The aim of our study was to determine whether ED could predict the severity of the disease in patients with PAD who had undergone peripheral angiography.

## METHODS

A total of 82 newly diagnosed patients who were scheduled for peripheral angiography between 2017 and 2018 were included in the study. The demographic characteristics of the patients (age, sex, smoking, hypertension, diabetes, cardiovascular disease, hyperlipidemia) were questioned and reported. ED was assessed using the International Index of Erectile Function (IIEF-5). The severity of the disease was determined by the Rutherford classification according to patients symptoms and physical examination findings and it was also determined after the intervention by the TASC-II classification using the angiographic findings.

## RESULTS

ED was present in 63 subjects (77%). 40 patients (49%) had severe symptoms according to Rutherford classification. All of the patients (n=82) underwent peripheral angiography. According to angiography findings, 57 (70%) of the patients were evaluated as TASC-II type

C-D. Logistic regression analyzes were performed to determine the variables affecting the severity of the disease. ED was found to be an independent predictor of severity of disease for both Rutherford and TASC-II classifications. There were also other independent predictors; age, smoking.

## CONCLUSION

In our study age, smoking and ED were determined as the independent predictors of Rutherford and TASC-II classification. ED, that can be easily identified by a shortened and written questionnaire; provide an estimate of the severity of PAD. These findings suggest that ED is associated with an increased risk of cardiovascular disease. Thus, patients with severe ED may be assumed to have higher priority for more frequent and advanced cardiovascular evaluation with aggressive treatment of cardiovascular risk factors.

## Keywords

erectile dysfunction, peripheral arterial disease, Rutherford classification, TASC-II classification

**Multivariate logistic regression analysis of independent parameters to define the severity of peripheral arterial disease by using TASC-II classification**

	Univariate	analysis	Multivariate	analysis	
variables	r	p	$\beta$ coefficient	95%CI	p
Age	0.504	<.001	0.769	(1.346-3.415)	.001
DM	0.048	0.526			
HT	0.176	0.029			
CVD	0.102	0.097			
Smoking	0.554	<.001	0.650	(1.256-2.715)	0.001
LDL- cholesterol	0.015	0.856			
Hemoglobin A1c	0.102	0.175			
Statin use	-0.156	0.050			
Anti-platelet use	-.257	0.003			
Rutherford class	0.657	<.001	0.105	(1.052-1.115)	0.001
ED	0.657	<.001	45.572	(37.15-53.99)	0.001

DM: diyabetes mellitus; HT: hypertension; CVD: cardiovascular disease; LDL: Low-density lipoprotein; ED: Erectile dysfunction

**Multivariate logistic regression analysis of independent parameters to define the severity of peripheral arterial disease by using Rutherford classification**

	Univariate	analysis	Multivariate	analysis	
variables	r	p	$\beta$ coefficient	95%CI	p
Age	0.421	<0.001	3.090	(2.081-4.100)	0.001
DM	0.143	0.067			
HT	0.102	0.097			
CVD	0.272	<0.001			
Smoking	0.537	0.001	3.326	(2.153-4.500)	0.001
LDL- cholesterol	0.144	0.065			
Hemoglobin A1c	0.144	0.065			
Anti-platelet use	-.342	0.001			
Statin use	-0.237	0.05			
TASC-II class	0.387	<0.001	3.326	(2.153-4.500)	0.001
ED	0.421	<0.001	3.090	(2.081-4.100)	0.001





OP(CP-02)

## Successful Treatment of External Iliac Artery Perforation with Covered Stent In A Patient with Hemorrhagic Shock

Ibrahim Kocayigit, Harun Kılıç, Emre Eynel, Murat Aksoy, Yusuf Can, Salih Şahinkuş

Department of Cardiology, University of Sakarya

### AIM

Retroperitoneal hemorrhage from iliac artery perforation is a rare and life threatening condition if not diagnosed and treated immediately. In this presentation we aimed to discuss successful treatment of external iliac artery perforation with covered stent in a patient with hemorrhagic shock.

### CASE REPORT

A 49-year-old woman presented to emergency department with the abdominal pain and tenderness in left lower quadrant and rectal bleeding. Medical history revealed a abdominal hysterectomy and bilateral oophorectomy operation due to the endometrial cancer 3 months ago and pelvic radiotherapy was performed after the surgery. Laboratory studies showed a hemoglobin of 6.39 g/dl and hematocrit 19.1 % with normal liver and kidney function. Abdominal computerized tomography showed a lobulated fluid collection compatible with abdominal abscess with a size of 10x4.5 cm next to the left iliopsoas muscle and descending colon (figure-1). CT angiography showed the extravasation of the contrast due to the erosion of the external iliac artery by the abdominal abscess. The patient was hospitalized to general surgery department for further evaluation and treatment. Massive bleeding required multiple transfusions and emergent endovascular intervention was planned because the patient became hemodynamically compromised. The femoral artery was accessed via the right groin. The digital subtraction angiogram showed the extravasation arising from left external iliac artery (figure-2). Diffuse vasospasm in the artery was also seen due to the hemodynamic compromise. An

8.0 x 59 mm balloon expandable covered stent was deployed to the left external iliac artery with successful sealing of the perforation (figure-3). Hemodynamically significant dissection occurred in the proximal region of the stented segment. Then a 8.0 x 39 mm balloon expandable stent was deployed to the dissected segment. Control angiography showed no further extravasation and dissection then the procedure was ended (figure-4). The patient was transferred to the intensive care unit.

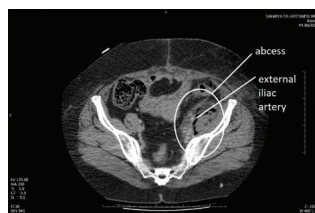


figure-1

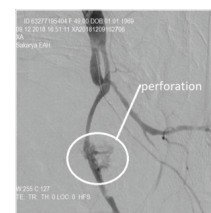


figure-2

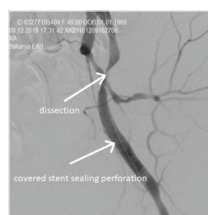


figure-3

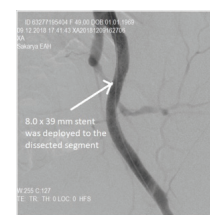

figure-4

### DISCUSSION

The iliac artery perforation is a rare and life threatening condition. Although various treatment modalities have been reported in the literature, endovascular treatment with covered stents appears to have emerged as the treatment of choice, especially for hemodynamically compromised life-threatening perforations.

### Keywords

external iliac artery, perforation, covered stent

OP(CP-03)

## Successful Use Of Atherectomy And Embolic Protection Filter In A Patient With Severe Common Femoral Artery Stenosis

Gokhan Altunbas

*Department of Cardiology, Gaziantep University School of Medicine*

### AIM

There are many therapies for peripheral arterial diseases. In this presentation, we aimed to discuss a case of Successful use of atherectomy and embolic protection filter in a patient with severe common femoral artery stenosis.

### CASE REPORT

A 69-year old male patient admitted with complaints of rest angina and severe claudication (Class III) on right leg and right foot. First, coronary angiography and peripheral angiography were performed at the same session. There was severe atherosclerotic narrowing on proximal part of the left anterior descending coronary artery (LAD) and peripheral angiography showed severe atherosclerotic stenosis on right common femoral artery (CFA) (Fig 1). The next day, successful stenting of the LAD was performed. Fifteen days later, the patient is hospitalized for revascularization for CFA stenosis. Since the stenosis was on a flexible point of the body, stenting was avoided. First, 7Fr crossover sheath

was placed on the left CFA and directed to the right CFA. The stenosis was crossed with a 0,14 inch, 180 cm long wire. Due to the risk of embolization, 6 mm Spider embolic protection filter was placed near right popliteal artery P3 segment. Then, directional atherectomy was performed using HawkOne atherectomy device. There was substantial atherosclerotic debris at the device when removed (Fig 2). Angiographic view was also improved after atherectomy (Fig 3). After successful atherectomy, 6,0\*20 mm cutting balloon was performed and then 8,0\*60 mm drug-eluting balloon was performed. Final images show complete resolution of the atherosclerosis (Fig 4).

### DISCUSSION

Atherectomy and embolic protection filter usage is very easy in common femoral artery stenosis.

### Keywords

atherectomy, emboli protection, drug coated balloon

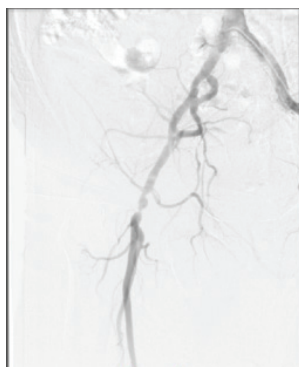


Figure 1: Angiography showing severe narrowing of right common femoral artery

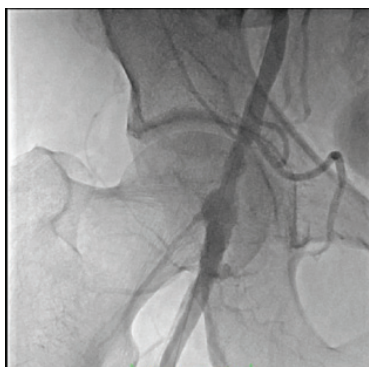

Figure 2: Angiography after atherectomy showing relieving of stenosis

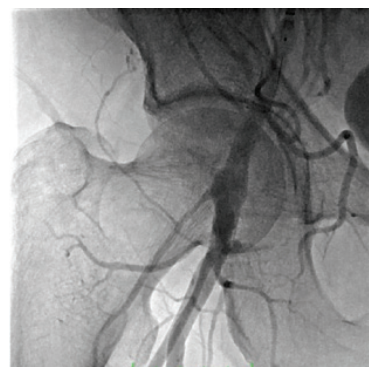

Figure 3: Final angiographic view after drug coated balloon angioplasty

OP(CP-04)

## Perkütan Tedavi Edilmiş Lerich Sendromu ve 2 yıllık Takip Sonucu

Zafer Kucuksu

Department of Cardiology, University of Sakarya

50 yaşında erkek hastanın eforla gelen bacak ağrıları olması üzerine çekilen ct anjio da Distal Aort un ve her iki ana iliak arterin total olması üzerine perkütan girişim planlandı.

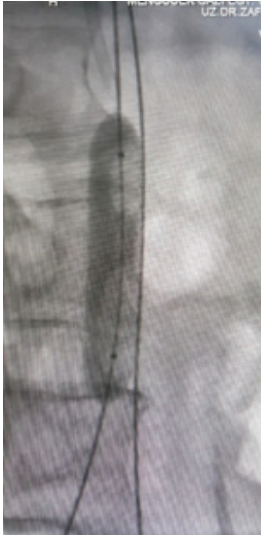Her iki femoral arter ve sol brakial arterlere sheath yerleştirildi total lezyonlar antegrad ve retrograd yolla geçildi önce PTA yapıldı sonra distal aorta balon expandable stent yerlestirildi.Her iki ana iliak artere proksimalleri ana govde stentinin icinde olacak şekilde kissing balon expandable stent yerleştirildi.Devamında iliak arterlerin distaline kadar her iki taraftan self ex-

pandable stent konuldu yalnız sol iliak artere self expandable stent konulurken lezyonun uzun olması nedeni ile femoral sheath geri çekilerek stent yerleştirildi. Çekilen kontrol anjiyografilerde sonucun optimal olduğu gözlemlendi.

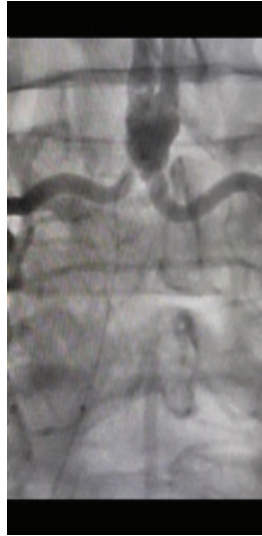Bir süre takipsiz kalan hasta nin yaklaşık iki yıl sonra çekilen CT anjiyografisinde stentlerin açık olduğu gözlemlendi.

### Keywords

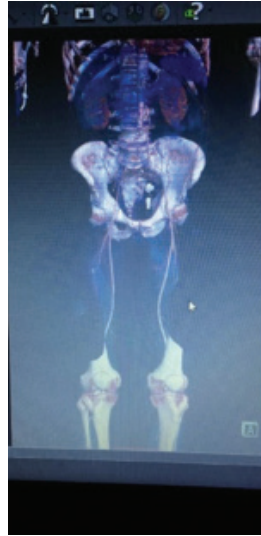
Lerich Sendromu, Aortik Stent,Kissing Stent



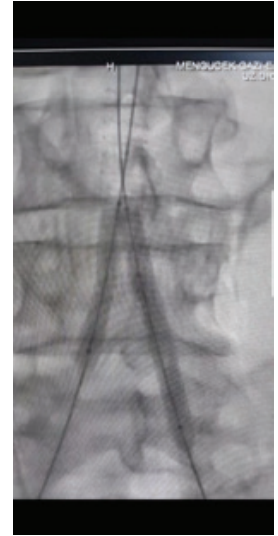
Aortik balon expandable stentin yerlestirilmesi



Brakial arterden yerleştirilen uzun sheath ile yapılan anjio Distal aort total,antegrad geçişe yol göstermesi amacıyla retrograd 0.35 wire yerleştirildi



İşlem öncesi 3D CT Anjio görüntüsü



Iliak kissing stent ile yeni karina olusturulması

# Akut Mezenter Arter Trombozu Hastanın Perkütan Endovasküler Girişimle Revaskülarizasyonu

Halit Acet, Faruk Ertaş

Department of Cardiology, Dicle University, Diyarbakır, Turkey

## OLGU

Daha önce Meme tm. nedeniyle mastektomi öyküsü olan 56 Yaşında kadın hasta endokrin kliniğinde DM-2, Hipertiroidi tanısıyla takip ediliyordu, hastada ani başlayan şiddetli karın ağrısı olması üzerine çekilen Batın Kontrastlı BT Anjiografisinde SMA'da lümeni tamamen dolduran tromboz saptandı.

Fizik muayenesinde Batında defans, rebound, hassasiyet mevcuttu. Akciğer ve kardiyak muayenesi doğaldı. Bakılan laboratuvar değerlerinde hemogram ve biyokimyasal parametrelerde hs-troponin;2144 (0-19), WBC;33000, EKG; Sinüs taşikardisi ve kalp hızı 130 civarındaydı. Mezenter arter görüntüleme ve tedavi amaçlı yapılan invaziv anjiografisinde; Süperieo mezenter arter proksimalinde total tromboze darlık mevcuttu, distal akım yok idi (Resim 1, Video 1). Perkütan işlem kararı alındı. Sağ femoral arterden ponksiyon yapıp sheat girildi, sonrasında 7F RCA kateter ile mezenter artere oturuldu 0.014 Nitrex tel ile mezenter arterdeki lezyon geçildi. Proksimal bölgeye 4.0\*15 mm ve 4.5\*20

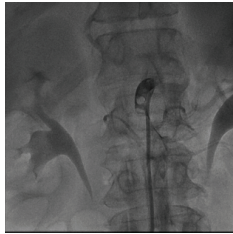
mm distal bölge 3.5x40, 3.5x60 mm balonlarla dilate edildi (Resim 2 ). SMA içine 10000 ü heparin ve aralıklı olarak toplamda 10 mg tpa 5'er mg tpa verildi. Trombüs aspirasyon kateteri ile trombüsün bir kısmı aspire edildi. Proksimalde tam açıklık distalde kısmi açıklık sağlandı. (Resim 3, Video 2). İşlem komplikasyonsuz olarak sonlandırıldı.

## TARTIŞMA VE SONUÇ

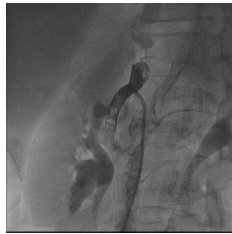
Karın ağrısı şikâyetiyle başvuran hastalarda, mutlaka mezenter iskemisi düşünülmelidir. Bu hastalarda konvansiyonel anjiyografi en iyi tanı yöntemidir. Bu hastalarda genel cerrahi ve kalp damar cerrahisini içeren multidisipliner yaklaşımın önemli olduğu düşüncesindeyiz. Özellikle komorbid risk faktörleri olan hastalarda perkütan endovasküler girişim ön planda tercih edilmelidir.

## Keywords

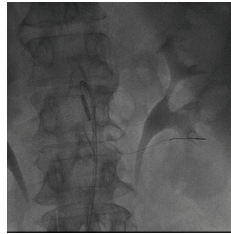
Mezenter Arter, Trombus, Perkütan Girişim



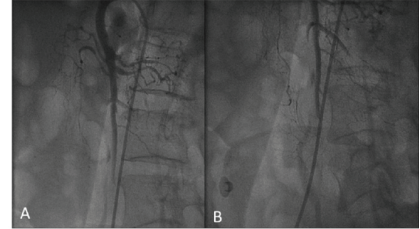
Resim 1



Resim 2



Resim 3



Resim 4



# Sol İliak Arter Darlığına Girişimde Gelişen Komplikasyonun Başarılı Yönetimi

Halit Acet, Faruk Ertaş, Bayram Arslan, Tuncay Güzel, Raif Kılıç, Mehmet Sait Coşkun,  
Nizamettin Toprak

Department of Cardiology, Dicle University, Diyarbakır, Turkey

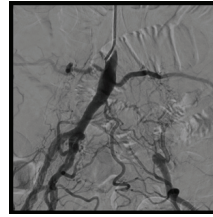
## OLGU

68 yaşında kadın hasta sağ ayağında ağrı, aralıklı sekleleme (Fontan 3, Rutherford 4 semptomlu) şikayeti ile merkezimize başvurdu. Dış merkezde yapılan alt ekstremité Doppler ultrasonografide sol iliak arterde kritik darlık saptanmış ve DSA önerilmiş. Merkezimizde yapılan DSA'da aortadan sol iliak arter distaline kadar kritik darlık saptandı (Resim 1, Video 1). Konsey kararı ile hastaya perkütan girişim kararı alındı.

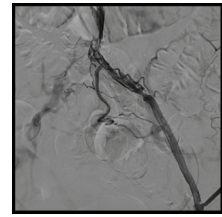
## İŞLEM AŞAMALARI

İşlemi gerçekleştirmek amacıyla sol brakial artere 7F 90 cm sheat, sol femoral artere 8F sheat girildi. Daha sonra 0.018 210 cm Pointer, 0.014 300 cm Nitrex marka teller ve 0.035 150 cm mikrokater ile aorto-osteal darlık geçildi. 4.5x20 mm balon ile predilatasyon yapıldı, daha sonra sol femoral arterden işleme devam kararı alındı, sol femoral arter üzerinden mikrokater ve kılavuz tel ile aortaya kadar gelindi, mikrokater içinden kan gelmesi üzerine aortaya düştüğümüzü düşünerek, buradan mikrokater içinden kılavuz tel gönderilip mikrokater çekildi daha sonra bu tel üzerinden Aorto-osteale 8.0x27 mm balon expandable stent implante edildi. Stent implantasyonundan sonra subintimal olduğumuzu fark ettik, tekrar brakial üzerinden aortada stentin hemen medialinden 0.018 210 cm Pointer tel ve 0.035 150 cm mikrokater ile ponksiyon yapıp femoral artere düşüldü. Bu tel üzerinden Aorto-osteal bölgeye osteale 8.0x27 mm ve 7.0x27 mm balon expandable stent ilk stenti crush edecek şekilde implante edildi, diseke eksternal iliak arter ve femoral artere de 5.0x60 mm self expandable stent implante edildi. 5.0x120 mm balon ile stent içi ve stent distalleri postdilate edildi. Sol

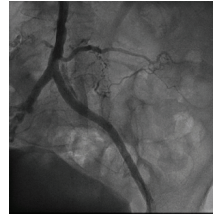
iliak aterde ve sol femoral arterde tam akım sağlandı. (Resim 2, Video 2)



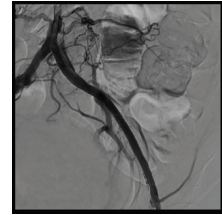
Resim 1A



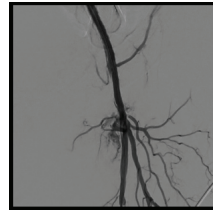
Resim 1B



Resim 2A



Resim 2B



Resim 2C

## TARTIŞMA VE SONUÇ

İliak arterlerin oklüzyonları tecrübe gerektiren ve komplikasyonlara açık girişimlerdir. Bu tarz lezyonlarda eşzamanlı brakial girişim yapılması, delici özelliği yüksek olan tellerin kullanılması başarı şansını arttırmaktadır. Olgumuz buna iyi bir örnek teşkil etmektedir.

## Keywords

İliak arter, periferik arter hastalığı, iliak arter perkütan girişim



OP(CP-07)

# Acute Aortofemoral Bypass Graft Occlusion After Coronary Angiography

Kudret Keskin<sup>1</sup>, Serhat Sığırcı<sup>1</sup>, Okay Abacı<sup>2</sup>

<sup>1</sup> Şişli Hamidiye Etfal Education and Research Hospital, Department of Cardiology

<sup>2</sup> İstanbul University, Institute of Cardiology

## INTRODUCTION

Although coronary angiography via peripheral bypass grafts is not an absolute contraindication, alternative access sites such as radial artery is desirable. Development of hematoma, retroperitoneal bleeding and acute thrombotic occlusion are among the most dreaded complications of these synthetic vascular grafts. In this case, we report an acute thrombotic occlusion of the aortofemoral bypass graft following percutaneous coronary intervention.

## CASE

A 65-year-old male patient with a history of hypertension, diabetes, peripheral artery disease with bilateral aortofemoral bypass grafts and chronic renal failure requiring hemodialysis was admitted to cardiology clinic because of acute coronary syndrome. After initial stabilization, the patient underwent coronary angiography via the right radial artery in order to avoid damage to the vascular grafts. His diagnostic coronary angiogram revealed significant stenosis in the mid portion of right coronary artery but the operator could not succeed to change the diagnostic catheter with the guiding due to the development of severe radial artery spasm. After multiple attempts, the operator switched to the left femoral route and used the left aortofemoral bypass graft for vascular access and completed the procedure successfully. The sheath was removed 4 hours later and a sand bag was placed for hemostasis. However, later in the course, the patient started having intractable ipsilateral leg pain and skin discoloration consistent with acute arterial occlusion. Without further delay, he was taken to the catheterization laboratory where peripher-

al angiogram via the right brachial artery revealed acute total occlusion of the left aortofemoral graft. A 0.035 inch hydrophilic guidewire passed the occlusion and multiple thrombus aspirations were performed along with intra-arterial tenecteplase and tirofiban administration. Antegrade flow was restored despite substantial residual thrombus. Later, the patient's symptoms and the findings related to occlusion disappeared completely. He was discharged one week later in stable condition.

## CONCLUSION

The incidence of acute iliofemoral bypass graft occlusion following vascular access was reported to be around 2.4%. Although rare, it can be a devastating complication leading to significant limb ischemia and possible limb loss. As recommended previously, if possible, alternative access sites should be chosen for intervention. However, when vascular access via a synthetic graft is mandatory, smaller diameter sheaths and minimal compression for hemostasis should be applied. Despite all efforts, if thrombosis occurs, thrombus aspiration, intra-arterial lytic therapy and GP 2b-3a inhibitors can be used to restore the flow. Vascular closure devices have no place for artificial grafts. Finally, the attending physician should be alert and have a low threshold for angiography if acute thrombosis is suspected in such cases.

## Keywords

aortofemoral graft, vascular access, thrombosis, occlusion

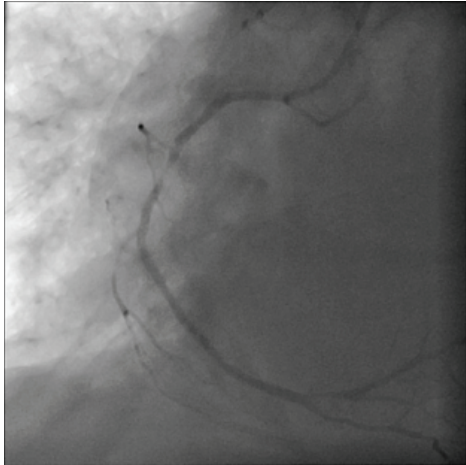

Figure 1: Diagnostic coronary angiogram showing significant right coronary artery stenosis

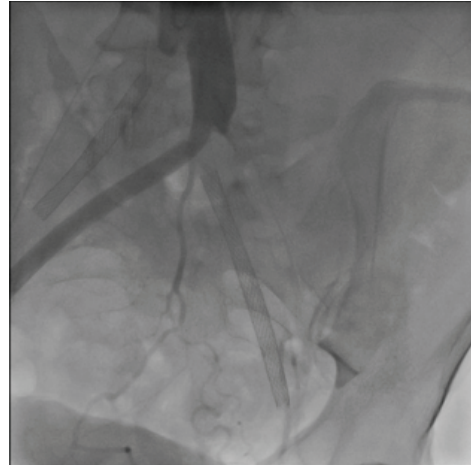


Figure 2: Acute left aortofemoral bypass graft thrombosis leading to total occlusion

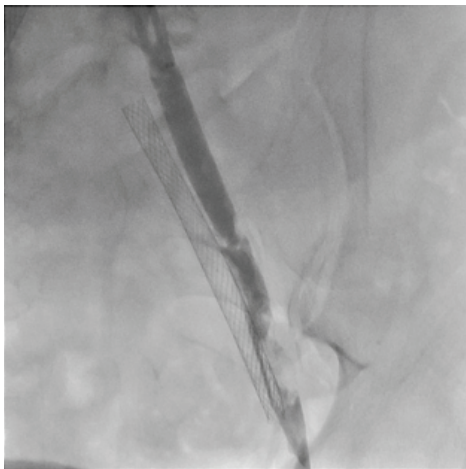


Figure 3: Restoration of antegrade flow despite substantial amount of residual thrombus

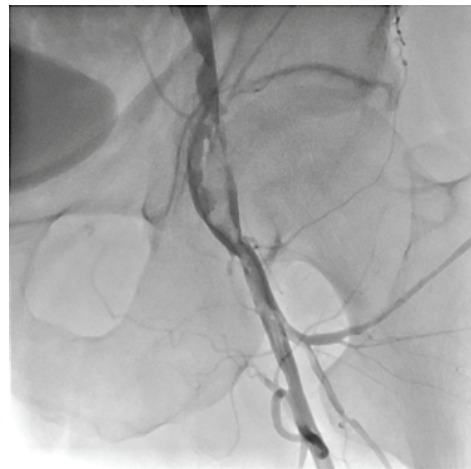


Figure 4: Restoration of antegrade flow despite substantial amount of residual thrombus

# Treatment of Late Common Femoral Artery Rupture by Cover Stent After Successful Transfemoral TAVI

Ali Rıza Akyüz, Levent Korkmaz, Hakan Erkan

University of Health Sciences, Trabzon Ahi Evren Cardiovascular and Thoracic Surgery Training and Research Hospital, Department of Cardiology

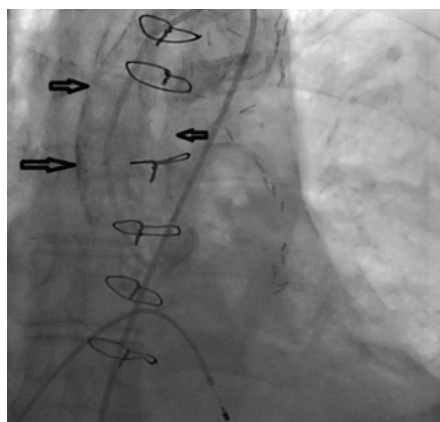
## INTRODUCTION

Transcatheter aortic valve implantation (TAVI) has emerged as a recommended therapeutic option for those patients with severe symptomatic aortic stenosis and ineligible for conventional surgical aortic valve replacement. Vascular complications are among the most frequent and serious complications of transfemoral TAVI and have been associated with significantly increased morbidity and mortality.

## CASE REPORT AND DISCUSSION

A 55-year-old man with a history of prior coronary artery bypass graft surgery admitted to our clinic due to severe progressive dyspnea. Transthoracic echocardiography (TTE) revealed severe aortic stenosis (mean gradient; 40 mmHg), mild aortic regurgitation, and a left ventricular ejection fraction (LVEF) of 0.45. The patient's Society of Thoracic Surgeons (STS) risk score was 4,184%. Since patient had a porcelain aorta (Figure 1), TAVI was recommended. According to the CT measurement (380 mm<sup>2</sup>), 23-mm SAPIEN XT (Edwards Lifesciences, Irvine, CA, USA) was selected for implantation. Transfemoral TAVI was planned with direct implant of a 23 mm SapienXT valve through the right femoral artery (Video 1) and ProStar XL® Percutaneous Vascular Surgical System (Abbott Vascular, unit of Abbott Laboratories; Redwood City, Calif) was preferred to close the right common femoral artery. After successful implantation of TAVI, peripheral angiography demonstrated right common femoral artery extravasation (Video 2). Since bleeding is not so severe, we decided to administer 5000 units of protamine intravenously and manual compression. After 20 minutes of compres-

sion, bleeding control was achieved (Video 3) and the patient was transferred to the intensive care unit. Approximately 2 hours later, the patient developed sudden hypotension and tachycardia. As the patient did not have tamponade in the emergency echocardiography, the patient was taken back to the angiography laboratory. In the control angiography, pulsatile extravasation from the right femoral artery was observed. Then, we decided to implant cover stent in order to stop bleeding. 10×60 mm self expandable cover stent was advanced through left femoral artery to implant right common femoral artery (Video 4-5). Successful bleeding control was achieved.



The porcelain ascending aorta and the calcification of the whole aorta (black arrows)

## Keywords

aortic stenosis, transcatheter aortic valve implantation, prostar failure, graft stent

OP(CP-09)

## What Is The Cause of Total Occlusion In Left External Iliak Artery?

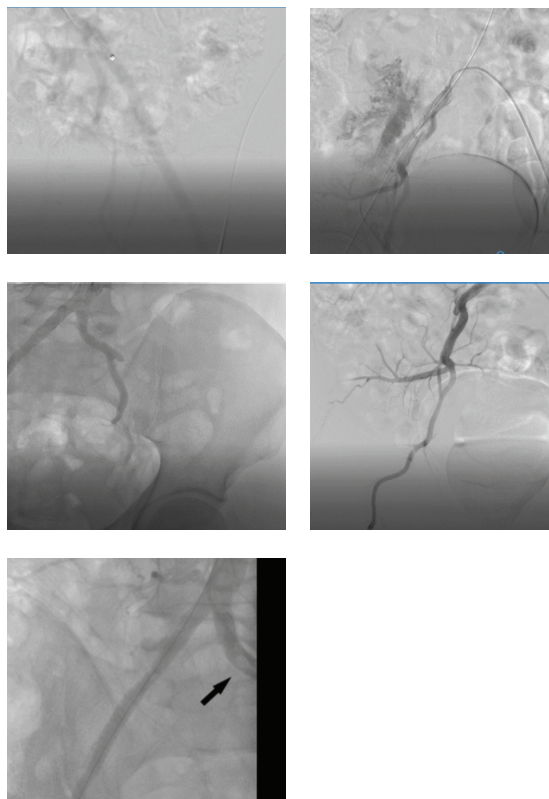
Emrah Erdal, Isa Sincer, Yilmaz Gunes, Oguz Kayabasi

Department of Cardiology, Abant Izzet Baysal University, Bolu, Turkey

63 years old male patient having history of hyperlipidemia and smoking presented with claudication and pain in right foot for 5 days. On physical examination right femoral and popliteal pulses were poor and dorsalis pedis was not palpable. Right external iliac artery was found to be totally occluded on angiography. Through right femoral sheath the lesion was crossed with 0.035 hydrophilic wire retrogradely and dilated with 5,0x40 and 7,0x40 balloons. Due to rupture in the external iliac artery a 7,0x38 mm graft stent implanted. 20 days after discharge the patient complained a severe pain in the right lower extremity persisting for 2 days. With the suspicion of subacute stent stenosis he was taken to cath lab. Right main iliac artery was totally occluded at the level of aortoiliac ostium. Again the lesion was crossed retrogradely with the control images obtained via a diagnostic catheter positioned on left side. 7 x 80 mm supra stent was implanted beginning from ostium of right main iliac artery. Dissection was observed distal to the previous graft stent and a 7X29 mm balloon expandable stent was implanted to this region. With normal distal flow was the intervention was considered to be successful. 5 days later he was admitted to hospital with back pain and claudication on the left side. Previous angiographic images were reevaluated and a thrombus shift to left main iliac artery was observed after ballooning of right ostial total occlusion which was missed by the operator because of focusing on right side. Angiography revealed total occlusion of left external iliac artery. After thrombus fragmentation and achievement of distal flow with balloon angioplasty catheter directed thrombolysis with 2 mg/h tPA infusion for 24 hours was performed after 5 mg bolus injection. Control an-

giography after cessation of tPA showed complete resolution of thrombus and restoration of distal flow with good run of.

Message to home: Operators should be alert for possible thrombus shift to contralateral side during interventions for ostial iliac lesions.



### Keywords

balloon, occlusion, thrombus, ostial

# Koroner Anjiyografi Sonrası Gelişen İliyac Arter Diseksiyonunun İpsilateral Antegrade Yoldan Başarılı Perkütan Tedavisi

Uğur Aksu

*Bölge Eğitim Araştırma Hastanesi, Kardiyoloji Kliniği, Erzurum*

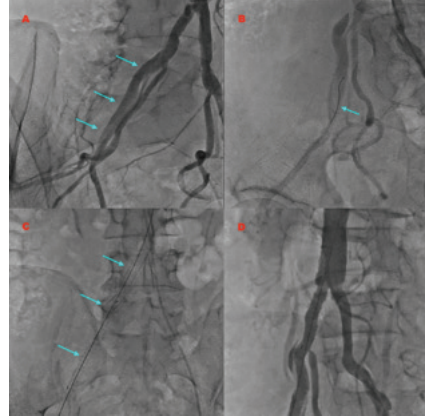
65 yaşında erkek hasta sağ femoral yoldan judkins tekniği ile yapılan koroner anjiyografi ve sonrasında başarılı sağ koroner artere stent implantasyonu uygulandıktan sonra koroner yoğun bakım ünitesine alındı. Takiplerinde sağ bacakta ağrı olması ve nabız alınamaması üzerine hasta tekrar kateter laboratuvarına alındı.

Radiyal yoldan Pig tail kateter ile yapılan periferik anjiyografi sonrası ise iliyaç arterde yaygın diseksiyon izlendi(Resim-1A). Hastaya antegrade yaklaşım ile sağ femoral arter yoluyla floppy guidewire ile diseksiyon hattı geçildi(Resim-1B). Sonrasında ise periferik balon expandable stent implantasyonu yapıldı (Resim-1C) ve final anjiyografide diseksiyonun(Resim-1D) sınırlandırıldığı gözükmesi üzerine işleme son verildi.

Koroner anjiyografi sırasında arteriyel travma gözükülebilir ve bacak ağrısı yada nabız alınamaması durmlarında hastalarda arteriyel travma akılda tutulması gerekir ve bu hastalarda erken müdahale ile hastalar cerrahiye gitmeden perkütan yolla tedavi edilebilir.

## Keywords

diseksiyon, anjiyografi, perkütan girişim



İliyaç arterdeki diseksiyon gelişimi ve perkütan tedavisi



## Subtotal Renal Arter Darlığına Başarılı Perkütan Girişim

Faruk Ertaş, Halit Acet, Hasan Kaya, Tuncay Güzel, Bayram Arslan,  
Raif Kılıç, Mehmet Sait Coşkun

Department of Cardiology, Dicle University, Diyarbakir, Turkey

### OLGU

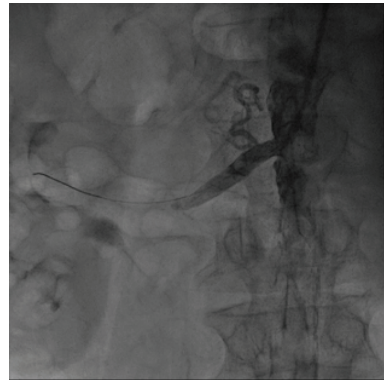
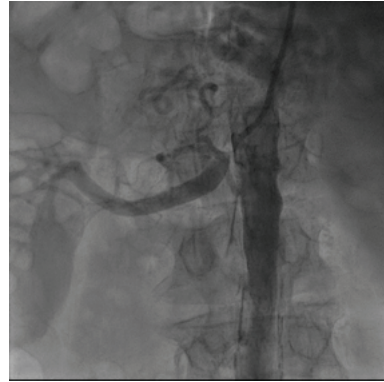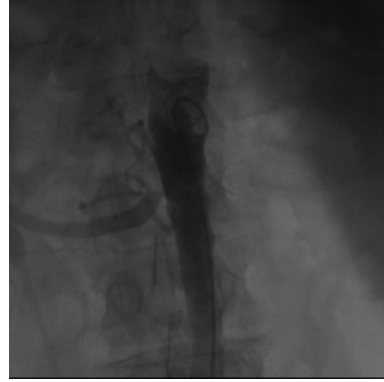74 yaşında hipertansiyonu olan hasta son 1 ay içinde 2 kez tekrarlayan akciğer ödemi tablosuyla kliniğimize başvurdu. Hastada başvuruda bakılan sistolik kan basıncı 200 mmHg, kreatin 2.5, üre 160 idi. Fizik muayenede karın sağ alt kadranda üfürüm mevcuttu. Hastada tekrarlayan akciğer ödemi olması ve karında üfürüm olması üzerine renal arter darlığından şüphelenilerek renal anjiyografi planlandı. Yapılan renal anjiyografide sol renal arter total tıkalı, sağ renal arterde % 99 subtotal darlık tespit edildi. (Resim 1A ve B, Video 1) Darlığın tıkalı uç kısmı yukarı yerleşimli olduğundan brakial arterden işlem yapılma kararı alındı. Sağ brakial artere 7F sheath takıldı. 7F RCA guiding kateter ile darlığa oturuldu. 0.014 floppy tel ile darlık geçildi, darlığa 3.0x15 mm NC balon ile predilatasyon yapıldı, ardından 7.0X20 mm Hipocampus marka balon expandable renal stent implante edildi. Balon aortaya çekilerek 11 atm basınç altında şişirilerek flaring yapıldı. Sağ renal arterde tam açıklık sağlandı. (Resim 2, Video 2)

### TARTIŞMA VE SONUÇ

Tekrarlayan akciğer ödeminin en sık nedenlerinden biri renal arter darlığıdır. Bu tarz darlıklara müdahale tecrübe gerektiren girişimlerdir. Olgumuz buna iyi bir örnek teşkil etmektedir.

### Keywords

Renal arter darlığı, akciğer ödemi, perkütan girişim



OP(CP-12)

## A Rare Complication of Mitral Balloon Valvuloplasty: Iliac Vein Perforation and Manegement

Ziya Gökalp Bilgel<sup>1</sup>, Arafat Yıldırım<sup>2</sup>, Mehmet Küçükosmanoğlu<sup>2</sup>

<sup>1</sup>Department of Cardiology, 25 December State Hospital, Gaziantep, Turkey

<sup>2</sup>Department of Cardiology, Adana City Education and Research Hospital, Adana, Turkey

### BACKGROUND

Percutaneous mitral balloon valvuloplasty (MBV) is an effective treatment method on mitral stenosis with high successful rate and low complication risk. In this case, a rare complication after MBV is summarized as iliac vein rupture and its management.

### CASE

62 female patient hospitalized due to progressing increasing dyspnea. In echocardiography examination, significant mitral valve stenosis, mitral valve area 1.2cm<sup>2</sup> and mean gradient 11mmHg, was determined and recommended to perform MBV. Via right femoral vein, the Mollens sheath and Brockenbrough needle were injected into the interatrial septum. Then 26mm Inoue balloon was forward from mitral valve to left ventricular and inflated. After successful valvuloplasty the mean gradient decreased to 6 mmHg and mean valve area was 2.1cm<sup>2</sup> without significant mitral regurgitation. In the first hour of follow-up patients systolic blood pressure start to decrease. Echocardiography was repeated with the preliminary diagnosis of cardiac tamponade but there were no significant pathology in ECHO. After that abdominal and thoracal computer tomography was performed to exclude any bleeding. The hemoglobin level was decreased 2 gr/dL compared to baseline value. Also, a 9\*8\*10cm diameter haematoma was observed in abdominal CT in retroperitoneal area. Therefore patient was transferred to catheter laboratory for venography. In the venography significant bleeding was observed in the medial side of right common iliac vein (Video-1). To control bleeding, a 8\*30 mm balloon inflated at the site of bleeding for 10 minutes. Unfor-

tunately, bleeding did not controlled and graft stent implantation recommend. At this stage, we decided to implante a cover stent to iliac vein. The diameter of iliac vein was calculated 7.5mm (Video-2) and a 8.0\*38 mm balloon expandable graft stent implanted (video-3). In the control images, due to the stent was undersize a post dilatation was planned with 10\*30 balloon. But, balloon pushed forward the stent into distal inferior vena cava (Video 4). At this stage, first balloon was pushed into the stent and then inflated for 3 atm and stent pushed back to distal iliac vein and implanted in this area. Another balloon expandable graft stent with 10\*30mm diameter was implanted to bleeding area and bleeding has controlled (Video 5). Patient has transferred to care unit and in the follow-up the hemodynamic parameters were stabilized.

### DISCUSSION

In this case, we believe that the rigid part the curved guidewire might be cause of perforation because of not totally put into the balloon. This is a rare complication observed in MBV patient. It should be kept in mind that removing the ball without making sure that the curling wire is inside the balloon can cause a vital complication when the procedure is over. Although graft stents are mostly used for therapeutic purposes in iliac artery lesions, they can also be used in iliac vein perforations to stop bleeding successfully as well as in our case.

### Keywords

iliac, mitral, balloon, valvuloplasty, vein, perforation

# Kritik Mezenter Arter Darlığının Perkütan Endovasküler Girişimle Başarılı Revaskülarizasyonu

Faruk Ertaş, Halit Acet

Department of Cardiology, Dicle University, Diyarbakir, Turkey

## OLGU

73 Yaşında erkek hasta yaklaşık bir yıldır özellikle yemek yemekle başlayan ve yemek sonrası yaklaşık bir saat kadar süren geçmeyen karın ağrısı ile dış merkezden refere edildi. Dış merkez çekimli Batın Kontrastlı BT Anjiyografisinde mezenter arter stenozu mevcuttu. Fizik muayenesinde Batında defans, rebound, hassasiyet, assit yoktu. Akciğer ve kardiyak muayenesi doğaldı. Bakılan laboratuvar değerlerinde hemogram ve biyokimyasal parametrelerde anlamlı patoloji yoktu. Çekilen EKG'sinde ritm Atriyal fibrilasyon ve kalp hızı 90 civarındaydı. (Resim 1) Mezenter arter görüntüleme ve tedavi amaçlı yapılan invaziv anjiyografisinde; İnferior mezenter arter proksimalinde %95 darlık mevcuttu (Resim 2, Video 1). Perkütan işlem kararı alındı. Brakiyal arterden ponksiyon yapıp sheat girildi, sonrasında 8F kateter ile mezenter artere oturuldu 0.014 Nitrex tel ile mezenter arterdeki lezyon geçildi. (Video 2) Lezyona 2.0\*15 mm ve 2.5\*20 mm balonlarla predilate edildi. Sonrasında lezyona 8.6\*40 mm self expandable stent

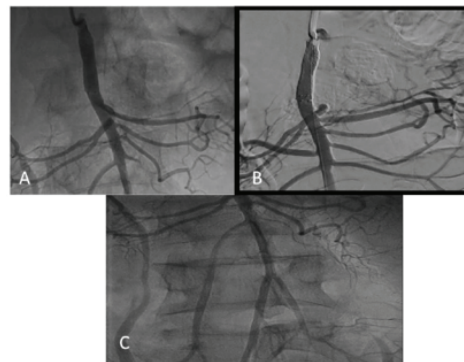
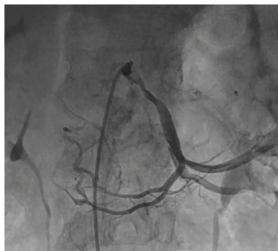
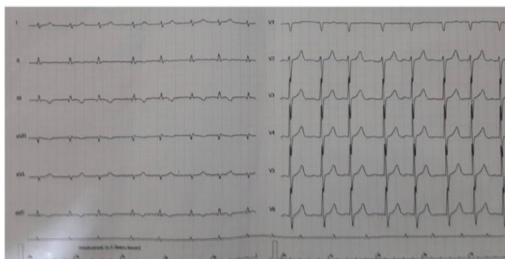
implante edildi. Optimal sonuç elde edilerek işlem başarılı olarak sonlandırıldı (Resim 3, Video 3). Sonrasında hasta 3 gün kadar medikal tedavi altında takip edildi. Yemek yemekle karın ağrısı olmadığı gözlemlendi. Ve sonrasında hasta medikal tedavi ve kontrol önerileri ile taburcu edildi.

## TARTIŞMA ve SONUÇ

İleri yaşlarda karın ağrısı varlığında mutlaka mezenter iskemi düşünülmelidir. Bu hastalarda konvansiyonel anjiyografi en iyi tanı yöntemidir. Bu hastalarda genel cerrahi ve kalp damar cerrahisini içeren multidisipliner yaklaşımın önemli olduğu düşüncesindeyiz. Özellikle yaşlı, komorbid risk faktörleri olan hastalarda perkütan endovasküler girişim ön planda tercih edilmelidir.

## Keywords

Mezenter Arter Stenozu, Ateroskleroz, Perkütan Girişim



OP(CP-14)

## Carotid Angioplasty and Stenting: Pre-Dilatation Versus Post-Dilatation

Şakir Arslan<sup>1</sup>, Elif Sariönder Gencer<sup>2</sup>, Erkan Köklü<sup>1</sup>

<sup>1</sup> Department of Cardiology, S.B.U. Antalya Education and Research Hospital, Antalya, Türkiye

<sup>2</sup> Department of Neurology, S.B.U. Antalya Education and Research Hospital, Antalya, Türkiye

### PURPOSE

Carotid artery stenting (CAS) has become a common treatment for carotid artery stenosis. However, complications, such as an ischemic event, can occur with balloon angioplasty and CAS during intra- and post-operative periods. Among these ischemic complications, plaque protrusion into the stent, thrombus on the stent and in-stent restenosis have occurred after balloon angioplasty and CAS. This study aims to evaluate the clinical outcome and in stent restenosis after (CAS) with or without post-dilatation.

### METHODS

Four hundred and eleven (343 men, mean age 68 years, range 47–88) were treated with CAS between December 2010 and April 2018. CAS was performed in all cases using a cerebral protection device (distal protection device or proximal balloon occlusion). Sixty-seven (16%) patients underwent CAS without post-dilatation. Three hundred and ninety (95%) patients had at least two ultrasound evaluation performed 6 months after procedure. In-stent stenosis >80% detected with duplex ultrasound scans were further evaluated by angiography.

### RESULTS

CAS was performed successfully for all lesions, although major adverse events occurred in six patients (1,4 %) within 30 days after CAS; none of the patients experienced myocardial infarction. In 67 patients underwent CAS without post dilatation, one major stroke (1.5%) occurred because of hyper perfusion syndrome. Post-CAS diffusion-weighted imaging (DWI) revealed a high-intensity area in patients with post dilatation 55 of 344 procedures (15,9%) and without post dilatations 6 of 67 procedures (8,9 %). In-stent restenosis in patients with post dilatation 13 of 344 procedures (3,7%) and without post dilatations 1 of 67 procedures (1,4 %)

### CONCLUSION

Carotid stenting without post-dilatation might achieve minimal plaque disruption therefore associated with a low incidence of stroke and restenosis.

### Keywords

carotid stenting, carotid angioplasty, technique, in-stent restenosis.

OP(CP-15)

## Percutaneous Intervention of Subclavian Vein Occlusion After DDD-ICD Implantation

**Nazif Aygul, Bulent Behlul Altunkeser**

*Department of Cardiology, Selcuk University, Konya, Turkey*

A 46-year-old male patient who were implanted DDD-ICD because of hypertrophic obstructive cardiomyopathy, was admitted to our cardiology clinic with a complaint of pain in left arm and swelling in the last 6 months. Computed tomography revealed that the complete stenosis of the left subclavian vein and 90% stenosis in the left subclavian vein proximal to the brachiocephalic trunk (Video1). Percutaneous intervention was planned. At first, we tried to cross the totally occluded lesion in left subclavian vein retrogradely with 0.035 inch hydrophilic wires, Hallbert and Roadrunner wires, but these wires could not penetrate the lesion (Video 2). Due to the inability to advance the hydrophilic guide-wires from retrograde way, we decided to catch the ICD lead with a snare from the femoral route and after this we planned to pull-back the ICD electrode and snare wire simultaneously from the subclavian route. But this attempt couldn't succeed to pass subclavian occlusion. We extracted the ICD lead by snare from femoral vein.

The procedure was terminated. After 1 month, the patient hospitalized again for the second intervention; the lesion was crossed retrogradely over left subclavian vein with 0.035 hydrophilic wire, Hallbert and Conquest pro 9 wires respectively. After that the totally occluded lesion in subclavian vein was dilated with 7,0x60 mm balloon and the lesion in brachiocephalic truncus was dilated with 6,0x80 mm balloon. After pre-dilatations, a 18x60 mm self-expandable stent implanted in subclavian vein and 18x40 mm and 18x60 mm self-expandable stents implanted in brachiocephalic trunk (Video 4). Finally, 8x60 mm, 7x60mm and 6x80 mm balloons were inflated simultaneously at the proximal part of the brachiocephalic truncus and postdilatation was performed (Video 5).

### **Keywords**

subclavian vein occlusion, venous intervention, pacemaker



OP(CP-16)

# The Subclavian Steal Syndrome and Successful Treatment with Percutaneous Intervention

**Yakup Balaban**

*VM Medicalpark Kocaeli Hospital*

## BACKGROUND

In a person without antegrade flow in the subclavian artery, the dizziness can be seen during exertion with the arm of same side because that the blood flow of subclavian artery supply from the vertebral artery through the basilar system.

## CASE PRESENTATION

A 74-year-old male patient with intermittent dizziness consulted a neurology doctor. The carotid, coronary and vertebral artery angiography was requested because of retrograde flow detection with USG Doppler examination in the left vertebral artery. The patient applied to our clinic for this purpose. Coronary, carotid and vertebral artery angiography performed via the right radial artery revealed a total occlusion in left subclavian artery. The blood flow to the left subclavian artery was detected coming through the basilar system via the ipsilateral vertebral artery. It was decided to open the left subclavian artery percutaneously. It was decided to open the left subclavian artery percutaneously. In another session, sheath was inserted into the left radial and femoral artery, and the subclavian artery was successfully revascularized with percutaneous intervention. Her complaints was resolved.

## DISCUSSION

Every patient which have a dizziness with upper extremity exertion should be investigated in detail. If stenosis or occlusion of neck arteries is suspected, the vertebral artery and carotid doppler should be performed. So, the carotid and vertebral artery stenosis may cause cerebral circulation disorder and dizziness.

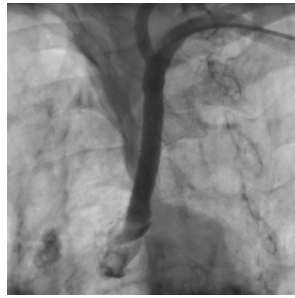
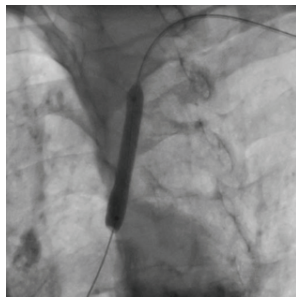
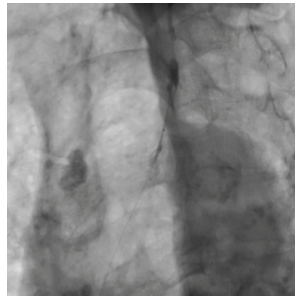
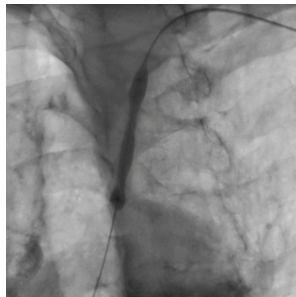
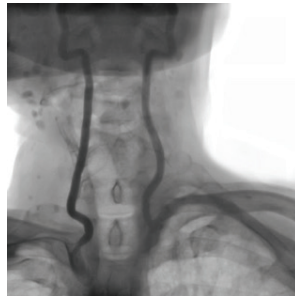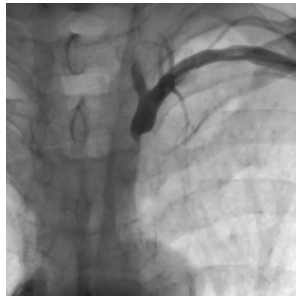
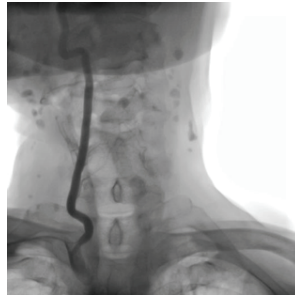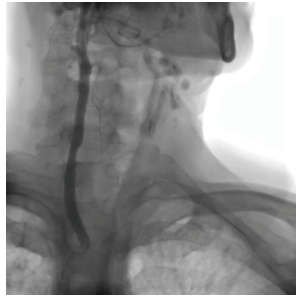
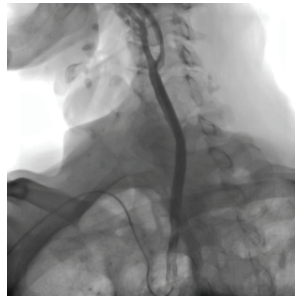
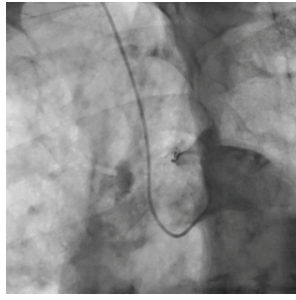
Actually it is known that; In patients with critical stenosis of the carotid, the possibility of stenosis in the coronary arteries is over 60%. The opposite is true as well, that is, patients with critical stenosis in the coronary arteries have a marked stenosis in their carotid as with more than 60% likely. Therefore, the issue also concerns cardiology. (1-4)

## CONCLUSION

For this reason, it will be beneficial for the patient to display carotid lesions in the same session with coronary angiography rather than in a separate session.

## Keywords

Subclavian steal syndrome, percutaneous intervention, vertebral artery



OP(CP-17)

## Revascularization of Subclavian Osteal Chronic Total Occlusion and Management of Dissection In A Patient Presenting with Subclavian Steal Syndrome

Hakkı Şimşek<sup>1</sup>, Erkan Baysal<sup>2</sup>, Serkan Akdağ<sup>3</sup>, Mehmet Sait Coskun<sup>1</sup>, Lezgin Dursun<sup>1</sup>

<sup>1</sup> Department of Cardiology, Dicle University, Diyarbakır, Turkey

<sup>2</sup> Department of Cardiology, Gazi Yasargil Hospital, Diyarbakır, Turkey

<sup>3</sup> Department of Cardiology, Memorial Hospital, Diyarbakır, Turkey

### CASE REPORT AND DISCUSSION

72 years old patient WITH Hypertension and smoking 50 pack / WAS admitted to another clinic with complaints of dizziness and MR angiography revealed totally occluded left subclavian artery and 95% stenosis in the ostium of right vertebral artery. Three months ago, tried to be revascularized with antegrade approach in another hospital but not successful. The patient was admitted to our hospital with the complaints of dizziness increased with left arm movement. We considered subclavian steal syndrome and decided to perform endovascular intervention. Because the lesion was osteal, brachial approach was preferred. 7F JR catheter was placed over the 7F femoral sheath. In the absence of penetration of the CTO lesion despite the microcatheter support the JR catheter was tried to be advanced in order to increase support. However dissection occurred due to subclavian distal angle and rapid advancement of catheter. With the support of JR catheter placed in the subclavian artery and microcatheter the lesion was

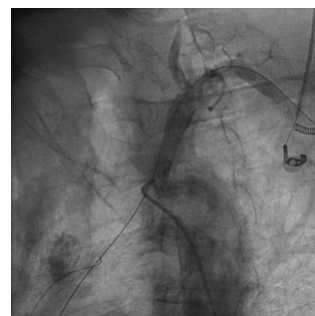
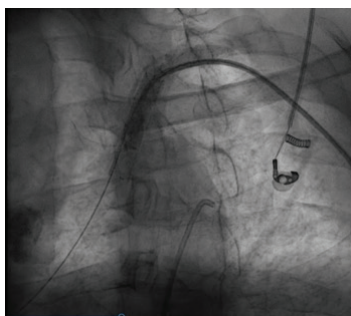
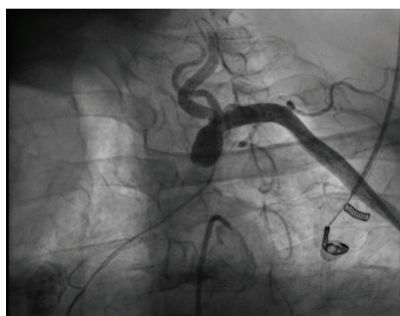
crossed by 0.035 hydrophilic wire. The lesion was predilated with a 4.0x40 mm balloon. Despite predilatation, balloon expandable stent was forced a lot to open. After placing the stent, we detected that dissection continued and slowed the flow of the vertebral artery. We have decided to close the dissection with stenting and second stent was implanted. Post-stent vertebral blood flow improved and the procedure was terminated.

### CONCLUSION

When placing the guiding catheter or long sheath in the subclavian artery we should be very careful, especially when crossing the distal angle. To place the catheter in the subclavian, manipulations including slow, clockwise and slightly push up it can work greatly.

### Keywords

chronic total occlusion, dissection, subclavian steal syndrome



OP(CP-18)

## Successful Middle Cerebral Artery Mechanical Thrombectomy and Carotid Stent Implantation In A Patient With Acute Ischemic Stroke

Murat Sunbul<sup>1</sup>, Kursat Tigen<sup>1</sup>, Emre Gurel<sup>1</sup>, Altug Cincin<sup>1</sup>, Anil Sahin<sup>1</sup>, Feyyaz Baltacioglu<sup>2</sup>

<sup>1</sup> Marmara University School of Medicine, Department of Cardiology, Istanbul, Turkey

<sup>2</sup> Marmara University School of Medicine, Department of Radiology, Istanbul, Turkey

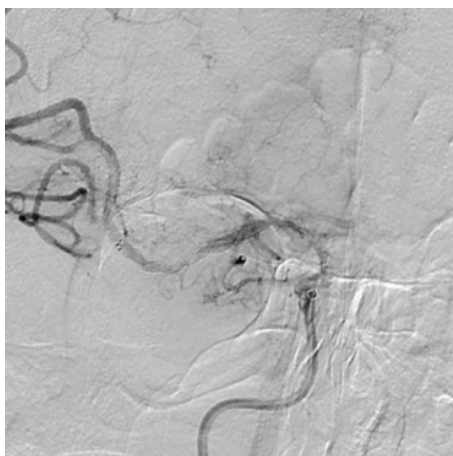
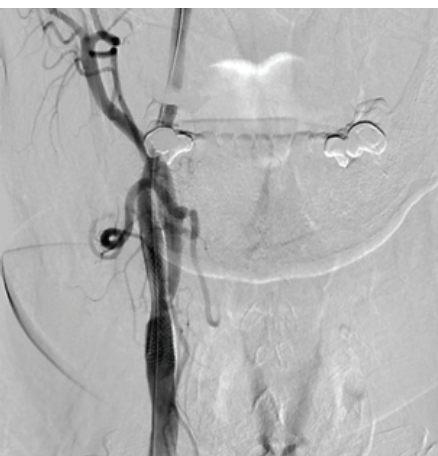
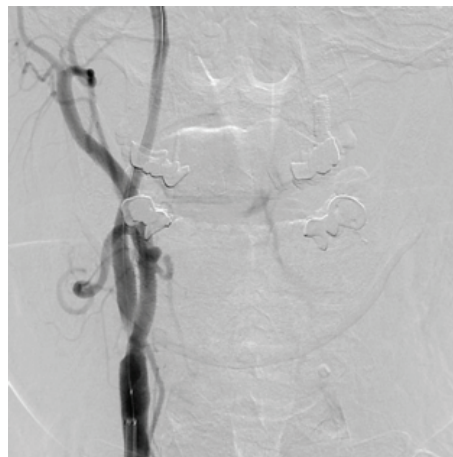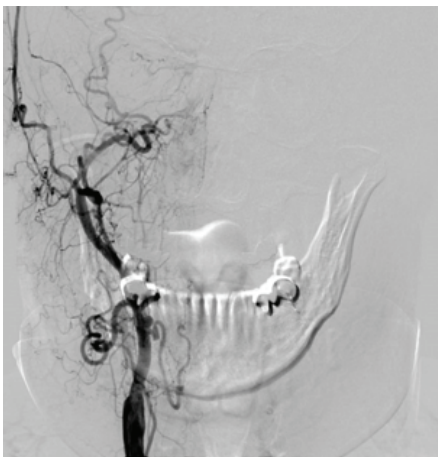
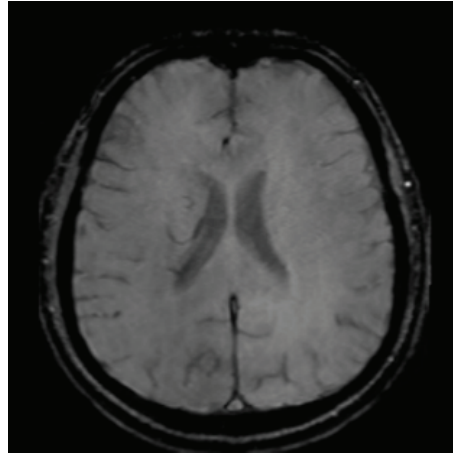
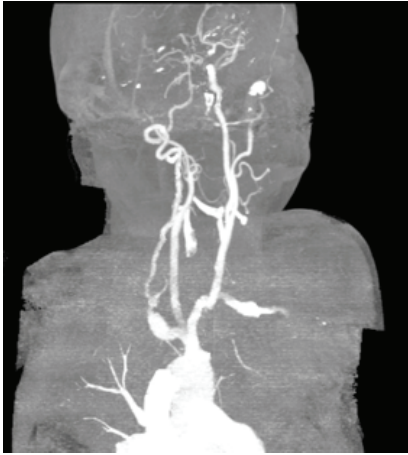A 65-year-old man presented with a 1-hour history of left facial palsy, mild left hemiparesis and hemiparesthesia. Patient have had history of coronary artery disease for five years and underwent carotid Doppler ultrasonography for symptoms of dizziness one year ago. Carotid Doppler Ultrasonography revealed 90% occlusion in the right internal carotid artery (ICA). He was treated with acetylsalicylic acid together with clopidogrel therapy due to no previous history of stroke. Before the symptoms occurred, he has not been taking his medical therapy for a week. At admission, computed tomography (CT) showed no signs of hemorrhage or acute ischemia. Hyperdense MCA sign was seen on the right side of the brain. Cranial and carotid CT angiography revealed a total occlusion of right ICA bulbous (Figure 1). Diffusion weighted imaging revealed low level hyperintensity at the right basal ganglia and corona radiata (Figure 2). The National Institute of Health Stroke Score (NIHSS) of patient was 4. Because of rapid progression of symptoms, we performed urgent intravenous (IV) tissue plasminogen activator (t-PA) with simultaneous angiography which showed total thrombosis of right ICA bulbous and tandem occlusion of right M1 segment (Figure-3). The patient was given IV heparin therapy and 6 Fr long sheath was advanced into the right common carotid artery via right femoral artery. After advancing a 0.014 guidewire (Boston Scientific, Costa Rica) to the distal ICA, total occlusion of right ICA bulbous was dilated with a 3.0 x 20 mm and 4.5 x 20 Simpass balloon (Simeks, Turkey) (Figure-4). After providing partial flow in the right ICA bulbous, we decided to continue with thrombectomy from the M1

segment occlusion. 6 Fr Sofia cerebral guiding catheter was advanced into the right ICA cavernous segment. A combination of Trevo 18 Synchro 14 microcatheter and micro-wire were advanced through the total occlusion segment of M1. A successful direct thrombectomy of occluded segment of M1 was performed with a 4 x 20 mm Trevo XP ProVue thrombus aspiration device (Stryker Neurovascular, USA), achieving a TICI 3 flow (Figure-5). Control cranial angiography revealed intact MCA branches and severe residual stenosis at the ICA bulbous. Thereafter, 7 x 30 mm carotis Wallstent (Boston Scientific, MA, USA) was deployed and post-dilatation was performed by using a 4.5 x 20 mm Simpass balloon (Simeks, Turkey). Control carotid angiography showed no significant residual stenosis of the right ICA bulbous (Figure-6). After procedure was completed, loading dose of acetylsalicylic acid (300 mg) and clopidogrel (300 mg) were given. Patient was discharged three days later with full recovery of his symptoms and no neurologic deficit.

### Keywords

acute ischemic stroke, carotid stent implantation, cerebral artery mechanical thrombectomy







OP(CP-19)

# TEVAR for Chronic Symptomatic DeBakey Tip III Dissection

Onder Ozturk<sup>1</sup>, Utkan Sevuk<sup>2</sup>

<sup>1</sup> *Diyarbakir Gazi Yasargil Education and Research Hospital, Department of Cardiology*

<sup>2</sup> *Diyarbakir Gazi Yasargil Education and Research Hospital, Department of Cardiovascular Surgery*

## BACKGROUND

Aortic dissection occurs when the blood flows between the layers of the wall of aorta. It can rapidly lead to death due to insufficient blood flow into the heart or the aorta rupture, which is a severe and fatal threat to the affected patients and constantly requires emergent management. Thoracic endovascular aortic repair (TEVAR) represents a minimally invasive technique alternative to conventional open surgical reconstruction for the treatment of thoracic aortic pathologies. Rapid advances in endovascular technology and procedural breakthroughs have contributed to a dramatic transformation of the entire field of thoracic aortic surgery. EVAR procedures can be challenging and, at times, extraordinarily difficult. They require seasoned endovascular experience and refined skills. Of all endovascular procedures, meticulous assessment of anatomy and preoperative procedure planning are absolutely paramount to produce optimal outcomes. In this report, we presented a 92-year-old female patient complicated with DeBakey Tip III aortic dissection successfully treated with TEVAR.

## CASE

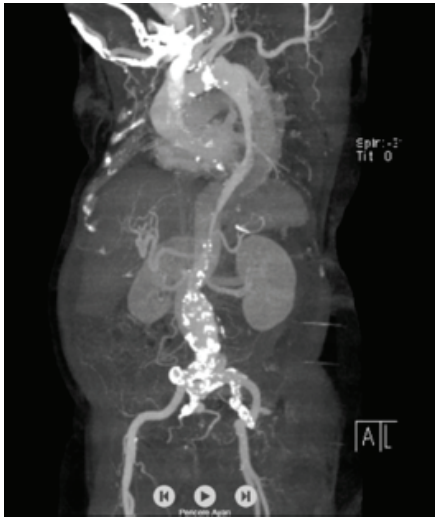A 92-year-old female patient was admitted to our hospital due to the complaints of acute-onset chest and back pain for 10 hours. The patient was diagnosed with hypertension 20 years and the high blood pressure was uncontrolled. Upon admission, the blood pressure was measured as 185/70 mm Hg in right arm, 130/65 mm Hg in left arm and pulse rate of 106 beats/minute. Computed tomography angiography (CTA) revealed that the aortic dissection beginning after left subclavian artery and dissection ending level of common iliac bifurcation arteries. Other vital visceral arteries were not affected,

as illustrated in Fig. 1. The patient was hospitalized and underwent TEVAR. The vascular stents were selected based upon the measurement of the vascular diameter (Fig.2). 38\*16 mm graft stent covered the origin of the left subclavian artery (Fig.3). No stent endoleak or dislocation occurred. The patient remained stable after TEVAR. The patient was discharged second day after TEVAR.

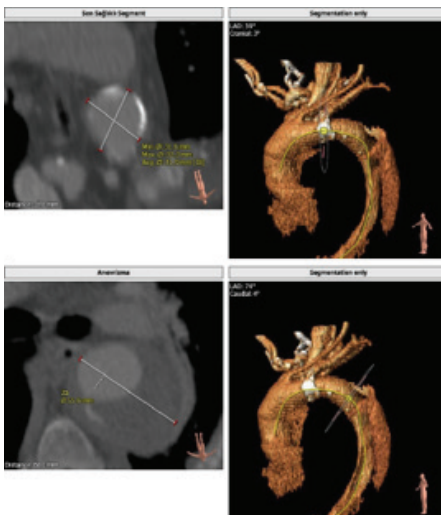
## DISCUSSION

Since the introduction of aortic stent grafting for the treatment of thoracic aortic aneurysms, TEVAR has gained widespread clinical application as a less invasive technique for DeBakey Tip III aortic dissection compared with the open surgery. However, the use of TEVAR is associated with the risk of postoperative complications, and even high rate of morbidity and mortality. Indications for TEVAR in treating thoracic aortic aneurysms include paraplegia, visceral ischemia, acute rupture, chronic aneurysm, etc. Paraplegia is the most severe acute complication after TEVAR. Previous studies have demonstrated that the incidence of both immediate and delayed paraplegia in patients undergoing TEVAR can be as high as 12%, compared with 2% to 21% in their counterparts after open surgery. Therefore, we used only one graft stent for prevention of paraplegia.

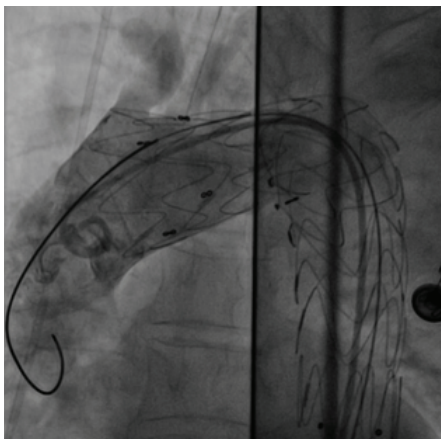Keywords: aortic dissection, TEVAR, stent



Computed tomography angiography of aorta



Measurement of the vascular diameter



Implantation of graft stent

## Successful Management Of EVAR Limb Extension Thrombosis

Mehmet Inanir, Emrah Erdal, Yilmaz Gunes

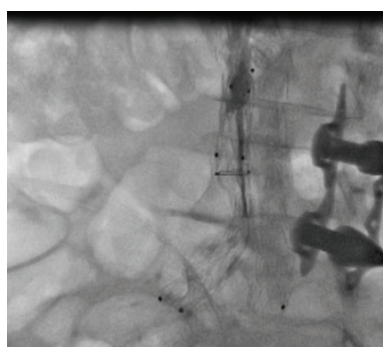
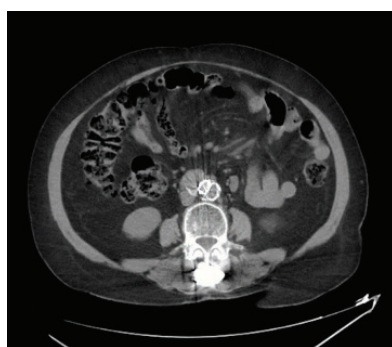
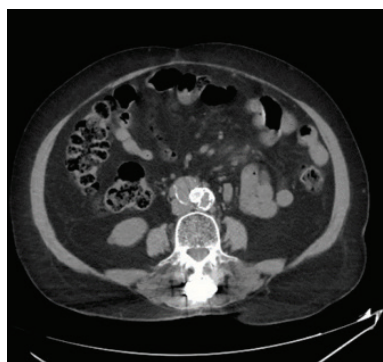
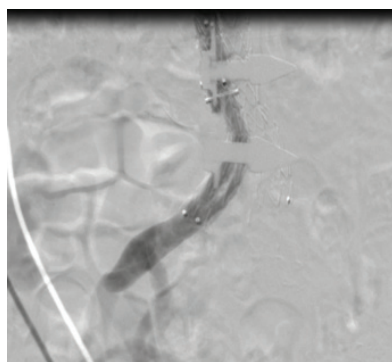
*Bolu Abant Izzet Baysal University Medical Faculty Hospital*

77 years old female patient who having history of endovascular aneurysm repair (EVAR) 40 days before presented with right lower extremity pain of one day duration. She was taking 100 mg of acetyl salicylic acid. Computed tomography showed thrombotic occlusion within right limb extension of endovascular graft (Figure 1-2). Via left brachial puncture a 90 cm destination sheath was inserted towards abdominal aorta and the occlusion was crossed with a 0.035 cm hydrophilic wire (Video 1). After fragmentation of total occlusion with 6.0x150 mm balloon distal blood flow achieved partially (Figure 3). After a selective intra-arterial bolus injection of 10 mg dose of recombinant tissue-type plasminogen activator (tPA) a continuous infusion for 20 hours is continued at 2.0 mg/h using a multisided port

catheter passed through the thrombotic lesion. Anticoagulation was managed with intravenous heparin. Pain of the patient resolved immediately after ballooning and right foot and leg warmed gradually and pulses became palpable within hours. Control angiography after cessation of thrombolysis revealed complete resolution of thrombus and adequate distal flow (Figure 4). Left radial artery was palpable and there was a slight ecchymosis on left arm. The patient was anticoagulated with warfarin. She is free of pain with palpable lower extremity pulsations at 6 month of outpatient examination.

### Keywords

endovascular aneurysm repair (EVAR), limb extension, recombinant tissue-type plasminogen activator (tPA)



# Endovascular Repair of Giant Abdominoiliac Aneurysm Under Local Anesthesia

Fatih Ada<sup>1</sup>, Vural Polat<sup>1</sup>, Ercan Karabey<sup>2</sup>, Ibrahim Gül<sup>2</sup>

<sup>1</sup> Sivas Cumhuriyet University School of Medicine, Department of Cardiovascular Surgery

<sup>2</sup> Sivas Cumhuriyet University School of Medicine, Department of Cardiology

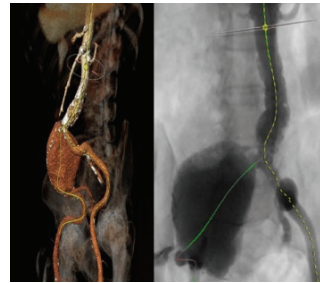
## INTRODUCTION AND OBJECTIVE

Endovascular abdominal aortic aneurysm repair (EVAR) has been widely used in the clinic as an alternative to open surgery, especially in patients with high-risk group abdominal aortic aneurysms. EVAR has superior aspects not only in the high-risk patient group, but in terms of mortality, shorter hospital stay, less blood and blood product usage, shorter operating time, and lower rates of early and late mortality. EVAR is usually performed under spinal or general anesthesia. We presented the repair process of giant abdominoiliac aneurysm under EVAR under local anesthesia.

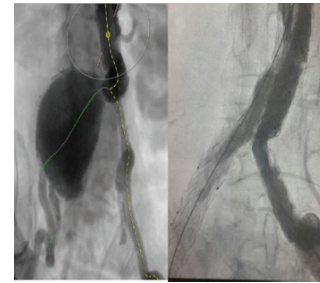
## METHOD

An 80-year-old male patient who was admitted with abdominal pain to emergency was consulted to our department. Physical examination revealed a pulsatile mass in the abdomen. The patient had distal arterial pulses. The blood pressure was 100/60 mmHg and the heart rate was 105 beats /min. The biochemical values were normal, but he had mild anemia (Hemoglobin 9.8 g / dl) in complete blood count. A contrast-enhanced thoracoabdominopelvic computed tomography (CT) was requested. A self-limited ruptured abdominal and iliac artery aneurysm was observed, which starts at the infrarenal abdominal aorta and end the iliac artery bifurcation level. The aneurysm was 52.5 mm in the abdominal aorta and 97 mm in the right iliac artery (Figure 1). After the examinations and preparations were completed, the patient was immediately taken to the angiography unit for EVAR. General anesthesia of the patient with general condition disorder was high risk and therefore, surgery was started under local anesthesia. Both femoral arteries were opened under local anesthesia. Abdominal aorta 28-16 cm in size, the main

body stent graft and 14-12 cm in size right and left iliac leg stent graft were placed (Figure 2). After EVAR was completed, the patient was taken to intensive care unit for observation. After 24 hours of observation, the patient was taken to the ward. The patient was discharged on postoperative 3th day without any complaints.



Preoperative appearance



Postoperative appearance

## DISCUSSION AND CONCLUSION

EVAR is a safe treatment method with low early and late mortality rates. EVAR procedure with under local anesthesia is not routinely performed in clinical practice. However, we believe that the EVAR procedure will be successful under local anesthesia with the planning of the anesthesia team in emergency or elective cases.

## Keywords

abdominal aortic aneurysm, local anesthesia, endovascular repair

OP(CP-22)

## Use of Coronary Wires In Endovascular Aortic Repair Process

Şükrü Arslan, Okay Abacı

*Department of Cardiology, Cardiology Institute of Istanbul University*

A 72-year-old male patient was detected incidentally abdominal aortic aneurysm during screening malignancy by abdominal USG. CT angiography revealed that abdominal aorta aneurysm with the length of 67 mm through craniocaudal axis and 55 mm width containing about 27 mm mural thrombus. (figure -1)

Endovascular aortic repair (EVAR) procedure was decided because of the high risk of surgery. The procedure was started by placing sheaths on both common femoral arteries (20 F right side; 14 F left side). The main body of the EVAR graft was directed from the right femoral artery and fixed to the abdominal aorta. And then Retrograde rewiring was attempted from left femoral artery sheath to main body but not successful. Therefore, it was decided to perform a left brachial artery puncture for trying to rewire again. However, during antegrade rewiring, the guidewire was constantly went on to the

aneurysm sac. And then, the lesion was re-evaluated, and subtotal lesion was detected in the distal aorta at the left side of the main body. (figure-2) Consequently antegrade rewiring were not successful, therefore we decided to try new ways. Then subtotal lesion was passed with 0.014 floppy guidewire from the left common femoral artery with microcatheter support. Then 0.014 wire exchanged with 0.035 stiff wire and the left leg of the EVAR graft was successfully implanted.

As a result, rewiring is an important step in EVAR operations. In the EVAR process; coronary guidewires can also be used for rewiring procedures in challenging lesions such as our case.

### Keywords

coronary wires, endovascular aortic repair, rewiring step



# Aortailiak Anevrizma İçin İnternal İliak Arter Oklüzyonu İle Endovasküler Aort Onarımı

Zeki Cetinkaya<sup>1</sup>, Joma Sulaiman<sup>2</sup>, Deniz Elcik<sup>3</sup>, Ramazan Topsakal<sup>4</sup>

<sup>1</sup> Zeki Cetinkaya: Department of Cardiology, Erciyes University, Kayseri, Turkey

<sup>2</sup> Joma Sulaiman: Department of Cardiology, Erciyes University, Kayseri, Turkey

<sup>3</sup> Deniz Elcik: Department of Cardiology, Erciyes University, Kayseri, Turkey

<sup>4</sup> Ramazan Topsakal: Department of Cardiology, Erciyes University, Kayseri, Turkey

Endovasküler aort onarımı (EVAR) yapılan aorto iliak anevrizma hastaları, endografi external iliak artere uzattıktan sonra tip II endoleak oluşumunu önlemek için vasküler plak ile internal iliak arter tıkanması ve stent greftle kaplanmasını gerektirir. Bununla birlikte internal iliak arter oklüzyonu pelvik iskemi nedeniyle kalça kaldikasyonuna ve diğer çeşitli şekillere neden olmaktadır.

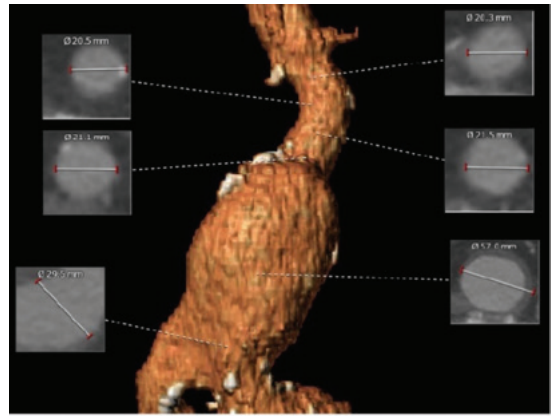
A. iliaca externa ve A. iliaca interna arasında anastomoz oluşturan arterler A. gluteainferior, a. circumflexa femoris medialis, A. perforans ve A. iliaca externanın A. epigastrica inferior dalı ile A. iliaca internanın A. obturatorios dalı arasındadır.

Özellikle A. glutea superior ve a. glutea inferior arter arasında ki bağlantının herhangi bir nedenle tıkanması pelvik kladikasyona neden olmaktadır.

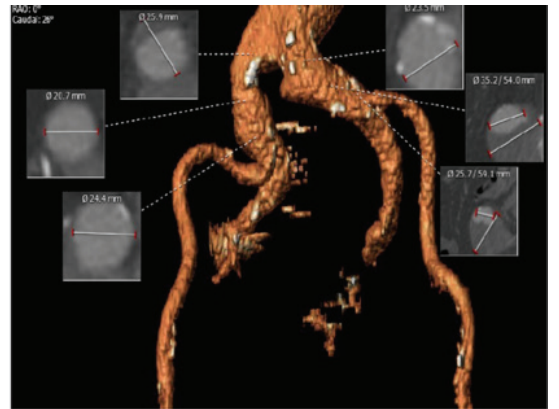
Kliniğimize de bilinen ht+ astım + mevcut 75 yaşında hasta epigastrik ağrı nedeniyle başvurdu. Çekilen Bt anjiyografide abdominal arter en geniş yerinde 57 mm, Sol A. iliaca en geniş yerinde 59 mm anevrizma mevcuttu. Tip 2 endoleak gelişmemesi açısından endovasküler greftimizi yerleştirmeden önce sol internal iliak arter vasküler plak ile kapatıldı. Daha sonra bifükarsyonlu moduler endovaskuler greftimiz implante edidi. Komplikasyon gelişmedi. Kontrollerinde herhangi bir şikayeti olmadı

## Keywords

Evar, aort, iliac, anastomoz



1-abdominal aort anevrizma 3 boyut



2-iliac arter anevrizma 3 boyut.png

# Billateral Aorto-İliak Arter Lezyonlarına Antero-Retrogard Girişimle Başarılı Perkütan Revaskülarizasyon

Faruk Ertaş, Halit Acet

Department of Cardiology, Dicle University, Diyarbakır, Turkey

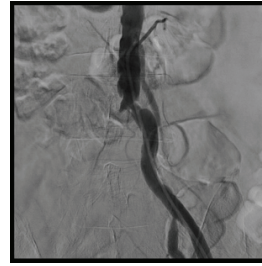
## OLGU

Son 1 yıldır yürümekle aralıklı kladiyasyon (Fontan 2b, Rutherford sınıf 3) tarifleyen 53 yaşında erkek hasta yapılmış olan periferik anjiyosunda sağ iliak arter femoral arter başına kadar total tıkalı sol iliak arter ostealde ise %80 darlık mevcuttu (Resim 1, Video 1). Yurtdışında iki merkezde ülkemizde de bir merkezde perkütan girişim denenmiş ancak başarılı olunamamış. Ameliyat olmak istemeyen genç hasta merkezimize başvurdu. Hastaya konsey kararıyla perkütan girişim kararı alındı.

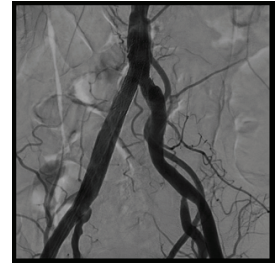
## İŞLEM AŞAMALARI

İşlem gerçekleştirmek amacıyla iki taraflı femoral arterlere 8F 25 cm sheat takıldı. Eşzamanlı sol brakial artere 7F 90 cm uzun sheat yerleştirildi. Sağ femoralden lezyon geçilememesi üzerine brakialden 0.35x135 cm mikrokateter desteğiyle 0.018 x210 mm Pointer marka tel ile sağ iliak ostealdeki darlık penetre edildi, sonrasında 0.035 260 cm hidrofilik tel ile darlık geçilip mikrokateter darlık distaline sağ SFA'ya gelindi daha sonra mikrokateter içinden 0.018 300 cm Nitrex marka tel ile değişim yapıldı. Sol femoral arterdeki sheat üzerinden de 0.035 260 cm hidrofilik tel ile sol osteal iliak lezyon geçildi. Öncelikle sol brakial arter üzerinden sağ iliak darlık 5.0x60 mm balon ile predilate edildi. Daha sonra aortya taşıyacak ve aortadaki diseksiyonu kaplayacak şekilde sağ iliak artere 8.0x37 mm balon expandable stent, sol iliak artere de 7.0x47 mm balon expandable stent eş zamanlı şişirildi. Daha sonra sağ iliak arter geri kalan darlığı kaplayacak şekilde sağ femoral arter başına kadar uzanan lezyona 8.0x150 mm self expandable stent implante edildi. Ardından sağ stenlerin hem overlap kısmını hemde self expandable stentin tam açılmayan geri kalan kısmını kapsayacak şekilde 8.0x37 mm balon ile postdilatasyon yapıldı Optimal sonuç elde edildi.

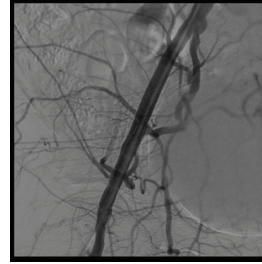
(Resim 2A-B, Video 2,3)



Resim 1



Resim 2A



Resim 2B

## TARTIŞMA VE SONUÇ

İliak arterlerin kronik total oklüzyonları tecrübe gerektiren ve komplikasyonlara açık girişimlerdir. Eşzamanlı aortadaki darlıkların varlığı işlem riskini daha da artırmaktadır. Bu tarz aortoiliak ve kronik lezyonlarda eşzamanlı brakial girişim yapılması, pointer gibi delici özelliği yüksek olan tellerin kullanılması başarı şansını artırmaktadır. Vakamız buna iyi bir örnek teşkil etmektedir.

## Keywords

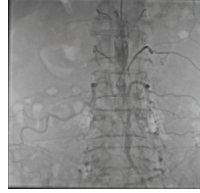
Billateral aortoiliak girişim, perkütan girişim, periferik arter hastalığı

## Distal Abdominal Aorta Total Oklüzyonuna Başarılı Perkütan Girişim

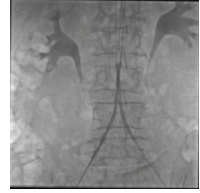
Mustafa Topuz, Mehmet Küçükosmanoğlu, Ibrahim Halil Kurt  
Sağlık Bilimleri Üniversitesi Adana Şehir Eğitim ve Araştırma Hastanesi

57 yaşındaki kadın hasta eforla gelişen her iki taraflı bacak ve kalça ağrısı şikâyeti ile başvurdu. Yapılan BT anjiyografisinde aortanın distalden total tıkalı olduğu common iliak arterlerin kolleteraller ile dolduğu saptanması üzerine diagnostik anjiyografi planlandı. Hastaya yapılan anjiyografide distal abdominal aortanın kısa segment total tıkalı olduğu ve kollateraller ile iliak arterlerin dolduğu izlendi (Figür 1). Konseyde cerrahi kararı verilen hasta cerrahi kabul etmemesi üzerine perkütan işlem için labaratuvara alındı. Sol brakial arter 7 F, sağ ve sol femoral arterlere 8 F kılıf yerleştirildi. 10 bin Ü heparin yapıldıktan sonra öncelikle sol brakial arterden guiding sağ kateter ile distal abdominal ortaya yaklaşıldı. 0.35 destek kateteri (TrailBlazer, Medtronic) ve 0.18 total oklüzyon teli (H1-Torque Steelcore, Medtronic) ile Sol ve sağ oblik açılar ile sağ ve sol iliak arter düzlemleri teyit edilerek distal abdominal total oklude lezyon penetre edilmeye çalışıldı. Sağ iliak arter lümenine düşüldü ve tip enjeksiyon yapıldı. 0.18 300 cm taşıma teli (Nitrex, Medtronic) ile exchange yapıldı. Daha sonra sol iliak arter düzlemi değişik açılardan teyit edilerek oklüzyon teli ve destek kateteri ile sol iliak artere düşülmeye çalışıldı ancak proksimal kep penetre edilemedi. Daha sonra 0.35 260 cm hidrofilik tel (Glide-Wire, Terumo) kateter lezyona dayandırılarak penetrasyon ve loop tekniği denendi ancak başarılı olunamadı. Son olarak destek kateter ucu kepe dayandırılarak düzlem teyit edildikten sonra aynı teli diğer ucu ile cap penetre edildi ve destek kateteri oklude segmente ilerletildi. Daha sonra tel tekrar yumuşak ucu ile loop yöntemi ile sol iliak artere düşüldü ve 0.18 taşıma teli (Nitrex, Medtronic) ile exchange yapıldı. Öncelikle 4x80 ve 4x100 mm düz balonlar (Evercross, Medtronic) ile kissing balon predilatasyonu uygulandı (Figür 2). Daha sonra 120x80 mm boyutunda iki adet kendiliğinden

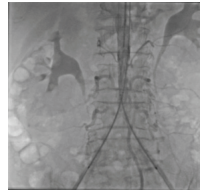
açılan periferik stentler (Protég EverFlex, Medtronic) eş zamanlı lezyona implante edildi. (Figür 3). 8x80 mm iki adet düz balonlar ile final kissing uygulandı (Figür 4). Diseksiyon veya perforasyon imajı izlenmedi (Figür 5). Distal embolizasyon kontrolü yapılarak işleme son verildi.



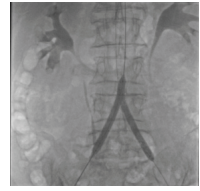
Figür 1 Diagnostik anjiyografide distal abdominal aortanın kısa segment total tıkalı olduğu ve kollateraller ile iliak arterlerin doluluğu izlenmekte



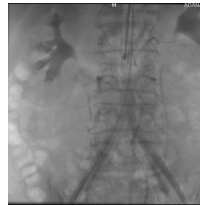
Figür 2 Kissing balon predilatasyonu



Figür 3 Self expandable periferik stentlerin simultane implantasyonu



Figür 4 Final kissing balon dilatasyonu



Figür 5 Final görüntü

### Keywords

total oklüzyon, distal abdominal aorta, kissing stentleme,

OP(CP-26)

## Sag Ana İliac Arter Total Oklüsyon

Yakup Çetinkaya

<sup>1</sup> Right Iliac Chronic totaly occlusion

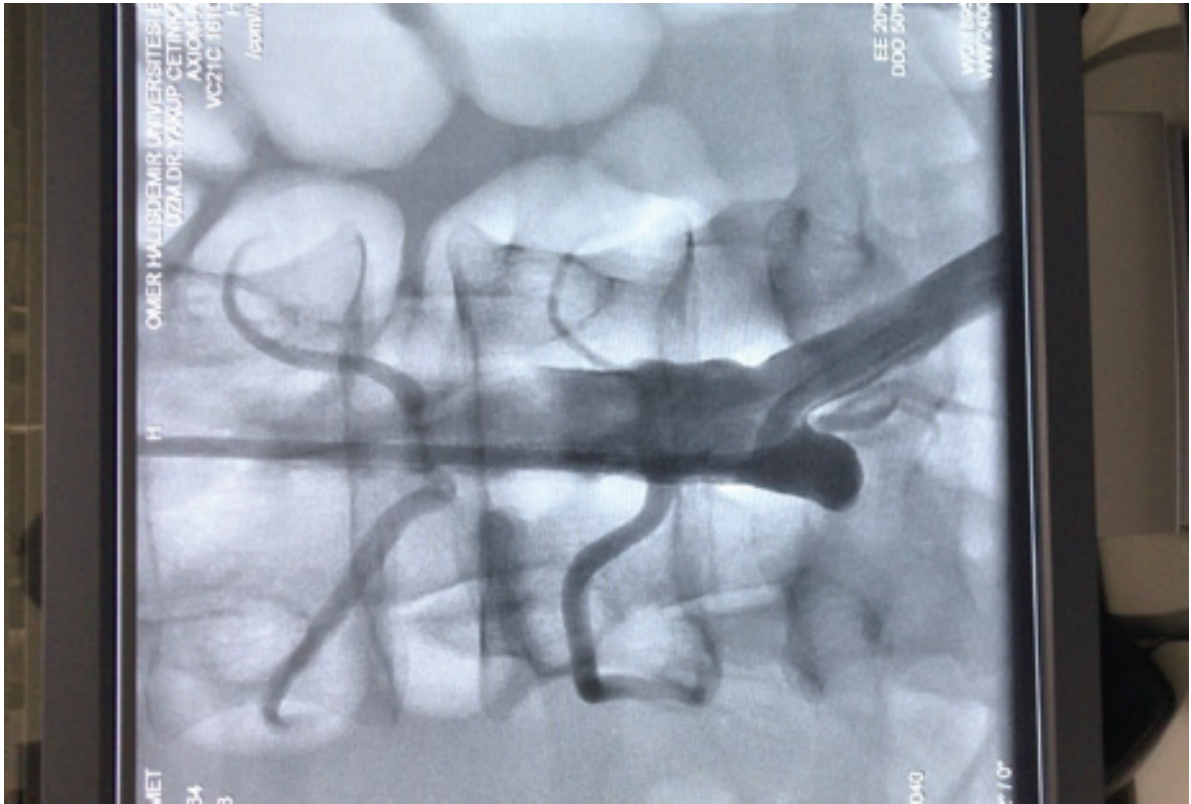
<sup>2</sup> Department of Cardiology Omer Halis Demir Universty,Nigde Turkey

### OLGU

Sağ ana iliac arter total oklüsyon sol brakial ponksiyon ile peruktan olarak açılması

### Keywords

Right iliac,CTO,Brachial aproach





## Lerich Sendromlu Hastaya Başarılı Girişim ve 9 Aylık Takibi

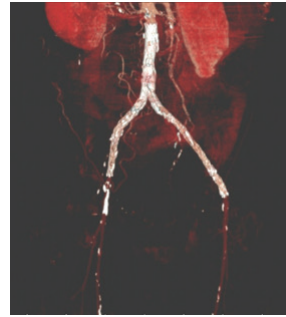
Göksel Dağışan

Ordu Medicalpak Hastanesi, Kardiyoloji Kliniği, Ordu

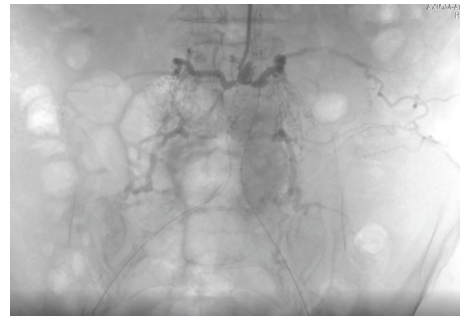
200 metre yürümek ile her iki ayağında ağrı hissedilen hasta mevcut şikayetler ile gittiği dış merkezde çekilen bt anjio sonrası lerisch sendromu tanısı konmuş medikal tedavi başlanan ve cerrahi operasyon önerilen hasta operasyonu kabul etmemiş. Mevcut şikayetleri artarak devam etmesi üzerine kliniğimize başvurdu. Hastaya yapılan periferel anjiosunda renal arter seviyesinin altından her iki femoral arterlere kadar okluzyon saptandı(LERİCHE SENDROMU.) Distal aorta okluzyonu (iliak arterleri içine alan) hastaya müdahale için sol brakial ponksiyon ile kılıf yerleştirilip mankorlu katater ve 0,035 hidrofilik floppy tel ile infrarenal seviye ye ulaşıldı. Uzun amplatz tel yerleştirilip katater çıkartıldı. Uzun 90 cm klavuz kılıf yerleştirildi. Çekimler alındı her iki femoral artere Shilt yerleştirilip 90 cm mikrokater ve gladius 0,018 tel ile her iki iliak arterden de subintimal ilerleme sağlanıp park edildi. Antegrad yoldan mikrokater ve sert hidrofilik uçlu tel ile penetrasyon yapıp hidrofilik regalia teli ile loop yapılarak ilerleme sağlanamadı ve lümene düşülemedi. Retrograd yoldan 6,0\*100 balon ile cart yapıldı takiben antegrad yoldan sert hidrofilik tel ile lezyon geçildi tip enjeksiyon ile lümene düşüldüğü teyit edilip uzun treasure floppy gönderilerek sol femoral yoldan gönderilen 7 mm snare ile yakalanan tel eksterne edildi. Mikrokatar ile retrograd geçiş yapıp aortaya 0,018 300 cm gladius teli yerleştirildi. Antegrad yoldan mikrokater ve sert hidrofilik tel ile sağ iliak lezyona penetrasyon yapıp regalia tel ile loop yapılarak ilerleme sağlanamadı. Retrograd yoldan gönderilen 6,0\*150 mm balon ile cart yapıp antegrad yoldan lümene düşüldü. Tip enjeksiyon ile lümen teyit edildi. 7 mm snare ile yakalanan uzun treasure floppy elsterne edildi. Mikrokatataer ile retrograd geçiş yapıp aortaya 300 cm gladius tel yerleştirildi. İnfrarenal total aorta ve bilateral total iliak

arterlere 7,0\*100 ve 7,0\*120 balonlar ile eş zamanlı kissing predilatasyon yapıldı. Ciddi diseksiyon gelişti bu nedenle aortaya 14\*59, bifurkasyon bölgesine ise 12\*49 ve 12\*59 mm aortik stentler yerleştirildi sonrasında sağ iliak yönüne 8,0\*37 mm greft stent yerleştirildi. Aortaya tacking balon ile post dilatasyon yapıldı. Stent optimize edildi. Sol iliak artere 10\*80 ve 80\*60 mm ses, sağ iliak yönüne ise 7,0\*100 ve 7,0\*40 mm ses implante edildi. Bifurkasyon bölgesine 8,0\*60 ve 7,0\*60 mm balonlar ile post dilatasyon yapıldı. Tam açıklık sağlandı. İşlem sonlandırıldı. İşlem sonrası ilk günde şikayetleri gerileyen hasta 9. ayda geldiği kontrolünde şikayetlerinin tekrarlamadığını söyledi hastaya çekilen kontrol bt anjiosunda stentlerin açık olduğu görüldü.

Keywords: Aortailiak total, Lerisch, Retrograd girişim

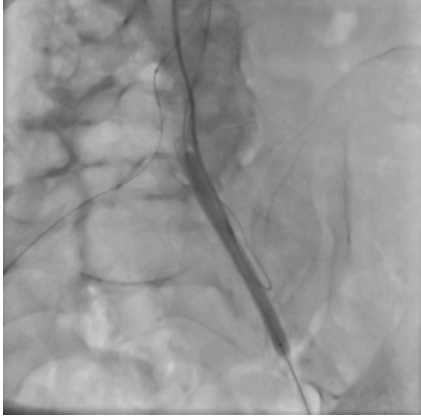


1 BT ANJİO  
LERİSCH

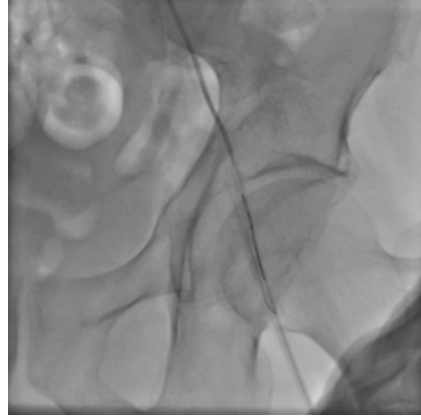


2 LERİCH İNFRAREANAL TOTAL

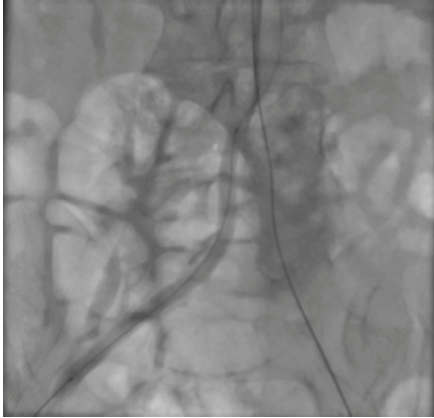




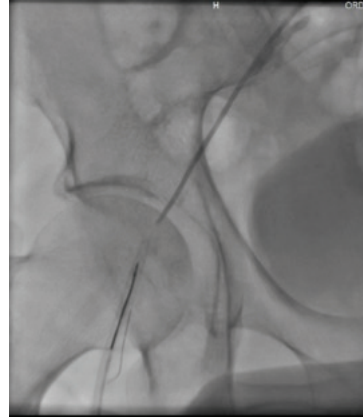3. RETROGRAD CART SOL



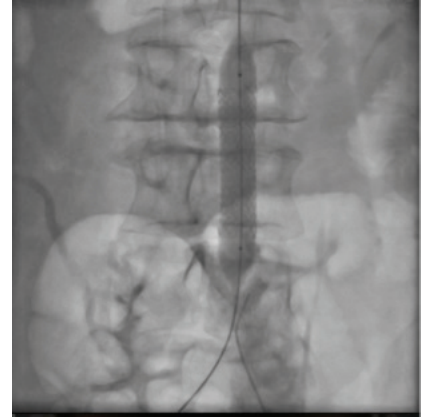
4. SOL SNARE



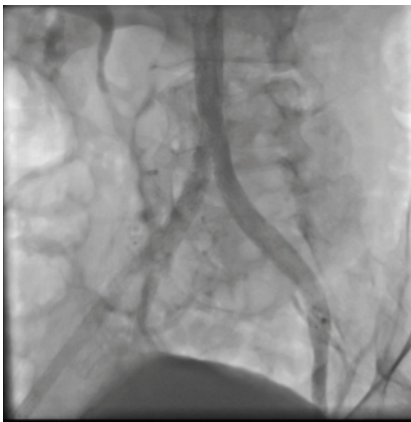
5. REVERSE CART SAĞ



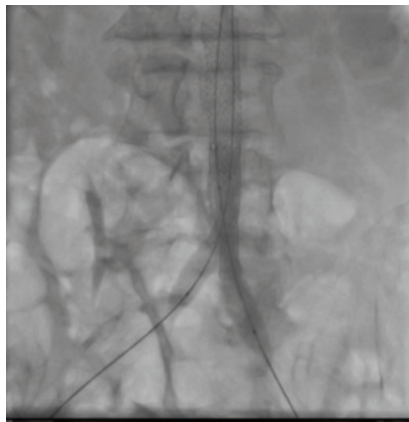6. SAĞ SNARE



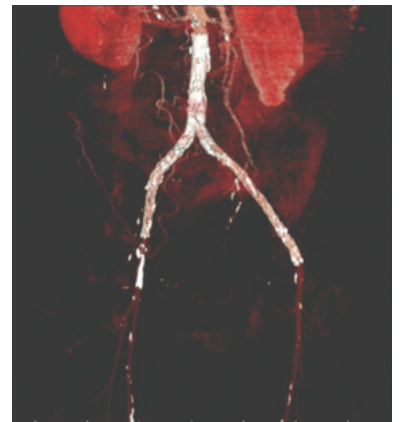7. AORT STENT



8. SAĞ SOL İLİAK STENT



9. SON GÖRÜNTÜ



10. BT ANJİO KONTROL

# SUPERA Stent İmplantation To The Patient with Re-Coil After The İntervention To The Superficial Femoral Artery Chronic Total Occlusion

Burak Öztürkeri<sup>1</sup>, Lütfi Öcal<sup>2</sup>

<sup>1</sup> Ümraniye Eğitim ve Araştırma Hastanesi, Sağlık Bilimleri Üniversitesi, İstanbul, Türkiye

<sup>2</sup> Kartal Koşuyolu Eğitim ve Araştırma Hastanesi, Sağlık Bilimleri Üniversitesi, İstanbul, Türkiye

## INTRODUCTION

Femoro-popliteal lesions are usually the first treatment option for endovascular treatment. Progress in endovascular techniques has led to the use of this treatment in complex lesions. The main method in endovascular treatment is drug coated balloon angioplasty. Stenting is postulated by residual stenosis after balloon angioplasty, current-limiting dissection and re-coil. In this case, SUPERA stent implantation and elongation will be shown in the chronic total occluded SFA lesion which is re-coiled after balloon angioplasty.

## CASE

A 42-year-old male patient is presented with resting pain on both legs to be more severe on the left side. There was a history of cerebrovascular infarction in 2016. Coronary and carotid angiography were performed in the same year. The coronary arteries had non-critical plaques and the left ICA was occluded totally and the right ICA had non-critical plaques in carotid angiography. He was a cigarette smoker and his family history was positive. He did not have diabetes and hypertension. On physical examination, distal pulsation could not be obtained in the lower extremities. Bilateral ankle-brachial index was <0.4. Electrocardiography rhythm was sinus; in Echocardiography, left ventricular ejection fraction was 65% and there was stage 1 left ventricular diastolic dysfunction. Bilateral SFAs were totally occluded in lower extremity peripheral angiography. Since the signs of the left SFA were more symptomatic, the first intervention was planned in this vessel. Lesion was passed by 0,035 guidewire with Des-

tinuation Catheter and 0,035 mm Minnie support. PTA treatment was performed with 5.0\*190mm Peripheral Balloon. The re-coil in the distal of CFA and osteal of CTO were not seen in the first image, it was showed when scopy device was positioned at 30 degrees laterally. Since the location of lesion was mobile, SUPERA 6.0\*60mm stent was implanted. There was a moderate elongation of the proximal part of stent while the stent has been implanting. The procedure was terminated without any complications.

## DISCUSSION

Stent implantation is considered in case of re-coil after balloon covered with drug was inflated in lower extremity endovascular interventions. If stenting is performed in the mobile part of joint, stent crushing and breaking may occur. Supera stent (Abbott Vascular, Santa Clara, Calif) has been developed to provide superior radial strength, fracture resistance and flexibility compared to laser-cut nitinol stents and can be used in joints. In this case, a re-coil was observed in osteal SFA after balloon angioplasty, and SUPERA stent was successfully implanted.

## Keywords

SUPERA stent implantation, Peripheral artery disease, chronic total occlusion

OP(CP-29)

## Percutan Intervention of the Tibialis Posterior Artery by Collaterals from Tibialis Anterior Artery

**Bulent Behlul Altunkeser, Nazif Aygul**

*Department of Cardiology, Selcuk University, Konya, Turkey*

A 54-year-old male patient who has a history of hypertension, chronic obstructive pulmonary disease and coronary artery disease. He was admitted to our cardiology clinic with a complaint of resting pain in his right leg for the last 1 month. The peripheral angiography revealed that the total occlusion of mid and distal segment of the right tibialis posterior artery (TPA), (Video.1.) Destination sheath was advanced from contralateral left femoral artery to right femoral artery and fincross microcatheter was advanced over destination sheath. 0.018 guidewire failed to pass the total occluded segment. In angiography, there were well developed collaterales from tibialis anterior artery (TAA) to TPA (Video 2). Under the Fincross microcatheter support, a 0.014-inch guide wire was advanced through the collateral from TAA to the TPA. TPA lesion was

retrogradely passed and the wire was taken out from left femoral artery. Then the system was converted to anterograde approach and the lesion was dilated with 2.5x30 mm and 2.5x120 mm balloons and TIMI 3 flow was supplied at the TPA (Video 3).

After that, a 6.0x80 mm stent was applied to the 80% stenosis in the mid segment of the right superficial femoral artery which was considered as the source of thrombus (Video 4). The patient was asymptomatic at the 10<sup>th</sup> month follow-up and TPA was patent open during on control angiography (Video 5)

### **Keywords**

peripheral artery disease, collateral, tibialis postery artery

OP(CP-30)

## Successful Intervention of the Total Occlusion of the Right Iliofemoral Graft of a Patient Undergoing Amputation

**Kenan Demir, Bulent Behlul Altunkeser**

*Department of Cardiology, Selcuk University, Konya, Turkey*

A 52-year-old male patient who has a history of diabetes mellitus and hypertension. The patient underwent coronary bypass surgery in 2012 and right iliofemoral bypass in 2014. He was admitted to our cardiology clinic with symptom of claudication and ulcerated lesion on the first finger of the right foot. The decision of amputation was taken at another center. The peripheral angiography revealed the total occlusion of iliofemoral bypass graft (Video.1.). We decided to perform percutaneous intervention for iliofemoral bypass graft. Destination sheath was advanced from contralateral left femoral artery to right femoral artery and fincross microcatheter was advanced over destination sheath. 0.018 guidewire passed the total occluded segment and advanced to the right popliteal artery lumen. Predilatations made with 4.0x120 mm, 5.0x120 mm balloons. Then, 6.0x120 mm and 7.0x120 mm self expandable stents were implanted. Postdilatations were performed with 7.0x40 mm and 8.0x60 mm balloons. Although there was thrombus in the lumen of graft we decided to terminate the process because we obtained distal TIMI 2-3 arterial flow (Video.2.). Heparin infusion therapy was given af-

ter the procedure. The patient was discharged with dual treatment of acetylsalicylic acid and Clopidogrel. Three years later, the patient was admitted our clinic again with the same claudication symptoms on the right leg before the first procedure. Peripheral angiography revealed total occlusion of the previously implanted stents in the iliofemoral graft (Video.3.). A percutaneous intervention was planned for the patient again. Total occlusions in the stent, was passed by the roadrunner and pilot 200 wires with navicross microcatheter support. Then dilatations were performed with 6.x80 mm, 6.0x150 mm and 7x150 mm balloons (Video.4.). TIMI 3 flow supplied (Video.5.). Tirofiban infusion was used due to intense thrombus burden. In follow-up, Acetylsalicylic acid + Clopidogrel + Warfarin triple therapy was given for 1 month. Then, Warfarin + Clopidogrel was used double treatment. The patient was asymptomatic at the 6th month follow-up.

### **Keywords**

peripheral artery disease, percutaneous intervention, graft occlusion

## Sol Popliteal Total Oklüzyonun Retrograd Yaklaşımla Başarılı Tedavisi

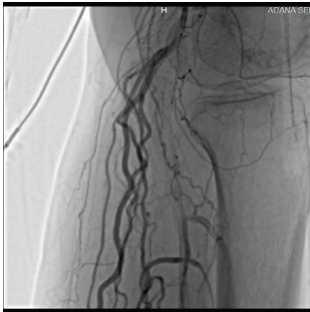Mustafa Topuz, Mehmet Küçükosmanoğlu, Ibrahim Halil Kurt  
Sağlık Bilimleri Üniversitesi Adana Şehir Eğitim ve Araştırma Hastanesi

45 yaşındaki kadın hasta sol ayak topuğunda ve lateralinde olan açık yara nedeniyle başvurduğu ortopedi tarafından değerlendirilerek vasküler oklüzyon açısından incelenmek üzere kliniğimize referans edildi. Özgeçmişinde hipertansiyon ve diyabet öyküsü olan hastanın yapılan dopler ultrasonografisinde sol poplitealde akımın alınamaması ve distalinde monofazik akım raporlanması üzerine hastaya diagnostik amaçlı alt ekstremité anjiyografi planlandı. Yapılan anjiyografide sol popliteal arterin total tıkalı olduğu kolleteral ile tibioperoneal arkın dolduğu izlendi (Figür 1). Konseyde perkütan girişim kararı alındı. Öncelikle sol süperfisiyal femoral artere (SFA) antegrade 7 F femoral kılıf girildi. Total oklüzyon güdüğünün ambigius olması ve kollateral ile devam etmesi nedeniyle başlangıçta retrograd olarak eş zamanlı posterior tibial artere 6 F radial kılıf yerleştirildi (Figür 2). Heparin 10 bin ünite

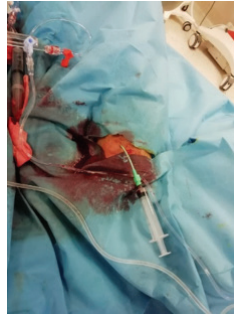uygulandıktan sonra 0.18 periferik destek kateteri (Carnelian, Tokai) ve 0.14 hidrofilik (H1- Torque whisper extrasupport, Abbott) tel ile 7F guiding kateter ile SFA' dan antegrad opak verilerek retrograd ilerleyerek total oklüzyon geçildi ve tip enjeksiyon yapıldı. 3.5x25 mm koroner Noncompliant balon (Simpass NC, Simex) ile ardışık dilatasyonlar uygulandı. Daha sonra 4.0x120 mm ilaç kaplı periferik balon (In-Pact Pacific, Medtronic) lezyonda en az 3 dk şişirilip bekletildi (Figür 3). Kontrol görüntüde minimal diseksiyon imajı ile birlikte distal akımın çok iyi olduğu izlendi (Figür 4). Hasta ertesi gün dual antiplatelet tedavi ile taburcu edildi.

### Keywords

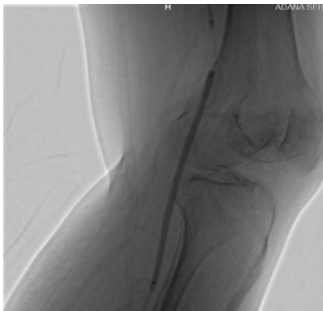retrograd girişim, popliteal arter, total oklüzyon



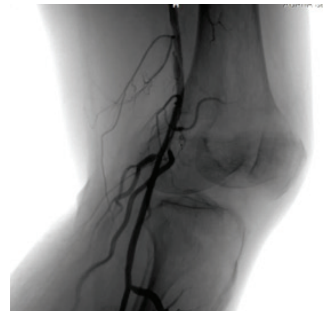Diagnostik anjiyografide popliteal arterin total tıkalı olduğu kolleteral ile tibioperoneal arkın dolduğu izlenmekte.



Posterior tibial arterine 6 F radial kılıf dilatatörünün yerleştirilmesi.



İlaç kaplı periferik balon ile dilatasyon uygulanması



Final görüntü



OP(CP-32)

## Successful Atherectomy Treatment For Left Superficial Femoral Artery with Previously Repeated Interventions

Ahmet Akdi, Ahmet Göktuğ Ertem

*Department of Cardiology, University of Health Sciences,  
Turkiye Yuksek Ihtisas Training and Research Hospital, Ankara, Turkey*

A 74-year-old male patient was referred to our hospital with increased left leg claudication, also continued during rest. He has a history of type 2 diabetes mellitus, coronary artery bypass grafting, hypertension and smoking. Prior to the admission, at different periods, he had multiple intervention to left superficial femoral artery for two times. Two months ago, peripheral artery angiography revealed occlusion in middle portion of left superficial femoral artery. The occluded calcific lesion could not passed with wire, whereas at the same session, the operator performed angioplasty with drug eluting balloon to right anterior tibial artery.

After evaluating the patient, we decided to take peripheral intervention for left superficial femoral artery again. The antegrade left common femoral artery (7F femoral sheath) approach was used for the percutane-

ous treatment of left superficial femoral artery disease. The calcific occluded lesion in the superficial femoral artery was crossed antegradely by 0.0035 inch hydrophilic wire (Figure 1). Predilatation was performed with 4.0x40 mm peripheral balloon. After this procedure, atherectomy was performed with the HawkOne™ 7F directional atherectomy system for left superficial femoral artery (Figure 2). After atherectomy procedure was performed with 7.0x120 mm drug coated balloon (Figure 3). No dissection or another complication was observed in the final angiogram (Figure 4). On discharge, acetylsalicylic acid 100 mg daily and Clopidogrel 75 mg once daily were prescribed.

### Keywords

Atherectomy, Superficial femoral artery, Intervention

OP(CP-33)

# Successful Recanalization of Popliteal, Anterior Tibial and Posterior Tibial Arteries In Patient with Thromboangiitis Obliterans

Fehmi Kaçmaz

Cardiology, NCR International Hospital, Gaziantep, Turkey

55 years-old male patient admitted to our hospital with complaint of left foot wound and pain. On physical examination, no pulse found on blow the knee arteries. Doppler-ultrasound imaging showed total occlusion of popliteal artery and angiography was planned. Total occlusion of popliteal artery with mild retrograde flow to peroneal artery via collateral circulation was found on angiography. Angioplasty was planned. Firstly, 7-F 65 cm long sheath was introduced to left superficial femoral artery antegradely. Then, 0.018 inch hydrophilic tip 300 cm wire with 0.018 inch support catheter was used to cross the total segment. After crossing the total occlusion, guide wire was delivered to posterior tibial artery and then we crossed the total occlusion at the distal part of posterior tibial artery. Firstly, balloon angioplasty was performed with 2.0x150 mm balloon, and 3.0x150

mm balloons. Anterior tibial artery was crossed with 0.018 inch hydrophilic tip 300 cm wire with 0.018 inch support catheter. However, the distal part of anterior tibial artery was very calcified and could not be crossed with 0.018 inch wire despite support catheter. So, we changed the wire with 0.035 inch straight tip hydrophilic wire with support catheter and distal part of lesion was crossed. But, none size of balloon including coronary balloons crossed distal part of lesion. So, we dilated anterior tibial artery with 3.0x150 mm balloon. Finally, popliteal artery was dilated with 5.0x80 mm balloon. On last angiogram, good angiographic result was obtained and procedure was finalized.

## Keywords

thromboangiitis obliterans, diffuse stenosis, PTA

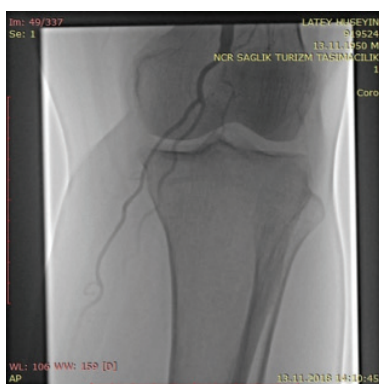

Figure 1. Before angioplasty

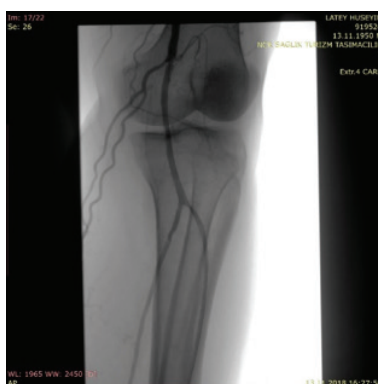


Figure 2. Post-angioplasty

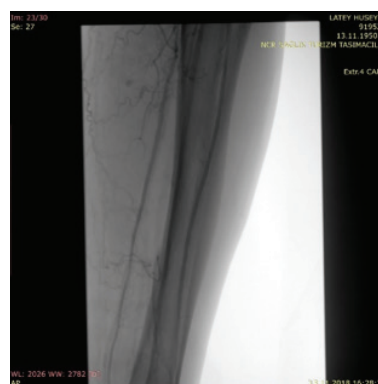


Figure 3. Post-angioplasty

# Below-the-Knee Percutaneous Peripheral Arterial Interventions Experience in Selcuk University Hospital

Nazif Aygul, Muhammed Ulvi Yalcin

Department of Cardiology, Selcuk University, Konya, Turkey

## AIM

Atherosclerotic peripheral arterial disease (PAD) is a common disease and associated with a high probability of morbidity and mortality. Despite the benefits of pharmacological therapy, the most effective treatment method of PAD is revascularization. Indication of percutaneous interventional procedures have been increased. Aim of the present study is to evaluate the procedural features and results of Below-the-Knee percutaneous transluminal angioplasty (BTK-PTA) in our center.

## METHODS

All patients undergoing BTK-PTA from September 2014 to January 2019 were retrospectively evaluated. Interventional procedural data were obtained from hospital records.

## RESULTS

There were 30 (67.40±12.15 years, %76.70 male) patients underwent BTK-PTA. 11 (% 36.66) patients have also above-the-knee PAD. Baseline clinical characteristics and comorbidities of the study population are showed in table 1. Only one patient underwent deployment stent deployment. Other procedural and material features are seen in table 2. Our procedural success was %80. Amputation was recommended by other clinics in 7 (14.28) patients before the procedure and in 5 of them the procedure was successful. Any mortality haven't been seen in periprocedural period.

## CONCLUSION

Percutaneous interventions for the management of peripheral arterial disease can be performed with high procedural success and acceptable adverse event rates

in our center. Also successful procedure can protect the patients from needless amputations.

**Table 1. Baseline characteristics of the study population (n=30)**

Age, years	67.40±12.15
Sex, male, n (%)	23 (76.70)
Coronary artery disease, n (%)	18 (60)
Hypertension, n (%)	19 (63.30)
Diabetes mellitus, n (%)	19 (63.30)
Smoking, n (%)	20 (66.7)
Concomitant above knee PAD, n (%)	11 (36.70)

**Table 2. Procedural and material features of the study population (n=30)**

Number of patients undergoing stent deployment, n (%)	1
Number of stents per patient	1
Number of patients used balloon expandable, n (%)	0
Number of balloon expandable stent per patient	0
Number of patients used self expandable, n (%)	1 (3.33)
Number of self expandable stent per patient	1 (3.33)
In patients undergoing stent deployment	
-Length of stent per patient, mm	160
-Diameter of stent, mm	5
Number of patients used conventional balloon, n (%)	25 (83.3)
Mean number of conventional balloon per patient	2.87±2.86
In patients used conventional balloon	
-Length of conventional balloon per patient, mm	270.36±214.64
-Mean diameter of conventional balloon, mm	3.10±1.11
Number of patients used drug-coated balloons, n (%)	20 (66.7)
Mean number of drug-coated balloons per patient	20 (66.6)
In patients used drug-coated balloon	
-Length of drug-coated balloon per patient, mm	290.50±234.46
-Mean diameter of drug-coated balloon, mm	2.91±0.60
Access site	
Ipsilateral femoral, n (%)	22 (73.3)
Contralateral femoral, n (%)	6 (20)
Brachial, n (%)	2 (6.7)
Distal Access site, n (%)	3 (10)
Intervention location	
Popliteal artery, n (%)	6 (20)
Anterior tibial artery, n (%)	23 (76.7)
Posterior tibial artery, n (%)	22 (73.40)
Peroneal artery, n (%)	8 (26.7)
Atherectomy, n (%)	4 (13.30)
Thrombus aspiration, n (%)	7 (23.30)
Fibrinolytic therapy, n (%)	4 (13.30)
Procedural success, n (%)	24 (80)

## Keywords

Percutaneous Interventions, peripheral arterial disease, atherosclerosis

OP(CP-35)

## Sequential Below-The-Knee Intervention In A Hemodialysis Patient with Critical Limb Ischemia

Altug Cincin, Emre Gurel, Murat Sunbul, Anil Sahin, Nurten Sayar, Beste Ozben, Kursat Tigen

*Department of Cardiology, Marmara University, Istanbul, Turkey*

Here we present a patient with CKD and bilateral prominent non-healing wounds due to below-the-knee (BTK) arterial occlusions. Our patient was a 69-year-old man with history of heart failure, DM and CKD. He was under chronic hemodialysis program for 2 years. His ejection fraction was 25% and he had moderate to severe mitral regurgitation according to his echocardiogram. His physical examination revealed prominent wounds with hyper-pigmented debris on surface. The surrounding surface of the wound was pale and both pulses were absent distally (Image 1). Firstly an angiogram of both coronary and peripheric arteries was done and severe obstructions were detected in left anterior descending artery and diagonal brunch. His lesions were ad-hoc treated with two stents in same session. On his peripheric angiogram, anterior tibial artery (ATA) of the left leg was occluded proximally and poserior tibial artery (PTA) was occluded at midsegment.. Likewise, ATA of the left leg was severely diseased and occluded proximally. For these calcific severe lesions identified on angiogram, sequential intervention was planned. In first session, a 6F short sheath was placed antegradly to left femoral artery and a 6F-MPA guiding catheter was advanced to popliteal artery and PTA. After crossing the occlusion by ease of a 300cm straight-tip Choice PT wire (Boston Scientific) advanced in Corsair microca-

theter, the whole artery was dilated by a 3x150mm balloon catheter (Boston Scientific). The same wire and a fielder FC wire was used for ATA but unfortunately wire crossing was not succesfull. DSA of the foot showed adequate vascularity from posterior tibial and peroneal arteries. For the right leg, again antegrad access was chosen and 6F MPA guiding catheter was directed to ATA. Although passing the highly calcified lumen by a Fielder FC wire was not challenging down to the distal region, total occlusion at the ankle level was so though to pass. Firstly a 1.5x20mm coronary balloon dialtion was applied to selectively visualize the arch and then the wire placed to distally. 2x150mm ballon catheter (Boston Scientific) was used to dilate the artery. Although some non-restrictive dissections were seen, flow was adequate at both arteries and DSA of the foot expose well vascularity. Although peripheric artery disease (PAD) is frequent in hemodialysis patients, management of the disease is not clear. These patients known to underwent more amputation and lesser revascularization procedures. Below-the-knee interventions seem to be favorable in this group nevertheless data from randomized trials are needed.

### Keywords

below-the-knee, hemodialysis, chronic kidney disease

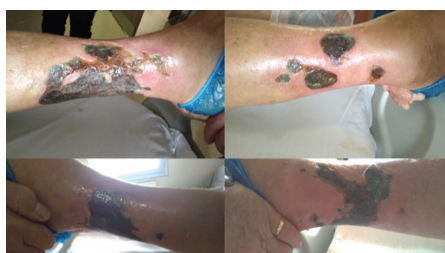

image 1 Non-healing leg wounds before the procedures.

Right side: right leg, left side:left leg

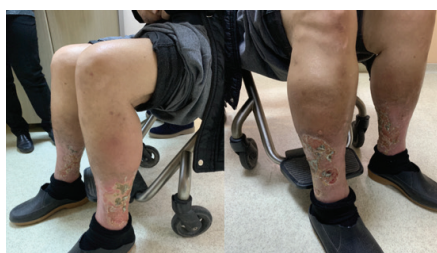

image 2 Leg wounds two months after procedure

# Perkütan Endovasküler Girişim İle Başarılı Olarak Tedavi Edilen Komplike Sol Tarafli Dizaltı Periferik Arter Darlığı Olgusu

Halit Acet, Faruk Ertaş, Hasan Kaya, Bayram Arslan, Tuncay Güzel, Raif Kılıç, M. Sait Coşkun

*Department of Cardiology, Dicle University, Diyarbakır, Turkey*

## OLGU

Tip-2 diabet, hipertansiyon ve KAH tanısı olan 59 yaşındaki kadın hasta iki aydır yürümekle olan bacaklarda ağrı, ayak parmak uçlarında yara şikayetiyle başvurduğu dış merkezde Doppler USG'de iki alt ekstremitte darlık saptanması üzerine merkezimize yönlendirilmiş. Alt ekstremitte anjiyografisinde sağ popliteal arterde ayırım öncesi %99, sağ anterior tibial arter proksimalde %80, sağ posterior tibial ve peroneal arter total tıkalı, distalleri kollateraller ile doluyordu (Resim 1). Sol popliteal arter distalinde %50, ayırım öncesi %90 kalsifik darlık, sol anterior tibial arter proksimalde %95, sol tibioperoneal arter osteal %95, Sol posterior tibial ve peroneal arterler ostealde tıkalı, sol anterior tibial ve sol posterior tibial arter distalleri zayıf doluyor (Resim 2A-B, Video 1 ) (Fontan 4, Rutherford 5 Semptomlu). Hastaya periferik girişim yapıldı. sol ayakta şikayetlerin fazla olması nedeniyle önce sol dizaltı sonrada sağ tarafta girişim kararı alındı.

## İŞLEM AŞAMALARI

Sağ femoral artere 7F 90 cm sheat 0.035 260 cm hidrofilik tel ile cross over yapılarak sol tarafa geçildi. 0.014

300 cm Nittrex marka tel ile ATA ve peroneal arterde darlıklar geçildi. Önce 2.5x80 mm balon ile lezyonlar distalden proksimale kadar predilate edildi. Ardından peroneal artere 2.5x200 mm, sonrasında ATA'ya 2.5x150 mm Vascular Luminor marka ilaçlı balonlar ile 16 atm'ye kadar 3 dk. boyunca şişirildi (Resim 3). Daha sonra ATA ve Tibioperoneal arter bifurkasyonuna 2.0x20 mm balonlarla 16 atm ye kadar kissing balon yapıldı (Resim 4) sonrasında PTA'ya 2.0x200mm aynı marka ilaçlı balon ile 20 atm'ye kadar 3 dk şişirildi. ATA ve Peroneal arterde tam akım, PTA da kısmi akım sağlandı (Resim 5 Video 2). Ayak arkının iyi kanlandığı görüldü. İşlem komplikasyonsuz olarak sonlandırıldı.

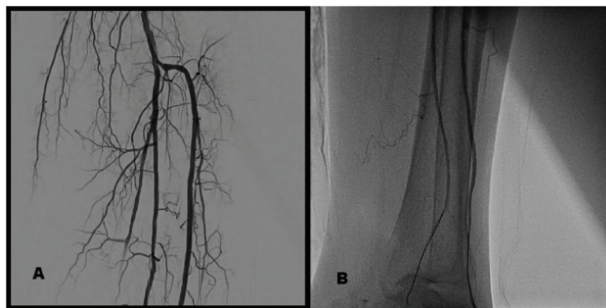
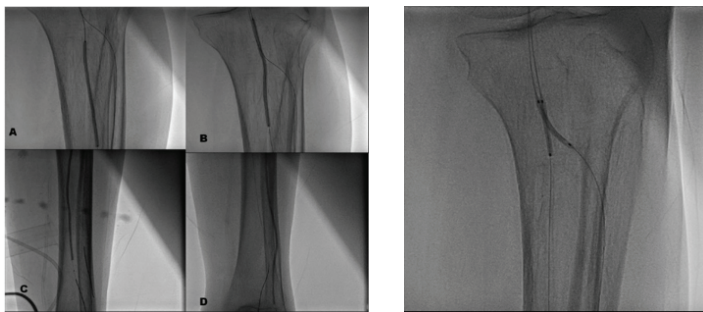
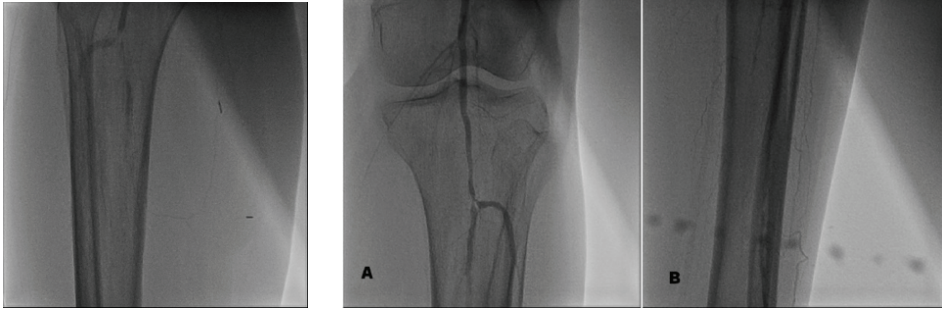## TARTIŞMA VE SONUÇ

Dizaltı arterler damar çapları küçük olduğundan komplet revaskülarizasyon çoğu zaman mümkün olmamaktadır. Olgumuz bu hasta grubunda komplet dizaltı arteriyel revaskülarizasyona iyi bir örnek teşkil etmektedir.

## Keywords

Dizaltı arter, periferik arter hastalığı, endovasküler girişim





# A Novel Technique For Treatment of Radial Artery Pseudoaneurysm

Ender Örnek<sup>1</sup>, Barış Doğuyıldız<sup>2</sup>, Mustafa Çetin<sup>1</sup>, Emrullah Kızıltunç<sup>1</sup>

<sup>1</sup> Health Sciences University, Ankara Numune Education and Research Hospital,  
Department of Cardiology

<sup>2</sup> Health Sciences University, Ankara Numune Education and Research Hospital,  
Department of General Surgery

## INTRODUCTION

Radial artery pseudoaneurysm is a rare complication of percutaneous intervention and should be treated due to rupture risk. Treatment options include surgery, ultrasound guided compression and ultrasound guided thrombine injection. In this report a novel treatment method for pseudoaneurysm is presented.

## CASE REPORT

A 63 years old woman was admitted due to a pulsatile mass on her right wrist. She had undergone coronary angiography via right radial artery access one month ago. She noticed the mass at the puncture site 2 days after the angiography and sought medical advice one week ago. On examination, radial artery was patent and a systolo-diastolic bruit was audible over the mass. A duplex ultrasound revealed a radial artery pseudoaneurysm 7×8 mm in size with a 5 mm neck. After compression treatment was unsuccessful, percutaneous treatment was decided. Because of distal radial artery puncture attempts was failed, a 6F radial sheath was introduced through proximal radial artery access retro-

gradely. Radial artery angiography showed radial artery pseudoaneurysm and an arterio-venous fistula which was not reported by ultrasound examination. (Figure1) A 2,5×20 mm monorail balloon was advanced through a 0,014" floppy wire and inflated in the radial artery alongside aneurysm. As soon as balloon inflation, 1 cc fibrine sealant (Tisseel®) was injected into the aneurysm percutaneously. (Figure 2) Balloon was deflated 5 minutes later. Control angiography showed complete resolution of aneurysm and fistula. The procedure was uneventful and patient was discharged on the following day.

## CONCLUSION

Percutaneous treatment of radial artery pseudoaneurysm with fibrin sealant or thrombine injection should be accompanied by balloon inflation covering the neck of aneurysm. This method can prevent escape of sealing material into the adjacent artery and vein.

## Keywords

radial artery, pseudoaneurysm, percutaneous, treatment

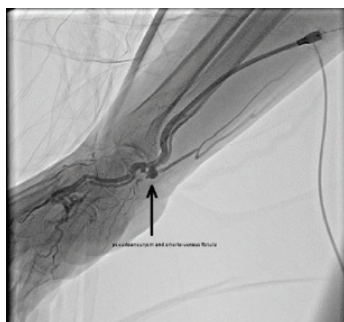

Figure 1. Right radial arteriography showing pseudoaneurysm and arterio-venous fistula at the previous puncture site.

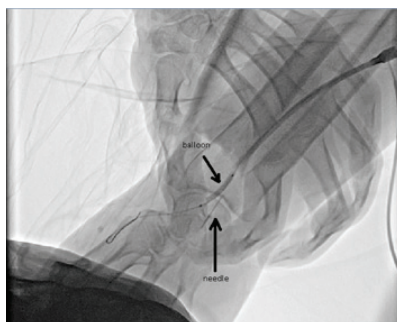


Figure 2. Fibrine sealant injection into the pseudoaneurysm while inflation of a balloon in radial artery covering the neck of pseudoaneurysm.

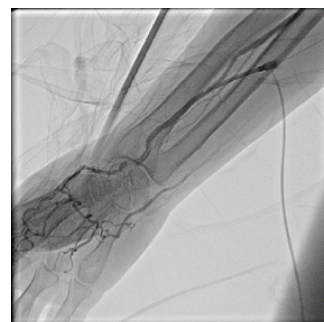

Figure 3. Radial arteriography showing complete resolution of pseudoaneurysm and arterio-venous fistula after the procedure.

## Coronary and Peripheral Artery Intervention in the Same Session

Çağrı Yayla, Ahmet Goktuğ Ertem, Mustafa Karanfil, Sefa Unal, Koray Demirtas, Ahmet Akdi

*Department of Cardiology, Health Sciences University,  
Turkiye Yuksek Ihtisas Education and Research Hospital, Ankara; Turkey*

A 51-year-old male patient referred to the catheter laboratory for imaging purposes because of chest pain and claudication. A 2.75/18 mm drug-eluting stent was inserted into the severe lesion in the RCA (figure 1 and 2). After that, The dissected distal aorta-iliac bifurcated lesion was crossed over both iliac commus arteries with the hydrophilic 0.035 inch wires by placing 7F sheath through both femoral arteries. 8 atm dilatation was per-

formed with a 6.0x60 mm evercross balloon which sent over the sheath in the right femoral artery. Then, the vi-si-pro 8x57 mm balloon expandable stents were placed end to end through the right and left femoral sheaths (figure 3-7).

Keywords: right coronary artery, common iliac artery, intervention

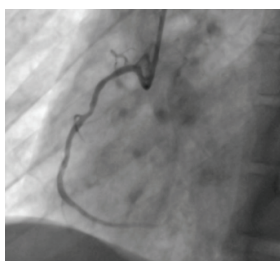


figure 1

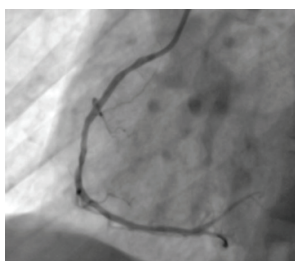

figure 2

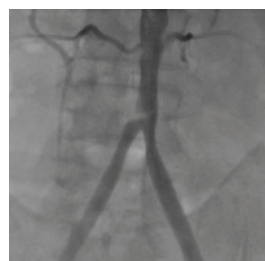

figure 3

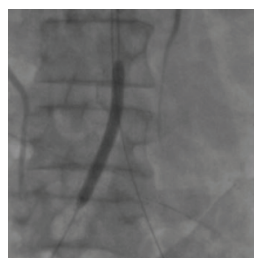


figure 4

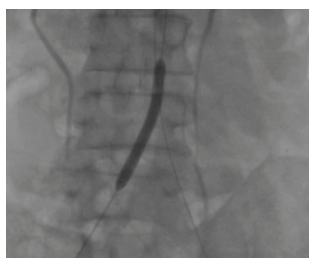

figure 5

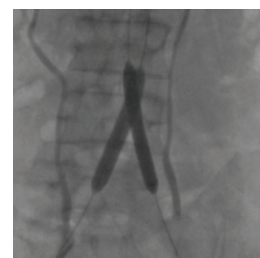

figure 6

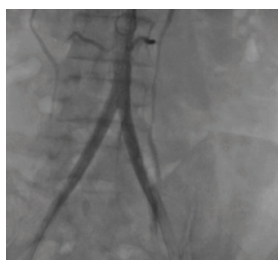

figure 7

OP(CP-39)

# Short and Long-Term Results of Thrombosed Arteriovenous Hemodialysis Fistulas Treated Percutaneously

Ibrahim Kocayigit<sup>1</sup>, Ersan Tatli<sup>4</sup>, Murat Aksoy<sup>1</sup>, Ahmet Bilal Genc<sup>5</sup>, Savas Sipahi<sup>2</sup>,  
Salih Şahinkuş<sup>3</sup>, Selcuk Yaylaci<sup>5</sup>, Mustafa Tarik Agac<sup>1</sup>, Hamad Dheir<sup>2</sup>

<sup>1</sup> Department of Cardiology, University of Sakarya

<sup>2</sup> Department of Nephrology, University of Sakarya

<sup>3</sup> Department of Cardiology, Sakarya University Education and Research Hospital

<sup>4</sup> Department of Cardiology, Sakarya Adatip Private Hospital

<sup>5</sup> Department of Internal Medicine, University of Sakarya

## INTRODUCTION

The thrombosis of hemodialysis arteriovenous fistulas (AVF) is a serious complication. Most of the cases are being treated surgically but recently endovascular strategies are being used to treat this patients. Endovascular treatment is less invasive, safe and has lower morbidity. We investigated the success rate, complication and patency rates of percutaneously treated hemodialysis AVFs.

## TOOL AND METHODS

We analyzed 33 patients with thrombosed native AVFs treated percutaneously. All patients were evaluated using colour duplex ultrasound and the thrombosed segment was confirmed. The success rates of the procedure and first, 6th and 12th months patency rates were evaluated. In all cases arterial access was used as entry site for interventional procedures. Brachial artery in 18 patients, femoral artery in 10 patients, distal radial artery in one patient and multisite access in 4 patients was used as entry site. Diagnostic angiography was performed to image arterial side and anastomosis of the AVF. After passing thrombosed segment with a 0.014 inch hydrophilic guidewire and an angled guiding catheter various sized (3-6mm) balloons were used for angioplasty. The procedure was completed after achieving adequate flow to the venous side. The patients were discharged on dual antiplatelet therapy for 1 month then single antiplatelet therapy. The patencies were evaluated one, 6

and 12 months after procedure by doppler ultrasonography. The flow rates of the AVFs above 500 mL/min were accepted as patent.

## RESULTS

33 patients (20 males, %60.6; 13 females, %39.4) with thrombosed native AVFs were enrolled. The mean age of the patients was 64,1±13.8 years (range, 23 to 91). 25 of the AVFs were radiocephalic and the remain were brachycephalic. The time between the detection of the lost of thrill on AVFs and the intervention was 43.6±26.1 hours (range, 10 to 96 hours). 23 thrombosed fistulas were treated successfully (69.7%). The age of the thrombus was an important factor for the success of the procedure. The mean age of the thrombi of the successfully treated AVFs was 36.5±24.8 hours, the mean age was 68±37 hours in the failed procedures of AVFs ( $p<0,05$ ). In four patients thromboaspiration were performed in addition to balloon angioplasty. There was no major procedural complication. In 3 patients site hematomas were observed and treated conservatively. In one patient intraarterial angioplasty balloon fracture and embolization was observed, the embolized part of the balloon was retrieved by using a snare. The patency rates of successfully treated fistulas were 95.6% at one month, 76.1% at six months and 57.9% at 12 months.

## DISCUSSION

Thrombosis of this fistulas is a serious complication

and needs urgent treatment. Most of the cases are being treated surgically but surgical revision has poor outcomes with low success rates. Percutaneous intervention of thrombosed hemodialysis AVFs is minimal invasive, safe and effective procedure.

**Keywords**

hemodialysis, arteriovenous fistulas, percutaneous treatment



OP(CP-40)

# Impaired Glucose Tolerance is Associated with Severity of Peripheral Artery Disease

Gündüz Durmuş, Erdal Belen, Semi Öztürk, Mehmet Mustafa Can

*Haseki Eğitim ve Araştırma hastanesi*

## INTRODUCTION

Diabetes Mellitus is accepted as a risk factor for Peripheral Artery Disease (PAD). The correlation of Impaired Glucose Tolerance (IGT) with severity of PAD has not been investigated in literature.

## TOOLS AND METHOD

105 consecutive patients with normal fasting glucose levels who were diagnosed to have a preliminary diagnosis of PAD by noninvasive imaging methods were included in the study. 75 g Oral Glucose Tolerance Test (OGTT) was performed for diagnosis of IGT. The severity of PAD was defined according to TASC II (Trans-Atlantic Inter-Society Consensus document) criteria from conventional peripheral angiograms by a cardiologist who was blinded to OGTT results. TASC C+D patients constituted the severe PAD group and were compared to TASC A+B patients.

## RESULTS

Patients with severe PAD had higher frequencies of hyperlipidemia and smoking. Even though fasting glucose and HgbA1c levels were similar between the two groups, 2-hours glucose levels of OGTT and frequency of IGT was higher in the severe PAD group. In Multivariable Logistic Regression Analysis, presence of IGT [odds ratio (OR)=3.296, 95% CI=(1.087-9.997), p=0.035], smoking (OR=3.395, 95% CI=(1.114-10.343), p=0.032) were independent correlates of severe PAD.

## CONCLUSION

The presence of IGT is associated with more severe PAD and is important especially in the evaluation of the cardiovascular system.

## Keywords

glucose tolerance, peripheral artery, disease

OP(CP-41)

## Acute Heart Failure After Transcatheter Aortic Valve Implantation

Salih Kilic

*Doctor Ersin Arslan Research and Training Hospital, Department of Cardiology*

### INTRODUCTION

Although transcatheter aortic valve implantation (TAVI) is an alternative treatment for high surgical risk patients with severe aortic stenosis (AS), post-implantation moderate-to-severe paravalvular aortic regurgitation (AR) remains a complication.

### CASE

A 88-year-old frail woman with a history of coronary artery disease, presented with dyspnea and chest pain (Canadian Cardiovascular Society Functional Class IV). Also, patient has moderate chronic kidney disease, asthma, and hypertension. The echocardiography (ECG) findings included normal sinus rhythm, normal axis, heart rate of 84 beats/min, ST depression, and T inversion in leads I, II, aVF, aVL, and V1-V6. Echocardiography revealed with severe AS, moderate thickening, and severe calcification and moderate aortic insufficiency. The ascending aorta was mildly dilated to 3.8 cm with moderate left ventricular (LV) hypertrophy, diastolic LV dysfunction, preserved systolic function, and good right ventricular size and function. The trans-aortic gradient was 111/59 mmHG and aortic valve area was 0.53 cm<sup>2</sup>. During previous years many times patient has been referred for surgery for AS but she denied each time. Since patient has high risk for surgery (Society of Thoracic Surgeons score 11.1%) heart team recommended to perform TAVI. Pre-operating sizing was performed with multi-slice computed tomography and decided to implantation Evolute -R 29 mm (Medtronic). Procedure was performed from right common femoral

artery. Because of heavy calcification pre-implantation valvuloplasty was done with a 20-40mm balloon. After full balloon expansion could be achieved, the valve successfully implanted. Since moderate AR and valve could not fully expand, post-dilatation was performed with 23\*40mm and 25\*40mm balloons (Figure 1-7). Unfortunately, moderate paravalvular aortic regurgitation was remained after balloons and due to heavy calcification the procedure decided to finish. Patient transferred to unit care after successfully closed femoral arteries with proglide. In the first hour of follow-up acute pulmonary edema immediately developed and systolic blood pressure decreased. An urgent echocardiography was performed in the context of an acute aortic regurgitation or cardiac tamponade. Echocardiography confirmed moderate-to-severe paravalvular aortic regurgitation and increased estimated pulmonary artery pressure of 65 mmHg. Although full medical treatment of acute pulmonary edema, patient's hemodynamic parameters were disrupted and the patient died within one hour.

### CONCLUSION

In present case we have shown that moderate paravalvular aortic regurgitation that acceptable in aortography might be cause acute heart failure and disrupted hemodynamic of patient acutely.

### Keywords

Transcatheter aortic valve implantation, paravalvular aortic regurgitation, acute heart failure

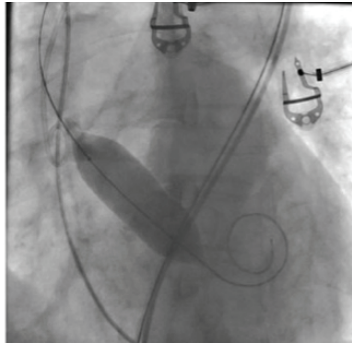


Figure-1

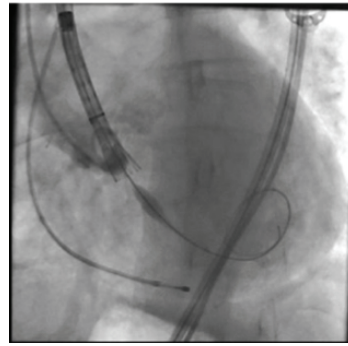


Figure-2

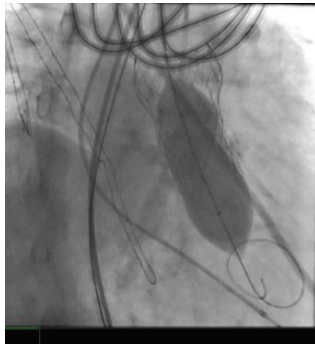


Figure-3

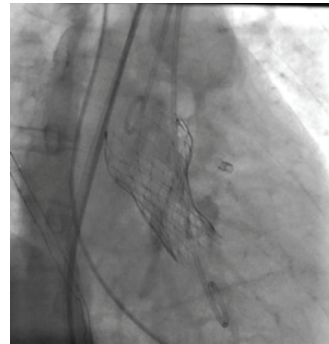


Figure-4

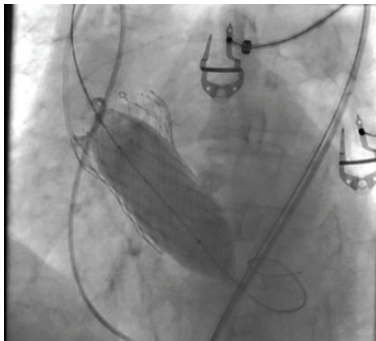


Figure-5

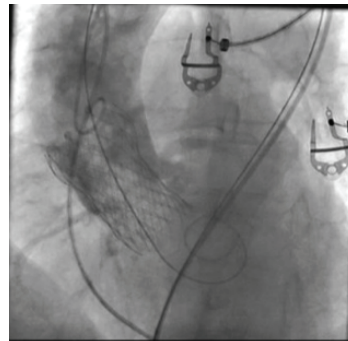


Figure-6

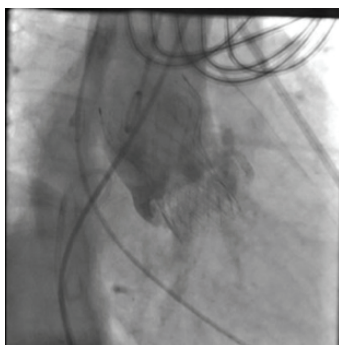

Figure-7

## Diz Altı Ampültasyon Planlanan Hastanın PTA Girişimleri Sonrası 16 Aylık Takibi

Göksel Dağışan<sup>1</sup>, Ahmet Yanık<sup>2</sup>

<sup>1</sup>Ordu Medicalpak Hastanesi, Kardiyoloji Kliniği, Ordu

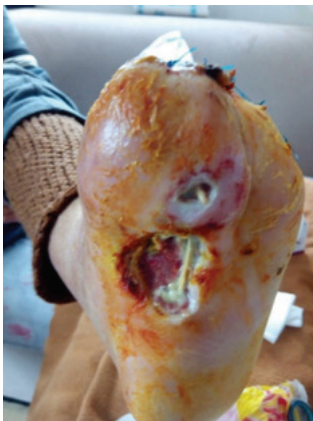<sup>2</sup>Samsun Eğitim Araştırma Hastanesi, Kardiyoloji Kliniği, Samsun

Sol ayak parmakları periferik arter hastalığı sebebi le ampültasyon yapılan sonrasında sol ayak tabanında iyileşmeyen yaraları oluşan hasta mevcut şikayetler ile gittiği dış merkezlerde periferik girişim denemiş fakat başarılı olunamamış.İstirahatte dahi şiddetli ayak ağrıları oluşan ve bu sebep ile narkotik aneljezik kullanan hastaya diz altı ampültasyon önerilmiş.Hasta mevcut şikayetler ile kliniğimize başvurdu.Yapılan periferik anjiosunda sol PTA total saptandı bunu üzerine sol diz altı lezyonuna müdahale için kontral lateral yöntem ile sağ femoral artere giriş yapıldı.Uzun kılıf yerleştirildi.Mankörlü kakater ve hidrofilik tel ile SFA seviyesine ulaşıldı ve taşıyıcı floppy tel gönderildi. Amplatz tel ile exchange yapıp uzun kılavuz kılıf pozisyonlandırıldı. Mikrokateter ve yumuşak uçlu tel ile sol popliteal arter oklüzyonları geçilip tip enjeksiyon ile lümen teyit edildi.Uzun tel yerleştirilip 2,5\*120 ve 2,5\*200 balonlar ile predilatasyonlar yapıldı. PTA distale 2,0\*150 mm ilaç kaplı balon uygulanıp tam açıklık sağlandı işlem sonlandırıldı.Hasta plastik cerrahi ve enfeksiyon hastalıkları ile birlikte takibi alındı.Ayağındaki

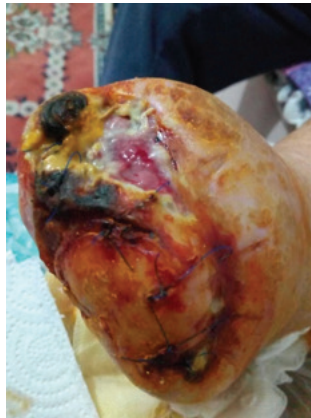ağrıları kaybolan ve yaraları iyileşen hasta ilk işlemden 16 ay sonra geldiği kontrolde sol ayağında uyuşma ve şişlik şikayetlerinin ortaya çıktığını söyledi bunun üzerine Hastaya perifer anjiyografi planlandı ve sol pta proksimal %95 mid total olarak saptandı sol pta mid total ve öncesinde %95 lezyonlara girişim için sağ femoral shilt yerleştirilip hidrofilik tel ile sağ popliteal seviyesine ulaşıldı. Poseidon 0,035 hidrofilik tel bırakılarak üzerinden uzun shiltles yerleştirildi. 0,014 microkateter ve 0,014 v14 hidrofilik tel ile lezyon geçilemedi sonrasında pilot 200 tel ile lezyon geçildi. Distale micro katataer ile inildi tip enjeksiyon yapılarak lümen teyidedildi. Total lezyona 2,0\*120 balon yapıldı sonrasında proksimal %95 ve mid total lezyonları kapsayacak şekilde 2,5\*150 balon yapıldı. Sonrasında her iki lezyonu (proksimal %95 ve mid total) kapsayacak şekilde 2,0\*150 ilaç kaplı balon uygulandı. Optimal sonuç sağlandı.

### Keywords

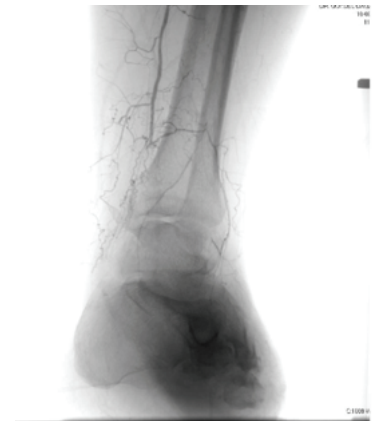PTA, Diyabetik ayak, Total,



1 İşlem öncesi ayak

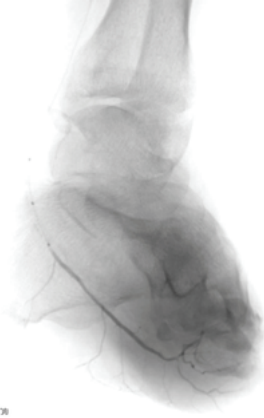


2 İŞLEM ÖNCESİ AYAK 2



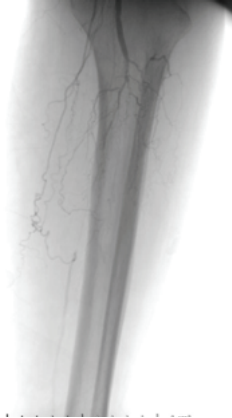
3 PTA DİSTAL TOTAL

18  
1998

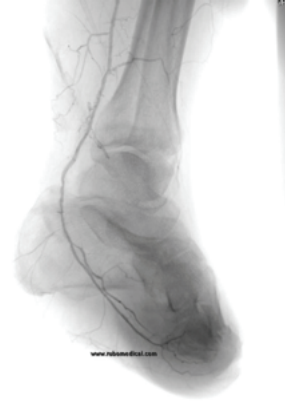


4 TİP ENJEKSİYON

DR. GÖKÇE

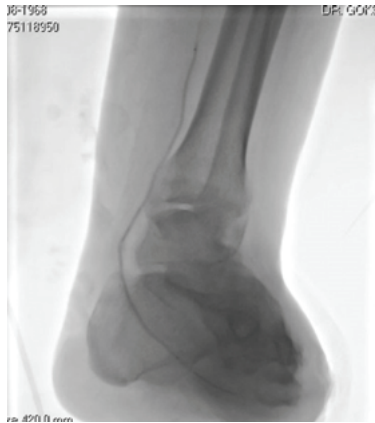

5 DİSTAL PTA PTA

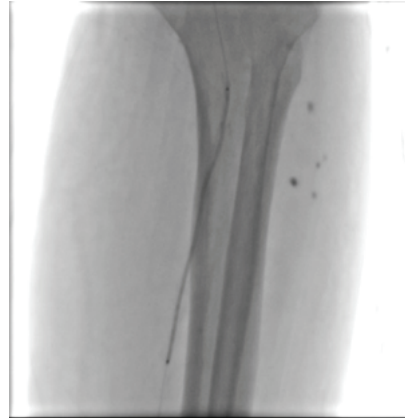


6 PTA SON

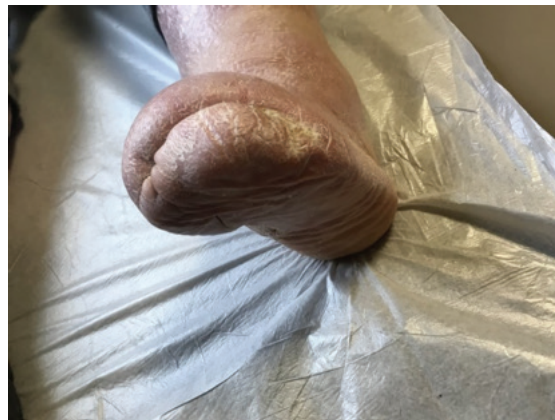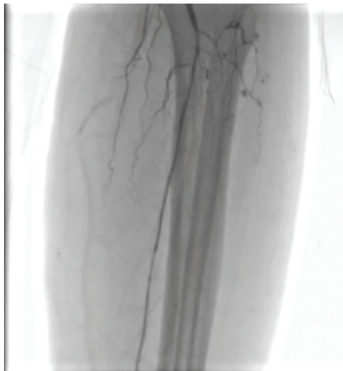10 mm  
8 CF46.0.30



7 PTA PROK TOTAL



8 PTA PROK PTA



10 gırısım ve takip sonrası



OP(CP-43)

## Surgical Treatment Of Desenden Aort Ruptur: A 25-Year Old Man

Halis Yilmaz, Aydın Tuncay

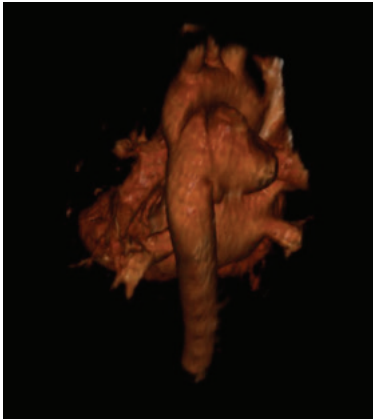
<sup>1</sup>Department of cardiyovaskuler surgery Erciyes University, Kayseri, Turkey

Blunt aortic injuries are mortal with %80-90 in the first hour and it is second most common cause of death in the trauma patient. Blunt traumatic disruption of the aorta can occur during motor vehicle collisions or falls from significant heights. This fatal condition is usually distal to the origin of the subclavian artery in the area known as the aortic isthmus. A 25-year-old man falls

from 15 m while motocross activity. He has threatened because of hemotorax and discharged. 1 month later he has gone to the hospital with difficulty of swallow. And diagnosed with ct angiography. And threatened with open surgery.

### Keywords

pseudoaneurysm, traumatic, surgery



preoperatif image

OP(CP-44)

# Recurrent Intervention In The Superior Mesenteric Artery Occlusion In Buerger's Patient

Serkan Asil, Veysel Özgür Barış, Suat Görmel, Murat Çelik, Uygur Çağdaş Yüksel  
*Gülhane Eğitim Araştırma Hastanesi Kardiyoloji Kliniği Ankara*

## INTRODUCTION

Buerger's disease is a recurrent, inflammatory, segmental, vasooclusive disease. Typically, the disease affects middle-aged male smokers and involves arteries and veins of extremities. Buerger's disease involving visceral vessels is rare. We report on a 47-year-old man with peripheral arterial disease and recurrent intestinal ischemia secondary to Buerger's disease.

## CASE REPORT

A 47-year-old patient with Buerger's disease in 2012 is being amputated from the bottom of the bilateral knee of the lower extremity. As a result of 55 kilograms of slimming in 2017, superior mesenteric artery stenosis is detected and SMA balloon angioplasty is performed by interventional radiology (Figure 1). In 2018, the patient's complaints of abdominal pain and slimming started again. In April 2018, CT angiography revealed occlusion in SMA again (Figure 2).

We decided to perform percutaneous intervention to SMA. The lesion is crossed with 0.035 Nitrix wire and is implanted with a 7.0x37 mm balloon expandable peripheral stent after balloon angioplasty performing with a 4.0x40 mm balloon (Figure 3). In the patient's follow-up, abdominal pain complaints regressed and he started to gain weight. However, in December 2018, the patient's complaints were start again and CT angiography showed that the stent was occluded at the SMA (Figure 4).

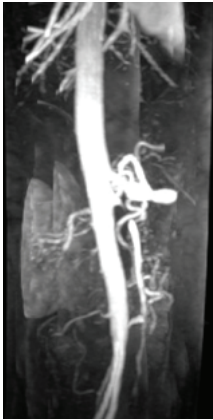As a result, we decided to perform percutaneous intervention again the patient. With the left brachial artery approach, we crossed a total occlusion of SMA with 0.014 coronary wire after that, balloon angioplasty performed with 2.0x12mm and 4.5x15 mm coronary semi-compliant balloon. After that the wire was exchanged with 0.035 nitrix wire with micro-catheter support and balloon angioplasty was performed with 7.0x40 mm balloon and complete patency was achieved (Figure 5). After the procedure, the patient's complaints regressed and he started to gain weight again.

## CONCLUSION

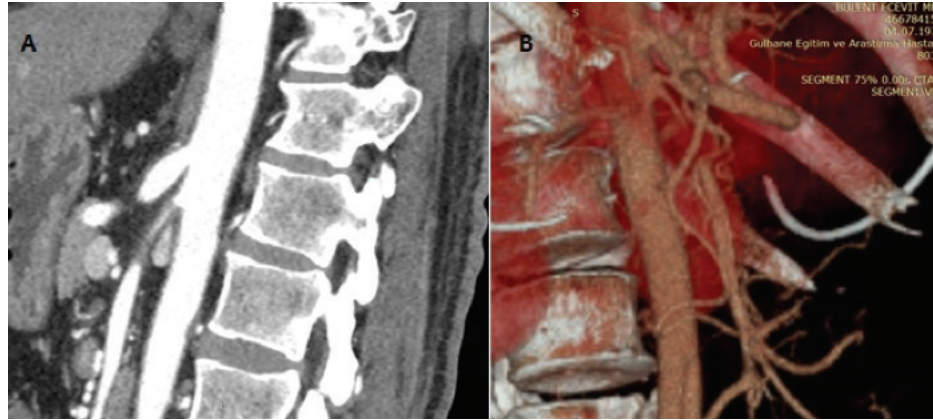
In general, it is known that the gastrointestinal involvement of Buerger's disease is difficult in early diagnosis and has poor prognosis. If the patients with established or suspicious clinical manifestation of extremity Buerger's disease complain of gastrointestinal symptoms, early interventional diagnosis is recommended for the prevention of intestinal obstruction and gangrene formation. However, the results of percutaneous interventions are not very adequate in these patients and the rates of restenosis are quite high.

## Keywords

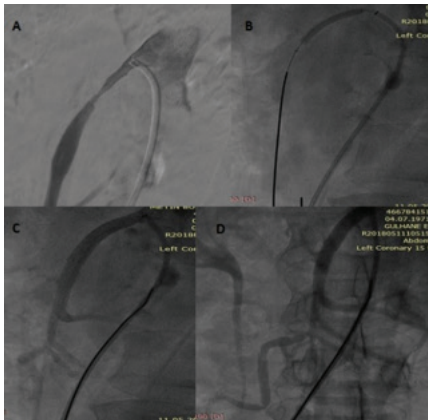
Buerger's disease, superior mesenteric artery, percutaneous intervention



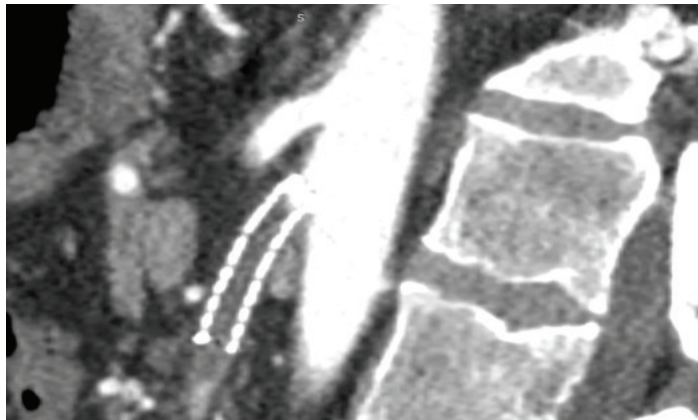
Superior mesenteric artery occlusion magnetic resonance angiography image



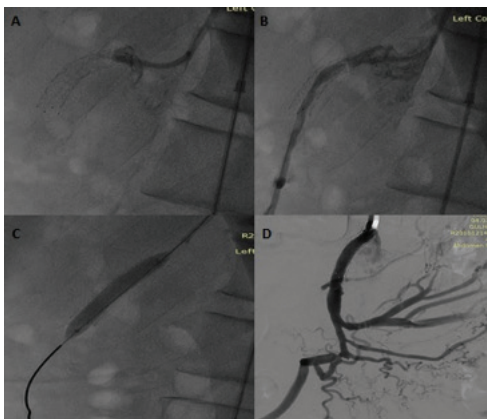
Computed tomographic angiography image of superior mesenteric artery occlusion



Percutaneous intervention and stent implantation of superior mesenteric artery



Restenosis of the stent in the superior mesenteric artery



Percutaneous treatment of stent restenosis in a superior mesenteric artery

OP(CP-45)

## Revascularization of A Totally Occluded Left Subclavian Artery Via Retrograde Approach

Mustafa Çelik

Department of Cardiology, Ahi Evran University Training and Research Hospital, Kırşehir, TURKEY

### INTRODUCTION

Subclavian artery stenosis is a significant form of peripheral artery disease, which may be a marker of diffuse atherosclerosis and increased risk for cardiovascular events. Patients with atherosclerotic occlusive plaques in the subclavian artery are usually asymptomatic. Intervention is warranted in the symptomatic patient. Hemodynamically significant stenosis of the subclavian artery usually presents with symptoms of upper limb ischemia on the ipsilateral side as the lesion. It may also present as subclavian steal syndrome with symptoms of vertebro-basilar insufficiency as a result of retrograde flow in the ipsilateral vertebral artery. There are several methods of treating symptomatic occlusive lesions of the proximal subclavian artery. An endovascular approach is attempted before proceeding to open subclavian artery revascularization as it is a less invasive procedure. Angioplasty and stenting are first line interventions for symptomatic subclavian occlusive disease. A retrospective study on the long-term outcome of this endovascular intervention concluded that there was high primary success with satisfactory outcomes beyond 10 years. In this report, we present a successful percutaneous intervention for a chronic total occlusion of a left subclavian artery.

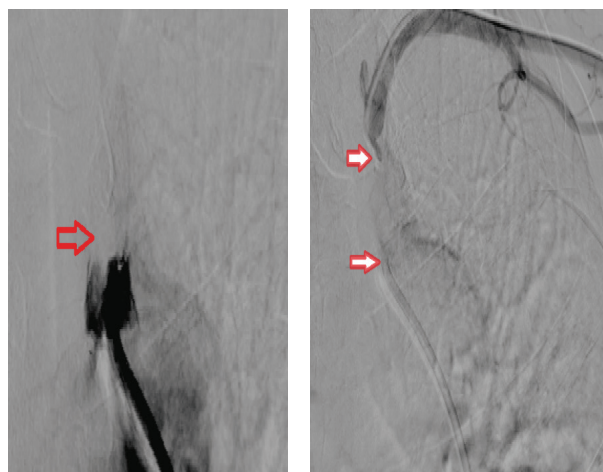
### Case Report

68 year old male smoker with hypertension, diabetes mellitus and peripheral vascular disease requiring lower limb vascular stents. He also complained of dizziness when moving her arm. Duplex ultrasonography showed stenosis in the ostial left subclavian artery. Magnetic resonance angiogram confirmed occlusion of the left subclavian artery. Percutaneous transfemoral and transbrachial approaches were used for vascular access. Aortography showed ostial left subclavian ar-

tery obstruction (Figure 1). Simultaneous retrograde peripheral angiography showed that the total occlusion was short (Figure 2). In the same session, the left subclavian artery obstruction was intraluminal crossed with peripheral guidewire (Gladius; ASAHI) with microcatheter support. The guide wire was advanced to the aorta (Figure 3) and a 5\*60 mm balloon (Armada 35; Abbott Vascular) was advanced in place and inflated. And then 8\*60 mm peripheral stent (ZENFlex; ZYLOX) was implanted. Final image demonstrated the complete revascularization of the left subclavian artery (Figure 4).

### Conclusion

Endovascular therapy for subclavian disease is effective and safe; however, open surgery still carries a better long-term durability and should be the preferred approach in low-risk patients. Symptomatic patients who failed endovascular treatment or subsequent loss of patency by stent occlusion should be considered for surgical revascularization.





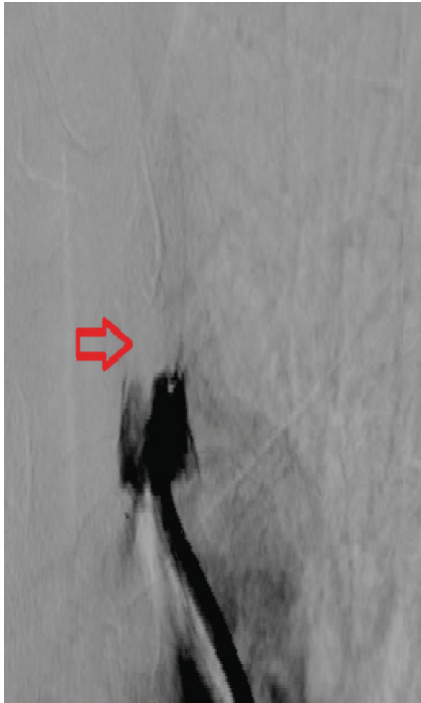


Figure 1

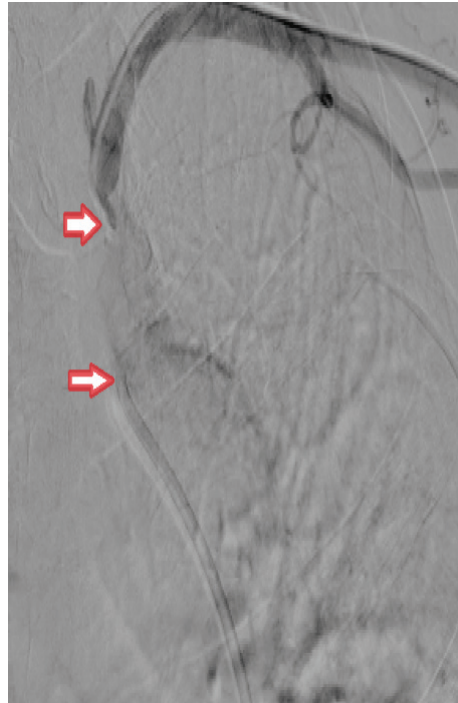


Figure 2

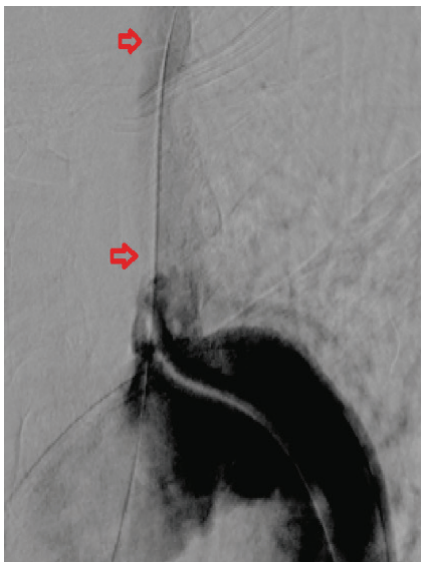


Figure 3

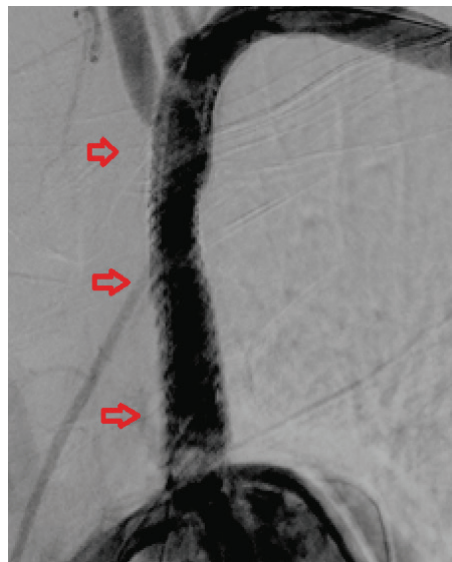


Figure 4



OP(CP-46)

## Revascularization of A Totally Occluded Common Iliac Artery Via Antegrade Approach

Serkan Sivri

Department of Cardiology, Ahi Evran University Training and Research Hospital, Kırşehir, TURKEY

### ABSTRACT

Surgical bypass strategies have been employed for mainstay management of aortoiliac occlusive disease, however, bypass rates have been steadily declining. The advancement in percutaneous management of aorto-iliac disease with angioplasty and stenting is driven by improvements in catheters, balloons, stents, closure devices, and increased operator experience. In this report, we present a successful percutaneous intervention for a chronic total occlusion of a common iliac artery (CIA). 60 year-old male patient was admitted to our clinic with complaint of claudicatio intermittens (Rutherford class 2) for six months. Peripheral angiography revealed a proximal total occlusion of left CIA (Figure 1). In the same session, CIA obstruction was crossed using 0.035" hydrophilic nitinol guide wire (Poseidon; Medtech) with the support of microcatheter (Asahi Intecc). And then, 0.018" guide wire (HT Connect 250T; Abbott) was advanced to the internal iliac artery and left there.

After that, external iliac artery was penetrated using 0.018" guide wire (Astato 30; Asahi Intecc) and 0.035" hydrophilic nitinol guide wire (Poseidon; Medtech) was passed to the lumen. Consequently, a 6 × 60 mm balloon (Armada 35; Abbott Vascular) was advanced in place and inflated. And then, 8\*120 mm peripheral stent (Protege Everflex; Medtronic) was implanted and post-dilated with a 7 × 80 mm balloon (Armada 35; Abbott Vascular). After that, because of the dissection image at the proximal edge of the stent, one more 9 × 19 mm stent (Omnalink Elite; Abbott Vascular) was implanted extend to the aorta. Final image demonstrated the complete revascularization of the CIA (Figure 2). There was no complication and the patient was discharged with medical treatment.

### Keywords

Aortoiliac occlusive disease, percutaneous intervention.

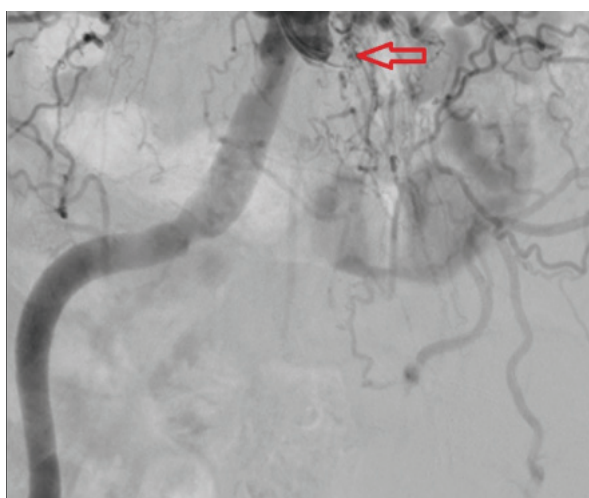


Figure 1

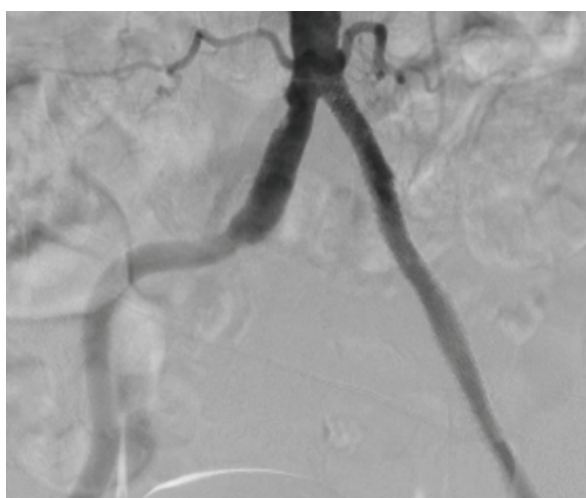

Figure 2

OP(CP-47)

## Blunt Aortic Injury with Dysphagia and Surgical Treatment

Aydın Tunçay, Halis Yılmaz

### ABSTRACT

Blunt aortic injuries are mortal with %80 in the first hour. It is second most common cause of death in the trauma patient after head trauma. Blunt traumatic disruption of the aorta, can occur during motor vehicle collisions or falls from significant heights. This fatal condition is usually distal to the origin of the subclavian artery in the area known as the aortic isthmus. Sudden hemorrhage, hypovolemic shock and consequently death affect 85% of victims. In the remainders self-limiting hematoma or pseudoaneurysm may develop. Computed tomography has replaced angiography as the gold standard for the diagnosis of blunt aortic injuries and delivers sensitivity and negative predictive values up to 100%.

### CASE PRESENTATION

A 25-year-old man falls from 15 m while motocross activity. He has threatened in a multitrauma center because of hemotorax and discharged. 1 month later he has gone to the hospital with dysphagia. The pseudoaneurysm of the aorta is diagnosed with ct angiography. It has localized just distal to the origin of the left subclavian artery. He has dispatched to our hospital. His blood pressure was 129/85 mmHg in upper extremities and 91/70 in lower extremities. Femoral pulses were diminished. He has headache. His nutrition was only liquid food. In the ct angiography aortic lumen was narrowed. The case was discussed with cardiovascular surgery team. The conclusion was to repair by open surgery because of serious dysphagia and coarctation. Dysphagia etiology was the pseudoaneurysm of the aorta. The aneurysm segment had been compressed to the esophagus. Surgical implementation with posterolateral thoracotomy has applied. The standard open surgery technique with shunt-

ing and cross-clamping was applied. Inside the aorta wasn't appropriate to repair. The proximal and distal of the graft was sutured to the aortic wall with 4-0 polypropylene by continuous suture. The total operation time was 176 min. There were no complications. Postoperatively, he was weaned from the ventilator 3 hours after the surgery. He was discharged from the hospital on postoperative 5. Day with no dysphagia.

### RESULTS

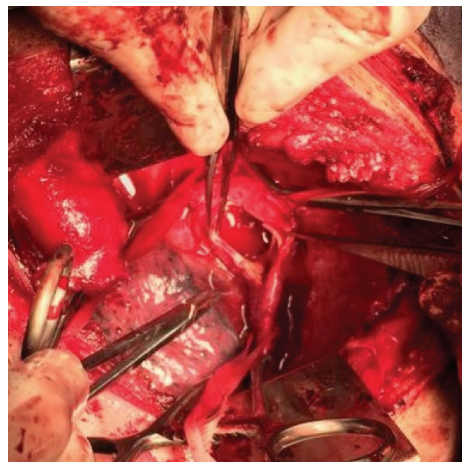
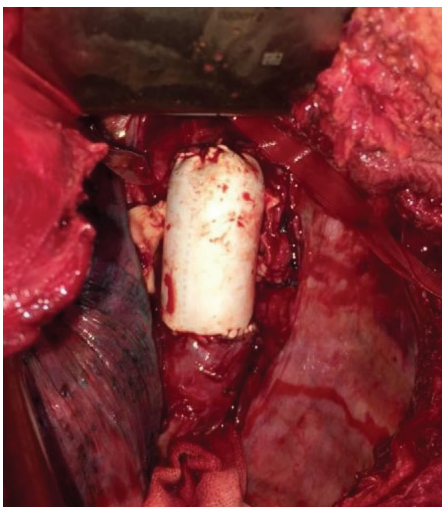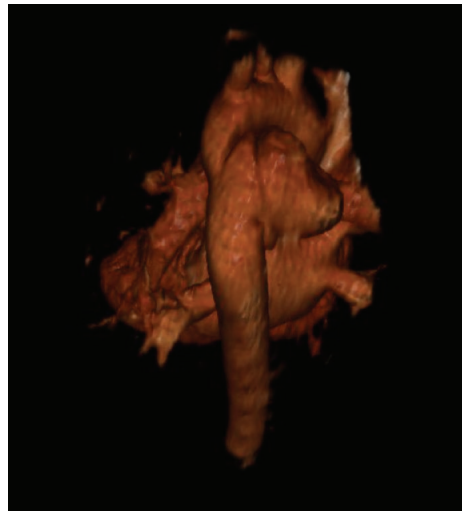
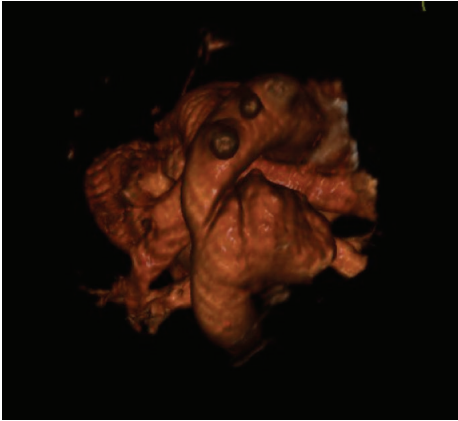
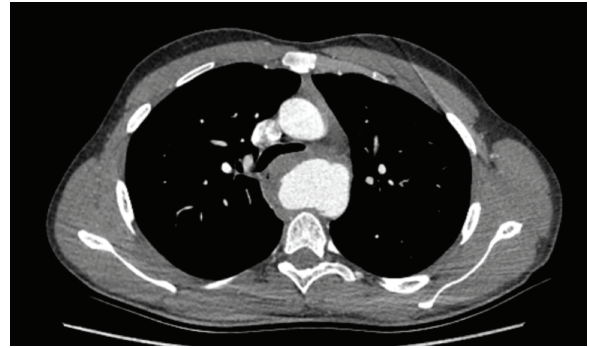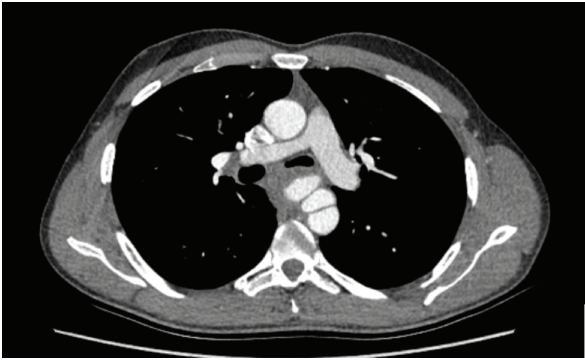The densely adherent tissue to the aorta was dissected as meticulously as possible. Dissection and pseudoaneurysm segment excluded and bypass applied with graft. Any neurological symptoms or other complications haven't developed. The patient hasn't dysphagia. Postoperative control ct angiography has optimal lumen size.

### DISCUSSION

TEVAR was suggested for BTAI if appropriate. But TEVAR cannot secure enough landing zones in some cases. However, no grafts with an appropriate caliber are usually available for otherwise normal aortas in the trauma setting. The long-term effects of endovascular stenting require further assessment in the predominantly younger population of patients who sustain BTAI. In the present case, cardiac surgery team decided to surgical treatment because of serious dysphagia. And this case was not appropriate for enough landing zone.

### KEY WORDS

Blunt Aortic Injury, Aortic pseudoaneurysm, Trauma



OP(CP-48)

## Sag Ana İliak Arter Total Oklüzyona Antegrade Müdahale

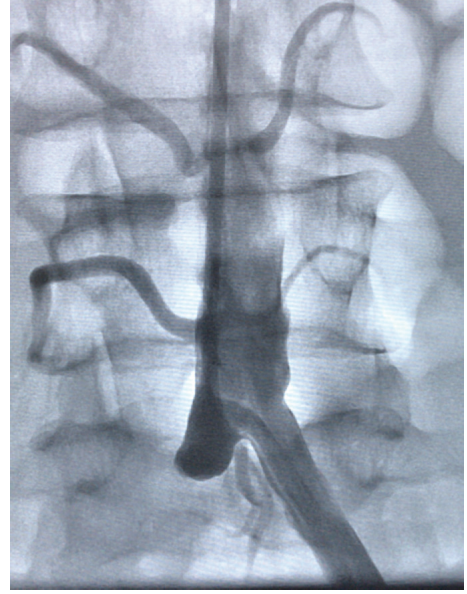
Yakup Çetinkaya

Ömer Halis Demir Üniversitesi, Kardiyoloji Bölümü

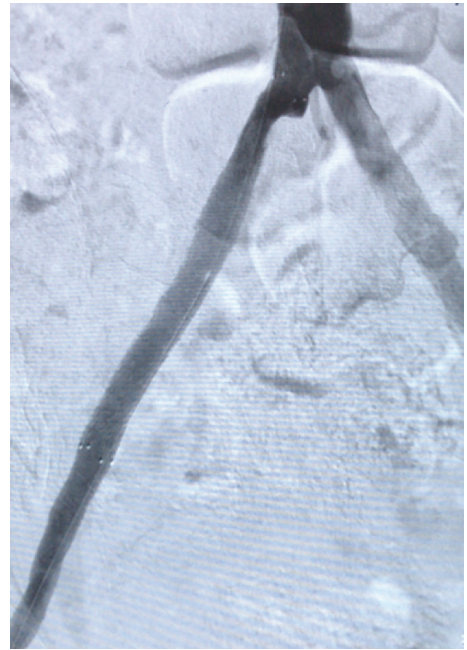
54 yaşında erkek hasta.Efor testi pozitif olduğu için hastaya koroner anjiyografi kararı alınmış. Kardiyak muayane bulguları normal. Sağ femoral nabız alınamıyor. Hastanın eforla göğüs ağrısı ve 100 metre yürümekle kladikasyotarifliyor Koroner anjiyografi esnasında sağ femoral nabız olmadığı için işlem sol femoral girişim ile yapılmış. Koroner anjiyografi non-kritik darlıklar

### PERİFERİK İŞLEM:

- Sağ common iliac güdük çok kısa bu yüzden sol brakial sheat girildi.
- Hidrofilik tel ve pigtail ile distal aortaya inildi.
- Amplats tel bırakılıp uzun kılavuz kılıf yerleşildi.
- Mikrokateter ve tressure floppy tel ile penetrasyon yapıp SFA distaline gönderildi
- 7.0x80 mm balon ile predilate edildi.sonrasında 9.0x10 mm SES stent implante edildi.
- İşlem 7.0x80 mm DCB balon uygulanarak işlem sonlandırıldı.



İşlem Öncesi:



İşlem Sonrası: