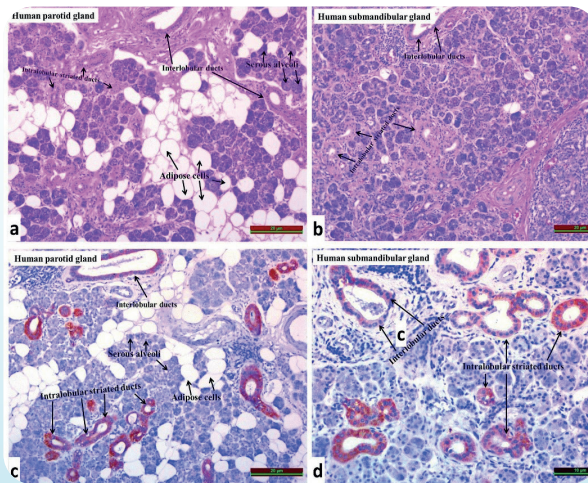


# mucosa

Volume 4 Number 1 March 2021

www.mucosa.org



Investigation of serum and saliva dermcidin levels in patients with recurrent aphthous stomatitis and dermcidin analysis in salivary gland

Oral lichen planus and oral lichenoid reactions: a retrospective evaluation of patch test results with dental series

Approach to the aphthous lesions of the oral mucosa

Parotitis in a pemphigus vulgaris patient with widespread oral lesions: a rare or underdiagnosed condition?

Self-resolving congenital form of oral lymphoepithelial cyst: case report



ISSN 2651-2750

The Society of Eastern Black Sea Dermatology and Venereology

# Contents

## Editorial

Savas Yayli, Murat Cakir

## Review Articles

**Approach to the aphthous lesions of the oral mucosa ..... 1-9**

Deniz Aksu Arica, Arzu Ferhatosmanoglu

## Original Articles

**Investigation of serum and saliva dermcidin levels in patients with recurrent aphthous stomatitis and dermcidin analysis in salivary gland..... 10-16**

Betul Demir, Demet Cicek, Ilker Erden, Suleyman Aydin, Ozlem Ucer, Tuncay Kuloglu, Mehmet Kalayci, Meltem Yardim, Esmâ Inan Yuksel

**Oral lichen planus and oral lichenoid reactions: a retrospective evaluation of patch test results with dental series ..... 17-22**

Burcu Aydemir, Leyla Baykal Selcuk, Deniz Aksu Arica, Ali Osman Metintas

## Case Reports

**Parotitis in a pemphigus vulgaris patient with widespread oral lesions: a rare or underdiagnosed condition? ..... 23-26**

Zuleyha Ozgen, Elif Comert Ozer, Dilek Seckin Gencosmanoglu

**Self-resolving congenital form of oral lymphoepithelial cyst: case report ..... 27-29**

Ayat Gamal-AbdelNaser

*Savas Yayli**Murat Cakir*

Dear colleagues,

We are delighted to welcome you to the first issue of Mucosa in 2021. It is a great pleasure for us to continue publishing during pandemic period without any interruptions.

In this issue, we have five scientific articles for you. Aksu Arica et al. reviewed the diagnostic approach to the aphthous lesions of the oral mucosa and they suggest a detailed anamnesis and physical examination.

In the research article section, Demir et al. investigated the serum and saliva dermcidin levels in patients with recurrent aphthous stomatitis, and they found that low levels of dermcidin with antimicrobial properties in saliva were considered as a predisposing factor for recurrent aphthous stomatitis. Aydemir et al. analyzed the patch test results with dental series in patients with oral lichen planus and oral lichenoid reactions, and they recommended to perform the dental patch testing in suspicious cases according to anamnesis and clinical findings.

Ozgen et al. reported a case with pemphigus vulgaris that presented with bilateral parotitis. They discussed associations between pemphigus vulgaris and parotitis and emphasized the importance of awareness of these two clinical entities in order to rapid diagnosis, treatment and prevention of unnecessary advanced tests. Finally, Ayat Gamal-AbdelNaser reported an interesting case with congenital form of oral lymphoepithelial cyst that was resolved spontaneously and recommended to follow up of the cases before a surgical intervention.

We would like to thank our readers, authors, and reviewers as well as our publisher for their meritorious contributions. We hope to hear good news for leading indexes as soon as possible. We await your valuable contributions for our forthcoming issues.

We wish you a healthy, happy, and successful new year!

Warm regards,

*Savas Yayli*

*Murat Cakir*

Editors-in-Chief

# Approach to the aphthous lesions of the oral mucosa

## Oral mukozanın aftöz lezyonlarına yaklaşım

Deniz Aksu Arica<sup>1</sup>, Arzu Ferhatosmanoglu<sup>1</sup>

<sup>1</sup>Dept. of Dermatology, Karadeniz Technical University Faculty of Medicine, Trabzon, Turkey

### Abstract

Aphthous oral cavity lesions are common in clinical practice that negatively affect the quality of life. It is possible to reveal the etiological cause in aphthous lesions, with detailed history, physical examination findings, and appropriate laboratory evaluation. In this article, we aimed to review the differential diagnosis by examining the conditions that need to be questioned with clinical clues to reveal the correct etiological cause in a patient presenting with the complaint of oral aphthae.

**Key words:** oral ulcer, stomatitis, diagnosis

### Özet

Oral kavitenin aftöz lezyonları klinik pratikte sıklıkla karşılaşılan hayat kalitesini olumsuz yönde etkileyen bir durumdur. Aftöz lezyonlarda etiyolojik nedenin ortaya konulabilmesi ayrıntılı anamnez, fizik muayene bulguları ve uygun laboratuvar değerlendirme ile mümkündür. Bu derlemede oral aft şikayetiyle başvuran bir hastada doğru etyolojik nedenin ortaya konulabilmesi için sorgulanması gereken durumlar, klinik ipuçlarıyla irdelenerek ayırıcı tanının gözden geçirilmesi amaçlanmıştır.

**Key words:** oral ülser, stomatit, tanı

### Introduction

Painful oral aphthous ulcers are commonly referred to as aphthae or canker sores.<sup>1</sup> They are characterized by an erythematous halo surrounding the ulcer and a fragile, yellowish-white fibrinous exudate covering the necrotic base.<sup>2,3</sup> Ulceration of the oral cavity may be a presenting sign of a broad spectrum of diseases such as inflammatory bowel disease, Behçet's disease, Human Immunodeficiency Virus (HIV) infection, systemic lupus erythematosus (SLE), and neutropenia, etc.<sup>4</sup> Ulcers lasting less than four weeks, which may progress as a single attack or recurrent attacks, are defined as acute oral ulcers.<sup>5</sup> Infective causes and recurrent aphthous stomatitis are among the most common causes of acute oral ulcers. Ulcers that persist for more than four weeks are considered as chronic oral ulcers. Chronic inflammatory diseases, autoimmune bullous dermatoses, and malignancies can cause this condition.<sup>5</sup>

**Corresponding author:** Deniz Aksu Arica, Dept. of Dermatology, Karadeniz Technical University Faculty of Medicine, Trabzon, Turkey  
Phone: +90 462 377 51 27, E-mail: drdenizaksu@gmail.com

**Received:** 2 March 2021 **Accepted:** 23 March 2021

**Conflicts of Interest:** None

**Funding:** None

**How to cite this article:** Aksu Arica D, Ferhatosmanoglu A. Approach to the aphthous lesions of the oral mucosa. Mucosa 2021;4:1-9



This work is licensed under a Creative Commons Attribution-NonCommercial 4.0 International License.

When dealing with aphthous ulcerations, the length of time of the lesions, frequency of episodes, inciting or triggering conditions, medications, accompanying systemic symptoms such as fever and arthritis should be questioned.<sup>4</sup> Table 1 summarizes the conditions that should be questioned in a patient presenting with oral aphthae. In physical examination, the number, type, location, size of the lesions, the base's consistency (soft or hard), and fixation to the underlying structures should be evaluated.<sup>3</sup> The initial laboratory tests should

**Table 1.** Initial questioning in a patient with an oral ulcer may include the following items

Initial questioning items
Accompanying subjective symptoms, like pain
Ulceration site in the oral mucosa
Ulcer size, number, and type
Healing time for past ulcers
Medicines
Predisposing factors
The presence of any of these
<i>Ocular, musculoskeletal, gastrointestinal, neurologic or skin findings</i>
<i>Family history for Behçet's disease, inflammatory bowel disease or Celiac disease</i>
<i>Immunocompromised condition, HCV or HIV seropositivity, weight loss</i>

include a complete blood count and ferritin levels. Laboratory assessment can be extended according to the patient's anamnesis. Histopathological and immunofluorescence evaluation should be planned for lesions that do not regress within a month. Table 2 summarizes the etiological factors that should be evaluated in a patient presenting with oral ulcers.

## Recurrent aphthous stomatitis and associated conditions

Recurrent aphthous stomatitis (RAS) is the most common cause of mouth ulcers.<sup>6</sup> The prevalence range is between 5-66%.<sup>7</sup> It occurs more frequently in women.<sup>8</sup> RAS accounts for 25% of recurrent ulcers in adults and 40% in children.<sup>9</sup>

It is characterized by the recurrent development of discrete, painful ulcers predominantly located on the

**Table 2.** The etiological factors that should be evaluated in a patient presenting with oral ulcers

Etiological factors
Recurrent aphthous stomatitis and associated conditions
Ulcerations of infective etiology: bacterial, viral and fungal causes
Erythema multiforme and medication-related ulcerations
Vesiculobullous disorders
Trauma
Neoplasia
Behçet's disease
Lichen planus

buccal mucosa, mouth floor, and ventral surface of the tongue.<sup>10</sup> Minor, major, and herpetiform types of lesions were described in the literature.<sup>3,11,12</sup>

Minor RAS lesions are 1 to 10 mm in diameter, usually confined to the lips, tongue, and buccal mucosa, and spontaneously heal within 10 to 14 days without scarring.<sup>9,13</sup> Aphthae that are larger than 10 mm in diameter are called major aphthae. Major aphthae can last up to 6 weeks to heal and tend to leave a

scar.<sup>13</sup> Major aphthous ulcers commonly extend to the gingiva and pharyngeal mucosa.<sup>1</sup> Aphthae that are less common, less than 2 mm in diameter, but usually coalesce to form large ulcers with irregular borders and heal without scarring are called herpetiform aphthae.<sup>1,5</sup> Herpetiform aphthae typically resolve within one month.<sup>1</sup>

Severe RAS lesions can cause chronic pain, malnutrition, and weight loss.<sup>14</sup> It can also impair speech and swallowing.<sup>13</sup> The etiology is unclear, but possible contributing factors are local and systemic conditions, genetic, immunological causes, foods, drugs, hormones, stress, nutritional deficiencies, and microbial factors.<sup>15,16</sup> In epidemiological studies, family history has been reported in 24% to 46% of patients.<sup>17</sup> People with a positive family history of RAS are prone to develop a more severe disease type with more frequent recurrences than the subjects with no family history.<sup>17</sup> Nutritional deficiencies, especially in iron, group B vitamins, vitamin C, folate, or zinc may contribute to RAS.<sup>18</sup> If necessary, replacement therapies should be done. In a study involving 40 patients with RAS, serum zinc levels were low in 42.5% of the patients. It was shown in this study that after one month of zinc treatment (220 mg of zinc sulfate once a day), aphthae were reduced and did not reappear for three months.<sup>19</sup> In another study, vitamin B1, B2, and B6 levels were examined. Vitamin B deficiency was found in 28.2% of patients with RAS, and significant improvement was observed in patients receiving replacement therapy.<sup>20</sup>

If there are foods that are thought to trigger RAS or delayed recovery, avoiding these foods should be recommended (acidic, salty, spicy foods, peanuts, chocolate, tomatoes, or alcoholic beverages). A food diary should be kept in order to detect the agent. Methods such as specific IgE tests, skin prick tests, skin patch tests can be used to detect food allergies associated with RAS. Hard foods that may cause trauma, biting lips or cheeks, brushing teeth with stiff brushes, and toothpaste containing sodium lauryl sulfate are among the local triggering factors. Non-steroidal anti-inflammatory drugs, antibiotics,

beta-blockers, and angiotensin-converting enzyme inhibitors may also cause RAS.<sup>15,21</sup> Emotional stress and menstrual cycle can trigger RAS attacks.<sup>21</sup> In the study of Tüzün et al., a negative epidemiological relationship was found between RAS and smoking.<sup>22</sup> According to the literature, the protective effect of smoking on RAS was only noticed in heavy smokers or persons who smoked for more extended periods.<sup>23</sup>

Celiac disease, Crohn's disease, and ulcerative colitis may have an association with RAS, and these should be considered in patients with gastrointestinal complaints.<sup>21</sup> Systemic immunosuppressing conditions such as HIV may cause RAS-type ulcers.<sup>24</sup> Conditions such as Behçet's disease, mouth and genital ulcers with inflamed cartilage (MAGIC), and Reiter's syndromes should be included in the differential diagnosis in patients with a history of other mucocutaneous and systemic complaints such as genital ulcerative lesions, papulopustular eruptions, erythema nodosum, uveitis and arthritis.<sup>21</sup> Autoinflammatory syndromes such as periodic fever, aphthous stomatitis, pharyngitis, and adenopathy (PFAPA) syndrome; cyclic neutropenia; and hyperimmunoglobulin D (hyper IgD) syndrome should be kept in mind in the presence of fever, malaise or other systemic symptoms.<sup>4</sup>

## Ulcerations of infective etiology: bacterial, viral and fungal causes

### Bacterial infections

Syphilis is a sexually transmitted disease caused by *Treponema pallidum*. The lesion of primary syphilis may begin as a papule after an incubation period, which can vary between 10-90 days, that may progress to a hard, painless, non-purulent, clean-based ulcer. Although the genital areas are the most common ulceration site, primary syphilis may also cause ulceration in the oral mucosa, depending on the contact area. Oral chancres of syphilis most often involve the lips and typically involute in 3-8 weeks.<sup>25,26</sup> Oral ulcers may also be observed in the secondary and tertiary stages of the disease. Oral ulcers are painless and heal spontaneously in 2 to 10 weeks in secondary syphilis.<sup>27</sup>

In tertiary syphilis, gumma may present as ulcerations, especially on the hard palate and tongue. Gummatous syphilis can destruct bone, perforate palate and leave scars.<sup>25</sup> When deemed necessary, suspicious sexual contact history should be questioned, and appropriate laboratory tests should be requested.

Tuberculosis (TB) is caused by *Mycobacterium tuberculosis*. Oral lesions are most commonly seen as ulcers. Oral TB may be either primary or secondary. Primary TB, which is most common in children, appears as a painless ulcer, while secondary TB is most commonly seen in adults with pulmonary or gastrointestinal TB and presents with painful ulcers.<sup>28</sup> Tubercular ulcers are long-lasting, slowly increasing in size, and do not tend to heal.<sup>28</sup>

### **Viral infections**

Herpes simplex virus (HSV) type 1 and HSV type 2 both induce ulceration, but HSV type 1-related ulcerations occur in the oral mucosa more frequently.<sup>29</sup> Primary herpetic gingivostomatitis is an acute onset of the primary form of HSV that occurs mainly between the ages of six months and five years.<sup>30</sup> Mild fever, malaise, local lymphadenopathy may be seen in some patients. Lips, gingivae, palate, or tongue may be affected.<sup>29</sup>

Secondary herpetic stomatitis, usually seen in adolescents and adults, may be precipitated by sunlight, trauma (including dental treatments), menstruation, and emotional stress.<sup>5</sup> Unlike a primary infection, symptoms such as fever, malaise, and lymphadenopathy are not accompanied.<sup>5</sup> Herpetic lesions are characterized by grouped vesiculations that may rupture and ulcerate with jagged edges in a localized area. The condition is generally self-limited and resolves within 7-10 days without scarring.

Coxsackievirus A is a causative agent of hand, foot, and mouth disease, which generally affects children and adults, and is characterized by herpetiform ulcers, especially in the soft palate and uvula, unlike HSV.<sup>5</sup> It regresses spontaneously within 7-10 days.

Varicella is a primary infection of varicella-zoster virus (VZV) that classically affects the skin. The lips,

buccal mucosa, and palate are the most common sites if oral ulcerations occur in severe disease.<sup>31</sup> Zoster occurs in older or immunosuppressed patients as a recurrent infection of varicella. Oral mucosal findings are characterized by crusting of erythematous macules and vesicles unilaterally distributed.

Oral ulcerations with Cytomegalovirus (CMV) not common; however, it may present with non-specific widespread ulcerated lesions in the oral mucosa. These non-specific ulcerations mainly occur in immunosuppressed patients and most commonly affect the hard palate, soft palate, tongue, and mouth floor.<sup>32</sup>

Recurrent aphthous ulcers are seen with a frequency of 0.6-13.6% in HIV-infected patients. Most of these had a CD4 cell count of fewer than 100 cells per mm.<sup>33</sup> Oral ulcers usually heal with antiretroviral therapy, and the incidence of oral ulcers was significantly reduced with antiretroviral treatments.<sup>34,35</sup>

Epstein-Barr virus (EBV)-positive mucocutaneous ulcers are self-limiting, silent ulcers associated with immunosuppression, generally responding well to conservative treatment.<sup>36</sup> It is essential to distinguish it from HIV-associated oral ulcers.<sup>37</sup>

### **Fungal infections**

Various fungal infections can cause oral ulcerations, especially in immunocompromised patients. Blastomycosis infection in oral mucosa may show erythematous, irregular, rolled borders and mimics squamous cell carcinoma.<sup>4</sup> Histoplasmosis often starts as erythematous macules located on the gingiva, palate, and tongue and forms painful ulcerative lesions.<sup>38</sup> In immunosuppressed patients, aspergillus most often involves the palate and tongue. Painful ulcerative lesions with the yellow-black necrotic area are characteristic.<sup>4</sup> Cryptococcal oral mucosal lesions are extremely rare and have been reported mainly in Acquired Immunodeficiency Syndrome (AIDS) patients. It can be seen as a tongue-palate ulcer, an ulcer that does not heal after tooth extraction, or hyperplastic tissue-mimicking benign or malignant tumor on the oral mucosa.<sup>39</sup>

## Erythema multiforme and medication-related ulcerations

Erythema multiforme (EM) is an immune-mediated abnormal T-cell response characterized by cutaneous targetoid lesions and mucosal erosive or ulcerative lesions.<sup>40</sup> Oral lesions occur more than 70% of patients.<sup>41</sup> EM is most commonly associated with infective agents such as HSV, *Mycoplasma pneumoniae*, and EBV.<sup>4,40</sup> Medications like non-steroidal anti-inflammatory drugs (NSAIDs), antibiotics, antifungals and antivirals, malignancies, radiation exposures, immunizations, foods, and hormones are the other possible etiologic factors.<sup>40</sup>

Stevens-Johnson syndrome / toxic epidermal necrolysis (SJS/TEN) is a severe mucocutaneous reaction mostly caused by drugs. Other potential etiologies include infections (*Mycoplasma pneumoniae*, HSV, HIV, influenza virus, hepatitis viruses, group A beta-hemolytic streptococci, etc.), malignancies, and vaccinations.<sup>42</sup> Mucosal involvement can occur before or after skin rash in more than 90% of patients. Following one to three weeks after taking the responsible drug (antibiotics, NSAIDs, and anticonvulsants), cutaneous lesions appear as tender, erythematous, dusky macules with a positive nikolsky sign.<sup>1</sup> Diffuse oral, ocular and genital mucosal involvement may be present. Labial mucosa, buccal mucosa, tongue, mouth floor, and the soft palate are the most common involvement sites. Burning sensation, erythema of the lips and buccal mucosa, and the hemorrhagic crusting of the vermilion zone of the lips are some of the accompanying complaints and signs.

Fixed drug eruptions (FDE) typically appear within one to two weeks of the first exposure to a drug. However, in repeated exposures, this period can be up to 1-2 days.<sup>1</sup> In FDE, oral cavity, skin and genital mucosa could be affected. Cutaneous manifestations include one or more sharply demarcated edematous plaques with a dusky center or ulceration.<sup>1</sup> FDE may present as ulcerative aphthous stomatitis of the oral mucosa.<sup>43</sup>

Immune checkpoint inhibitor-associated oral mucositis, erosions, and ulcerations<sup>44</sup>, Mammalian (mechanistic) target of rapamycin (mTOR) inhibitor-associated stomatitis (mIAS)<sup>45</sup>, and nicorandil-induced oral ulcerations<sup>46</sup> have also been reported in the literature.

## Vesiculobullous disorders

Pemphigus vulgaris (PV), paraneoplastic pemphigus (PNP), bullous pemphigoid (BP), linear IgA bullous dermatosis (LABD), mucous membrane pemphigoid (MMP), epidermolysis bullosa acquisita (EBA) are some of the vesiculobullous disorders which can affect the oral mucosa. Since there are many causes of mouth ulcers, it is crucial to recognize the essential clinical features at the presentation.

PV is characterized by flaccid, intraepithelial bullae and shows oral lesions as early manifestations of the disease in nearly 50% of the cases.<sup>47</sup> It involves both men and women with a mean age between 40 and 60 years.<sup>48</sup> Mucosal lesions may occur first, and then disease may progress to involve the skin.<sup>47</sup> Clinically oral lesions appear as long-lasting painful ulcers and erosions that do not heal spontaneously. Buccal mucosa, lips, and soft palate are most commonly involved.<sup>48</sup> PNP is a rare mucocutaneous blistering disorder accompanied by both benign and malignant neoplasms.<sup>49</sup> PNP should be kept in mind in the presence of polymorphous cutaneous eruption and severely painful, hemorrhagic oral erosions. Oral lesions frequently involve the vermilion and the tongue.<sup>5,49</sup>

BP characteristically occurs in the elderly, especially patients older than 70 years, and is associated with neurological disorders such as dementia, Parkinson's disease, and cerebrovascular diseases.<sup>50</sup> The disease typically presents with a generalized itchy blistering eruption, although non-bullous presentations may also be seen.<sup>50</sup> Oral involvement is seen in 10-30% of BP patients.<sup>51</sup> The chance of seeing an intact blister on oral examination is higher in BP than in PV because of the deep subepithelial involvement.<sup>5</sup>



MMP is a rare subepidermal blistering disorder that predominantly involves mucosal tissues. It is more common in middle-aged women.<sup>52</sup> Lesions may affect oral mucosa, conjunctiva, anogenital tissues, and upper aerodigestive tract and may lead to scarring in mucous membranes, skin, or both.<sup>53</sup>

In most patients, the oral mucosa is the site of onset and the most frequent area of involvement (85%) in the disease process.<sup>54</sup> Gingiva (80%), buccal mucosa (58%), and palate (26%) are the most affected localizations in the oral mucosa.

EBA is a rare autoimmune blistering disease that has autoantibodies to collagen VII.<sup>55</sup> Vesicle and bullae formation appear predominantly at sites of trauma. Mucosal involvement occurs in 23% of EBA patients, and the most affected localizations are the oral, ocular, and genital areas.<sup>55</sup>

LABD is characterized by tense vesicles and bullae that usually appear 1-15 days after drug exposure.<sup>1</sup> IgA autoantibodies produced against basement membrane antigens are responsible for this entity.<sup>56</sup> LABD could be triggered by drugs (vancomycin, penicillins, cephalosporins, insulin) and infection and may be associated with malignancy.<sup>56</sup>

### **Trauma**

Oral traumatic ulcers are thought to be less common than aphthous stomatitis. Ulcers resulting from acute trauma are generally self-resolving without complication within 14 days; otherwise, if an ulcerative lesion lasts for two weeks or longer, it is considered as chronic ulceration and may require a biopsy to rule out neoplasia or other conditions.<sup>5,57</sup>

It may be caused by chemicals such as restorative materials, local anesthetics, sodium hypochlorite, formocresol, topical aspirin, topical oral care products, or thermal, electrical, or mechanical trauma (a sharp surface on a tooth, restoration, or denture).<sup>57</sup>

### **Neoplasia**

Non-healing mass or persistent ulcers with indurated margins may present oral squamous cell carcinoma

(SCC). The most common localizations are lateral and ventrolateral aspects of the tongue, the mouth floor, and the buccal mucosa.<sup>58</sup> SCC frequently occurs in areas of abnormal mucosa, such as leukoplakia, erythroplakia, or lichen planus. The presence of non-healing wounds longer than three weeks in the absence of evidence of trauma or systemic disease should raise SCC suspicion in persons over 40 years of age, male, heavily smoker, and alcohol drinker.<sup>58</sup> Human papillomavirus (HPV) infection may also lead to oropharyngeal SCCs, particularly at the tongue base and palatine tonsils.<sup>59</sup>

Malignant lesions of B or T-cell origin such as cutaneous T-cell lymphomas (CTCL), extranodal NK/T-cell lymphoma and EBV positive mucocutaneous ulcer may be observed in the oral cavity.<sup>4</sup>

### **Behçet's disease**

Behçet's disease should be considered in recurrent painful oral ulcers, especially if there are accompanying genital ulcers or other mucocutaneous findings like erythema nodosum and papulo-vesiculopustular eruptions and systemic complaints. Disease-related oral ulcers tend to be more frequent and often multiple.<sup>60</sup> Minor aphthous ulcers are the most common type.<sup>60</sup> Mucosal aphthosis is the presenting sign in 80% of cases.<sup>1</sup> Even if there is no active genital ulcer, patients with a history of genital wounds should be evaluated in terms of genital mucosa scar. If necessary, a pathology test should be done to make the diagnosis. Ocular diseases such as anterior-posterior uveitis or retinal vasculitis, central nervous system deficits, gastrointestinal involvement, arthritis, and vascular disease may be observed.<sup>60</sup>

### **Lichen planus**

Lichen planus is a T-cell mediated chronic inflammatory disease.<sup>61</sup> Oral mucosal involvement may be seen alone, or other mucosa, skin, and nail involvement may accompany. In oral involvement; white, reticular, papular, plaque-like, erosive, atrophic, bullous lesions may be observed. They may be asymptomatic or painful. Buccal mucosa, lateral tongue, and gingiva are

the most frequently affected areas.<sup>62</sup> Hepatitis C virus infection, amalgam, food additives, or dental materials may be involved in etiology.<sup>61,62</sup> If any, like removing the amalgams, improvement can be achieved by eliminating the etiological factor, especially in related localizations.

## Conclusion

Oral aphthous lesions have extensive etiologic factors and differential diagnosis. Therefore, detailed anamnesis is also very important as well as a physical examination. In the presence of any other concomitant systemic complaints or suspected malignancy findings, biopsy and additional tests may be necessary to confirm the diagnosis.

**Peer-review:** Externally peer-reviewed

### Authorship contributions:

Conception and design, or analysis and interpretation of data: DAA, AF

Drafting the manuscript or revising the content: DAA, AF

Final approval of the version to be published: DAA

## References

1. Edgar NR, Saleh D, Miller RA. Recurrent aphthous stomatitis: a review. *J Clin Aesthet Dermatol* 2017;10:26-36.
2. Schemel-Suarez M, Lopez-Lopez J, Chimenos-Kustner E. Oral ulcers: differential diagnosis and treatment. *Med Clin (Barc)* 2015;145:499-503.
3. Tarakji B, Gazal G, Al-Maweri SA, et al. Guideline for the diagnosis and treatment of recurrent aphthous stomatitis for dental practitioners. *J Int Oral Health* 2015;7:74-80.
4. Fitzpatrick SG, Cohen DM, Clark AN. Ulcerated lesions of the oral mucosa: Clinical and histologic review. *Head Neck Pathol* 2019;13:91-102.
5. Uzun S. Erosive, ulcerative, vesicular and bullous lesions of oral mucosa. *Turkderm-Turk Arch Dermatol Venereol* 2012;46:77-85.
6. Scully C. Clinical practice. Aphthous ulceration. *N Engl J Med* 2006;355:165-72.
7. Bratel J, Hakeberg M. Anamnestic findings from patients with recurrent aphthous stomatitis. *Swed Dent J* 2014;38:143-9.
8. Ma R, Chen H, Zhou T, et al. Effect of bedtime on recurrent aphthous stomatitis in college students. *Oral Surg Oral Med Oral Pathol Oral Rad* 2015;119:196-201.
9. Wallace A, Rogers HJ, Hughes SC, et al. Management of recurrent aphthous stomatitis in children. *Oral Medicine* 2015;42:564-72.
10. Sakarya U, Gundogan O, Imre A, Arslan B, Pinar E. Rekurren aftoz stomatitli 112 hastanın demografik ve labaratuvar verileri: Retrospektif inceleme. *KBB-Forum* 2014;13:19-25.
11. Akintoye SO, Greenberg MS. Recurrent aphthous stomatitis. *Dent Clin North Am* 2014;58:281-97.
12. Tappuni AR, Kovacevic T, Shirlaw PJ, et al. Clinical assessment of disease severity in recurrent aphthous stomatitis. *J Oral Pathol Med* 2013;42:635-41.
13. Yasui K, Kurata T, Yashiro M, et al. The effect of ascorbate on minor recurrent aphthous stomatitis. *Acta Paediatrica* 2010;99:442-5.
14. Lodi G, Varoni E, Robledo-Sierra J, et al. Oral ulcerative lesions. In: *Contemporary Oral Medicine* (Farah C, Balasubramaniam R, McCullough M, eds.), Springer, 2017.
15. Shah K, Guarderas J, Krishnaswamy G. Aphthous stomatitis. *Ann Allergy Asthma Immunol* 2016;117:e341-3.
16. Topkarci Z. Current treatment options in challenging oral diseases: recurrent oral aphthosis. *Turkderm-Turk Arch Dermatol Venereol* 2012;46:123-9.
17. Slebioda Z, Szponar E, Kowalska A. Recurrent aphthous stomatitis: genetic aspects of etiology. *Postepy Dermatol Alergol* 2013;30:96-102.
18. Slebioda Z, Krawiecka E, Szponar E, et al. Haematinic deficiencies and patient clinical profiles in Polish patients with recurrent aphthous stomatitis (RAS). *J Oral Pathol Med* 2018;47:531-7.
19. Orbak R, Cicek Y, Tezel A, Dogru Y. Effects of zinc treatment in patients with recurrent aphthous stomatitis. *Dent Mater J* 2003;22:21-9.
20. Nolan A, McIntosh WB, Allam BF, Lamey PJ. Recurrent aphthous ulceration: vitamin B1, B2 and B6 status and response to replacement therapy. *J Oral Pathol Med* 1991;20:389-91.
21. Scully C, Grosky M, Nur FL. Aphthous ulcerations. *Dermatol Ther* 2002;15:185-205.
22. Tuzun B, Wolf R, Tuzun Y, Serdaroglu S. Recurrent

- aphthous stomatitis and smoking. *Int J Dermatol* 2000;39:358-60.
23. Rajendran K. Relation between smoking and recurrent aphthous stomatitis. *Oral Maxillofac Pathol J* 2016;7:761-2.
  24. Miziara ID, Auaujo-Filho BC, Weber R. AIDS and recurrent aphthous stomatitis. *Rev Bras Otorhinolaringol* 2005;71:517-20.
  25. Leao JC, Gueiros LA, Porter SR. Oral manifestations of syphilis. *Clinics* 2006;61:161-6.
  26. Alam F, Argiriadou AS, Hodgson TA, et al. Primary syphilis remains a cause of oral ulceration. *Br Dent J* 2000;189:352-4.
  27. de Andrade RS, de Freitas EM, Rocha BA, et al. Oral findings in secondary syphilis. *Med Oral Patol Oral Cir Bucal* 2018;23:138-43.
  28. Krawiecka E, Szponar E. Tuberculosis of the oral cavity: an uncommon but still a live issue. *Adv Dermatol Allergol* 2015;32:302-6.
  29. Whitley RJ, Kimberlin DW, Roizman B. Herpes simplex virus. *Clin Infect Dis* 1998;26:541-55.
  30. Clarkson E, Mashkoo F, Abdulateef S. Oral viral infections: diagnosis and management. *Dent Clin N Am* 2017;61:351-63.
  31. Kolokotronis A, Louloudiadis K, Fotiou G, et al. Oral manifestations of infections due to varicella zoster virus in otherwise healthy children. *J Clin Pediatr Dent*. 2001;25:107-12.
  32. Ueda T, Ogata H, Kojima Y, et al. Cytomegalovirus oral ulcers. *Infection* 2014;42:235.
  33. Reichart PA. Oral ulcerations in HIV infection. *Oral Dis* 1997;3:180-2.
  34. Ramirez-Amador V, Esquivel-Pedraza L, Sierra-Madero J, et al. The changing clinical spectrum of human immunodeficiency virus (HIV)-related oral lesions in 1000 consecutive patients: a 12-year study in a referral center in Mexico. *Medicine (Baltimore)* 2003;82:39.
  35. Alegre M, Dalmau J, Domingo P, et al. Successful treatment of major oral aphthous ulcers in HIV-1 infection after highly active antiretroviral therapy. *Int J Infect Dis* 2007;11:278.
  36. Dojcinov SD, Venkataraman G, Raffeld M, Pittaluga S, Jaffe ES. EBV positive mucocutaneous ulcer-a study of 26 cases associated with various sources of immunosuppression. *Am J Surg Pathol* 2010;34:405-17.
  37. Bunn B, van Heerden W. EBV-positive mucocutaneous ulcer of the oral cavity associated with HIV/AIDS. *Oral Surg Oral Med Oral Pathol Oral Radiol* 2015;120:725-32.
  38. Bugshan A, Farag AM, Desai B. Oral complications of systemic bacterial and fungal infections. *Atlas Oral Maxillofac Surg Clin North Am* 2017;25:209-20.
  39. Delgado W. Oral cryptococcosis. *JSM Trop Med Res* 2017;2:1015.
  40. Celentano A, Tovar S, Yap T, Adamo D, Aria M, Mignogna MD. Oral erythema multiforme: trends and clinical findings of a large retrospective European case series. *Oral Surg Oral Med. Oral Pathol Oral Radiol* 2015;120:707-16.
  41. Sokumbi O, Wetter DA. Clinical features, diagnosis, and treatment of erythema multiforme: a review for the practicing dermatologist. *Int J Dermatol* 2012;51:889.
  42. MEDSCAPE. Toxic Epidermal Necrolysis (TEN). 2018 Available at: <https://emedicine.medscape.com/article/229698-overview> (last accessed 20 March 2021).
  43. Ozkaya E. Oral mucosal fixed drug eruption: characteristics and differential diagnosis. *J Am Acad Dermatol* 2013;69:2:51-8.
  44. Shazib MA, Woo SB, Sroussi H, et al. Oral immune related adverse events associated with PD-1 inhibitor therapy: A case series. *Oral Dis* 2020;26:325.
  45. Chambers MS, Rugo HS, Litton JK, Meiller TF. Stomatitis associated with mammalian target of rapamycin inhibition: a review of pathogenesis, prevention, treatment, and clinical implications for oral practice in metastatic breast cancer. *J Am Dent Assoc* 2018;149:291-8.
  46. Lee MT, Lin HY, Lee SH, et al. Risk of skin ulcerations associated with oral nicorandil therapy: a population-based study. *Br J Dermatol* 2015;173:498.
  47. Black M, Mignogna MD, Scully C. Number II. Pemphigus vulgaris. *Oral Dis* 2005;11:119-30.
  48. Joly P, Litrowski N. Pemphigus group (vulgaris, vegetans, foliaceus, herpetiformis, brasiliensis). *Clin Dermatol* 2011;29:432-6.
  49. Wiczorek M, Czernik A. Paraneoplastic pemphigus: a short review. *Clin Cosmet Investig Dermatol* 2016;9:291-5.
  50. Amber KT, Murrell DF, Schmidt E, Joly P, Borradori L. Autoimmune subepidermal bullous diseases of

- the skin and mucosae: Clinical features, diagnosis, and management. *Clin Rev Allergy Immunol* 2018 ;54:26-51.
51. Di Zenzo G, DellaTorre R, Zambruno G, Borradori L. Bullous pemphigoid: from the clinic to the bench. *Clin Dermatol* 2012;30:3-16.
  52. Bagan J, Jimenez Y, Murillo J, Bagan L. Oral mucous membrane pemphigoid: a clinical study of 100 low-risk cases. *Oral Dis* 2018;24:132-4.
  53. Carey B, Setterfield J. Mucous membrane pemphigoid and oral blistering diseases. *Clin Exp Dermatol* 2019;44:732-9.
  54. Setterfield J. Clinicopathological associations in mucous membrane pemphigoid. MD thesis, University of London, 2009.
  55. Kridin K, Kneiber D, Kowalski EH, et al. Epidermolysis bullosa acquisita: a comprehensive review. *Autoimmun Rev* 2019;18:786-95.
  56. Chaudhari S, Mobini N. Linear IgA bullous dermatosis: a rare clinicopathologic entity with an unusual presentation. *J Clin Aesthet Dermatol* 2015;8:43-6.
  57. Munoz-Corcuera M, Esparza-Gomez G, Gonzalez-Moles MA, et al. Oral ulcers: clinical aspects. A tool for dermatologists. Part I. Acute ulcers. *Clin Exp Dermatol* 2009;34:289-94.
  58. Ellington TD, Henley SJ, Senkomago V, et al. Trends in incidence of cancers of the oral cavity and pharynx - United States 2007-2016. *MMWR Morb Mortal Wkly Rep* 2020;69:433.
  59. Kalavrezos N, Scully C. Mouth cancer for clinicians part 6: potentially malignant disorders. *Dent Update* 2015;42:866-8.
  60. Yazici Y, Yurdakul S, Yazici H. Behcet's Syndrome. *Curr Rheumatol Rep* 2010;12:429-35.
  61. Lavanya N, Jayanthi P, Rao UK, Ranganathan K. Oral lichen planus: an update on pathogenesis and treatment. *J Oral Maxillofac Pathol.* 2011;15:127-32.
  62. Muller S. Oral lichenoid lesions: distinguishing the benign from the deadly. *Mod Pathol* 2017;30:54-67.

# Investigation of serum and saliva dermcidin levels in patients with recurrent aphthous stomatitis and dermcidin analysis in salivary gland

## Rekürren aftöz stomatitli hastalarda serum ve tükürükte dermcidin düzeylerinin araştırılması ve tükürük bezinde dermcidin analizi

Betul Demir<sup>1</sup>, Demet Cicek<sup>1</sup>, Ilker Erden<sup>2</sup>, Suleyman Aydin<sup>3</sup>, Ozlem Ucer<sup>4</sup>, Tuncay Kuloglu<sup>5</sup>, Mehmet Kalayci<sup>6</sup>, Meltem Yardim<sup>7</sup>, Esmâ Inan Yuksel<sup>1</sup>

<sup>1</sup>Dept. of Dermatology, Firat University Hospital, Elazığ, Turkey, <sup>2</sup>Ozel Batman Dünya Hospital, Batman, Turkey, <sup>3</sup>Dept. of Biochemistry and Clinical Biochemistry, Firat University Hospital, Elazığ, Turkey, <sup>4</sup>Dept. of Pathology, Firat University Hospital, Elazığ, Turkey, <sup>5</sup>Dept. of Histology and Embryology, Firat University Hospital, Elazığ, Turkey, <sup>6</sup>Dept. of Biochemistry Laboratory, Fethi Sekin City Hospital, Elazığ, Turkey, <sup>7</sup>Dept. of Biochemistry Laboratory, Yerkoy Medical Hospital, Yozgat, Turkey

### Abstract

**Objective** Recurrent aphthous stomatitis (RAS) is a common self-limiting oral mucosa disease. In this study, it was aimed to determine the dermcidin level in the serum and saliva of patients with RAS, the presence of dermcidin in the salivary gland and its role in the pathogenesis of RAS.

**Methods** Thirty-one patients presenting with RAS and 30 control subjects participated in this study. Dermcidin levels in serum and saliva of patients and control group were studied in accordance with the working procedures specified in the catalogs of the human dermcidin ELISA kit. The presence of dermcidin in salivary glands was assessed by immunohistochemical analysis.

**Results** A statistically significant difference was found when the mean salivary dermcidin levels ( $105.80 \pm 80.14$  ng/mL) of the RAS patients were compared with the mean salivary dermcidin levels ( $456.13 \pm 354.59$  ng/mL) of the control group ( $P=0.000$ ). There was no statistically significant difference between the mean serum dermcidin levels ( $316.41 \pm 784.55$  ng/mL) of the RAS patient and those of ( $130.65 \pm 179.75$  ng/mL) the control group. Dermcidin immunoreactivity was observed in the parotid gland, submandibular gland and interlobular striated ducts.

**Conclusion** The findings in this study showed that striated cells in salivary gland synthesized dermcidin. Low levels of dermcidin with antimicrobial properties in saliva were considered as a predisposing factor for RAS.

**Key words:** dermcidin, recurrent aphthous stomatitis, salivary gland

**Corresponding author:** Betül Demir, Dept. of Dermatology, Firat University Hospital, Elazığ, Turkey, Phone: +90 507 3403504, E-mail: drbkaraca@yahoo.com

**Received:** 11 January 2021 **Accepted:** 20 March 2021

**Conflict of Interest:** None.

**Funding:** None

**How to cite this article:** Demir B, Cicek D, Erden I, et al. Investigation of serum and saliva dermcidin levels in patients with recurrent aphthous stomatitis and dermcidin analysis in salivary gland. Mucosa 2021;4:10-16



This work is licensed under a Creative Commons Attribution-NonCommercial 4.0 International License.

## Öz

**Amaç** Rekürren aftöz stomatit (RAS) dudak mukozası, yanak ve dilde, tekrarlayıcı, küçük, ağrılı, eritemli halesi bulunan, nekrotik ülserlerle karakterize, kendi kendini sınırlayabilen, sık görülen bir oral mukoza hastalığıdır. Bu çalışmada RAS'lı hastaların serum ve tükürüğünde dermcidin düzeyinin, tükürük bezinde dermcidin varlığının ve RAS patogenezindeki rolünün belirlenmesi amaçlandı.

**Yöntem** Bu çalışma 31 hasta ve 30 sağlıklı gönüllü ile yapıldı. Hasta ve kontrol grubunun serum ve tükürüğündeki dermcidin düzeyleri, insan dermcidin ELISA kitinin kataloglarında belirtilen çalışma prosedürlerine göre çalışıldı. Tükürük bezlerinde dermcidin varlığı immünohistokimyasal analiz ile değerlendirildi.

**Bulgular** RAS'lı hasta grubunun ortalama tükürük dermcidin düzeyleri ( $105.80 \pm 80.14$ ), kontrol grubunun ortalama tükürük dermcidin düzeyleri ( $456.13 \pm 354.59$ ) ile kıyaslandığında istatistiksel anlamlı farklılık tespit edildi ( $P=0.000$ ). RAS'lı hasta grubunda ortalama serum dermcidin düzeyleri ( $316.41 \pm 784.55$ ), kontrol grubunun ortalama serum dermcidin düzeyleri ( $130.65 \pm 179.75$ ) ile kıyaslandığında istatistiksel anlamlı farklılık tespit edilemedi. İmmünohistokimyasal boyamada parotis ve submandibular bezlerde, interlobular kanallarda dermcidin immünreaktivitesi gözlemlendi.

**Sonuç** Sonuç olarak bu çalışmada tükürük bezinin striated hücrelerinin dermcidin sentezlediği ortaya kondu. Tükürükte antimikrobial özellikli dermcidin azlığının RAS için predispozan bir faktör olduğu düşünüldü.

**Anahtar kelimeler:** dermcidin, rekürren aftöz stomatit, tükürük bezi

## Introduction

Recurrent aphthous stomatitis (RAS) is a common self-limiting oral mucosa disease characterized by necrotic ulcers. Many agents, such as genetic factors, food allergies, local trauma, vitamin and element deficiencies, endocrine factors, stress, smoking

cessation, chemical substances, viral and bacterial infections have been accused of its etiology.<sup>1,2</sup> The pathogenesis of RAS has been explained by the activation of proinflammatory cytokines leading to the damage of the oral mucosa under the influence of triggering factors on the basis of genetic susceptibility.<sup>2</sup> It is known that RAS is associated with microbial agents such as *Streptococcus sanguis* and inflammatory markers such as TNF- $\alpha$ .<sup>3</sup>

Dermcidin was discovered by Schitteck et al. in 2001. The peptide is released from the sweat glands as a precursor protein with a weight of 9.3 kD, cleaved by proteolytic enzymes and converted into small peptides with antimicrobial properties.<sup>4</sup> Some studies have indicated that the peptides derived from the dermcidin have antibacterial activity against *Staphylococcus aureus*, *Escherichia coli*, *Enterococcus faecalis*<sup>4</sup>, *Candida albicans*<sup>5</sup>, *Staphylococcus epidermidis*<sup>6</sup>, *Pseudomonas putida*, rifampicin- and isoniazid-resistant *Mycobacterium tuberculosis*<sup>7</sup> and *P. acnes*.<sup>8</sup> Also, it was detected that the concentration of dermcidin in the skin of patients with tinea pedis was low, which suggests that dermcidin may be mycostatic activity and may prevent fungal colonization.<sup>9</sup>

This study was planned because of the antimicrobial properties of the dermcidin molecule, and the presence of microbial agents in the etiology of RAS. It is notable that there is no research in the literature that investigating the serum and salivary dermcidin levels of RAS patients. To contribute to the relevant literature, in the present research, we aim to determine the level of dermcidin in the serum and saliva of patients, the presence of dermcidin in the salivary gland, and its role in the pathogenesis of RAS.

## Methods

Thirty-one patients presenting with RAS and 30 control subjects participated in this study. This study was approved by the ethics committee (30.09.2014, no:02) and conducted at a dermatology outpatient clinic. The patient group consisted of participants older than 18

years old who had clinically recurrent aphthous lesions in the oral mucosa and no other underlying disease. The control group consisted of individuals aged 18 years old or older who applied to the hospital for the annual check-up. Pregnancy, diabetes, hypertension, hyperthyroidism and hypothyroidism, malignancy, alcohol-drug abuse and any systemic drug treatment were considered as an exclusion criteria. Patients and control group were informed about the study and then they gave informed consent.

To obtain saliva, participants were allowed to spit for 1-2 minutes into the sterile urine culture containers after 5 minutes they thoroughly gargled their mouths. A stimulation test was not performed to obtain saliva. 1-2 mL of saliva was taken into urine culture containers that include the same amount of aprotinin. The samples in the eppendorf tubes were stored at  $-80^{\circ}\text{C}$ . 5 mL fasting blood sample from each participant was taken in the morning. Since dermcidin is a hormone in peptide structure, before receiving blood from the participants, 500 mL of kallikrein unite aprotinin for 1 mL was added to the tubes to prevent its disintegration by proteases. After receiving, blood samples were centrifuged, then they were transferred to the eppendorf tubes and stored in the deep freezer ( $-80^{\circ}\text{C}$ ) until the analysis.

#### **Immunohistochemical analysis of dermcidin in serum and saliva**

Dermcidin levels in serum and saliva of patients and control group were studied in accordance with the working procedures specified in the catalogs of the human dermcidin ELISA kit Sunred Bioscience (Catalog ID: 201-12-5460 Shanghai, CHINA). Intra-Assay CV value of the reagent was  $<10\%$ , while Inter-Assay CV value was  $<12\%$ . Plate washes were performed with an automatic washer Bio-Tek ELX50 instrument (BioTek Instruments, USA) and absorbance measurements were performed by ChroMate, Microplate Reader P4300 instrument (Awareness Technology Instruments, USA). Test results were reported as ng/mL. The reference range was considered as 1 ng/mL-300 ng/mL while sensitivity value was 0.903 ng/mL.

Immunohistochemical analysis of dermcidin in the salivary gland was performed with salivary gland tissue without any pathology (n:10), which was previously excised for any reason and sent to pathological examination. Immunohistochemical staining of the tissues was performed using the method of Hsu et al.<sup>10</sup> The amount of dermcidin in the tissue was measured by the ELISA method<sup>11</sup> after the saliva gland was grinded in the phosphate buffer. Anti-DCD/Dermcidin antibody (aa96-110) produced by LSBio (Life Span BioSciences, Inc.) (Catalog ID/Lot ID: LS-C128574/32734) was used for the measurement.

Sections with 5-6 mm in thickness taken from paraffin blocks were transferred into the slides with polylysine. The deparaffinized tissues were passed through graded alcohol series and boiled in the microwave (750W) for 7+5 minutes at pH:6 in citrate buffer solution for antigen retrieval. The tissues that were left to cool in the room temperature for about 20 minutes after boiling were incubated with hydrogen peroxide block solution for 5 minutes (Hydrogen Peroxide Block, TA-125-HP, Lab Vision Corporation, USA) to prevent endogenous peroxidase activity after washing for 3x5 minutes with PBS (Phosphate Buffered Saline, P4417, Sigma-Aldrich, USA). After Ultra V Block solution (TA-125-UB, Lab Vision Corporation, USA) was applied for 5 minutes to the tissues washed with PBS for 3x5 minutes to prevent floor paint, 1/200 of diluted primary antibody (Anti-DCD/Dermcidin Antibody, aa96-110, Life Span BioSciences, Inc., Seattle, USA) was incubated for 60 min in a humid environment at room temperature. The tissues were incubated at room temperature for 30 minutes in a humidified environment with a secondary antibody (biotinylated Goat Anti-Polyvalent (anti-mouse/rabbit IgG  $80^{\circ}\text{C}$ ), TP-125-BN, Lab Vision Corporation, USA) after washing with PBS for 3x5 minutes and application of the primer antibody. The tissues were washed with PBS for 3x5 minutes after the application of secondary antibody, and then, incubated with PBS (Streptavidin Peroxidase, TS-125-HR, Lab Vision Corporation, USA) for 30 minutes at room temperature in humidified atmosphere and finally transferred to the PBS. After

the solution of 3-amino-9-ethylcarbazole (AEC) Substrate+AEC Chromogen (AEC Substrate, TA-015 and HAS, AEC Chromogen, TA-002-HAC, Lab Vision Corporation, USA) were added to the tissues. The vision signal was taken on the light microscope, the tissues were simultaneously washed with PBS. Mayer's hematoxylin-counterstained tissues were covered with the appropriate closure solution (Large Volume Vision Mount, TA-125-UG, Lab Vision Corporation, USA) after the applications of PBS and distilled water. Preparations were photographed by examining on a Leica DM500 microscope (Leica DFC29580°C).

### Statistical analysis

SPSS version 22.0 was used for statistical analysis. The

values obtained in the study were given as mean  $\pm$  SD. Student t-test and Mann-Whitney-U test were applied for inter-group comparisons.  $P < 0.05$  were considered statistically significant.

### Results

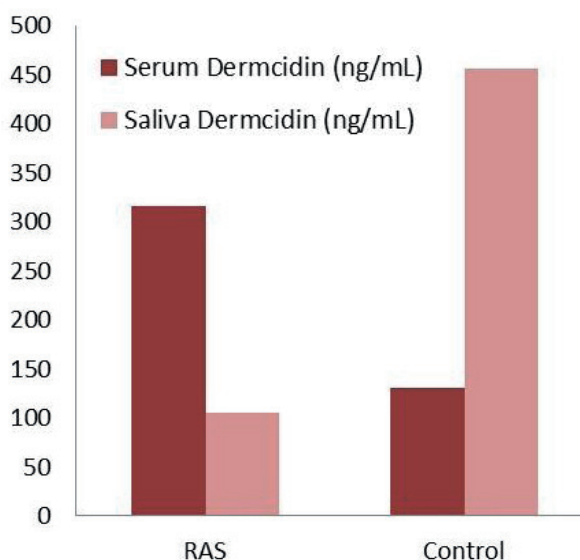
A total of 61 participants consisting of 28 (45.9%) female and 33 (54.1%) male were included in the present study. A total of 31 patients consisting of 15 (48.4%) female and 16 (51.6%) male were enrolled in the patient group, while there were 30 volunteers as 13 (43.3%) female and 17 (56.7%) male in the control group. Patients were in the age range between 21-55 years, with a mean age of  $34.22 \pm 9.00$  and the age range was between 18-48 years and mean age was

**Table 1.** Demographic and laboratory characteristics of the patient and the control group

Parameters	RAS	Control	P
<b>n</b>	31	30	
<b>Gender (M/F)</b>	16/15	17/13	$P > 0.05$
<b>Age* (year)</b>	$34.22 \pm 9.00$	$34.80 \pm 8.00$	$P > 0.05$
<b>Serum Dermcidin (ng/mL)</b>	$316.41 \pm 784.55$	$130.65 \pm 179.75$	$P > 0.05$
<b>Saliva Dermcidin (ng/mL)</b>	$105.80 \pm 80.14$	$456.13 \pm 354.59$	$P = 0.000$

\*(Mean  $\pm$  SD)

RAS, Recurrent aphthous stomatitis



**Fig. 1.** Serum and saliva dermcidin levels of the patients and control groups

$34.80 \pm 8.00$  in the control group (Table 1).

A statistically significant difference was found when the mean salivary dermcidin levels ( $105.80 \pm 80.14$  ng/mL) of the RAS patients were compared with the mean salivary dermcidin levels ( $456.13 \pm 354.59$  ng/mL) of the control group ( $P = 0.000$ ). There was no statistically significant difference between the mean serum dermcidin levels ( $316.41 \pm 784.55$  ng/mL) of the RAS patient and those of ( $130.65 \pm 179.75$  ng/mL) the control group. (Table 1) (Fig. 1).

Although serum dermcidin levels were higher in women with RAS ( $489.59 \pm 1068.63$  ng/mL) than men with RAS ( $154.05 \pm 327.23$  ng/mL), the difference was not statistically significant. Similarly, although the salivary dermcidin levels in patients were higher



in female patients ( $120.77 \pm 112.42$  ng/mL) than male patients ( $91.77 \pm 24.81$  ng/mL), the difference was not statistically significant. Also, for the control group serum and saliva dermcidin levels were higher in females than males but these differences were not statistically significant. In addition, a significant correlation was not found out between serum and salivary dermcidin levels.

Parotid (Fig. 2a) and submandibular glands (Fig. 2b) were used to investigate dermcidin immunoreactivity. Dermcidin immunoreactivity was observed in the parotid gland (Fig. 2c) and submandibular gland (Fig. 2d) and interlobular ducts.

## Discussion

In this study, to our knowledge, dermcidin concentrations in saliva of patients were determined for the first time. Also, in this study, salivary glands contribute to dermcidin levels are investigated. In addition, an immunohistochemical scanning of dermcidin was performed on the salivary glands to detect the source of the dermcidin in the saliva. Our findings showed that there was immunoreactivity of dermcidin in striated portions of submandibular and parotid salivary glands.

Saliva has many functions, including moisturizing,

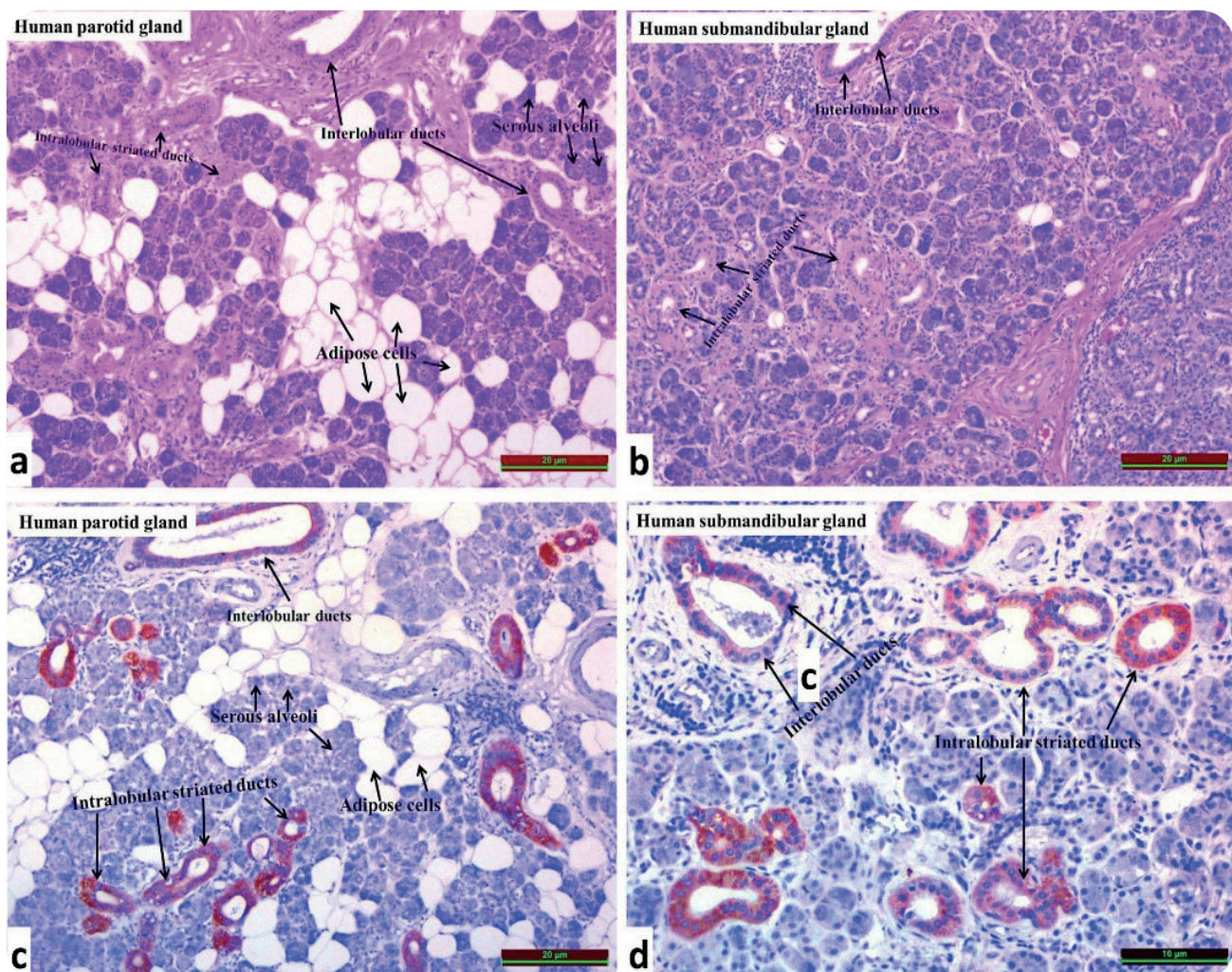


Fig. 2. Parotid (2a.) and submandibular (2b.) glands, dermcidin immunoreactivity in parotid (2c.), and submandibular glands (2d.) and interlobular ducts

lubrication and cleaning of the oral cavity, helping digestion and talking, contributing to dental health, antimicrobial and immunological properties.<sup>12</sup> Many salivary proteins and antimicrobial peptides contribute for the defense system of saliva.<sup>13</sup> Antimicrobial peptides form a natural antibiotic layer on the surface of the oral mucosa as a strong member of the innate immune response and activate the acquired immunity against pathological conditions.<sup>14</sup> Antimicrobial peptides detected in saliva are  $\alpha$  and  $\beta$ -defensins, histatins, LL-37 and cathelicidin.<sup>15</sup> Previous proteomic studies have also reported the presence of dermcidin in the saliva; however, it was not detected which cells of the salivary gland synthesize dermcidin.<sup>16,17</sup> Therefore, to our knowledge, this is the first study that showed which cells of the salivary glands synthesized dermcidin.

In a previous study, peptides deriving from dermcidin could not be detected in body fluids, such as nasal secretion, tears and saliva<sup>18</sup>, while the analysis of dermcidin was performed in cervicovaginal fluid<sup>19</sup> and tear<sup>20</sup> in some other studies. It has been thought that dermcidin is not a peptide with a high concentration in body fluids.<sup>21</sup> In this study, it was shown that the mean dermcidin level of 456 ng/mL (0.456  $\mu$ g/mL) in the saliva of healthy controls.

The antimicrobial action mechanism of dermcidin in saliva is unknown. However, relevant studies reported that the peptides derived from dermcidin exhibit antimicrobial effect without permeabilization to microbial membranes.<sup>5,22</sup> It has been shown that dermcidin may contribute to cutaneous immunity by releasing various cytokines, such as TNF- $\alpha$ , interleukin-8 with activating keratinocytes. Dermcidin was unaffected by salt, pH, and inflammatory media.<sup>22</sup> and was at an excessively stable level.<sup>21</sup>

In this study, salivary dermcidin levels in patients decreased. In the light of this information and results obtained in this research, it was detected that patients were sensitive to microbial agents on the basis of genetic susceptibility and considering the fact that

antimicrobial dermcidin was also capable of triggering inflammation. Thus, the findings suggest that low dermcidin levels in the saliva result in a predisposition to infections and contribute to the development of aphthae.

In this study, how the level of antimicrobial dermcidin in saliva changes as well as the relationship between its salivary level, and its serum level were investigated in patients. The dermcidin synthesized from the salivary gland appears to be transferred to both the saliva and the serum. Since salivary dermcidin levels in controls were higher than its serum levels, the findings suggest that the main source of dermcidin in serum was salivary gland and this condition could be contribute to the serum level of dermcidin synthesized in the salivary gland. However, it is notable that that salivary and serum dermcidin levels of the patients were not parallel, and there was not a significant difference between patients and the control group regarding serum dermcidin levels. This finding suggests that salivary dermcidin rather than serum may be a candidate biomarker of the disease in patients.

The findings in this study showed that striated cells in salivary gland synthesized dermcidin. Low levels of dermcidin with antimicrobial properties in saliva were considered as a predisposing factor for RAS. In light of insightful findings, this study sheds light on novel treatment methods.

**Acknowledgments:** Thanks to the NOVA translation company for language translation.

**Ethics committee approval:**

Local Ethics Committee approval was obtained (30.09.2014, no:02)

**Informed consents:** They were obtained.

**Peer-review:** Externally peer-reviewed.

**Authorship contributions:**

Conception and design, or analysis and interpretation of data: BD, DC, IE, SA, OU, TK, MK, MY

Drafting the manuscript or revising the content: BD, DC, EIY

Final approval of the version to be published: BD, DC

## References

1. Belenguer-Guallar I, Jimenez-Soriano Y, Claramunt-Lozano A. Treatment of recurrent aphthous stomatitis. A literature review. *J Clin Exp Dent* 2014;6:168-74.
2. Slebioda Z, Szponar E, Kowalska A. Etiopathogenesis of recurrent aphthous stomatitis and the role of immunologic aspects: literature review. *Arch Immunol Ther Exp (Warsz)* 2014;62:205-15.
3. Chavan M, Jain H, Diwan N, Khedkar S, Shete A, Durkar S. Recurrent aphthous stomatitis: a review. *J Oral Pathol Med* 2012;41:577-83.
4. Schitteck B, Hipfel R, Sauer B, et al. Dermcidin: a novel human antibiotic peptide secreted by sweat glands. *Nat Immunol* 2001;2:1133-7.
5. Mehra T, Koberle M, Braunsdorf C, Mailander-Sanchez D, Borelli C, Schaller M. Alternative approaches to antifungal therapies. *Exp Dermatol* 2012;21:778-82.
6. Vuong C, Voyich JM, Fischer ER, et al. Polysaccharide intercellular adhesin (PIA) protects *Staphylococcus epidermidis* against major components of the human innate immune system. *Cell Microbiol* 2004;6:269-75.
7. Lai YP, Peng YF, Zuo Y, et al. Functional and structural characterization of recombinant dermcidin-1L, a human antimicrobial peptide. *Biochem Biophys Res Commun* 2005;328:243-50.
8. Nakano T, Yoshino T, Fujimura T, et al. Reduced expression of dermcidin, a peptide active against propionibacterium acnes, in sweat of patients with acne vulgaris. *Acta Derm Venereol* 2015;95:783-6.
9. Arai S, Yoshino T, Fujimura T, et al. Mycostatic effect of recombinant dermcidin against *Trichophyton rubrum* and reduced dermcidin expression in the sweat of tinea pedis patients. *J Dermatol* 2015;42:70-6.
10. Hsu SM, Raine L, Fanger H. Use of avidin-biotin-peroxidase complex (ABC) in immunoperoxidase techniques: a comparison between ABC and unlabeled antibody (PAP) procedures. *J Histochem Cytochem* 1981;29:577-80.
11. Aydin S. A short history, principles, and types of ELISA, and our laboratory experience with peptide/protein analyses using ELISA. *Peptides* 2015;72:4-15.
12. Holmberg KV, Hoffman MP. Anatomy, biogenesis and regeneration of salivary glands. *Monogr Oral Sci* 2014;24:1-13.
13. Dawes C, Pedersen AM, Villa A, et al. The functions of human saliva: a review sponsored by the World Workshop on Oral Medicine VI. *Arch Oral Biol* 2015;60:863-74.
14. van't Hof W, Veerman EC, Nieuw Amerongen AV, Ligtenberg AJ. Antimicrobial defense systems in saliva. *Monogr Oral Sci* 2014;24:40-51.
15. Dale BA, Tao R, Kimball JR, Jurevic RJ. Oral antimicrobial peptides and biological control of caries. *BMC Oral Health* 2006;6:13.
16. Denny P, Hagen FK, Hardt M, et al. The proteomes of human parotid and submandibular/sublingual gland salivas collected as the ductal secretions. *J Proteome Res* 2008;7:1994-2006.
17. Preza D, Thiede B, Olsen I, Grinde B. The proteome of the human parotid gland secretion in elderly with and without root caries. *Acta Odontol Scand* 2009;67:161-9.
18. Rieg S, Seeber S, Steffen H, et al. Generation of multiple stable dermcidin-derived antimicrobial peptides in sweat of different body sites. *J Invest Dermatol* 2006;126:354-65.
19. Shaw JL, Smith CR, Diamandis EP. Proteomic analysis of human cervico-vaginal fluid. *J Proteome Res* 2007;6:2859-65.
20. You J, Fitzgerald A, Cozzi PJ, et al. Post-translation modification of proteins in tears. *Electrophoresis* 2010;31:1853-61.
21. Schitteck B. The multiple facets of dermcidin in cell survival and host defense. *J Innate Immun* 2012;4:349-60.
22. Wiesner J, Vilcinskis A. Antimicrobial peptides: the ancient arm of the human immune system. *Virulence* 2010;1:440-64.

# Oral lichen planus and oral lichenoid reactions: a retrospective evaluation of patch test results with dental series

## Oral liken planus ve oral likenoid reaksiyonlar: Dental seri yama testi sonuçlarının retrospektif olarak değerlendirilmesi

Burcu Aydemir<sup>1</sup>, Leyla Baykal Selcuk<sup>1</sup>, Deniz Aksu Arica<sup>1</sup>, Ali Osman Metintas<sup>1</sup>

<sup>1</sup>Dept. of Dermatology, Karadeniz Technical University Faculty of Medicine, Trabzon, Turkey

### Abstract

**Objective** Oral lichen planus (OLP) and oral lichenoid reactions (OLR) may occur secondary to dental procedures. Patch testing with the dental series is a simple diagnostic method that can guide the identification of the relevant allergen. In this study, it was aimed to evaluate the patch test results with dental series in OLP and OLR patients.

**Methods** A retrospective review of the medical records of patients who were clinically and/or histopathologically diagnosed with OLP or OLR and, who underwent dental series patch testing at our dermatology clinic in between January 2015 and January 2021 was performed.

**Results** In total, 36 patients with a diagnosis of OLP (n=14, 38.9%) or OLR (n=22, 61.1%) were included, 15 of whom (41.7%) had positive patch test results. The mean age at presentation was 54.6 years (range 28-72 years). The duration of the disease was 21.9 (range 1-144 months) months on average. Positive findings on patch tests were approximately three times higher in OLR patients than in OLP patients. Gold(I) sodium thiosulfate dihydrate was the most frequent positive reaction (n=6) detected against. Habits (smoking, alcohol) and comorbidities were not significantly associated with the patch test results.

**Conclusion** Detection of allergens with patch test is a helpful diagnostic method for effective control of the disease in both OLP and OLL patients. We think that the detection of contact allergies with patch testing may guide decisions regarding related changes such as dental restorations.

**Key words:** dental series, oral lichen planus, oral lichenoid reactions, patch test

### Öz

**Amaç** Oral liken planus (OLP) ve oral likenoid reaksiyonlar (OLR) dental işlemlere ikincil ortaya çıkabilir. Dental seri yama testi, ilgili alerjenin belirlenmesine rehberlik edebilecek basit bir tanı yöntemidir. Bu çalışmada OLP ve

**Corresponding author:** Burcu Aydemir, Dept. of Dermatology, Karadeniz Technical University Faculty of Medicine, Trabzon, Turkey, Phone: +90 553 8520267, E-mail: burcaydemr@gmail.com

**Received:** 22 March 2021 **Accepted:** 30 March 2021

**Conflicts of Interest:** None

**Funding:** None

**How to cite this article:** Aydemir B, Baykal Selcuk L, Aksu Arica D, Metintas AO. Oral lichen planus and oral lichenoid reactions: a retrospective evaluation of patch test results with dental series. Mucosa 2021;4:17-22



This work is licensed under a Creative Commons Attribution-NonCommercial 4.0 International License.

OLR hastalarında dental seri yama testi sonuçlarının değerlendirilmesi amaçlanmıştır.

**Yöntem** Klinik ve/veya histopatolojik olarak OLP veya OLR tanısı almış ve Ocak 2015 ile Ocak 2021 arasında dermatoloji kliniğimizde dental seri yama testi yapılan hastaların tıbbi kayıtlarının retrospektif bir incelemesi yapıldı.

**Bulgular** Toplamda, OLP (n=14, %38.9) veya OLR (n=22, %61.1) tanısı alan 36 hasta dahil edildi, bunların 15'inde (% 41.7) yama testi pozitif. Başvuru anındaki ortalama yaş 54.6 yıldır (28-72 yaş aralığı). Hastalık süresi ortalama 21.9 aydır (1-144 ay aralığı). Yama testlerindeki pozitif bulgular, OLR hastalarında OLP hastalarına göre yaklaşık üç kat daha yüksekti. En sık pozitif reaksiyon (n = 6) altın (I) sodyum tiyosülfat dihidrata karşı tespit edildi. Alışkanlıklar (sigara, alkol) ve komorbiditeler, yama testi sonuçlarıyla önemli ölçüde ilişkili değildi.

**Sonuç** Yama testi ile temas alerjilerinin tespitinin, diş restorasyonları gibi ilişkili değişikliklere yönelik kararlara rehberlik edebileceğini düşünüyoruz.

**Key words:** dental seri, oral liken planus, oral likenoid reaksiyon, yama testi

## Introduction

Lichen planus is a chronic inflammatory mucocutaneous disease, which most commonly affects the skin, genitalia and oral mucous membranes.<sup>1</sup> Oral lichen planus (OLP) is a common variant of lichen planus. Although there is no comprehensive epidemiological study of OLP prevalence, recent review articles have shown prevalences ranging from 0.5% to 4%.<sup>2-4</sup> OLP most commonly occurs in middle-aged adults, and women are more frequently affected than men.<sup>5</sup>

The most common theory for the pathogenesis of OLP is that an immune reaction against an exogenous or endogenous antigen triggers the onset of the disease. Although the etiology is unknown; various factors such as genetic background, dental materials, drugs, infectious agents - bacterial and viral

infections, autoimmune diseases, immunodeficiency, food allergies, stress, habits, trauma, diabetes and hypertension, malignant neoplasms, and bowel disease have been proposed.<sup>6</sup>

The buccal mucosa, tongue and gingiva are commonly affected by OLP. It presents as symmetrical or multiple lesions. There are six variants such as reticular, papular, plaque-like, erosive, atrophic and bullous types.<sup>7</sup> Patients may complain about pain, a burning sensation or swelling. It may be concomitant with cutaneous and genital lichen planus.<sup>8</sup>

Lichenoid changes which occur in the oral mucosa as a result of dental restorations, drugs, systemic diseases and allergies to food or flavouring are referred as oral lichenoid reactions (OLR).<sup>9</sup> OLR is rare and most commonly associated with dental amalgam, the most widely used filling material in the world.<sup>2</sup> OLR is a type IV or delayed hypersensitivity reaction. Lesions caused by hypersensitivity to amalgam or its constituents resemble those of OLP. The lesions can be asymptomatic, or when ulcerated, painful; especially when eating hot, salty, spicy foods. Unlike lichen planus, which usually has a symmetrical distribution in the mouth, the OLR can typically be unilateral and asymmetrical depending on the location of the dental materials.<sup>10</sup>

These clinical features and the epicutaneous patch test for dental materials are helpful diagnostic methods in distinguishing OLP and OLR. It can still be difficult for the clinician to make a clear distinction if dental restorations are widespread in the mouth. Both OLP and OLR secondary to dental restorations can be painful.<sup>7</sup> The results have the potential to guide patients and physicians in making the decision to change dental restorations. Elimination of the allergen in OLR may result in clinical improvement and therefore it is important to distinguish the two conditions.<sup>11</sup>

In this retrospective study, we aimed to evaluate the patch test results with dental series in the patients with OLP or OLR in order to specify the association of the clinical findings and the patch test results.

## Methods

This study was approved by the Institutional Ethics (Date:15.03.2021, number:2021/77). We retrospectively evaluated patients who were clinically or histopathologically diagnosed with OLP or OLR with a patch test result of dental series performed between January 2015 and January 2021 at the Department of Dermatology, Faculty of Medicine in Karadeniz Technical University. Demographic characteristics (gender, age, etc.), disease-related characteristics (duration, subtype, clinical features), habits (smoking, alcohol), comorbidities (hyperlipidemia, Hepatitis B and C infection, cardiovascular disease, neuropsychiatric disease, autoimmune disease), history of dental procedures were noted from the patients records. In patients with oral lichen planus who had concomitant cutaneous or genital lichen planus, these involvements were also recorded.

All patients were patch-tested using European dental screening (DS-1000) serial. By using standard methods, 35 antigens were placed on the back of the patients, and fixed by using Finn chambers and taped. Evaluations were performed approximately 48 and 96 hours after the application of antigens. In the evaluation, if an erythematous and/or palpable, but not vesicular reaction were seen, it is pointed as "1+". Two points for edematous or vesicular reactions, and 3+ points for dissemination, bullous or ulcerative reactions were given.

In statistical analysis, descriptives were expressed as mean  $\pm$  standard deviation (SD) for continuous variables and as percentages (%) for categorical variables.

## Results

Patch tests were performed in 36 patients diagnosed with OLP or OLL. In 14 (38.9%) of these patients, the diagnosis of OLP was clinically or histologically confirmed. Table 1 summarizes the demographics, comorbidities, disease duration, results of patch test, clinical morphology, history of dental procedure in the 36 patients diagnosed with OLL or OLP.

Within this retrospective cohort, there were 33 females and 3 male. The mean age at presentation was  $54.60 \pm 12.30$  years (range 28-72 years). The duration of the disease ranged from 1 to 144 months ( $21.90 \pm 31.52$  months). Four (18.1%) of the 22 patients were smokers. The predominant type of the clinical morphologic lesions was non-erosive type including mostly reticular lesions (n=21, 58.3%). The most common comorbidities were detected as hyperlipidemia and neuropsychiatric diseases (n=8, 22.2%). Others, in order of frequency, included cardiovascular diseases (n=5, 13.9%), autoimmune disease (n=5, 13.9%) and hepatitis B infection (n=1, 2.7%). None of the patients had hepatitis C infection. Seventy-five per cent of the patients (n=27) had a history of dental procedures before the lesions started. In most of these patients, the region of the dental procedure and lesions were compatible (n=25, 69.4%). In addition, of the 14 patients with OLP, four (28.6%) had concomitant cutaneous lichen planus and one (7.1%) had concomitant genital lichen planus.

Of the 36 patients, 15 (41.7%) had positive findings according to the results of dental patch test readings. In this group, only four (26.6%) of the patients with positive results were diagnosed as OLP. When compared proportionally, positive findings on patch tests were nearly three times greater in patients with OLR.

Eight (53.3%) of the patients with positive results had a positive reaction to more than one substance in the patch test. The most frequent detected positive reaction (n=6) against was gold(I) sodium thiosulfate dihydrate. It was one of the most common substances with positive reactions in patients with OLP. The others were cobalt(II)chloride hexahydrate and copper(II) sulfate pentahydrate.

Regarding the patients with OLL, the most frequent positive reaction was detected against to gold(I)sodium thiosulfate dihydrate. Other allergens that were detected included cobalt(II)chloride hexahydrate, nickel(II)sulfate hexahydrate, eugenol, copper(II)sul-

**Table 1.** Demographic and clinical features of the patients with oral lichenoid reactions and oral lichen planus

Demographic and clinical features	n (%)
Age (mean ± SD)	54.60 ± 12.30
Sex (female/male)	33/3
<b>Diagnosis</b>	
OLR*	22 (61.1)
OLP**	14 (38.9)
<b>Smoker</b>	4 (18.1)
<b>Alcohol consumption</b>	0 (0.0)
<b>Comorbidities</b>	
Hepatitis B	1 (2.7)
Hepatitis C	0 (0.0)
Hyperlipidemia	8 (22.2)
Cardiovascular disease	5 (13.9)
Neuropsychiatric disease	8 (22.2)
Autoimmune disease	5 (13.9)
<b>Disease duration, (mean ± SD), months</b>	21.90 ± 31.52
<b>Patch test positivity</b>	
N,N-dimethyl-4-toluidine	1 (2.7)
Potassium dichromate	1 (2.7)
Mercury	2 (5.5)
Cobalt (II) chloride hexahydrate <sup>1</sup>	4 (11.1)
Gold (I) sodium thiosulfate dihydrate	6 (16.6)
Nickel (II) sulfate hexahydrate <sup>1</sup>	3 (8.3)
Eugenol	3 (8.3)
Formaldehyde	1 (2.7)
Copper(II)sulfate pentahydrate	3 (8.3)
Methylhydroquinone	1 (2.7)
Palladium(II)chloride	1 (2.7)
Dimethylaminoethyl methacrylate	1 (2.7)
Drometizole	1 (2.7)
Sodium tetrachloropalladate(II) hydrate	2 (5.5)
Glutaral	1 (2.7)
Negative	21 (58.3)
<b>Clinical morphology</b>	
Erosive	15 (41.7)
Non-erosive	21 (58.3)
<b>Dental procedure history</b>	27 (75.0)
<b>Dental procedure and localization compliance</b>	25 (69.4)

\*OLR, oral lichenoid reaction; \*\*OLP, oral lichen planus

fate pentahydrate, copper(II)sulfate pentahydrate, mercury, sodium tetrachloropalladate(II) hydrate, n, n-dimethyl-4-toluidine, potassium dichromate, formaldehyde, methylhydroquinone, palladium(II) chloride, dimethylaminoethyl methacrylate, drometizole and glutaral.

When we examine the positive results in detail, the number of patients with positive reactions against to sodium tetrachloropalladate (II) hydrate and cobalt (II) chloride hexahydrate was similar in both groups. Patients with a positive reaction against to copper (II) sulfate pentahydrate were twice as much in the OLP group compared to the other. The number of patients with a positive reaction against to gold (I) sodium thiosulfate dihydrate was twice as high in the OLR group compared to OLP. All of the patients with positive reactions to other allergens were in the OLR group.

## Discussion

Oral lichen planus is a variant of lichen planus that affects the oral mucosa. The diagnosis of OLP is usually made by clinical and histological examination, but when classical lesions are seen, clinical appearance is often sufficient. There are many oral lichenoid lesions, especially OLR, which can be confused with OLP in the differential diagnosis. Besides systemic medications, dental restorative materials such as amalgam, gold and nickel may also be associated with OLR, and the patch tests with dental series contribute the etiology.<sup>12</sup>

The rate of positive patch test results of dental series in OLP or OLR ranges from 14% to 70%.<sup>10,13</sup> The rate we found (41.7%) is in this wide range. In our study, gold(I)sodium thiosulfate dihydrate was the most frequent allergen in both groups. In the study of Tiwari et al., a total of 68 patients with a diagnosis of OLP were evaluated, and 39 (79%) of the patients had positive findings in the patch test. Gold (48%) were the most common allergens that patients tested positive. Other common allergens were mercury, nickel, copper, potassium dichromate, and methylhydroquinone.<sup>14</sup> Koch et al. evaluated the frequency of sensitivity to

metal salts in 194 patients (OLR patients partially adjacent to amalgam fillings, OLP not in close contact with amalgam, other oral diseases, mouth complaints, control group) The frequency of sensitivity to inorganic mercury, gold sodium thiosulfate and palladium chloride was found to be high in all groups.<sup>15</sup>

Previous studies have not shown a clear relationship between comorbidities and patch test results in patients with OLP or OLR. While OLP was associated with hepatitis C, hepatitis C was not detected in any patients in both groups of our study.

In the study of Şahin et al., thirty-three patients diagnosed with OLP or OLL were evaluated. In patients with a positive patch test result, the non-erosive type was the most common clinical morphology.<sup>12</sup> In our study, patch test positivity was more frequent in the non-erosive type than in the erosive forms.

Additionally, in OLP patients, 75% of those with a positive patch test had no prior history of dental procedures. Most of the OLR patients (%91.6) had a history of dental procedures before the lesions. This result supports a contact dermatitis in OLR patients caused by contact with dental materials. The positive reactions obtained in the patch test support that OLR develops as a result of the hypersensitivity reaction, but for a definite relationship, it is necessary to show that the lesions regress after removing the relevant dental material.<sup>16</sup>

The limitations of the study include the small number of the patients, and the lack of histologically confirmed diagnosis in all OLP patients.

Both OLP and OLR may occur secondary to dental procedures, and lesions may be painful. It is an important cause of morbidity and lesions may also carry a risk of malignant transformation into squamous cell carcinomas.<sup>7</sup> Identifying and removing relevant materials is important in preventing this morbidity.

In conclusion, we suggest that the detection of allergens with patch test will contribute the etiology of the disease, and help the effective control of the disease in both OLP and OLL patients.

**Ethics Committee approval:**

(Date:15.03.2021, number:2021/77)

**Informed consent:** They are obtained.

**Peer-review:** Externally peer-reviewed

**Authorship contributions:**

Conception and design, or analysis and interpretation of data: BA, LBS, DAA, AOM

Drafting the manuscript or revising the content: BA, LBS, DAA, AOM

Final approval of the version to be published: BA, LBS, DAA

## References

1. McCartan BE, Healy CM. The reported prevalence of oral lichen planus: a review and critique. *J Oral Pathol Med* 2008;37:447-53.
2. Al-Hashimi I, Schifter M, Lockhart P, et al. Oral lichen planus and oral lichenoid lesions: diagnostic and therapeutic considerations. *Oral Surg Oral Med Oral Pathol Oral Radiol Endod* 2007;103:1-12.
3. Lodi G, Scully C, Carrozzo M, et al. Current controversies in oral lichen planus: report of an international consensus meeting. Part 2. Clinical management and malignant transformation. *Oral Surg Oral Med Oral Pathol Oral Radiol Endod* 2005;100:164-78.
4. Scully C, Beyli M, Ferreiro M, et al. Update on oral lichen planus; etiopathogenesis and management. *Crit Rev Oral Biol Med* 1998;9:86-122.
5. Eisen D. The clinical features, malignant potential, and systemic associations of oral lichen planus: a study of 723 patients. *J Am Acad Dermatol* 2002;46:207-14.
6. Roopashree MR, Gondhalekar RV, Shashikanth MC, George J, Thippeswamy SH, Shukla A. Pathogenesis of oral lichen planus a review. *J Oral Pathol Med* 2010;39:729-34.
7. Ismail SB, Kumar SKS, Zain RB. Oral lichen planus and Lichenoid reactions; etiopathogenesis, diagnosis, management and malignant transformation. *J Oral Sci* 2007;49:89-106.
8. Eisen D. The clinical manifestations and treatment of oral lichen planus. *Dermatol Clin* 2003;21:79-89.
9. Dudhia BB, Dudhia SB, Patel BS, et al. Oral lichen planus to oral lichenoid lesions: evolution or revolution. *J. Oral Maxillofac. Pathol* 2015;19:364-70.
10. Thornhill MH, Pemberton MW, Simmons RK,



- Theaker ED. Amalgam contact hypersensitivity lesions and oral lichen planus. *Oral Surg Oral Med Oral Path* 2003;95:291-9.
11. Laine J, Kalimo K, Happonen RP. Contact allergy to dental restorative materials in patients with oral lichenoid lesions. *Contact Dermatitis* 1997;36:141-6.
  12. Sahin EB, Cetinozman F, Avcu N, Karaduman A. Evaluation of patients with oral lichenoid lesions by dental patch testing and results of removal of the dental restoration material. *Turkderm* 2016;50:150-6.
  13. Raap U, Stiesch M, Reh H, et al. Investigation of contact allergy to dental metals in 206 patients. *Contact Dermatitis* 2009; 60:339-43.
  14. Tiwari SM, Gebauer K, Frydrych AM, Burrows S. Dental patch testing in patients with undifferentiated oral lichen planus. *Australas J Dermatol* 2018;59:188-93.
  15. Koch P, Bahmer FA. Oral lesions and symptoms related to metals used in dental restorations: a clinical, allergological, and histologic study. *J Am Acad Dermatol* 1999;41:422-30.
  16. Magnusson B, Blohm SG, Fregert S, et al. Routine patch testing. IV. Supplementary series of test substances for Scandinavian countries. *Acta Derm Venereol* 1968;48:110-4.

# Parotitis in a pemphigus vulgaris patient with widespread oral lesions: a rare or underdiagnosed condition?

## Yaygın oral lezyonları olan bir pemfigus vulgaris hastasında parotit gelişmesi: nadir ya da gözden kaçan bir durum?

Zuleyha Ozgen<sup>1</sup>, Elif Comert Ozer<sup>1</sup>, Dilek Seckin Gencosmanoglu<sup>1</sup>

<sup>1</sup>Dept of Dermatology, Marmara University School of Medicine, Istanbul, Turkey

### Abstract

Parotitis is the inflammation of the parotid gland and frequently due to bacterial and viral infections, but mechanical obstruction of parotitis ductus, Sjogren's disease, other xerostomia etiologies, sarcoidosis, tuberculosis, oral ulcerations, and drugs can also cause parotitis though less frequently. Pemphigus vulgaris patients may theoretically be at an increased risk for parotitis and other salivary gland inflammations because of various reasons such as oral ulcers, poor oral intake, multiple drug use and other possible accompanying autoimmune diseases, however, such an association is reported rarely in literature. In this study, development of parotitis in a pemphigus vulgaris patient with widespread oral ulcers is presented and a possible association between parotitis and pemphigus is discussed.

**Key words:** parotitis, sialadenitis, pemphigus vulgaris, oral ulcer

### Öz

Parotit, parotis bezinin iltihaplanması olup, sıklıkla bakteriyel ve viral enfeksiyonlar nedeniyle, daha nadir olarak da parotis kanalının mekanik tıkanması, oral alımın bozulması, Sjögren hastalığı, diğer ağız kuruluğu nedenleri, sarkoidoz, tüberküloz, ağız içinde ülser gelişimi ve bazı ilaçlar ile gelişebilmektedir. Pemfigus vulgaris hastalarının ağız içi ülserleri, oral alımlarında bozulma, kullandıkları çoklu ilaçlar ve eşlik edebilecek diğer otoimmün hastalıklar gibi çeşitli nedenlerle parotit ve diğer tükürük bezi iltihaplanmaları açısından artmış riske sahip olabilecekleri teorik olarak beklenmesine karşın literatürde bildirilmiş birliktelik az sayıdadır. Burada, yaygın oral ülserleri olan bir pemfigus vulgaris hastasında parotit gelişimi sunulmakta, parotit ile pemfigus arasındaki olası ilişki tartışılmaktadır.

**Anahtar kelimeler:** parotit, tükürük bezi iltihabı, pemfigus vulgaris, oral ülser

**Corresponding author:** Elif Comert Ozer, Dept. of Dermatology Marmara University Fevzi Cakmak M. Mimar Sinan C. No:41 34899 Pendik, Istanbul, Turkey, Phone: +90 216 6570606, E-mail: elifcomertt@gmail.com

**Received:** 1 July 2020 **Accepted:** 15 February 2021

**Conflicts of Interest:** None

**Funding:** None

**How to cite this article:** Ozgen Z, Comert Ozer E, Seckin Gencosmanoglu D. Parotitis in a pemphigus vulgaris patient with widespread oral lesions: a rare or underdiagnosed condition? Mucosa 2021;4:23-26



This work is licensed under a Creative Commons Attribution-NonCommercial 4.0 International License.

## Introduction

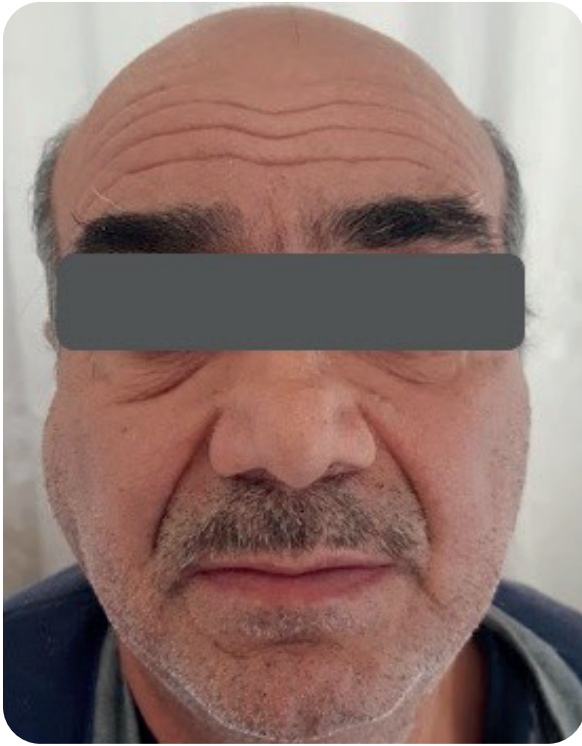Parotitis and other salivary gland inflammations are usually caused by mechanical trauma and infections such as mumps- a well-known etiology- tuberculosis and *Staphylococcus aureus* and commensal bacteria infections. Hypersensitivity reactions, Sjogren's syndrome and other dry mouth causes, sarcoidosis, obstruction of the salivary gland ducts and its branches with stone, tumor and mucous plug, diseases leading to dehydration such as anorexia nervosa and gastrointestinal pathologies, granulomatosis with polyangiitis and organic phosphate poisoning are other rare etiological factors.<sup>1</sup> Drugs have also been reported to cause parotitis. Although certain drugs such as chlormethiazole, methimazole, epinephrine, naproxen, antipsychotics and antidepressants, cytarabine, histamine receptor blockers, interferon alpha, methyl dopa, antihypertensive agents and antibiotics are among these, there are sufficient evidence for direct causal association only with a small number of drugs, such as asparaginase, clozapine, and phenylbutazone.<sup>2-7</sup> The mechanism of drug induced parotitis is mainly dry mouth as a result of drug hypersensitivity, toxic accumulation or anticholinergic effects. Dryness of the oral mucosa leads to blockage of ducts or lower branches of salivary glands.<sup>8</sup>

As far as we know, there are no reports of development of parotitis after immunosuppressive therapies in English literature, but theoretically, immunosuppressive therapies can increase the risk of viral and bacterial infections in all salivary glands. Apart from a tendency to develop infections due to their treatment induced immunosuppressed state, pemphigus vulgaris patients can also be expected to have an increased risk of parotitis and other salivary gland infections due to various reasons such as oral ulcers, deterioration in oral intake, multiple medications used and other autoimmune diseases that may accompany, although such an association has been reported rarely.<sup>9</sup> Here, a pemphigus vulgaris patient with enlargement of the parotid glands on both sides is reported and association of parotitis and pemphigus vulgaris is

discussed in light of the scarce data in literature.

## Case report

A 51-year-old male patient presented with a two-months history of widespread ulcers in his mouth. He had been hospitalized and a nasogastric catheter was placed for a while due to his poor oral intake. Personal and family history were unremarkable. Dermatological examination revealed widespread ulcerated areas on buccal mucosa, hard palate, tongue and gums as well as an erythema in the right conjunctiva. Histopathological examination showed suprabasal separation and acantholytic cells and intracellular IgG accumulation was detected in direct immunofluorescence (DIF) analysis. Positive anti-desmoglein 3 antibodies were shown by ELISA whereas antidesmoglein-1 was negative. Based on clinical, histopathological and direct immunofluorescence findings, mucosal dominant pemphigus vulgaris was diagnosed. The patient was started on oral methylprednisolone (48 mg/day) and methotrexate (15 mg/week). However, methotrexate had to be stopped after a month because of nausea, and mycophenolate mofetil 2 gr/day was initiated. Systemic steroid and mycophenolate mofetil combination was used for an additional month without any improvement. The ongoing severity of oral erosions and deterioration of oral intake necessitated a more effective disease control and the patient was admitted to the dermatology clinic for rituximab treatment. On the following day of 1000 mg rituximab infusion, severe infiltration and swelling of the left preauricular region appeared without any tenderness or pain in jaw movements. The patient was consulted to otorhinolaryngology and the clinical picture was found to be consistent with idiopathic parotitis, and no further investigation was needed (imaging, etc.). No treatment other than hydration was recommended, preauricular swelling regressed spontaneously in a day and the patient was discharged. On his next admission to the clinic for the second infusion of 1000 mg rituximab, oral lesions had significantly improved, however, infiltration and swelling were observed on



**Fig. 1.** Infiltration and swelling in the right preauricular region on the face

the other side of the face, in the right preauricular region (Fig. 1). This recurrence of parotitis on the contralateral side regressed in two days with hydration, mouth care and healing of oral lesions with rituximab. Patient's treatment continued with intravenous immunoglobulin, oral and conjunctival lesions healed completely and no recurrence of parotitis was seen in 14-months of follow-up. Written consent was taken from the patient for publication.

## Discussion

Oral mucosa is almost always affected in pemphigus vulgaris patients. Painful erosions and ulcers are the cause of significant impairment in eating and drinking, which then leads to dehydration and malnutrition. Multiple drug exposure, possible accompanying autoimmune diseases, oral ulcers, poor oral intake and risk of superinfection of the oral ulcers are all predisposing factors for development of parotitis and other salivary gland infections in pemphigus patients,

however, data about this association is very limited. Two cases of temporary parotitis in pemphigus vulgaris have been reported and parotitis development was considered to be associated with the presence of extensive oral ulcers.<sup>9,10</sup> There may be different explanations for the scarce data in literature: parotitis may easily be overlooked because of its mild and self-limiting course or it is really an unusual event as current treatment options in pemphigus can prevent its occurrence by providing effective disease control.

In the current patient with pemphigus vulgaris, bacterial or viral infection was not considered as an etiological factor of acute, self-limiting and two-sided migratory parotitis because of the otherwise good general health of the patient and the absence of fever and local tenderness. Although he was being treated with systemic steroids and immunosuppressive medications at the time of parotitis development, two-months of treatment is rather short to consider immunosuppression as the principal cause of parotitis. A high incidence of Sjogren's disease has been reported in pemphigus patients<sup>11</sup>, however, significant dominance of Sjogren's and pemphigus association in female patients as well as the chronic course of salivary gland pathologies in Sjogren's disease rather than an acute occurrence as seen in the current patient makes this diagnosis unlikely.

Our patient presented with severe, widespread oral ulcers which significantly disrupted his oral intake, led to weight loss and even resulted in replacement of nasogastric catheter for a short period. First swelling of the parotid gland regressed very rapidly in a day and the second attack on the contralateral side also regressed in a short time without any specific treatment. No recurrence was observed after improvement of oral lesions in the follow-up period despite ongoing steroid therapy. Regarding all these facts in the history and course of the disease, development of acute parotitis in our patient can be explained by dehydration induced mucous plug formation in the parotid ductus and further narrowing of the ductal opening due to widespread inflammation and ulcers in the buccal mucosa.

In pemphigus vulgaris or patients with impaired oral mucosal integrity and decreased oral intake, unilateral or bilateral swelling of the parotid or other salivary glands should raise the suspicion of salivary gland inflammation. Awareness of such an association is important in terms of rapid diagnosis and treatment and also for prevention of unnecessary advanced tests.

**Informed consent:** The authors certify that they have obtained all appropriate consent forms from the patient.

**Peer-review:** Externally peer-reviewed

**Authorship contributions:**

Conception and design, or analysis and interpretation of data: ECO

Drafting the manuscript or revising the content: ZO

Final approval of the version to be published: DSG

gus vulgaris. *Isr J Med Sci* 1986;22:903-5.

11. Chiu YW, Chen Y da, Hua TC, et al. Comorbid autoimmune diseases in patients with pemphigus: a nationwide case-control study in Taiwan. *Eur J Dermatol* 2017;27:375-81.

## References

1. Brook I. Diagnosis and management of parotitis. *Arch Otolaryngol Head Neck Surg* 1992;118:469-71.
2. Mahdiabadi FM, Nikvarz N. Captopril-induced sialadenitis in a patient with end-stage renal disease. *J Res Pharm Pract* 2016;5:146-8.
3. Brooks KG, Thompson DE. A review and assessment of drug-induced parotitis. *Ann Pharmacother* 2012;46:1688-99.
4. Kenningham J. An unusual case of postoperative facial swelling. *Anaesthesia* 2000;55:601-2.
5. Capoccia L, Sbarigia E, Speziale F. Monolateral sialadenitis following iodinated contrast media administration for carotid artery stenting. *Vascular* 2010;18:34-6.
6. Almeida P de, Gregio A, Brancher JA, et al. Effects of antidepressants and benzodiazepines on stimulated salivary flow rate and biochemistry composition of the saliva. *Oral Surg Oral Med Oral Pathol Oral Radiol Endod* 2008;106:58-65.
7. Vinasco LG, Bares S, Sandkovsky U. Acute suppurative parotitis caused by *Streptococcus pneumoniae* in an HIV-infected man. *BMJ Case Rep* 2015; bcr2014209082
8. Bonnet U, Khalil-Boutros Y. Acute bilateral parotitis occurring during venlafaxine titration in an adolescent female with major depression. *Pharmacopsychiatry* 2014;47:36-8.
9. Iqbal K, Fassih H, Setterfield JF, Groves RW. Recurrent acute bilateral facial pain and swelling in a patient with severe recalcitrant pemphigus vulgaris. *Clin Exp Dermatol* 2011;36:436-7.
10. Frumkin A. Low-dose aurothioglucose in pemphi-

# Self-resolving congenital form of oral lymphoepithelial cyst: case report

## Spontan düzelen konjenital oral lenfoepitelyal kist: Olgu sunumu

Ayat Gamal-AbdelNaser<sup>1</sup>

<sup>1</sup>Dept. of Oral Medicine and Periodontology, Cairo University Faculty of Dentistry, Cairo, Egypt

### Abstract

Oral lymphoepithelial cyst is a rare benign cystic lesion affecting the oral cavity; mainly the floor of the mouth. It was reported to affect patients with a wide age range extending from childhood to geriatrics. It is treated by conservative surgical excision with excellent prognosis. A case of 2-month old infant presented with a congenital asymptomatic white dome-shaped swelling in the floor of the mouth. The lesion was reported to resolve spontaneously with no intervention. To the best of our knowledge, this is the first report of a congenital oral lymphoepithelial cyst. We recommend the follow up of the cases of infants and children as resolution may occur spontaneously with no need for intervention.

**Key words:** benign lymphoepithelial cyst, branchial cleft cyst, self-limiting

### Öz

Oral lenfoepitelyal kist, ağız zemini başta olmak üzere oral boşluğu etkileyen nadir bir benign kistik lezyondur. Çocukluktan geriatriye kadar geniş bir yaş aralığına sahip hastaları etkilediği bildirilmiştir. Konservatif cerrahi eksizyon ile mükemmel prognozla tedavi edilir. İki aylık bir bebek ağız zemininde doğuştan asemptomatik beyaz kubbe şeklinde bir şişlik ile başvurdu. Lezyonun hiçbir müdahale olmadan kendiliğinden gerilediği bildirildi. Bilgimize göre bu olgu, bildirilen ilk spontan gerileyen konjenital oral lenfoepitelyal kist olgusudur. Müdahaleye gerek kalmadan kendiliğinden düzelmeye olabileceği için bebek ve çocuk vakalarının takibini öneririz.

**Anahtar kelimeler:** iyi huylu lenfoepitelyal kist, brankial yarık kisti, kendini sınırlayan

### Introduction

Oral lymphoepithelial cyst (LEC) is a rare benign lesion affecting the oral cavity. The floor of the mouth is the most commonly affected intraoral site. It affects a wide age range extending from 2 to 75 years of age. Rare cases

**Corresponding author:** Ayat Gamal-AbdelNaser, Department of Oral Medicine and Periodontology, Cairo University Faculty of Dentistry, Cairo, Egypt. Phone: +20 01001874257, E-mail: ayat.gamal@dentistry.cu.edu.eg

**Received:** 31 December 2020 **Accepted:** 25 March 2021

**Conflicts of Interest:** None

**Funding:** None

**How to cite this article:** Gamal-AbdelNaser A. Self-resolving congenital form of oral lymphoepithelial cyst: case report. Mucosa 2021;4:27-29



This work is licensed under a Creative Commons Attribution-NonCommercial 4.0 International License.

of children have been reported.<sup>1</sup>

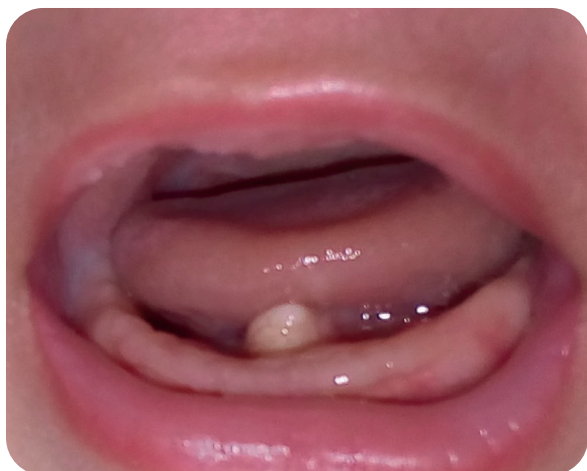### Case report

This report presents a case of a healthy 2-month-old female who was born with a whitish lump under her tongue. The mother reported that the lesion did not affect suckling or cause any pain to the infant.

Examination revealed a well defined, sessile, solitary, round, soft, white, non-tender, non-fluctuant swelling of 0.5 cm diameter, in the floor of the mouth near the orifice of the right submandibular salivary gland duct. (Fig. 1)

The differential diagnosis of the lesion included lymphoepithelial cyst and dermoid cyst. The dermoid cyst is characterized by its rubbery consistency and its location strictly in the midline. As both conditions did not fit the case, lymphoepithelial cyst was believed to be the most probable diagnosis.

An excisional biopsy was indicated as the treatment of choice. However, the risk for performing surgery under general anesthesia for the 2-month-old baby was outweighed by the benefits of performing periodic follow up for the asymptomatic lesion to monitor the progression of lesion size and symptoms till the case becomes operable. The parents provided their informed consent for this management plan. After two weeks of the first visit, the lesion spontaneously resolved



**Fig. 1.** Clinical presentation of the oral lymphoepithelial cyst

during the patient's sleep. The mother reported that the patient woke up free of any oral lesions.

### Discussion

To the best of our knowledge, this is the first report for a congenital form of oral LEC. The mean age of the affected patients has been highlighted in the literature as the fourth decade of life; however reports include cases ranging from 2 to 75 years old.<sup>1</sup> Some sporadic cases were reported for patients under 10 years of age.<sup>1-3</sup> However, only McDonnell<sup>2</sup> reported a case of a 5-year-old child who had the lesion "shortly after birth". It also constituted the only article to report spontaneous resolution of the lesion. The author assumed the lesion was exposed to minor trauma causing either rupture into the mouth or herniation through the thin overlying mucosa causing its resolution.<sup>2</sup>

As the name refers, oral lymphoepithelial cyst represents a cystic lesion with both epithelial and lymphocytic components.<sup>4</sup> It has been hypothesized to be caused by either the inclusion of epithelial cells in lymphoid aggregates followed by cystic growth<sup>5</sup>, or being a pseudocyst caused by plugging of the crypt opening of lymphatic tissue by desquamated epithelial lining causing swelling.<sup>6</sup>

Reports show that it affects the floor of the mouth the most, followed by the lateral border of the tongue then the ventral surface and soft and hard palates.<sup>1</sup> The preference of the floor of the mouth was attributed to the hypothesis that the cyst originates from the excretory duct of the sublingual salivary gland or from ectopic minor salivary glands.<sup>7</sup>

Clinically, oral LEC is characterized by its presentation as a dome-shaped submucosal nodule with normal non-ulcerated covering mucosa. It has a yellow to white color and soft to firm cheese-like consistency.<sup>1</sup>

Diagnosis of oral LEC is based only on its clinical picture and behavior-namely its color and asymptomatic slowly growing nature- together with its histopathological picture. Imaging techniques are not used for diagnosis; as ultrasonography, computed tomography and magnetic resonance imaging were

reported to be non-conclusive.<sup>1</sup>

Accordingly, a decision should be made to stick to follow up or to perform conservative surgical excision or marsupialization under local anaesthesia. The management decision is based on the judgement of the lesion size and symptoms.<sup>8</sup> Intralesional injection of sclerosing agent was also a proposed line of treatment.<sup>9</sup>

Generally, the lesion has favorable prognosis of no recurrence.<sup>1</sup> However, if traumatized or irritated, the lesion either resolves -as in the hereby presented case- or becomes symptomatic secondary to proliferation of lymphoid tissue.<sup>10</sup>

Although it is always addressed as a rare lesion, the prevalence of oral LEC is thought to be underestimated due to scarcity of reports of such cases. This may be attributed to the small size of the lesions, asymptomatic nature and -according to this report- its occasional self-limiting nature.<sup>10</sup>

**Informed consent:** The author certifies that he has obtained all appropriate consent forms from the parents of the patient.

**Peer-review:** Externally peer-reviewed

**Authorship contributions:**

Conception and design, or analysis and interpretation of data: AG

Drafting the manuscript or revising the content: AG

Final approval of the version to be published: AG

## References

1. Yang X, Ow A, Zhang CP, et al. Clinical analysis of 120 cases of intraoral lymphoepithelial cyst. *Oral Surg Oral Med Oral Pathol Oral Radiol* 2012;113:448-52.
2. McDonnell D. Spontaneous regression of a yellow sublingual swelling : a case report. *Pediatr Dent* 1972;12:388-9.
3. Flaitz C. Oral lymphoepithelial cyst in a young child. *Pediatr Dent* 2000;22:422-3.
4. Bhaskar SN. Lymphoepithelial cysts of the oral cavity. *Oral Surg Oral Med Oral Pathol* 1966;21:120-8.
5. Gold C, Levittown N. Branchial cleft cyst located in the floor of the mouth. *Oral Surg Oral Med Oral Pathol* 1962;15:1118-20.
6. Knapp MJ. Pathology of oral tonsils. *Oral Surg Oral Med Oral Pathol* 1970;29:295-7.
7. Chaudhry AP, Yamane G, Scharlock E, SunderRaj M, Jain R. A clinicopathological study of intraoral lymphoepithelial cysts. *J Oral Med* 1984;39:79-84.
8. Castro JGL, Ferreira GM, Mendonca EF, de Castro LA. A rare occurrence of lymphoepithelial cyst in the palatine tonsil: a case report and discussion of the etiopathogenesis. *Int J Clin Exp Pathol* 2015;8:4264-8.
9. Kim MG, Lee NH, Ban JH, Lee KC, Jin SM, Lee H. Sclerotherapy of branchial cleft cysts using OK-432. *Otolaryngol Head Neck Surg* 2009;141:329-34.
10. Acevedo A, Nelson JF. Lymphoepithelial cysts of the oral cavity: report of nine cases. *Oral Surg* 1971;31:632-6.