



ISSN 2146-4006

# Bozok Medical Journal

Cilt: 13, Sayı: 2, Haziran 2023

## BOZOK TIP DERGİSİ

Volume: 13, Issue: 2, June 2023

Yozgat Bozok Üniversitesi Tıp Fakültesi Yayın Organıdır

Official Journal of Yozgat Bozok University Medical Faculty

[www.bozok.edu.tr](http://www.bozok.edu.tr)



# BOZOK TIP DERGİSİ



## Tıp Fakültesi Adına Sahibi

Prof. Dr. Mustafa Fatih ERKOÇ

## Yazı İşleri Müdürü

Doç. Dr. Sercan SARI

## Editör

Prof. Dr. Levent IŞIKAY

## Editör Başyardımcıları

Prof. Dr. Volkan BALTACI

Prof. Dr. Işıl ÖZKOÇAK TURAN

## Editör Yardımcıları

Prof. Dr. Hülya ŞİMŞEK (Temel Tıp Alan Editörü)

Doç. Dr. Vugar Ali TÜRKSÖY (Yardımcı Editör)

Prof. Dr. Esat ADIGÜZEL (Temel Tıp Alan Editörü)

Doç. Dr. Emre GÖKÇEN (Yardımcı Editör)

Doç. Dr. Murat ÇAKIR (Temel Tıp Alan Editörü)

Doç. Dr. Taylan ONAT (Yardımcı Editör)

Dr. Handan ONULAY (Temel Tıp Alan Editörü)

Dr. Öğr. Üyesi Ayça ÇAKMAK (Yardımcı Editör)

Doç. Dr. Emine ÖKSÜZ (Hemşirelik Alan Editörü)

Dr. Öğr. Üyesi Ayşen CANIKLIOĞLU (Yardımcı Editör)

Prof. Dr. Murat KORKMAZ (Cerrahi Tıp Alan Editörü)

Dr. Öğr. Üyesi Mahmud Mustafa Özkut (Yardımcı Editör)

Prof. Dr. Hasan Ali BAYHAN (Cerrahi Tıp Alan Editörü)

Op. Dr. Nursen KARTAL (Yardımcı Editör)

Prof. Dr. Nesrin TURHAN (Cerrahi Tıp Alan Editörü)

Doç. Dr. Sercan SARI (Yazım Dil Editörü)

Prof. Dr. Ümit KOÇ (Cerrahi Tıp Alan Editörü)

Doç. Dr. Volkan Selmi (Yabancı Dil ve Son Okuma Editörü)

Prof. Dr. Ayşe Gül ALTINTAŞ (Cerrahi Tıp Alan Editörü)

Doç. Dr. Mehmet CANIKLIOĞLU (İstatistik Editörü ve

Prof. Dr. Çiğdem KADER (Dahili Tıp Alan Editörü)

Bilimsel Sekreter)

Prof. Dr. Nermin TANIK (Dahili Tıp Alan Editörü)

Dergimiz Türkiye Atıf Dizini (Türkiye Citation Index) ve Türk Medline Ulusal Sağlık Bilimleri Süreli Yayınlar Veritabanı'na kayıtlıdır.

**Yayın Türü** / Type of Publication  
Yerel Süreli Yayın / Periodical Publication

**Tasarım - Dizgi** / Designing- Editing  
Mehmet Kaan BAŞER / Mustafa ÇELİKAYA

**Mizanpaj** / Layout  
Mehmet Kaan BAŞER

# BOZOK TIP DERGİSİ

Cilt 13, Sayı 2, 2023

## DANIŞMA KURULU

Ak Hakan, Yozgat	Ede Hüseyin, Katar	Özkan Akyüz Esra, Yozgat
Anlar Ömer, Ankara	Ede Ghaniye, Katar	Öztekin Ünal, Yozgat
Aral Yalçın, Yozgat	Ekim Hasan, Yozgat	Öztürk Hayati, Sivas
Arıkan Fatma İnci, Yozgat	Er Zafer Cengiz, Yozgat	Öztürk Kahraman, İstanbul
Arslan Ergin, Yozgat	Erbay Ali Rıza, Ankara	Presmann Mark R, ABD
Arslan Halil, Ankara	Erbay Ayşe, Yozgat	Polat Muhammed Fevzi, Yozgat
Atabek Didem, Ankara	Erdem Senay Bengin, Yozgat	Sabah Özcan Seda, Yozgat
Ataseven Hilmi, Sivas	Eren Gök Şebnem, Yozgat	Sarı Sercan, Yozgat
Ateş Yalım, Ankara	Fırat Selma, Ankara	Sarıkaya Pervin, Yozgat
Atılğan Kıvanç, Yozgat	Göçmen Ayşe Yeşim, Yozgat	Sarıçioğlu Levent, Antalya
Aypar Ülkü, Yozgat	Gümüşlü Saadet, Antalya	Saydam Levent, Ankara
Banlı Oktay, Ankara	Günaydın İlhan, Almanya	Selmi Volkan, Yozgat
Bakırtaş Hasan, Ankara	Gürdal Canan, Ankara	Sevcan Levent, Yozgat
Başer Emre, Yozgat	Gürdal Mesut, Ankara	Sipahi Mesut, Yozgat
Bavbek Canıgür Nehir, Ankara	Gürel Abdullah, Yozgat	Solak Ahmet Şükrü, Yozgat
Bayhan Seray Aslan, Yozgat	Gürel Gülhan, Yozgat	Suher Mehmet Murat, Ankara
Bayhan Hasan Ali, Yozgat	Hacimusalar Yunus, Yozgat	Şen İlker, Ankara
Boynueğri Süleyman, Ankara	Hamamcı Mehmet, Yozgat	Talih Gamze, Yozgat
Bozkurt Murat, Ankara	İmamoğlu M. Abdurrahim, Ankara	Tanık Nermin, Yozgat
Börekeçi Elif, Yozgat	İnan Levent Ertuğrul, Yozgat	Tubaş Filiz, Kayseri
Börekeçi Hasan, Yozgat	İnadıklioğlu Nihal, Yozgat	Tuncer Baloş Burcu, Ankara
Caltekin İbrahim, Yozgat	İntepe Yavuz Selim, Yozgat	Turan Elif, Yozgat
Canıklioğlu Aysen, Yozgat	Kader Çiğdem, Yozgat	Turan Yaşar, Yozgat
Cengiz Gül Ferda, Yozgat	Kahraman Fatih Ahmet, Yozgat	Tutkun Lütfiye, Yozgat
Çakmak Ayça, Yozgat	Kantekin Yunus, Yozgat	Tutkun Engin, Yozgat
Çiçekçioğlu Ferit, Yozgat	Kantekin Ünal Çiğdem, Yozgat	Türksoy Vugar Ali, Yozgat
Çiftçi Bülent, Yozgat	Kara Mustafa, Yozgat	Ulukavak Çiftçi Tansu, Ankara
Çölgeçen Emine, Yozgat	Karaaslan Fatih, Kayseri	Ulusoy Tangül Sevgi, Yozgat
Dağistan Hakan, Yozgat	Karaaslan Özgül, Yozgat	Üstün Yaprak, Ankara
Daltaban İskender Samet, Yozgat	Karacabey Sinan, İstanbul	Vural Sevilay, Yozgat
Demir Çaltekın Melike, Yozgat	Karadöl Müjgan, Urfa	Yalvaç Ethem Serdar, Yozgat
Demir Vahit, Yozgat	Korkmaz Murat, Yozgat	Yıldırım Tekin, Yozgat
Demirdaş Ertan, Yozgat	Külah Bahadır, Ankara	Yılmaz Neziha, Yozgat
Demirtürk Fazlı, Tokat	Marklund Marie, İsviç	Yılmaz Seher, Yozgat
Dinç Soykan, Yozgat	Metin Bayram, Yozgat	
Doğanyığıt Züleyha, Yozgat	Onat Taylan, Yozgat	
Durusoy Serhat, Yozgat	Ozan Zeynep Tuğba, Yozgat	

Yozgat Bozok Üniversitesi Tıp Fakültesi Yayın Organıdır. Yılda 4 kez, Mart, Haziran, Eylül ve Aralık aylarında yayınlanır.

**Yazışma Adresi:** Yozgat Bozok Üniversitesi Tıp Fakültesi Çapanoğlu Mah. Cemil Çiçek Cad. Erdoğan Akdağ Yerleşkesi Atatürk Yolu 7. Km 66100 YOZGAT

**YASAL UYARI:** Bu dergide yayımlanan içerik kullanımından doğabilecek sonuçlardan veya yanlışlardan yayınevi ve editörler sorumlu tutulamayacaklardır. İçeriklerde yer alan görüşler ve fikirler yayınevi ve editörlerin görüşlerini yansıtmaz.

# BOZOK TIP DERGİSİ

Cilt 13, Sayı 2, 2023

## YAYIN KURULU

Adıgüzel, Esat; Denizli Pamukkale Üniversitesi Tıp Fakültesi  
Altıntaş, Ayşegül; Ankara Ulucanlar Göz Eğitim ve Araştırma Hastanesi  
Baltacı, Volkan; Ankara Üniversitesi Tıp Fakültesi  
Bayhan, Hasan Ali; Yozgat Bozok Üniversitesi Tıp Fakültesi  
Caniklioğlu, Ayşen; Yozgat Bozok Üniversitesi Tıp Fakültesi  
Caniklioğlu, Mehmet; Yozgat Bozok Üniversitesi Tıp Fakültesi  
Çakır, Murat; Yozgat Bozok Üniversitesi Tıp Fakültesi  
Çakmak, Ayça; Yozgat Bozok Üniversitesi Tıp Fakültesi  
Gökçen, Emre; Yozgat Bozok Üniversitesi Tıp Fakültesi  
Işıkkay, Levent; Yozgat Bozok Üniversitesi Tıp Fakültesi  
Kader, Çiğdem; Yozgat Bozok Üniversitesi Tıp Fakültesi  
Kartal, Nursen; İstanbul Nursen Kartal Muayenehanesi  
Koç, Ümit; İstanbul İstinye Üniversitesi Tıp Fakültesi  
Korkmaz, Murat; Yozgat Bozok Üniversitesi Tıp Fakültesi  
Onat, Taylan; Malatya İnönü Üniversitesi Turgut Özal Tıp Merkezi  
Onulay, Handan; Ankara Prof. Dr. Yunus Müftü Ana Çocuk Sağlığı Ve Aile Planlaması Merkezi  
Öksüz, Emine; Ankara Sağlık Bilimleri Üniversitesi  
Özkoçak Turan, Işıl; Ankara Şehir Hastanesi  
Özkut, Mahmud Mustafa; Afyonkarahisar Sağlık Bilimleri Üniversitesi Tıp Fakültesi  
Sarı, Sercan; Yozgat Bozok Üniversitesi Tıp Fakültesi  
Selmi, Volkan; Yozgat Bozok Üniversitesi Tıp Fakültesi  
Şimşek, Hülya; Yozgat Bozok Üniversitesi Tıp Fakültesi  
Tanık, Nermin; Yozgat Bozok Üniversitesi Tıp Fakültesi  
Turhan, Nesrin; Ankara Bilkent Şehir Hastanesi  
Türksoy, Vugar Ali; Yozgat Bozok Üniversitesi Tıp Fakültesi

Yozgat Bozok Üniversitesi Tıp Fakültesi Yayın Organıdır. Yılda 4 kez, Mart, Haziran, Eylül ve Aralık aylarında yayınlanır.

**Yazışma Adresi:** Yozgat Bozok Üniversitesi Tıp Fakültesi Çapanoğlu Mah. Cemil Çiçek Cad. Erdoğan Akdağ Yerleşkesi Atatürk Yolu 7. Km 66100 YOZGAT

**YASAL UYARI:** Bu dergide yayımlanan içerik kullanımından doğabilecek sonuçlardan veya yanlışlardan yayınevi ve editörler sorumlu tutulamayacaklardır. İçeriklerde yer alan görüşler ve fikirler yayınevi ve editörlerin görüşlerini yansıtmaz.

# İÇİNDEKİLER

## ORJİNAL ÇALIŞMA

1. Primeri Bilinmeyen Kanselerde PET BT'nin Rolü (İNGİLİZCE MAKALE)  
*Ozan KANDEMİR, Fadime DEMİR*

8-13

2. Ekstremitte Yabancı Cisim Yaralanmalarının Analizi (İNGİLİZCE MAKALE)  
*Erdi İMRE*

14-20

# CONTENTS

## ORIGINAL ARTICLE

1. The Role of PET CT in Cancer of Unknown Primary (ENGLISH ARTICLE)  
*Ozan KANDEMİR, Fadime DEMİR*
2. Analysis of Extremity Foreign Body Injuries (ENGLISH ARTICLE)  
*Erdi İMRE*

8-13

14-20

# THE ROLE OF PET CT IN CANCER OF UNKNOWN PRIMARY

## Primeri Bilinmeyen Kanserlerde PET BT'nin Rolü

Ozan KANDEMİR<sup>1</sup>, Fadime DEMİR<sup>2</sup>

<sup>1</sup>Muğla Sıtkı Koçman Üniversitesi,  
Eğitim ve Araştırma Hastanesi,  
Nükleer Tıp Kliniği  
<sup>2</sup>Sağlık Bilimleri Üniversitesi,  
Kayseri Şehir Sağlık Uygulama ve  
Araştırma Merkezi,  
Nükleer Tıp Kliniği

Ozan KANDEMİR, Dr. Öğr. Ü.  
(0000-0003-3978-1222)  
Fadime DEMİR,  
(xxxx-xxxx-xxxx-xxxx)

**İletişim:**  
Dr. Öğr. Ü. Ozan KANDEMİR  
Muğla Sıtkı Koçman Üniversitesi Eğitim  
ve Araştırma Hastanesi Nükleer Tıp  
Kliniği

**Geliş tarihi/Received:** 16.05.2022  
**Kabul tarihi/Accepted:** 17.05.2023  
**DOI:**

Bozok Tıp Derg 2023;13(2):8-13  
Bozok Med J 2023;13(2):8-13

### ABSTRACT

**Objective:** This study aimed to investigate the diagnostic value of positron emission tomography/computed tomography (PET/CT) in detecting the primary focus and in suspicious foci in patients who underwent PET/CT with a pre-diagnosis of carcinoma of unknown primary.

**Material and Methods:** In this retrospective study, a total of 49 patients who underwent PET/CT scan with a prediagnosis of carcinoma of the unknown primary between 2015 and 2019, and whose clinical follow-up and histopathological data were available, were included. PET/CT study was performed in 20 (40%) patients after the metastatic lesion was detected as a result of pathology, and in 29 (60%) patients due to clinical findings and imaging methods and suspicion of malignancy. The histopathological and clinical evaluation of the patients before PET/CT and the primary surgery, histopathological examinations and clinical follow-ups after PET/CT were examined. The success of PET/CT in detecting primary lesions and evaluating suspicious lesions in metastatic cases was analyzed.

**Results:** Seventeen (34.7%) of the patients were female and 32 (65.3%) were male. A primary malignant tumor was detected in 34 (85%) of 40 patients with PET/CT. Regional distribution in patients with primary cancer focus; 9 pancreases, 9 lungs, 4 livers, 3 urothelial, 2 thyroids, 1 vertebra, 1 breast, 1 ovary, 1 esophagus, 1 prostate, 1 iliac bone, 1 skin, 1 stomach and 1 colon. In the follow-up of 6 cases whose primary could not be determined; Cervical cancer was detected in 1, ovarian cancer in 1, and the primary focus could not be detected in the clinical follow-up of 4 metastatic patients.

**Conclusion:** PET/CT is highly successful in detecting cancers whose primary is unknown. Therefore, PET/CT is a diagnostic imaging method for the detection of the primary in cancer patients whose primary is unknown.

**Keywords:** Cancer of Unknown Primary; Positron Emission Tomography; Malignant Lesion

### ÖZET

**Amaç:** Bu çalışmanın amacı, primeri bilinmeyen karsinom ön tanısı ile pozitron emisyon tomografisi/bilgisayarlı tomografi PET/BT uygulanan hastalarda, PET/BT'nin primer odak tespiti ve şüpheli odaklardaki tanısallık değerini araştırmaktır.

**Gereç ve Yöntemler:** Bu retrospektif çalışmaya 2015-2019 yılları arasında primeri bilinmeyen karsinom ön tanısı ile PET/BT çekimi yapılmış, klinik takibi ve histopatolojik verileri mevcut toplam 49 hasta dahil edilmiştir. PET/BT çalışması hastaların 20 (%40)'sinde patoloji sonucunda metastatik lezyon tespit edilmesi sonrası, 29 (%60)'unda ise klinik bulgular ve görüntüleme yöntemleri ile malignite şüphesi varlığı nedeniyle uygulandı. Hastaların PET/BT öncesi histopatolojik ve klinik değerlendirilmesi ile PET/BT sonrası primere yönelik cerrahi, histopatolojik incelemeler ve klinik takipleri incelendi. PET/BT'nin metastatik olgularda primer lezyon tespiti ve şüpheli lezyonları değerlendirmesindeki başarısı analiz edildi.

**Bulgular:** Hastaların 17(%34,7)'si kadın, 32 (%65,3)'si erkekti. PET/BT ile 40 hastadan 34'ünde (%85) primer malign tümör saptandı. Primer kanser odağı tespit edilen hastalarda bölgesel dağılım; 9 pankreas, 9 akciğer, 4 karaciğer, 3 üretelyal, 2 tiroid, 1 vertebra, 1 meme, 1 over, 1 özofagus, 1 prostat, 1 iliak kemik, 1 deri, 1 mide ve 1 kolon idi. Primeri saptanamayan 6 olgunun takiplerinde; 1'inde serviks kanseri, 1'inde over kanseri saptanırken, 4 metastatik hastanın klinik takibinde ise primer odak saptanamamıştır.

**Sonuç:** Primeri bilinmeyen kanserlerin tespitinde PET/BT oldukça yüksek oranda başarı göstermektedir. Bu nedenle PET/BT primeri bilinmeyen kanserli hastalarda primerin tespiti için, tanıya yardımcı bir görüntüleme metodudur.

**Anahtar Kelimeler:** Primeri Bilinmeyen Kanseri; Pozitron Emisyon Tomografisi; Malign Lezyon



## INTRODUCTION

Cancers of unknown origin refer to a heterogeneous group of metastatic tumors whose origin of the primary tumor cannot be determined despite extensive research (1,2).

Cancers whose primary is unknown constitute 2-5% of all cancers (3). The median age at diagnosis is 60-65 years, and it is more common in men than women. Sensitivity to treatment is low and the median survival time is 6-10 months (4).

To identify the primary focus in cancers of unknown origin, patients typically undergo a comprehensive physical examination, laboratory tests, and diagnostic procedures, including chest radiographs, computed tomography (CT), and/or magnetic resonance imaging (MRI), ultrasonography, mammography, and endoscopy (5). Even after these extensive tests, the primary site of origin cannot be determined in the majority of patients (6). In cases where a definitive diagnosis cannot be made with all these methods, PET/CT is applied as an auxiliary test.

Patients who underwent PET/CT imaging with a preliminary diagnosis of carcinoma of unknown primary can be divided into two groups. The first of these; is the patient group in whom metastatic focus was detected histologically and the primary focus could not be found by clinical and radiological imaging methods. The second is the group in which a suspicious metastatic lesion was detected by imaging methods, but the biopsy was not performed, and the group with high tumor markers and the tumor focus could not be detected.

PET/CT is among the recommended tests in current guidelines because it can change the management plan in the diagnosis and treatment of patients with tumors of unknown primary, detecting the primary tumor focus, especially in the head and neck region, and detecting possible additional metastases in other regions (6). The study aims to determine the primary focus of PET/CT and to investigate the diagnostic value of suspicious foci in patients who underwent PET/CT with a pre-diagnosis of carcinoma of unknown primary.

## MATERIAL AND METHODS

In this retrospective study, a total of 49 patients who underwent PET/CT scan with a prediagnosis

of carcinoma of unknown primary in our clinic between 2015-2019 and whose clinical follow-up and histopathological data were available were included. PET/CT imaging was acquired using Siemens Biograph 2 (Biograph, Siemens, USA) PET/CT device approximately 60 minutes after intravenous injection of 296-407 MBq 18F-fluorodeoxyglucose (18F-FDG). All patients were fasted for at least 6 hours before PET/CT imaging and a blood glucose level of <200 mg/dL was confirmed before 18F-FDG administration. First, a low-dose CT scan was performed for precise anatomic localization and attenuation correction. Next, a three-dimensional PET scan was performed from the skull base to the proximal femur. Images were evaluated visually, lesions were evaluated together with the maximum standardized uptake value (SUV max), which is a semi-quantitative parameter. The histopathological and clinical evaluation of the patients before PET/CT and the primary surgery, histopathological examinations and clinical follow-ups after PET/CT were examined. All analyzes were performed with SPSS 20.0 (IBM corp. Released 2011. IBM SPSS Statistic for Windows, Version 20.0. Armonk, NY: IBM Corp.). The success of PET /CT in detecting primary lesions and evaluating suspicious lesions in metastatic cases was analyzed.

For this study, the approval of Tokat Gaziosmanpaşa University Faculty of Medicine Clinical Research Ethics Committee dated 15.05.2019 and registration number 19-KAEK-110 was obtained.

## RESULTS

Of the 49 patients included in the study, 17 (34.7%) were female and 32 (65.3%) were male. The mean age was 64.47±9.92 years. PET/CT was performed to investigate the primary tumor after the metastatic lesion pathology results in 20 (40%) patients, and in 29 (60%) because of imaging methods and clinical findings and suspicion of malignancy. The diagnosis of the primary lesion after PET/CT was by pathology in 29 (60%) patients, and by clinical follow-up-evaluation in 20 patients.

Regional distribution of metastasized or suspicious lesions; they were 18 bones, 8 livers, 6 brains, 6 peritoneal-mesenteric-acid, 4 lymph nodes, 4 lungs and 3 pancreases.

The rate of detecting malignant primary tumors

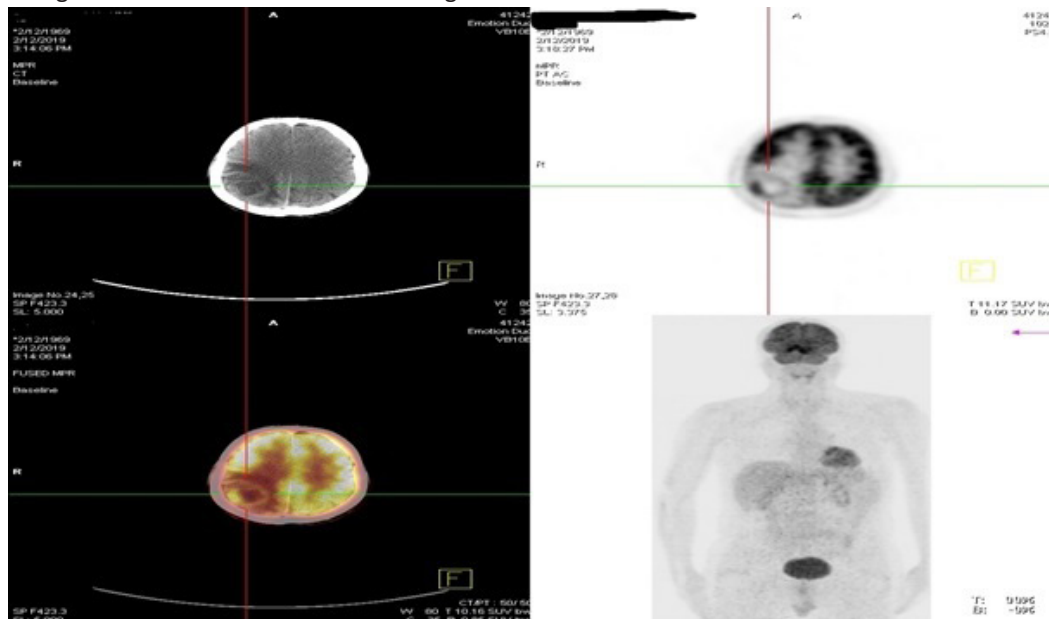
by PET/CT was 34/42 (80%). In the follow-up of 6 cases whose primary could not be determined; Cervical cancer was detected in 1, ovarian cancer in 1, and the primary focus could not be detected in the clinical follow-up of 4 metastatic patients. PET/CT gave false-positive results in 1 patient. The pathology of the patient was Schwannoma. The percentage of PET/CT benign cases was 5/7 (71.3%) (Table 1). While the pathology results of lesions detected by PET/CT as benign were 1 osteochondroma, 1 giant

cell tumor and 1 para tubal Morgagni hydatid, no malignant finding was found in the follow-ups of 2 cases. Of the 3 cases evaluated as suspicious by PET/CT; 2 of them were malignant (glioblastoma, squamous cell carcinoma), and 1 was a benign lesion (fibrous dysplasia) (Figure 1). Regional distribution of primary malignancy; 9 pancreas, 9 lungs, 4 liver, 3 urothelial, 2 thyroids, 1 vertebra, 1 breast, 1 ovary, 1 esophagus, 1 prostate, 1 iliac bone, 1 skin, 1 stomach and 1 colon (figure 2).

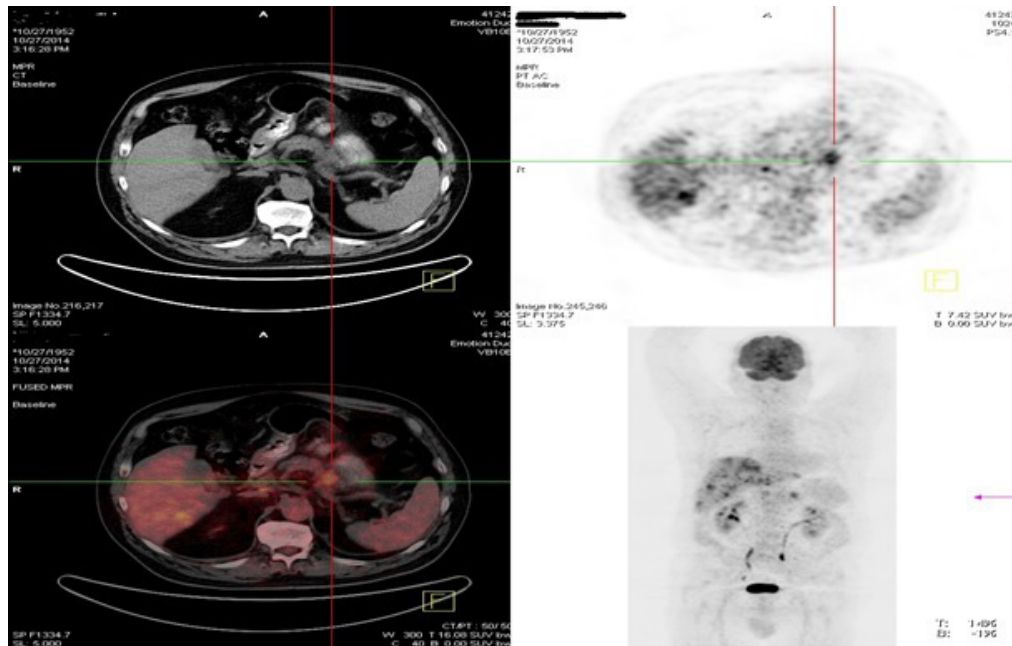
**Table 1.** Comparison of PET/CT findings and diagnostic data for the primary lesion

		PET CT			
DIAGNOSIS		Malignant	Benign	Suspicious	Metastasis positive but primary focus undetected
(histological/clinical)	Malignant (primary)	34		2	2
	Benign (primary)	1	5	1	
	Patient with primary undetected malignant metastasis				4

**Figure 1.** A 50-year-old male patient was diagnosed with FDG-PET/CT imaging after detecting a lesion (met?) in the cerebrum on CT. In FDG-PET/CT, a suspicious lesion with hypometabolic middle and pathologically increased FDG uptake in the periphery was defined in the right part posterior of the cerebrum (primary lesion?). Histopathological confirmation of the lesion was glioblastoma multiforme.



**Figure 2.** FDG-PET/CT imaging of a 62-year-old male patient was performed to investigate the primary lesion after the liver biopsy was adenocarcinoma metastasis. PET/CT imaging revealed a primary lesion in the pancreas, metastatic lesions in the liver, and metastasis in the hepatic lymph nodes. Histopathological confirmation of the mass in the pancreas was pancreatic adenocarcinoma, one of the most common cancers in our study.



## DISCUSSION

In patients with cancer of unknown primary, despite a standard comprehensive diagnostic study according to published guidelines, there is pathological evidence of malignancy, but the primary cancer site could not be identified (7-8). Imaging with FDG PET/CT is more successful than other imaging methods in detecting the primary tumor site and detecting additional metastasis sites (6).

In patients with cancer of unknown primary, the primary tumor is usually small in size. Small tumors with a size below the PET/CT resolution limit can only be detected as long as there is increased FDG uptake (9). Many tumors exhibit maximum FDG uptake 60 minutes after FDG injection, while normal surrounding tissues show a decline in FDG uptake over time. Therefore, in PET/CT late imaging, the primary tumor-background contrast may increase significantly, thereby increasing the detectability of tumors of unknown primary (10-12). Yoo et al., in their study with 74 patients with suspected metastatic foci in the skeletal system, reported that focal increased FDG uptake in areas outside the

skeletal system in PET/CT was an important factor in determining the biopsy site and thus affecting the detection of the primary (13).

Intense FDG uptake other than metastatic foci in PET/CT and guidance of the FDG uptake area to the biopsy site is very useful in detecting the primary tumor.

In our study, PET/CT was performed for patients whose metastatic focus was detected histologically and the primary focus could not be found by clinical and radiological imaging methods, and for patients with suspected malignancy based on imaging methods and clinical findings. We tried to detect the primary focus by detecting areas of intense FDG uptake outside of the metastatic foci, comparing the SUVmax values of the tumoral area in the early late images, and providing guidance for the areas of intense FDG uptake instead of the biopsy. The diagnosis of the primary lesion after PET/CT scan was by pathology in 60% of the patients, and by clinical follow-up-evaluation in 40% of the patients.

In the literature, the success of FDG-PET/CT in detecting primary lesions has been reported at varying rates.

Soni et al. reported that 18F-FDG PET/CT detects the primary in 39% of patients, Thai et al. 40.5%, Ella et al. 44%, in the range of 22-75% reported in other studies in the literature. (14,5,4).

In a comprehensive review of 16 studies and 302 patients, Liu reported that the accuracy rate of FDG-PET in detecting tumors of unknown primary was 78.8% (14).

In our study, we found the rate of detection of malignant primary tumors by PET/CT as 34/42 (80%), slightly higher than the literature. The reason why this rate is slightly higher than in the literature is that the majority of the cases in our study were primarily located in an organ of thoracoabdominal origin as stated in the literature, it was easier to detect compared to those with head and neck cancer, or the widespread use of PET/CT and technological developments in devices may be associated with increased sensitivity (15). In addition, in our study, PET/CT was primarily used in patients with suspected metastasis lesions and was preferred for ease of diagnosis.

In PET/CT studies performed to detect the primary cancers whose primary is unknown in the literature; false positives are also encountered. In the study performed by Soni et al. false positivity was reported histopathologically in 7 of 81 patients whose primary was detected in PET/CT (17). In our study, only 1 patient out of 35 patients who were evaluated as malignant in PET/CT was false positive and 1 was considered suspicious. The causes of these false-positive cases are most commonly various physiological involvement and inflammation (16). In addition, some benign lesions (Schwannoma, fibrous dysplasia, etc.) and cases where the area thought to be primary in PET/CT is histopathologically metastasis of the primary can be counted as causes of false positives. In a meta-analysis by Burglin et al., the mean age of patients with cancers of unknown primary was approximately 60 years for most studies, and 17 of the 20 studies included more men than women (median ratio of men: 57.9%) (17). In our study, the mean age was 64.47±9.92 years, consistent with the literature, and 65.3% of the patients were male.

In our study, the three most common primary tumor sites detected by PET/CT were the digestive system 16 (44.4%) and the respiratory system 9 (25%) and

the excretory system (8.3%) according to pathological examination, which is similar to other studies in the literature (18).

The limitations of our study are that it is a single-center, retrospective study with a limited number of patients.

## CONCLUSION

As a result, PET/CT primary shows a very high success rate in detecting cancers unknown primary. For this reason, we recommend PET/CT imaging as a diagnostic test for the detection of the primary in cancer patients whose primary is unknown.

## Acknowledgements

The authors declare that there is no conflict of interest between the authors.

## REFERENCES

1. Rassy E, Assi T, Pavlidis N. Exploring the biological hallmarks of cancer of unknown primary: where do we stand today? *Br J Cancer*. 2020;122(8):1124–32.
2. Dermawan JK, Rubin BP. The role of molecular profiling in the diagnosis and management of metastatic undifferentiated cancer of unknown primary: Molecular profiling of metastatic cancer of unknown primary. *Semin Diagn Pathol*. 2021;38(6):193-8.
3. Siegel RL, Miller KD, Jemal A. Cancer statistics. *CA. Cancer J Clin*. 2019;69(1):7-34.
4. Nissan E, Amit U, Baron L, Zabatani A, Urban D, Barshack I, et al. The usefulness of [18F]FDG PET/ CT in detecting and managing cancers with unknown primary site depends on histological subtype. *Sci Rep*. 2021;11(1):17732.
5. Soni N, Ora M, Aher PY, Mishra P, Maheshwarappa RP, Priya S, et al. Role of FDG PET/CT for detection of primary tumor in patients with extracervical metastases from carcinoma of unknown primary. *Clin Imaging*. 2021;78:262-70.
6. Woo S, Becker AS, Do RKG, Schoder H, Hricak H, Vargas HA. Impact of 18F-Fluorodeoxyglucose positron emission tomography on management of cancer of unknown primary: systematic review and meta-analysis. *Eur J Cancer*. 2021;159:60-77.
7. Stares M, Purshouse K, Knowles G, Haigh R, Irvine J, Gatenby A, et al. Characterisation and outcomes of patients referred to a regional cancer of unknown primary team: a 10-year analysis. *Br J Cancer*. 2021;125(11):1503-10
8. Fizazi K, Greco FA, Pavlidis N, Daugaard G, Oien K, Pentheroudakis G, et al. Cancers of unknown primary site: ESMO Clinical Practice Guidelines for diagnosis, treatment and follow-up. *Ann Oncol*.

2015;26 Suppl 5:v133–8.

9. Pavlidis N, Fizazi K. Carcinoma of unknown primary (CUP). *Crit Rev Oncol Hematol*. 2009;69(3):271-8.

10. Kwee TC, Basu S, Cheng, Alavi A. FDG PET/CT in carcinoma of unknown primary. *Eur J Nucl Med Mol Imaging*. 2010;37(3):635-44.

11. Kumar R, Dhanpathi H, Basu S, Rubello D, Fanti S, Alavi A. Oncologic PET tracers beyond [(18)F]FDG and the novel quantitative approaches in PET imaging. *Q J Nucl Med Mol Imaging*. 2008;52(1):50-65.

12. Sanz-Viedma S, Torigian DA, Parsons M, Basu S, Alavi A. Potential clinical utility of dual time point FDG-PET for distinguishing benign from malignant lesions: implications for oncological imaging. *Rev Esp Med Nucl*. 2009;28:159–66.

13. Yoo SW, Chowdhury SA, Jeon S, Kang SR, Lee C, Jabin Z, et al. Clinical Impact of F-18 FDG PET-CT on Biopsy Site Selection in Patients with Suspected Bone Metastasis of Unknown Primary Site. *Nuclear Medicine and Molecular Imaging*. 2020;54(4):192-8.

14. Liu Y. FDG PET/CT for metastatic squamous cell carcinoma of unknown primary of the head and neck. *Oral Oncol*. 2019; 92:46–51.

15. Ota I, Kitahara T. Cancer of unknown primary in the head and neck: Diagnosis and treatment. *Auris Nasus Larynx*. 2021;48(1):23-31.

16. Chen B, Zhang H, Liu D, Wang X, Ji B, Gao S. Diagnostic performance of 18F-FDG PET/CT for the detection of occult primary tumors in squamous cell carcinoma of unknown primary in the head and neck: a single-center retrospective study. *Nucl Med Commun*. 2021 1;42(5):523-7.

17. Burglin SA, Hess S, Høilund-Carlsen PF, Gerke O. 18F-FDG PET/CT for detection of the primary tumor in adults with extracervical metastases from cancer of unknown primary A systematic review and meta-analysis. *Medicine*. 2017;96(16):e6713.

18. Li X, Shao Y, Sheng L, Zhu J, Wang Z, Guo K, et al. Risk factors and predictors for tumor site origin in metastatic adenocarcinoma of unknown primary site *Cancer Med*. 2021;10:974-88.

## ANALYSIS OF EXTREMITY FOREIGN BODY INJURIES

## Ekstremitte Yabancı Cisim Yaralanmalarının Analizi

Erdi İMRE<sup>1</sup>,

<sup>1</sup>Abdulkadir Yüksel State Hospital,  
Gaziantep,  
Türkiye.

Erdi İMRE, Op. Dr.  
(0000-0003-2893-721X)

## ABSTRACT

**Objective:** Extremity foreign body injuries are common in trauma departments. In this study, we aimed to find a relation to demographics, treatment methods, injury characteristics, environmental and injury conditions so that prevention methods could be more effective.

**Material and Methods:** Hospital digital archives were searched between July 2014 and March 2020 retrospectively and 146 patients were included. The demographic information, injury place, injured extremity with side, foreign body type and opacity, presence of infection, type of anesthesia performed, operation time, incision length were recorded. Data were analyzed statistically.

**Results:** The mean age of the patients was  $25.9 \pm 17.99$  (2-78). According to gender and side examination, 90 patients were male and 56 patients were female. Metallic object and bullet injuries were mostly seen in males and needle injuries were mostly seen in females. Injuries caused by metallic objects were significantly more common in the upper extremity (p: 0.001). Glass and needle injuries were seen significantly as indoor injuries; as well as bullet, wooden part, and metallic part injuries were seen as outdoor injuries (p<0.001). The infection rate was significantly higher in outdoor injuries (p: 0.006). Age (p: 0.005), operation time (p: 0.007) and incision length (p: 0.019) were significantly higher in outdoor injuries. Indoor injuries were significantly higher under 18 years of age (p:0.036). There was a significant correlation between upper extremity injury and age (r: 0.358, p<0.001) and between upper extremity injury and male gender (r: 0.241, p: 0.003). **Conclusion:** Foreign body injuries are common injuries seen in wide age range. Antibiotic prophylaxis and tetanus vaccine should be applied as primary care. Since firearm injuries, wooden part injuries, and injuries in the rural environment are found to be associated with infection, further studies are needed to discuss extending the duration of antibiotic prophylaxis in these cases.

**Keywords:** Foreign Body, Extremity, Infection, Removal, Injury

## ÖZET

**Amaç:** Ekstremitte yabancı cisim yaralanmaları travma bölümlerinde sık görülmektedir. Bu çalışmada, önleme yöntemlerinin daha etkili olabilmesi için demografik özellikler, tedavi yöntemleri, yaralanma özellikleri, çevresel ve yaralanma koşulları ile bir ilişki bulmayı amaçladık.

**Gereç ve Yöntemler:** Hastane dijital arşivleri Temmuz 2014 ile Mart 2020 tarihleri arasında geriye dönük olarak tarandı ve 146 hasta dahil edildi. Demografik bilgileri, yaralanma yeri, yanı olan ekstremitte, yabancı cisim tipi ve opaklığı, enfeksiyon varlığı, uygulanan anestezi tipi, ameliyat süresi, kesi uzunluğu kaydedildi. Veriler istatistiksel olarak analiz edildi.

**Bulgular:** Hastaların yaş ortalaması  $25,9 \pm 17,99$  (2-78) idi. Cinsiyet ve yan muayeneye göre 90 hasta erkek, 56 hasta kadındı. Metalik cisim ve mermi yaralanmaları daha çok erkeklerde, iğne yaralanmaları ise kadınlarda daha sık görüldü. Metalik cisimlerin neden olduğu yaralanmalar üst ekstremitte anlamlı olarak daha yaygındı (p: 0,001). Cam ve iğne yaralanmaları iç mekân yaralanmaları olarak önemli oranda görüldü; kurşun, ahşap parça ve metal parça yaralanmaları açık hava yaralanmaları olarak görüldü (p<0,001). Dış mekân yaralanmalarında enfeksiyon oranı anlamlı olarak daha yüksekti (p: 0,006). Açık hava yaralanmalarında yaş (p: 0,005), ameliyat süresi (p: 0,007) ve kesi uzunluğu (p: 0,019) anlamlı olarak daha yüksekti. İç mekân yaralanmaları 18 yaş altında anlamlı derecede yüksekti (p:0,036). Üst ekstremitte yaralanması ile yaş (r: 0,358, p<0,001) ve üst ekstremitte yaralanması ile erkek cinsiyet (r: 0,241, p: 0,003) arasında anlamlı bir ilişki vardı.

**Sonuç:** Yabancı cisim yaralanmaları geniş yaş aralığında sık görülen yaralanmalardır. Birinci basamak olarak antibiyotik profilaksisi ve tetanos aşısı uygulanmalıdır. Ateşli silah yaralanmaları, tahta parça yaralanmaları ve kırsal çevre yaralanmaları enfeksiyonla ilişkili bulunduğu için, bu olgularda antibiyotik profilaksisinin uzatılmasının tartışıldığı ileri çalışmalara ihtiyaç vardır.

**Anahtar Kelimeler:** Yabancı Cisim, Ekstremitte, Enfeksiyon, Çıkarım, Yaralanma

## İletişim:

Op. Dr. Erdi İMRE  
Değirmiş Mah. Fevzi Çakmak Bul.  
No:52/8 Şehitkamil/Gaziantep/Türkiye

Geliş tarihi/Received: 08.07.2022

Kabul tarihi/Accepted: 05.10.2022

DOI:

Bozok Tıp Derg 2023;13(2):14-20

Bozok Med J 2023;13(2):14-20

## INTRODUCTION

Extremity foreign body injuries are frequent in emergency and orthopedic departments. It may cause tissue damage, inflammation, infection, delayed wound healing, toxic or allergic reactions, and late injury as a result of migration. Therefore, removal is necessary in most cases. Even though any pathologic situation may not be encountered in short term, it may occur in long term (1). These injuries are usually considered as simple injuries, but sometimes conditions could be complicated. Superficial injuries could be simply taken out of tissues in a sterile fashion while deep-seated foreign bodies need deep dissection. Local anesthesia is the chosen anesthetic method for most cases, depending on the injury site, depth, and age of patients. Direct radiography is the most used imaging modality for radiopaque foreign bodies. For nonradiopaque foreign bodies, ultrasonographic imaging is used to confirm the diagnosis. Moreover, the size of a foreign body is important to identify with direct radiography. In literature, there is a growing interest in these injuries. In this study, we aimed to find a relation to demographics, treatment methods, injury characteristics, environmental and injury conditions so that prevention methods could be more effective.

## MATERIAL AND METHODS

Hospital digital archives were searched between July 2014 and March 2020 retrospectively and patients who had foreign body removal were identified. The patients with missing data were excluded. The study was approved by the Local Ethical Committee (date: 18.3.2020, no: 2020-121). Picture Archiving and Communication Systems (PACS) and hospital archive files were examined.

Preoperative radiographic views were taken in all the patients. If not radiolucent, ultrasound examination was used. Surgery was planned according to clinical examination and radiologic findings. Informed consent was obtained before surgery. After removal, soft tissues were irrigated and the wound was closed. Infected wounds were debrided and a cultural sample was taken before closure. The excision of radiopaque foreign bodies was confirmed by fluoroscopy. Prophylactic antibiotics and tetanus vaccine (rappel dose if necessary) were started in all patients. Infected

patients were treated with empirical antibiotherapy (Amoxicillin/clavulanic acid) until the result of the cultural sample.

Demographic information, injury place, injured extremity with side, foreign body type and opacity, presence of infection, chosen anesthetic method, operation time, incision length were recorded. All information was analyzed statistically.

Data were expressed as mean  $\pm$  standard deviation and frequency. Data distribution was analyzed with the Kolmogorov-Smirnov test. Comparison of different parameters was done using Mann-Whitney U test whereas Chi-square test or Fisher's exact test was used for categorical variables. The phi-coefficient Cramer's V is used to assess the association between two dichotomous categorical variables. The rank-biserial correlation coefficient, rrb, is used for dichotomous nominal data vs rankings (ordinal). The correlation analyses were performed to evaluate the relationship between object type causing the injury, place of injury, age, and localization of the injury. The SPSS version of 22.0 for Windows software was used for analyses (IBM Corp. Released 2013. IBM SPSS Statistics for Windows, Version 22.0. Armonk, NY: IBM Corp.). A two-tailed p-value  $<0.05$  was considered statistically significant.

## RESULTS

A total of 146 patients were included. The mean age of the patients was  $25.9 \pm 17.99$  (2-78). According to gender and side examination, 90 patients (61%) were male and 56 patients (39%) were female; 79 injuries were left (54%) and 67 were right (46%) sided. There were injuries in 68 upper extremities (46%) and 78 lower (54%) extremities. When foreign body types were examined, 5 types of foreign bodies were found: Needle (48), glass (25), wooden pieces (17), metal pieces (24), bullets&pellets (32). The vast majority of the chosen anesthetic method was local anesthesia (137, 93.8%). Other applied methods were sedation (7 patients), spinal anesthesia (1 patient), and general anesthesia (1 patient). The mean operation duration was  $17.51 \pm 10.18$  (range 10-60) and the mean incision length was  $1.32 \pm 0.66$  mm (range 1-5).

Statistical analysis was made between object types, results were brought into a table (table 1) and analyzed. Analysis showed a significant relationship with gender

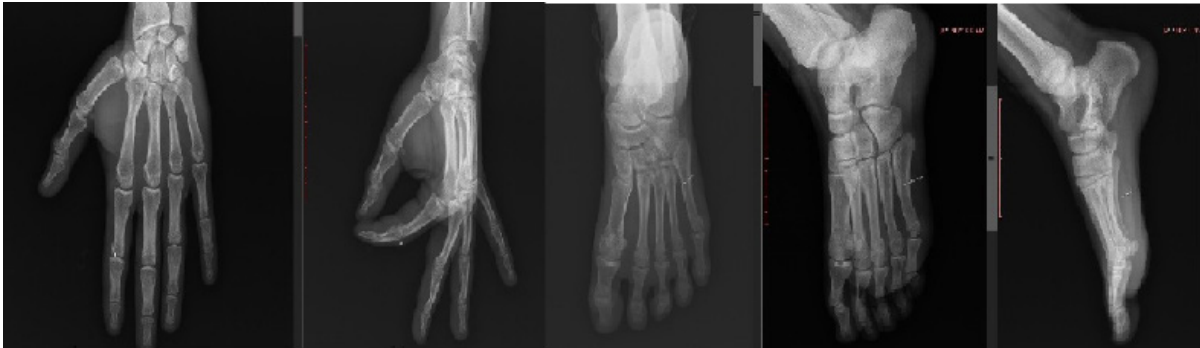( $p: 0.001$ ); metallic object and bullet injuries were mostly seen in males and needle injuries were mostly seen in females. Injuries caused by metallic objects were significantly more common ( $p: 0.001$ ) in the upper extremity and the vast majority of upper extremity injuries ( $p: 0.035$ ) were located distal to the wrist (Figure 1). Bullet and needle injuries were significantly ( $p:0.001$ ) higher in lower extremities (Figure 1). In lower extremity injuries, glass and needle injuries were mostly seen in the distal part of the ankle (Figure 2), however, bullet injuries were mostly seen in the proximal part of the ankle ( $p<0.001$ ). Glass and needle injuries were seen significantly as indoor

injuries; as well as the bullet, wooden part, and metallic part injuries were seen as outdoor injuries ( $p<0.001$ ). Infection rates were significantly higher in bullet pellet and wooden part injuries ( $p: 0.009$ ). Operation duration ( $p: 0.003$ ) and incision length ( $p:0.001$ ) were significantly longer in bullet injuries. There was no significant difference between object types and the applied anesthetic method ( $p: 0.314$ ). Four patients with bullet injuries were operated on under sedation, 1 patient under general anesthesia, and 1 patient (3.1%) under spinal anesthesia. 2 patients with needle injury and 1 patient with metal piece injury were operated on under sedation.

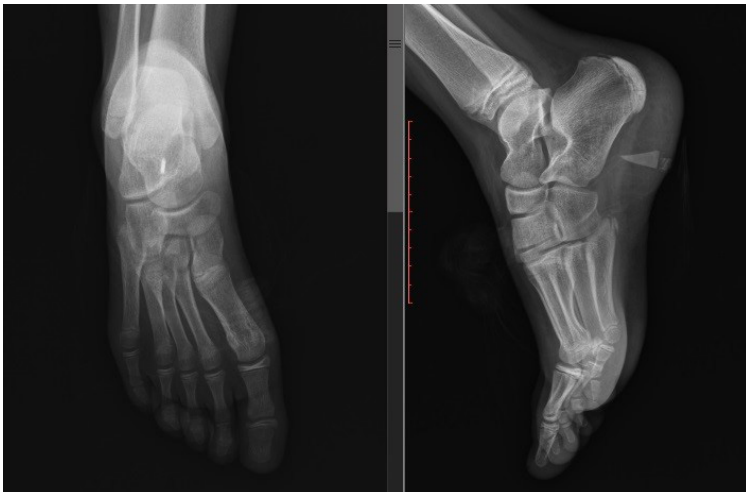**Figure 1.**

**A.** 32-year-old patient with foreign body in left proximal interphalangeal joint

**B.** 13-year-old patient with left foot needle injury. Needle was successfully removed and patient was healed without any complication



**Figure 2.** 10-year-old patient with glass in left foot. Glass piece was removed under local anesthesia and patient was discharged in the same day.





Statistical analysis was applied according to injury place and results were brought into a table (table 2). The male gender was significantly higher in outside injuries. Although there was no significant difference between upper and lower extremity injuries, it was observed that injuries distal to the ankle were frequently indoor injuries ( $p < 0.001$ ). The infection rate was significantly higher in outdoor injuries ( $p: 0.006$ ). Age ( $p: 0.005$ ), operation time ( $p: 0.007$ ) and incision length ( $p: 0.019$ ) were significantly higher in outdoor injuries. No significant relationship was found between injury place and anesthesia method ( $p: 0.149$ ).

Patients were divided into 3 groups according to age as under 18, between 18-65 and over 65, were analyzed and brought into a table (table 3). There were 66 patients (45.2%) under 18, 72 patients (49.3%) between 18-65, and 8 patients (5.4%) older than 65 years of age. Wooden part injuries were significantly higher in patients over 65 years of age ( $p < 0.001$ ).

Upper extremity injuries were significantly more common in patients aged 18 years and older ( $p < 0.001$ ) and lower extremity injuries were significantly more common under 18 years of age ( $p < 0.001$ ). Injuries with radiopaque objects were significantly higher in patients under 18 years of age ( $p: 0.001$ ). Indoor injuries were significantly frequent under 18 years of age ( $p: 0.036$ ). There was no significant relationship between anesthesia method and age ( $p: 0.817$ ) and extremities ( $p: 0.435$ ). General anesthesia was performed in 1 patient and sedation was performed in 4 patients under the age of 18. Spinal anesthesia was performed in 1 patient and sedation was performed in 3 patients between 18-65 ages.

There was a significant correlation between upper extremity injury and age ( $r: 0.358$ ,  $p < 0.001$ ) and weak correlation between upper extremity injury and male gender ( $\phi = 0.241$ ). Operation duration was found significantly correlated with incision length ( $r: 0.458$ ,  $p < 0.001$ ) and bullet&pellet injuries ( $r: 0.281$ ,  $p: 0.001$ ) but no correlation was found with radiopacity ( $r: -0.044$ ,  $p: 0.602$ ), age ( $r: 0.018$ ,  $p: 0.826$ ), extremities ( $r: 0.045$ ,  $p: 0.591$ ), infection presence ( $r: 0.087$ ,  $p: 0.295$ ). Infection presence was found significantly correlated with incision length ( $r: 0.285$ ,  $p < 0.001$ ) and weakly correlated with wooden piece injuries ( $\phi = 0.237$ ) but no correlation was found with male gender ( $\phi = 0.166$ ),

bullet & pellet injuries ( $\phi = 0.141$ ,  $p: 0.091$ ). Incision length was also significantly correlated with bullet injury ( $r: 0.294$ ,  $p < 0.001$ ). A weak correlation was found between metal piece injuries and upper extremities ( $\phi = 0.298$ ) as well as between needle injuries and lower extremities ( $\phi = 0.227$ ). The male gender was not significantly correlated with metal piece injuries ( $\phi = 0.18$ ) and bullet&pellet injuries ( $\phi = 0.186$ ), also female gender was moderately correlated with needle injuries ( $\phi = 0.323$ ). Age was also significantly correlated with wooden piece injuries ( $r: 0.177$ ,  $p: 0.033$ ).

In the binary logistic regression analyses, upper extremity injury was independently associated with the male gender (table 4). Upper extremity injury was also independently associated with metal piece injury.

## DISCUSSION

Foreign body-related extremity injuries are common injuries in a wide age range. We had 146 patients included in this study, fewer patients than most studies; although all of them were done in tertiary healthcare centers this study was done in a secondary healthcare center. Age range (2-78) and mean age ( $25.9 \pm 17.99$ ) in this study was found similar to current literature (2-5). Under the age of 18, the lower extremity (75.8%) was the most common injury site and most of the injuries were indoor injuries ( $p: 0.036$ ). These results were caused by the fact that children and young people under the age of 18 spend more time at home as literature corroborated (3). A previous study revealed that, under the age of 18, the needle was the most common injury object (67.4% in men and 94.2% in women) (3). Another previous study revealed that needle was the most common injury cause (29%) under the age of 13 (6). Although both studies verified needle was the most common injuring object under the age of 18; we believe this study revealed a more accurate result. Because both studies were from tertiary healthcare centers with the heterogenic patient group sent from other hospitals and this study was from a state hospital of a small district (pop.:80447) and had more homogenous patient group.

In our study, the most injuring object was needle (48; 32.4%) which is compatible with literature; despite different percentages (2,3,7). Object types differ as a result of social situations. The district where this study

was conducted is a settlement with predominant rural life. Metal piece injuries were seen mostly in males and needle injuries were seen mostly in females; because the majority of men work in industrial labor works and the majority of women do housework at home. Bullet&pellet injuries were seen mostly in males in lower extremities; because men hunt more like a rural life activity and consequently injure themselves as an accident. This also explains the reason metallic object and bullet injuries occur outdoor and needle injuries indoor as well as male gender association with outdoor and upper extremity injuries. These results were compatible with the literature although bullet&pellet injuries were excluded in other studies (3).

Infection is a major complication of foreign body injuries. It has been reported in the literature that soft tissue infections can lead to serious conditions such as osteomyelitis and septic arthritis, and successful results have been obtained with foreign body removal, debridement, and antibiotherapy in treatment (1, 8-10). These infections may be asymptomatic in the acute period and may occur in the late period as 8-20 years (1, 10). In this study, no patient was presenting at such a late stage. The presence of infection was associated with bullet and wood piece injuries; bullet&pellet injuries were associated with severe soft tissue damage and contamination as stated in literature (11-13). Patients with accompanying bony injuries were excluded from the study; tetanus and antibiotic prophylaxis were immediately applied to all patients admitted with foreign body injury. These were the main reasons for the lower infection rate (4%) compared to literature (8.5-9%) (13, 14). Wood pieces were also associated with infection presence; the most probable explanation is that these were generally farmyard injuries with high contamination risk. Also, difficulty to access primary care services where the injury occurred, and ignorance of injuries contributed to this. It is interpreted that the relationship between infection and outdoor injuries to fact that both bullet and wood fragment injuries occur outdoor and outdoor injuries carry a higher risk of contamination. The correlation between incision length and infection is suggested due to wider incisions made for debridement in presence of infection.

There was no significant relationship between injury

place and extremity; however, it was observed that ankle injuries and distal were mostly indoor. Glass and needle injuries were also significantly more common than indoor injuries. Therefore, it is found reasonable that the mechanism behind is to step on these two common objects at home with bare feet.

Clinical examination and radiological evaluation are important in the diagnosis of foreign body injuries. Evidence of local infection and foreign body reaction can be seen in clinical evaluation (4). Especially in children, it may be overlooked or hard to realize; therefore, foreign body injury should be suspected in presence of allergic reaction, inflammation, and local infection. Radiological evidence usually supports the diagnosis. Glass pieces larger than 2 mm., metal, some plastic, and wooden pieces can be viewed with AP and lateral radiography (15). Ultrasonography and computed tomography are successful methods in cases where the object cannot be visualized by radiography (16, 17).

Due to the insufficient number of studies on the treatment of foreign body injuries, there is no standard treatment algorithm (7). Prophylactic tetanus vaccination and antibiotherapy should be administered in the emergency room immediately. Although removal is performed in all foreign body injuries which are easy to access, conservative treatment should be preferred in foreign body injuries that penetrate deep tissues without causing an infection, due to the risk of serious complications such as neurovascular injury (4). Removal can be performed under local anesthesia in emergency departments, but operation room conditions are mandatory to avoid iatrogenic infection. We recommend this procedure to be performed in the operation room, for benefit of the C-arm scope and avoidance of serious complications.

There is no definite way of prevention from foreign body injuries. Protection methods may vary according to age as well as characteristics of the environment and society. Proper protective gear is the primary method of prevention from these injuries at heavy labor workplaces. Parents should be instructed of such injuries to prevent kids from this kind of injuries.

There were some strengths and limitations of this study. This study was retrospective so that, it had inferior level of evidence compared with prospective

studies. There were only 6 years of hospital data therefore 146 patients were included which means fewer patients comparing other studies in literature (2, 3, 5) . Consequently, a multicenter study with a large number of patients with a longer follow-up period is needed for a common injury like this to achieve more accurate results. There were data of different doctors, with no common work time, which makes the data less reliable. The hospital where this study was done is in a rural state, thus patient population was more homogenous than tertiary centers.

## CONCLUSION

Foreign body injuries are common injuries seen in a wide age range. Serious complications may occur if not intervened appropriately, and clinical picture may emerge even years after injury. Although local anesthetic methods are often sufficient, general anesthetic methods may be required especially for kids and deep-seated foreign body injuries. Antibiotic prophylaxis and tetanus vaccine should be applied as primary care. Since firearm injuries, wooden part injuries and injuries in the rural environment are found to be associated with infection, further studies are needed to discuss to extend the duration of antibiotic prophylaxis in these cases. Local anesthetics are usually sufficient, however general anesthesia may be required for pediatric cases, and deep seated injuries. Firearm and farmyard injuries are associated with infection. Infection requires longer incision, due to the need of appropriate surgical debridement. A multicenter study with a large number of patients with a longer follow-up period is needed for a common injury like this to achieve more accurate results.

## Acknowledgements

The authors have no conflict of interest to declare. The authors declared that this study has received no financial support.

## REFERENCES

1. Gulati D, Agarwal A. Wooden foreign body in the forearm - presentation after eight years. *Ulus Travma Acil Cerrahi Derg.* 2010;16(4):373-5.
2. Kurtulmuş T, Sağlam N, Saka G, Imam M, Akpınar F. Tips and tricks in the diagnostic workup and the removal of foreign bodies in extremities. *Acta Orthopaedica et Traumatologica Turcica.* 2013;47(6):387-92.
3. Özer M, Türker M, Başbuğ V, Kesik K, Türkmen F, Kaçira BK, et al. Evaluation of Deep-Seated Soft Tissue Foreign Bodies According to Gender and Age Groups. *Selcuk Medical Journal.* 2019;35(1):24-30.
4. Uludağ A, Tosu HB, Çiçek N, Şirik M, Uludağ Ö, Atıç R. Surgical approach to foreign bodies observed in the soft tissue of extremities after injury. *Dicle Medical Journal.* 2019;46(2):215-23.
5. Öztürk AM, Aljasim O, Şanlıdağ G, Taşbakan M. Retrospective evaluation of 377 patients with penetrating foreign body injuries: a university hospital experience (a present case of missed sponge foreign body injury). *Turkish Journal of Medical Sciences.* 2021;51(2):570-82.
6. Agarwal A. Foreign Body-Related Extremity Trauma in Children: A Single-Center Experience. *Indian Journal of Orthopaedics.* 2018;52(5):481-8.
7. Alemdar C, Demirtaş A, Azboy İ, Gem M, Özkul E, Bulut M, et al. Orthopedic Approach to Foreign Body Injuries. *J Clin Exp Invest.* 2013;4(4):443-8.
8. Ekinci Y, Gürbüz K, Çiraklı A, Ekinci D, Çiraklı S. Pseudomonas aeruginosa as a Cause of Septic Arthritis After a Sewing Needle Injury. *Ege Journal of Medicine.* 2016;55(2):95-7
9. Chandrashekara CM, George MA, Al-Marboi BS. Neglected Foreign Body, the Cause of Navicular Osteomyelitis in a Paediatric Foot: A Case Report. *Journal of Orthopaedic Case Reports.* 2013;3(3):26-9.
10. Markiewitz AD, Karns DJ, Brooks PJ. Late Infections of The Foot Due to Incomplete Removal of Foreign Bodies: A Report of Two Cases. *Foot & Ankle International.* 1994;15(1):52-5.
11. Metcalf KB, Smith EJ, Wetzel RJ, Sontich JK, Ochenjele G. Comparison of Clinical Outcomes After Intramedullary Fixation of Tibia Fractures Caused by Blunt Trauma and Civilian Gunshot Wounds: A Retrospective Review. *Journal of Orthopaedic Trauma.* 2020;34(6):e208-e13.
12. Sari A, Ozcelik IB, Bayirli D, Ayik O, Mert M, Ercin BS, et al. Management of upper extremity war injuries in the subacute period: A review of 62 cases. *Injury.* 2020;51(11):2601-11.
13. Baumfeld D, Brito ASP, Torres MS, Prado KL, de Andrade MAP, Campos TVO. Firearm-Related Fractures: Epidemiology and Infection Rate. *Revista Brasileira de Ortopedia.* 2020;55(5):625-8.
14. Visbeek MC, Taljaard JJ, De Boer MG, Cronje UJ, Steyn E. Efficacy and patterns of use of antimicrobial prophylaxis for gunshot wounds in a South African hospital setting: an observational study using propensity score-based analyses. *South African Journal of Surgery.* 2020;58(1):27-32.
15. Courter BJ. Radiographic Screening for Glass Foreign Bodies--What Does a "Negative" Foreign Body Series Really Mean? *Annals of*

Emergency Medicine. 1990;19(9):997-1000.

**16.** Yang XJ, Xing GF, Shi CW, Li W. Value of 3-dimensional CT virtual anatomy imaging in complex foreign body retrieval from soft tissues. Korean Journal of Radiology. 2013;14(2):269-77.

**17.** Shrestha D, Sharma UK, Mohammad R, Dhoju D. The role of ultrasonography in detection and localization of radiolucent foreign body in soft tissues of extremities. Journal of The Nepal Medical Association (JNMA). 2009;48(173):5-9.



## BOZOK TIP DERGİSİ

Yayın hakkı devir ve çıkar çatışması beyan formu

### Makale Adı:

### Makale Numarası:

Bu form ile yazar(lar) bildirir ki:

1. Yayın hakları yazının sınırsız olarak basılmasını, çoğaltılmasını ve dağıtılmasını ve mikrofilm, elektronik form (offline, online) veya başka benzer reproduksiyonlarını kapsamaktadır.
2. Ben (biz) makale ile ilgili herhangi bir konuda ortaya çıkabilecek herhangi bir çıkar çatışması veya ilişkisi olduğu durumlarda, makale yayınlanmadan önce Bozok Tıp Dergisi editörünü bilgilendirmeyi taahhüt ediyorum(z). Bu ilişki ilaç firmaları, biyomedikal alet üreticileri veya ürün veya hizmetleri makalede geçen konular ile ilgili olabilecek veya çalışmayı destekleyen diğer kuruluşları kapsamaktadır.
3. Yazar(lar) makaleyi herhangi bir dağıtım amacı ile herhangi bir şekilde çoğaltmak istediğinde Bozok Tıp Dergisi'nden izin almak zorundadır.
4. Biz aşağıda isim ve imzaları bulunan yazarlar, Bozok Tıp Dergisi'nde yayınlanmak üzere gönderdiğimiz yazımızın original olduğunu; eşzamanlı olarak herhangi bir başka dergiye değerlendirilmek üzere sunulmadığını; daha önce yayınlanmadığını; gerekli görülen düzeltmelerle birlikte her türlü yayın hakkımızı, yazı yayına kabul edildiği taktirde "Bozok Tıp Dergisi"ne devrettiğimizi kabul ederiz.

### Katkıda bulunanlar:

Çalışmanın düşünülmesi ve planlanması:	
Verilerin elde edilmesi:	
Verilerin analizi ve yorumlanması:	
Yazının kaleme alınması:	
Eleştirel gözden geçirme:	
İstatistiksel değerlendirme:	

### Makaledeki Sırasıyla Yazarın Adı Soyadı İmza Tarih

- 1.
- 2.
- 3.
- 4.
- 5.
- 6.



## BOZOK MEDICAL JOURNAL

Copyright transfer and conflict of interest statement

**Article Title:**

**Manuscript Number:**

With this form all author(s) certify and accept that:

1. The copyright covers unlimited rights to publish, reproduce and distribute the article in any form of reproduction including microfilm electronic form (online, offline) and any other forms.
2. We grant to inform the editor of the Bozok Medical Journal about real or apparent conflict(s) of interest that may have a direct bearing on the subject matter of the article before the article is published. This pertains to relationships with pharmaceutical companies, biomedical device manufacturers or other corporation whose products or services may be related to the subject matter of the article or who have sponsored the study.
3. Author(s) must obtain permission from the Bozok Medical Journal to reproduce the article in any medium for distribution purposes.
4. The author(s) undersigned hereby declare that the manuscript submitted for publication in the Bozok Medical Journal is original; has not previously been published elsewhere nor is it under consideration by any other journal; and agree to transfer all copyright ownership to the “Bozok Medical Journal” effective upon acceptance of the manuscript for publication with all necessary revisions In the order that they appear in the manuscript

**Author Contributions:**

Study conception and design:	
Acquisition of data:	
Analysis and interpretation of data:	
Drafting of manuscript:	
Critical revision:	
Statistical Analysis:	

**Author Name Surname Sign Date**

- 1.
- 2.
- 3.
- 4.
- 5.
- 6.



## Yazarlara Bilgi

### Kapsam

Bozok Tıp Dergisi, Yozgat-Bozok Üniversitesi'nin bilimsel içerikli, resmi yayınıdır.

Mart, Haziran, Eylül, Aralık aylarında olmak üzere yılda 4 sayı olacak şekilde yayımlanır.

Bozok Tıp Dergisi, tıbbın tüm alanlarında, cerrahi, klinik ve temel tıp bilimleri orijinal araştırma makaleleri, derlemeler, editör görüşleri, editöre mektup ve olgu sunumları yazılarının yayımlandığı "çift-kör" danışmanlık (peer-review) ilkelerine dayanan uluslararası bir dergidir.

Bozok Tıp Dergisi'nde makale başvuru veya işlem ücreti uygulanmamaktadır. Yayımlanan yazılar için herhangi bir ücret ya da karşılık ödenmez.

### Amaç

Bozok Tıp Dergisi; tıbbın tüm alanlarında, cerrahi, klinik ve temel tıp bilimleri alanlarına ulusal ve uluslararası düzeyde katkı yapan özgün araştırma makaleleri, derlemeler, olgu sunumları, editör görüşleri ve editöre mektupları yayımlamayı amaçlamaktadır.

### Genel Bilgiler

Yayımlanmak için gönderilen makalelerin daha önce başka bir yerde yayımlanmamış veya yayımlanmak üzere gönderilmemiş olması gerekir. Eğer makalede daha önce yayımlanmış; alıntı yazı, tablo, resim vs. mevcut ise makale yazarı, yayın hakkı sahibi ve yazarlarından yazılı izin almak ve bunu makalede belirtmek zorundadır.

Dergi, yayımlanan makalelerin bilimsel ve etik kurallar çerçevesinde hazırlanmış olması ve ticari kaygılarda olmaması şartını gözetmektedir. Makalelerin bilimsel ve etik kurallara uygunluğu yazarların sorumluluğundadır. Makalenin değerlendirilmesi aşamasında, yayın kurulunun gerek görmesi halinde, makale ile ilgili araştırma verilerinin ve/veya etik kurul onayı belgesinin sunulması yazarlardan talep edilebilir.

Dergiye gönderilen makale biçimsel esaslara uygun ise, editör ve en az iki danışmanın incelemesinden geçip, gerek görüldüğü takdirde, istenen değişiklikler yazarlarca yapıldıktan sonra yayımlanır. Yazarlar taslağın son halini tek bir word dosyası olarak sisteme yüklemelidir. Gönderilmiş olan makalelerdeki yazım ve dilbilgisi hataları, makalenin içeriğine dokunmadan, editorial komitemiz tarafından düzeltilmektedir.

Makalelerin değerlendirilmeye alınabilmesi için, 'Telif Hakkı', 'Potansiyel Çıkar Çatışması Beyanı' ve klinik araştırmalarda 'Etik Kurul Onayı' nın bir kopyası sisteme yüklenmelidir. Bu formları içermeyen yazılar değerlendirilmeye alınmayacaktır. Potansiyel çıkar çatışması beyanı için IJME'nin formu dikkate alınmaktadır. Aşağıdaki bağlantıdan indirilebilir:

[https://www.jmcp.org/pb-assets/pdf/ICMJE%20coi\\_disclosure-1554411604567.pdf](https://www.jmcp.org/pb-assets/pdf/ICMJE%20coi_disclosure-1554411604567.pdf)

Yayımlanmak üzere kabul edilen yazıların her türlü yayın hakkı dergiyi yayımlayan kuruma aittir. Yazılardaki düşünce ve öneriler tamamen yazarların sorumluluğundadır ve yazarlara gönderdikleri yazıları karşılığında herhangi bir ücret ödenmez.

### Yazım Kuralları

• Yazılar çift aralıklı, yazı boyutu 12 punto olmalı, kenarlardan 2,5 cm boşluk bırakılarak, standart A4 sayfasına, Microsoft Office Word belgesi veya rich text format olarak hazırlanmalıdır.

• Her bölüm yeni bir sayfadan başlamalıdır.

• Yazılar başlık sayfasından başlanarak numaralanmalı, sayfa numaraları sağ alt köşeye yazılmalıdır.

• Kapak sayfasında; yazının başlığı (Türkçe ve İngilizce), sayfa başlarında kullanılacak 40 karakteri aşmayan kısa başlık, en az 3 ve en çok 6 anahtar sözcük, tüm yazarların ad-soyadları, akademik ünvanları, kurumları, iş telefonu-GSM, e-posta ve yazışma adresleri bulunmalıdır. Ayrıca yazının hazırlanması için alınmış herhangi bir destek ya da bağış varsa belirtilmelidir.

• Özetler; Türkçe ve İngilizce olarak yazının çeşidine uygun olarak hazırlanmalıdır.

• Anahtar kelimeler; en az 3 en çok 6 olmak üzere Türkçe ve İngilizce yazılmalıdır. Kelimeler birbirlerinden noktalı virgül (;) ile ayrılmalıdır. İngilizce kelimeler Index Medicus taki Medical Subjects Headings listesine uygun olmalıdır (Bkz: [www.nlm.nih.gov/mesh/MBrowser.html](http://www.nlm.nih.gov/mesh/MBrowser.html)). Türkçe anahtar kelimeler Türkiye Bilim Terimleri (TBT)'ne uygun olarak verilmelidir (Bkz: [www.bilimterimleri.com](http://www.bilimterimleri.com)).

• Şekil, resim, tablo ve grafiklerin metin içinde geçtiği yerler ilgili cümlelerin sonunda belirtilmeli; sırayla numaralanmalı ve yazıdan ayrı olarak sunulmalıdır. Şekil, resim, tablo ve grafiklerin açıklamaları makale sonuna eklenmelidir. Kullanılan kısaltmalar şekil, resim, tablo ve grafiklerin altındaki açıklamada belirtilmelidir. Görseller EPS, TIFF, JPG ve PDF formatında gönderilmeli ve fotoğraflar 300 dpi ve vektörel çizimler ise 600 dpi çözünürlükte olmalıdır.

• Teşekkür kısmında; çıkar çatışması, finansal destek, bağış ve diğer bütün editöryal (istatistiksel analiz, İngilizce/Türkçe değerlendirme) ve/veya teknik yardım varsa, metnin sonunda sunulmalıdır.

• Yazının sonundaki kaynak listesi kaynakların yazıdaki geliş sıralarına göre hazırlanmalıdır. Kaynak yazımı için kullanılan format Index Medicus'a uygun olmalıdır. (Bkz: [www.icmje.org](http://www.icmje.org)). Kaynaklar yazıda, ilgili cümle sonunda parantez içine alınarak belirtilmelidir. Kaynak numaraları birbirini takip ediyorsa başlangıç ve bitiş sayıları arasında kısa çizgi konur. Kaynaktaki yazar sayısı 6 veya daha az ise tüm yazarlar belirtilmeli; 6'dan fazla ise, sadece ilk 6 isim yazılmalı ve diğerleri et al şeklinde gösterilmelidir. Kongre bildirileri, kişisel deneyimler, basılmamış yayınlar, tezler ve internet adresleri kaynak olarak gösterilemez. On-line yayınlar için; DOI tek kabul edilebilir on-line referanstır.

• Kaynak seçiminin ulusal yayınlardan yapılması tavsiye edilmektedir.

Kaynakların yazımı için örnekler (Lütfen noktalama işaretlerine dikkat ediniz):

• Makale için; Yazar(lar)ın soyad(lar)ı ve isim(ler)inin başharf(ler)i, makale ismi, dergi ismi, yıl, cilt, sayı, sayfa no'su belirtilmelidir.

\*Rempel D, Dahin L, Lundborg G. Pathophysiology of nerve compression syndromes: response of peripheral nerves to loading. J Bone Joint Surg. 1999;81(11):1600-10.

• Kitap için; Yazar(lar)ın soyad(lar)ı ve isim(ler)inin başharf(ler)i, bölüm başlığı, editörün(lerin) ismi, kitap ismi, kaçınıcı baskı olduğu, şehir, yayınevi, yıl ve sayfalar belirtilmelidir.

\*Kozin SH, Bishop AT, Cooney WP. Tendinitis of the wrist. In Cooney WP, Linscheid RL, Dobins JH, eds. The wrist: diagnosis and operative



treatment. Vol. 2. St. Louis: Mosby, 1998. p. 1181-96.

• Digital Object Identifier (DOI):

\*Zhang M, Holman CD, Price SD, Sanfilippo FM, Preen DB, Bulsara MK. Comorbidity and repeat admission to hospital for adverse drug reactions in older adults: retrospective cohort study. BMJ. 2009 Jan 7;338:a2752. doi: 10.1136/bmj.a2752.

• Diğer kaynak türleri için, Bkz. "ICMJE Uniform Requirements for Manuscripts Submitted to Biomedical Journals: Sample References".

#### **Yazı çeşitleri**

##### **Orijinal araştırmalar:**

Prospektif veya retrospektif, tıbbın tüm alanları ile ilgili her türlü deneysel ve klinik çalışmalardır.

İçerik:

- Özet; Türkçe ve İngilizce olarak, ortalama 200-250 kelime olacak şekilde; amaç, gereç ve yöntemler, bulgular ve sonuç bölümlerinden oluşmalıdır.

- Giriş

- Gereç ve yöntemler

- Bulgular

- Tartışma / sonuç

- Teşekkür

- Kaynaklar

\*Makalenin tamamı, yaklaşık 5000 sözcükten uzun olmamalı, şekil ve tablo sayısı altıyı geçmemeli, kaynaklar 40'ı aşmamalıdır.

##### **Klinik Derlemeler:**

Doğrudan veya davet edilen yazarlar tarafından hazırlanır. Tıbbi özellik gösteren her türlü konu için son tıp literatürünü de içine alacak şekilde hazırlanmalıdır. Yazarın o konu ile ilgili basılmış yayınlarının olması özellikle tercih nedenidir.İçeriği;

- Özet (Ortalama 200-250 kelime, bölümsüz, Türkçe ve İngilizce)

- Konu ile ilgili başlıklar

- Kaynaklar

\*Derleme 5000 sözcüğü aşmamalı, şekil ve tablo en fazla 4, kaynak sayısı en fazla 100 olmalıdır.

##### **Kısa bildirimler:**

-2000 sözcüğü aşmamalı, şekil ve tablo en fazla 2, kaynak sayısı en fazla 20 olmalıdır.

##### **Olgu Sunumu:**

Nadir görülen, tanı ve tedavide farklılık gösteren makalelerdir. Yeterli sayıda fotoğraflarla ve şemalarla desteklenmiş olmalıdır.

İçerik:

- Özet (ortalama 100-150 kelime; bölümsüz; Türkçe ve İngilizce)

- Giriş

- Olgu Sunumu

- Tartışma

- Kaynaklar

##### **Editöre mektup**

Son bir yıl içinde dergide yayınlanmış makalelere yanıt olarak gönderilir. Yazı hakkında okuyucuların farklı görüş, deneyim ve sorularını içerir.

İçerik:

- Başlık ve özet bölümleri yoktur

- Mektuplar en fazla 500 kelimelik yazılardır, kaynak sayısı 5 ile sınırlıdır, şekil ve tablo içermez.

- Hangi makaleye (sayı, tarih verilerek) ithaf olunduğu belirtilmeli ve sonunda yazarın ismi, kurumu, adresi bulunmalıdır.

- Mektuba cevap, editör veya makalenin yazar(lar)ı tarafından, yine dergide yayımlanarak verilir.

##### **Kontrol Listesi**

Makale aşağıda gösterildiği gibi ayrı dosyalar halinde hazırlanmalıdır:

1.Başvuru Mektubu

2.Başlık sayfası

3.Özet

4.Ana metin (makale metni, teşekkür, kaynaklar, tablolar ve şekil başlıkları)

5.Şekiller

6.Yayın Hakları Devir Formu





## Instructions For Authors

### Scope

Bozok Medical Journal is the official publication of Yozgat-Bozok University, Faculty of Medicine that offers scientific content. It is printed 4 times in a year in the months of March, June, September and December.

Bozok Medical Journal is a national journal, based on peer-review consultation principles publishing clinic and basic science, original research articles, reviews, editor views and case reports in every field of medicine.

Bozok Medical does not request application or process fees. Also, it does not pay any kind of compensation or fee for the published articles

### Aim

The journal aims to publish research, original work, review and case reports that contribute in its field on national and international levels in basic medical sciences and clinical branches.

### General Information

Articles are accepted for publication on the condition that they are original, are not under consideration by another journal, or have not been previously published. Direct quotations, tables, or illustrations that have appeared in copyrighted material must be accompanied by written permission for their use from the copyright owner and authors.

The Journal commit to rigorous peer review, and stipulates freedom from commercial influence, and promotion of the highest ethical and scientific standards in published articles. It is the authors' responsibility to prepare a manuscript that meets scientific criterias and ethical criterias. During the evaluation of the manuscript, the research data and/or ethics committee approval form can be requested from the authors if it's required by the editorial board.

All articles are subject to review by the editors and at least two referees. Acceptance is based on significance, and originality of the material submitted. Authors should upload the final version of the draft to the system as a single word file If the article is accepted for publication, it may be subject to editorial revisions to aid clarity and understanding without changing the data presented.

A copyright release form signed by all authors, a copy of conflict of interest and a copy of the approval of ethics committee must be uploaded to the system simultaneously with the manuscript. Submissions received without these forms (copyright, conflict of interest and approval of ethics committee) cannot be sent out for review. The form of IJME should be used for copyright release statement. This form can be downloaded from the link below: [https://www.jmcp.org/pb-assets/pdf/ICMJE%20coi\\_disclosure-1554411604567.pdf](https://www.jmcp.org/pb-assets/pdf/ICMJE%20coi_disclosure-1554411604567.pdf)

The publisher owns the copyright of all published articles. Statements and opinions expressed in the published material herein are those of the author(s). Manuscript writers are not paid by any means for their manuscripts

### Editorial Policies

• Text should be double spaced with 2,5 cm margins on both sides of a standard A4 page, using 12-point font. Manuscripts should be written with Microsoft Office Word document or rich text format.

• Each section should start on a separate page.

• The pages should be numbered consecutively, beginning with the title page and the page numbers should be placed in the lower right corner of each page.

• The title page should be organized as follows: Full title of the article, both in Turkish and English, all author's full names with academic degrees, and names of departments and institutions, short title of not more than 40 characters for page headings, at least 3 and maximum 6 key words, corresponding author's e-mail, postal address, telephone and fax numbers, any grants or fellowships supporting the writing of the manuscript.

• Abstracts should written Turkish and English according to categories of articles.

• Key words should be minimally 3 and maximum 6, and should written Turkish and English. The words should be separated by semicolon (;), from each other. English key words should be appropriate to "Medical Subject Headings (MESH)" (Look: [www.nlm.nih.gov/mesh/MBrowser.html](http://www.nlm.nih.gov/mesh/MBrowser.html)). Turkish key words should be appropriate to "Türkiye Bilim Terimleri (TBT)" (Look: [www.bilimterimleri.com](http://www.bilimterimleri.com)).

• All figures, pictures, tables and graphics should be cited at the end of the relevant sentence and numbered consecutively and kept separately from the main text. Explanations about figures, pictures, tables and graphics must be placed at the end of the article. All abbreviations used, must be listed in explanation which will be placed at the bottom of each figure, picture, table and graphic. Submit your figures as EPS, TIFF, JPG or PDF files, use 300 dpi resolution for pictures and 600 dpi resolution for line art.

• In acknowledgements section; conflict of interest, financial support, grants, and all other editorial (statistical analysis, language editing) and/or technical assistance if present, must be presented at the end of the text.

• The list of the references at the end of the paper should be given according to their first appearance in the text. Journal abbreviations should conform to the style used in the Cumulated Index Medicus (please look at: [www.icmje.org](http://www.icmje.org)). Citations in the text should be identified by numbers in brackets at the end of the relevant sentence. If reference numbers follow each other, the hyphen is placed between the starting and ending numbers. All authors should be listed if six or fewer, otherwise list the first six and add the et al. Declarations, personal experiments, unpublished papers, thesis can not be given as reference. Format for on-line-only publications; DOI is the only acceptable on-line reference.

• Choosing references from national magazines is recommend.

Examples for writing references (please give attention to punctuation):

• Format for journal articles; initials of author's names and surnames, titles of article, journal name, date, volume, number, and inclusive pages, must be indicated.

\* Rempel D, Dahin L, Lundborg G. Pathophysiology of nevre compression syndromes: response of peripheral nerves to loading. J Bone Joint Surg. 1999;81(11):1600-10.

• Format for books; initials of author's names and surnames, chapter title, editor's name, book title, edition, city, publisher, date and pages.

\* Kozin SH, Bishop AT, Cooney WP. Tendinitis of the wrist. In Cooney WP, Linscheid RL, Dobins JH, eds. The wrist: diagnosis and operative



treatment. Vol. 2. St. Louis: Mosby, 1998: 1181-96.

- Article with a Digital Object Identifier (DOI):

\*Zhang M, Holman CD, Price SD, Sanfilippo FM, Preen DB, Bulsara MK. Comorbidity and repeat admission to hospital for adverse drug reactions in older adults: retrospective cohort study. *BMJ*. 2009 Jan 7;338:a2752. doi: 10.1136/bmj.a2752.

• For other reference style, please refer to "ICMJE Uniform Requirements for Manuscripts Submitted to Biomedical Journals: Sample References".

## CATEGORIES OF ARTICLES

### Original Research Articles:

Original prospective or retrospective studies of basic or clinical investigations in areas relevant to medicine.

Content: - Abstract (200-250 words; the structured abstract contain the following sections: Objective, material and methods, results, conclusion; both in Turkish and English)

- Introduction
- Material and Methods
- Results
- Discussion/ Conclusion
- Acknowledgements
- References

\*Original articles should be no longer than 5000 words and should include no more than 6 figures / tables and 40 references.

### Review Articles

The authors may be invited to write or may submit a review article. Reviews including the latest medical literature may be prepared on all medical topics. Authors who have published materials on the topic are preferred.

Content: - Abstract (200-250 words; without structural divisions; both in Turkish and English)

- Titles on related topics
- References

\* These manuscripts should be no longer than 5000 words and include no more than 4 figures and tables and 100 references.

### Short Communications

It should be no longer than 2000 words and include no more than 2 figures and tables and 20 references.

### Case Reports

Brief descriptions of a previously undocumented disease process, a unique unreported manifestation or treatment of a known disease process, or unique unreported complications of treatment regimens. They should include an adequate number of photos and figures.

Content: - Abstract (average 100-150 words; without structural divisions; both in Turkish and English)

- Introduction
- Case report
- Discussion
- References

### Letter to the Editor

These are the letters that include different views, experiments and questions of the readers about the manuscripts that were published in this journal in the recent year.

Content: - There's no title, abstract, any figures or tables

- It should be no more that 500 words, the number of references should not exceed 5.
- Submitted letters should include a note indicating the attribution to an article (with the number and date) and the name, affiliation and address of the author(s) at the end.
- The answer to the letter is given by the editor or the author(s) of the manuscript and is published in the journal.

### Checklist

The manuscript should be prepared as separate files in the following order:

1. Cover Letter
2. Title Page
3. Abstract
4. Main Text (text, acknowledgments, references, tables, and figure legends)
5. Figures
6. Copyright Form

