

European Research Journal

4th Uludağ Cardiology Summit



4. Uludağ
KARDİYOLOJİ Zirvesi

07-10 Mart 2024, Grand Yazıcı Otel - Uludağ

Volume 10 Supplement 1 March 2024

Available at <https://dergipark.org.tr/en/pub/eurj>

© 2024 by Prusa Medical Publishing



The European Research Journal

Aim and Scope

The European Research Journal (EuRJ) is an international, independent, double-blind peer reviewed, Open Access and online publishing journal, which aims to publish papers on all the related areas of basic and clinical medicine.

Editorial Board of the European Research Journal complies with the criteria of the International Council of Medical Journal Editors (ICMJE), the World Association of Medical Editors (WAME), and Committee on Publication Ethics (COPE).

The journal publishes a variety of manuscripts including original research, case reports, invited review articles, technical reports, how-to-do it, interesting images and letters to the editor. The European Research Journal has signed the declaration of the Budapest Open Access Initiative. All articles are detected for similarity or plagiarism. Publication language is English. The journal does not charge any article submission or processing charges.

EuRJ recommends that all of our authors obtain their own ORCID identifier which will be included on their article.

The journal is published bimonthly (January, March, May, July, September, and November).

Abstracting and Indexing

The journal is abstracted and indexed with the following: ULAKBİM TR Index (ULAKBİM TR DİZİN), NLM Catalog (NLM ID: 101685727), Google Scholar (h-index: 12), Index Copernicus (ICV 2022: 100), EMBASE, ProQuest Central, EBSCO Academic Search Ultimate, ROAD, SciLit, MIAR (ICDS 2021: 3.8), J-Gate, SHERPA/RoMEO, BASE, EZB, CrossRef, JournalTOCs, WorldCat, TURK MEDLINE, Turkish Citation Index, EuroPub, OpenAIRE, ResearchGate, SOBIAD, Advanced Science Index, ScienceGate, OUCI, Publons, (Clarivate Web of Science)

Publisher

The European Research Journal (EuRJ)
Prusa Medical Publishing
Konak Mh. Kudret Sk. Şenyurt İş Mrk. Blok No:6 İç kapı no: 3
Nilüfer/Bursa-Turkey
info@prusamp.com

www.dergipark.org.tr/eurj/
<http://www.prusamp.com>



e-ISSN: 2149-3189

The European Research Journal, hosted by Turkish JournalPark ACADEMIC, is licensed under a Creative Commons Attribution-NonCommercial-NoDerivatives 4.0 International License.



EDITORIAL BOARD

EDITOR-IN-CHIEF

Senol YAVUZ, MD,

Professor,

University of Health Sciences, Bursa Yuksek Ihtisas Training & Research Hospital,
Department of Cardiovascular Surgery,
Bursa, Turkey,

MANAGING EDITORS

Nizameddin KOCA, MD,

Associate Professor,

University of Health Sciences, Bursa Şehir Training & Research Hospital,
Department of Internal Medicine,
Bursa, Turkey

Soner CANDER, MD

Professor,

Uludag University Medical School,
Department of Endocrinology and Metabolism
Bursa, Turkey

Mesut ENGİN, MD,

Associate Professor,

University of Health Sciences, Bursa Yuksek Ihtisas Training & Research Hospital,
Department of Cardiovascular Surgery,
Bursa, Turkey

FOUNDING EDITOR

Rustem ASKIN, MD,

Professor of Psychiatry

İstanbul Ticaret University, Department of Psychology
İstanbul, Turkey

EDITORIAL ASSISTANT

Ugur BOLUKBAS

4th Uludağ Cardiology Summit



4. Uludağ KARDİYOLOJİ Zirvesi

07-10 Mart 2024, Grand Yazıcı Otel - Uludağ

Organizasyon Sekreteryası



Dear colleagues,

We are pleased to invite you to the 4th Uludağ Cardiology Summit to be held at Grand Yazıcı Hotel Uludağ between 7 – 10 March 2024.

This year's congress will feature the latest developments in cardiology with sessions that include both theoretical and practical presentations. Developments in the field of cardiology will be discussed in the presence of expert speakers. During the Congress; it is aimed to evaluate developments in diagnosis and treatment spectrum in the light of current approaches. Research and projects in the field of cardiology can be presented and experiences can be shared with oral presentation sessions.

The success of the congress will be possible with your active participation. Looking forward to meeting in the winter of 2024 and having a successful, productive congress...

Doç. Dr. Mehmet MELEK
Congress President

4th Uludag Cardiology Summit Organizing Committee

Congress President

Doç. Dr. Mehmet MELEK

Congress General Secretary

Prof. Dr. Dilek Yeşilbursa

Congress Secretary

Prof. Dr. Hakan Erkan

Bursa Uludag University, Faculty of Medicine, Department of Cardiology

Prof. Dr. Tunay Şentürk
Prof. Dr. Sümeyye Güllülü
Prof. Dr. Dilek Yeşilbursa
Prof. Dr. Bülent Özdemir
Prof. Dr. Mustafa Yılmaz
Prof. Dr. Alparslan Birdane
Doç. Dr. Şeyda Günay Polatkan

University of Health Sciences, Bursa Faculty of Medicine Bursa Yüksek İhtisas Training and Research Hospital, Department of Cardiology

Prof. Dr. Mehmet Demir
Prof. Dr. Hasan Arı
Doç. Dr. Mehmet Melek
Doç. Dr. Fahriye Vatansever Ağca
Doç. Dr. Ahmet Tütüncü

Bursa City Hospital Department of Cardiology

Prof. Dr. Hakan Erkan
Doç. Dr. Mustafa Adem Yılmaztepe
Doç. Dr. Selma Kenar Tiryakioğlu

Scientific Committee Members


Prof. Dr. Tunay Őentürk
Prof. Dr. Sümeyye Güllülü
Prof. Dr. Dilek YeŐilbursa
Prof. Dr. Bülent Özdemir
Prof. Dr. Mustafa Yılmaz
Prof. Dr. Alparslan Birdane
Doç. Dr. Őeyda Günay Polatkan
Prof. Dr. Mehmet Demir
Prof. Dr. Hasan Arı
Doç. Dr. Mehmet Melek
Doç. Dr. Fahriye Vatansever Ağca
Doç. Dr. Ahmet Tütüncü
Prof. Dr. Hakan Erkan
Doç. Dr. Mustafa Adem Yılmaztepe
Doç. Dr. Selma Kenar Tiryakiođlu

Scientific Programme



07 MART 2024, PERŞEMBE		
	A SALONU	B SALONU
16.15 - 16.30	AÇILIŞ	
16.30 - 17.30	OTURUM - 1 HİPERTANSİYON Oturum Başkanları: Dr. Aytül Belgi, Dr. Alparslan Birdane	
16.30 - 16.42	2023 ESH Kılavuzu Hipertansiyona Yaklaşımımızı Değiştirdi mi? Dr. Fatih Sinan Ertaş	
16.42 - 16.54	Nefroloji Uzmanı Gözüyle Dirençli Hipertansiyona Bakış Dr. Abdülmecit Yıldız	
16.54 - 17.06	Endokrinoloji Uzmanı Gözüyle Dirençli Hipertansiyona Bakış Dr. Metin Güçlü	
17.06 - 17.18	Hipertansif Acillerin Yönetimi Nasıl Olmalıdır ? Dr. Servet Altay	
17.18 - 17.30	Tartışma	
17.30 - 17.50	ARA	
17.50 - 18.30	UYDU SEMPOZYUM - 1  Oturum Başkanı: Dr. Mehmet Akbulut Pulmoner Hipertansiyonda Geleceği Bugünden Görebilmek Dr. Cihangir Kaymaz	
19.30 - 21.30	AKŞAM YEMEĞİ	
08 MART 2024, CUMA		
	A SALONU	B SALONU
09.00 - 10.00	OTURUM - 2 KAPAK HASTALIKLARI: HER YÖNÜYLE AORT KAPAK Oturum Başkanları: Dr. İrem Dinçer, Dr. Dilek Yeşilbursa	SÖZLÜ BİLDİRİ OTURUMU - 1 Oturum Başkanları: Dr. Vedat Koca, Dr. Yusuf Ata
09.00 -	Aort Kapağın Anatomisi ve Multimodalite Görüntüleme	Sağ Ventrikülde Davetsiz Misafir: Kardiyak Kist Hidatik /

09.12	Dr. Özge Özden	The Intruder in the Right Ventricle : Cardiac Cyst Hydatidic
09.12 – 09.24	İzole ve Kombine Aort Kapak Hastalıklarında Girişim Zamanlaması Dr. Demet Menekşe Gerede	<u>Harun Şenocak</u> , Çetin Alak, Dilek Yeşilbursa, Bülent Özdemir
09.24 – 09.36	Cerrah Gözüyle Aort Kapak Cerrahisinin Zorlukları (Kapak Seçimi, Kök Genişletme, Tamir vb.) Dr. Şenol Yavuz	Bir Varmış Bir Yokmuş Sağ Atriyumda Trombüs / Once Upon A Time, Thrombus In The Right Atrium <u>Ayşe Nilgün Kara</u> , Çetin Alak, Alparslan Birdane
09.36 – 09.48	Disfonksiyone Protez Kapağı Nasıl Yöneteyim? (Hasta-Kapak Uyumsuzluğu, Pannus, Stenoz vb.) Dr. Ebru Özpelit	İshalden Kalbe! Triküspit Kapak Endokarditi / From Diarrhea to the Heart! Tricuspid Valve Endocarditis <u>Ali Melik Doğan</u> , Çetin Alak, Tunay Şentürk, Murat Biçer
09.48 – 10.00	Tartışma	Gerçekten Deliryum mu? : Kontrasta Bağlı Ensefalopati / Delirium or Not?: Contrast Induced Encephalopathy <u>Samatar Adam</u> , Çetin Alak, Bülent Özdemir Atipik Prezantasyonlu Perikardiyal Efüzyon Olgusu / A Case Of Pericardial Effusion With Atypical Presentation <u>Ömer Faruk Kahraman</u> , Mehmet Taşci, Mehmetcan Çilğın, Enes İsmet Erkoç, Hasan Arı A Rare Cause of Aortic Interruption: Mid Aortic Syndrome Esra Akpınar, <u>Ayşe Dilara Balyımez</u> , Bilal Mete Ülker, Ömer Faruk Kahraman, Soner Aksüyek, Fatih Koca, Mehmet Taşci, Hasan Arı
10.00 – 10.20	ARA	
10.20 – 11.00	UYDU SEMPOZYUM - 2  Oturum Başkanı: Dr. Yüksel Çavuşoğlu Olgular Eşliğinde; Kalp Yetersizliği ve Konjesyon Tedavisinde Tolvaptan'ın Yeri Dr. Saim Sağ	SÖZLÜ BİLDİRİ OTURUMU - 2 Oturum Başkanları: Dr. Hasan Arı, Dr. Ufuk Aydın Miyokart infarktüsü sonrası gelişen ventriküler septal rüptürün perkütan kateter temelli kapatma deneyimi ve işlem sırasında yaşanan güçlükler; 2 vaka ile klinik tecrübe paylaşımı / Experience with Percutaneous Catheter-Based Closure of Ventricular Septal Rupture Developing After Myocardial Infarction and Difficulties Encountered During the Procedure; Sharing Clinical Experience with 2 Cases <u>Hilal Erken</u> , Saadet Demirtaş İnci, Gürkan İş, Muhammed Erzurum, Sadık Açikel, İbrahim Hakan Güllü Kalp yetmezliği hastasında sağ koroner arterden sağ pulmoner artere açılan fistülün transkateter koil embolizasyonla başarılı tedavisi / Successfully Treated

		<p>With Transcatheter Coil Embolization Right Coronary Artery Fistula To Right Pulmonary Artery in A Patient With Heart Failure <u>Umut Uyan</u></p> <p>İatrojenik Mitral Kapak Perforasyonunun Perkütan Onarımı / Percutaneous Closure of an Iatrogenic Mitral Valve Perforation <u>Hatice Feyza Dilek</u>, Hilal Erken, Saadet Demirtaş İnci, Gürkan İş, İbrahim Hakan Güllü</p> <p>Closure of a Paravalvular Leak Between Ring and Valve: A Case Report <u>Ertan Ekici</u>, Hilal Erken Pamukçu, Sinan Cemgil Özbek, Buse Çuvalcıoğlu, İbrahim Hakan Güllü</p>
11.00 - 11.20	ARA	
11.20 - 12.20	<p>OTURUM - 3 8 MART DÜNYA KADINLAR GÜNÜNDE KADIN KALBI Oturum Başkanları: Dr. Merih Kutlu, Dr. Bilgin Timuralp, Dr. Dilek Çiçek Yılmaz</p>	<p>SÖZLÜ BİLDİRİ OTURUMU - 3 Oturum Başkanları: Dr. Mustafa Yıldız, Dr. Hakan Özkan</p> <p>The Effect of Emergency Department Delay Time on All Cause Mortality of ST-Segment Elevation Myocardial Infarction Patients Who Underwent Primary Percutaneous Intervention <u>Ercan Taştan</u></p> <p>Göğüs Ağrısı + Troponin Yüksekliği ≠ Akut Koroner Sendrom / Chest Pain + Elevated Troponin Levels ≠ Acute Coronary Syndrome <u>Orkhan Yunisli</u>, Çetin Alak, Dilek Yeşilbursa</p> <p>Akut Koroner Sendroma Neden Olan Sağ ve Sol Ön İnen Koroner Arterler Arasındaki İnterkoroner Devamlılık / Intercoronary Continuity Between The Right and Left Anterior Descending Coronary Arteries Causing Acute Coronary Syndrome <u>Mustafa Yıldız</u>, Sait Altıntaş, Hasan Ali Barman, Rıdvan Türkmen, İffet Doğan, Nurullah Yücel, Serkan Arslan</p> <p>Alerji İlişkili Akut Koroner Sendrom:Kounis Sendromu / Allergy Related Acute Coronary Syndrome: Kounis Syndrome <u>Mustafa Kani Gözcü</u>, Doğan Ormancı, Ömer Faruk Kahraman, Mahmut Kapsız, Davut Davutoğlu, Abdulsamet Arslan, Mehmet Taşçı, Ayşe Dilara Balyımez, Muhammed Nusret Ak, Bilal Mete Ülker, Esra Akpınar, Ahmet Fatih Kışpınar, Haydar Selçuk Demiray, Hasan Arı,</p>
11.20 - 11.32	<p>Kadınlarda Koroner Arter Hastalığı Dr. Nihan Çağlar</p>	
11.32 - 11.44	<p>Kadınlarda Aritmi Dr. Ayşen Ağaçdiken</p>	
11.44 - 11.56	<p>Gebelik ve Kalp Hastalıkları Dr. Kadriye Kılıçkesmez</p>	
11.56 - 12.08	<p>Kadın Kardiyolog Olmak Dr. Necla Özer</p>	
	<p>Tartışma</p>	

12.08 – 12.20		<p>Tahsin Bozat</p> <p>Akut Koroner Sendrom Hastalarında No-Reflow Fenomeni Gelişimi ve Lenfosit/HDL Oranının İlişkisi / Relationship Between the Development of No-Reflow Phenomena and Lymphocyte/HDL Ratio in Acute Coronary Syndrome Patients</p> <p><u>Ömer Faruk Kahraman</u>, Ömer Furkan Demir, Doğan Ormancı, Barış Şensoy</p> <p>ST Yükselmeli Miyokard Enfarktüsü ve Şiddetli Aort Darlığı Olan Hastada Kardiyak Arrestin Etkin Yönetimi: Çok Disiplinli Bir Yaklaşım / Effective Management of Cardiac Arrest With ST-Elevation Myocardial Infarction And Severe Aortic Stenosis Patient: A Multidisciplinary Approach</p> <p>Fatma Esin, <u>Yalın Çetin</u></p>
12.20 – 14.00	ÖĞLE YEMEĞİ	
14.00 – 14.40	<p>UYDU SEMPOZYUM - 3</p> <p></p> <p>Oturum Başkanı: Dr. Mehmet Baran Karataş</p> <p>Kardiyovasküler Korumada Eksik Parça Tamamlandı: Kolşisinin Kardiyovasküler Korumadaki Yeri</p> <p>Dr. Regayip Zehir</p>	<p>SÖZLÜ BİLDİRİ OTURUMU - 4</p> <p>Oturum Başkanları: Dr. İbrahim Baran, Dr. Ilgın Karaca</p> <p>Acute Coronary Syndrome in a Young Patient with Subsequent Psoriasis Diagnosis: A Case Report</p> <p><u>Hüseyin Tezcan</u>, Zafer Büyükerzi</p> <p>Relationship Between Triglyceride/High Density Lipoprotein Cholesterol Ratio and Functional Significance of Coronary Lesions</p> <p>Can Özkan, Orhan Karayığıt, <u>Nil Helvacıoğlu</u></p> <p>Wellens Sendromu: 70 Yaşındaki Hastada Koroner Spazm Olgusu / Wellens Syndrome Unveiled: A Case Report of Coronary Spasm in a 70-Year-Old Patient</p> <p><u>Almina Erdem</u>, Mustafa Oğuz, Hatice Altınışik, Yusuf Turan Gül, Ahmet Lütfullah Orhan</p> <p>The Effect of Naples Prognostic Score in Predicting Saphenous Vein Graft Disease in Patients with Coronary Bypass</p> <p>Akın Torun, <u>Şahhan Kılıç</u>, Mehmet Şeker, Serkan Dilmen, Selami Doğan, Samet Yavuz, Didar Mirzamidinov</p>
14.40 – 15.00	ARA	

15.00 - 16.00	<p>OTURUM - 4</p> <p>KALP YETERSİZLİĞİ: ATRİYAL FİBRİLASYON + İLERİ MİTRAL YETERSİZLİĞİ + DAL BLOKU + RENAL YETERSİZLİKLİ DEF-KY HASTASINDA</p> <p>Oturum Başkanları: Dr. Yüksel Çavuşoğlu, Dr. Fatih Duhan Bayrak</p>	<p>SÖZLÜ BİLDİRİ OTURUMU - 5</p> <p>Oturum Başkanları: Dr. Enbiya Aksakal, Dr. Erhan Tenekecioğlu</p> <p>A Case of Massive Pulmonary Embolism in a Hemodynamically Stable Elderly Patient: Anticoagulation, Thrombolytic or Surgical Treatment?</p> <p><u>İrem Yılmaz</u>, Mustafa Oğuz, Mehmet Uzun</p>
15.00 - 15.12	<p>Bu Hastanın Tedavisi AF'de Ritim Kontrolünden Geçer</p> <p>Dr. Fethi Kılıçaslan</p>	<p>Comparison of Thyroid Function Tests of Newly Diagnosed Hypertension Patients with the Healthy Control Group</p> <p><u>Sabri Abuş</u></p>
15.12 - 15.24	<p>Bu Hastanın Tedavisi Cihazdan Geçer (CRT/D, LVAD vb.)</p> <p>Dr. Ahmet Vural</p>	<p>Evaluation of Increase in the Adhesion Molecules (ICAM-1, VCAM-1) According to the Types of Atrial Fibrillation</p> <p><u>Hakan Kilci</u>, Köksal Ceyhan, Lütfü Bekar</p>
15.24 - 15.36	<p>Bu Hastanın Tedavisi MY'nin Tedavisinden Geçer (Mitraklip, Cerrahi vb.)</p> <p>Dr. Hakan Uçar</p>	<p>Alt Ekstremitte Periferik Arter Hastalarında Kronik İnflamasyon Belirteci: Platelet Albumin Oranı / Chronic Inflammation Marker in Lower Extremity Peripheral Artery Patients: Platelet Albumin Ratio</p> <p><u>Gürkan İş</u>, Hilal Erken</p>
15.36 - 15.48	<p>Bu Hastanın Tedavisi Renal Replasman Tedavisinden Geçer</p> <p>Dr. Mehmet Birhan Yılmaz</p>	<p>Gebelik Sırasında Çift Yönlü Ventriküler Taşikardi Tanısı Alan Andersen-Tawil Sendromu / Andersen-Tawil Syndrome Diagnosed with Bidirectional Ventricular Tachycardia During Pregnancy</p> <p><u>Mustafa Yıldız</u>, Hasan Ali Barman, Ömer Doğan, Bengisu Keskin Meriç, Şükrü Arslan, Nurullah Yücel, Rıdvan Türkmen, İffet Doğan, Serkan Arslan</p>
15.48 - 16.00	<p>Tartışma</p>	<p>Normotansif Hastalarda Non-dipper Paternini Öngören Naples Prognostik Skorunun Kullanılabilirliği / Usability of Naples Prognostic Score Predicting Non-dipper Pattern in Normotensive Patients</p> <p><u>Tuba Unkun</u></p>
16.00 - 16.20	ARA	
	<p>UYDU SEMPOZYUM - 4</p> <p></p>	<p>SÖZLÜ BİLDİRİ OTURUMU - 6</p> <p>Oturum Başkanları: Dr. Mehmet Melek, Dr. Ahmet Tütüncü</p>


16.20 - 17.00	<p>Oturum Başkanı: Dr. Dilek Yeşilbursa</p> <p>Hiperlipidemi Tedavisinde Güncel Tedavi Yaklaşımları ve Kombine Tedavinin Önemi</p> <p>Dr. Sadi Güleç</p>	<p>Transradyal Kataterizasyon Sırasında Radyal Arter Spazmı / Radial Artery Spasm During Transradial Catheterization</p> <p><u>Şahhan Kılıç</u>, Mustafa Oğuz, Süha Asal, Kenan Kadırlı, Ahmet Lütfullah Orhan</p> <p>Effect of Glyceryl Trinitrate-Containing or Lidocaine-Containing Cream Applications Before Transradial Coronary Angiography on Procedure Success and Complications</p> <p>Nurullah Uslu, Aykut Demirkıran, Cihan Aydın, <u>Hüseyin Aykaç</u></p> <p>A Rare Complication After Transradial Intervention: Sterile Granuloma</p> <p><u>Fahrettin Tuğrul Çitekçi</u>, Zeynep Yapan Emren, Sadık Volkan Emren, Narmina Ahmadlı</p> <p>A Case with Coronary Perforation</p> <p><u>Mustafa Yılmaz</u>, Sefa Erdi Ömür</p>
17.00 - 17.20	ARA	
17.20 - 18.20	<p>OTURUM - 5</p> <p>GİRİŞİMSEL KARDİYOLOJİ</p>   <p>Oturum Başkanları: Dr. Mehmet Ertürk, Dr. Mehmet Demir</p>	
17.20 - 17.32	<p>Girişimsel İşlemlerde Gri Alanlar (Trombüs Aspirasyonu, Peri Prosedürel Antitrobotikler, Yaşlı Hasta (>80 Yaş), Mekanik Destek Cihazları vb.)</p> <p>Dr. Taner Şeker</p>	<p>SÖZLÜ BİLDİRİ OTURUMU - 7</p> <p>Oturum Başkanları: Dr. Selçuk Kanat, Dr. Tunay Şentürk</p>
17.32 - 17.44	<p>Zorlu Bifurkasyona Yaklaşım (Medina 0,0,1 ve 90 derece)</p> <p>Dr. Şükrü Akyüz</p>	<p>Paget-Schroetter Sendromu ve Pil Disfonksiyonu Gelişen Bir Hastada Başarılı Lead Ekstraksiyonu ve Tekrar Pil İmplantasyonu / Successful Lead Extraction and Repeat Pacemaker Implantation in a Patient with</p>
17.44 - 17.56	<p>FFR ve IVUS Kılavuzluğunda Koroner Girişim</p> <p>Dr. Nihat Kalay</p>	<p>Paget-Schroetter Syndrome and Pacemaker Dysfunction</p> <p><u>Gökhun Akkan</u>, Tuncay Kırış, Emre Özdemir, Mustafa Karaca</p>
17.56 - 18.08	<p>Kalsifik Lezyona Yaklaşım</p> <p>Dr. Kürşat Tigen</p>	
	<p>Tartışma</p>	<p>Şizofreni Hastalarında Yeni Ventriküler Aritmi Belirteçlerinin Değerlendirilmesi / Evaluation of Novel</p>

18.08 – 18.20	<p>Ventricular Arrhythmia Markers in Patients with Schizophrenia Yaşar Kapıcı, Sabri Abuş</p> <p>Malign Melanomlu Bir Hastada Atriyoventriküler Düğüm İnvazyonuna Bağlı Tam Atriyoventriküler Blok / Complete Atrioventricular Block Due to Atrioventricular Node Invasion in a Malignant Melanoma Akin Torun, Şahhan Kılıç, Samet Yavuz, Yusuf Turan Gül, Yiğithan Okar, Mehmet Uzun</p> <p>Kalp Yetmezliği Olan Hastalarda Sağ Ventriküler Pacing'den Kardiyak Resenkronizasyon Tedavisine Yükseltmenin Etkileri ve Çift Odacıklı Defibrilatör ile Karşılaştırma / Effects of Upgrading from Right Ventricular Pacing to Cardiac Resynchronization Therapy and Comparison with Dual-Chamber Defibrillator in Patients with Heart Failure Mücahit Yarar, Hasan Arı, Mehmet Melek, Ahmet Tütüncü, Selma Arı, Tahsin Bozat, Mehmet Can Çılgın, Soner Aksüyek, Seray Yazgan, Enes İsmet Erkoç, Hüseyin Akdoğan, Doğan Ormancı, Ömer Faruk Kahraman, Bilal Mete Ülker, Esra Akpınar</p> <p>ICD İmlante Etsem mi Etmesem mi? İşte Bütün Mesele Bu! / ICD or No ICD? That is the Question! Selin Abdu, Çetin Alak, Nazmiye Sümeyye Güllülü</p> <p>Epileptik Nöbet ile Karışan Malign Ventriküler Aritmi Elektriksel Fırtınası / Electrical Storm of Malignant Ventricular Arrhythmia Confused with Epileptic Seizure Ataç Çelik, Yağmur Demirezen</p>
------------------	---

19.30 – 21.30	AKŞAM YEMEĞİ
------------------	---------------------

09 MART 2024, CUMARTESİ

	A SALONU	B SALONU
09.00 – 10.00	<p>OTURUM – 6 ARİTMİ ve ANİ KARDİYAK ÖLÜM Oturum Başkanları: Dr. Sedat Köse, Dr. Basri Amasyalı</p>	<p>SÖZLÜ BİLDİRİ OTURUMU – 8 Oturum Başkanları: Dr. Başar Candemir, Dr. Hakan Erkan</p>
09.00 – 09.12	<p>İleti Sistemi Pacing: Kime, Nasıl? Dr. Uğur Canpolat</p>	<p>Challenging Rotablator Case Accompanied by IVUS Zeynep Pelin Orhan, Atıla Bitigen, Kudret Keskin</p>
09.12 – 09.24	<p>Şoklayan ICD Hastasını Nasıl Yönetelim? Dr. Kutay Vurgun</p>	<p>Carotid Stent Migration, A Rare Late Complication and Its Management İbrahim Aktaş</p>

09.24 - 09.36	Bütün SVT'lere Ablasyon Yapalım mı? Dr. Nihal Akar	Stent Sıyrılması Sonrası Total Olan RCA'nın Subintimal Geçiş ile Tedavisi / Treatment of Total Ocluded RCA Because of Stent Detachment with Subintimal Crossing <u>Seray Yazgan</u> , Enes İsmet Erkoç, Hüseyin Akdoğan, Doğan Ormancı, Ömer Faruk Kahraman, Bilal Mete Ülker, Esra Akpınar, Ayşe Dilara Balyımez, Ahmet Fatih Kışpınar, Abdulsamet Arslan, Mehmet Taşçı, Muhammed Nusret Akin, Erhan Tenekecioğlu, Hasan Arı
09.36 - 09.48	Olgularla Cihaz İlişkili Enfeksiyonlar ve Yönetimi Dr. Barış Akdemir	Percutaneous Treatment of Pseudoaneurysm with Graft Stent After Intervention of the Left Main Coronary Artery <u>Soner Aksüyek</u> , Hasan Arı, Tahsin Bozat
09.48 - 10.00	Tartışma	Radial Artery Perforation and Its Treatment During Percutaneous Coronary Intervention Ayşe Dilara Balyımez, <u>Bilal Mete Ülker</u> , Esra Akpınar, Seray Yazgan, Mustafa Gözcü, Mehmetcan Çilğın, Hasan Arı, Tahsin Bozat Koroner Anomalili Hastalarda Atriyal Septal Defektin Transkateter Kapatılması / Transcatheter Closure Of Atrial Septal Defect in Patients With Coronary Anomal Ahmet Fatih Kışpınar, Ayşe Dilara Balyımez, <u>Bilal Mete Ülker</u> , Esra Akpınar, Doğan Ormancı, Soner Aksüyek, Mehmet Taşçı, Abdulsamet Arslan, Mustafa Kani Gözcü, Davut Davutoğlu, Ömer Furkan Demir, Selma Arı, Mehmet Melek, Fahriye Vatansever Ağca, Hasan Arı
10.00 - 10.20	ARA	
10.20 - 11.00	UYDU SEMPOZYUM - 5  Oturum Başkanı: Dr. Tunay Şentürk Kararın Fark Yaratsın: Forziga Tedavisi Dr. Mehmet Birhan Yılmaz	SÖZLÜ BİLDİRİ OTURUMU - 9 Oturum Başkanları: Dr. Ethem Kumbay, Dr. Aysel Aydın Kaderli Biventricular Noncompaction with Ascending Aortic Dilatation Presenting with Congestive Heart Failure: A Rare Case of Nonischemic Cardiomyopathy <u>Onur Argan</u> , Eyup Avci Akut Kalp Yetmezliği Hastalarında Prognostik Nutrisyonel İndeksinin (PNI) Mortalite Üzerine Etkisinin Değerlendirilmesi / Evaluation of the Effect of Prognostic Nutritional Index On Mortality in Acute Heart Failure

		Alperen Taş, <u>Mehmet Taha Özkan</u> , Ayşe Nur Özkaya, Çağatay Tunca, Muhammed Erzurum Evaluation of Medication Use in Heart Failure Patients: An Observational Study <u>Sena Ustaömer</u> , Nurten Sayar, Murat Sünbül, Ümit Öztürk, Zekeriya Doğan, Mesut Sancar Multidisciplinary Management of a Common Variable Immunodeficiency Case with Myopericarditis <u>Yiğit Yaren</u> , Selin Abdu, Şeyda Günay-Polatkan, Gökhan Gökcalp
11.00 - 11.20	ARA	
11.20 - 12.20	OTURUM - 7 KORONER ARTER HASTALIĞI Oturum Başkanları: Dr. Engin Bozkurt, Dr. Mustafa Yılmaz	KARDİYAK YOĞUN BAKIM HEMŞİRELİĞİ -1 Oturum Başkanları: Dr. Mustafa Adem Yılmaztepe, Dudu Biler, Sevil Tecir
11.20 - 11.30	OLGU-1; CCS-III Stabil LMCA Lezyonu Olan 75 Yaşında Hasta Cerrahi Tedavi Daha Uygundur Dr. Mehmet Tuğrul Göncü	11.20 - 11.32 Sistemik EKG Analizi ve Ritim Bozuklukları Fatma İnanlı
11.30 - 11.40	OLGU-1; CCS-III Stabil LMCA Lezyonu Olan 75 Yaşında Hasta Girişimsel Tedavi Daha Uygundur Dr. Nazif Aygül	11.32 - 11.44 Kalp Yetersizliği Hastalarında Hemşirelik Bakımı Züleyha Erdağı
11.40 - 11.50	Tartışma	11.44 - 11.56
11.50 - 12.00	OLGU-2; AKS Nedeniyle PKG Yapılan 75 Yaşında Hasta DAPT Ne Zaman Daha Kısa? Dr. İrfan Barutçu	Kalıcı Pacemaker & ICD Hastalarında Hemşirelik Bakımı Öznur Acar
12.00 - 12.10	OLGU-2; AKS Nedeniyle PKG Yapılan 75 Yaşında Hasta DAPT Ne Zaman Daha Uzun? Dr. Davran Çiçek	11.56 - 12.08 Kardiak Arrest'ten Dönen Hastada Hemşirelik Bakımı Hüseyin Baykal
12.10 - 12.20	Tartışma	12.08 - 12.20 Tartışma
12.20 - 14.00	ÖĞLE YEMEĞİ	
14.00 - 14.40	UYDU SEMPOZYUM - 6  Oturum Başkanı: Ertuğrul Okuyan Koronar İlaç Kaplı Balonlar Ömer Göktekin	KARDİYAK YOĞUN BAKIM HEMŞİRELİĞİ - 2 Oturum Başkanları: Dr. Selma Arı, Eylem Gürdoğan

14.40 - 15.00	ARA	14.00 - 14.12 AF'de Antikoagulan Kullanımı ve Hemşirelik Yaklaşımı Hamide Baykan Karadaş
15.00 - 16.00	OTURUM - 8 PULMONER HİPERTANSİYON Oturum Başkanları: Dr. Sümeyye Güllülü, Dr. Mehmet Akbulut	
15.00 - 15.12	PH'de Sağ Ventrikülün İleri Ekokardiyografik Değerlendirmesi Dr. Fahriye Vatansever Ağca	14.12 - 14.24 Ventilatöre Bağlı Hasta Takibi ve Bakımı Kevser Oral
15.12 - 15.24	PH'de Kalp Kateterizasyonunun İncelikleri Dr. Burçak Kılıçkiran Avcı	14.24 - 14.36 Akut Koroner Sendromlu Hastalarda Hemşirelik Bakımı Ayşegül Akkaya
15.24 - 15.36	PVR'si Yüksek (4 - 8 WU) Olan ASD/VSD/PDA Hastasını Nasıl Yönetelim? Dr. Omaç Tüfekçioğlu	14.36 - 14.40 Tartışma
15.36 - 15.48	KTEPH Hastasının Tedavi Yönetimi Nasıl Olmalıdır? Dr. Murat Biçer	KATETER LABORATUARI HEMŞİRELİĞİ - 1 Oturum Başkanları: Dr. Tolga Doğan, Ercan Karabey
15.48 - 16.00	Tartışma	15.00 - 15.12 Kompleks Koroner & Vasküler Girişimlerde Anjiyografi Hemşireliği Nurullah Kaya
16.00 - 16.20	ARA	
16.20 - 17.00	UYDU SEMPOZYUM - 7  Oturum Başkanı: Dr. Kudret Aytemir Olgularla 3 Boyutlu Haritalama Sistemi Eşliğinde Ablasyon Yaklaşımları Dr. Hikmet Yorgun	15.12 - 15.24 IVUS, FFR, Rotablatör İşlemlerinde Salon, Hasta ve Malzeme Hazırlığı Sümeyye Gedik
17.00 - 17.20	ARA	15.24 - 15.36 TAVİ İşleminde Salon, Hasta ve Malzeme Hazırlığı Yüksel Çiçek
17.20 - 18.20	OTURUM - 9 HER TELDEN KARDİYOLOJİ Oturum Başkanları: Dr. Ertuğrul Okuyan, Dr. Bülent Özdemir	
17.20 - 17.28	Yüksek Riskli PFO'nun Belirlenmesi ve Hasta Seçimi Dr. Şeyda Günay Polatkan	15.36 - 15:48 Radyasyon Güvenliği Mehmet Yılmaz

17.28 - 17.36	Kardiyoloji'de Yapay Zeka Uygulamaları Sercan Okutucu	15.48 - 16.00 Tartışma
17.36 - 17.44	Plak Ruptürü ve Trombüs Dışı AKS Sebepleri Ataç Çelik	KATETER LABORATUARI HEMŞİRELİĞİ - 2 Oturum Başkanları: Dr. Alper Karakuş, Zeynep Atçeken, Zülfıye Tay Göven
17.44 - 18.52	Herkes Kolşisin Verelim mi? Atilla Bitigen	16.20 - 16.32 EPS ve Ablasyon İşlemlerinde Anjiyografi Hemşireliği Doğukan Dülger
17.52 - 18.00	Aritmojenik Mitral Kapak Prolapsusu Dr. Elif Eroğlu	16.32 - 16.44 Kalıcı Pacemaker & ICD İşlemlerinde Salon, Hasta ve Malzeme Hazırlığı Gamze Gelen
18.00 - 18.08	Kardiyoonkolojide Zor Olgular, Zor Kararlar Dr. Cafer Zorkun	16.44 - 16.56 Kardiyak Destek Cihazlarının Kullanımı ve Laboratuvar Hazırlığı Eşe Hanım Karaoğlu
18.08 - 18.20	Tartışma	16:56 - 17:00 Tartışma
19.30 - 21.30	ARA	

10 MART 2024, PAZAR

	A SALONU	B SALONU
09.00 - 10.00	OTURUM - 10 GİRİŞİMSSEL İŞLEMLERDE KOMPLİKASYON YÖNETİMİ Oturum Başkanları: Dr. Cevat Kıрма, Dr. Tahsin Bozat	Akılcı İlaç Kullanımı Dr. Fatih Koca
09.00 - 09.12	Olgularla Koroner Komplikasyon Dr. Ersan Tatlı	
09.12 - 09.24	Olgularla Yapısal Komplikasyon Dr. Hakan Güllü	
09.24 - 09.36	Olgularla Pacemaker ve Ablasyon Komplikasyon Dr. Mustafa Karaca	
09.36 - 09.48	Olgularla Periferik Komplikasyon Dr. Ahmet Arif Yalçın	
09.48 - 10.00	Tartışma	
10.00 - 10.20	ARA	

10.20 - 11.20	OTURUM - 11 KARDİYOLOJİ'DE 2023 YILI GÜNCELLEMESİ: KILAVUZLAR Oturum Başkanları: Dr. Mustafa Kemal Erol, Dr. Ali Aydınlar	
10.20 - 10.28	2023 ESC Kardiyovasküler Hastalıklar ve Diyabet Kılavuzu Dr. Umut Kocabaş	
10.28 - 10.36	2023 ESC Akut Koroner Sendrom Kılavuzu Dr. Muhammet Gürdoğan	
10.36 - 10.44	2023 ESC Kardiyomiyopati Kılavuzu Dr. Selma Tiryakioğlu	
10.44 - 10.52	2023 ESC Endokardit Kılavuzu Dr. Emine Gazi	
10.52 - 11.00	2023 ACC/AHA Atriyal Fibrilasyon Kılavuzu Dr. Erkan Baysal	
11.00 - 11.08	2023 AHA/ACC Kronik Koroner Sendrom Kılavuzu Dr. Oğuz Yavuzgil	
11.08 - 11.20	Tartışma	
11.20 - 11.30	KAPANIŞ	

4th Uludag Cardiology Summit

March 7-10, 2024, Bursa, Turkey



4. Uludağ Kardiyoloji Zirvesi

7-10 Mart 2024, Bursa, Türkiye

Oral Presentations

Table of Contents

OP-01. [Successful Lead Extraction and Repeat Pacemaker Implantation in a Patient with Paget-Schroetter Syndrome and Pacemaker Dysfunction]. Paget-Schroetter Sendromu ve Pil Disfonksiyonu Gelişen Bir Hastada Başarılı Lead Ekstraksiyonu ve Tekrar Pil İmplantasyonu

Gökhun AKKAN, Tuncay KIRIŞ, Emre ÖZDEMİR, Mustafa KARACA

OP-02. Acute Coronary Syndrome in a Young Patient with Subsequent Psoriasis Diagnosis: A Case Report

Hüseyin TEZCAN, Zafer BÜYÜKTERZİ, Süleyman KANYILMAZ

OP-03. Relationship between Triglyceride/High Density Lipoprotein Cholesterol Ratio and Functional Significance of Coronary Lesions

Can ÖZKAN, Orhan KARAYİĞİT, Eda ÖZCAN

OP-04. Biventricular Noncompaction with Ascending Aortic Dilatation Presenting with Congestive Heart Failure: A Rare Case of Nonischemic Cardiomyopathy

Onur ARGAN, Eyup AVCI

OP-05. Evaluation of the Effect of Prognostic Nutritional Index on Mortality in Acute Heart Failure

Alperen TAŞ, Mehmet Taha ÖZKAN, Ayşe Nur ÖZKAYA, Çağatay TUNCA, Muhammed ERZURUM

OP-06. Evaluation of Medication Use in Heart Failure Patients: An Observational Study

Sena USTAÖMER, Nurten SAYAR, Murat SÜNBÜL, Ümit ÖZTÜRK, Zekeriya DOĞAN, Mesut SANCAR

OP-07. Evaluation of Increase in the Adhesion Molecules (ICAM-1, VCAM-1) According to the Types of Atrial Fibrillation

Hakan KILCI, Köksal CEYHAN, Lütfü BEKAR

OP-08. Wellens Syndrome Unveiled: A Case Report of Coronary Spasm in a 70-Year-Old Patient

Almina ERDEM, Mustafa OĞUZ, Hatice ALTINIŞIK, Yusuf Turan GÜL, Ahmet Lütfullah ORHAN

OP-09. [Chest Pain+Elevated Troponin Levels ≠ Acute Coronary Syndrome]. Göğüs Ağrısı+Troponin Yüksekliği≠Akut Koroner Sendrom

Orkhan YUNISLI, Çetin ALAK, Dilek YEŞİLBURSA

OP-10. [Radial Artery Spasm during Transradial Catheterization]. Transradyal Kateterizasyon Sırasında Radyal Arter Spazmı

Şahhan KILIÇ, Mustafa OĞUZ, Süha ASAL, Kenan KADİRLİ, Ahmet Lütfullah ORHAN

OP-11. The Effect of Naples Prognostic Score in Predicting Saphenous Vein Graft Disease in Patients with Coronary Bypass

Akın TORUN, Şahhan KILIÇ, Mehmet ŞEKER, Serkan DİLMEN, Selami DOĞAN, Samet YAVUZ, Didar MIRZAMIDINOV

OP-12. Complete Atrioventricular Block Due to Atrioventricular Node Onvasion in a Malignant Melanoma

Akın TORUN, Şahhan KILIÇ, Samet YAVUZ, Yusuf Turan GÜL, Yiğithan OKAR, Mehmet UZUN

OP-13. Effects of Upgrading from Right Ventricular Pacing to Cardiac Resynchronization Therapy and Comparison with Dual-Chamber Defibrillator in Patients with Heart Failure

Mücahit YARAR, Hasan ARI, Mehmet MELEK, Ahmet TÛTÛNCÛ, Selma ARI, Tahsin BOZAT, Mehmet Can ÇILGIN, Soner AKSÛYEK, Seray YAZGAN, Enes İsmet ERKOÇ, HÛseyin AKDOĞAN, Dođan ORMANCI, Ömer Faruk KAHRAMAN, Bilal Mete ÛLKER, Esra AKPINAR

OP-14. [Chronic Inflammation Marker in Lower Extremity Peripheral Artery Patients: Platelet-Albumin Ratio]. Alt Ekstremitte Periferik Arter Hastalarında Kronik İnflamasyon Belirteci: Platelet-Albümin Oranı

Gürkan İŞ, Hilal ERKEN

OP-15. Andersen-Tawil Syndrome Diagnosed with Bidirectional Ventricular Tachycardia during Pregnancy

Mustafa YILDIZ, Hasan Ali BARMAN, Ömer DOĞAN, Bengisu KESKIN MERİÇ, Şükriü ARSLAN, Nurullah YÛCEL, Rıdvan TÛRKMEN, İffet DOĞAN, Serkan ARSLAN

OP-16. Intercoronary Continuity between the Right and Left Anterior Descending Coronary Arteries Causing Acute Coronary Syndrome

Mustafa YILDIZ, Sait ALTINTAŞ, Hasan Ali BARMAN, Rıdvan TÛRKMEN, İffet DOĞAN, Nurullah YÛCEL, Serkan ARSLAN

OP-17. Effect of Glyceryl Trinitrate-Containing or Lidocaine-Containing Cream Applications before Transradial Coronary Angiography on Procedure Success and Complications

Nurullah USLU, Aykut DEMIRKIRAN, Cihan AYDIN, HÛseyin AYKAÇ

OP-18. [A Rare Complication after Transradial Intervention: Sterile Granuloma]. Transradyal Girişim Sonrası Nadir Bir Komplikasyon: Steril Granülom

Fahrettin Tuđrul ÇİTEKÇİ, Zeynep YAPAN EMREN, Sadık VOLKAN EMREN, Narmina AHMADLI

OP-19. [Multidisciplinary Management of a Common Variable Immunodeficiency Case with Myopericarditis]. Miyoperikarditli Yaygın Deđişken İmmün Yetmezlik Olgusunun Multidisipliner Yönetimi

Yiđit YAREN, Selin ABDU, Şeyda GÛNAY POLATKAN, Gökhan GÖKALP

OP-20. A Case with Coronary Perforation

Mustafa YILMAZ, Sefa Erdi ÖMÛR

OP-21. [Experience with Percutaneous Catheter-Based Closure of Ventricular Septal Rupture Developing After Myocardial Infarction and Difficulties Encountered During The Procedure; Sharing Clinical Experience with 2 Cases]. Miyokart İnfarktüsü Sonrası Gelişen Ventriküler Septal RÛptürün Perkütan Kateter Temelli Kapatma Deneyimi ve İşlem Sırasında Yaşanan Güçlükler; 2 Vaka ile Klinik Tecrübe Paylaşımı

Hilal ERKEN, Saadet DEMIRTAŞ İNCİ, Gürkan İŞ, Muhammed ERZURUM, Sadık AÇIKEL, İbrahim Hakan GÛLLÛ

OP-22. Usability of Naples Prognostic Score Predicting Non-Dipper Pattern in Normotensive Patients

Tuba UNKUN

OP-23. [The Intruder in The Right Ventricle: Cardiac Cyst Hydatidic]. Sağ Ventrikülde Davetsiz Misafir: Kardiyak Kist Hidatik

Harun ŞENOCAK, Çetin ALAK, Dilek YEŞİLBURSA, Bülent ÖZDEMİR

OP-24. Challenging Rotablator Case Accompanied By IVUS

Zeynep Pelin ORHAN, Atila BİTİGEN, Kudret KESKİN

OP-25. [ICD or No ICD? That is the Question!]. ICD İmplant Etsem mi Etmesem mi? İşte Bütün Mesele Bu!

Selin ABDU, Çetin ALAK, Nazmiye Sümeyye GÜLLÜLÜ

OP-26. Electrical Storm of Malignant Ventricular Arrhythmia Confused with Epileptic Seizure

Ataç ÇELİK, Yağmur DEMİREZEN

OP-27. Allergy Related Acute Coronary Syndrome: Kounis Syndrome

Mustafa Kani GÖZCÜ, Doğan ORMANCI, Ömer Faruk KAHRAMAN, Mahmut KAPSIZ, Davut DAVUTOĞLU, Abdulsamet ARSLAN, Mehmet TAŞÇI, Ayşe Dilara BALYİMEZ, Muhammed Nusret AK, Bilal Mete ÜLKER, Esra AKPINAR, Ahmet Fatih KIŞPINAR, Haydar Selçuk DEMİRAY, Hasan ARI, Tahsin BOZAT

OP-28. Relationship between the Development of No-Reflow Phenomenon and Lymphocyte/HDL Ratio in Acute Coronary Syndrome Patients

Ömer Faruk KAHRAMAN, Ömer Furkan DEMİR, Doğan ORMANCI, Barış ŞENSOY

OP-29. [Once Upon a Time, Thrombus in the Right Atrium]. Bir Varmış Bir Yokmuş Sağ Atriyumda Trombüs

Ayşe Nilgün KARA, Çetin ALAK, Alparslan BİRDANE

OP-30. [From Diarrhea to the Heart! Tricuspid Valve Endocarditis]. İshalden Kalbe! Triküs pit Kapak Endokarditi

Ali Melik DOĞAN, Çetin ALAK, Tunay ŞENTÜRK, Murat BİÇER

OP-31. [Delirium or Not?: Contrast Induced Encephalopathy]. Gerçekten Deliryum mu?: Kontrasta Bağlı Ensefalopati

Samatar ADAM, Çetin ALAK, Bülent ÖZDEMİR

OP-32. Percutaneous Closure of an Iatrogenic Mitral Valve Perforation

Hatice Feyza DİLEK, Hilal ERKEN, Saadet DEMİRTAŞ İNCİ, Gürkan İŞ, İbrahim Hakan GÜLLÜLÜ

OP-33. Closure of a Paravalvular Leak between Ring and Valve: A Case Report

Ertan EKİCİ, Hilal ERKEN PAMUKÇU, Sinan CEMGİL ÖZBEK, Buse ÇUVALCIÖĞLU, İbrahim Hakan GÜLLÜLÜ

OP-34. Effective Management of Cardiac Arrest with ST-Elevation Myocardial Infarction and Severe Aortic Stenosis Patient: A Multidisciplinary Approach

Fatma ESİN, Yalım ÇETİN

OP-35. [Carotid Stent Migration, a Rare Late Complication and Its Management]. Nadir Bir Geç Komplikasyon Olan Karotis Stent Migrasyonu ve Yönetimi

İbrahim AKTAŞ

OP-36. Treatment of Total Ocluded RCA Because of Stent Detachment with Subintimal Crossing

Seray YAZGAN, Enes İsmet ERKOÇ, Hüseyin AKDOĞAN, Doğan ORMANCI, Ömer Faruk KAHRAMAN, Bilal Mete ÜLKER, Esra AKPINAR, Ayşe Dilara BALYİMEZ, Ahmet Fatih KIŞPINAR, Abdulsamet ARSLAN, Mehmet TAŞÇI, Muhammed Nusret AKIN, Erhan TENKEKİCİÖĞLU, Hasan ARI

OP-37. A Case of Pericardial Effusion with Atypical Presentation

Ömer Faruk KAHRAMAN, Mehmet TAŞÇI, Mehmetcan ÇILGIN, Enes İsmet ERKOÇ, Hasan ARI

OP-38. Percutaneous Treatment of Pseudoaneurysm with Graft Stent after Intervention of the Left Main Coronary Artery

Soner AKSÜYEK, Hasan ARI, Tahsin BOZAT

OP-39. A Rare Cause of Aortic Interruption: Mid Aortic Syndrome

Esra AKPINAR, Ayşe Dilara BALYİMEZ, Bilal Mete ÜLKER, Ömer Faruk KAHRAMAN, Soner AKSÜYEK, Fatih KOCA, Mehmet TAŞCI, Hasan ARI

OP-40. Radial Artery Perforation and Its Treatment during Percutaneous Coronary Intervention

Ayşe Dilara BALYİMEZ, Bilal Mete ÜLKER, Esra AKPINAR, Seray YAZGAN, Mustafa GÖZCÜ, Mehmetcan ÇILGIN, Hasan ARI, Tahsin BOZAT

OP-41. Transcatheter Closure of Atrial Septal Defect in Patients with Coronary Anomaly

Ahmet Fatih KIŞPINAR, Ayşe Dilara BALYEMEZ, Bilal Mete ÜLKER, Esra AKPINAR, Doğan ORMANCI, Soner AKSÜYEK, Mehmet TAŞCI, Abdülşamet ARSLAN, Mustafa Kani GÖZCÜ, Davut DAVUTOĞLU, Ömer Furkan DEMİR, Selma ARI, Mehmet MELEK, Fahriye VATANSEVER AĞCA, Hasan ARI

4th Uludag Cardiology Summit

March 7-10, 2024, Bursa, Turkey

MEETING ABSTRACTS

Oral Presentations

MEETING ABSTRACTS

Meeting Abstracts of the 4th Uludag Cardiology Summit, March 7-10, 2024, Bursa, Turkey


MEETING ABSTRACTS

- OP-01. [Successful Lead Extraction and Repeat Pacemaker Implantation in a Patient with Paget-Schroetter Syndrome and Pacemaker Dysfunction]
- OP-02. Acute Coronary Syndrome in a Young Patient with Subsequent Psoriasis Diagnosis: A Case Report
- OP-03. Relationship between Triglyceride/High Density Lipoprotein Cholesterol Ratio and Functional Significance of Coronary Lesions
- OP-04. Biventricular Noncompaction with Ascending Aortic Dilatation Presenting with Congestive Heart Failure: A Rare Case of Nonischemic Cardiomyopathy
- OP-05. Evaluation of the Effect of Prognostic Nutritional Index on Mortality in Acute Heart Failure
- OP-06. Evaluation of Medication Use in Heart Failure Patients: An Observational Study
- OP-07. Evaluation of Increase in the Adhesion Molecules (ICAM-1, VCAM-1) According to the Types of Atrial Fibrillation
- OP-08. Wellens Syndrome Unveiled: A Case Report of Coronary Spasm in a 70-Year-Old Patient
- OP-09. [Chest Pain+Elevated Troponin Levels \neq Acute Coronary Syndrome]
- OP-10. Radial Artery Spasm during Transradial Catheterization
- OP-11. The Effect of Naples Prognostic Score in Predicting Saphenous Vein Graft Disease in Patients with Coronary Bypass
- OP-12. Complete Atrioventricular Block due to Atrioventricular Node Invasion in a Malignant Melanoma
- OP-13. Effects of Upgrading from Right Ventricular Pacing to Cardiac Resynchronization Therapy and Comparison with Dual-Chamber Defibrillator in Patients with Heart Failure
- OP-14. [Chronic Inflammation Marker in Lower Extremity Peripheral Artery Patients: Platelet-Albumin Ratio]
- OP-15. Andersen-Tawil Syndrome Diagnosed with Bidirectional Ventricular Tachycardia during Pregnancy
- OP-16. Intercoronary Continuity between the Right and Left Anterior Descending Coronary Arteries Causing Acute Coronary Syndrome
- OP-17. Effect of Glyceryl Trinitrate-Containing or Lidocaine-Containing Cream Applications before Transradial Coronary Angiography on Procedure Success and Complications
- OP-18. [A Rare Complication after Transradial Intervention: Sterile Granuloma]
- OP-19. Multidisciplinary Management of a Common Variable Immunodeficiency Case with Myopericarditis
- OP-20. A Case with Coronary Perforation
- OP-21. [Experience with Percutaneous Catheter-Based Closure of Ventricular Septal Rupture Developing After Myocardial Infarction and Difficulties Encountered During The Procedure; Sharing Clinical Experience with 2 Cases]
- OP-22. Usability of Naples Prognostic Score Predicting Non-Dipper Pattern in Normotensive Patients
- OP-23. [The Intruder in The Right Ventricle: Cardiac Cyst Hydatid]
- OP-24. Challenging Rotablator Case Accompanied by IVUS
- OP-25. [ICD or No ICD? That is the Question!]
- OP-26. Electrical Storm of Malignant Ventricular Arrhythmia Confused with Epileptic Seizure
- OP-27. Allergy Related Acute Coronary Syndrome: Kounis Syndrome
- OP-28. Relationship between the Development of No-Reflow Phenomenon and Lymphocyte/HDL Ratio in Acute Coronary Syndrome Patients
- OP-29. [Once Upon a Time, Thrombus in the Right Atrium]
- OP-30. [From Diarrhea to the Heart! Tricuspid Valve Endocarditis]
- OP-31. [Delirium or Not?: Contrast Induced Encephalopathy]
- OP-32. Percutaneous Closure of an Iatrogenic Mitral Valve Perforation
- OP-33. Closure of a Paravalvular Leak between Ring and Valve: A Case Report

Received: February 28, 2024; Accepted: March 20, 2024; Published Online: March 22, 2024



e-ISSN: 2149-3189



This is an open access article distributed under the terms of [Creative Commons Attribution-NonCommercial-NoDerivatives 4.0 International License](https://creativecommons.org/licenses/by-nc-nd/4.0/)

Copyright © 2024 by Prusa Medical Publishing
Available at <http://dergipark.org/en/eurj>



- OP-34. Effective Management of Cardiac Arrest with ST Elevation Myocardial Infarction and Severe Aortic Stenosis Patient: A Multidisciplinary Approach**
- OP-35. [Carotid Stent Migration, a Rare Late Complication and Its Management]**
- OP-36. Treatment of Total Ocluded RCA Because of Stent Detachment with Subintimal Crossing**
- OP-37. A Case of Pericardial Effusion with Atypical Presentation**
- OP-38. Percutaneous Treatment of Pseudoaneurysm with Graft Stent after Intervention of the Left Main Coronary Artery**
- OP-39. A Rare Cause of Aortic Interruption: Mid Aortic Syndrome**
- OP-40. Radial Artery Perforation and Its Treatment during Percutaneous Coronary Intervention**
- OP-41. Transcatheter Closure of Atrial Septal Defect in Patients with Coronary Anomaly**

Received: February 28, 2024; **Accepted:** March 20, 2024; **Published Online:** March 22, 2024



e-ISSN: 2149-3189



This is an open access article distributed under the terms of [Creative Commons Attribution-NonCommercial-NoDerivatives 4.0 International License](https://creativecommons.org/licenses/by-nc-nd/4.0/)

Copyright © 2024 by [Prusa Medical Publishing](https://prusa-medical-publishing.com/)
Available at <http://dergipark.org/en/eurj>



OP-01.

[Successful Lead Extraction and Repeat Pacemaker Implantation in a Patient with Paget-Schroetter Syndrome and Pacemaker Dysfunction]

Paget-Schroetter Sendromu ve Pil Disfonksiyonu Gelişen Bir Hastada Başarılı Lead Ekstraksiyonu ve Tekrar Pil İmplantasyonu

Gökhun Akkan, Tuncay Kırış, Emre Özdemir, Mustafa Karaca

İzmir Katip Çelebi Üniversitesi, Atatürk Eğitim ve Araştırma Hastanesi, Kardiyoloji Kliniği, İzmir, Türkiye

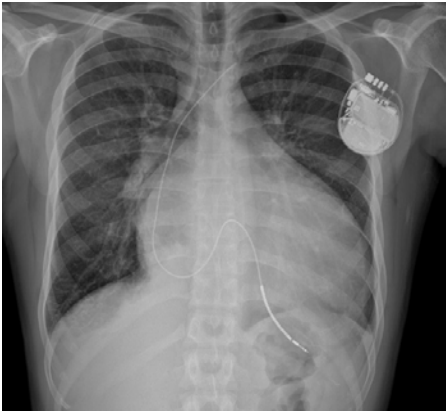
Giriş: Günümüzde, kalp pillerinin yaygın kullanımı sonucunda farklı komplikasyonlarla hastalar karşımıza çıkabilmektedir. Cihaz enfeksiyonları ve disfonksiyonları en sık komplikasyonlar olarak karşımıza çıkmaktadır. Noniskemik dilate kardiyomyopati genç bir erkek hastaya takılan VVI ICD'nin Paget-Schroetter sendromu ile birlikteliğinde meydana gelen pil disfonksiyonu ile farklı bir mücadele yöntemi sunulacaktır.

Olgu: Yirmi iki yaş erkek hasta 3 yıl önce dekompanse kalp yetmezliği ile interne edildi. Öyküsünde dış merkezde noniskemik kardiyomyopati nedeni ile primer profilaksi amaçlı VVI ICD implantasyonu mevcuttu. Yapılan ekokardiyografisinde ejeksiyon fraksiyonu (EF) %15 olarak ölçüldü. Hasta kompanse hale getirilip medikal tedavisi optimize edildi ve poliklinik takibine alındı. Daha sonra yaklaşık birer yıl ara ile 2 kere daha dekompanse kalp yetmezliği ile yatırıldı. Son olarak pil kontrolünde empedans yüksekliği nedeniyle interne edildi ve akciğer grafisinde pil bataryasının pil cebinde olduğu, subclavian ven içerisinde clavícula hizasında lead'in tamamen koparak yarısının cep içinde kaldığı, diğer yarısının da venöz sisteme düştüğü izlendi (Resim 1). Hasta lead revizyonu için salona alındı. Cep açıldığında lead'in ucunun tamamen boşa olduğu gözlemlendi. Yapılan venografide pil tarafındaki subclavian venin yüzde %99 tıkalı olduğu, sağ subclavian venin de tamamen tıkalı olduğu ve kollaterallerle dolduğu gözlemlendi (Resim 2-3). Hastanın sorgulamasında kağıt toplayıcısı olarak çalıştığı öğrenildi. Kullandığı toplama aracının, yüksek tutma alanlarına uzun süreli uzanma ve germe hareketleri sonucu olan venöz torasik outlet sendromuna (Paget-Schroetter sendromu) neden olduğu ve bu sebeple kronik venöz bası sonucu ile venöz okluzyonların geliştiği, sol subclavian venin lead sebebi ile tamamen oklude olmadığı ve oluşan bası nedeni ile lead'in kırıldığı düşünüldü. Kardiyoloji-kalp damar cerrahisi konseyinde tartışılan hasta için, perkutan lead çıkarılması ve aynı zamanda düşük EF'li olup genç yaş olması nedeni ile ICD profilaksisinin devamına karar verildi. Venöz sistem içerisindeki yüzen lead, femoral ponksiyonla girilerek snare ile yakalanarak çıkarıldı (Resim 4). Venöz görüntüleme sonrası yüzde %99 tıkalı olan sol subclavian vene ilaçlı balon yapılarak uygun açıklık sağlandı (Resim 5). Bu bölgeden yeni VVI ICD implante edildi. Oral antikoagulanla taburcu edilen hastanın 3. ay venografisinde lead'in olduğu taraftaki ven akımının sebat ettiği izlendi (Resim 6).

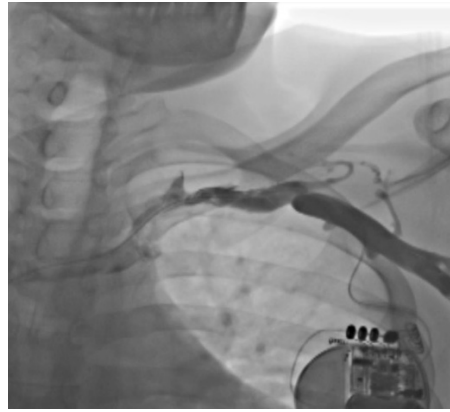
Sonuç: Günümüzde primer profilaksi nedeniyle implante edilen ICD'lerin artması ve ulaşılabilirliğin yaygınlaşması nedeni ile farklı olgulara farklı yaklaşım gerekmektedir. Bir kardiyoloğun çok nadir olarak rastlayabileceği venöz torasik çıkış sendromu sonucunda subclavian darlık ve laed'in kesilmesi ile sonuçlanan

farklı bir komplikasyonla başarılı mücadele yöntemi anlatılmıştır. Hastayı ani kardiyak ölümden korumak için yapılan bu işlemde aynı sorunla bir daha karşılaşmamak adına, hastanın eğitilmesi ile bu sorunun çözülmesi mümkün olup hastalara bu konuda bilgi vermek esas teşkil etmektedir. Ancak buna rağmen bu gibi olaylarla karşılaşma, farklı ve inovatif yaklaşımları gerektirmekte olup bu sorunlara müdahale etmek girişimsel kardiyologların deneyimi dahilinde yapabileceği işlemlerdendir.

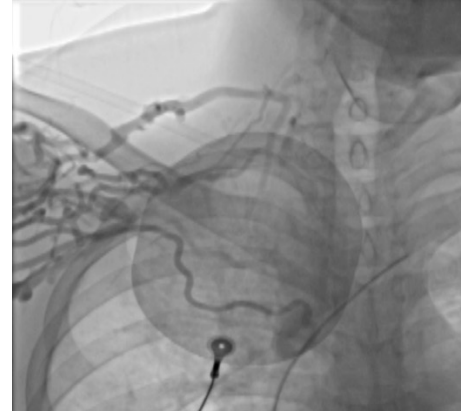Anahtar Kelimeler: Paget-Schroetter sendromu, pil disfonksiyonu, pil ekstraksiyonu, yeniden pil implantasyonu



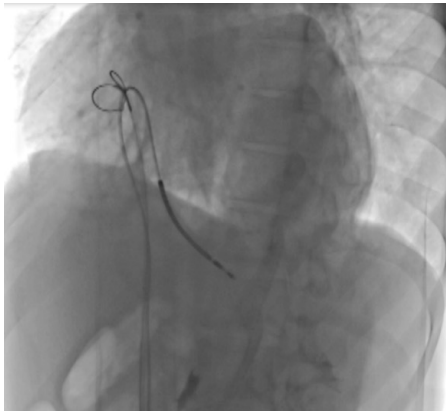
Resim 1



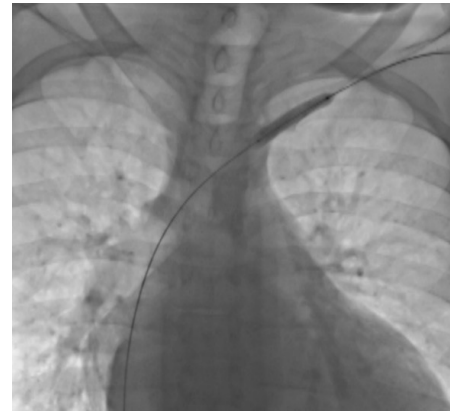Resim 2



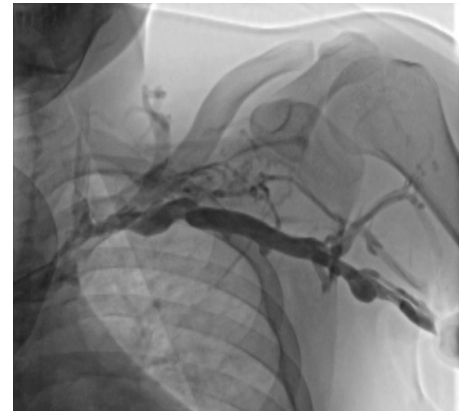
Resim 3



Resim 4



Resim 5



Resim 6

OP-02.

Acute Coronary Syndrome in a Young Patient with Subsequent Psoriasis Diagnosis: A Case Report

Hüseyin Tezcan, Zafer Büyükterzi, Süleyman Kanyılmaz

Department of Cardiology, Konya City Hospital, Konya, Türkiye

Introduction: Acute coronary syndrome (ACS) is typically associated with traditional cardiac risk factors. However, this case report discusses a unique presentation of ACS in a young patient without such risk factors, who was subsequently diagnosed with psoriasis, highlighting an atypical risk factor for cardiovascular diseases.

Case Presentation: A 33-year-old male patient with no history of diabetes mellitus, smoking, or dyslipidemia presented to the emergency department complaining of chest pain. The electrocardiogram (ECG) showed normal sinus rhythm with a heart rate of 77 bpm and nonspecific ST-segment depressions. Echocardiography revealed an ejection fraction (EF) of 50% with slight movement defects in the lateral wall. Laboratory tests, including hemogram and renal function tests, were within normal limits, with an LDL cholesterol level of 115 mg/dL. Notably, an elevated troponin level of 650 (normal range: 0-14) ng/mL was observed. Based on these findings, the patient underwent coronary angiography, which led to the diagnosis of Non-ST-Segment Elevation Myocardial Infarction (NSTMI). Percutaneous coronary intervention (PCI) was performed on a lesion in the circumflex artery. The patient's hospital course was stable, and he was discharged after three days on ticagrelor, acetylsalicylic acid, pantoprazole, and atorvastatin. **Notable Development:** Six days post-discharge, the patient consulted a dermatology clinic for widespread squamous skin rashes and was diagnosed with psoriasis (Figs. 1 and 2)

Discussion: This case is significant for its rare presentation of ACS in a young patient without traditional cardiac risk factors, followed by the diagnosis of psoriasis. Psoriasis, a chronic, autoimmune, and inflammatory disease, is reported in 0.09% to 5.1% of the global population, often manifesting before 40 years of age. It confers a high relative risk of cardiovascular disease in 25% of patients, irrespective of other risk factors, with a 6.2% increased risk of major adverse cardiovascular events within ten years compared to healthy individuals. Psoriasis is characterized by the activation of Th1 and Th17 lymphocytes and overexpression of cytokines, which are also present in vascular atherosclerotic lesions, suggesting a link to atherogenesis and cardiovascular diseases. The impaired regulatory T cell function and proinflammatory activity of macrophages and neutrophils in psoriasis further support this association.

Given these findings, individuals with psoriasis should be considered at elevated risk for cardiovascular diseases, warranting proactive management similar to that for traditional risk factors. Recommendations include regular monitoring of blood pressure, lipid profiles, glucose levels, and lifestyle modifications.

Conclusion: This case highlights the importance of recognizing psoriasis as a potential risk factor for ACS, particularly in younger patients without traditional cardiac risk factors. A multidisciplinary approach involving comprehensive cardiovascular evaluation and management is crucial for patients with psoriasis to mitigate the risk of cardiovascular events.

Keywords: Psoriasis, acute coronary syndrome, myocardial infarction, risk factor

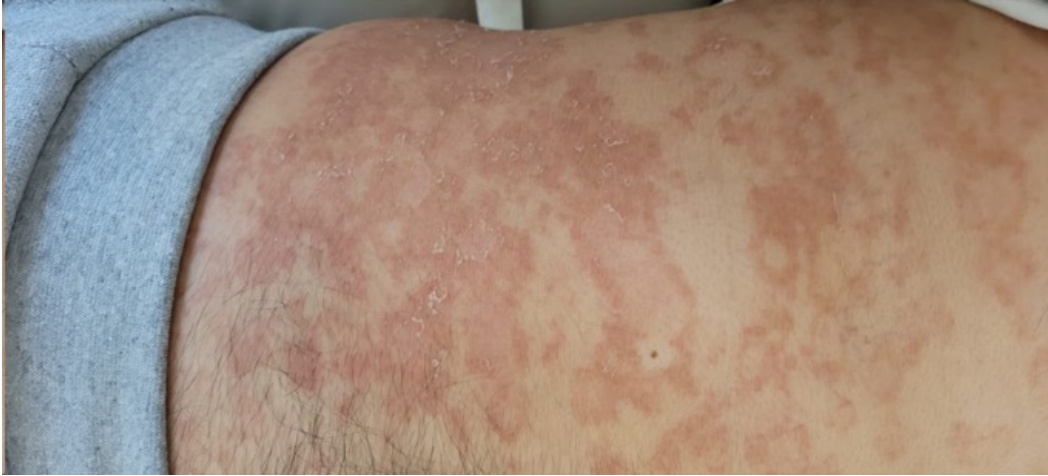

Fig. 1

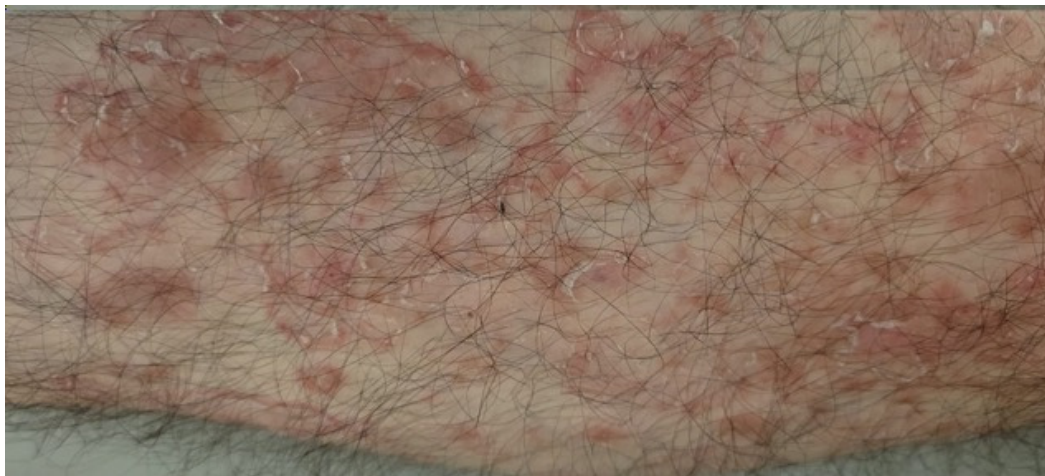

Fig. 2

OP-03.

Relationship between Triglyceride/High Density Lipoprotein Cholesterol Ratio and Functional Significance of Coronary Lesions

Can Özkan¹, Orhan Karayığit², Eda Özcan¹

¹Department of Cardiology, Bursa City Hospital, Bursa, Türkiye; ²Department of Cardiology, Yozgat City Hospital, Yozgat, Türkiye

Objective: Studies have shown that triglycerides (TG) are an independent risk factor for cardiovascular disease (CVD). Dyslipidemia characterized by low high-density lipoprotein cholesterol (HDL-C) has been shown to be associated with symptoms of CAD. In previous studies, the TG/HDL-C ratio has been found to be strongly associated with the extent of coronary disease. In this study, we aimed to investigate whether the TG/HDL-C ratio is associated with the functional significance of middle coronary artery lesions.

Methods: A total of 102 consecutive patients (72 males and 30 females) with angiographically moderate coronary stenosis (40-70% on quantitative coronary analysis) who underwent fractional flow reserve (FFR) measurement were included in the study. An FFR value ≤ 0.80 was considered hemodynamically significant. (Tablo 1)

Results: Among the 102 patients included into the study, 52 (50.9 %) were found to have significant functional stenosis. Group II has a lower left ventricle EF than group I (55% (50-60) vs. 60% (55-62.5), $P=0.006$). While group II had a higher ratio of male patients, the difference between the two groups was not significant (68% vs. 77%, $P=0.072$). Univariate and multiple logistic regression analysis indicated that TG/HDL-C ($OR=1.278$, 95% $CI=1.078-1.514$, $P=0.005$) is independent predictors of significant functional stenosis (Table 2 and Fig. 1.). ROC analysis revealed that an TG/HDL-C value of 3.89 had a specificity of 64% and a sensitivity of 61.5% in predicting hemodynamically significant coronary artery stenosis.

Conclusion: Elevated TG/HDL-C values have been associated with the functional significance of angiographically moderate coronary artery stenosis.

Keywords: Coronary lesion, triglycerides/high-density lipoprotein cholesterol ratio, cardiovascular disease, angiography

Table 1. Baseline Characteristics and Laboratory Parameters of the Study Groups

Variables	Total study population (n=102)		P value
	Insignificant FFR (Group 1) (n= 50)	Significant FFR (Group 2) (n=52)	
Baseline characteristics			
Age, years	59.4 ± 9.5	56.1 ± 7.3	0.058
Male gender, n (%)	32 (64)	40 (76.9)	0.152
Diabetes Mellitus, n (%)	16 (32)	20 (38.5)	0.495
Hypertension, n (%)	31 (62)	31 (59.6)	0.805
Dyslipidemia, n (%)	16 (32)	21 (40.4)	0.379
Current smokers, n (%)	21 (42)	28 (53.8)	0.231
Left ventricle EF, %	60 (55-62.5)	55 (50-60)	0.006
After Adenosin FFR	0.86 ± 0.03	0.74 ± 0.03	<0.001
Laboratory parameters			
Glucose, mg/dL	105 (93-148)	110 (96-154)	0.364
Urea, mg/dL	14.1 (12.5-17)	13.7 (11-16.8)	0.286
Creatinine, mg/dL	0.87 (0.74-1.00)	0.85 (0.75-0.99)	0.658
Total cholesterol, mg/dL	177.2 ± 35	184.6 ± 49.7	0.388
HDL cholesterol, mg/dL	42 (37-51)	38 (32-44)	0.013
LDL cholesterol, mg/dL	100.2 ± 29.6	104.6 ± 43.1	0.547
Triglycerides, mg/dL	129 (101-195)	178 (122-269)	0.010
WBC count, ×103/μL	7.8 (6.5-9.2)	9.5 (7.6-11.1)	0.003
Neutrophil count, ×103/μL	4.6 (3.4-6.1)	5.7 (4.2-7.3)	<0.026
Lymphocyte count, ×103/μL	2.1 (1.6-2.6)	2.4 (1.9-2.9)	0.162
Hemoglobin, g/dL	13.8 ± 1.8	13.7 ± 2.1	0.639
RDW, fL	13.1 (12.4-14)	13.3 (12.5-14.1)	0.393
MPV, fL	10.4 (10-11.1)	10.1 (9.8-10.7)	0.026
Platelet count, ×103/μL	244 (207-289)	268 (233-313)	0.072
TG/HDL-C	3.74 ± 2.13	6.14 ± 4.37	0.003

All values are expressed as mean±standard deviation, median (25th and 75th interquartile range), and number (%). Abbreviations: EF, ejection fraction; FFR, fractional flow reserve; HDL, high-density lipoprotein; LDL, low-density lipoprotein; MPV, mean platelet volume; RDW, red cell distribution width; TG/HDL-C, triglyceride/high-density lipoprotein cholesterol ratio; WBC, white blood cell. p values in bold signify statistically significant differences.

Table 2. Univariate and Multivariate Logistic Regression Analysis Showing the Independent Predictors for Hemodynamically Significant Coronary Artery Stenosis

Variables	Univariate analysis		Multivariate analysis	
	OR (95% CI)	P value	OR (95% CI)	P value
Age	0.956 (0.911-1.002)	0.062	0.956 (0.906-1.008)	0.094
Neutrophil	1.235 (1.022-1.492)	0.029	0.995 (0.576-1.719)	0.986
TG/HDL-C	1.269 (1.090-1.477)	0.002	1.278 (1.078-1.514)	0.005
WBC	1.242 (1.053-1.465)	0.010	1.187 (0.739-1.906)	0.478

Abbreviations: CI, confidence interval; TG/HDL-C, triglyceride/high-density lipoprotein cholesterol ratio; OR, odds ratio; WBC, white blood cell.

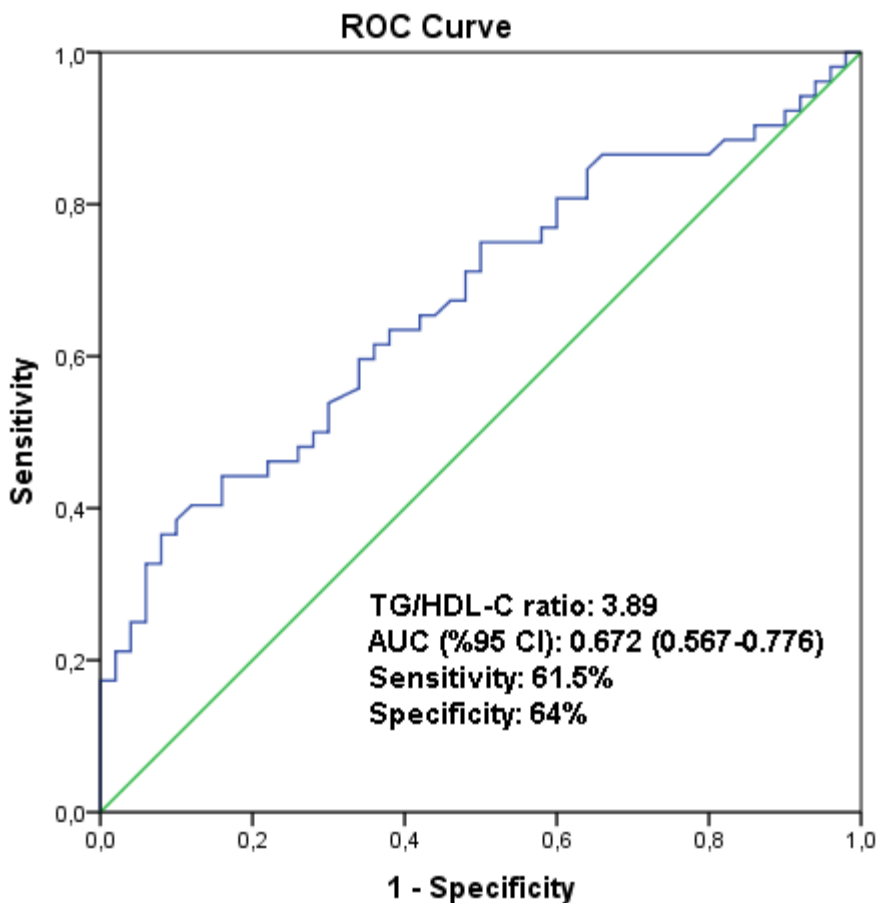


Fig. 1.

OP-04.**Biventricular Noncompaction with Ascending Aortic Dilatation Presenting with Congestive Heart Failure: A Rare Case of Nonischemic Cardiomyopathy****Onur Argan, Eyup Avci***Department of Cardiology, Balıkesir University, School of Medicine, Balıkesir, Türkiye*

Introduction: Biventricular noncompaction is an extremely rare form of cardiomyopathy that is characterized by deep abnormal trabeculations and intertrabecular recesses in ventricle. Biventricular involvement is even less common. The major clinical manifestations of noncompaction are heart failure, embolic events and arrhythmias. We emphasized that different diagnostic modalities may be useful in diagnosing rare diseases that cannot be detected with echocardiography.

Method: A 47-year-old male patient presented with progressively worsening dyspnea. The patient had no other comorbidities. Bilateral pleural effusion detected in torax computed tomography. Heart failure treatment was administered.

Results: In echocardiographic imaging, reduced left ventricular ejection fraction (LVEF: 45%) was detected (Fig. 1). The appearance of abnormal trabeculations and intertrabecular recesses in ventricle made us suspicious of noncompaction cardiomyopathy. Cardiac magnetic resonance (MR) imaging supported biventricular noncompaction with ascending aortic dilatation (52 mm) (Fig. 2 ve Fig. 3). Nonischemic etiology was confirmed by cardiac catheterization. No arrhythmia was detected in rhythm holter. After the treatment of heart failure, patient discharged with ACE inhibitor, spironolacton, diuretic and B-bloker.

Discussion: Biventricular involvement occurs in one-third of the cases. Echocardiography is the first method of the diagnosis of noncompaction, but diagnosis may be missed. Cardiac MR is effective in order to confirm the diagnosis and rule out other cardiac pathologies, especially in patients with poor echocardiographic image quality.

Conclusions: This case emphasizes the importance of further investigation with other imaging methods in patients whose etiology of heart failure cannot be determined by echocardiography. Echocardiography may be non-diagnostic or insufficient, in which case MR is useful in detecting the etiology of non-ischemic cardiomyopathy.

Keywords: Non-ischemic cardiomyopathy, biventricular noncompaction, ascending aortic dilatation

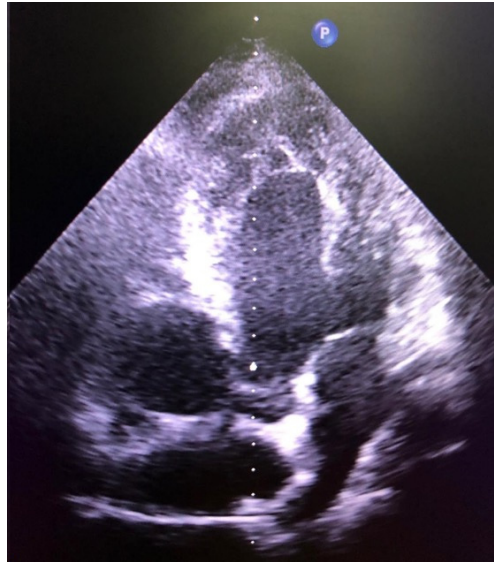


Fig. 1. Echocardiographic imaging of noncompaction cardiomyopathy- Four chamber view.

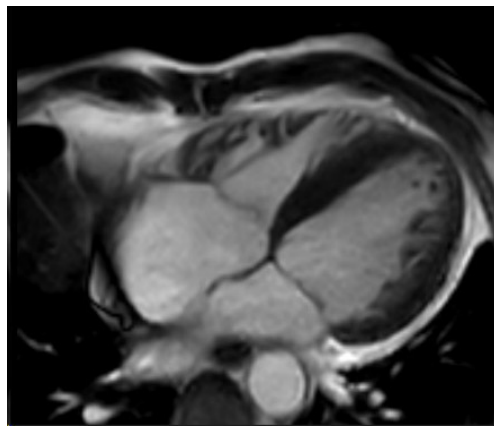


Fig. 2. Cardiac magnetic resonance imaging of noncompaction cardiomyopathy - Four chamber view.

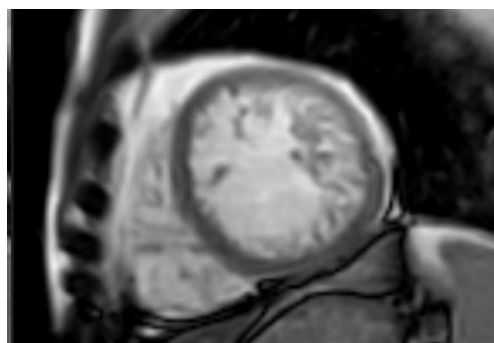


Fig. 3. Cardiac magnetic resonance imaging of noncompaction cardiomyopathy - Short axis view.

OP-05.**Evaluation of the Effect of Prognostic Nutritional Index on Mortality in Acute Heart Failure****Alperen Taş², Mehmet Taha Özkan¹, Ayşe Nur Özkaya¹, Çağatay Tunca¹, Muhammed Erzurum³**

¹Department of Cardiology, Ankara Etlik City Hospital, Ankara, Türkiye; ²Department of Cardiology, Kırşehir Training and Research Hospital, Kırşehir, Türkiye; ³Department of Cardiology, Eskişehir Yunus Emre State Hospital, Eskişehir, Türkiye

Background: Acute heart failure (AHF) constitutes a critical medical condition that necessitates immediate therapeutic intervention and continuous monitoring. Despite advancements in pharmacological and device-based therapies, AHF remains a major public health issue with high morbidity, hospital readmission rates, and substantial mortality. An emerging area of research that has gained significant attention is the potential role of nutritional status as an independent prognostic factor in AHF outcomes. The Prognostic Nutritional Index (PNI), initially designed to evaluate preoperative nutritional status and systemic inflammatory response in oncologic patients, has been increasingly explored in the context of cardiovascular diseases. However, comprehensive data elucidating the relationship between PNI and mortality risk in AHF patients are notably sparse. This study aims to bridge this gap by investigating the impact of the Prognostic Nutritional Index on mortality rates among patients admitted with acute heart failure.

Methods: This study is a single-center, retrospective analysis aimed at investigating the prognostic implications of the Prognostic Nutritional Index (PNI) in patients hospitalized for acute heart failure (AHF). A total of 245 patients admitted to a tertiary medical center for AHF were included in the analysis. PNI was calculated as $10 \times \text{serum albumin (g/dL)} + 0.005 \times \text{total lymphocyte count (per mm}^3\text{)}$. Patients were followed for an average duration of one year after hospital admission. The primary endpoint for this study was all-cause mortality. Statistical analyses were conducted to evaluate the independence and robustness of PNI as a predictor of mortality. Multivariate logistic regression models were employed to adjust for potential confounders.

Results: Two hundred and forty-five patients were included in the study retrospectively. The mean age was 60.5 ± 14.2 years and 173 (70%) of them were male. In the group with mortality, PNI and albumin were lower ($P < 0.001$, $P < 0.001$); age were higher ($P < 0.001$); etiology, other comorbidities, hemoglobin and creatinine levels were similar (Table 1). Both groups were similar in terms of prescribed medications, as outlined in Table 2. Multivariable regression analysis showed; age and PNI were determined as independent risk factors for all cause mortality (Age; OR (95% CI): (1.044 (1.018-1.070), $P < 0.001$) (PNI; OR (95% CI): 0,953 (0,918-0,990), $P = 0.013$) (Table 3).

Conclusions: In summary, our investigation elucidates the Prognostic Nutritional Index (PNI) as an independent predictor of all-cause mortality in patients hospitalized for acute heart failure (AHF). Remarkably, the predictive capacity of PNI remained robust even after adjustment for sex, estimated glomerular filtration rate (eGFR), left ventricular ejection fraction (LVEF), prescribed medications and hemoglobin levels. Derived from routine biochemistry and hemogram tests, PNI stands as a cost-effective and easily accessible metric that holds significant promise for clinical utility.

Keywords: Acute heart failure, prognostic nutritional index, predictors

Table 1. Characteristics of the patients

	All patients (n=245)	Patient with primer endpoint (n=94)	Patient without primer endpoint (n=151)	P value
Age	60.51±14.2	66.4±13.9	56.9±13.1	<0.001
Male	173 (68%)	65 (69%)	108 (71%)	0.692
DM	90 (36%)	35 (37%)	55 (36%)	0.898
HT	155 (63%)	70 (74%)	85 (54%)	0.004
Ischemic etiology	113 (46%)	50 (53%)	63 (40%)	0.08
Creatinine (mg/dL)	1.8 ± 6.0	1.9 ± 6.7	1.7 ± 5.5	0.741
Sodium (mEq/L)	136.5 ± 4.1	136.4 ± 4.7	136.5 ± 3.8	0.866
Potassium (mEq/L)	4.5 ± 3.0	4.4 ±0.6	4.5 ± 3.8	0.642
Albumin (g/dL)	3.6 ± 0.5	3.4 ±0.5	3.7 ± 0.5	<0.001
Hb (g/dl)	12.4 ± 1.9	11.9 ± 2.0	12.7 ± 1.7	0.002
PNI	45.6 ± 9.0	42.4 ± 9.0	47.7 ± 8.4	<0.001
LVEF	27.6 ± 8.1	28.4 ± 7.9	27.1 ± 8.2	0.226

DM=diabetes mellitus; Ht=hypertension LVEF, left ventricular ejection fraction, PNI=prognostic nutritional index

Table 2. Medication utilization

	All patiens (n=245)	Patient with primer endpoint (n= 94)	Patient without primer endpoint (n=151)	P value
ACE inhibitors	198 (71%)	73 (77%)	125(82%)	0.322
ARB	18 (7%)	5 (5%)	13 (8%)	0.337
Beta blocker	243(99%)	93 (99%)	150 (99%)	0.734
Statine	103 (42%)	40 (42%)	63 (41%)	0.898
Antiplatelet agent	143 (58%)	51 (54%)	92 (60%)	0.303
Anticoagulant	126 (51%)	54 (57%)	72 (47%)	0.137
Aldosterone antagonist	142 (57%)	51 (54%)	91 (60%)	0.354

ACE=angiotensin-converting enzyme\ARB, angiotensin II receptor blocker.

Table 3. Univariate-multivariate regression analysis

	Univariate OR	Regression 95% CL	P value	Multivariate OR	Regression 95% CL	P value
Age	1.054	1,032-1.077	<0.001	1.044	1.018-1.070	<0.001
HT	0.442	0,251-0.776	0.005	0.972	0.483-1.955	0.936
Hb	0.801	0,695-0.922	0.002	0.897	0.763-1.055	0.190
PNI	0.925	0,892-0.958	<0.001	0.953	0.918-0.990	0.013

HT=hypertension, Hb=Hemoglobin, PNI=prognostic nutritional index

OP-06.

Evaluation of Medication Use in Heart Failure Patients: An Observational Study

Sena Ustaömer¹, Nurten Sayar², Murat Sünbül², Ümit Öztürk², Zekeriya Doğan², Mesut Sancar³

¹Health Sciences Institute, Marmara University, İstanbul, Türkiye; ²Department of Cardiology, Marmara University, İstanbul, Türkiye; ³Department of Clinical Pharmacy, Marmara University, Faculty of Pharmacy, İstanbul, Türkiye

Introduction: In addition to standard treatment, heart failure (HF) patients use many medications for the treatment of their co-morbidities. For this reason, polypharmacy is common in HF patients. It is known that patients are at risk for potential drug-drug interactions and adverse effects. In the international guidelines, a multidisciplinary team approach is recommended for managing HF that causes multiple comorbidities.

Aim: The aim of this study is to detect DRPs during HF treatment by the clinical pharmacist and to evaluate the appropriateness of the medications used by patients ≥ 65 years of age.

Method: The medication use of HF patients aged ≥ 18 years hospitalized in the Cardiology service of Marmara University Pendik Training and Research Hospital between 18 September -18 December 2023 was prospectively evaluated. The DRPs were classified according to the Hepler-Strand system, and the potentially inappropriate medication use in patients aged ≥ 65 years was determined by the 2023 Beers Criteria[®].

Results: Of the 64 HF patients included in the study, 32.81% were women (n=21), and the average age was 70.64 ± 10.66 . The average number of medications used by patients is 8.31 ± 2.09 . A total of 112 DRPs were identified due to consensus with the cardiologists after evaluation with the current guidelines and databases. The number of DRPs per patient was 1.75 ± 1.02 . The detected DRPs are 4.46% unnecessary drug use, 60.72% the patient isn't using drugs for a condition that is an indication, 8.03% low-dose drug use, 2.67% high-dose drug use, 7.14% the patient's failure to use the appropriate drug, 0.89% side effects, and 4.46% clinically significant drug-drug interactions. The relationship between the demographic information of the patients and the LVEF value of the drugs they used was also evaluated in Tables 1 and 2. 76.26% of the 64 HF patients included in the study (n=49) were patients ≥ 65 years old. The evaluation conducted with the 2023 Beers Criteria[®] for geriatric patients found that the medications in the treatment of 23 patients didn't comply with a total of 36 criteria.

Discussion: According to the evaluation of medication use in HF patients, the prescribing rate of SGLT2i is low. Nearly half of the detected DRPs are caused by the inability to prescribe SGLT2i that do not reimburse in this indication. As a significant proportion of HF patients are older, it is necessary to review the treatment with the international criteria established to evaluate the treatment of these individuals.

Conclusion: The cooperation of the clinical pharmacist and the physician is very important in preventing the detected DRPs and ensuring optimal treatment.

Keywords: Heart failure (HF), drug related problems (DRPs), Beers criteria, clinical pharmacist

Table 1. Demographic findings of heart failure patients

Variables	HFpEF (n=7)	HFmrEF (n=14)	HFrEF (n=38)	P value
Demographic findings				
Age, year	76.5±0.71 (76-77)	75.66±6.43 (71-83)	74.15±5.32 (65-81)	0.631
Gender				0.354
Male, n (%)	5 (71.4)	11 (78.5)	22 (57.9)	
Female, n (%)	2 (28.6)	3 (21.5)	16 (42.1)	
BMI kg/m ²	28.44 ± 0.62	24.34 ± 2.62	27.95 ± 3.28	0.454
Smoke, n (%)	1 (20)	2 (15.4)	6 (16.2)	0.971
Alcohol, n (%)	0 (0)	2 (15.4)	1 (2.7)	0.190
Co-morbidity				
Number of co-morbidity	2.00 ± 1.41	3.33 ± 0.58	3.54 ± 1.27	0.351
HT, n (%)	1 (14.3)	9 (64.3)	21 (55.3)	0.082
CAD, n (%)	5 (71.4)	9 (64.3)	15 (39.5)	0.129
DM, n (%)	1 (14.3)	8 (57.1)	21 (55.3)	0.119
AF, n (%)	3 (42.9)	2 (14.3)	10 (26.3)	0.358
Asthma, n (%)	0 (0)	2 (14.3)	2 (5.4)	0.388
COPD, n (%)	1 (14.3)	2 (14.3)	6 (14.8)	0.988
Previous MI, n (%)	1 (14.3)	8 (57.14)	18 (47.36)	0.168
Cancer, n (%)	0 (0)	2 (14.3)	0 (0)	0.036

HT=Hypertension, CAD=Coronary Artery Disease, DM=Diabetes Mellitus, AF=Atrial Fibrillation, COPD=Chronic Obstructive Pulmonary Disease

Table 2. Medication use rates in heart failure patients

Variables	HFpEF (n=7)	HFmrEF (n=14)	HFrEF (n=38)	P value
Use of medication				
ARNI, n (%)	0 (0)	1 (7.1)	8 (21.1)	0.228
ACEi, n (%)	5 (71.42)	7 (50)	19 (50)	0.567
ARB, n (%)	1 (14.28)	2 (14.28)	2 (5.,26)	0.492
Beta blocker, n (%)	5 (71.4)	14 (100)	34 (89.5)	0.123
MRA, n (%)	2 (28.6)	2 (14.3)	20 (52.6)	0.035
SGLT2i, n (%)	2 (28.6)	0 (0)	9 (23.7)	0.117
Diuretic, n (%)	5 (71.4)	4 (28.6)	19 (50)	0.156
Anticoagulant, n (%)	5 (71.4)	6 (42.9)	23 (57.6)	0.029
Antiplatelet, n (%)	4 (57.1)	12 (85.7)	26 (68.4)	0.381
Statin, n (%)	5 (71.4)	11(78.6)	32(84.2)	0.073
OAD, n (%)	1 (14.3)	0 (0)	4 (10.5)	0.28
Insulin, n (%)	0 (0)	3 (21.4)	11 (26.3)	0.539
Inhaler, n (%)	3 (42.9)	1 (7.1)	7 (18.42)	0.57
DRPs	1.14±0.38	1.93±1.21	1.82±1.06	0.244
Number of drug–drug interactions	5.50±2.12	11.67±10.97	11.69±4.66	0.716
Number of inappropriate Beers criteria	0.00±0.00	0.67±1.15	0.54±1.13	0.193

ARNI=Angiotensin Receptor Neprilicin Inhibitor, ACEi=Angiotensin Converting Enzyme Inhibitor, ARB=Angiotensin Receptor Blocker, MRA=Mineralocorticoid Receptor Antagonists, SGLT2i=Sodium Glucose Co-transporter-2 Inhibitors

OP-07.

Evaluation of Increase in the Adhesion Molecules (ICAM-1, VCAM-1) According to the Types of Atrial Fibrillation

Hakan Kilci¹, Köksal Ceyhan², Lütfü Bekar³

¹Department of Cardiology, Şişli Hamidiye Etfal Training and Research Hospital, Istanbul, Türkiye; ²Department of Cardiology, Special Century Gebze Hospital, Kocaeli, Türkiye ; ³Department of Cardiology, Hitit University, Faculty of Medicine, Çorum, Türkiye

Background: Atrial fibrillation (AF) is the most frequent arrhythmia in the adult ages and related with the one third of the hospitalizations for rhythm disorders. Stroke is the most important cause of morbidity at these patients. In patients with valvular atrial fibrillation (VAF), the risk of developing of atrial thrombus and thromboembolic event is much higher than in the subjects with NVAf.

Aim: We aimed to evaluate the levels of vascular cell adhesion molecule-1 (VCAM-1) and intercellular adhesion molecule-1 (ICAM-1) at the patients with valvular (VAF) and non-valvular atrial fibrillation (NVAf).

Methods: 45 control and 44 patients with VAF or NVAf, total 89 subjects who have not coronary artery diseases were included in the study. Demographic features, major cardiovascular risk factors (hypertension, hyperlipidemia and diabetes) and laboratory findings were all recorded. VCAM-1 and ICAM-1 levels were measured in each group (Table 1).

Results: There wasn't any significant difference between control and atrial fibrillation (AF) group in term of plasma ICAM-1 levels. Plasma VCAM-1 levels were found higher in AF group than the control group (1169±246 mg/dL vs. 1072±229 mg/dl, P=0.056) (Fig. 1). In the subgroup analysis; there were statistically significant differences between control and VAF and NVAf groups in terms of VCAM-1 levels (P=0.021) (Fig. 2). There were statistically significant differences in term of VCAM-1 between VAF and control groups (1260±291 mg/dL and 1072±229 mg/dL, P=0.016) (Table 2 and Table 3).

Conclusion: While ICAM-1 levels are alike in patients with valvular atrial fibrillation and patients with sinus rhythm, VCAM-1 levels are higher at patients with valvular atrial fibrillation. We suggest that high VCAM-1 levels can be a risk for the development of thromboembolic events in this group.

Keywords: Atrial fibrillation, VCAM-1, ICAM-1

Table 1. Baseline clinical and laboratory characteristics of patients with atrial fibrillation and control group

	Control (N=45)	NVAF (N=27)	VAF (N=17)	P value
Male, n (%)	16 (35.6)	12 (44.4)	3 (17.6)	0.190
Hypertension, n (%)	28 (62.2)	22 (81.5)	8 (47.1)	0.055
Diabetes mellitus, n (%)	9 (20.0)	6 (22.2)	2 (11.8)	0.675
Smoking, n (%)	6 (13.3)	4 (14.8)	2 (11.8)	0.958
Age (years)	51±8	65±9	57±11	<0.001
Family history, n (%)	4 (8.9)	4 (14.8)	2 (11.8)	0.415
BUN (mg/dL)	14±5	19±10	17±6	0.009
Creatinin (mg/dL)	0.8±0.3	0.9±0.3	0.8±0.2	0.076
Fasting blood glucose (mg/dL)	106±34	121±57	107±44	0.236
Total cholesterol (mg/dL)	208±47	175±35	185±36	0.009
LDL (mg/dL)	126±40	106±30	116±28	0.036
HDL (mg/dL)	46±11	41±10	43±15	0.171
Triglyceride (mg/dL)	174±96	136±57	138±66	0.191
LVEF (%)	61±9	52±9	53±11	0.002
VCAM -1(mg/dL)	1072±229	1113±198	1260±291	0.021
ICAM-1 (mg/dL)	671±132	680±163	748±203	0.216
CRP (mg/dL)	4.8±2.9	5.9±5.1	10.5±11.0	0.163

Continuous variables are shown as mean±standard deviation; quantitative variables are shown as numbers and percentages. VAF=valvular atrial fibrillation, BUN=blood urea nitrogen, LDL=low-density lipoprotein, HDL=high-density lipoprotein, LVEF=left ventricular ejection fraction, VCAM=vascular cell adhesion molecule, ICAM=intercellular adhesion molecule

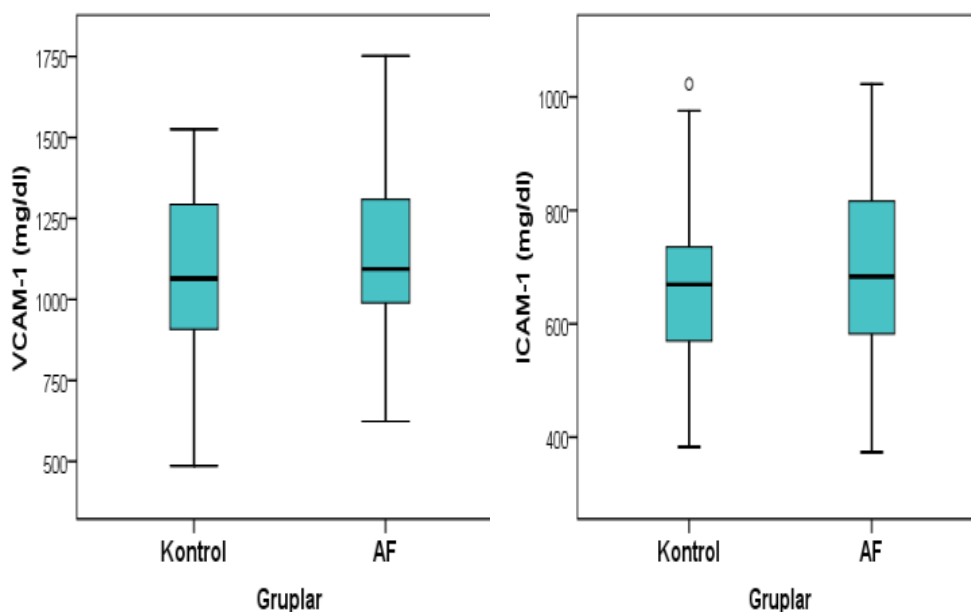


Fig. 1. Distribution of VCAM-1 levels (1072±229 mg/dL vs 1169±246 mg/dL, P=0.056) and ICAM-1 levels at both groups (671±132 mg/dL vs 706±180 mg/dL, P=0.313). AF=atrial fibrillation, ICAM=intercellular adhesion molecule, VCAM=vascular cell adhesion molecule

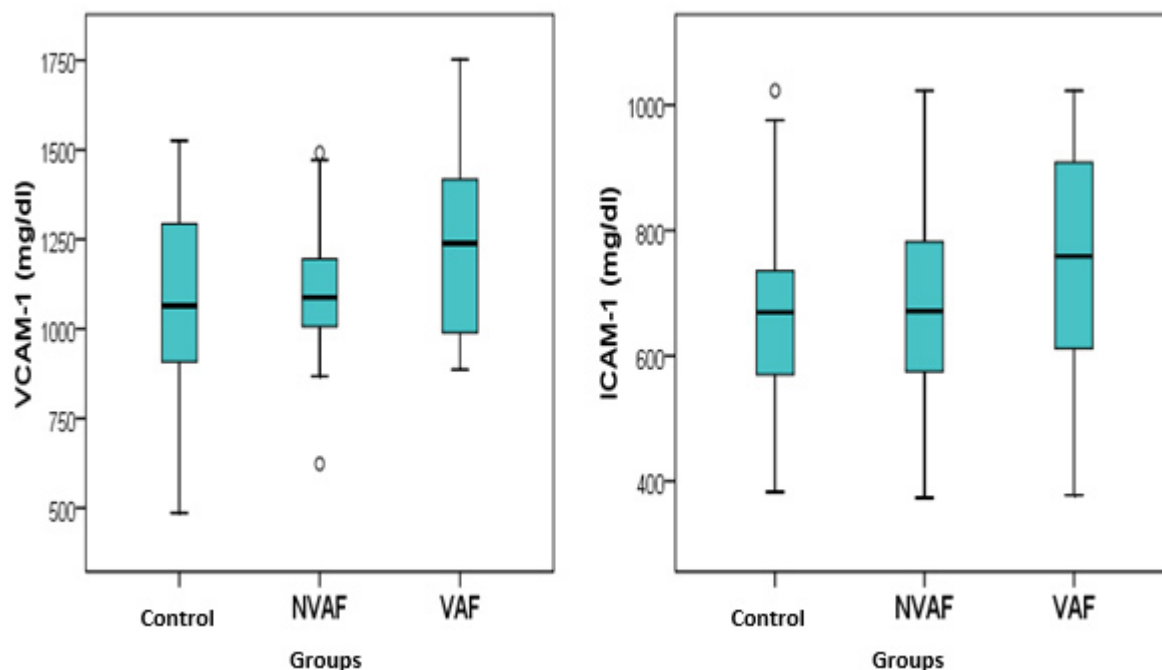


Fig. 2. Distribution of VCAM-1 levels (1260±291 mg/dL vs 1113±198 mg/dL vs 1072±229 mg/dL, P=0.021) and ICAM-1 levels at study groups (671±132 mg/dL vs 680±163 mg/dL vs 748±203 mg/dL, P=0.216). NVAf=non-valvular atrial fibrillation, VAF= valvular atrial fibrillation, VCAM=vascular cell adhesion molecule

Table 2. Comparison of control group and valvular atrial fibrillation

	Control (n=45)	VAF (n=17)	P value
Age (years)	51±8	57±11	0.104
BUN (mg/dL)	14±5	17±6	0.253
Total cholesterol (mg/dL)	208±47	185±36	0.130
LDL (mg/dL)	126±40	116±28	0.564
VCAM -1 (mg/dL)	1072±229	1260±291	0.016
ICAM-1 (mg/dL)	671±132	748±203	0.199

Continuous variables are shown as mean±standard deviation. VAF=valvular atrial fibrillation, BUN=blood urea nitrogen, LDL=low-density lipoprotein, VCAM=vascular cell adhesion molecule, ICAM=intercellular adhesion molecule

Table 3. Multivariate Cox regression analysis

	Hazard Ratio	%95 CI	P value
Hypertension	0.59	0.23-1.50	0.27
Diabetes mellitus	0.64	0.21-1.88	0.42
Smoking	1.22	0.23-5.33	0.79
Age	1.07	1.01-1.12	0.01
AF	0.88	0.29-2.62	0.82

VCAM-1 cut off value >1200 mg/dl

OP-08.**Wellens Syndrome Unveiled: A Case Report of Coronary Spasm in a 70-Year-Old Patient****Almina Erdem, Mustafa Oğuz, Hatice Altınışık, Yusuf Turan Gül, Ahmet Lütfullah Orhan***Department of Cardiology, Sultan 2. Abdulhamid Han Training and Research Hospital, İstanbul, Türkiye*

Wellens syndrome is an ECG pattern often observed in patients with critical proximal left anterior descending (LAD) coronary artery stenosis. Conventionally, these ECG findings are indicative of an impending anterior wall myocardial infarction. However, it is crucial to recognize that these ECG changes may also arise due to coronary artery spasm, an infrequent yet significant etiology. This report aims to present a case of Wellens syndrome secondary to coronary spasm in a 70-year-old patient, emphasizing the importance of accurate diagnosis and tailored treatment approaches.

A 70-year-old male with a medical history of hypertension and dyslipidemia presented to the emergency department with acute-onset chest pain. He was smoker. The pain was described as pressure-like and radiated to his left arm. His blood pressure was 150/90 mmHg, and heart rate was 55 bpm. Physical examination revealed no significant abnormalities, and cardiac enzymes were upper limit of the normal.

An ECG was promptly performed, revealing classic findings of Wellens syndrome. The patient's ECG demonstrated deeply inverted and symmetrical T-waves in leads V2 to V6, highly suggestive of critical LAD coronary artery disease (Fig. 1). On the Echocardiography, ejection fraction was %60 and there was no left ventricular wall motion defect. Given the high-risk ECG findings, the patient was immediately taken for emergency coronary angiography.

Surprisingly, the coronary angiography demonstrated no evidence of obstructive atherosclerotic lesions in the LAD or other coronary arteries (Fig. 2). Instead, a transient spasm was observed in the mid-segment of the LAD during the procedure, confirming the diagnosis of coronary spasm as the cause of the patient's Wellens syndrome ECG pattern.

After a coronary spasm was diagnosed, the patient administered intracoronary nitroglycerin, which caused the coronary spasm and normalization of the ECG findings. The patient's chest pain regressed, and his ECG returned to a stable baseline. He was started on calcium channel blockers and advised on lifestyle modifications, including smoking cessation and stress reduction techniques.

An important early indicator of a potential anterior wall myocardial infarction is the Wellens syndrome on the ECG. Clinicians must understand that coronary artery spasm can also present with similar ECG changes, though. This case presented a possible diagnostic problem because the patient's coronary spasm mimicked the normal ECG findings seen in serious LAD stenosis.

The recognition of coronary spasm as a cause of Wellens syndrome has several implications for patient management. It emphasizes the importance of performing coronary angiography promptly to differentiate between obstructive and non-obstructive causes. Additionally, appropriate pharmacotherapy, such as calcium channel blockers, plays a pivotal role in preventing further episodes of spasm and reducing the risk of major adverse cardiac events.

Keywords: Wellens Syndrome, coronary artery spasm, coronary angiography

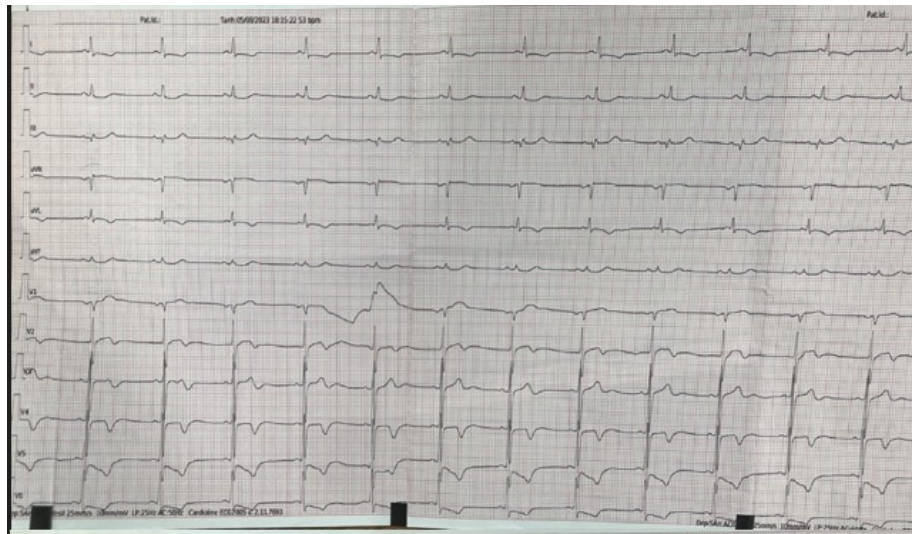


Fig. 1. Electrocardiogram.

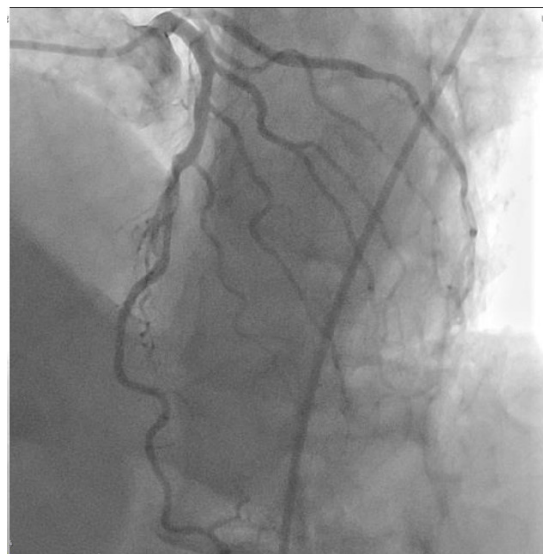

Fig. 2. Coronary angiogram.

OP-09.

[Chest Pain+Elevated Troponin Levels \neq Acute Coronary Syndrome]

Göğüs Ağrısı+Troponin Yüksekliği \neq Akut Koroner Sendrom

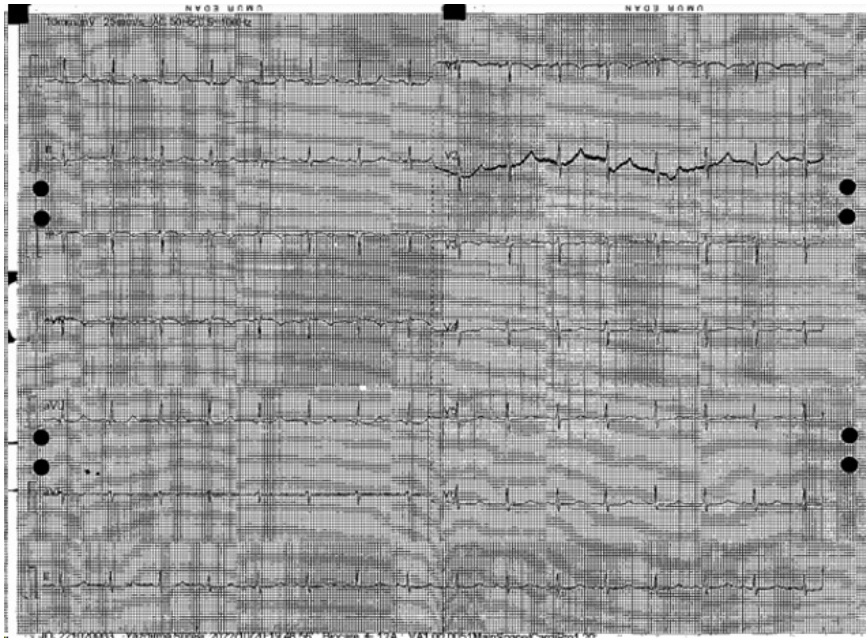
Orkhan Yunisli, Çetin Alak, Dilek Yeşilbursa

Bursa Uludağ Üniversitesi, Tıp Fakültesi, Kardiyoloji Anabilim Dalı, Bursa, Türkiye

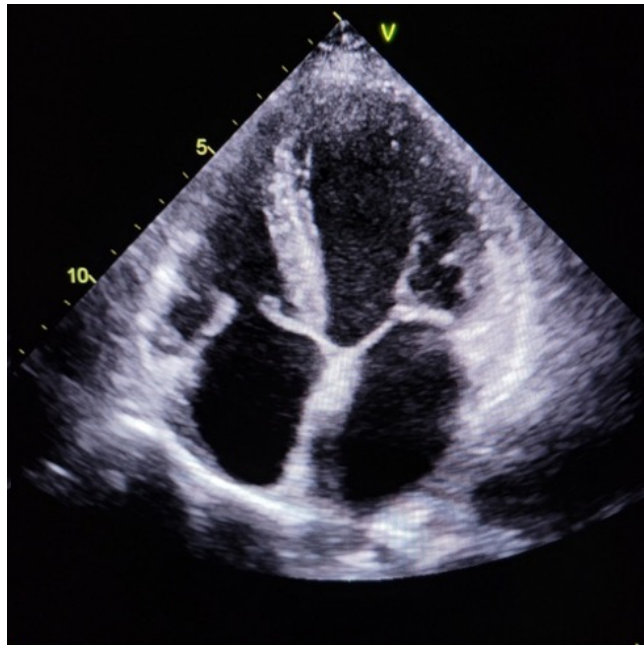
Vaka: Elli dokuz yaşında kadın hasta acil servise atipik, sızlama şeklinde göğüs ağrısı şikayeti ile başvurdu. Hastanın yapılan değerlendirmelerinde hemogram değeri 11,7 g/dL, Troponin-I değeri (46,4-44,7 ng/mL cut-off 15,6 ng/mL) cut-off değerinin üzerinde saptandı. Yapılan ekokardiyografide EF %58 interventriküler septum ve arka duvar kalınlığı 1,1 cm olarak saptandı ve 1. Derece triküspit yetersizliği ve minimal derece mitral yetersizliği mevcuttu. Hastanın troponin seyri akut miyokardiyal hasar ile uyumlu olmasa da biomarker yüksekliğinin nedenini anlamak ve koroner arter hastalığının dışlamak için yatırılarak koroner anjiyografi (KAG) planlandı. Yapılan KAG sonrasında koroner arterlerde anlamlı darlık saptanmayarak taburcu edildi. Takiplerde göğüs ağrılarının devam ettiği ve Troponin-I yüksekliğinin sebat ettiği gözlenerek ileri değerlendirme amacıyla yatırıldı. Hastanın yatışında BNP değeri:345.5 pg/mL ve troponin-I değeri 48.2 ng/mL saptandı. Hastada göğüs ağrısı ve biomarker yüksekliği nedeni ayrıntılı değerlendirilerek GLS ekokardiyografi ve Kardiyak MR (KMR) planlandı (Şekil 1, 2, 3, 4 ve 5). KMR'de de duvar kalınlıkları olağan EF %50 olarak değerlendirildi ve geç gadalinyum tutulumu izlenmedi. Yapılan GLS TTE değerlendirmesinde hipertrofi bulguları saptanmamasına rağmen hastanın GLS değerlendirmesinde (Ortalama GLS $-\%17,7$) bazal bölgelerdeki strainin azaldığı ve Apikal bölge strainin korunduğu gözlemlendi. Erken evre kardiyak amiloidoz ile uyumlu olabileceği düşünüldü. Serum ve idrar immün elektroforezi ve kemik iliği biopsisi planlandı. Serum ve idrar immün elektroforezi lambda hafif zincir bandı saptandı ve kemik iliği biyopsisi sonucunda yaygın blast görülmesi üzerine hastaya multipl miyelom (MM) tanısı kondu. Hastaya VEL-DEX (2,2 mg bortezomib+40 mg deksametazon) protokolü başlandı. Evreleme için PET planlandı. PET sonucu ile birlikte hastaya sırt, kalça ve göğüs kafesi bölgelerinde evre III lambda hafif zincir MM olarak belirlendi. Hastanın PET görüntülemesinde göğüs kafesi kemiklerinde tutulum olduğu gözlemlendi ve hastanın göğüs ağrısının nedeninin MM kemik tutulumu ve biomarker yüksekliğinin nedeninin ise kardiyak amiloidoz olduğu saptandı.

Sonuç: Kardiyak amiloidoz nadir hastalıklardan biridir. Avrupa Kardiyoloji kılavuzlarında TTE ile değerlendirilen hastalarda hipertrofi bulgularının görülmesi ve duvar kalınlığı 12 mm üzerinde olması durumunda amiloidoz açısından GLS ekokardiyografi önerilmektedir. Hastamızda hipertrofi bulguları olmamasına rağmen klinik şüphe üzerine GLS ekokardiyografi incelemesinde amiloidoz ile uyumlu bulgular saptandı. Bu vakayı hipertrofi olmayan hastalarda bile amiloidoz görülebileceği ve amiloidozun nadir de olsa göğüs ağrısı ve biomarker yüksekliğine yol açabileceğini vurgulamak istedik.

Anahtar kelimeler: Kardiyak amiloidoz, multipl miyelom, göğüs ağrısı



Şekil 1. Elektrokardiyografi.



Şekil 2. Transtorasik ekokardiyografi (Apikal 4 boşluk).

OP-10.

[Radial Artery Spasm during Transradial Catheterization]

Transradyal Kateterizasyon Sırasında Radyal Arter Spazmı

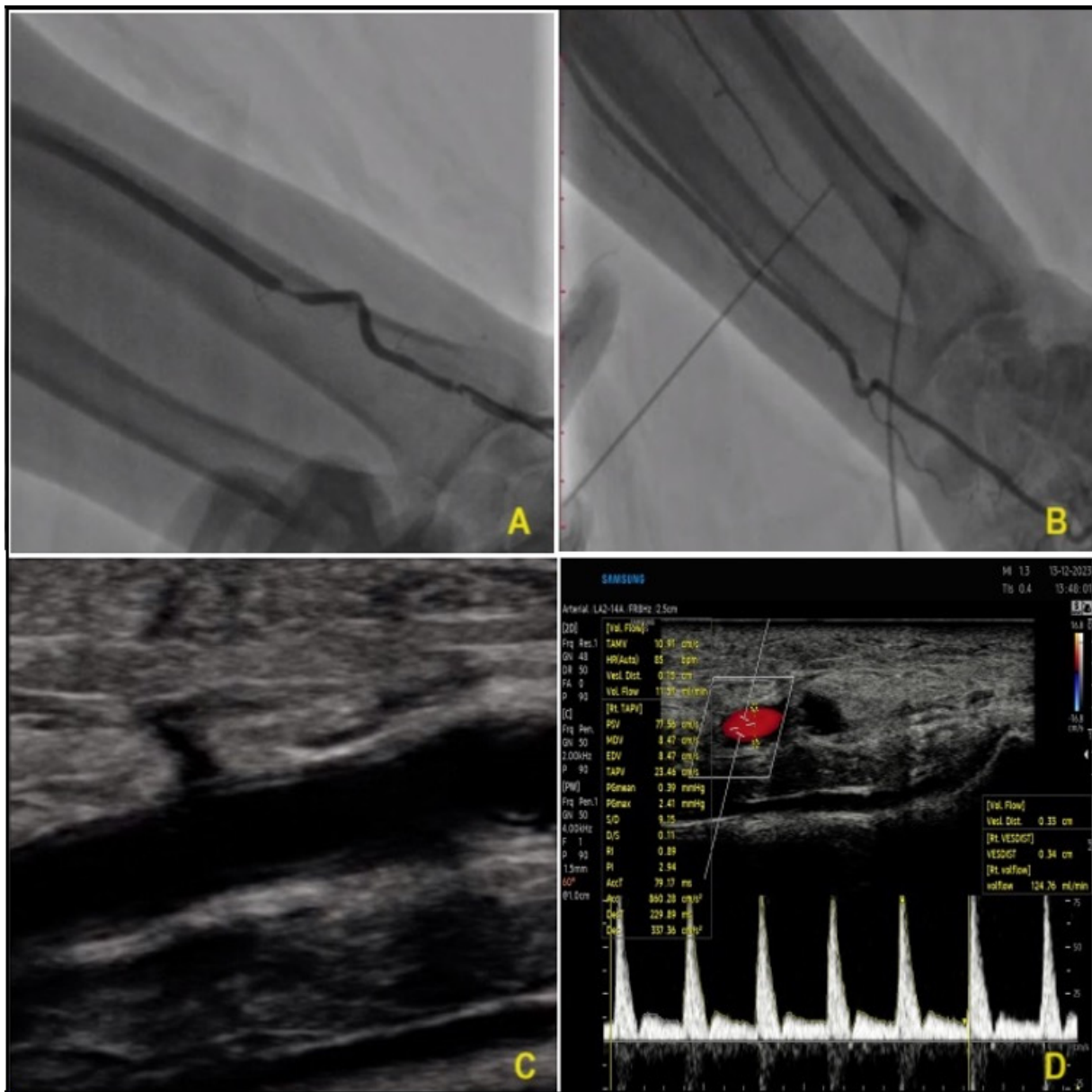
Sahhan Kılıç¹, Mustafa Oğuz¹, Süha Asal¹, Kenan Kadirli², Ahmet Lütfullah Orhan¹

¹SBÜ Sultan 2. Abdülhamid Han Eğitim ve Araştırma Hastanesi, Kardiyoloji Kliniği, İstanbul, Türkiye; ²SBÜ Sultan 2. Abdülhamid Han Eğitim ve Araştırma Hastanesi, Radyoloji Kliniği, İstanbul, Türkiye

Günümüzde koroner anjiyografide transradyal yaklaşım (TRA) transfemoral yaklaşıma göre daha çok tercih edilmektedir. Hem tanı hem de tedavi prosedürlerinde TRA'nın transfemoral yaklaşıma göre daha az lokal komplikasyon, majör kanama, iskemik oranlarına sahip olduğu gösterilmiştir. Ancak TRA'nın uzun süreli radyasyona maruz, uzun süreli öğrenme eğrisi ve radyal arter spazmı (RAS) nedeniyle dezavantajları bulunmaktadır. Radyal arter spazmını öngörmenin ve olası komplikasyonun yönetimi oldukça önemlidir. Bu vakamızda radyal ponksiyon esnasında radyal arter spazmı gelişen hastada önleyici ve işlem stratejimizi paylaşıyoruz. Yetmiş üç yaşında erkek hasta eforla anjina yakınması nedeniyle başvuruyor. Bilinen koroner arter hastalığı ve periferik arter hastalığı, hipertansiyon, sigara risk faktörleri mevcuttu. Alt ekstremitte BT anjiyografide sağ ana iliak arterde oklüde stent, sol ana iliak %50'e varan plak mevcuttu. EKO'da EF%60 ve sol ventrikül hipertrofisi vardı. Koroner anjiyografi önerildi. Femoral nabız muayenelerinde ve sağ radyal arterde nabız hissedilmemesi üzerine işlem sol radyal arter ponksiyonu ile planlandı. Koroner anjiyografide IM proksimal ve CX mid bölgede kritik lezyon saptandı. Kritik lezyonları IM ve CX'e PCI planlandı. TRA ponksiyon bölgesine lokal anestezi yapıldı. Radyal artere iğne ponksiyonu sonrası kanül teli ilerletilememesi üzerine spazmdan şüphelenildi. Seldinger iğnesi üzerinde kontrast verilerek skopide spazm seviyesi belirlendi (Şekil 1A). Sedasyon amaçlı IV midazolam ve seldinger iğne üzerinden nitrogliserin ve verapamil uygulandı. Tel ilerletilemeyince skopide spazmın devam ettiği ve spazm bölgesine işaret konularak spazm bölgesinin proksimalinden tekrar ponksiyon uygulandı (Şekil 1B). Transradyal yaklaşımla 5F kanül yerleştirildi ve işlem komplikasyonsuz sonlandırıldı. Yatışından 1 gün sonra yapılan sol radyal arter Doppler incelemede akımın normal olduğu ve lezyon olmadığı spazm lehine olduğu izlendi (Şekil 1C ve D). Sağ radyal arterin oklüde olduğu görüldü. Hasta medikal tedavisi düzenlenerek önerilerle taburcu edildi. Radyal arter, diğer somatik damarlara kıyasla spazma karşı daha yatkındır. Dolayısıyla kılavuz telin, kılıf kanalının veya kateterin yerleştirilmesi kolaylıkla radyal arterde vazokonstriksiyona neden olur. Spesifik olarak RAS işlemin herhangi bir aşamasında ortaya çıkabilir. RAS öngörücüleri arasında küçük radyal arter çapı, dış kılıf çapı/RA çap oranı, değiştirilen kateter sayısı, başarısız ilk kanülasyon denemesi, kullanılan kontrast miktarı, diyabet, kadın cinsiyet, radyal arter anomalileri, ağırlı kateterizasyon, genç yaş sıralanır. TRA'da RAS gelişmesini önlemek amacıyla nitrogliserin, verapamil ve midazolam ajanları verilebilir. Hidrofilik kaplı kılıf ve kateterlerin kullanımı RAS insidansını %1'e kadar azaltabilmektedir. Literatürde, başarılı ponksiyon sonrası kılavuz tel, kateter ilerlemesi ve manipülasyonu sonrası gelişen radyal arter spazm yönetimine yönelik birçok çalışma vardır. Ancak ilk ponksiyon esnasında spazm gelişen ve kanülasyon yapılamayan hastada işlem yönetimi hakkında sınırlı veri bulunmaktadır. Klinik pratikte başarısız radyal arter kanülasyonu sonrası genellikle karşı taraf radyal arter ya

da femoral arter ponksiyonuna geçilir. Ponksiyon yeri sınırlı olan hastalarda, bilateral femoral arter tıkanıklığı, abdominal aort tıkanıklığı, tek taraflı kolda diyaliz fistülü olması gibi, başarısız arter kanülasyonu nedeniyle işlem başarısı azalmaktadır. Bu nedenle başarılı bir kanülasyon için RAS önleyici uygulamalar eksiksiz yapılmalıdır. Buna rağmen ilk ponksiyon esnasında spazm gelişirse, bu vakada uyguladığımız basamaklar önem kazanmaktadır. Vakada uygulanan, seldinger içerisinden vazodilatatör madde uygulamasına rağmen spazmın çözülmemesi, daha sonra aynı yerden kontrast madde ile görüntüleme yapılarak radyal arterde gelişmiş olan spazm seviyesinin belirlenmesi ile aynı arterde yeni bir ponksiyon lokasyonu şansı doğabilir. Bu seviye işaretlenip proksimaline başarılı bir ponksiyon yapılması, işlem başarısını artıracaktır.

Anahtar kelimeler: Transradyal kateterizasyon, radyal arter spazmı, vasodilatör



Şekil 1.

OP-11.

The Effect of Naples Prognostic Score in Predicting Saphenous Vein Graft Disease in Patients with Coronary Bypass

Akın Torun¹, Şahhan Kılıç¹, Mehmet Şeker², Serkan Dilmen³, Selami Doğan⁴, Samet Yavuz¹, Didar Mirzamidinov⁵

¹Department of Cardiology, University of Health Sciences, Sultan 2. Abdülhamid Han Training and Research Hospital, İstanbul, Türkiye; ²Department of Cardiology, Şırnak State Hospital, Şırnak, Türkiye; ³Department of Cardiology, İzmir Bayraklı City Hospital, İzmir, Türkiye; ⁴Department of Cardiology, Malkara State Hospital, Tekirdağ, Türkiye; ⁵Department of Cardiology, Kocaeli University, Kocaeli, Türkiye

Objective: Coronary artery bypass graft surgery (CABG) is one of the main revascularization methods in coronary artery disease. However, incidence of saphenous vein graft disease (SVGD) is high in the long term. Inflammatory processes affect the formation of SVGD. Therefore, we evaluated the predictive value of Naples prognostic score for SVGD.

Methods: The study was retrospective in design. We included the data of 514 patients who presented to two centers between 2019-2022. A stenosis of 50% or more in the saphenous graft other than the anastomotic line was considered as SVGD. Patients with a history of inflammatory disease were excluded from the study. Results from routine rheological and biochemical studies obtained 24 hours before the operation were evaluated. The Naples scores of the SVGD group and the control group were compared and their effects on saphenous vein graft disease were investigated.

Results: Naples score was higher in the group with saphenous vein disease (mean: 2.2 ± 1.2) than the group without saphenous vein disease (mean: 1.8 ± 1.2) ($P=0.006$) (Table 1-2). Also, Naples classification was found to be higher in the group with saphenous vein disease (mean: 2.3 ± 0.7) than in the group without saphenous vein disease (mean: 2.1 ± 0.7) ($P=0.029$) (Table 3).

Conclusion: Naples prognostic score is a simple, cost-effective and easily calculable prognostic score. Considering the inflammatory processes in the pathophysiology of atherosclerosis, the Naples prognostic score was observed to be useful in predicting saphenous vein graft disease. This positive prognostic effect is present in both the Naples score and the Naples group classification.

Keywords: Naples group classification, saphenous vein graft disease, predictors

Table 1. Basal characteristics of the patients during the index coronary angiography

	SVGD (278)	Control group ^a (236)	P value
Male Gender, n (%)	236 (45.9)	201 (39.1)	0.999
Age (years) (mean±SD)	68.6±9.3	67.1±7.5	0.329
Hypertension, n (%)	242 (47.1)	192 (37.4)	0.087
Diabetes mellitus, n (%)	162 (31.5)	115 (22.4)	0.033
Hyperlipidemia, n (%)	195 (37.9)	142 (27.6)	0.020
Peripheral arterial disease, n (%)	47(9.1)	32(6.2)	0.327
Chronic kidney disease, n (%)	79 (15.4)	42 (8.2)	0.005
Cerebrovascular accident, n (%)	26 (5.1)	20 (3.9)	0.759
Smoking, n (%)			0.001
Active	102 (19.8)	73 (14.4)	
Ex-smoker	19 (3.7)	2 (1)	
Never	157 (30.5)	161 (31.5)	
Medical treatment, n (%)			
Antiaggregant	257(50.0)	218(42.4)	0.999
Anticoagulant	38(7.4)	25(4.9)	0.345
Beta Blocker	227(44.2)	182(35.4)	0.228
ACE/ARB	188(36.6)	119(23.2)	0.001
Spirinolactone	55(10.7)	24(4.7)	0.003
Statin	190(37.0)	127(24.7)	0.001
Calcium Channel Blocker	70(13.6)	46(8.9)	0.139

ACE/ARB=angiotensin converting enzyme/ angiotensin receptor blocker, SVGD=saphenous vein graft disease.

^aPatients with patent saphenous vein grafts without disease.

Table 2. Graft Details and Laboratory Parameters of Groups

	SVGD	Control Group ^a	P value
Age of saphenous vein graft (mean±SD)	9.30±8.10	7.50±5.90	0.003
Saphenous graft (mean±SD)	2.10±0.80	1.60±0.80	<0.001
Hemoglobin, mg/dL (mean±SD)	13.80±9.80	14.10±10.80	0.850
WBC, ×1000μL (median, IQR)	8.90±9.0	8.0±2.80	0.194
Platelet, × 1000μL (median,IQR)	224.9±68.5	219,9±59,8	0.429
Total cholesterol, mg/dl (median,IQR)	170.8 (46.9)	180 (51.5)	0.060
LDL, mg/dL (median, IQR)	99.50 (39.60)	106.6 (42.5)	0.870
HDL, mg/dL (mean±SD)	42.30±10.90	43.60±11.40	0.265
Albumin	41.6 (25,9)	39.7 (5.2)	0,411
Lymphocyte-to-monocyte ratio	20.2 (25.0)	6.1 (9.9)	<0.001
Neutrophil-to-lymphocyte ratio	17.3 (20.6)	3.4 (4.2)	<0.001

HDL=high density lipoprotein, LDL=low density lipoprotein, SII=systemic inflammation index, SVGD=saphenous vein graft disease, WBC=white blood cell. ^aPatients with patent saphenous vein grafts.

Table 3. Comparison of Naples score and group of two patient groups according to saphenous vein graft disease

	Mean (SD)	P value
Naples score: SVGD	2.2 (1.2)	0.006
Control group	1.8 (1.2)	
Naples group: SVGD	2.3 (0.7)	0.029
Control Group	2.1 (0.7)	

SVGD=saphenous vein graft disease.

OP-12.**Complete atrioventricular block due to atrioventricular node invasion in a malignant melanoma****Akın Torun¹, Şahhan Kılıç¹, Samet Yavuz¹, Yusuf Turan Gül¹, Yiğithan Okar², Mehmet Uzun¹**

¹Department of Cardiology, University of Health Sciences, Sultan 2. Abdülhamid Han Training and Research Hospital, İstanbul, Türkiye; ²Department of Nuclear Medicine, University of Health Sciences, Sultan 2. Abdülhamid Han Training and Research Hospital, İstanbul, Türkiye

A 47-year-old female patient applied to the emergency department with complaints of facial numbness and fatigue. The patient's ECG was observed as complete atrioventricular (AV) block and hemodynamic was stable (Fig. 1). The patient was followed up with malignant melanoma in her medical history. The patient was followed up in the cardiology intensive care unit and a transesophageal echo was performed due to a mass in the heart in the transthoracic echo (TEE). TEE revealed that a multilobular mass of 71×34 mm was observed in the interatrial septum, originating from the mitral and tricuspid side (AV node localization) (Fig. 2). This mass contacts all parts of the interatrial septum except the aneurysm, prolapses into the right ventricle in diastole and partially blocks the right ventricular flow. In addition, it was observed that the mass filled the area where the superior vena cava opened into the right atrium and affected the flow. There was a PFO in the interatrial septum that created a wide right-left shunt similar to ASD. PET ct was performed in the patient considering malignant melanoma and cardiac involvement was demonstrated (Fig. 3). The patient with multiple body metastases was followed up for 16 days. No deterioration in hemodynamics was observed. The patient who did not describe any cardiac symptoms did not want pacemaker implantation. The patient was accepted as inoperative by the multidisciplinary team and his close follow-up continues. AV complete block rhythm continues in the patient, and there was no deterioration in hemodynamics.

Keywords: Malignant melanoma, atrioventricular node, complete atrioventricular block

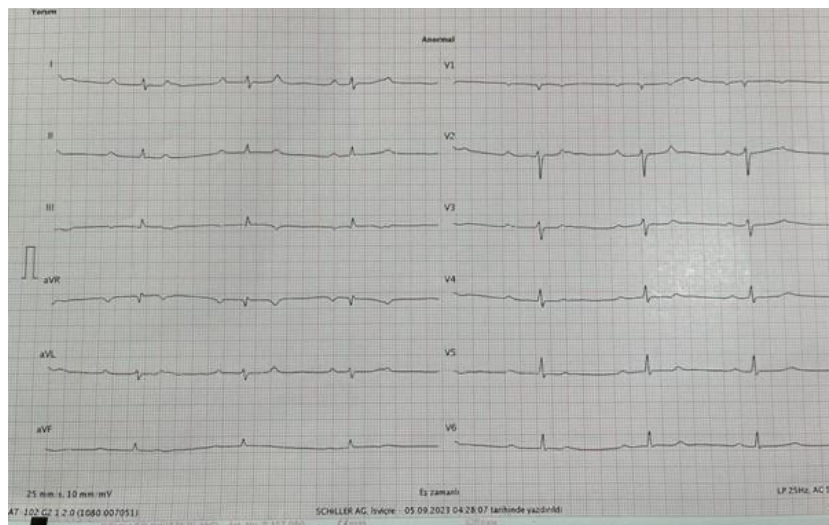


Fig. 1. Electrocardiography shows complete atrioventricular block. Atrial rate 65 bpm, ventricular rate 42 bpm.

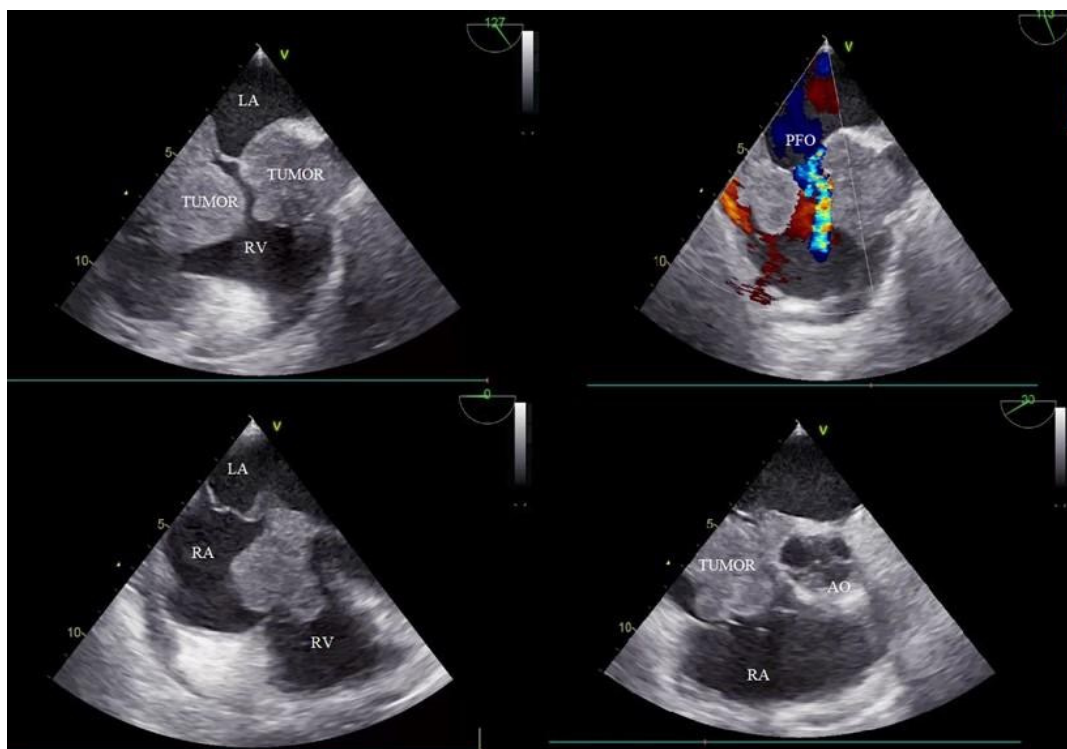


Fig. 2. TEE revealed that a multilobular mass of 71x34 mm was observed in the interatrial septum, originating from the mitral and tricuspid side (AV node localization). This mass contacts all parts of the interatrial septum except the aneurysm, prolapses into the right ventricle in diastole and partially blocks the right ventricular flow. In addition, it was observed that the mass filled the area where the superior vena cava opened into the right atrium and affected the flow. There was a PFO in the interatrial septum that created a wide right-left shunt similar to ASD.

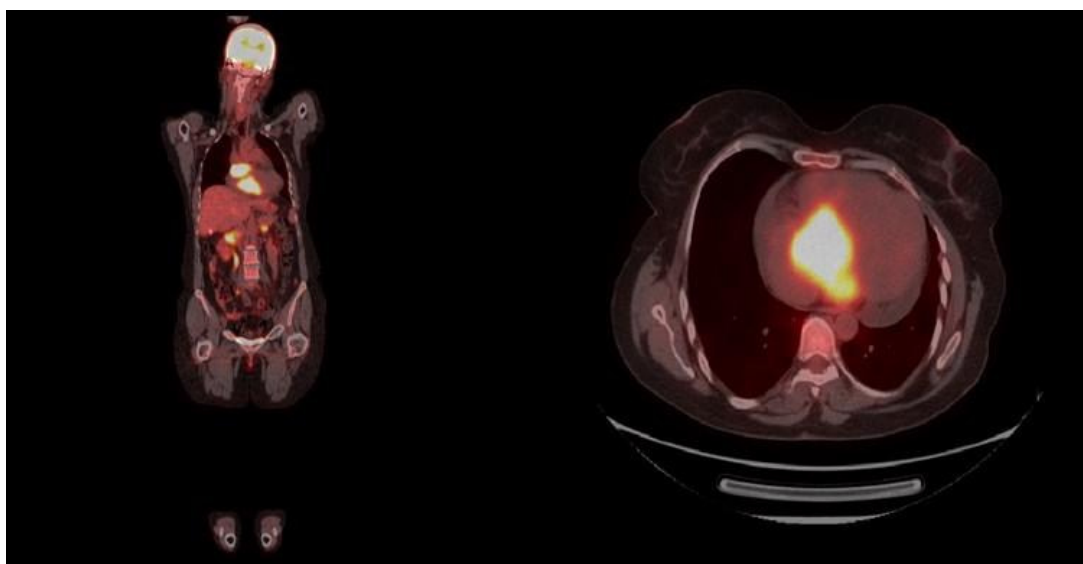


Fig. 3. In a patient diagnosed with malignant melanoma, hypermetabolic metastatic lesions were observed in the heart, both kidneys, pancreas, left hemithorax pleura, diaphragmatic surfaces, intra-abdominal peritoneal surfaces, and anterior abdominal wall. Two hypermetabolic foci are observed, measuring 29×51 in the right atrium localization and 40×31 in the atrioventricular area.

OP-13.**Effects of Upgrading from Right Ventricular Pacing to Cardiac Resynchronization Therapy and Comparison with Dual-Chamber Defibrillator in Patients with Heart Failure**

Mücahit Yarar, Hasan Arı, Mehmet Melek, Ahmet Tütüncü, Selma Arı, Tahsin Bozat, Mehmet Can Çılgın, Soner Aksüyek, Seray Yazgan, Enes İsmet Erkoç, Hüseyin Akdoğan, Doğan Ormancı, Ömer Faruk Kahraman, Bilal Mete Ülker, Esra Akpınar

Department of Cardiology, University of Health Sciences, Bursa Yüksek İhtisas Training and Research Hospital, Bursa, Türkiye

Aim: To evaluate the effects of upgrading from right ventricular (RV) pacing to cardiac resynchronization therapy (CRT) and compare it with DDDR ICD in patients with heart failure.

Methods: Patients with heart failure, left ventricular ejection fraction (LVEF)<35% and QRS>130 ms underwent de novo CRT (n=100) or upgrading to CRT [n=38; (from VVIR ICD in 16 (47.3±25.7 months after first implantation), from DDDR ICD in 15 (61.0±40.1 months after first implantation), from DDDR pace in 7 patients (66.8±57.7 months after first implantation)], and patients with heart failure, LVEF<35% and QRS≤120 ms underwent DDDR ICD (n=169) were included the study. The endpoints were death from any cause and hospitalization for heart failure, determined after a maximum follow up of 5 years.

Results: Ischemic etiology was significantly higher (P=0.002), hypertension (P=0.001) and atrial fibrillation (P<0.001) incidence were significantly lower in DDDR patients than CRT patients. The other baseline parameters were similar in the three groups (Table 1). No differences emerged between the de novo CRT, the upgrade-to-CRT, and the DDDR ICD groups with respect to any of the clinical endpoints. Death from any cause, in DDDR ICD group (n=28, 22.5 %), in de novo CRT group (n=20, 20 %), in CRT upgrade group (n=9, 23.7 %); Log Rank test P=0.64 (Fig. 1). Hospitalization for heart failure, in DDDR ICD group (n=63, 37.3 %), in de novo CRT group (n=53, 53 %), in CRT upgrade group (n=17, 44.7 %); Log Rank test P=0.83 (Fig. 2). Combination of death and hospitalization; in DDDR ICD group (n=83, 49.1 %), in de novo CRT group (n=58, 58 %), in CRT upgrade group (n=21, 55.3 %); Log Rank test P=0.67 (Fig. 3). DDDR ICD group; average number of hospitalizations before implantation: 1.91±1.36 vs after implantation: 0.66±1.13; P<0.001. De Novo CRT group; average number of hospitalizations before implantation: 1.70±1.06 vs after implantation: 0.99±1.26; P<0.001. CRT Upgrade group: average number of hospitalizations before implantation: 3.18±1.64 vs after implantation: 0.97±1.47; P<0.001. According to multivariate analysis of in this 307 patients; Age (OR: 1.05 (1.02 - 1.09), P=0.001), EF (OR: 0.91 (0.88-0.95), P=0.001), ACE/ARB using (OR: 0.41 (0.20 - 0.85), P=0.017) and MRA using (OR: 0.39 (0.19 - 0.77), P=0.007) are independent predictors of mortality (Table 2).

Conclusion: In patients with heart failure who are right ventricular ICD or pace, upgrading to CRT is associated with a similar long-term risk of mortality and hospitalization to patients undergoing de novo CRT and DDDR ICD patients. Average number of hospitalizations is significantly lower in all groups after upgrading CRT and de novo implantation CRT, DDDR ICD than before them. Age, EF, ACE/ARB using and MRA using are independent predictors of mortality in this heart failure population.

Keywords: Cardiac resynchronization therapy, right ventricular pacing, dual-chamber defibrillator, heart failure

Table 1. Baseline characteristics of the study patients

Variable	DDDR ICD	De Novo CRT	CRT Upgrade	P Value	P 1 (DDDR ICD– De Novo CRT)	P 2 (DDDR ICD– CRT Upgrade)	P 3 (De Novo CRT– CRT Upgrade)
Age (years)	63.2±11.3	66.5±9.9	62.9±10.9	0.02			
Gender (female), n (%)	30 (17.8)	23 (23)	7 (18.4)	0.56			
Ischaemic aetiology	134 (79.3)	62 (62)	22 (57.9)	0.002	0.002	0.006	0.65
CABG	39 (23.1)	25 (25)	8 (21.1)	0.87			
AVR	4 (2.4)	3 (3)	0	0.57			
MVR	6 (3.6)	5 (5)	2 (5.39)	0.80			
Diabetes mellitus	65 (38.5)	40 (40)	13 (34.2)	0.82			
Hypertension	89 (52.7)	72 (72)	30 (78.9)	0.001	0.002	0.003	0.40
Peripheral arterial disease	14 (8.3)	9 (9)	0	0.16			
CRI	10 (5.9)	13 (13)	6 (15.8)	0.06			
Medication, n (%)							
Antiplatelets	143 (84.6)	71 (71)	23 (60.5)	0.001	0.007	0.001	0.23
ACE/ARB	141 (83.4)	79 (79)	31 (81.6)	0.66			
Beta blocker	156 (93.4)	92 (92)	31 (81.6)	0.06			
Spironalakton	129 (57.3)	70 (70)	26 (68.4)	0.40			
Statin	96 (56.8)	55 (55)	17 (44.7)	0.40			
SGLT-2 inh	32 (18.9)	18 (18)	4 (10.5)	0.46			
Anticoagulants	31 (18.3)	34 (34)	17 (44.7)	0.001	0.004	0.001	0.24
EKG							
AF	26 (15.4)	33 (33)	16 (42.1)	<0.001	0.001	0.001	0.31
EF (Before pace)	28.1±9.3	25.5±6.5	25.3±9.3	0.06			
EF follow up	25.5±8.8	29.5±9.2	30.3±10.8	0.18			
EF control time after device implantation	16.8±13.03	23.8±12.7	18.8±13.01	0.04			
VT	35 (20.7)	10 (10)	9 (23.7)	0.048			
VT Ablation	18 (10.7)	4 (4)	7 (18.4)	0.02			
AF Ablation	4 (2.4)	5 (5)	1 (2.6)	0.48			
Mean hospitalization before device	1.91±1.36 (0-6)	1.70±1.06 (0-6)	3.18±1.64 (0-7)	<0.001	0.23	<0.001	<0.001
Mean hospitalization after device	0.66±1.13 (0-8)	0.99±1.26 (0-6)	0.97±1.47 (0-7)	0.04			
Time to CRT upgrade	57.3±39.4 (7-180)						
Follow up (month)	24.2±16.5	28.2±16.9	26.9±19.5	0.28			
Death, n (%)	38 (22.5)	20 (20)	9 (23.7)	0.85			
Hospitalization, n (%)	63 (37.3)	53 (53)	17 (44.7)	0.04			
Death and hospitalization, n (%)	83 (49.1)	58 (58)	21 (55.3)	0.35			

CABG=Coronary artery by-pass graft surgery, AVR=Aortic valve replacement, MVR=Mitral valve replacement, CRI=Chronic renal insufficiency, AF=Atrial fibrillation, VT=Ventricular tachicardia, EF=Ejection fraction

Table 2. Multivariate analysis of mortality predictors

Variable	Univariate	P value	Multivariate	P value
Age	1.05 (1.02-1.09)	<0.001	1.05 (1.02-1.09)	0.001
Gender	0.76 (0.37-1.57)	0.46		
Ejection fraction	0.94 (0.90-0.97)	0.001	0.91 (0.88-0.95)	0.001
Ischemic etiology	1.54 (0.81-2.92)	0.18		
CABG	1.85 (1.02-3.37)	0.04	1.50 (0.76-2.94)	0.23
Hypertension	1.71 (0.94-3.09)	0.07		
Diabetes mellitus	1.29 (0.74-2.24)	0.35		
AF	1.17 (0.63-2.18)	0.60		
VT	1.66 (0.86-3.22)	0.12		
Beta blocker	0.47 (0.20-1.12)	0.08		
ACE/ARB	0.27 (0.14-0.51)	<0.001	0.41 (0.20 - 0.85)	0.017
MRA	0.28 (0.16-0.52)	<0.001	0.39 (0.19 - 0.77)	0.007
SGLT 2	0.47 (0.20-1.16)	0.08		
DDDR ICD De Novo CRT	1.16 (0.63-2.13)	0.63		
DDDR ICD-CRT upgrade	0.93 (0.40-2.15)	0.87		
De Novo CRT-CRT upgrade	1.24 (0.50-3.03)	0.63		

CABG=Coronary artery bypass graft surgery, AF=Atrial fibrillation, VT=Ventricular tachicardia

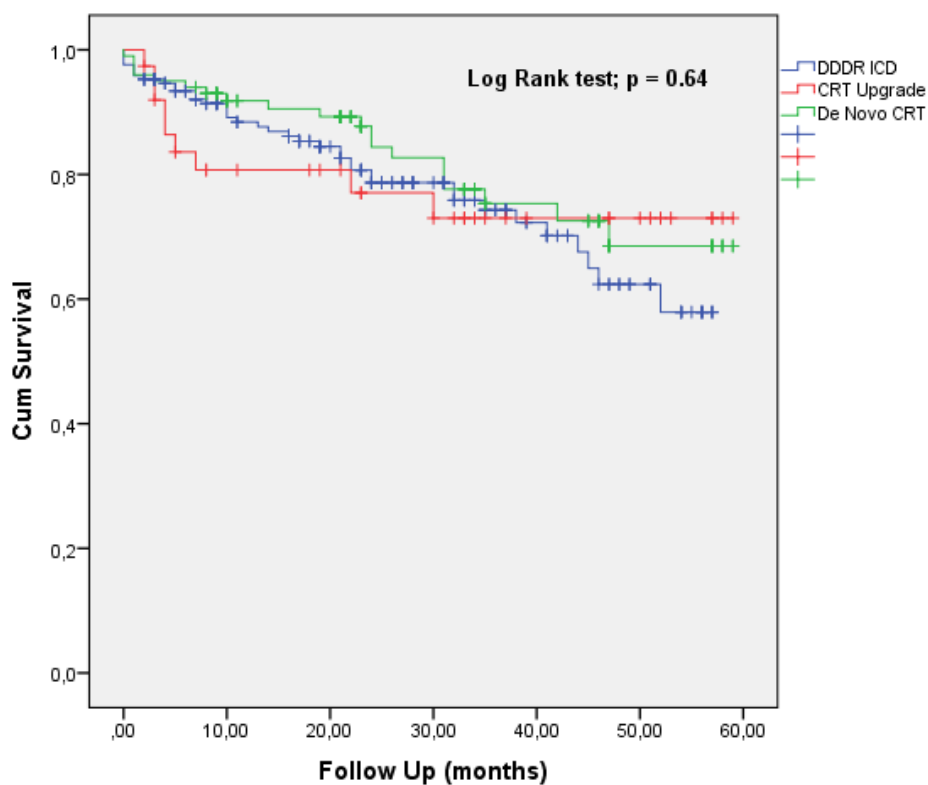


Fig. 1. All cause mortality analysis in the three groups.

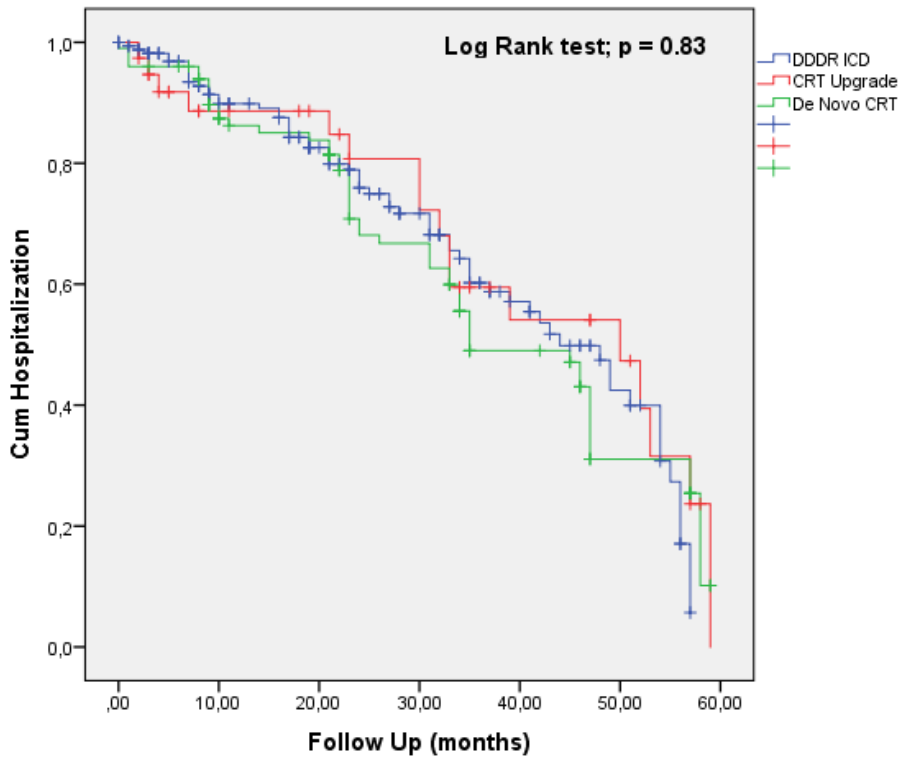


Fig. 2 Heart failure related hospitalization analysis in three groups.

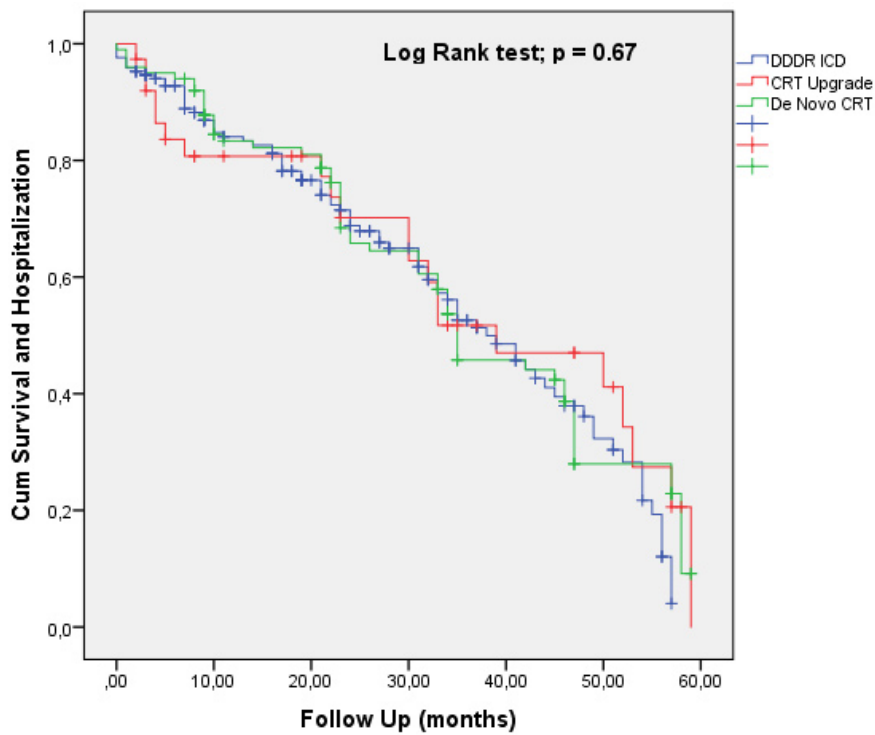


Fig. 3. Cumulative analysis of all cause mortality and heart failure related hospitalization in three groups.

OP-14.

[Chronic Inflammation Marker in Lower Extremity Peripheral Artery Patients: Platelet-Albumin Ratio]

Alt Ekstremitte Periferik Arter Hastalarında Kronik İnflamasyon Belirteci: Platelet-Albümin Oranı

Gürkan İş, Hilal Erken

Etlik Şehir Hastanesi, Kardiyoloji Kliniği, Ankara, Türkiye

Giriş ve Amaç: Alt ekstremitte periferik arter hastalığı (PAH) abdominal aorta ve aort bifurkasyonun distalindeki arterlerde daralmayla seyreden ve klinik olarak kladikasyondan amputasyona kadar ilerleyebilen ve görülme sıklığı zaman içinde giderek artan bir hastalıktır. Periferik arter hastalığı gelişimi açısından erkek cinsiyet, ileri yaş, sigara kullanımı, hiperlipidemi, hipertansiyon, diabetes mellitus ve metabolik sendrom varlığı risk faktörüdür. Periferik arter hastalığı kronik inflamasyonla seyretmektedir. Platelet-albümin oranının (PAR), kronik inflamasyonla ilişkili çeşitli bozukluklarda yükseldiği önceki çalışmalarda gösterilmiştir. Biz bu çalışmamızda alt ekstremitte periferik arter hastalarında, PAR ile belirlenen kronik inflamasyon varlığını ortaya koymayı planladık.

Yöntem: Kardiyoloji kliniğine kladikasyo şikayetiyle başvurmuş ve selektif periferik anjiyografi ile %50'den fazla arteriyel darlığı olması ile tanısı konmuş alt ekstremitte periferik arter hastaları ile hasta grubu oluşturuldu. Yaş ve cinsiyet açısından benzer normal gönüllüler ile kontrol grubu oluşturuldu. Vücut kitle indeksi (BMI) 18 kg/m²'in altında olan hastalar, akut veya kronik enfeksiyon, karaciğer yetmezliği, böbrek hastalığı, kronik inflamatuvar hastalık ve kalp yetmezliği hastaları çalışma dışı bırakıldı. Bu retrospektif çalışmada hasta ve kontrol grubunun demografik verileri, komorbid durumları ve laboratuvar verileri karşılaştırıldı. İstatistiksel analizde SPSS 20 paket programı kullanıldı. İlişkili laboratuvar verileri korelasyon analizi ile değerlendirildi.

Bulgular: İkiyüz altmış altı periferik arter hastası ile hasta grubu; 68 periferik arter hastası olmayan gönüllü ile kontrol grubu oluşturuldu. Hasta ve kontrol grubunda kadın cinsiyet oranı benzerdi (%18.4 vs.%19.1).Hasta grubunda HT sıklığı kontrol grubundan yüksekti (161 hasta(%60.5) vs.16 hasta (%23.5); DM sıklığı da hasta grubunda kontrol grubundan yüksekti (159 hasta (%59.8) vs. 8 hasta (%11.8)). Hasta grubunda albumin düzeyi kontrol grubuna göre daha düşük saptandı (3.6±0.6 vs 3.9±0.2, P<0.001),hasta grubunda platelet düzeyi kontrol grubuna göre daha yüksek saptandı (354±110 vs. 302±75, P=0.003).Hasta grubunda platelet albumin oranı kontrol grubundan anlamlı derecede daha yüksek saptandı (100±42 vs. 77.3±20.9, P<0.001).Gruplar arasında anlamlı derecede farklılıkları bulunan veriler korelasyon analizi ile incelendiğinde; PAR 0.228 korelasyon katsayısı ile en ilişkili parametre olarak saptandı, serum albümini -0.227 korelasyon katsayısı değeri ile negatif yönde olmak üzere ikinci en ilişkili parametre idi, bunu 0.164 değeri ile platelet sayısı izlemekteydi.

Tartışma ve Sonuç: Platelet albumin oranı alt ekstremitte periferik arter hastalarında anlamlı derecede yüksektir ve hastalık varlığı ile pozitif yönde ilişkilidir. Bu parametrenin bileşenleri de PAH hastalarında kontrol grubuna göre anlamlı farklılıklar göstermektedir ancak PAR kendi başına hastalıkla daha korele görülmektedir. Platelet albumin oranının PAH komplikasyonları gibi olası sonlanım ön gördürücü özelliği gelecek çalışmalarla araştırılabilir.

Anahtar kelimeler: Periferik arter hastalığı, alt ekstremitte, kronik inflamasyon, platelet-albümin oranı

Tablo 1. Hasta ve kontrol gruplarının demografik ve laboratuvar verileri

	Hasta grubu	Kontrol grubu	P değeri
Yaş (yıl)	65.9±10	64.7±5.9	0.438
Kadın cinsiyet	49 (%18.4)	13 (%19.1)	0.518
Hipertansiyon	161 (%60.5)	16 (%23.5)	<0.001
Diyabetes melitus	159 (%59.8)	8 (%11.8)	<0.001
Sigara	70 (%26.3)	13 (%19.1)	0.142
Glukoz	158±79	113±32	<0.001
BUN (mg/dL)	55.9±13	32±3	<0.001
Kreatinin (mg/dL)	1.9±0.6	0.8±0.1	0.128
Potasyum (mEq/L)	4.47±0.7	4.47±0.4	0.554
AST (IU/L)	38±5	18±0.6	0.133
LDL kolesterol (mg/dL)	124±69	120±30	0.647
Hemoglobin (g/dL)	13±8.2	14.4±1.6	0.080
WBC (10 ⁹ /L)	10.1±4.9	8.1±1.9	0.004
Platelet (10 ⁹ /L)	354±110	302±75	0.003
Albümin (g/L)	3.6±0,6	3.9±0,2	<0.001
Platelet-albümin oranı	100±42	77.3±20.9	<0.001

Veriler ortalama±standart deviasyon veya hasta sayısı (%) olarak gösterilmiştir. BUN=kan üre nitrojeni, LDL=düşük dansiteli lipoprotein, WBC= beyaz kan hücresi

Tablo 2. Periferik arter hastalığı ile ilişkili laboratuvar verileri korelasyon tablosu

Parametreler	Korelasyon Katsayısı	P değeri
Glukoz	0.218	<0.001
BUN	0.192	<0.001
WBC	0.161	0.004
Albümin	-0.227	<0.001
Platelet	0.164	0.003
Platelet-albümin oranı	0.228	<0.001

BUN=kan üre nitrojeni, WBC=beyaz kan hücresi

OP-15.**Andersen-Tawil Syndrome Diagnosed with Bidirectional Ventricular Tachycardia during Pregnancy****Mustafa Yıldız¹, Hasan Ali Barman¹, Ömer Doğan¹, Bengisu Keskin Meriç¹, Şükrü Arslan¹, Nurullah Yücel², Rıdvan Türkmen¹, İffet Doğan³, Serkan Arslan⁴**

¹Department of Cardiology, İstanbul University, Cerrahpaşa Cardiology Institute, İstanbul, Türkiye; ²Department of Anatomy, University of Health Sciences, Hamidiye International Medical Faculty, İstanbul, Türkiye; ³Department of Radiology, Mehmet Akif Ersoy Thoracic and Cardiovascular Surgery Training and Research Hospital, İstanbul, Türkiye; ⁴Department of Cardiology, University of Health Sciences, Mehmet Akif Ersoy Thoracic and Cardiovascular Surgery Training and Research Hospital, İstanbul, Türkiye

Aim: Andersen-Tawil syndrome (ATS) is a rare autosomal dominant potassium channelopathy and caused by loss-of-function mutations in the KCNJ2 and KCNJ5 genes. It is characterized by the clinical triad of periodic paralysis, cardiac arrhythmias and dysmorphic feature. This report describes a pregnant patient with ATS presenting bidirectional ventricular tachycardia.

Case: A 23 year-old female with 28 week of pregnancy referred our outpatient clinic with palpitations and dizziness. She has no remarkable medical past and no history of syncope. The physical examination revealed short stature, micrognathia, broad nose, short neck, broad forehead and fifth digit clinodactyly (Fig. 1). An initial ECG showed a prolonged QTc (518 ms) and runs of non-sustained bidirectional ventricular tachycardia (Fig. 2). Her mother and younger sister also have history of ventricular arrhythmias and fifth digit clinodactyly. Her examination was unremarkable except of irregular pulse rate. 24 hours holter revealed 40.314 (%38) premature ventricular contractions and 7 beats bidirectional non sustained ventricular tachycardia. Exercise stress testing showed non sustained bidirectional VT without an increase with exercise. Laboratory testing and transthoracic echocardiogram were normal. Genetic testing revealed KCJN2 gene mutation also in mother and sister. She was given metoprolol 2×50 mg and her holter revealed no reduction on PVCs burden and 37 beats bidirectional VT. She gave birth to her second healthy baby during approximately 4 years of follow-up. The patient, who did not accept the previously recommended ICD device, accepted the device to be inserted after her second birth. The patient with a dual ICD is being followed without any problems. Also, mother and other daughter are being followed without symptoms.

Conclusion: ATS is a rare autosomal dominant potassium channelopathy. Treatment of ventricular arrhythmias in patients with ATS is controversial and the efficiency of medication is vague. Eventhough the prognosis of ATS is believed to be benign, close monitoring is essential due to assign the patients with high risk for sudden cardiac arrest.

Discussion: ATS, also known as Long QT syndrome Type 7 (LTQ7), is a rare autosomal dominant potassium channelopathy, with a prevalence of 1/500,000. It's characterized by the clinical triad of periodic paralysis, cardiac arrhythmias (frequently ventricular arrhythmias), and dysmorphic features which includes short stature, hypertelorisms, broad nose, short neck, scoliosis, fifth digit clinodactyly, hypertelorism, low-set ears, micrognathia and broad forehead. Cardiac involvement may be asymptomatic and can be noticed incidentally. The classic cardiac characteristics include prominent U waves, bidirectional VT and very high burden of PVC. Our three cases had prolonged QTc interval marked during rest, high burden of ventricular ectopy which was more prominent in index case whom had bidirectional ventricular tachycardia on baseline ECG and holter monitoring. Antiarrhythmic treatment for patients with ATS is empirical.

Keywords: Andersen-Tawil syndrome, bidirectional ventricular tachycardia, pregnancy

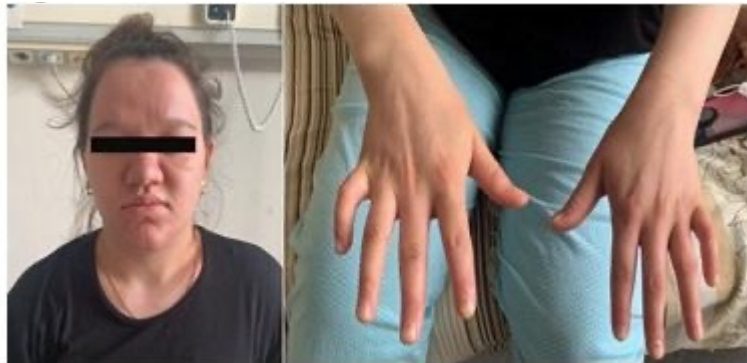

Fig. 1.

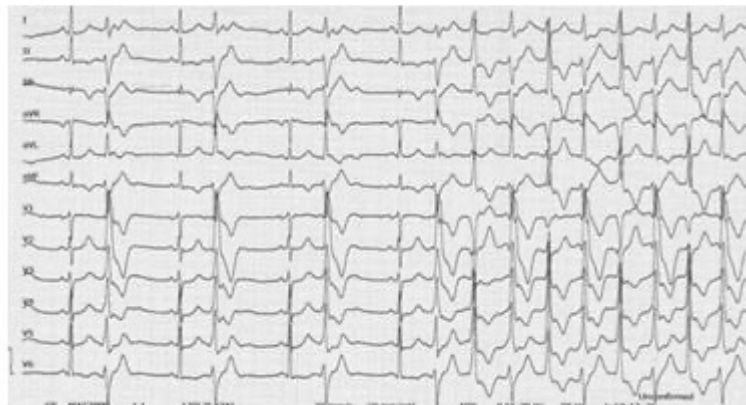

Fig. 2.

OP-16.**Intercoronary Continuity between the Right and Left Anterior Descending Coronary Arteries Causing Acute Coronary Syndrome**

Mustafa Yıldız¹, Sait Altıntaş², Hasan Ali Barman¹, Rıdvan Türkmen¹, İffet Doğan³, Nurullah Yücel⁴, Serkan Arslan⁵

¹Department of Cardiology, İstanbul University, Cerrahpaşa Cardiology Institute, İstanbul, Türkiye; ²Department of Cardiology, University of Health Sciences Training and Research Hospital, İstanbul, Türkiye; ³Department of Radiology, University of Health Sciences, Mehmet Akif Ersoy Thoracic and Cardiovascular Surgery Training and Research Hospital, İstanbul, Türkiye; ⁴Department of Anatomy, University of Health Sciences, Hamidiye International Medical Faculty, İstanbul, Türkiye; ⁵Department of Cardiology, University of Health Sciences, Mehmet Akif Ersoy Thoracic And Cardiovascular Surgery Training and Research Hospital, İstanbul, Türkiye

Aim: Intercoronary continuity refers to a bidirectional or unidirectional flow in patients with coronary arteries. This connection may have a protective role against potential obstructive coronary artery disease or related coronary steal phenomenon.

Case: A 62-year-old woman admitted with a complaint of typical chest pain (acute coronary syndrome, namely unstable angina pectoris). Surface ECG showed minimal ST segment depression at DI, DII, avF, and V4-6 derivation. Transthoracic echocardiography was normal; Ejection fraction was 53%. The patient was transferred to coronary angiography. In coronary angiography, RCA was 95% occluded in the distal region and LAD was completely occluded in the proximal region. LAD CTO region was being filled with intercoronary continuity from RCA. The RCA lesion was crossed with a floppy guide wire and 3.0x24 mm drug eluting stent was implanted (Fig. 1). The patient, who described angina and detected anterior ischemia (>10%) in myocardial perfusion scintigraphy, underwent an intervention for LAD CTO lesion one month later. The 7F Ebu catheter was placed in the LMCA and the LAD CTO lesion was crossed with a Fielder XT wire, accompanied by a microcatheter. Then, another Fielder XT wire was placed in the diagonal artery. The wire in the microcatheter was replaced with a floppy wire, and after subsequent balloons, a 3.0x32 mm drug eluting stent was placed distally and a 3.0x18 mm drug eluting stent was placed proximally by overlap (Fig. 2). The LAD artery was opened successfully.

Conclusion: This rare case report demonstrates the very dynamic nature of coronary artery flow, influenced by sometimes big sometimes small changes in the anatomy of the coronary vessels.

Discussion: Intercoronary continuity is a congenital open-ended connection between two major epicardial coronary arteries. This connection can be between the Cx and RCA or between the LAD and the PDA. The importance of intercoronary continuity is not fully understood due to very low incidence (approximately 0.02%). However, this large anastomotic connection (>1 mm) might have a potential role in protecting the myocardium in the presence of significant stenosis in main arteries. To support this hypothesis, our case had severe stenosis RCA and totally occluded in the proximal LAD, but she was hemodynamically stable. However, it should not be ignored that this anomaly itself may trigger ischemia through the coronary steal phenomenon.

Keywords: Acute coronary syndrome, intercoronary continuity, coronary artery

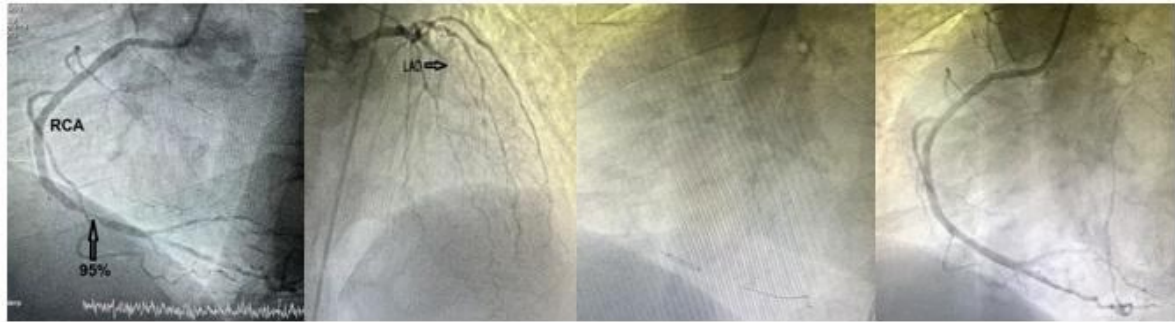


Fig. 1.

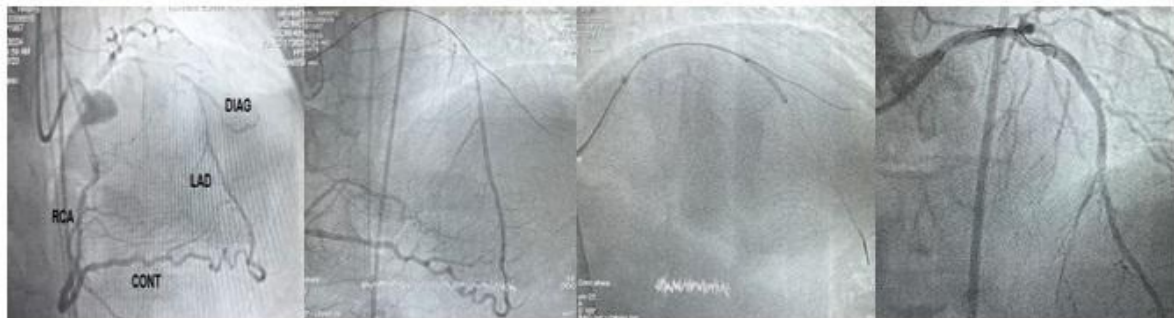

Fig. 2.

OP-17.

Effect of Glyceryl Trinitrate-Containing or Lidocaine-Containing Cream Applications before Transradial Coronary Angiography on Procedure Success and Complications

Nurullah Uslu¹, Aykut Demirkıran¹, Cihan Aydın¹, Hüseyin Aykaç²

¹Department of Cardiology, Tekirdağ Namık Kemal University, School of Medicine, Tekirdağ, Türkiye; ²Department of Cardiology, Zonguldak Atatürk State Hospital, Zonguldak, Türkiye

Objective: We aimed to investigate the impact of topical nitrate application on the puncture time and complication rate before coronary angiography using a radial approach.

Materials and Methods: All patients presenting to our university hospital with indications for coronary angiography between February 2023 and August 2023 were included in our study. Patients with topical saline applied to the radial artery half an hour before the procedure were designated as Group 1, those with topical nitrate were designated as Group 2, and those with topical lidocaine were designated as Group 3. The data of the three groups were compared.

Results: Our average puncture time was 142±122 seconds, with 171±131 seconds in Group 1, 88±48 seconds in Group 2, and 157±146 seconds in Group 3 (Table 1). In Group 1, successful single puncture was achieved in 49.1% of patients, in Group 2 it was 76.7%, and in Group 3 it was 57.5%. The failure rate in puncture was 11.8% in Group 1, only 2.3% in Group 2, and 7.5% in Group 3. The homogeneously distributed data of these three groups were compared, and significant differences were observed among the groups in terms of puncture time (P=0.002), success in a single puncture (P=0.018), and number of punctures (P=0.001), as well as the transition to the femoral artery due to unsuccessful access (P=0.045). This difference was determined to originate from the second group where nitrate-containing cream was applied.

During the procedure, radial artery spasm was observed in 15.2% of patients in Group 1, 6.9% in Group 2, and 12.5% in Group 3 (P=0.043). Radial artery occlusion was seen in 8% of patients in Group 1, 2.5% in Group 3, while it was not observed at all in the nitrate-applied group (P=0.041). When the groups were compared for total complications, a significant difference was observed, and this difference was again attributed to the group where nitrate-containing cream was applied (P=0.010).

Conclusion: The topical application of nitroglycerin half an hour before radial artery intervention is a feasible and easy strategy to reduce radial puncture time and number, facilitate transradial catheterization, and decrease the incidence of radial artery spasm and occlusion.

Keywords: Coronary angiography, transradial, nitroglycerin, lidocaine, spasm

Table 1. Comparison of the puncture characteristics and complications of the groups

	Group 1		Group 2		Group 3		P value
	Saline	(n=59)	Nitrate	(n=43)	Lidocaine	(n=40)	
	n	%	n	%	n	%	
Puncture count							
Single puncture	29	49.1	33	76.7	23	57.5	0.018
>2 puncture	30	50.9	10	23.3	17	42.5	
Transition to femoral	7	11.8	1	2.3	3	7.5	0.045
Complications	24	40.6	4	9.3	9	22.5	0.010
Spasm	9	15.2	3	6.9	5	12.5	0.043
Hematoma	9	15.2	1	2.3	3	7.5	0.022
Occlusion	5	8.47	0	0	1	2.5	0.041
Pseudoaneurysm	0	0	0	0	0	0	1.000
Dissection/Rupture	0	0	0	0	0	0	1.000
Compartment syndrome	0	0	0	0	0	0	1.000
Puncture time (seconds)	171±131		88±48		157±146		0.002
Puncture count, median (min-max)	2 (1-8)		1 (1-4)		1 (1-6)		<0.001

OP-18.

[A Rare Complication after Transradial Intervention: Sterile Granuloma]

Transradyal Girişim Sonrası Nadir Bir Komplikasyon: Steril Granülom

Fahrettin Tuğrul Çitekcı¹, Zeynep Yapan Emren², Sadık Volkan Emren¹, Narmina Ahmadli¹

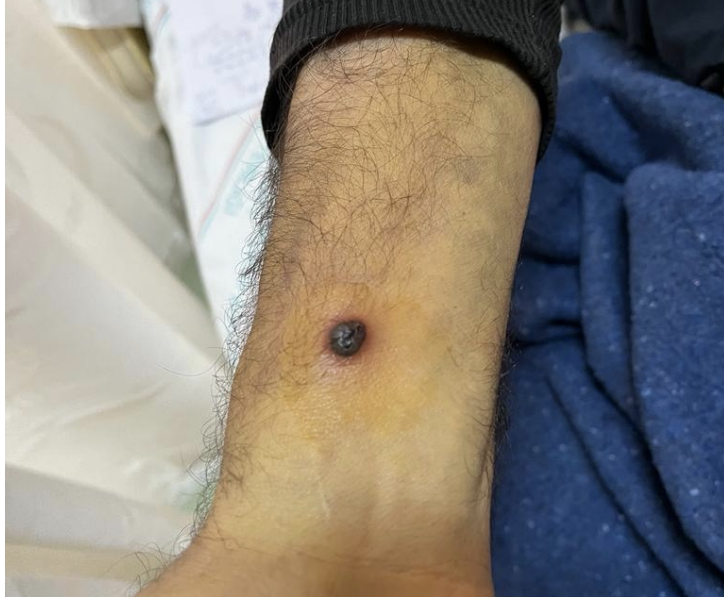¹Katip Çelebi Üniversitesi, Tıp Fakültesi, Kardiyoloji Anabilim Dalı, İzmir, Türkiye; ²Departman of Cardiology, Bakırçay University, Medical of School, İzmir, Turkey

Giriş: Radial arter girişimleri komplikasyonlar açısından transfemoral girişimlere göre daha üstün olsa da nadir komplikasyonlar görülebilmektedir. Bu olguda transradial girişim sonrası işlem bölgesinde oluşan steril granülom vakası sunulmuştur.

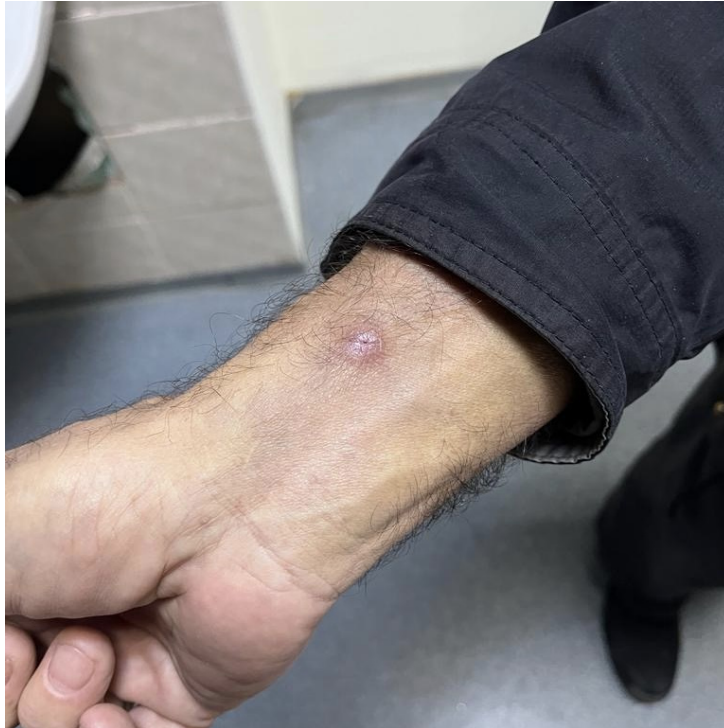Olgu: Altmış altı yaşında erkek hasta dispne, ortopne ve konjesyon bulguları ile acil servise başvurdu. Bilinen ek bir hastalığı olmayan ve ilaç kullanımı da bulunmayan hastanın fizik muayenede bilateral bazalde ralleri, 1+/1+ pretibial ödemi mevcuttu, kardiyak oskültasyonda kalp sesleri aritmikti, ek ses veya üfürüm işitilmedi. Hastanın elektrokardiyografisinde atrial fibrilasyon harici ek patoloji izlenmedi. Yapılan ekokardiyografide ejeksiyon fraksiyonu %23 saptandı, major kapak patolojisi izlenmedi. Hasta yeni tanı kalp yetmezliği ile kardiyoloji servisine yatırıldı. Kalp yetmezliği açısından medikal tedavisi başlanan ve diüretik tedavi ile konjesyon bulguları gerileyen hastaya koroner anjiyografi planlandı. Sağ radial arter yoluyla hastaya koroner anjiyografi yapıldı ve nonkritik koroner arter hastalığı saptandı. Koroner anjiyografi Ares Medikal 6F A2615(TM) marka kılıf ile gerçekleştirildi. İşlem sonrası radial kılıfı sorunsuz çıkarılan hasta 3 saat radial bant ile takip edildi ve hemostaz sağlandı. Koroner anjiyografiden 7 gün sonra hastanın girişim bölgesinde ağrısız bir papül nodüler lezyon izlendi (Şekil 1). Kapiller dolum zamanı normal ve radial arter pulsatil idi, o bölgede ısı artışı izlenmedi. Hastanın kan kültürlerinde üreme gözlenmedi ve enfektif değerlerinde artış izlenmedi. Sıcak uygulama ve yara bakımı ile takip edilen hastanın lezyonu 1 hafta içerisinde kendiliğinden geriledi (Şekil 2).

Tartışma: Granülomatöz inflamasyon bir organizmaya, sistemik hastalığa veya yabancı cisme karşı bağışıklık sisteminin inflamatuvar reaksiyonu ardından aktive makrofajların yer aldığı bir cevap olarak tanımlanabilir. Steril tanımı ise bu reaksiyonun non-enfektif süreçlerini ifade etmekte kullanılır. Steril granülom transradial girişimler sonrası girişim bölgesinde oluşan papül nodüler bir lezyondur. Nadir görülür, iyi seyirli ve spontan regresyon sıktır. Yapılan çalışmalarda radial arterler için kullanılan hidrofilik kılıfların steril granülom riskini arttırdığı gözlenmiştir. Steril granülom genellikle işlemden 1-3 hafta sonra gözlenir ve herhangi bir cerrahi işleme gerek duyulmadan haftalar içerisinde regrese olur ve sekelsiz iyileşir. Ayırıcı tanılardan radial arter pseudoanevrizmalarının dışlanması için ultrasonografik değerlendirmelerin yapılması benzer vakalarda uygun bir yaklaşım olacaktır.

Anahtar kelimeler: Transradyal Girişim, Steril Granülom, Komplikasyon



Şekil 1. Sağ radial arter girişim bölgesinde işlemten 1 hafta sonra görülen papulonodüler lezyon görülmekte.



Şekil 2. Lezyon gelişiminden 1 hafta sonra granülomda spontan iyileşme mevcut.

OP-19.**[Multidisciplinary Management of a Common Variable Immunodeficiency Case with Myopericarditis]****Miyoperikarditli Yaygın Değişken İmmün Yetmezlik Olgusunun Multidisipliner Yönetimi****Yiğit Yaren¹, Selin Abdu¹, Şeyda Günay Polatkan¹, Gökhan Gökalp²**

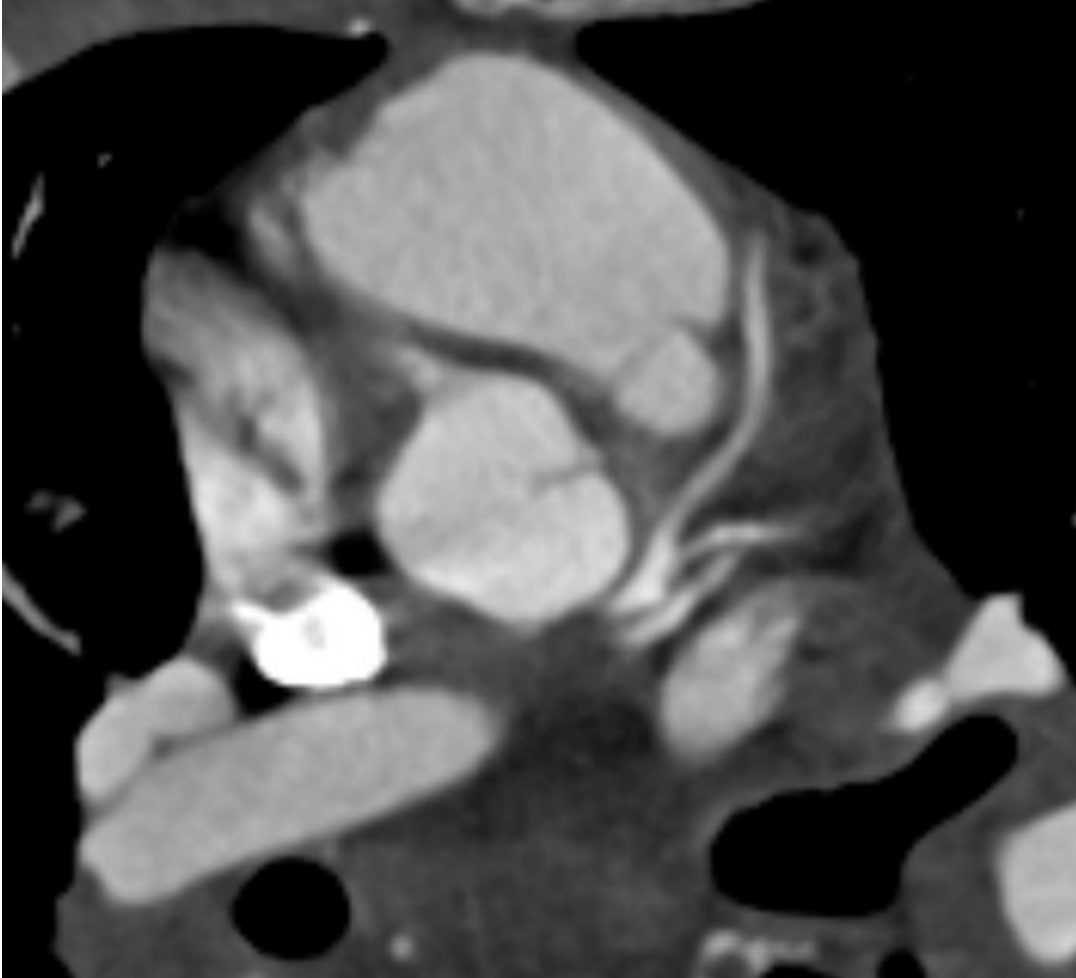
¹Bursa Uludağ Üniversitesi Tıp Fakültesi, Kardiyoloji ABD, Bursa, Türkiye; ²Bursa Uludağ Üniversitesi Tıp Fakültesi, Radyoloji ABD,, Bursa, Türkiye

Giriş: Yaygın değişken immün yetmezlik (common variable immunodeficiency-CVID) en sık görülen primer immün yetmezliklerden biridir. CVID, hipogamaglobulinemi ve zayıf antikör yanıtı ile karakterizedir. Sık tekrarlayan üst ve alt solunum yolu bakteriyel enfeksiyonları, otoimmünite, enteropati, malignite, alerjik ve lenfoproliferatif hastalık tablolarına neden olabilir. Kardiyovasküler tutulum yaygın görülmemekle beraber, literatürde bildirilen akut perikardit, perikardiyal efüzyon, miyokardit ve aort anevrizması vakaları mevcuttur.

Olgu: Yirmi bir yaşında, CVID tanısıyla takip edilmekte olan ve büyüme geriliği, kronik hepatit, portal hipertansiyon öyküsü olan erkek hasta nefes darlığı ve batıcı vasıfta göğüs ağrısı nedeniyle acil serviste değerlendirildi. Hastanın son birkaç gündür ateş yüksekliği ve üst solunum yolu enfeksiyonu semptomları olduğu öğrenildi. Fizik muayenede ateş: 37.4°C, nabız:122 vuru/dk, kan basıncı 126/66 mmHg saptandı. Kalp sesleri ritmik taşikardikti, solunum sesleri doğal, ral ve ronküs yoktu, asit ve pretibial ödemi yoktu. Elektrokardiografide sinüs ritmi, 100 atım/dk, inkomplet RBBB, V1-2'de 1-2 mm ST elevasyonu izlendi. PA akciğer grafisinde kardiyotorasik oran artmış, kostofrenik sinüsler açık izlendi (Resim 1). Laboratuvar bulgularında; Lökosit: $5.64 \times 10^9/L$, nötrofil: %59, hemoglobin: 9 g/dL, platelet: $91 \times 10^9/L$, C-reaktif protein: 201 mg/L, kreatinin: 0,89 mg/dL, D-dimer: 3539 mcg/L, prokalsitonin: 59 mcg/L, Troponin-I: 636 ng/L, CK: 203 IU/L, CK-MB: 57 IU/L, BNP: 264 ng/L saptandı. Yapılan transtorasik ekokardiyografide (TTE): Sol ventrikül çap ve duvar hareketleri normal, LVEF: %60, sağ atriyum ve sağ ventrikülde dilatasyon, hafif derecede mitral, hafif-orta derecede triküspit yetmezlik, sPAB: 36 mmHg, perikardiyal aralıkta en kalın olduğu yerde 8 mm perikardiyal mayi izlendi. Toraks BT'de: Pulmoner arter ve ana dallarında pulmoner emboli ile uyumlu dolum defekti saptanmadı. Sol üst lobda konsolidasyon, solda 1 cm plevral efüzyon, perikardiyal aralıkta en kalın olduğu yere 1 cm perikardiyal mayi, interlobüler septalarda kalınlık artışı ve buzlu cam alanları izlendi. Hasta kardiyoloji, göğüs hastalıkları, immünoloji ve enfeksiyon hastalıkları tarafından multidisipliner değerlendirilerek ön planda influenza veya covid pnömonisi, eşlik eden olası sekonder bakteriyel pnömoni ve viral miyokardit ön tanılarıyla iv sefepim, oral klaritromisin, oseltamivir, metoprolol ve subkutan DMAH başlandı. Koroner yoğun bakıma yatırılarak monitörize takip edildi. Takipte hipotansiyon gelişmesi nedeniyle noradrenalin infüzyonu başlandı. Troponin-I değerinin 1533 ng/L'ye yükseldiği ve kontrol TTE'de perikardiyal mayide artış (apeks komşuluğunda 10 mm, sağ ventrikül komşuluğunda 20 mm, sağ atriyum komşuluğunda 14 mm) saptandı, sağ yapılar sistol ve diyastolde bası yoktu. Solunum yolu viral panel ve covid pcr testleri negatif sonuçlandı. Tekrar immünoloji görüşü alınarak 30 gr IVIG verildi ve tedaviye kolşisin eklendi. Takipte akut faz reaktanları geriledi, noradrenalin infüzyonu kesildi. Hemodinamisi stabil olan hasta mobilize edildi. Koroner BT anjiyografide koronerler normal saptandı (Resim 1). Hasta şifa ile taburcu edildi.

Sonuç: CVID hastalarında kardiyovasküler tutulum literatürde nadir bildirilmekle birlikte fulminan seyirli bir miyoperikardit ile komplike olmadan vakalar erken tanınmalı, multidisipliner yönetilmeli ve gerekli immünolojik tedaviler hızlıca başlanmalıdır.

Anahtar Kelimeler: Miyoperikardit, yaygın değişken immün yetmezlik, multidisipliner yönetim



Resim 1. Koroner BT Anjio

OP-20.

A Case with Coronary Perforation

Mustafa Yılmaz, Sefa Erdi Ömür

Department of Cardiology, Tokat Gaziosmanpaşa University, School of Medicine, Tokat, Türkiye

Introduction: Coronary perforation is a very rare complication that can be observed during percutaneous coronary interventions. They may develop due to the guide wire perforating small branches, high pressures during balloon stent applications, intracoronary device applications (coronary rotablator) or rarely due to trauma. Coronary perforation has high mortality when not diagnosed or treated appropriately. Coronary perforations can be divided into 3 subtypes. Ellis Type 1 perforations opening into extraluminal spaces, Ellis Type 2 myocardial or pericardial flushing, Ellis Type 3 perforations opening outwards.

Purpose: This case report aims to raise awareness about coronary perforations, which are a rare but difficult to manage complication, and to provide ideas to operators in case of a possible coronary perforation. We are sharing with you this rare and difficult to manage complication that we encounter in our clinic.

Case: A 59-year-old male patient was taken to the cath laboratory. The 90% tubular calcific lesion in the left anterior descending artery (LAD) was wired with floppy wire and predilated with a 2.0×20 mm semicompliant balloon. When thrombolysis in myocardial infarction (TIMI) -1 flow was detected in the LAD, the wire was thought to be subintimal and the wire was withdrawn and the LAD wire was pulled again. When the balloon was inflated again, TIMI 2 flow and Ellis type 3 perforation were observed in the LAD (Fig.1). On bedside echocardiography, a 1.5 cm pericardial effusion was observed in the widest area (near the posterior wall). Due to the deterioration of the patient's hemodynamics, pericardiocentesis and autotransfusion were performed. The semi-compliant balloon was inflated at nominal pressure at intervals of 5 to 10 minutes and waited for 10 minutes at a time. A 3.5'19 mm graft coated with polytetrafluoroethylene stent was implanted to cover the perforation area, but it was observed that the perforation continued. The semicompliant balloon in the stent area was inflated again at nominal pressure and protamine sulfate was started (40 mg/30 min.). When the balloon was removed, it was observed that the implanted stent was thrombosed (Fig.2). Since the patient continued to have chest pain, emergency surgery was planned. The patient underwent LAD-LIMA (left internal mammary artery) anastomosis with Beating Heart Coronary Artery Bypass Grafting. The patient was discharged with full recovery a week later.

Conclusion: Coronary perforation is a complication that must be recognized and treated urgently. The ability of graft stents to maintain luminal flow is a superior feature of other methods. Prolonged balloon application may limit perforation. Thrombosis of the perforated vessel with embolic materials is also among the techniques used. If the perforation cannot be limited despite coronary interventions, surgical closure of the perforation should be considered.

Discussion: Graft stent applications and extended balloon applications seem to be useful in limiting perforations. In long or wide perforations, graft stents are superior to prolonged balloon applications. In cases where perforation cannot be limited, surgical ligation of the perforated vessel seems to be an appropriate approach. Pericardiocentesis may be life-saving in case of tamponade, characterized by rapid hemodynamic deterioration.

Keywords: Coronary perforation, Ellis type perforations, surgical closure

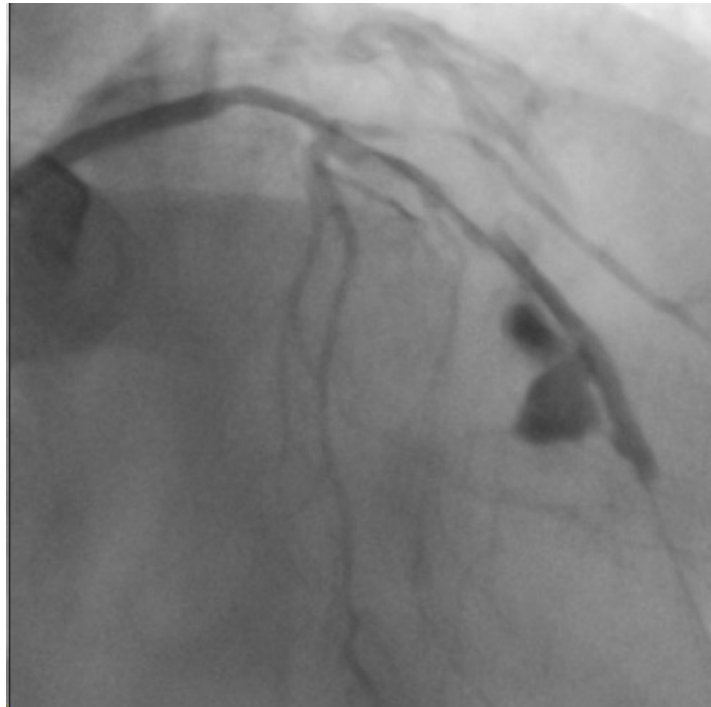


Fig. 1. Ellis type 3 perforation observed after balloon inflation in the true lumen.

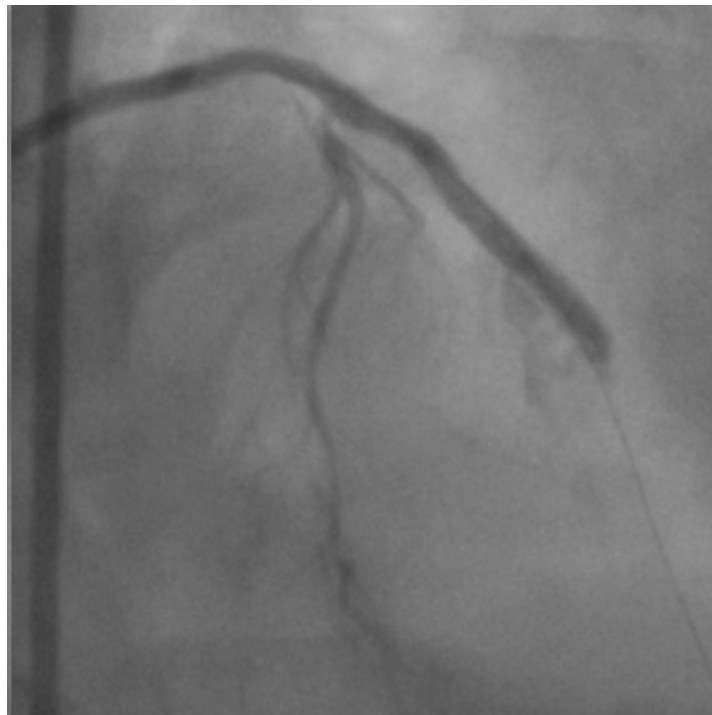


Fig. 2. Thrombosed image of LAD after protamine and balloon inflation.

OP-21.

[Experience with Percutaneous Catheter-Based Closure of Ventricular Septal Rupture Developing After Myocardial Infarction and Difficulties Encountered During The Procedure; Sharing Clinical Experience with 2 Cases]

Miyokart İnfarktüsü Sonrası Gelişen Ventriküler Septal Rüptürün Perkütan Kateter Temelli Kapatma Deneyimi ve İşlem Sırasında Yaşanan Güçlükler; 2 Vaka ile Klinik Tecrübe Paylaşımı

Hilal Erken¹, Saadet Demirtaş İnci¹, Gürkan İş¹, Muhammed Erzurum², Sadık Açikel³, İbrahim Hakan Güllü¹

¹Etilik Şehir Hastanesi, Kardiyoloji Kliniği, Ankara, Türkiye; ²Yunus Emre Devlet Hastanesi, Kardiyoloji Kliniği, Eskişehir, Türkiye; ³Yenimahalle Eğitim ve Araştırma Hastanesi, Kardiyoloji Kliniği, Ankara, Türkiye

Giriş: Müsküler ventriküler septal rüptür (VSR) miyokart infarktüsü (Mİ)'nin ciddi ve hayatı tehdit eden önemli bir komplikasyonudur. Mİ sonrası oranı %0.2'dir. VSR Mİ sonrası ilk 24 saatte nadir olup, genellikle ilk bir hafta içerisinde görülür. Tedavinin gecikmesi durumunda, genellikle biventriküler yetersizlik ve hayatı tehdit eden ciddi komplikasyonlar (böbrek yetersizliği, enfeksiyon vs.) gelişir. Günümüzde önerilen tedavi, cerrahi kapatmadır. Bir diğer tedavi seçeneği ise kateter yoluyla kapatma yöntemidir. Biz kliniğimizde perkütan yolla kapatma işlemi denediğimiz iki post MI VSR olgusunu paylaşmak istedik.

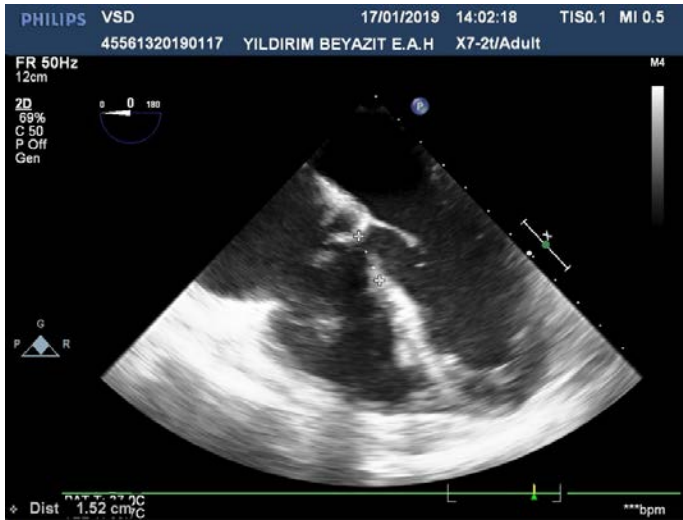
Vaka 1: Altmış yedi yaşındaki kadın hasta, Akut inferior Mİ tanısıyla dış merkezde RCA da saptanan %100 tromboze lezyona primer PTCA sonrası takiplerinde VSR gelişmesi üzerine hastanemiz Kalp Damar Cerrahi kliniğine operasyon amaçlı kabul edilmiş. Tarafımızca yapılan konsültasyonda genel durumu orta, vitalleri stabil seyretmekteydi, transtorasik ekokardiyografi (TTE)'de sağ boşluklar geniş, SPAB: 55 MMHG, orta TY, 1.2 cm çapında VSR (Şekil 1) ile uyumlu görünüm ve renkli doppler ile sol ventrikülden sağ ventriküle geçiş izlendi. Kalp damar cerrahisi tarafından takibinde 3. gün ani gelişen hipotansiyon, taşikardi ve genel durum bozukluğu olan hastaya yapılan TTE'de önceki ile benzer bulgular izlendi. Hasta Kalp damar cerrahisi konseyi tarafından değerlendirildi ve klinik açıdan operasyonun çok yüksek riskli olduğu düşünülerek inoperabl kabul edildi. Perkütan yolla VSR kapatma açısından tarafımıza yönlendirildi. TEE de 1.8 cm ölçülen VSR ye 18 mm amplatzer cihazı yerleştirilmesi planlandı. (Şekil 2) Tekrarlayan denemeler esnasında defekt çapı artarak 25 mm'ye ilerledi. (Şekil 3) Cihaz yerleştirilmesi işlemi başarısız oldu. Sheat ilerletilirken triküspit papiller kas rüptürü de tabloya eklendi. Hastada işlem sırasında AV tam blok ardından kardiyopulmoner arrest gelişti (Şekil 4). Etkin CPR'a yanıt vermeyen hasta exitus kabul edildi.

Vaka 2: Elli altı yaşında kadın hasta, subakut anterior Mİ tanısıyla LAD %100 lezyonu açılan TIMI 2 akım sağlanan hastanın 3.gününde üfürüm saptanması nedeniyle yapılan EKO'da IVS apikalinde 12 mm VSR

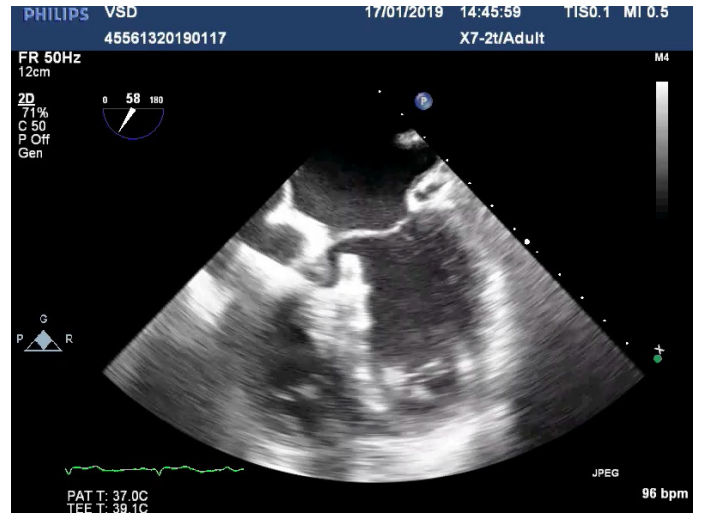
saptandı (Şekil 5, 6), yapılan konseyde cerrahi çok yüksek riskli olduğu için perkütan kapatma kararı alındı, işlem sırasında, septum frajilitesi nedeniyle daha flexible olduğu için VSD değil ASD kapatma cihazı kullanıldı (Şekil 7, 8), işlemden 6 saat sonra hastada hemodinamik instabilite gelişti genel durumu kötüleşti, TTE’de cihazın septumdan ayrıldığı çok az bir kısmının septumu tuttuğu görüldü, cihaza müdahale edilemeden gelişen ani kardiyak arrest sonrası eksitus gelişti .

Tartışma: Mİ sonrası VSR’nin erken kapatılması, genelde kötü prognosisla ilişkilidir. Bunun nedeni, doku nekrozunun ve buna bağlı olarak da defektin büyümeye devam etmesidir. Bu nedenle VSR onarımının zamanlamasının hayati önemi vardır. Cerrahi onarımın doku iyileşmesi için beklenildiği olgularda vakamızdaki gibi istenmeyen kardiyak olaylar gelişebilmektedir. Bu nedenle cihaz temelli VSR kapatılması bir alternatif tedavi olmakla birlikte VSR kapatılmasının vakamızda olduğu gibi teknik anatomik ve cihaz temelli kısıtlılıklarının iyi bilinmesi gerekmektedir. Hemodinamik instabilite nedeniyle intraaortik balon pompası eşliğinde alınan hastalarımızın; Yüksek riskli bir klinik tabloda alınması, VSD cihazının defekte uygun olmaması sebebiyle tekrarlayan cihaz yerleştirme denemeleri sırasında defektin büyümesinin işlem başarısızlığı ve hastanın kaybedilmesinin sebepleri olduğu düşünüldü.

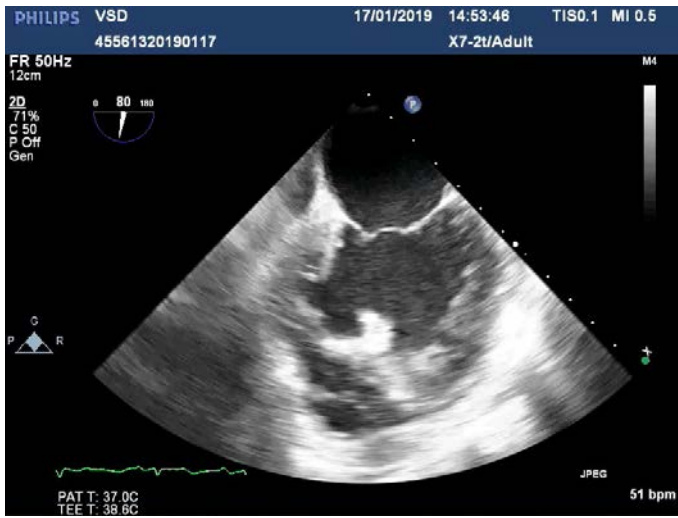
Anahtar Kelimeler: Miyokart infarktüsü, ventriküler septal rüptürü, perkütan kateter temelli kapatma, işlem güçlükleri



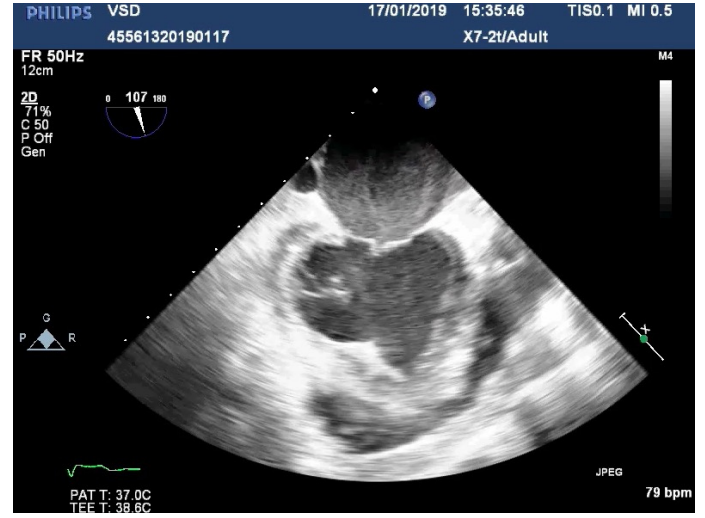
Şekil 1. Vaka 1, görüntü 1, preoperatif



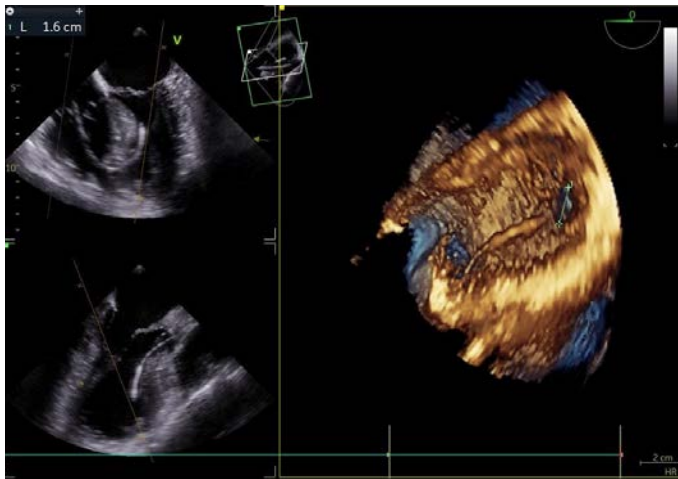
Şekil 2. Vaka 1, görüntü 2, cihaz implantasyon



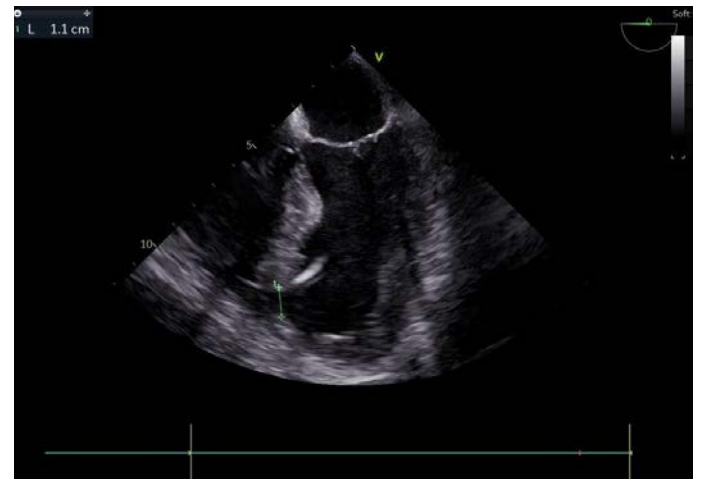Şekil 3. Vaka 1, görüntü 3, cihaz implantasyonu esnasında VSR büyümesi



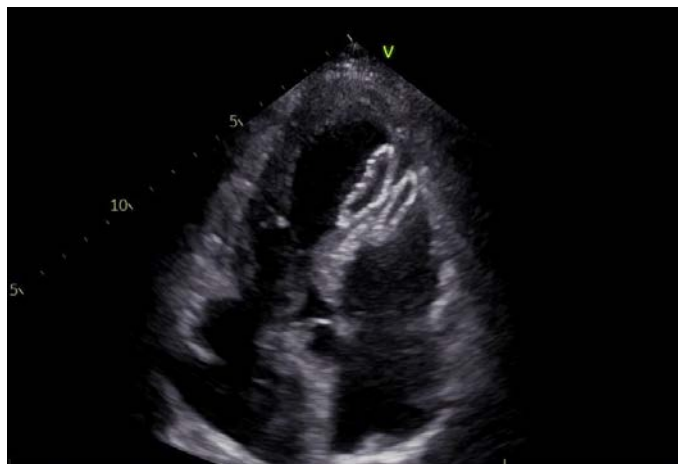Şekil 4. Vaka 1, görüntü 4, cihaz implantasyonu denemeleri sonrası oldukça genişlemiş VSR



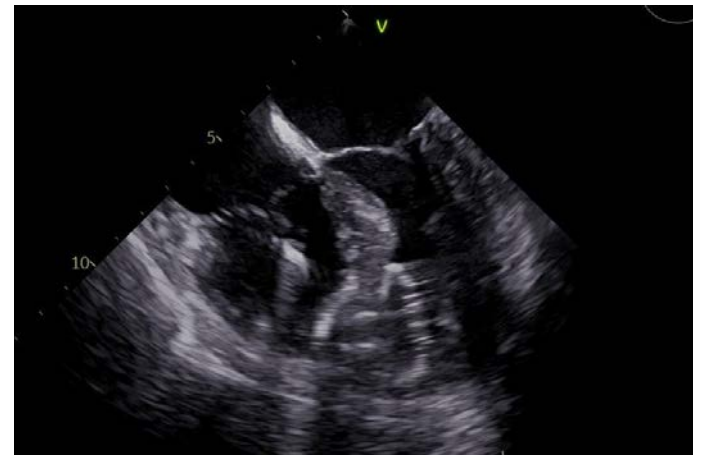Şekil 5. Vaka 2, görüntü 1, 3D Preoperatif



Şekil 6. Vaka 2, görüntü 2, VSR geçilmiş sheat ile



Şekil 7. Vaka 2, görüntü 3, VRS de ASD cihazı



Şekil 7. Vaka 2, görüntü 4, cihazlı postoperatif kontrol ekokardiyografi

OP-22.

Usability of Naples Prognostic Score Predicting Non-Dipper Pattern in Normotensive Patients

Tuba Unkun

Department of Cardiology, Koşuyolu Yüksek İhtisas Training and Research Hospital, İstanbul, Türkiye

Background: Non-dipper pattern (NDP) detected in 24-hour ambulatory blood pressure monitoring in hypertensive individuals is known to have adverse consequences associated with cardiovascular events. There are conflicting data that NDP poses a risk for future hypertension development in normotensive individuals. The Naples prognostic score (NPS) is a scoring system reflecting inflammatory and nutritional status and is calculated using neutrophil-to-lymphocyte ratio (NLR), lymphocyte-to-monocyte ratio (LMR), serum albumin and total cholesterol levels. NPS was first investigated as an indicator of poor prognosis in gastrointestinal system malignancies. Recent studies have shown that this score has predictive value in cardiovascular diseases and is associated with poor prognosis. Our aim in this study was to evaluate the relationship between the non-dipper pattern detected in ambulatory blood pressure monitoring and Naples score in normotensive individuals.

Methods: Sixty-three normotensive individuals were included in our study by retrospective screening method. Patients 24 hour ambulatory blood pressure monitoring was performed. NPS was calculated from biochemistry and hemogram examinations of the patients and the results were correlated between non-dipper and dipper groups.

Results: The mean age of the patients included in the study was 45.7 ± 10.9 . Twenty-eight female patients were included in the study. Non-dipper subjects were included in group 1 with 24 subjects, dipper subjects were included in group 2 with 39 subjects. No statistical difference was found between normotensive patients divided into two groups as non-dipper and dipper in terms of age, hemoglobin, neutrophil, total cholesterol, creatinine, EF (ejection fraction), E/e' (45.1 ± 10.7 , 47.3 ± 11.1 , $P=0.43$; 12.8 ± 2.2 , 12.2 ± 2.0 , $P=0.29$; 5.5 ± 1.7 , 5.7 ± 2.6 , $P=0.78$; 184.4 ± 82.7 , 212.0 ± 89.0 $P=0.22$; 0.89 ± 0.2 , 0.79 ± 0.1 $P=0.07$; 60.7 ± 3.1 , 60.5 ± 3.6 , $P=0.85$; 7.7 ± 2.4 , 6.9 ± 2.0 , $P=0.14$, respectively) others shown in Table 1. Naples prognostic score was higher in non-dipper group compared to dipper group (2.63 ± 0.8 vs 2.0 ± 1.0 , $P=0.014$).

Conclusion: In our study, we found that Naples prognostic score, which is known to be associated with cardiovascular events, was significantly higher in patients with non-dipper pattern compared to the other group.

Keywords: Non-dipper hypertension, monocyte-to-lymphocyte ratio, Naples prognostic score, neutrophil-to-lymphocyte ratio

Table 1. Demographic characteristics, laboratory and echocardiographic parameters of patients

Parameters	Grup 1 (non-dipper) n=24	Group 2 (dipper) n=39	P value
Age (years)	45.1±10.7	47.3±11.1	0.43
Hemoglobin (g/dL)	12.8±2.2	12.2±2.0	0.29
Neutrophil (cells/μL)	5.5±1.7	5.7±2.6	0.78
Lymphocyte (cells/μL)	1.9±0.8	2.0±0.8	0,69
Monocyte (cells/μL)	0.6±0.2	0.7±0.3	0,70
Serum albumin, (g/L)	4.0±0.2	4.1±0.3	0.17
Total cholesterol (mg/dL)	184.4±82.7	212.0±89. 0	0,22
Creatinine (mg/dL)	0.8±0.2	0.7±0.1	0.07
EF (teicholtz)	60.7±3.1	60.5±3.6	0.85
E/e'	7.7±2.4	6.9±2.0	0.14
Naples prognostic score	2.63 ±0.8	2.0 ±1.0	0.014

EF=ejection fraction,

OP-23.

[The Intruder in The Right Ventricle: Cardiac Cyst Hydatic]

Sağ Ventrikülde Davetsiz Misafir: Kardiyak Kist Hidatik

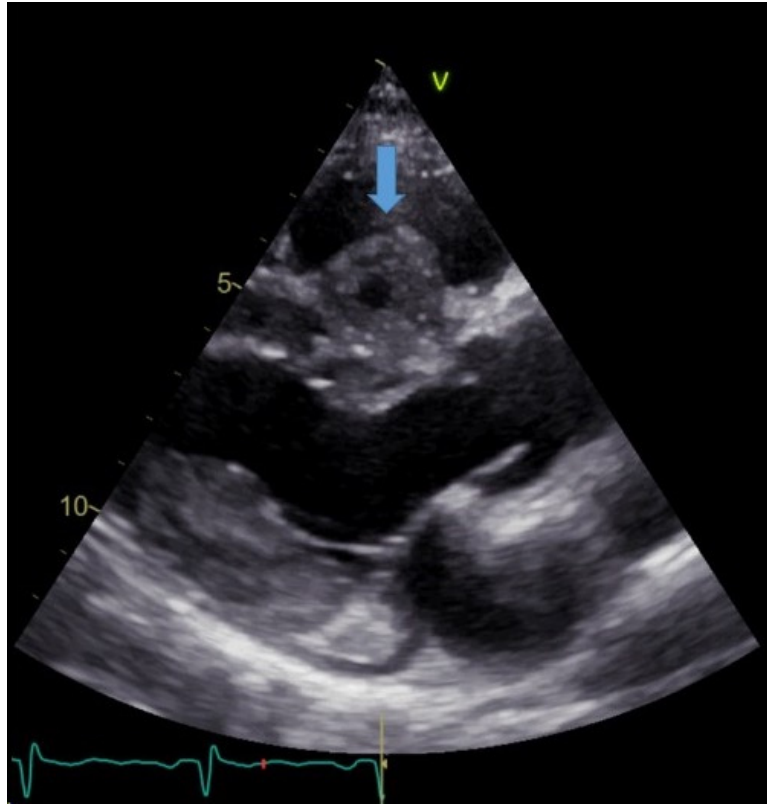
Harun Şenocak, Çetin Alak, Dilek Yeşilbursa, Bülent Özdemir

Bursa Uludağ Üniversitesi, Tıp Fakültesi, Kardiyoloji Anabilim Dalı, Bursa, Türkiye

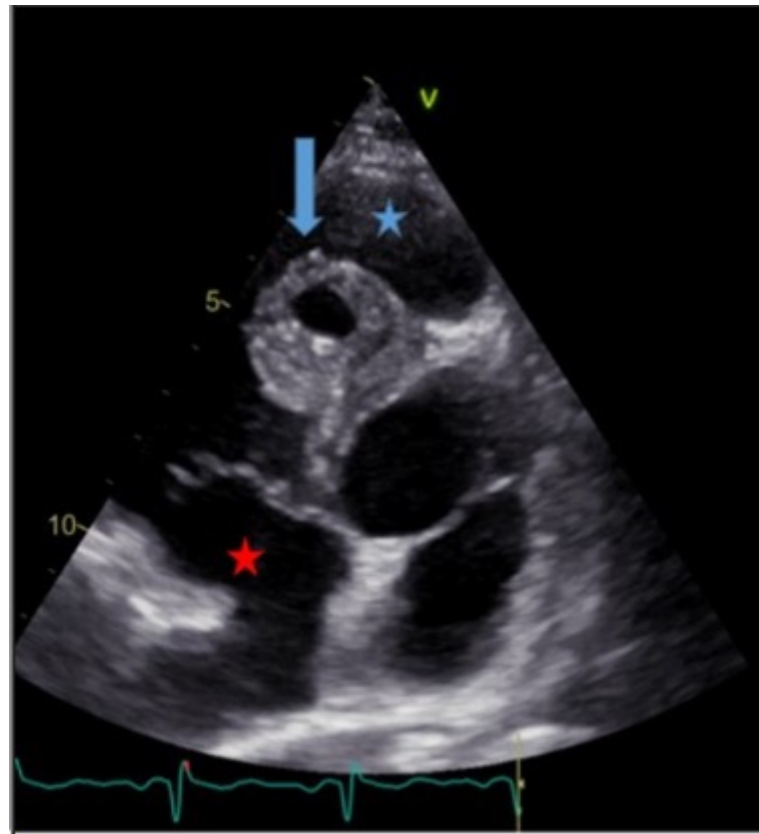Olgu Sunumu: Otuz dokuz yaşında erkek hasta, 2 yıldır ara ara nefes darlığı ile tarafımıza başvurdu. Hastanın bilinen pulmoner emboli (2019), pulmoner kist hidatik, Protein C ve S hastalıkları mevcuttu. Hasta 2 defa pulmoner hidatik (2012 ve 2017) nedeniyle opere edildi. Göğüs röntgeninde kardiyotorasik oranın artmış olduğu görüldü. Hastanın yapılan tetkiklerinde Ekinokok İndirekt Hemaglutinasyon değeri 1/40960 pozitif saptandı. Hastaya tarafımızca yapılan transtorasik ekokardiyografide (TTE) ejeksiyon fraksiyonu %60 minimal derece mitral yetersizlik (MY), minimal derece triküspit yetersizliği, interventriküler septuma tutunan 2.3×2.3cm boyutlarında kitle (kist hidatik?) izlendi (Şekil 1, 2 ve 3). Hastanın çekilen Toraks BT'sinde "Sol akciğer alt loba perilerde izlenen halı işareti sergileyen nodüler konsolide alanın kalın duvarlı kaviler lezyona doğru dönüşümü, hemen inferiorunda yeni gelişen yaklaşık 3.5 cm çapında yeni gelişen benzer natürde aktif olduğu düşünülen periferinde eşlik eden milimetrik modüler belirginleşmelerin olduğu görünüm dikkat çekmektedir. Pulmoner kist hidatiğin bronşa açılımı, İPA benzeri fırsatçı enfeksiyonlar düşünülebilir. İnterventriküler septum düzeyinden pulmoner artere doğru protüzyon gösteren yaklaşık 3.5 cm çapında hipodens kitle lezyonu izlenmektedir." olarak raporlandı (Şekil 4). Hastanın yapılan Abdominal Ultrasonografisinde "Dalak içerisinde 53×46mm boyutunda içeriği heterojen içerisinde ve periferinde kalsifiye odaklar barındıran kist ile uyumlu lezyon izlenmiştir." olarak raporlandı. Hastaya kardiyak MR çekilmesi planlandı fakat hastanın kabul etmemesi üzerine çekilmedi. Hasta Kalp Damar Cerrahisi ile birlikte konseyde değerlendirildi ve yüksek riskli operasyon kararı verildi. Hastanın operasyon olmak istememesi üzerine takip kararı alındı. Hasta albendazol tedavisi ile 6 ay sonra TTE ile değerlendirilmek üzere kontrole çağırıldı.

Tartışma: Echinococcus granulosus, genelde karaciğer ve akciğeri tutan kistlerle seyreden bir parazittir. Kardiyak kist hidatik %0.5-2 arasında görülen oldukça nadir bir hastalıktır. Kardiyak kist hidatik genelde asemptomatik seyretmesine rağmen özellikle rüptüre olması ile birlikte ölümcül komplikasyonlara neden olabilir. Hastaların dispne, göğüs ağrısı, çarpıntı, senkop gibi semptomlarla başvurduğu ve bu semptomların altında yatan sebebin ise kardiyak kist hidatiğe bağlı perikardiyal efüzyon, AV blok, supraventriküler taşikardi, enfektif endokardit, pulmoner hipertansiyon, anaflaksi, ani ölümün görüldüğü vakalar bildirilmiştir. Günümüzde kardiyak görüntüleme yöntemlerinin artması ile birlikte erken teşhis kolaylaşmıştır. Kardiyak kist hidatik tedavisinde ise genelde cerrahi tedavi ön plana çıkmakla birlikte bu hasta grubunda albendazol gibi anti-paraziter ilaç kullanılmalı ve TTE ile belli aralıklarla takip edilmelidir. Bizim hastamızda sağ ventrikül çıkış yolunda kitle imajı görüntüsünün hastanın geçmiş öyküleri ve multimodalite görüntülemelerinde kist Hidatik ile uyumlu olduğu düşünüldü. Hastaya ani ölüm ve diğer riskleri önlemek açısından cerrahi operasyon önerilse de hasta kabul etmediği için ekokardiyografi ile takip edilmektedir.

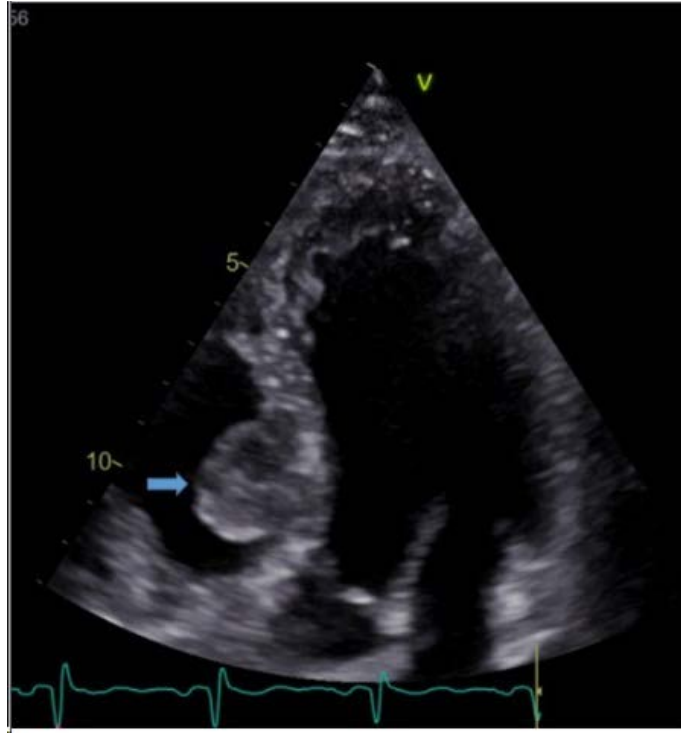
Anahtar Kelimeler: Kardiyak kist hidatik, sağ ventrikül, tedavi, cerrahi, takip



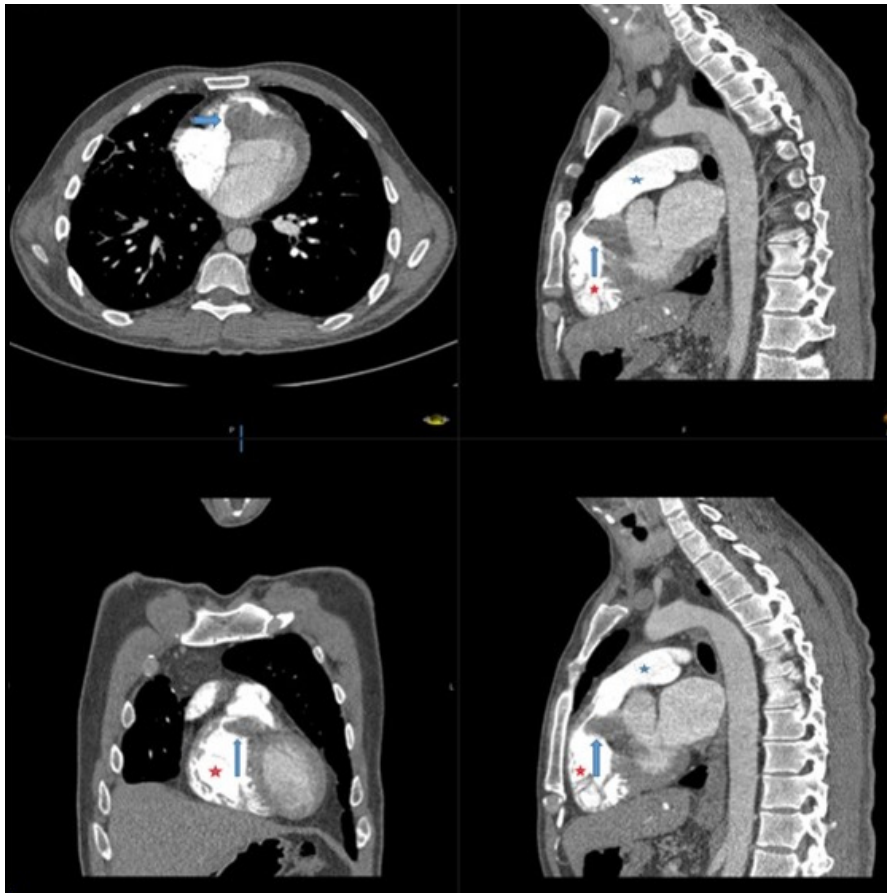
Şekil 1. Parasternal uzun eksen. Mavi ok: Kardiyak kist hidatik



Şekil 2. Parasternal kısa eksen. Mavi ok: Kardiyak kist hidatik, Mavi yıldız: Sağ ventrikül çıkış yolu, Kırmızı yıldız: Sağ atriyum



Şekil 3. Apikal 5 boşluk. Mavi ok: Kardiyak kist hidatik



Şekil 4. Sağ ventrikül çıkış yolunda yer alan kardiyak kist hidatik BT görüntüsü. Mavi ok: Kardiyak kist hidatik, Kırmızı yıldız: Sağ ventrikül, Mavi yıldız: Pulmoner arter

OP-24.

Challenging Rotablator Case Accompanied By IVUS

Zeynep Pelin Orhan, Atila Bitigen, Kudret Keskin

Department of Cardiology, Şişli Hamidiye Etfal Training and Research Hospital, İstanbul, Türkiye

Introduction: The presence of severe coronary calcification in complex PCI cases increases MACE rates. Atherectomy modifies the calcific plaques and allows for more appropriate stent placement.

Case Presentation: An 81-year-old male patient with known DM, CHF was admitted to the emergency room with back pain for 4 days. ECG showed ST elevation in anterior leads on a Q background and was admitted to the cath lab with a diagnosis of subacute STEMI. Angiography showed dissected plaque in the highly calcified LAD ostial, 50-60% stenosis in the proximal, 95% stenosis in the mid-segment, and 90% stenosis before the apex. Cx-OM with diffuse 70% stenosis proximally. RCA 80-90% stenosis in the mid segment. The decision was left to the heart team. Echocardiography revealed an EF of 35%, segmental wall motion defect (apicoseptal akinetic), mild Mitral Regurgitation CABG was decided in the council and the patient was transferred to Cardiovascular Surgery. However, the patient then signed a refusal of treatment form. 4 days later, the patient was admitted to the emergency department with a recurrence of chest pain and was interned to the hospital. In the catheterization laboratory the calcific lesion in the RCA was predilated with 1.25×10 mm, 2.0×0.8 mm, 2.25×0.8 mm, NC balloons. A 2.75×23 mm DES was implanted distal to the RCA. When a lesion was observed proximal to the stent, a 3.0×32 mm DES was implanted after pre-dilatation with 2.5×10 mm. Postdilations were performed with a 3.25×15 mm balloon to the overlap area. After successful RCA PCI, it was decided to perform an elective procedure under IVUS guidance due to the LAD lesion was very calcific. After 2 weeks, IVUS imaging of the LAD showed 360-degree advanced calcification, and a decision was made to treat the lesion in the LAD with a rotablator. LAD MLA was calculated as 2.5 mm² by IVUS. The lesion area was predilated with a 2.0×12 mm balloon. With the help of a microcatheter, the lesion area in the LAD was opened with a 1.5 mm burr rotablator. After the rotablator, no-reflow in the LAD was detected in control images. Thereupon, intracoronary aggrastat, adenosine, diltiazem and nitrate were administered to the patient until flow was restored. After flow was restored in the LAD territory, 2.75×38 mm DES and 3.0×33 mm DES were implanted. Postdilatation was then performed with a 3.5×16 mm NC balloon. The procedure was terminated in the patient with TIMI-2 flow in control images. A decrease in troponin levels was observed in the follow-up. The discharge prescription was adjusted for optimal medical treatment. (Figs. 1-5)

Conclusion: Atherectomy is one of the most effective devices in complex atherosclerotic lesions or restenosis, especially in ostial lesions. Complications such as arrhythmia, dissection, rupture, distal embolization, slow flow, no-reflow, tamponade, MI are seen during the procedure. No-reflow is one of the most common complications and the experience of the operator is important.

Keywords: Severe coronary calcification, IVUS, atherectomy, rotablator,

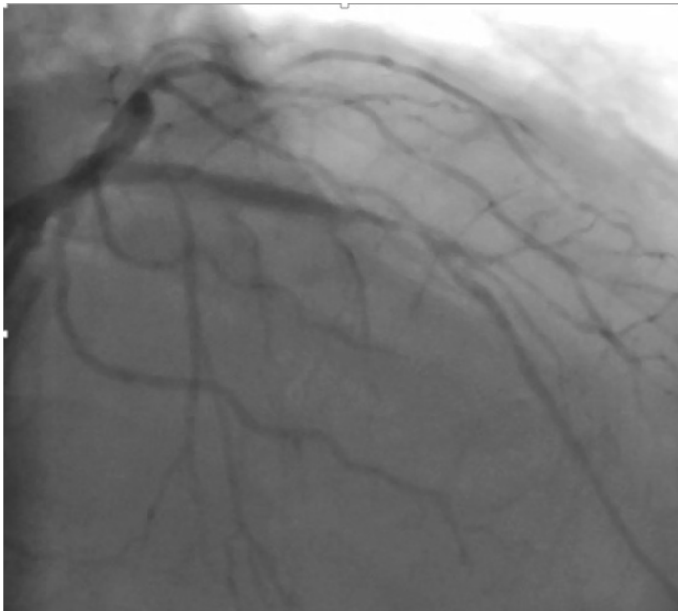


Fig. 1. The angiography image of the patient at the time of admission showed long, widespread and calcific lesions in the LAD.

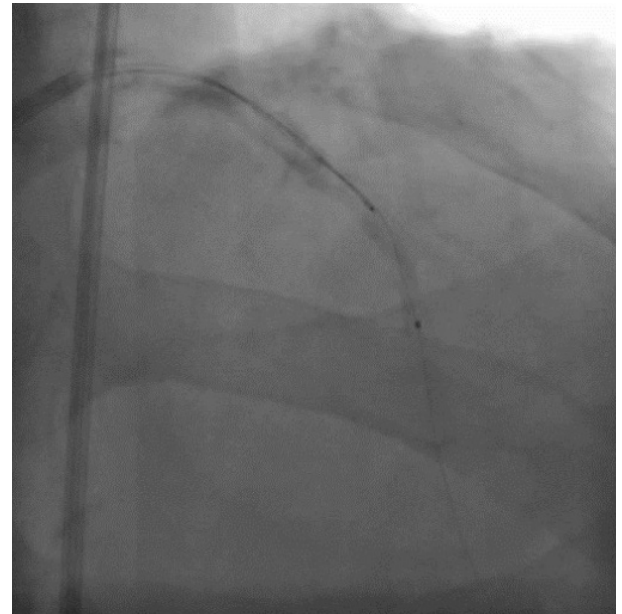


Fig. 2. LAD was predilated with a 2.0x12 mm balloon, and then the lesion areas were evaluated with IVUS.

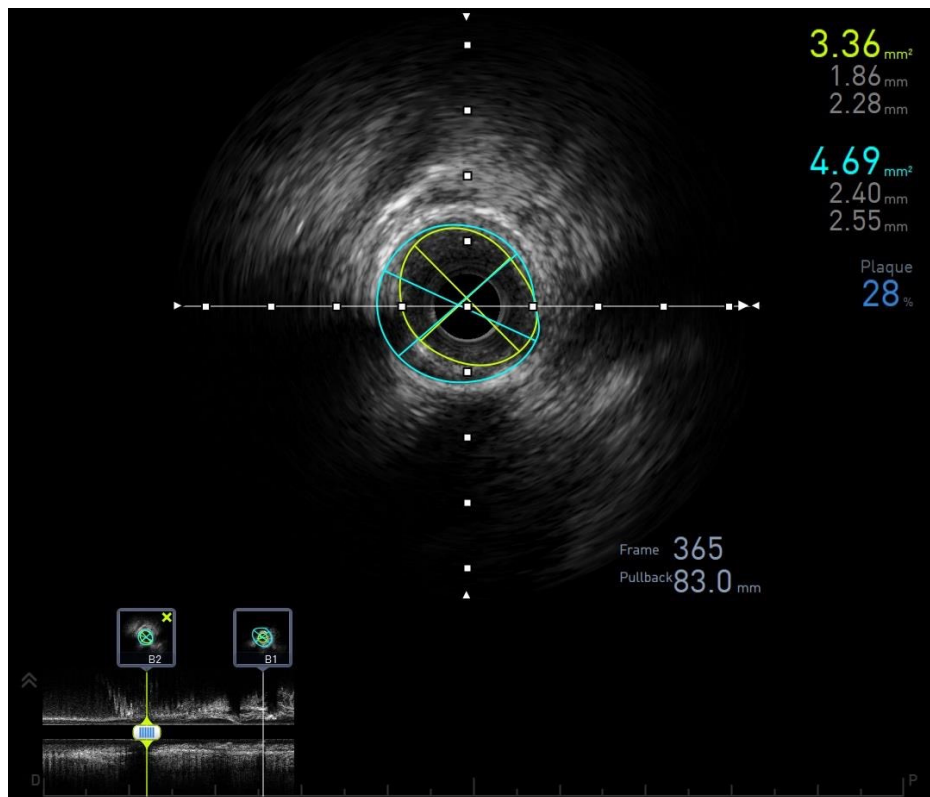


Fig. 3. IVUS image of the LAD lesion. LAD area was seen as 4.69 mm².

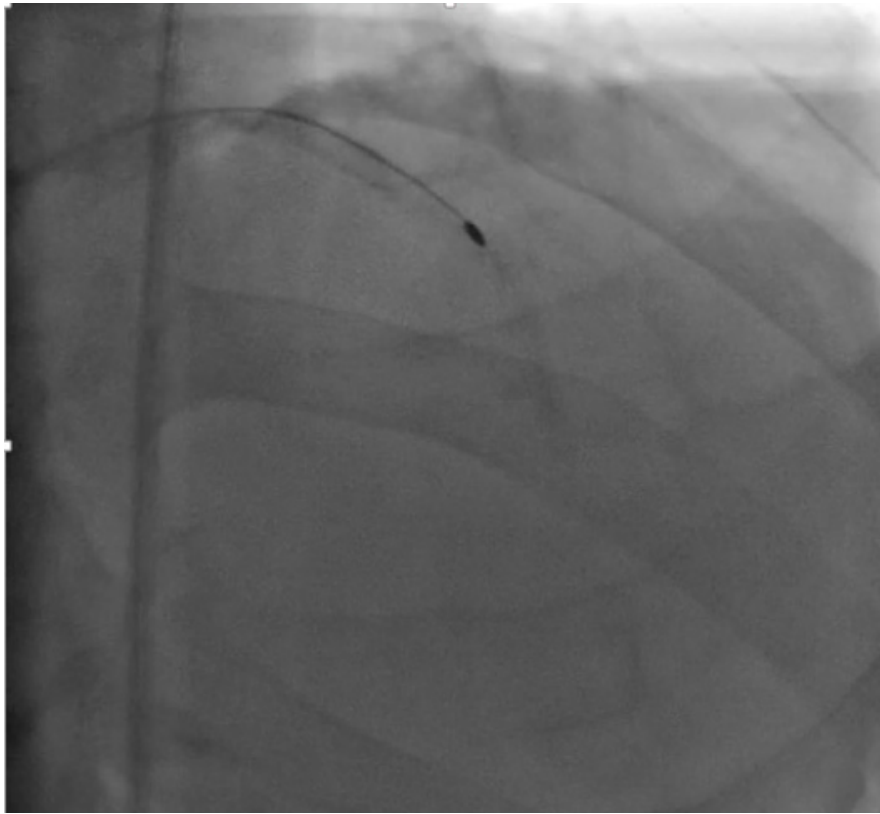


Fig. 4. Atherectomy was performed with a rotablator for calcific lesions in the LAD.

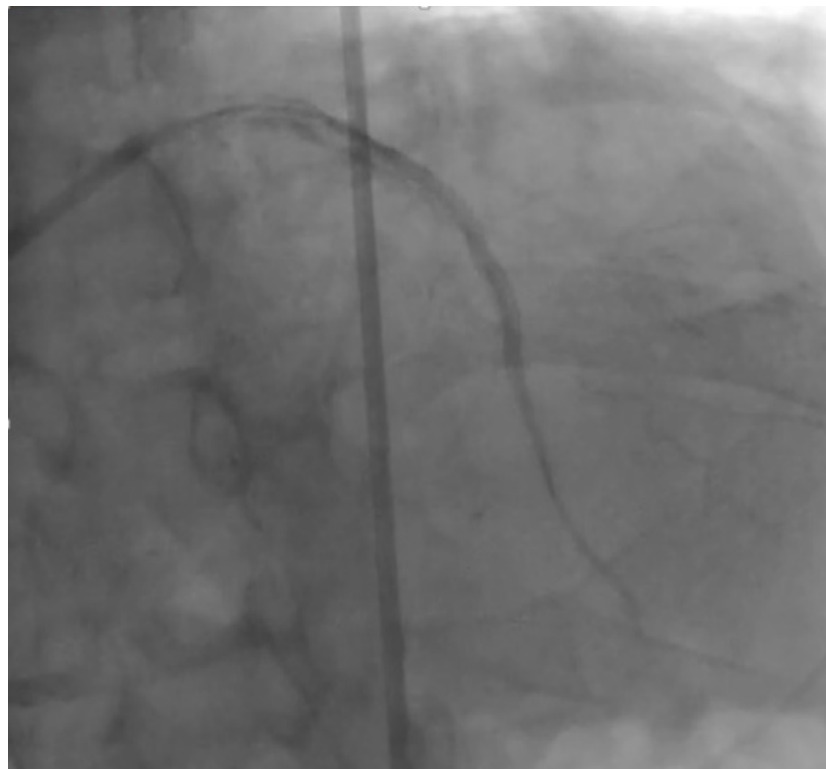

Fig. 5. Distal flow control was performed with a microcatheter. It was observed that TIMI was 0-1 current.

OP-25.

[ICD or No ICD? That is the Question!]

ICD İmplant Etsem mi Etmesem mi? İşte Bütün Mesele Bu!

Selin Abdu, Çetin Alak, Nazmiye Sümeyye Güllülü

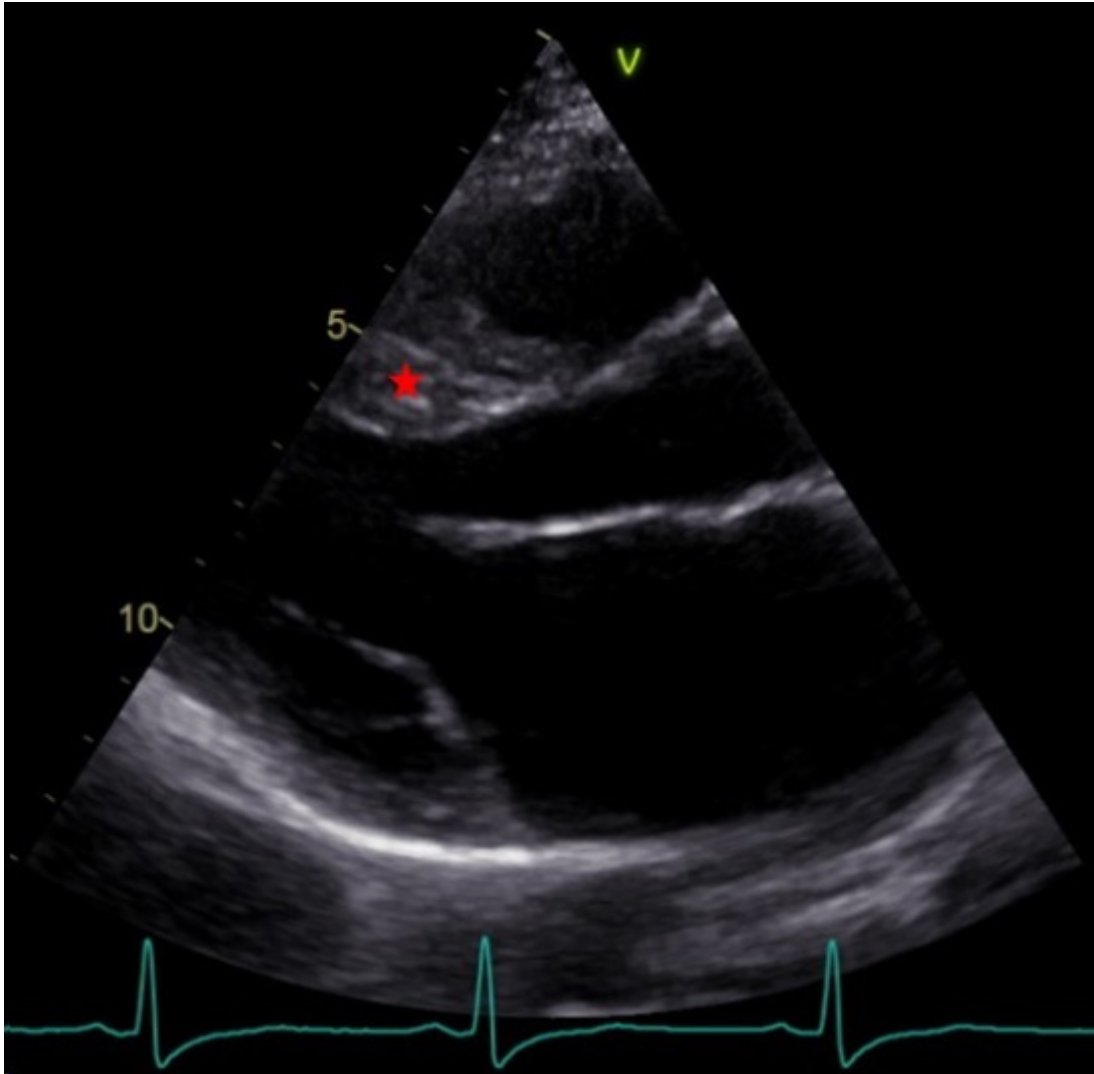
Bursa Uludağ Üniversitesi, Tıp Fakültesi, Kardiyoloji Anabilim Dalı, Bursa, Türkiye

Olgu Sunumu: Kırk dört yaşında kadın hasta çarpıntı şikayeti ile başvurdu. Daha önce göğüs ağrısı ve çarpıntı nedeni ile koroner anjiyografi (KAG) yapıldığı ve koroner damarlarında darlık saptanmadığını belirtti. Aile öyküsü sorgulandığında ise; ablası yirmi üç yaşında aniden vefat etmiş, annesi kırk yedi yaşında vefat etmiş ve kuzenlerde erken yaşta ölümler mevcut olduğu öğrenildi. Elektrokardiyogramında kalp hızı 78/dak sinüs ritmi, sol ventrikül hipertrofi bulguları saptandı. Ön tanı hipertrofik kardiyomyopati den düşünülerek ekokardiyografi, kardiyak manyetik rezonans (KMR) görüntüleme ve ritm holder planlandı (Şekil 1-7). Yapılan transtorasik ekokardiyografisinde (TTE) enjeksiyon fraksiyonu (EF) %58 saptandı. Sol ventrikül konsantrik hipertrofik izlendi. 1-2 derece mitral yetersizlik, 1-2 derece triküspit yetersizlik izlendi ve pulmoner arter basıncı 40 mmHg saptandı. İnferoapikal septumda anevrizma olduğu saptandı. Ritm holterde ventriküler taşikardi saptanmadı. Bunun üzerine KMR ve Genetik tetkik istendi. KMR'de septumda asimetrik kalınlaşma görülmektedir. Septum en kalın yerinde 2.1 cm'ye ulaşmaktadır. Apikal inferior duvarda fokal kalınlaşma izlenmektedir. Bu seviyelerde transmurale yakın geç kontrastlanma görülmektedir. Apekte de fokal incelmeye anevrizmatik görünüm gözlenmiştir. Miyokardın T1 ve T2 zamanları uzamıştır. İnterstisyel fibroze bağlı olabileceği düşünüldü. Genetik test sonucunda MYL3 geninde c.445A>G (p. Met149Val) Heterozigot muhtemel patojenik varyant (NM_000258.2) saptandı. Hastanın anginal yakınması olması nedeni ile KAG planlandı. Koronerler doğal izlendi. Sol ventrikül inferoapikal anevrizma izlendi. Hastaya sarkomerik gen mutasyonuna bağlı hipertrofik kardiyomyopati (HKMP) tanısı konularak intrakardiyak defibrillatör (ICD) implantasyonu açısından kalp takımı ile değerlendirildi. Bu hasta ve birçok HKMP hastasında ICD kararı vermek zorlayıcı olabilmektedir. Bu hastada Avrupa Kardiyoloji kılavuzunun önerdiği risk skorlaması yapıldığında yıllık risk %3.65 saptanmıştır ve düşük risk grubuna girmektedir. Düşük risk grubunda bir risk faktörü mevcutsa (EF<%50 veya KMR'de %15 üzeri geç gadolinyum tutulumu varlığı) Class 2b ile implantasyon önermektedir. Amerika Kılavuzlarında ise risk faktörü bazlı yaklaşım mevcut olup hastanın aile öyküsü varlığı (bizim hastamızda olduğu gibi), apikal anevrizma varlığı (ESC risk skorunda hesaplanarak) durumunda Class 2a ile implantasyon önerilmektedir. Görüldüğü gibi kılavuzlarda da bu hasta grubunda Class 1 bir öneri mevcut olmayıp hasta bazlı karar vermek gerekmektedir. Biz hastamıza ciddi aile öyküsü olması nedeni ile ICD implantasyonu planlandık. Bizim hastamız iki kılavuz arasında kalan ICD implantasyonu açısından karar vermenin zor olduğu gerçek dünya verisi olması nedeni ile paylaşmak istedik.

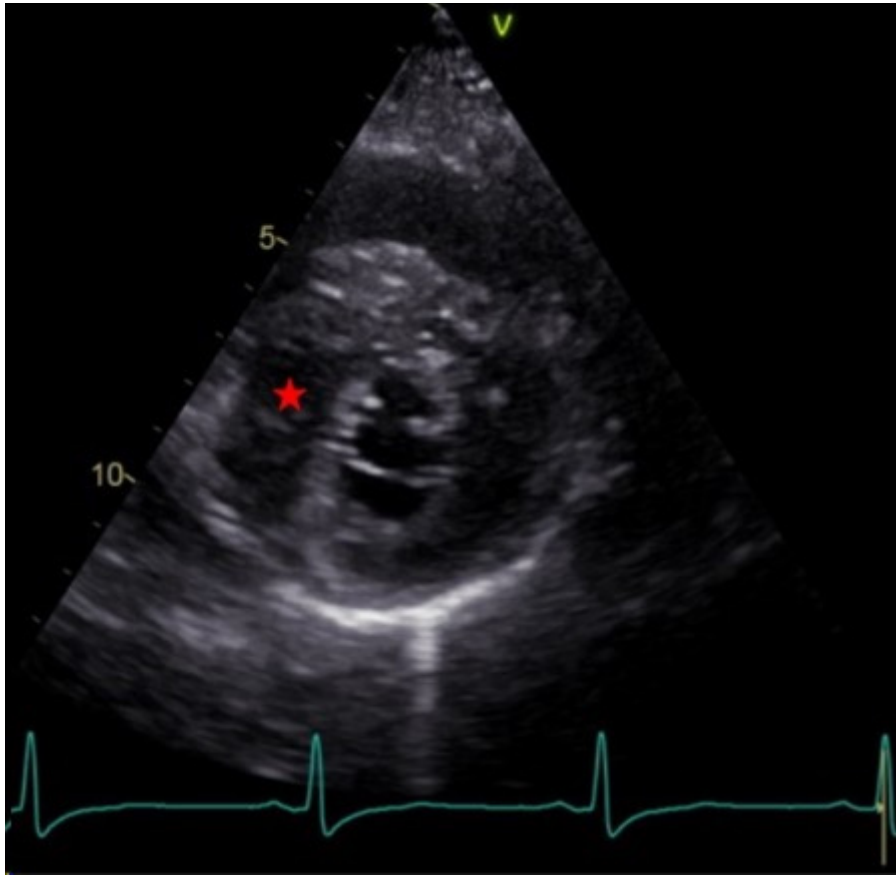
Sonuç: Hipertrofik kardiyomyopati ilk semptomu ani ölüm olabilen katastrofik bir hastalıktır ve erken tanı koyduğumuz hastalarda en önemli nokta ani ölümün önlenmesidir. Ancak ani ölüm gelişebilecek hastayı saptamak ve ICD implant etmek gerçek hayatta mevcut kılavuzlar ışığında zorlayıcı olabilmektedir. Hastalara risk faktörü bazlı yaklaşım ile mi yoksa risk skorları bazlı yaklaşımla mı ICD kararı verileceği hala tartışmalı bir konudur. Hastada risk faktörlerinin dışında genetik mutasyon ve apikal anevrizma varlığının ICD kararında

yeri olup olmadığı da tartışma konusu olmaya devam etmektedir. Amerika kılavuzlarında apical anevrizma varlığı ani ölüm açısından risk faktörü olarak belirlenmiş ve saptanan hastalara Class 2a ile implantasyon önerilmektedir. Fakat Avrupa Kılavuzlarında sadece apical anevrizma varlığına göre ICD kararı verilmemesi gerektiği belirtilmiştir. Yine aynı şekilde aile öyküsü varlığı Amerika kılavuzlarında risk faktörü olarak kabul edilerek ICD implantasyonu önerilirken, Avrupa kılavuzlarında risk skoru hesabının bir parçası olup tek başına varlığı endikasyon koydurmaz. Biz hastamızı iki ayrı kıta kılavuzları arasında kalan gerçek bir olgu olması nedeni ile paylaşmak istedik.

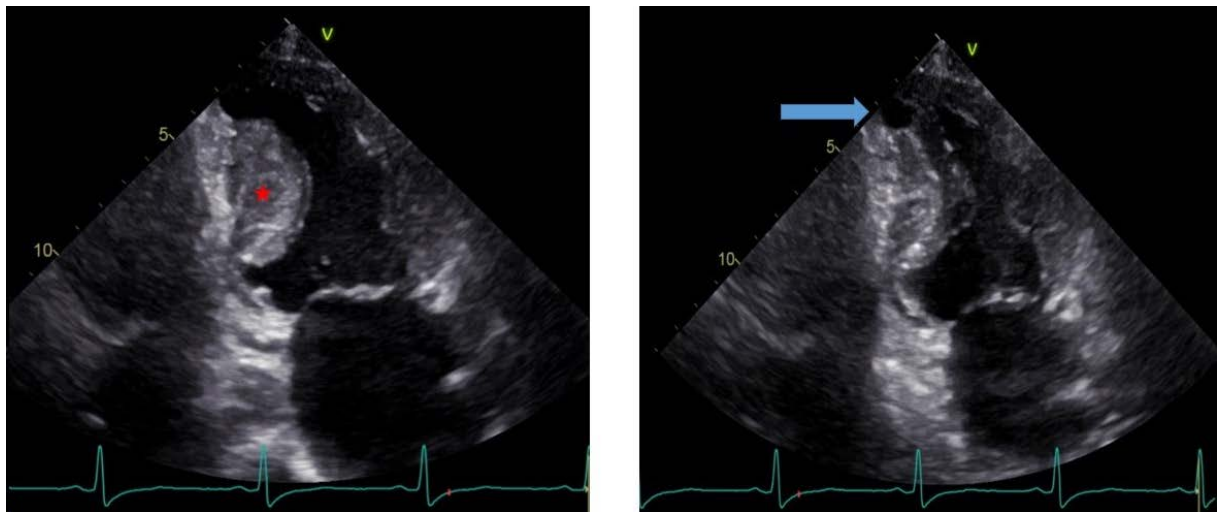
Anahtar Kelimeler: Hipertrofik kardiyomiyopati, ICD, kardiyak manyetik rezonans, kılavuzlar



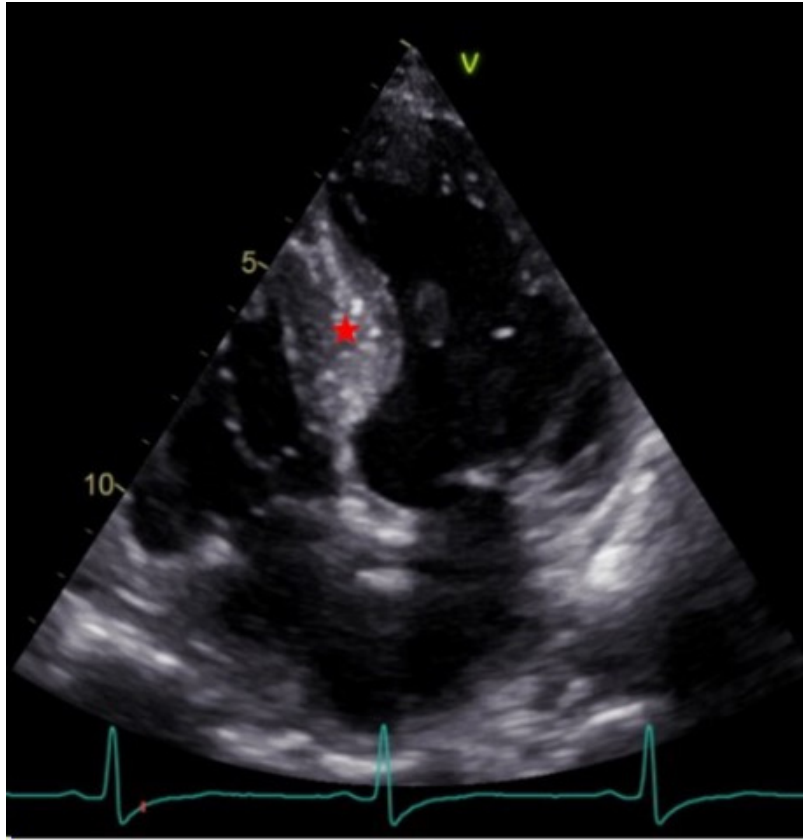
Şekil 1. Parasternal uzun aks. Kırmızı yıldız: Septal hipertrofi



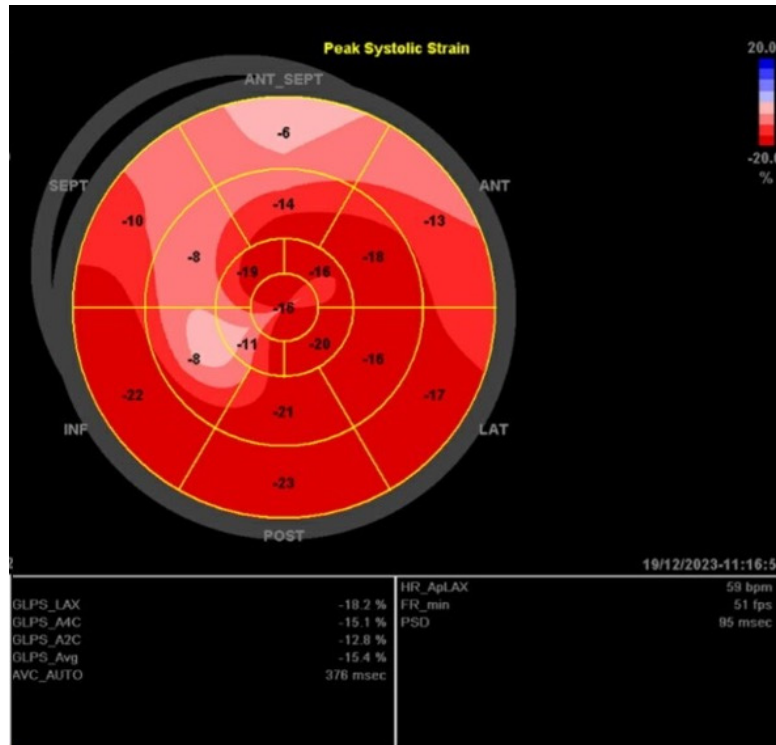
Şekil 2. Parasternal kısa aks. Kırmızı yıldız: Septal hipertrofi



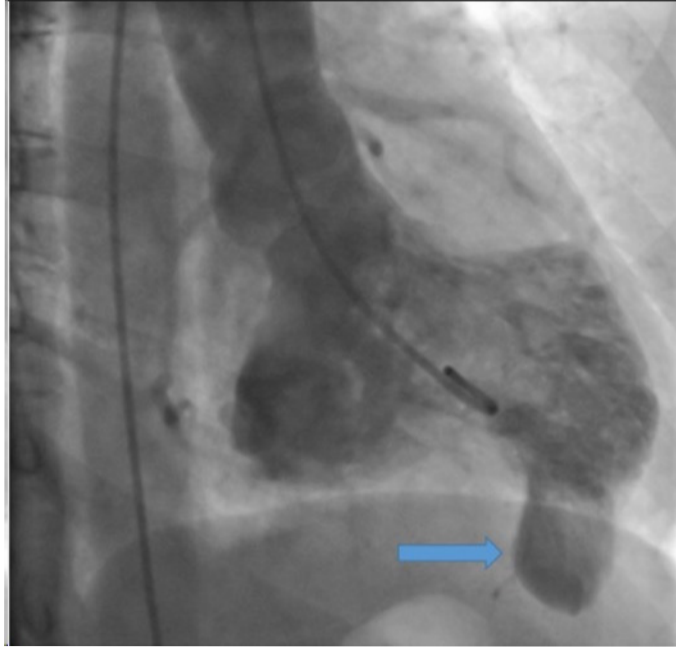Şekil 3. (a) İki Boşluk görüntü, Kırmızı yıldız: Septal hipertrofi; (b) İki boşluk görüntü, Mavi ok: İnféroapikal anevrizma



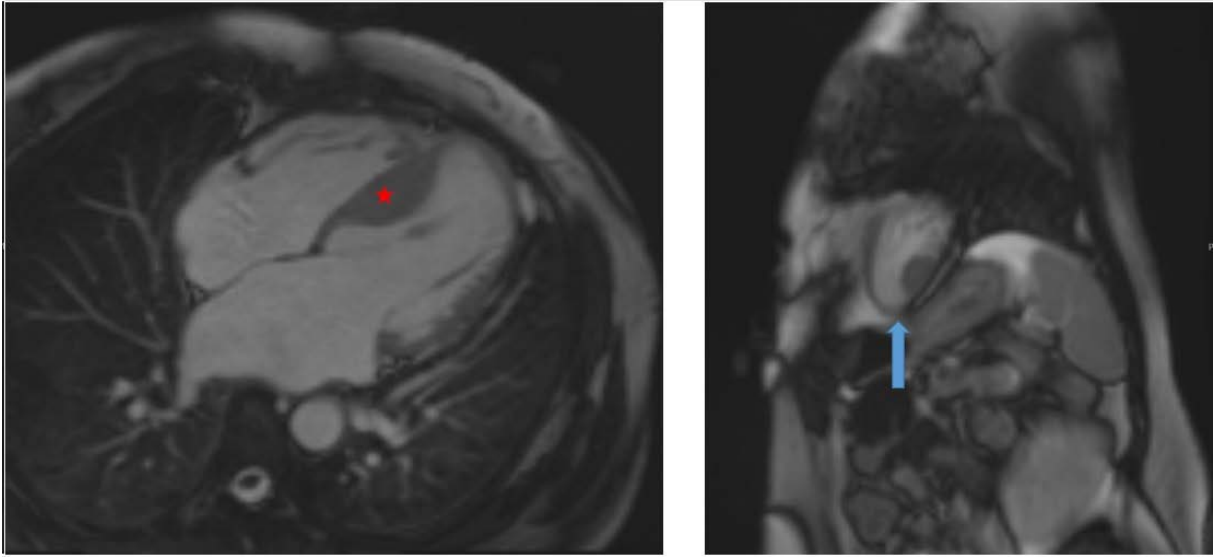
Şekil 4. Apikal dört boşluk görüntü. Kırmızı yıldız: Septal hipertrofi



Şekil 5. Strain görüntüleme. Anterior septumda strain belirgin azalmış



Şekil 6. Ventrikülografi. Mavi ok: İnféroapikal anevrizma



Şekil 7. (a) Kardiyak manyetik rezonans görüntüleme, Kırmızı yıldız: Septal hipertrofi; (b) Kardiyak manyetik rezonans görüntüleme, Mavi yıldız: İnféroapikal anevrizma

OP-26.

Electrical Storm of Malignant Ventricular Arrhythmia Confused with Epileptic Seizure

Ataç Çelik, Yağmur Demirezen

Department of Cardiology, Tokat Gaziosmanpaşa University, School of Medicine, Tokat, Türkiye

Introduction: Epileptic seizures and malignant ventricular tachycardia attacks, which are among the causes of syncope, are clinical events that can be confused during diagnosis and have serious consequences in cases where differential diagnosis is delayed. Although observing the patient during the seizure, neurological evaluation after the seizure, and electroencephalography often reveal the epileptic cause, sometimes the results may not be clear. In addition, the possibility of co-occurring syncope due to arrhythmia is possible in people with epileptic seizures, although it is rare.

Purpose: It is aimed to differentiate the newly developed and repeated cyanosis and convulsion seizures in a patient who has epileptic seizures due to a brain tumor and is being treated, from malignant ventricular arrhythmia storm due to the appearance of interference in the ECG monitoring during the seizure.

Method: A 34-year-old female patient, who had been receiving antiepileptic treatment with the diagnosis of epileptic seizure for approximately 4 years, applied to the emergency department with complaints of fainting repeatedly, bruising in the mouth and face area, and body convulsions. It was learned that the patient had been diagnosed with cavernoma in the frontal lobe of the brain 4 years ago and had been followed up. During her follow-up in the hospital, she developed a new seizure and his pulse could not be taken, so she was considered to be in cardiac arrest and was resuscitated. Although sinus rhythm was restored after defibrillation, she was intubated and admitted to intensive care because his hemodynamics were unstable. Cardiac evaluation was requested due to attacks requiring resuscitation-defibrillation during intensive care follow-up. During the seizure, interference was observed in the ECG monitoring due to spasms, and a clear diagnosis of cardiac arrhythmia could not be made.

Results: As a result of cardiac evaluation, invasive intraarterial pressure monitoring was performed for the differential diagnosis of malignant ventricular arrhythmia in order to avoid being affected by ECG interference occurring during the seizure. Ventricular fibrillation was diagnosed when a sudden decrease in the arterial pressure trace was observed during the seizure. Since the initial parenteral amiodarone and then lidocaine treatment could not suppress the electrical storm attacks, flecainide 200 mg/day and metoprolol 100 mg/day started via nasogastric tube. With this treatment, ventricular fibrillation attacks were stopped, then she was extubated and service follow-up started. The patient discharged after implanting an implantable cardioverter-defibrillator pacemaker.

Discussion: In case of newly developing syncope in a patient with a diagnosis of brain tumor and a history of receiving anti-epileptic seizure treatment due to epileptic seizures, the first diagnosis that comes to mind will be epilepsy. Unlike our patient, the absence of a pulse during the seizure and the slight return of the pulse after defibrillation raised the suspicion of syncope due to an arrhythmia of cardiac origin. Since seizures sometimes resolve spontaneously and the ECG during the seizure is not diagnostic due to interference caused by the convulsions, a definitive diagnosis cannot be made. In such a case, intra-arterial invasive blood pressure monitoring may help in making a definitive diagnosis.

Keywords: Malignant ventricular tachycardia, epileptic seizures, electrical storm attacks, diagnosis

OP-27.**Allergy Related Acute Coronary Syndrome: Kounis Syndrome**

Mustafa Kani Gözcü, Doğan Ormanlı, Ömer Faruk Kahraman, Mahmut Kapsız, Davut Davutoğlu, Abdulsamet Arslan, Mehmet Taşçı, Ayşe Dilara Balyımez, Muhammed Nusret Ak, Bilal Mete Ülker, Esra Akpınar, Ahmet Fatih Kışpınar, Haydar Selçuk Demiray, Hasan Arı, Tahsin Bozat

University of Health Sciences, Bursa Yüksek İhtisas Training and Research Hospital, Bursa, Türkiye

A 24-year-old male patient who had received corticosteroid treatment due to nasal polyps is presenting to an external center with epigastric pain occurring after meals for the past month. Following investigations at the external center, coronary angiography (CAG) is recommended due to elevated enzymes. Coronary angiography (CAG) reveals a 50% stenosis in the left anterior descending artery (LAD) (Fig. 1), and the patient is discharged with aspirin (ASA) and statin therapy. After ASA treatment, the patient had chest pain than he presented to our hospital's emergency department. Upon examination, elevated cardiac enzymes prompted admission to the intensive care unit for monitoring. Colchicine and ibuprofen were initiated for the patient suspected of myocarditis. Following ibuprofen usage, the patient experienced numbness and swelling of the tongue, accompanied by the recurrence of chest pain. The patient with EKG changes (Fig. 2) underwent CAG, revealing LMCA, LAD, Cx and RCA vasospasm (Fig. 3). The vasospasm was regressed (Fig. 4) and EKG normalized (Fig. 5) after nitrate administration. Echocardiography showed segmental wall motion abnormalities. The patients Troponin and CK MB value 3.000-50 Elevated eosinophils and IgE levels in the tests led to the diagnosis of Kounis syndrome. The patient treated with nitrates, calcium channel blockers, clopidogrel and statin. Kounis syndrome is defined as the simultaneous occurrence of acute coronary syndrome with allergy, hypersensitivity, anaphylaxis, or anaphylactoid conditions. Clinical symptoms range from subclinical reactions to various manifestations such as coronary spasm, acute thrombotic myocardial infarction, and involvement of cerebral, mesenteric, and coronary arteries. Three different variants of the syndrome are identified: Type I variant includes patients without atherosclerotic coronary artery disease, where coronary artery spasm develops secondary to the release of inflammatory mediators. Type II variant encompasses patients with existing atheromatous disease. Type III variant involves patients who present with stent thrombosis or restenosis after a severe allergic reaction, with a history of previous percutaneous coronary intervention. Useful measures for diagnosis include the measurement of serum histamine, tryptase, cardiac enzymes, and cardiac troponins. Elevated levels of IgE and eosinophils may also be observed. Echocardiography and coronary angiography are necessary for diagnosing heart wall abnormalities, including Takotsubo cardiomyopathy, and identifying coronary anatomy in Kounis syndrome cases. The diagnosis of Type I variant has been established with ischemia and subendocardial involvement using SPECT and dynamic cardiac MR. Treatment involves the administration of nitrates and calcium channel blockers. Antihistamines and corticosteroid therapy may also be given. Beta-blockers should be avoided due to their potential to increase alpha-adrenergic effects. Instead of adrenaline, which can exacerbate spasm, glucagon may be preferred.

Keywords: Kounis Syndrome, acute coronary syndrome, allergy

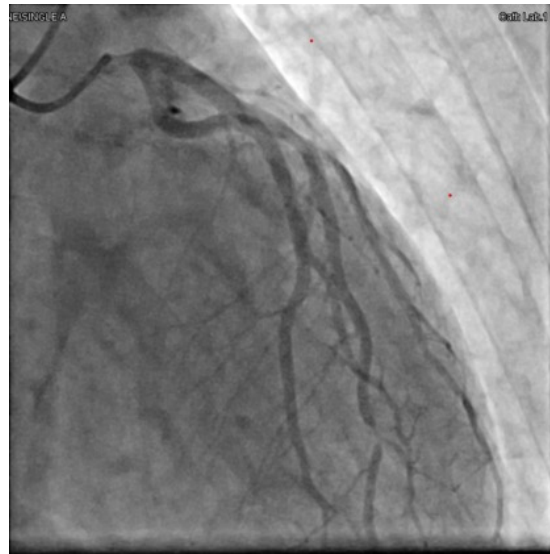

Fig. 1.

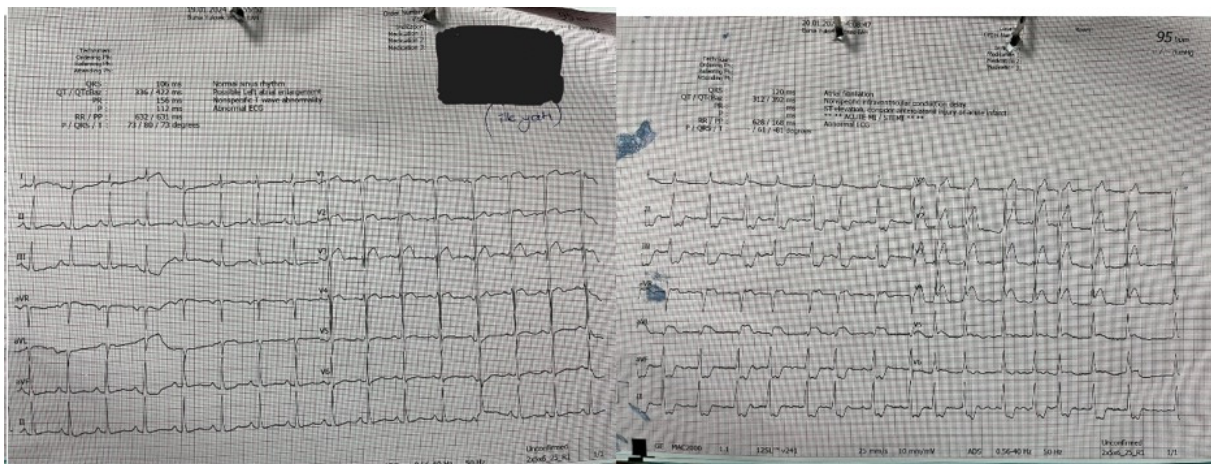


Fig. 2.

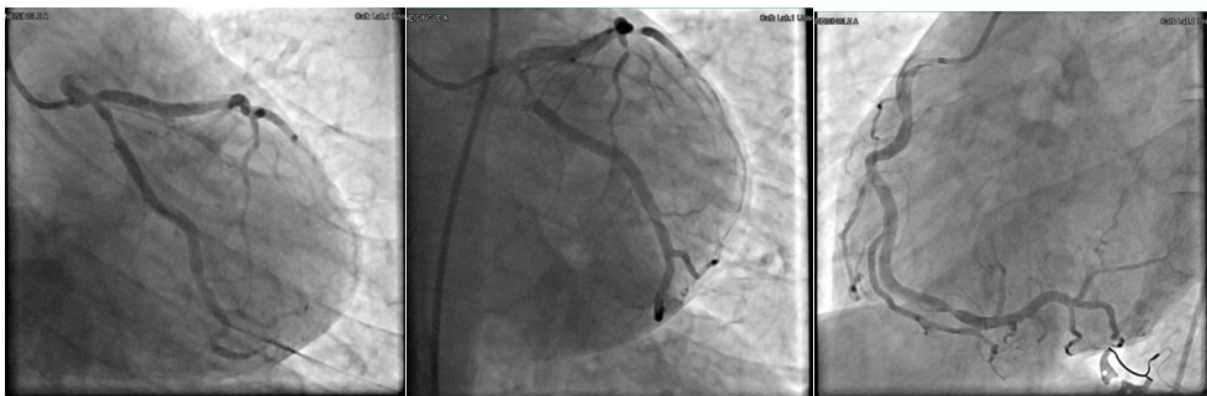

Fig. 3.

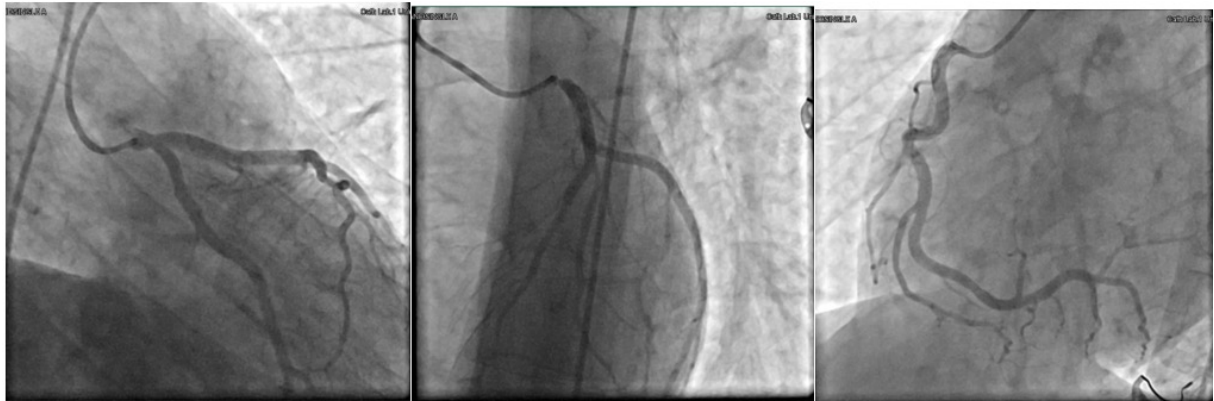

Fig. 4.

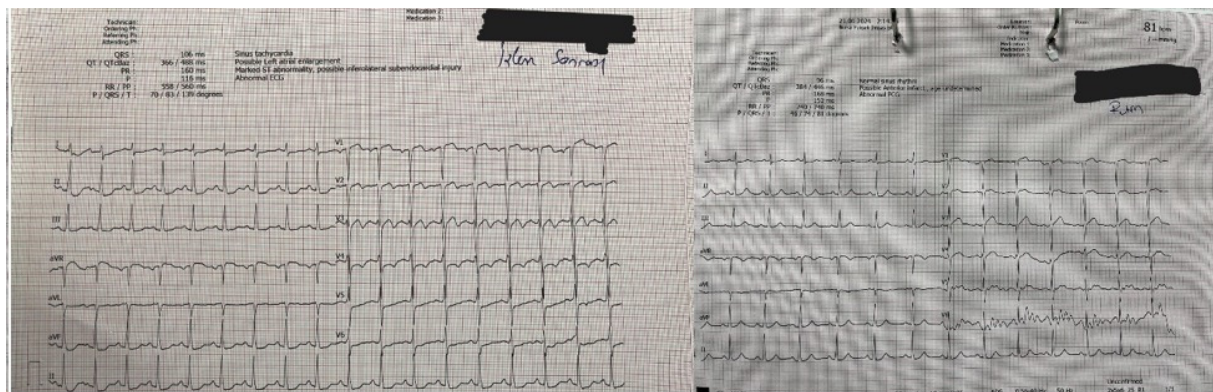


Fig. 5.

OP-28.**Relationship between the Development of No-Reflow Phenomenon and Lymphocyte/HDL Ratio in Acute Coronary Syndrome Patients****Ömer Faruk Kahraman, Ömer Furkan Demir, Doğan Ormanlı, Barış Şensoy***Department of Cardiology, University of Health Sciences, Bursa Yüksek İhtisas Training and Research Hospital, Bursa, Türkiye*

Introduction: Acute coronary syndrome is an important life-threatening condition and percutaneous coronary intervention (PCI) is at the forefront in its treatment. Although coronary revascularization is achieved during PCI, in some patients optimal results cannot be achieved due to the development of coronary no-reflow phenomenon (NRP). There is evidence in the literature that inflammatory biomarkers and the HDL molecule, which has anti-inflammatory properties, can be used to identify individuals at risk for developing NRP.

Aim: Our aim in this study is to investigate the effect of monocyte/HDL ratio (MHR) and Lymphocyte/HDL ratio (LHR) on the development of NRP in ACS patients.

Methods: Ninety-seven patients diagnosed with acute coronary syndrome who applied to our center and were revascularized with PCI were retrospectively screened. Patients were divided into two groups according to their TIMI flow score after the intervention: those with normal flow and those with NRP. The parameters affecting the development of NRP in these patients were investigated.

Results: A total of 97 patients were included in the study. The average age of the patients was observed to be 70 (62-79) years. NRP was observed to develop in 32 patients. In patients who developed NRP, smoking was found to be 56.3% ($P=0.016$), and blood glucose levels at the time of admission (231 mg/dL vs 154.6 mg/dL, $P<0.001$) and LDL values (117 vs 83, $P<0.001$) were found to be statistically significantly higher.

Conclusion: LHR values were found to be significantly higher in the patient group that developed NRP.

Keywords: Acute coronary syndrome, lymphocyte/HDL ratio, percutaneous coronary intervention, no-reflow phenomenon

Table 1. Basic characteristics and laboratory examinations of the no-reflow and normal flow groups

	All Patients (n=97)	NRP developed (n=32)	Normal flow achieved (n=65)	P value
Demographic features				
Age (years)	70 (62-79)	64 (56-70)	73 (67-80)	0.002
Male Sex, n (%)	81 (83.5)	25 (78.1)	56 (86.2)	0.316
Comorbidities, n (%)				
Hypertension	72 (74.2)	27 (84.4)	45 (69.2)	0.109
Diabetes	33 (34)	11 (34.4)	22 (33.8)	0.959
Hyperlipidemia	88 (90.7)	28 (87.5)	60 (92.3)	0.443
Smoking	38 (39.2)	18 (56.3)	20 (30.8)	0.016
Chronic renal failure	33 (34)	13 (40.6)	20 (30.8)	0.335
At the time of application				
Systolic blood pressure (mmHg)	131 (111-150)	134 (124-148)	129 (110-150)	0.259
Heart Rate (bpm)	77 (71-82)	79 (75-85)	77 (71-80)	0.505
LVEF (%)	42 (35-50)	40 (28-50)	42 (35-50)	0.481
Anti platelet drug use, n (%)	97 (100)	32 (100)	65 (100)	1
Beta blocker drug use, n (%)	77 (79.4)	23 (71.9)	54 (83.1)	0.200
ACE inh. Drug use, n (%)	55 (56.7)	25 (78.1)	30 (46.2)	0.003
Oral anti diabetic drug use, n (%)	19 (19.6)	7 (21.9)	12 (18.5)	0.690
Insulin use, n (%)	12 (12.4)	5 (15.6)	7 (10.8)	0.495
Laboratory values				
HbA1c (%)	7.27 (5.99-7.8)	7.42 (5.54-7.90)	7.19 (6.19-7.40)	0.645
Glucose levels at the time of admission (mg/dL)	179.96 (124-205)	231.4 (144.5-297)	154.6 (117-189)	<0.001
eGFR (ml/min/1.73 m ²)	73.64 (48.4-93)	69.1 (35.3-101)	75.9 (53.9-92.8)	0.242
Neutrophil (×10 ⁹ /L)	6.0 (4.8-8.1)	6.9 (4.7-9.3)	5.8 (4.8-6.3)	0.046
Lymphocyte (×10 ⁹ /L)	2.0 (1.5-2.9)	2.3 (1.7-3.5)	1.9 (1.4-2.7)	0.036
Monocyte (×10 ⁹ /L)	0,6 (0.5-0.7)	0.7 (0.5-0.8)	0.63 (0.5-0.7)	0.218
Hemoglobin (g/dL)	12.9 (11.3-14.4)	13.8 (11.5-15.5)	12.5 (10.5-13.5)	0.006
Peak Troponin I (ng/L)	21793 (288-20640)	22016 (362-29767)	21683 (288-18882)	0.968
Total cholesterol (mg/dL)	166.52 (130-209)	196.1 (154-219)	151.9 (126-185)	<0.001
LDL cholesterol (mg/dL)	94.31 (57.6-120)	117.2 (78.7-133.9)	83 (53.4-107.6)	<0.001
HDL cholesterol (mg/dL)	35.0 (30.0-42.4)	32.3 (28.0-41.3)	36.0 (32.9-43.0)	0.02
LHR (×100)	5.6 (4.1-7.9)	6.6 (5.1-9.7)	5.1 (3.1-6.9)	0.004
MHR (×100)	1.7 (1.37-2.06)	1.9 (1.6-2.1)	1.5 (1.2-2.0)	0.06

Data are presented as median (interquartile range) or number of patients (percentage). LVEF=left ventricular ejection fraction, ACE=angiotensin-converting enzyme, OAD=oral antidiabetic, LDL=low density lipoprotein eGFR=estimated glomerular filtration rate, LHR=Lymphocyte/HDL ratio, MHR=Monocyte/HDL ratio

Table 2. Angiographic status of the groups in which no-reflow developed and normal flow was achieved

Angiographic parameters	NRP Developed (n=32)	Normal flow achieved (n=65)	P value
LAD, n (%)	0 (0)	5 (7.7)	0.004
RCA, n (%)	15 (46.9)	11 (16.9)	
Cx; n (%)	11 (34.4)	43 (66.2)	
Diagonal, n (%)	4 (12.5)	5 (7.7)	
IM, n (%)	2 (6.3)	1 (1.5)	
Procedural data			
Pre-PCI, P2Y12 inhibitors			
Clopidogrel	23 (71.9)	62 (95.4)	0.001
Ticagrelor	9 (28.1)	3 (4.6)	
Stent implantation, n (%)	29 (90.6)	65 (100)	0.012
Stent diameter (mm)	26.9 (16-38)	25.8 (20-32)	0.693
Predilatation, n (%)	23 (71.9)	27 (41.5)	0.005
Postdilatation, n (%)	12 (37.5)	19 (29.2)	0.412
Thrombus grade, n (%)			
1	0 (0)	2 (3.1)	0.001
2	0 (0)	17 (26.2)	
3	6 (18.8)	20 (30.8)	
4	16 (50)	19 (29.2)	
5	10 (31.1)	7 (10.8)	
Total ischemia time, h	13.1 (7-16)	9.4 (3-13)	0.024

Data are presented as median (interquartile range) or number of patients (percentage). NRP=no-reflow phenomenon, Cx=circumflex artery, LAD=left anterior descending artery, PCI=percutaneous coronary intervention, RCA=right coronary artery

OP-29.

[Once Upon a Time, Thrombus in the Right Atrium]

Bir Varmış Bir Yokmuş Sağ Atriyumda Trombüs

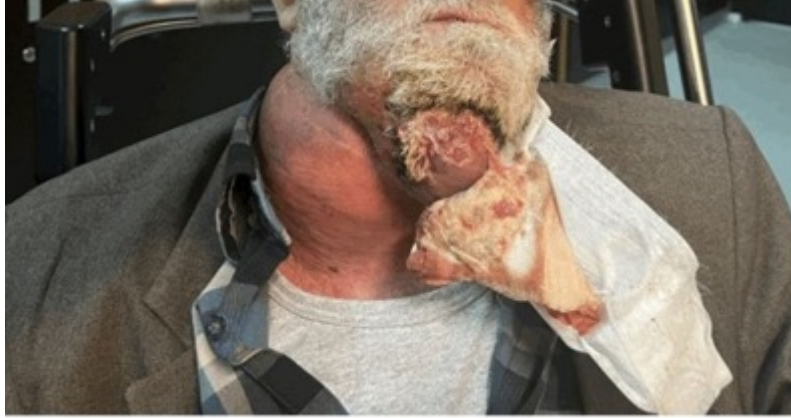Ayşe Nilgün Kara, Çetin Alak, Alparslan Birdane

Bursa Uludağ Üniversitesi, Tıp Fakültesi, Kardiyoloji Anabilim Dalı, Bursa, Türkiye

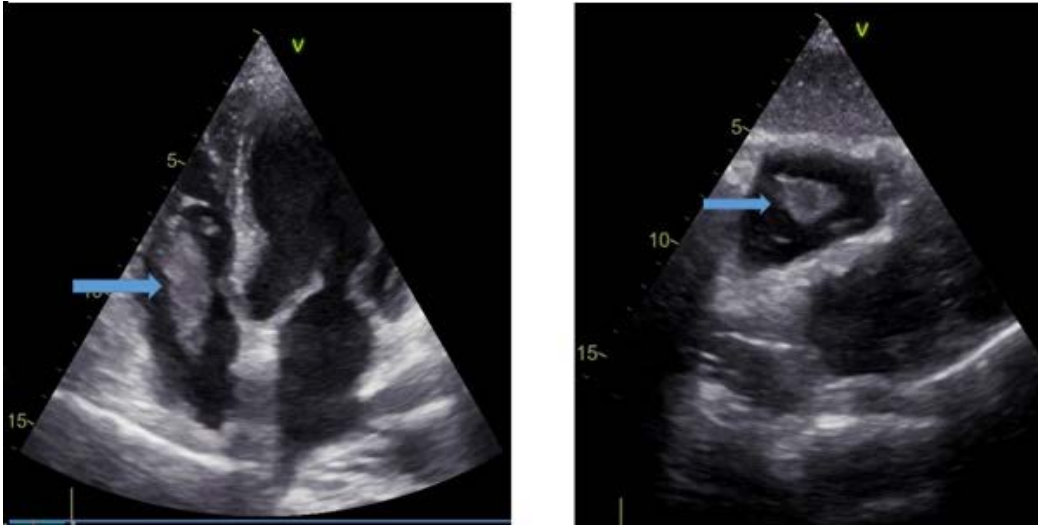
Olgu Sunumu: Seksen yaşında erkek hasta, boyunda yerleşim gösteren skuamoz hücreli Karsinom (SCC) nedeniyle kemoterapi planlandığı için, kemoterapi öncesi kardiyoloji görüşü istenmesi üzerine polikliniğimize başvurdu. Hastanın yapılan fizik muayenesinde çene sağ alt yanında enfekte kesi ve boyunda ciddi şişlik izlendi (Resim 1). Kemoterapi öncesi rutin olarak hastadan istenen transtorasik ekokardiyografisinde sağ atriumdan sağ ventriküle girip çıkan 4.2×1.6 cm boyutlarında trombüs? kitle? imajı ile uyumlu yapı izlendi. (Şekil 1a-b) Hasta kardiyak kitle? etiolojisini araştırmak ve hastanın tedavisini başlatmak amacıyla hasta kardiyoloji yoğun bakıma yatırıldı. Yoğun bakım takipleri sırasında tedavi dozunda düşük molekül ağırlıklı heparin (DMAH) başlanan hastaya kardiyak manyetik rezonans görüntüleme (KMR) planlandı. Çekilen KMR'da superior vena cavada trombüs ile uyumlu görünüm izlenirken sağ atriyum ve ventrikülde kitle imajı izlenmediği gözlemlendi (Şekil 5). Hastaya bir gün sonra yapılan kontrol ekokardiyografide daha önceki ekokardiyografisinde izlenen trombüs? kitle? imajının izlenmemesi (Şekil 2a-b) üzerine emboli şüphesiyle hastaya BT anjiyografi çekirildi. Çekilen BT anjiyografisinde; ağız tabanı düzeyinden submental bölgeye uzanan yaklaşık 73 mm ve sağ supraklavikuler alanda yaklaşık 11 cm boyutlarına varan nekrotik komponente baskın solid kitle lezyonları izlendi. Sözkonusu lezyonlara bağlı trakea ve larenks düzeyi sola deviye olduğu gözlemlendi. Sağ juguler vene belirgin bası bulgusu saptandı. Sağ juguler venden başlayıp sağ brakioyosefalik trunkusa ve bu düzeyden vena kava superiora uzanan trombüs formasyonu izlendi (Şekil 4). Sol pulmoner arterin lobar-segmental dallarında emboli ile uyumlu dolum defekti (Şekil 3) izlenmekte olduğu gözlemlendi. Hastanın boyundan köken alan SCC'si bası yoluyla sağ juguler vende trombüse yol açtığı ve trombüsün sağ juguler venden başlayıp sağ brakioyosefalik vene ve vena cava superiora ordan da sağ atriyum ve sağ ventriküle ilerlediği anlaşıldı. Hastanın ekokardiyografi yapılan günde Trombüsün sağ Atriyum ve sağ ventrikülde gözlemlendiği fakat kardiyak MR ve BT çekilirken trombüsün sağ ventrikülden pulmoner yatağa embolize olduğu anlaşıldı. Sonuç olarak hasta göğüs hastalıkları ile birlikte değerlendirilerek DMAH tedavisine devam edildi. Aktif semptomu olmayan hasta yakın dönem poliklinik kontrolü önerilerek taburcu edildi.

Sonuç: Sağ atrial trombüs nadir görülen ancak pulmoner emboli veya paradoksal sistemik emboliye neden olabilen önemli bir durumdur. Pulmoner emboliye ve paradoksal sistemik emboliye neden olması halinde emboli lokalizasyonuna göre çok çeşitli semptomlar gösterebilmekle beraber asemptomatik de olabilmektedir. Malignite öyküsü olan hastaların tromboza yatkın olduğu bilinmektedir. Bu hasta grubunda en önde gelen mekanizmalardan biri artmış koagülabilitedir. Cilt kanserlerinde sistemik maligniteler gibi artmış koagülabilitate gözlenmemektedir. Fakat bizim hastamızda olduğu gibi belirgin bası bulgusu yapan cilt maligniteleri de tromboza yol açabildiği gözlenmiştir. Biz bu hastamızı kardiyak kitle ? trombüs ? ayırıcı tanısı ve multimodalite görüntülemenin önemini vurgulamak için paylaşmak istedik. Aynı zamanda malignite hastalarında artmış trombojenite yanında basının da direkt tromboza yatkınlık yapabileceğini göstermek amacıyla paylaşmak istedik.

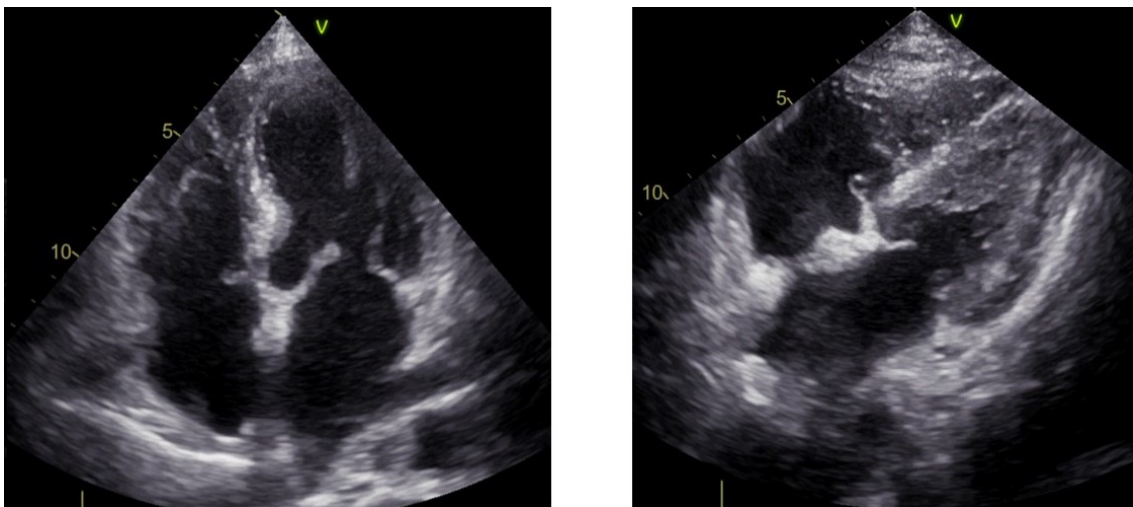
Anahtar Kelimeler: Sağ atrial trombüs, cilt kanseri, multimodalite görüntüleme



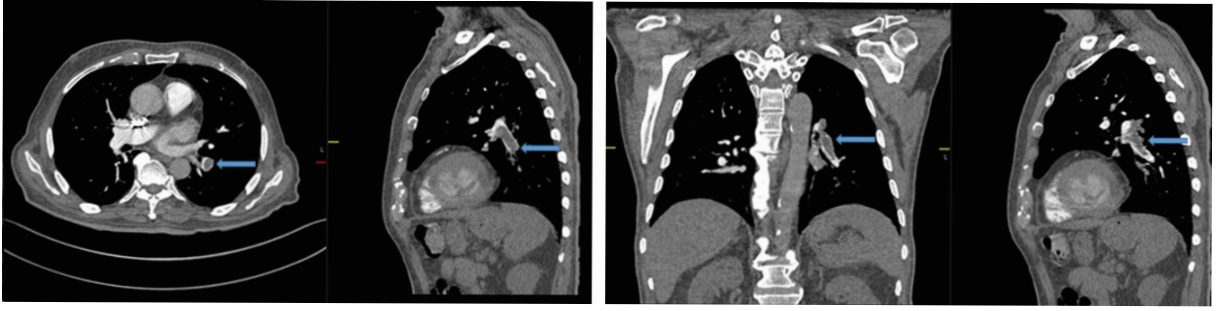
Resim 1. Skuamöz hücreli karsinom



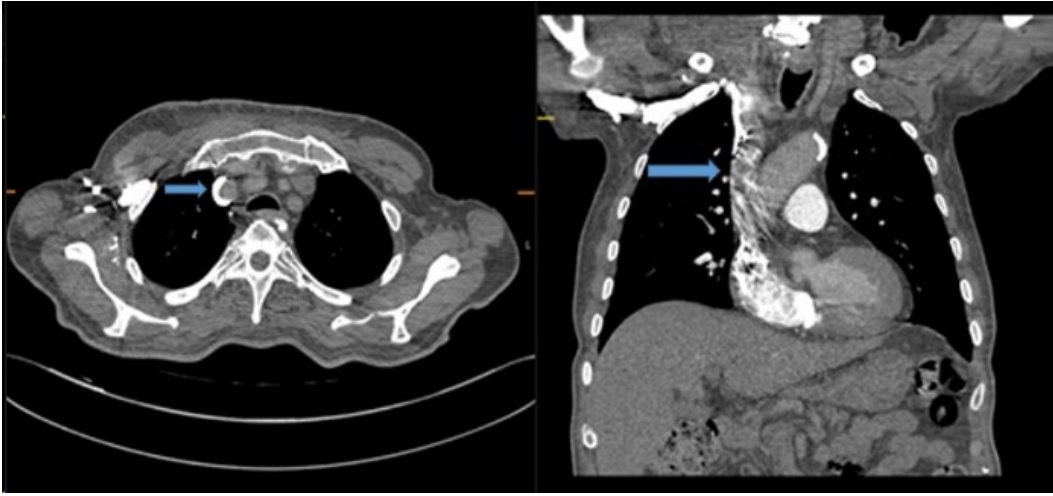
Şekil 1. (a) Ekokardiyografi-Apikal 4 boşluk, Mavi ok: Sağ atriyum ve ventrikül içinde trombüs. (b) Subkostal görüntü, Mavi ok: Sağ atriyum ve ventrikül içinde trombüs



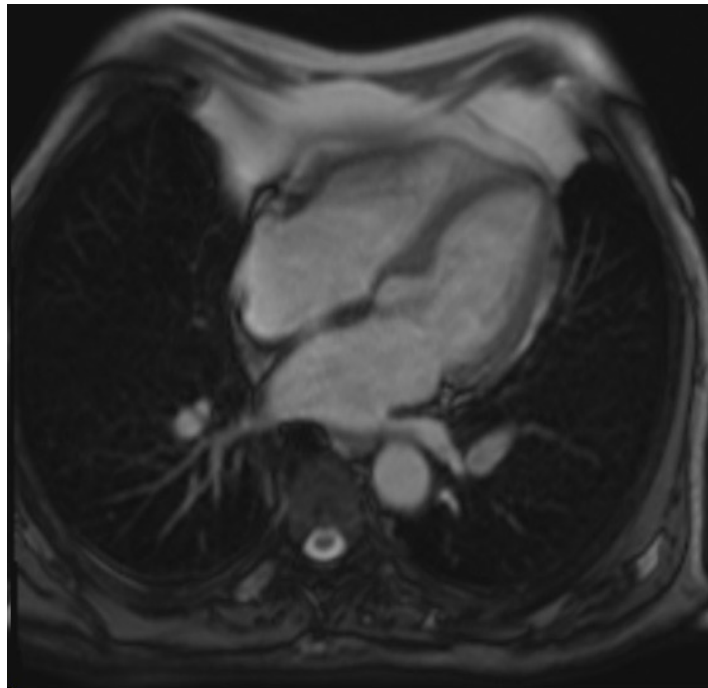
Şekil 2. (a) Ekokardiyografi-Apikal dört boşluk, Sağ atriyum ve ventrikül içindeki trombüsün kaybolduğu izlendi. (b) Subkostal görüntü, Sağ atriyum ve ventrikül içindeki trombüsün kaybolduğu izlendi.



Şekil 3. Bilgisayarlı tomografi, Mavi ok: Embolize olan sağ atriyum ve ventriküldeki trombüs



Şekil 4. Bilgisayarlı tomografi, Mavi ok: Sağ juguler vende ve superior vena kava'da trombüs



Şekil 5. Kardiyak MR, Sağ atriyum ve ventrikülde trombüs veya kitle imajı izlenmedi.

OP-30.

[From Diarrhea to the Heart! Tricuspid Valve Endocarditis]

İshalden Kalbe! Triküspit Kapak Endokarditi

Ali Melik Doğan¹, Çetin Alak¹, Tunay Şentürk¹, Murat Biçer²

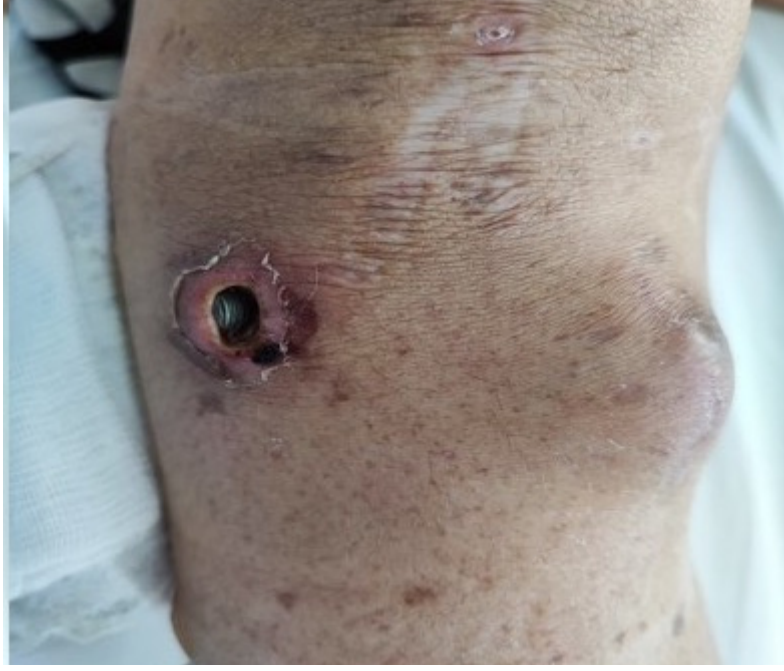¹Bursa Uludağ Üniversitesi Tıp Fakültesi, Kardiyoloji Anabilim Dalı, Bursa, Türkiye; ²Bursa Uludağ Üniversitesi Tıp Fakültesi, Kalp ve Damar Cerrahisi Anabilim Dalı, Bursa, Türkiye

Olgu Sunumu: Kırk sekiz yaşında kadın hasta diyaliz sonrası ateş, bilinç bulanıklığı nedeni ile Nefroloji kliniği tarafından yatırılmış. Hastanın öyküsünde ailesel akdeniz ateş öyküsü ve kronik renal yetersizliği mevcut. Rutin diyaliz programına alınan ve fistül işlemi planlanan hastada fistül trombozuna bağlı sık fistül değişimi yapılmış. 2022 mayıs ayında ekstremitelerde yaygın ülsere lezyonlara biopsi yapılmış ve sonucunda mikroskopik vaskülit ile uyumlu gelmiş. Romatoloji tarafından poliarteritiz nodoza düşünülmüş ve deltacortil başlanmış. Hastanın 1998 yılında kemik tüberkülozu geçirdiği ve iki yıl önce spontan femur kırığı öyküsü olduğu öğrenildi. 17.08.2022 tarihinde diyaliz sonrası ateş bilinç bulanıklığı gelişen hasta katater enfeksiyonu sepsis ön tanıları ile nefrolojiye yatırılmış. Hastanın bu olaydan iki hafta önce bir ishal atağı yaşadığı öğrenildi. Hastanın ateşi 39°C civarında seyretmekteydi. Bu süreçte nefrolojide yatmakta olan hastanın diz bölgesinde, platin implante edilen bölgede (Resim 1) apse ile uyumlu görünüm izlendi. Hastanın az da olsa ishali devam etmesi üzerine hastadan dışkı ve kan kültürü alındı. Daha önce fistülü olan hasta sık fistül trombozu nedeni ile fistülü kullanılmamakta bu nedenle kalıcı diyaliz katateri mevcuttu. Hastanın olası enfeksiyon kaynağı diyaliz katateri olabileceği düşünülerek diyaliz katateri çekildi ve oradan kültür gönderildi. Hastanın ateşleri antibiyoterapi altında devam etmesi nedeni ile enfektif endokardit? Ön tanısı ile ekokardiyografi ile değerlendirildi. Transtorasik ekokardiyografi'de sağ atriyumda triküspit kapağın lateral tarafında düzensiz kenarlı yumuşak dansiteli 2.2×0.8 cm çapında sağ ventriküle girip çıkan trombüs? Vejetasyon? ile uyumlu görünüm izlendi (Şekil 1). Hastanın bu dönem takibinde bacakta platin implante edilen bölgeden apse spontan drene oldu ve oradan da yara yeri kültürü gözlendi. Hastanın alınan kan, dışkı ve pü kültüründe enterococcus faecalis üremesi saptandı. Hastanın enterococcus faecalis etkenine bağlı tüm semptomlara yol açtığı düşünüldü. Hasta mevcut tabloda triküspit endokarditi, açık diz apsesi nedeni ile servisimizde takip edilmekteydi. Bu hastanın yönetimi kalp takımı ile tartışıldı. Hastada enfeksiyöz süreci devam ettirebileceği, sağ taraflı endokarditlerde operasyon sonrası nüksün de sık olması nedeni ile öncelikle dizden ortopedi tarafından opere edilmesi sonrasında triküspit kapak açısından cerrahi kararı verildi. Bu dönemde antibiyoterapisi enfeksiyon hastalıkları tarafından düzenlendi. Hastaya başarılı diz operasyonu yapıldıktan sonra triküspit kapak açısından ameliyata alındı. Sağ taraflı endokardit hastalarında bizim hastamızda olduğu gibi predizpozan faktörlerin sık olması nedeni ile nüks ihtimali yüksek saptanmaktadır. Bu nedenle operasyonda öncelikle mümkünse triküspit kapak tamiri önerilmektedir. Konseyde kalp takımı ile kapağın durumu uygunsa öncelikle onarım yapılması planlandı fakat kapak yapısı ileri derece destrükte olması nedeni ile triküspit kapak replasmanı kararı alındı. Hastaya 29 St Jude bioprotez triküspit kapak replasmanı yapıldı. Ameliyat komplikasyonsuz sona erdirildi. Hasta tarafımızca poliklinikten takip edilmektedir.

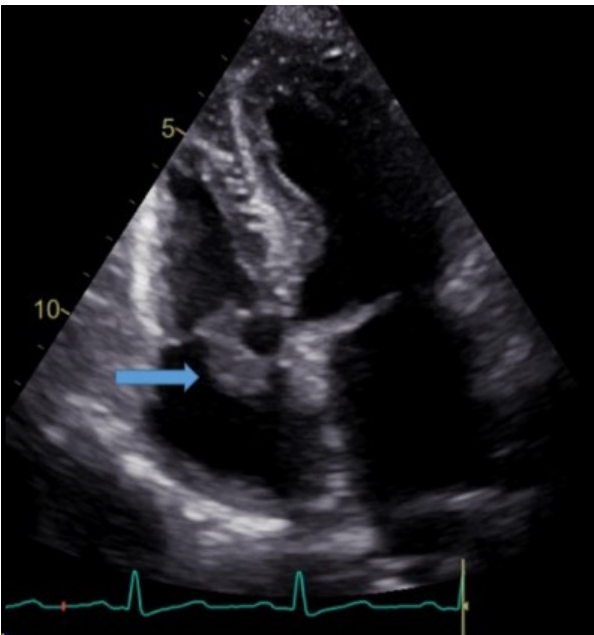
Sonuç: İntravenöz ilaç kullanımı gelişmiş ülkelerde sağ taraflı endokarditlerin en sık nedeni oluşturmakla birlikte birçok predispozan faktör literatürde tanımlanmıştır. Bizim hastamızın kronik hemodiyaliz alması,

katateri olması, immunsuprese olması sağ taraflı infektif endokardit riskini artmıştır Bu hastalarda tanı koymak bazen zorlayıcı zorlayıcı olabilmekle birlikte erken teşhis hayat kurtarıcıdır. Bu hastaların altta yatan predispozan durumlarına bağlı tekrarlayan sağ taraflı endokardit açısından büyük risk altında oldukları unutulmamalıdır. Bizim hastamızda sağ taraflı endokardit tanı ve yönetimi açısından zorlu bir vaka olması nedeni ile paylaşmayı amaçladık.

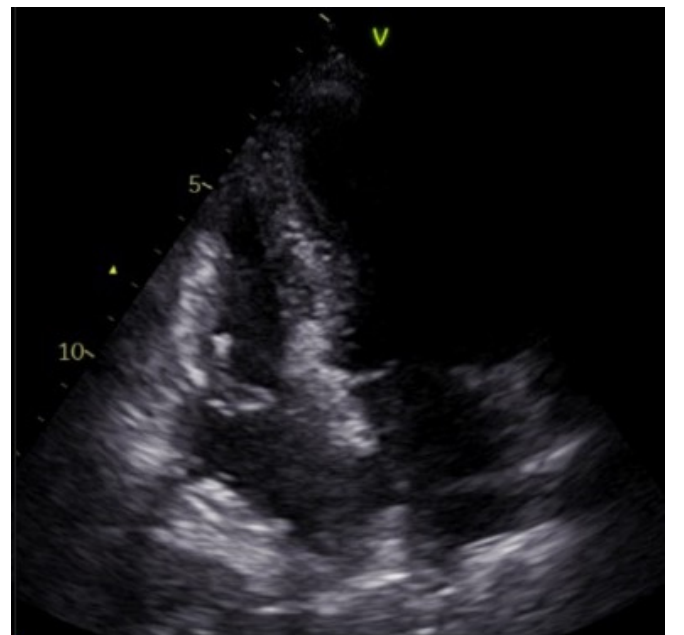
Anahtar Kelimeler: Triküspit kapak endokarditi, diyare, diyaliz, cerrahi girişim



Resim 1. Diz bölgesinde açık enfekte yara.



Şekil 1. Apikal dört boşluk görüntü, Mavi ok: Triküspit kapak üzerinde vejetasyon



Şekil 2. Operasyon sonrası fonksiyone biyoprotez triküspit kapak

OP-31.

[Delirium or not?: contrast induced encephalopathy]

Gerçekten Deliryum mu?: Kontrasta Bağlı Ensefalopati

Samatar Adam, Çetin Alak, Bülent Özdemir

Department of Cardiology, Bursa Uludağ University, Medical of Scholl, Bursa, Turkey

Vaka: 64 yaşında erkek hasta, baskı tarzı göğüs ağrısıyla tarafımıza başvurdu. Hastanın acil serviste çekilen elektrokardiyografisinde sinüs bradikisi ve inferior derivasyonlarda ST elevasyonu izlendi (Şekil 1). STEMI tanısı ile sağ femoral yaklaşımla yapılan koroner anjiyografide (KAG), sağ koroner arter (RCA)'in %100 tıkalı olduğunu ortaya çıkı (Şekil 2, Şekil 3). Bradikardik seyreden hastaya geçici pacemaker takıldı ve RCA stent implante edildi (Şekil 4). Hastanın işlem sırasında ve sonrasında herhangi bir şikayeti olmadı. KAG işleminde kontrast madde olarak düşük ozmolar, iyonik olmayan, monomerik, iyot bazlı iopromid (200 mililitre) uygulandı.

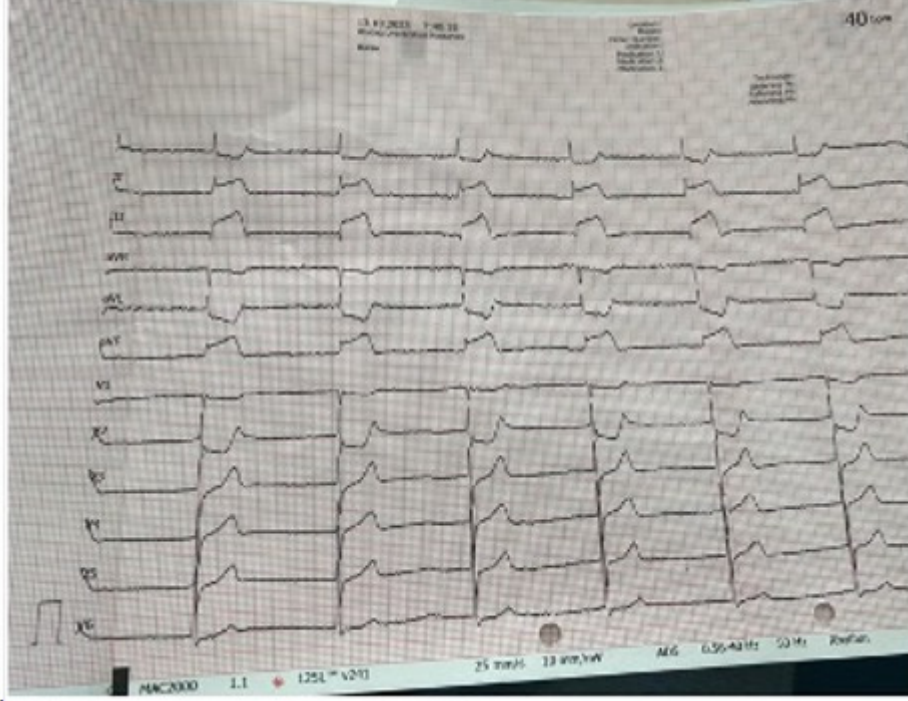
Hasta KAG sonrasında öğlen saatlerinde ajitasyon, anlamsız konuşmalar sergilemesi üzerine yapılan nörolojik muaynesinde Glaskow Koma Skalası 11, pupilleri izokorik olarak izlendi, ışık refleksi değerlendirilemedi. Ajite olan hastanın, ekstremiteleri tespitli ve spontan hareketleri mevcuttu. Hastada taraf bulgusu gözlenmedi. Acil olarak çekilen bilgisayarlı beyin tomografisinde ve beyin manyetik rezonans görüntüleme herhangi bir akut patolojik bulgu görülmedi (Şekil 5, Şekil 6).

Hastaya kontrast madde atılımını hızlandırmak için intravasküler hidrasyon uygulandı. Hastanın semptomları azaltmak için psikiyatri tarafından Haloperidol damla ve uyku desteği için Ketiyapin tablet önerildi. Hastanın semptom başlangıcından 8 saat sonra şikayetlerinde tamamen gerileme gözlemlendi.

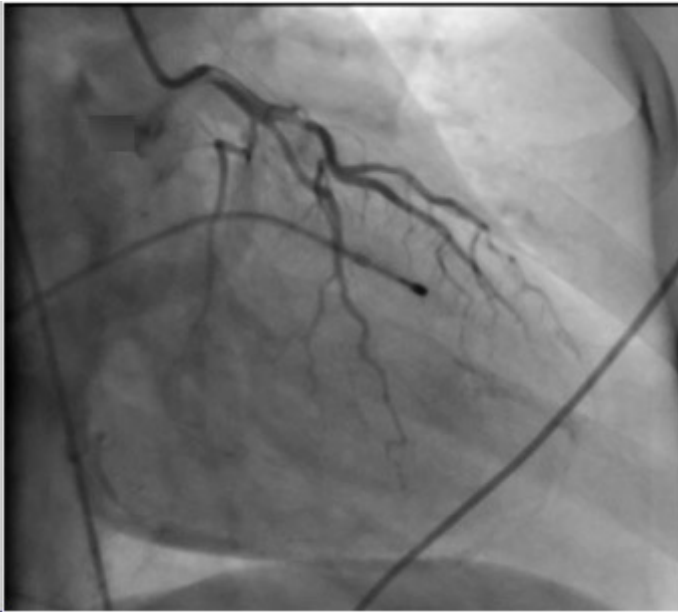
Sonuç: Kontrast kaynaklı ensefalopati (CIE), perkütan karotis ve koroner girişimlerin nadir bir komplikasyonudur. İyonik, iyonik olmayan, düşük ozmolariteli, izo-ozmolariteli ve yüksek ozmolariteli solüsyonları içeren kontrast ortamının CIE'yi indüklediği rapor edilmiştir. CIE görülme sıklığı %0,3 ile %1,0 arasında değişmektedir. Hiperosmolar iyotlu kontrast maddelerinin kullanımı, %4'e varan CIE insidansı ile sonuçlanır. İyonik olmayan, düşük ozmolar ajanlar nispeten daha az nörotoksik. Hipertonik kontrast maddelerinin kan beyin bariyerini (KBB) bozma olasılığı daha yüksektir, bu da beyne girişin artmasına neden olur, bu da ödeme ve doğrudan nöronal toksisiteye neden olabilir. Kontrast madde kaynaklı nörotoksik etkiler KBB'nin bozulmasından kaynaklanır. KBB'ye artan geçirgenlik, kontrast madde sızıntısına ve beyin dokusu kolloid ozmotik basınç değişikliklerine izin verir, bu da serebral ödem, nörotoksisite ve kontrastın neden olduğu ensefalopati ile sonuçlanır. Lokal kortikal kontrastlanma, subaraknoid dansitesi artışı, beyin ödemi gibi beyin BT bulguları görülebilir. Ancak CIE'li bazı hastaların radyolojik özellikleri yoktur. CIE'li hastaların çoğunun prognozu iyidir ve intravenöz sıvılar ve yakın gözlem dahil olmak üzere destekleyici tedaviyle hızla iyileşir. Bazı durumlarda nöbetleri tedavi etmek için antikonvülsif ilaçlar kullanılabilir ve beyindeki basıncı azaltmak için mannitol kullanılabilir. Gerekliğinde inflamatuvar reaksiyonları azaltmak için deksametazon gibi steroid hormonları kullanılabilir. Genelde semptomları 48-72 saatte tamamen düzelir.

KAG sonrası CIE nadir fakat karmaşık bir nörolojik bozukluktur. CIE'nin belirtileri değişiklik gösterir ancak destekleyici tedaviyle birlikte prognoz genellikle iyidir. Birçok çalışma, yüksek ozmolaliteli ajanlara yanıt olarak CIE gelişme riskinin daha yüksek olduğunu öne sürse de, vakamız, düşük ozmolar, noniyonik, monomerik iyot bazlı kontrast ajanların küçük miktarlarına yanıt olarak da ciddi CIE semptomlarının ortaya

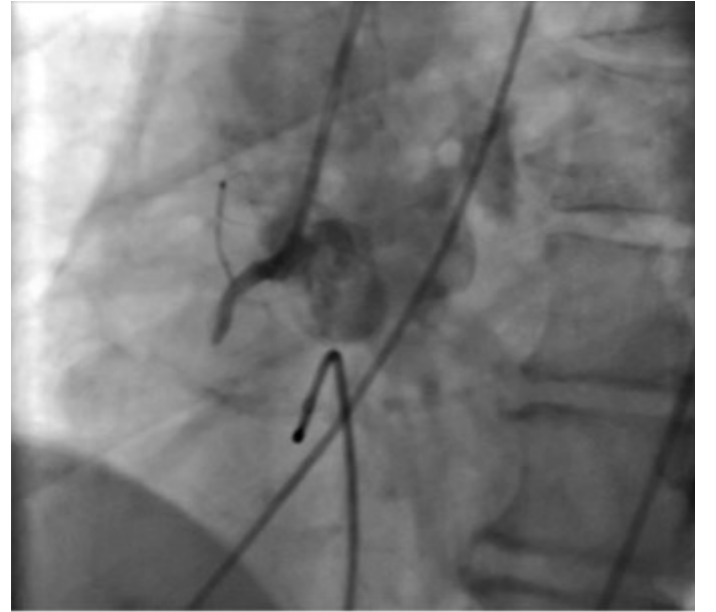
çıkabileceğini göstermektedir. Kalp kateterizasyonunu takiben gelişen inmenin ayırıcı tanısında kontrast maddeye bağlı ensefalopati mutlaka göz önünde bulundurulmalıdır. CIE'nin erken klinik şüphesi, terapötik hususları değiştirebilir ve tromboliz gibi potansiyel olarak zararlı müdahalelerden kaçınmaya yardımcı olabilir. **Anahtar Kelimeler:** Deliryum, kontrasta bağlı ensefalopati, kalp kateterizasyonu



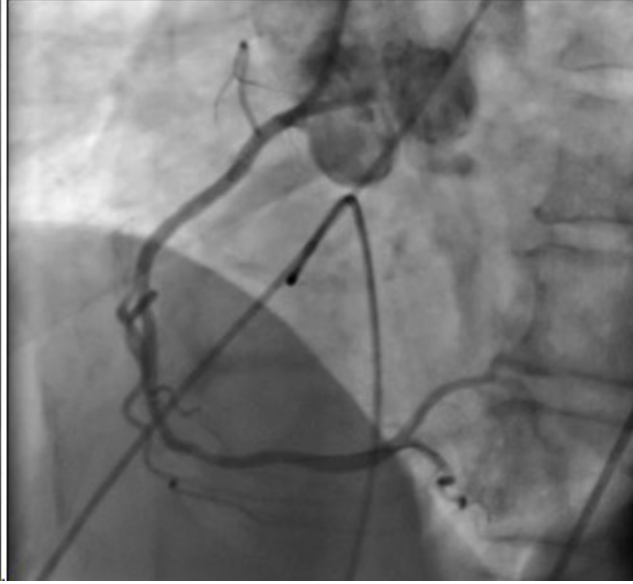
Şekil 1. Hastanın Acil Serviste Çekilden EKG'si



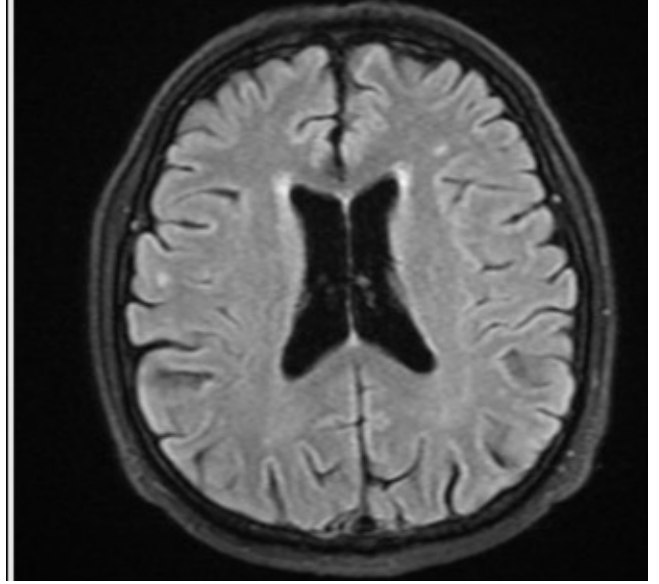
Şekil 2. Hastanın LAD ve Cx'I



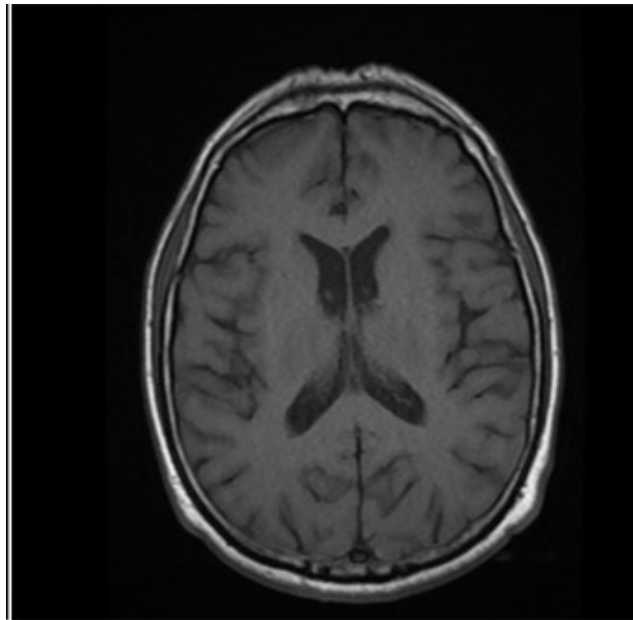
Şekil 3. Hastanın Stent Öncesi RCA'sı



Şekil 4. Hastanın Stent Sonrası RCA'sı



Şekil 5. Hastanın Beyin BT'si



Şekil 6. Hastanın Beyin MR'ı

OP-32.

Percutaneous Closure of an Iatrogenic Mitral Valve Perforation

Hatice Feyza Dilek, Hilal Erken, Saadet Demirtaş İnci, Gürkan İş, İbrahim Hakan Güllü

Department of Cardiology, Etlik City Hospital, Ankara, Türkiye

A 60 years old female patient with a history of atherosclerotic cardiovascular disease, hypertension, aortic valve replacement (3 years prior; mechanical valve), pace maker and asthma present to cardiology outpatient clinic with the complaint of progressive exertional dyspnea and decreased functional capacity. Transthoracic echocardiography revealed severe eccentric mitral regurgitation flow from a perforation on anterior mitral leaflet (Fig. 1a). Transesophageal echocardiography confirmed that perforation was in the A2 scallop in the anterior mitral leaflet (Fig. 1b). Also separate mitral insufficiency flow was seen in the A2 and P2 scallops confirming the moderate to severe mitral insufficiency. Most probable cause being the AVR surgery as the patient did not have any history of infective endocarditis or any other underlying medical pathology. Considering patient's co-morbidities and history of past AVR, heart team decided to proceed with percutaneous repair of the perforation.

Performance of the mitral valve perforation repair: Under proper anesthetic care; the right femoral vein was accessed. Septostomy was performed from a proper point. Then Agilis catheter was advanced into the left atrium and directed to the mitral A2 scallop. Using a cut pigtail and 0.018 inch gladius wire the defect was crossed and the 0.018 inch wire was replaced with a 0.035 inch safari wire. Therefore, over the safari wire 5F delivery catheter was advanced into the left ventricle through the mitral rupture (Fig. 2a). Through the catheter 4 mm Lifetech symmetrical MVSD occluder was implanted into the perforation on the mitral A2 scallop (Fig. 2b). The defect was successfully closed. Control transesophageal images showed successful closure of the perforation without any regurgitant flow (Fig. 3).

Keywords: Iatrogenic mitral valve perforation, mitral insufficiency, percutaneous closure

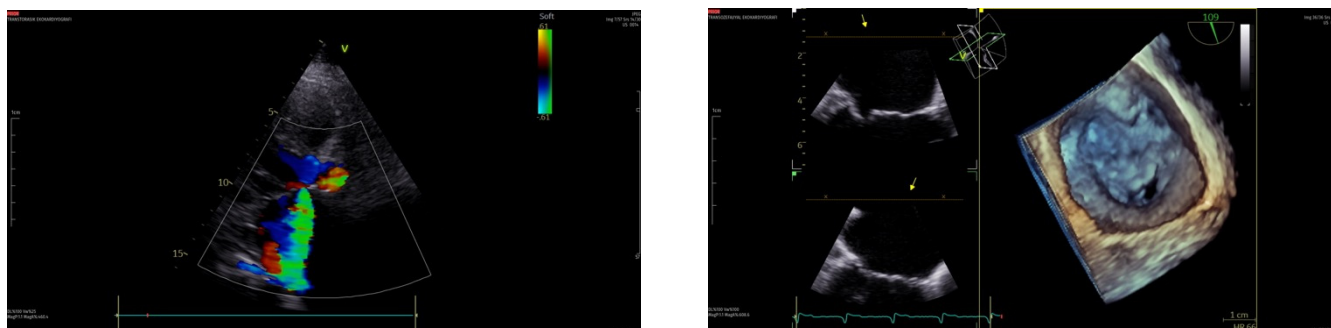


Fig. 1. (a) Mitral regurgitation flow seen due to a perforation of the anterior mitral leaflet on transthoracic echocardiography, **(b)** 3-dimensional transesophageal echocardiography showing the perforation on A2 mitral leaflet scallop (red arrows).

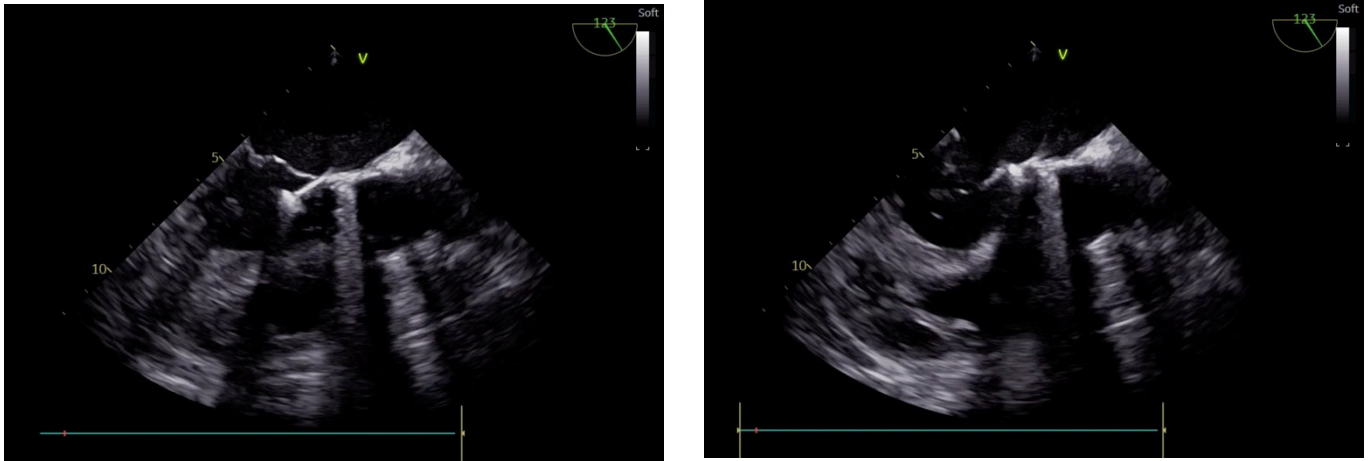


Fig. 2. Transesophageal echocardiography images of (a) The Agilis catheter crossing anterior mitral leaflet in the left atrium (b) 6 mm Lifetech symmetrical Musd occluder placement into the perforation on the mitral anterior leaflet.

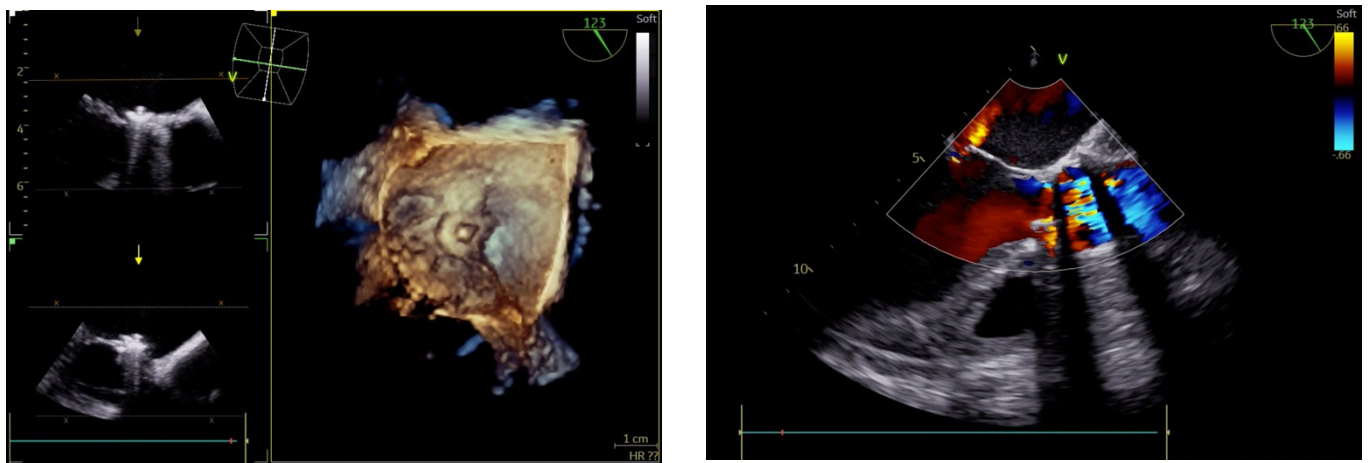


Fig. 3. Successful closure of the perforation without a residual regurgitant flow and the Musd occluder (green arrows) are shown both by 3-dimensional and 2-dimensional transesophageal echocardiography.

OP-33.

Closure of a Paravalvular Leak between Ring and Valve: A Case Report

Ertan Ekici, Hilal Erken Pamukçu, Sinan Cemgil Özbek, Buse Çuvalcioglu, Ibrahim Hakan Güllü

Department of Cardiology, Etlik City Hospital, Ankara, Türkiye

Paravalvular leak is an important complication of valve replacement procedures with the incidence around 7% to 17%. Despite being relatively uncommon, major leaks may have some serious consequences such as heart failure, hemolysis. Thus, diagnostic approach must seek the individuals with these symptoms suffering from more severe leakage. Particularly, patients with abnormal murmurs, hemolytic anemia and/or heart failure need more attention. Transthoracic echocardiography (TTE) is the first diagnostic step when paravalvular leak is suspected. TTE provides a lot of data including chamber sizes, gradients, systolic functions and pulmonary pressure. When PVL is suspected, transesophageal echocardiography (TEE) is the gold standart for diagnosing PVL, locating the origin, sizing of the defect and evaluating the severity of leakage.

Our patient is a 68-year-old female with history of ring annuloplasty of mitral valve, thereafter mechanical mitral valve replacement in 1988 (Monoleaflet Bjork -Shiley) and re-do mitral and aortic valve replacement (Bileaflet, St Jude Medical) in 2021. She was admitted to hospital with gradually worsening heart failure symptoms and anemia. At the time of admission, patient had severe congestion including pleural effusion, ascites and orthopnea, compatible with NYHA Class III. Her laboratory parameters were Hemoglobin 8.7 gr/dL, haptoglobin 0.01 g/L total bilirubin 2.79 mg/dL direct bilirubin 0.85 mg/dL, LDH 1787U/L pointing to hemolytic anemia and NT-ProBNP was 9936 pg/mL due to congestion.

TTE revealed severe paravalvular leak on mitral position, severe tricuspid regurgitation and systolic pulmonary artery pressure was 60 mmHg. TEE showed three foci of paravalvular leak one of which was severe and located on 6 o'clock position in between the mitral valve annulus and an outer sutured ring which then thought to be an annuloplasty ring. Since redo surgery was performed in a center affected by the earthquakes, further investigation on patient's surgical records was not possible. The patient evaluated by Heart Team and percutaneous paravalvular closure is decided (Figs. 1, 2, and 3).

The procedure was initiated through right femoral vein (7F) and left femoral artery (6F) access, under fluoroscopic and 3D TEE guidance. Following the right atrial access, infero-posterior septostomy was performed. Culprit defect was crossed using Agilis™ N×T Steerable Introducer and 0.035 inch hydrophilic straight wire. After getting into the left ventricle by a cut pigtail, the hydrophilic wire exchanged by a 0.035 inch Safari wire. Over the Safari wire 5F 120 cm delivery catheter was advanced into the left ventricle. Through the delivery catheter, Amplatzer Vascular Plug III (10×3mm) was implanted in the defect at 6 o'clock position. Left femoral arterial access was used only for ventriculography to confirm severity of paravalvular leakage. PVL closure is complex procedure, requiring both teamwork and expertise. We believe this particular case was even more interesting due to the unusual location of the defect between preexisting mitral annuloplasty ring and mechanical valve ring. In this case, because of the metallic artifact, computerized tomography (CT) was insufficient to confirm the presence of a second outer ring around the mechanical mitral valve. Although multimodality imaging has major effects in Cardiology, 3D TEE is still essential both diagnostic and interventional management of PVL.

Keywords: Paravalvular leak, percutaneous closure, multimodality imaging, treatment

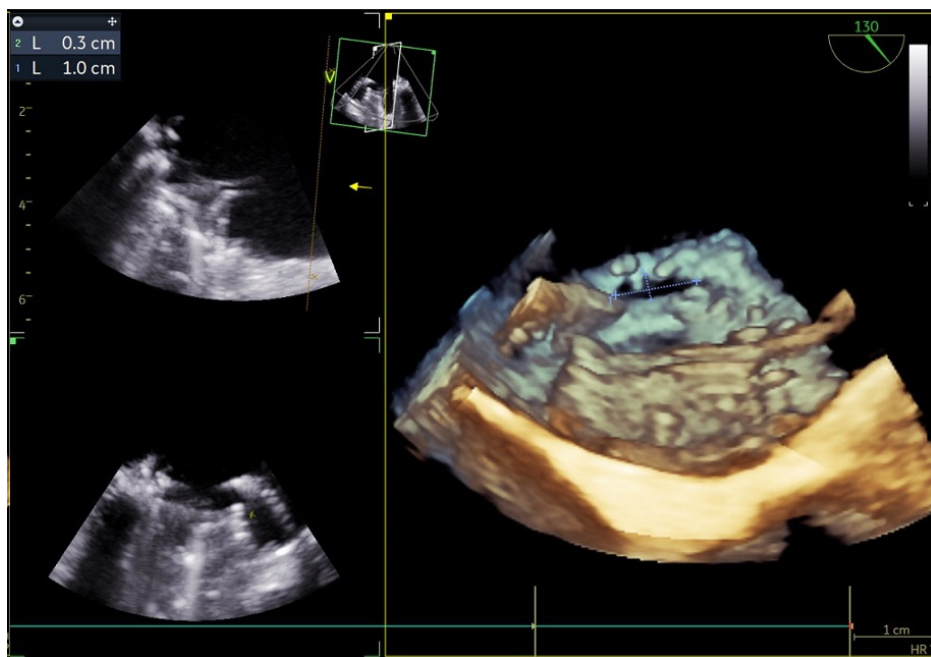


Fig. 1.

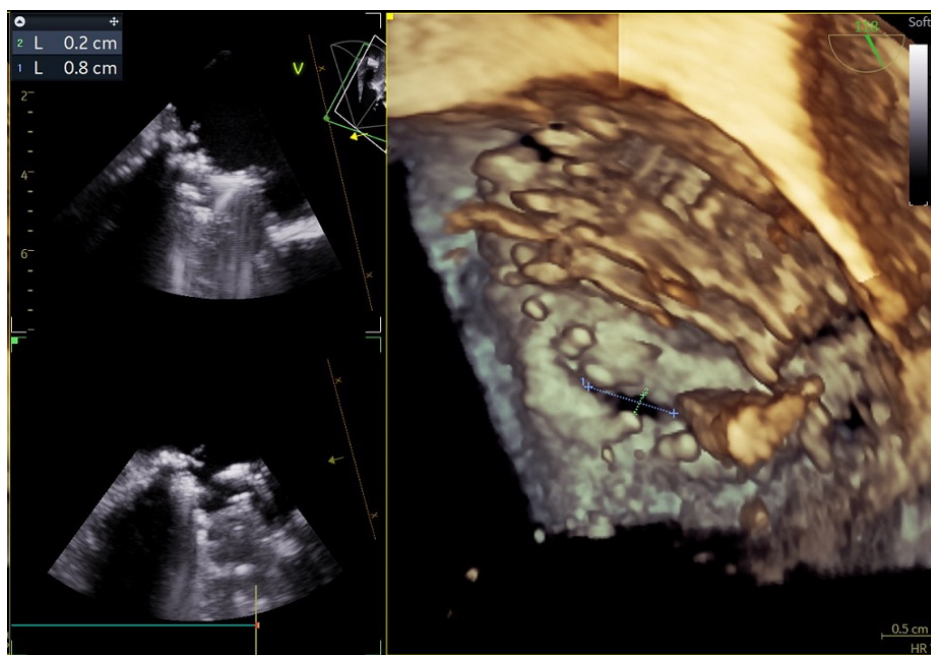


Fig. 2.

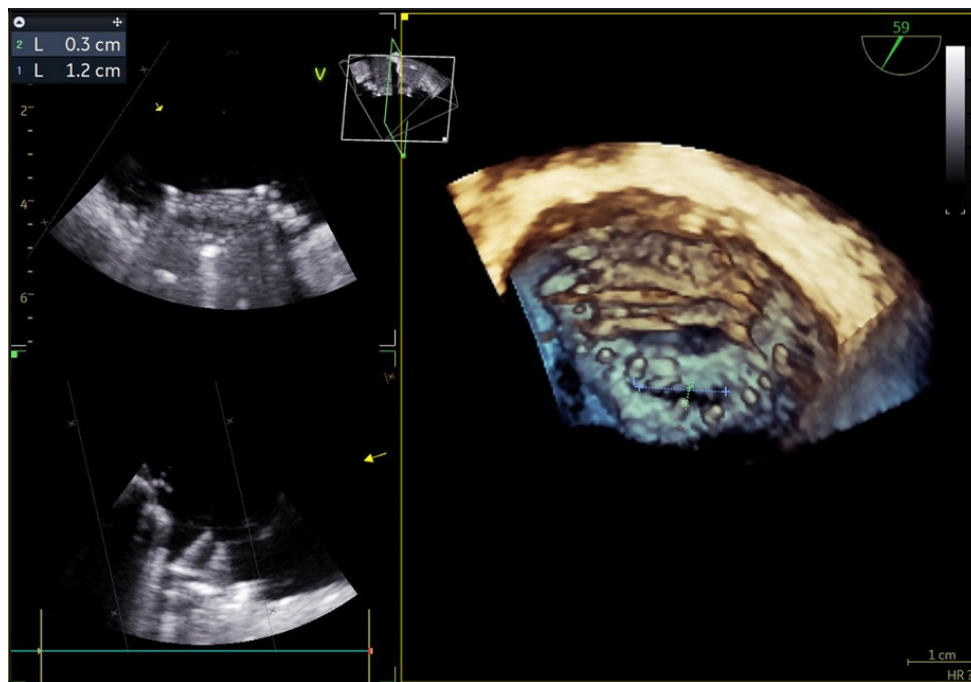


Fig. 3.

OP-34.

Effective Management of Cardiac Arrest with ST-Elevation Myocardial Infarction and Severe Aortic Stenosis Patient: A Multidisciplinary Approach

Fatma Esin, Yalım Çetin

Department of Cardiology, İzmir Katip Çelebi University, Atatürk Training and Research Hospital, İzmir, Türkiye

Introduction: The simultaneous occurrence of ST-elevation myocardial infarction (STEMI) and severe aortic stenosis (AS) in elderly patients presenting with cardiac arrest represents a critical management challenge. This case report delineates the successful intervention strategies employed in the face of such complex, concurrent pathologies. It underscores the importance of a coordinated, multidisciplinary approach that integrates timely diagnostics, therapeutic decision-making, and advanced interventional techniques to optimize patient outcomes in acute, high-risk clinical settings.

Case: A 69-year-old female with a history of hypertension presented to our clinic with symptoms of exertional chest pain, shortness of breath, dizziness, and palpitations. Transthoracic echocardiographic (TTE) assessment revealed left ventricular hypertrophy (LVH), mild mitral regurgitation (MR), moderate tricuspid regurgitation (TR), and a systolic pulmonary artery pressure of 45 mmHg. Additionally, she had a left ventricular ejection fraction (LVEF) of 60%, severe aortic stenosis with a peak gradient (PG) of 90 mmHg, a mean gradient (MG) of 55 mmHg, alongside moderate aortic regurgitation (AR). Coronary angiography (CAG) diagnosed an 80% stenotic lesion in the mid-left anterior descending (LAD) artery (Fig. 1A-C). Considering the severity of AS, the heart team recommended surgical aortic valve replacement (AVR) and coronary artery bypass grafting (CABG); however, the patient declined the surgical intervention and opted for discharge against medical advice. One month later, she was emergently readmitted with an inferior ST-elevation myocardial infarction (STEMI) and concomitant hypotension. Repeat CAG showed a persistent 80% lesion in the mid-LAD (Fig. 1D). The circumflex artery (CX) was patent (Fig. 1E) and the right coronary artery (RCA) was non-dominant but also patent (Fig. 1F). Following a cardiac arrest with successful resuscitation, the patient was intubated and received a temporary pacemaker. Severe AS was deemed the culprit for her hemodynamic instability and ST elevation. Aortic valve predilatations were performed with 18×40 mm and 22×40 mm balloons, reducing the MG from 90 mmHg to 35 mmHg. Post-extubation, the patient's hemodynamics and mental status improved. After one week, a control CAG was conducted, and a 3.5×24 mm DES was implanted in the LAD. Subsequently, a size 25 transcatheter aortic valve implantation (TAVI) was successfully performed (Fig 1G-K). TTE post-TAVI, revealed PG of 22 mmHg and MG of 13 mmHg across aortic valve. Five days later, the patient was discharged in New York Heart Association (NYHA) class I condition.

Conclusion: This case highlights the complexities of managing elderly patients with concurrent severe AS and STEMI presenting as cardiac arrest. The heart team's initial recommendation for surgical AVR and CABG underscores the traditional approach to such complex cases. Our experience demonstrates the efficacy of integrating percutaneous valve intervention (TAVI) with coronary revascularization in managing high-risk patients, thereby providing a viable pathway to recovery and significantly improving the quality of life in these challenging scenarios.

Keywords: ST-elevation myocardial infarction, aortic stenosis, transcatheter aortic valve implantation

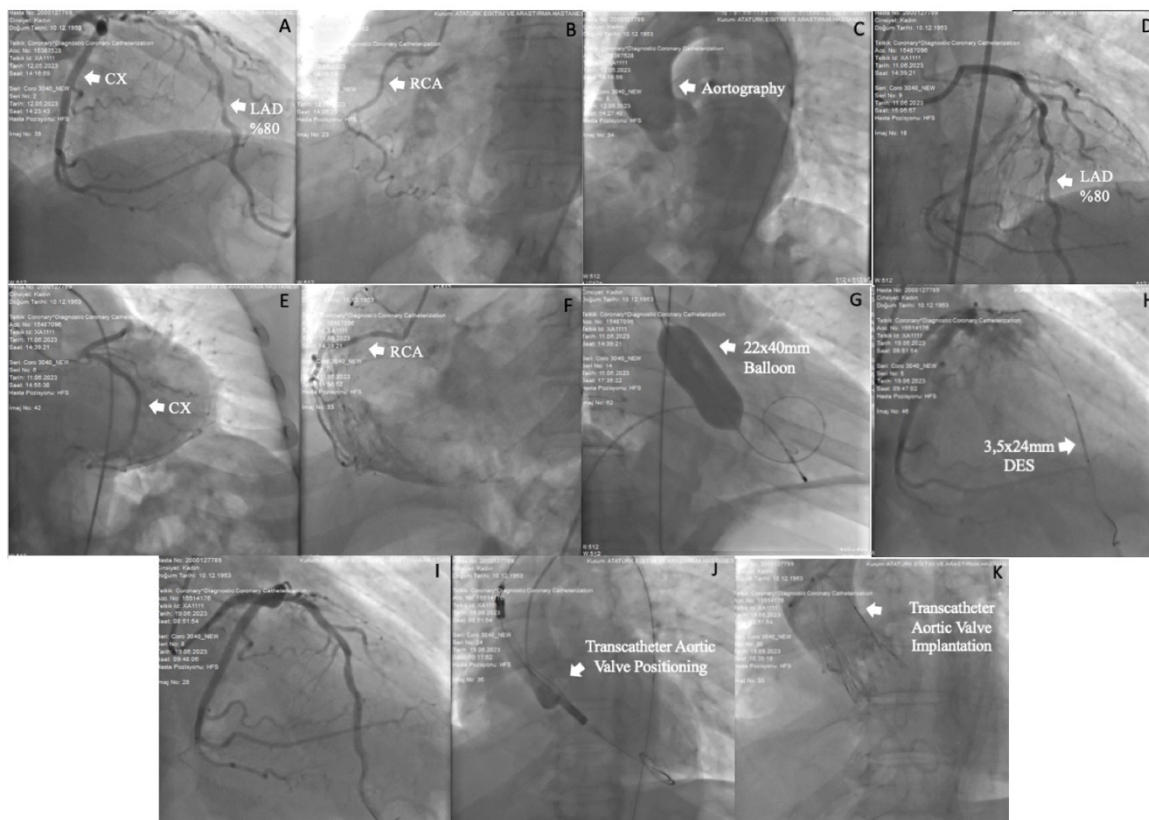


Fig. 1. Coronary arteriography (CAG) showed that LAD mid has 80% stenosis (A). RCA non-dominant, open (B). Aortography was performed due to aortic stenosis (C). CAG was performed due to inferior ST-elevation myocardial infarction (STEMI): 80% stenosis in LAD mid (D). CX open (E). RCA open (F). After CPR was performed on the arrested patient and a temporary pacemaker was placed, predilatations of the aortic valve were performed with 18-22×40 mm balloons (G). Post-extubation, the patient's hemodynamics and mental status improved, one week later, a control CAG was conducted, and a 3.5×24 mm DES was implanted in the LAD (H). Positioning of the trans-catheter aortic valve (J). A size 25 transcatheter aortic valve implantation (TAVI) was successfully performed (K).

OP-35.

[Carotid Stent Migration, a Rare Late Complication and Its Management]

Nadir Bir Geç Komplikasyon Olan Karotis Stent Migrasyonu ve Yönetimi

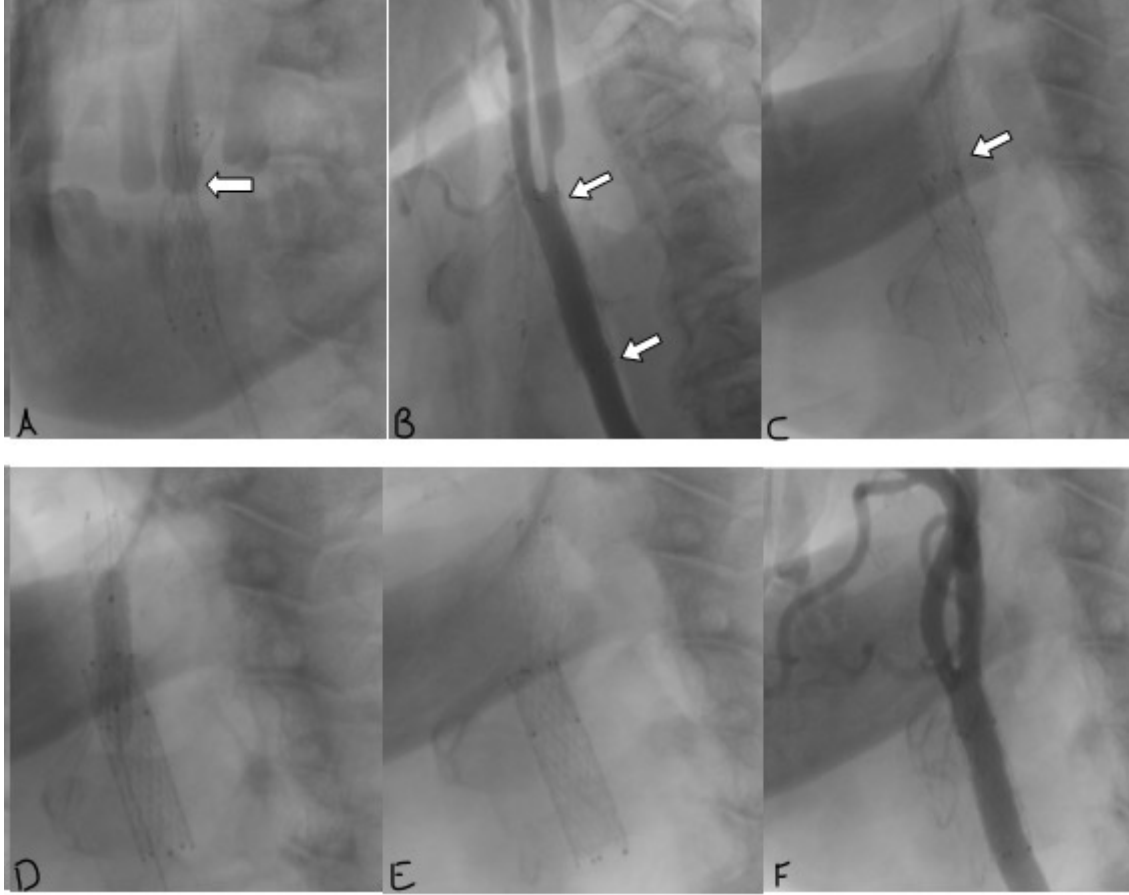
İbrahim Aktaş

Malatya Turgut Özal Üniversitesi, Tıp Fakültesi, Kardiyoloji Kliniği, Malatya, Türkiye.

Aterosklerotik karotis hastalığını tedavi etmek için kullanılan yöntemlerden biri karotis arter stentlemesidir (CAS). Bu işlemin nadir görülen kısıtlılıklarından biri stent migrasyonudur. Biz de burada karotis stent takıldıktan 1 yıl sonra, stentin aşağı doğru kaydığı nadir görülen bir vakayı sunacağız. 68 yaşında kadın hastanın sağ internal carotis arter (İCA) proksimalinde %90 kritik darlık tespit edildi. İCA proksimalinde yaklaşık 13 mm uzunluğunda %90 stenoz yapan darlığa, lezyon distalindeki İCA çapının 5,6 mm ölçülmesi ve koyulacak stentin proksimalininin yerleşeceği common carotis arter (CCA) distal çapının 6,7 mm ölçülmesi üzerine 7.0×30 mm self-expandable stent koyulma kararı alındı. Distal ucu kritik darlığı kapsayacak şekilde İCA'ya, proksimal ucu ise CCA'ya yerleşecek şekilde stent açıldı. Lezyon bölgesinde stentin tam açılmadığı gözlemlense de olası iskemik inme riski ve akımın yeterli olması nedeniyle post-dilatasyon düşünülmedi. Şikayeti olmayan hastanın birinci yılında yapılan rutin kontrolleri sırasında karotis ultrasonda stent distalinde kritik darlık tespit edilmesi üzerine tekrar anjio planlandı. Gerçekleştirilen anjiyoda distal ucu İCA daki lezyonu kapsayacak şekilde implante edilmiş olan stentin tamamının CCA ya kaydığı ve İCA proximalinde, eski lezyonun bulunduğu aynı noktada %90 darlığın persiste ettiği gözlemlendi. Bunun üzerine 7.0-9.0×40 mm çapında self expandable tapered stent distal ucu lezyonu kapsayacak şekilde, proksimal ucu ise CCA ya kaymış eski stentin içinde olacak şekilde implante edildi. Lezyon bölgesinde %80 rezidü lezyon tespit edilmesi üzerine 6.0×20 mm çapında balon ile lezyon post-dilate edildi. Tam açıklık sağlandı ve komplikasyon izlenmedi (Şekil 1). CAS sonrası stent migrasyonu nadir görülen bir komplikasyondur. Daha önce 'watermelon-seeding effect' olarak tanımlanan özellikle balon işlemlerinde balonun sıkı bir stenoz karşısında stabil kalamaması ve daha az kısıtlandığı alana doğru kayma hareketi yapma isteği bildirilmiştir. Her ne kadar bu etki balon için tanımlansa da self expandable stentlerin de stenozun olmadığı, daha az kısıtlandığı geniş alana hareket etme potansiyeli bizim vakamız için de temel teşkil etmiş olabilir. Referans damara göre düşük size stent kullanılması da stent migrasyonu için önemli olabilecek sebeplerdendir. Bir başka olası risk faktörü ise kalsifiye tıkanıklıkların üzerine kısa stent implantasyonu olabilir. Bu durumda stent kısa olduğundan proksimal segmentte stentin kaymaması için yeterli damar duvarı desteği sağlanamamış olur. Özellikle bizim vakamızda da olduğu gibi varsayımsal olarak stent sonrası tam açılmayan lezyonlara uygulanacak balon anjioplasti, stent sirtatlarının kalsifiye plaklara çapalayarak stabilize olmasına yardımcı olacak ve darlık seviyesini azaltarak stente uygulanacak radyal gücün o noktada azalmasına sebebiyet verecek. Ayrıca stent/damar çapı oranının distal uçta daha fazla olması distal uçta daha fazla bir radyal kuvvet oluşmasına neden olur. Tapered olmayan stentlerde bu oran ve dolayısıyla radyal kuvvet özellikle CCA bölümüne denk gelen stent proksimalinde daha az olduğundan stentin kayarak aşağı doğru hareketine neden olabilir. Stent migrasyonunu birinci yılında tespit etmiş olsak da stentin yerleştirildikten birkaç hafta sonra endotelize olup migrasyonun zorlaşacağı göz önüne alındığında, stent

migrasyonlarının takıldıktan sonraki ilk günlerde gerçekleştiğine inanmak makul görünmektedir. Bu tür self-expandable stentlerin hangi sebeplerle kaydığına iyi anlaşılması, nadir de olsa günümüzde sık uygulanan CAS işlemlerinde önemli bir komplikasyon olan stent migrasyonundan korunma konusunda önemlidir. Endotelizasyon dolayısıyla ilk günlerde gerçekleşmesi daha muhtemel görünen migrasyonun özellikle ilk haftalarda tetkik edilmesi uygun olacaktır.

Anahtar Kelimeler: Karotis arter hastalığı, karotis stentleme, stent migrasyonu



Şekil 1. (A) Karotis stentin ilk yerleştirildiği lezyonu kapsadığı görülüyor. (B) Stentin CCA ya kaydığı ve lezyonun tekrar belirtildiği görülüyor. (C) Yeni yerleştirilen stentin tam açılmadığı görülüyor. (D) Stent sonrası balon işlemi. (E) Her iki stentin iç içe geçip lezyonu kapsadığı ve tam açıldığı izleniyor. (F) Final görüntü.

OP-36.

Treatment of Total Ocluded RCA Because of Stent Detachment with Subintimal Crossing]

Seray Yazgan, Enes İsmet Erkoç, Hüseyin Akdoğan, Doğan Ormanlı, Ömer Faruk Kahraman, Bilal Mete Ülker, Esra Akpınar, Ayşe Dilara Balyımeç, Ahmet Fatih Kışpınar, Abdulsamet Arslan, Mehmet Taşçı, Muhammed Nusret Akın, Erhan Tenekecioğlu, Hasan Arı

Department of Cardiology, University of Health Sciences, Bursa Yüksek İhtisas Training and Research Hospital, Bursa, Türkiye

Case: A 50-year-old male patient was admitted to the emergency department with chest pain. The patient, with hypertension, hyperlipidemia and 30 pack-year smoking history, had a RCA-stent implanted 5 years ago (Fig. 1). The patient ECG was shown ST-elevation on anterior derivation. Patient taken into primary percutaneous coronary intervention (PCI) procedure. Successful primary PCI performed to LAD. Elective percutaneous intervention was recommended for 90-99% CX and 70-90% proximal RCA lesions (Fig. 2). Transthoracic echocardiography showed, EF was 25%, the apex is akinetic. For RCA-PCI the patient was took to angiography laboratory. Right-guiding-catheter was engaged the RCA than the lesion was crossed with a 0.14 choice-floppy-guidewire (Fig. 3). An attempt was performed to implant a 2.75×24 mm Drug-eluting stent (DES) after a 2.5×15 mm balloon dilatation to proximal RCA-lesion (Fig. 4). As a result of the stent balloon bursting while being inflated, it was observed that the stent remained in the vessel in an hourglass-shape and was not fully deployed (Fig. 5). Later, an attempt was performed to withdraw the balloon of the stent, which not be fully inflated, but in the meantime, deformation occurred in the proximal part of the stent, then the RCA was fully occluded. The patient chest-pain was started. The RCA was cannulated again with right-guiding-catheter but when it could not crossed from total occluded RCA to the distal end (Fig. 6), AL-1 guiding catheter was taken and a microcatheter was sent through it for pass to the distal end of RCA. However, the occlusion could not crossed with soft wires (Fig. 7). Afterwards, the true lumen was reached distally from the subintimal area next to the deformed stent with Hornet 14 through the microcatheter. The microcatheter was advanced into the distal (Fig. 8). Hornet-14 has been replaced by 0.14 choice-floppy. Afterwards, sequential predilatation was performed with 1.0×10 mm, 1.5×10 mm and a 2.0×20 mm balloons (Fig. 9). Then, 3.5×28 mm DES was placed to crush the deformed stent (Fig. 10) to open the occluded RCA. TIMI-3 flow was achieved in the RCA (Figs. 11 and 12).

Discussion: When the occluded vessel cannot be opened by passing through the stent that is not fully opened due to the bursting of the stent balloon and is deformed while the bursted balloon was taking back, opening the vessel by passing through the subintimal area next to the deformed stent is one of the life-saving applications in emergency situations. When evaluating the treatment strategies to be applied in case of stent balloon rupture, one of the most important points is whether the stent is still on the guide wire. For this reason, in cases where the stent is stripped, the guide wire should not be withdrawn if possible and the stent should be gradually inflated and implanted with balloons sent over this guide wire if it is in the appropriate position. If the stent is stripped when it isn't in the appropriate position it can be captured with a microsnares or taken out with entwined guidewires. If it cannot removed, it can fixed by crushing with another stent at the point where it was stripped, in the presence of an appropriate anatomical position. In cases where the stent was completely deformed and completely occluded the vessel, subintimal passage may be required to fix the stent by crushing and open the vessel.

Keywords: Total RCA occlusion, PCI, stent detachment

OP-37.

A Case of Pericardial Effusion with Atypical Presentation

Ömer Faruk Kahraman, Mehmet Taşci, Mehmetcan Çılğın, Enes İsmet Erkoç, Hasan Arı

Department of Cardiology, University of Health Sciences, Bursa Yüksek İhtisas Training and Research Hospital, Bursa, Türkiye

Introduction: Pericardial effusion is a clinical condition that can be seen secondary to many etiologies. While it may be mild, it can also cause life-threatening complications such as cardiac tamponade.

Case: A 64-year-old male patient applied to us with complaints of fatigue, dyspnea and orthopnea. In the echocardiographic examination, it was determined that he had serious pericardial effusion. The patient, who had clinical findings compatible with cardiac tamponade, was admitted to the intensive care unit and pericardiocentesis was performed urgently. Samples of pericardial effusion fluid were taken and sent to the laboratory for necessary examinations. When the patient was questioned because the fluid was found to be exudative with a chylous appearance, it was learned that the patient was using a nutritional supplement containing turmeric. When the wavelengths of the base mixture obtained from turmeric extract and pericardial effusion were compared with the spectrophotometer device, they were found to have similar wavelengths.

Conclusion: Recently, the use of herbal medicines and food supplements has increased, and in case of a pericardial fluid with such different characteristics, patients should be questioned in detail about the substance or medication they use. This may be a guide to elucidate the etiology of pericardial effusion in patients.

Keywords: Pericardial effusion, echocardiographic examination, etiology, atypical presentation

OP-38.**[Percutaneous Treatment of Pseudoaneurysm with Graft Stent after Intervention of the Left Main Coronary Artery****Soner Aksüyek, Hasan Arı, Tahsin Bozat***Department of Cardiology, University of Health Sciences, Bursa Yüksek İhtisas Training and Research Hospital, Bursa, Türkiye*

Pseudoaneurysms are extremely rare and usually iatrogenic. They may be present with recurrent angina, as they may be asymptomatic. It is extremely important to diagnose and intervene because the rupture of pseudoaneurysm can be mortal. 77 years old, male patient with hypertension, type 2 diabetes mellitus and diagnosis of coronary artery disease (2018 LAD stent) applied to the emergency room with typical angina complaints. The electrocardiography taken by the patient, whose physical examination was natural, was seen in T negativity in anterior depressions. There was a slight increase in normal, troponin levels of urea creatinine in the patient's laboratory (49, 95 ng/L). In the coronary angiography of the patient, 90-99 lesions before the old LAD stent (Fig. 1), Cx plates and RCA were normal. 4.0×32 mm DES implanted 6.0×8 mm POT was applied with NC balloon (Fig. 2). It was taken back to the hemodynamics laboratory after detecting anterior ST changes in the ECG of the patient with chest pain again during the coronary intensive care follow-up. IVUS (Fig. 3) was performed on monitoring self-limiting extravasation (Fig. 4) at the LAD site in control angiography. Removed from the table for 3-dimensional coronary CT angiography for further evaluation (Fig. 5). The appearance of pseudoaneurysm in the tomography was taken back to the laboratory to intervene in the percutaneous route. LAD proximal 4.0×15 mm graft-coated stent implanted (Fig. 6). It was seen that there was no extravasation and the processing was terminated. On the absence of a shortage in the follow-up of the patient was discharged on the 5th day of his stay, it should be noted that the maneuvers of the wires and catheters used during the coronary intervention are suitable for the size of the balloon or stent vein to be applied. Because when we look at the literature, in most cases, large-sized balloons or stents appeared after percutaneous interventions due to arterial wall injury due to high-pressure balloon dilatation, coronary atherectomy or laser angioplasty. According to the size of pseudoaneurysm and the hemodynamics of the patient, it can be left to spontaneous resistance, as well as to be percutaneous closed by coil embolization or graft stent. Aneurysms that cannot be closed by percutaneous route may be surgically resected or coronary artery bypass grafted. The end of the procedure should be taken from different angles, in case of doubt, the patient should wait for a while at the angiography table and the procedure should be terminated after the control angiography images are taken. IVUS, OCT and multi-section CT angiography are diagnostic methods that can be used. Graft-coated stents should be considered to cause restenosis risk and lateral loss.

Keywords: Left main coronary artery disease, stenting, pseudoaneurysm, graft-coated stents

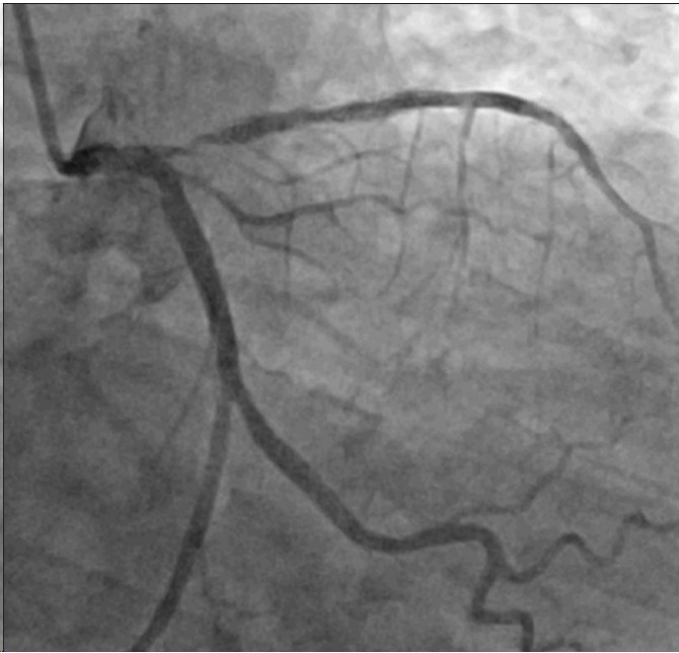

Fig. 1.

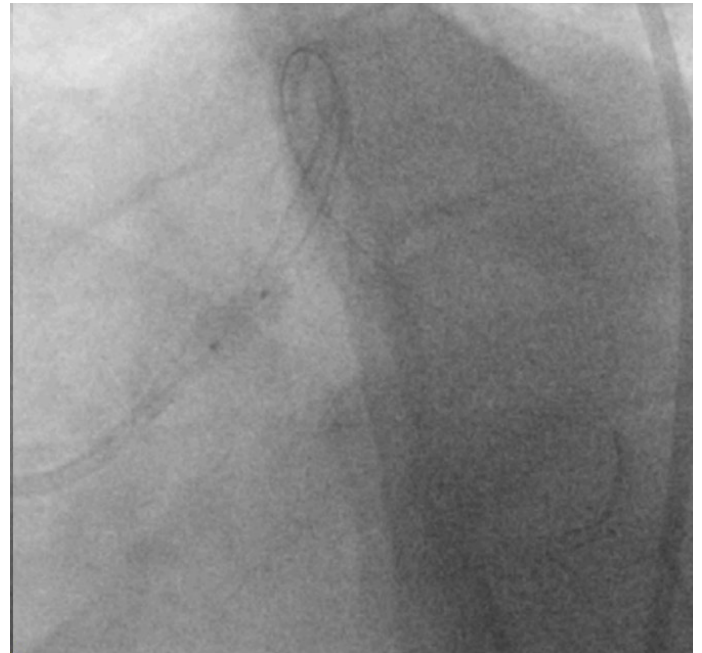

Fig. 2.

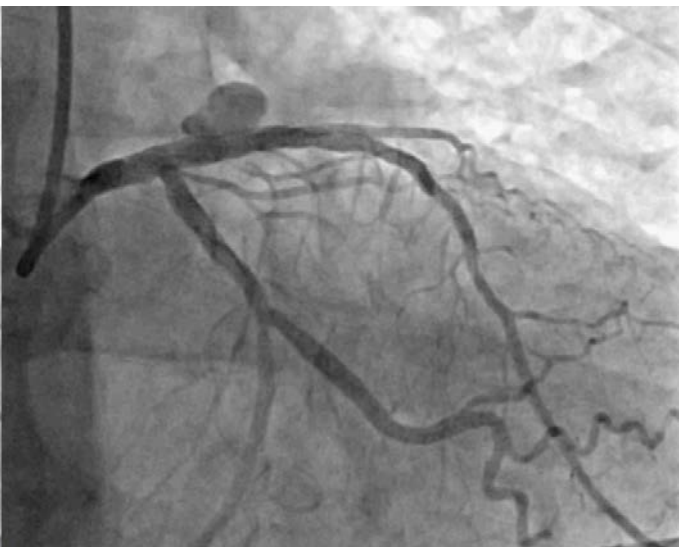

Fig. 3.

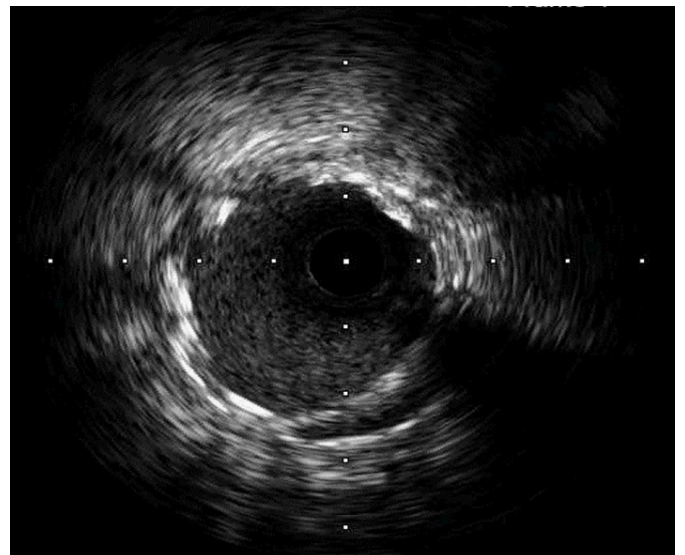


Fig. 4.

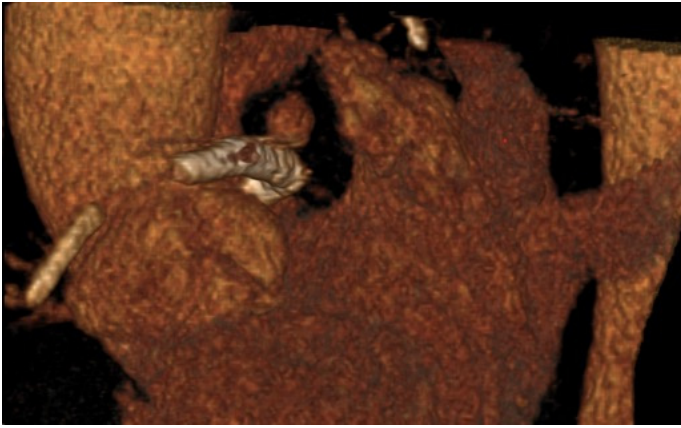


Fig. 5.

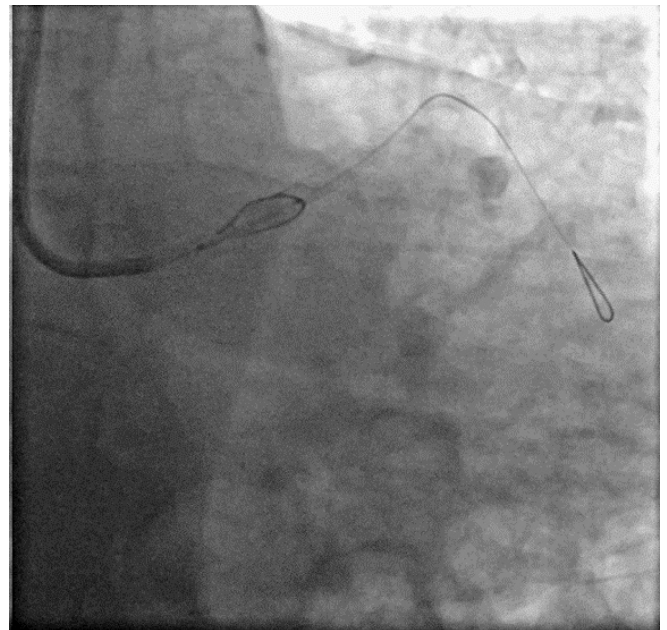


Fig. 6.

OP-39.**A Rare Cause of Aortic Interruption: Mid Aortic Syndrome****Esra Akpınar, Ayşe Dilara Balyımez, Bilal Mete Ülker, Ömer Faruk Kahraman, Soner Aksüyek, Fatih Koca, Mehmet Taşci, Hasan Arı***Department of Cardiology, University of Health Sciences, Bursa Yüksek İhtisas Training and Research Hospital, Bursa, Turkey*

Case: A 32-year-old male patient presented to the cardiology clinic with complaints of dyspnea persisting for one month and swelling in the legs. The patient has a history of smoking 10 packs/year, methamphetamine use two years ago, and hypertension for the past 10 years. Physical examination revealed bilateral rales at the lung bases, diastolic murmur on aortic region, and pretibial edema +/+ (Fig. 1) Laboratory values showed a BNP of 247 pg/mL, with no pathology detected in other routine laboratory tests. Transthoracic echocardiography revealed an ejection fraction of 25%, moderate to severe aortic regurgitation, and the ascending aorta diameter 6.3 cm (Fig. 2). Total occlusion at the abdominal aorta level was detected during coronary angiography via the right femoral artery (Fig. 3), and the procedure continued using the radial route. There was a plaque in the LAD; CX and RCA were normal. Multislice CT angiography, performed for further investigation, showed total occlusion of the abdominal aorta from the mid-level and distal flow provided through collaterals (Figs. 4, 5, 6 and 7). Transesophageal echocardiography revealed severe aortic insufficiency and an ascending aortic aneurysm. The patient, without complaints such as claudication, erectile dysfunction, or abdominal pain, and with blood pressure controlled by medical treatment, and normal ABI was evaluated by the cardiology-cardiovascular surgery council. The council decision was planned for medical follow-up for the periphery and Benthall operation was considered for the ascending aortic aneurysm and aortic regurgitation. The patient underwent a successful operation with the placement of a metallic aortic valve conduit graft (No. 27/30) and was discharged with no complications on follow-up.

Discussion: Mid Aortic Syndrome is a rare condition characterized by segmental or diffuse narrowing of the abdominal and/or descending aorta, often presenting with hypertension in childhood, accompanied by varying degrees of involvement of renal and visceral arteries. Published series related to children with renovascular hypertension report variable MAS incidence, ranging from 2% in Turkey to 12% in the United States. MAS, usually idiopathic, can also occur in genetic and some acquired disorders such as neurofibromatosis type I, Williams syndrome, Alagille syndrome, tuberous sclerosis, and mucopolysaccharidoses. Symptoms related to the affected organs and systems may vary depending on the location and severity of the narrowings. Medical methods are generally insufficient in the treatment of MAS, and endovascular and surgical interventions are the primary treatment modalities. Endovascular interventions such as balloon angioplasty and stenting may be considered in children to avoid surgical intervention on the aorta. Surgical interventions include aorto-aortic bypass grafting, graft vessel replacement, and patch angioplasty. Although various surgical procedures have been developed, the evidence level is low due to the limited number of multicenter studies and cases. A multidisciplinary approach and regular follow-up are crucial for monitoring signs of uncontrolled hypertension and end-organ damage in MAS. In summary, MAS should be considered in the etiological investigation of hypertension cases detected at a young age. In this case, we summarized the interesting association and management of a middle aortic syndrome case, which is typically accompanied by aortic stenosis, but this instance, presented with anuloaortic ectasia.

Keywords: Mid aortic syndrome, aortic interruption, surgical intervention

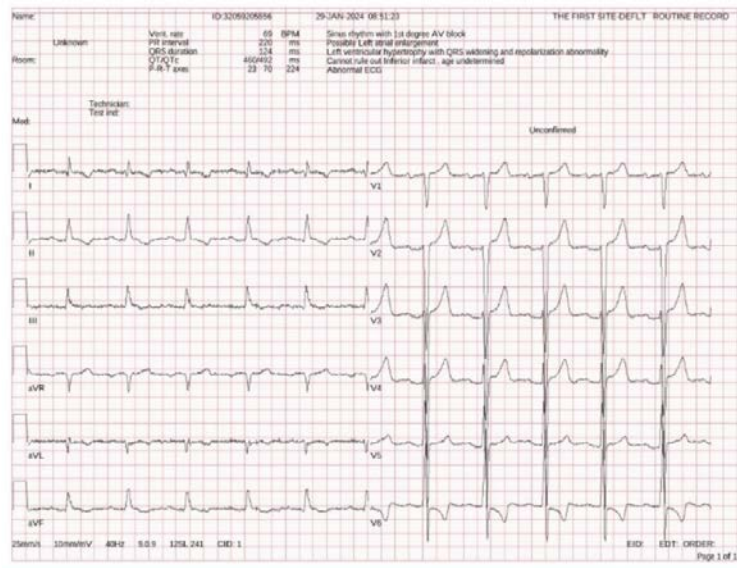


Fig. 1

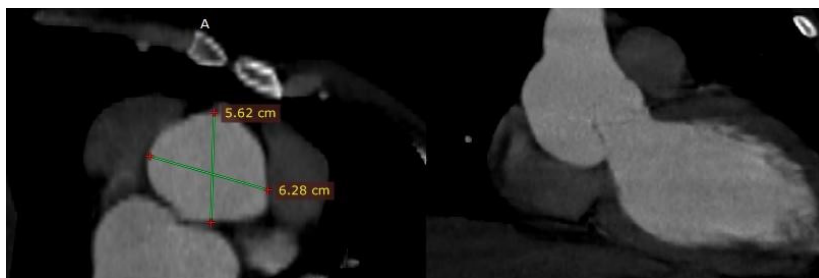


Fig. 2

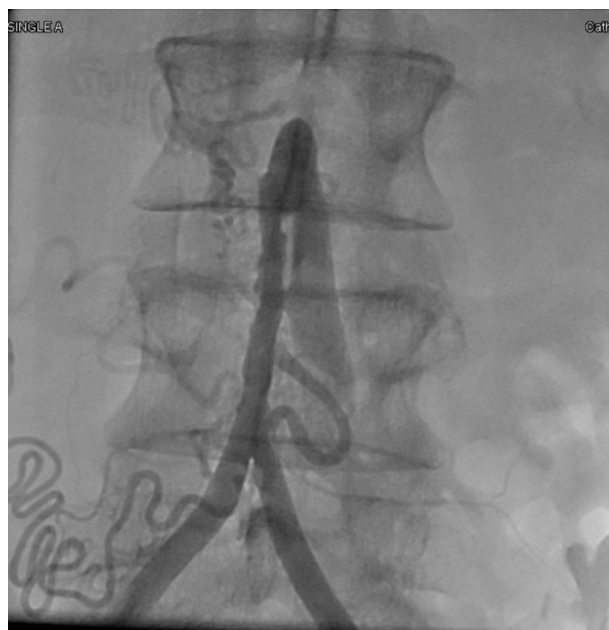

Fig. 3

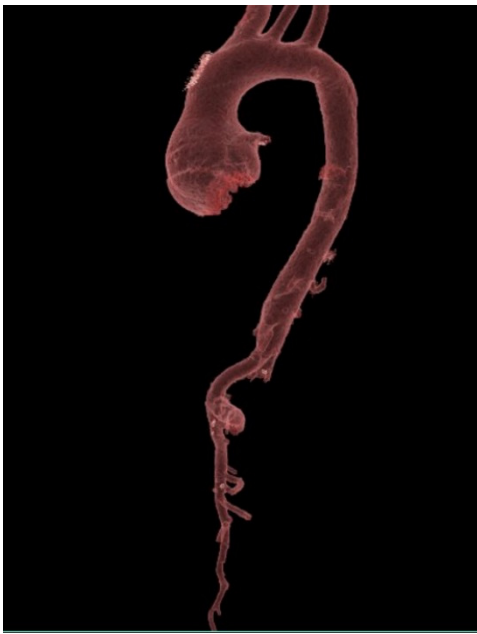

Fig. 4

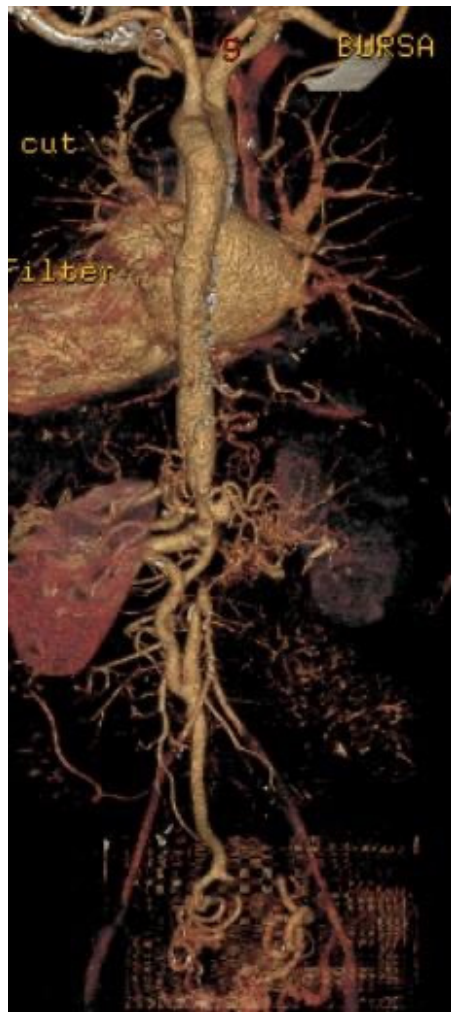

Fig. 5

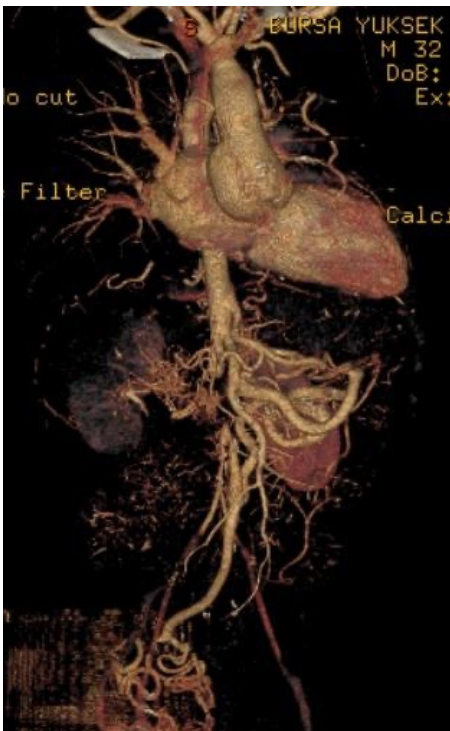

Fig. 6

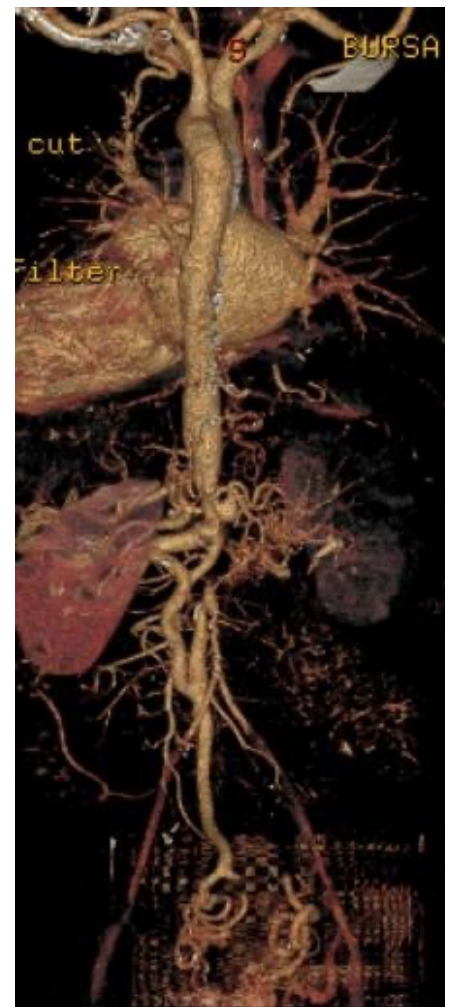


Fig. 7

OP-40.

Radial Artery Perforation and Its Treatment during Percutaneous Coronary Intervention

Ayşe Dilara Balyımez, Bilal Mete Ülker, Esra Akpınar, Seray Yazgan, Mustafa Gözcü, Mehmetcan Çılğın, Hasan Arı, Tahsin Bozat

Department of Cardiology, University of Health Sciences, Bursa Yüksek İhtisas Training and Research Hospital, Bursa, Turkey

Case: A 59-year-old female patient presented to the cardiology clinic with a complaint of typical anginal pain that has been occurring with exertion for the past 5-6 months and relieved by rest. The patient has a history of hypertension, diabetes, and peripheral artery disease. Coronary and peripheral angiography were planned for the patient. Laboratory tests did not reveal any significant pathology. Echocardiography showed an ejection fraction of 65% with no significant valve pathology. Coronary angiography revealed lesions of LAD 50%, CX 40%, RCA 80%, and peripheral angiography showed abdominal aorta 90%, bilateral iliac arteries 90%. The decision was made to intervene first on the coronary vessels and then on the peripheral vessels. The patient underwent catheterization, and a 6F sheath was placed in the left radial artery. It was observed that the 0.038-inch guide wire did not advance through the radial artery. Subsequent imaging revealed extravasation in the left radial artery (Fig. 1). The extravasation was crossed with a 0.014 choise floppy guidewire, 6F right guiding chateter was advanced over the 0.014 guidewire with inflating 2.0×15mm balloon tip of the guiding chateter (balloon assisted tecnique) to ascendan aorta (Fig. 2). Than the RCA lesion treated with 2.5×32 mm drug-eluting stent (DES). (Fig. 3) After that, left radial artery was checked, the extravasation was going on (Fig. 4). Than 2.5×150 mm peripheral balloon was advanced the extravasation segment over the 0.014 guide wire and inflated up to 6 Atm for 10 minutes, (Fig. 5) during this time an elastic bandage was wrapped over the arm for external mechanical compression. Ten minutes later the balloon occlusion, it was observed that the extravasation had closed (Fig. 6). During the patient's follow-up, there were no hematoma and symptom. With stable general condition and no decrease in hemoglobin levels, the patient was discharged with medical treatment.

Discussion: Transradial intervention is a popular alternative to traditional femoral artery intervention in the diagnosis and treatment of coronary artery disease. Studies such as RIVAL, RIFLE-STEACS, STEMI-Radial, and MATRIX have shown it to be safe and beneficial. Radial artery perforation (RAP) is a rare complication of transradial intervention that can lead to forearm hematoma. Early diagnosis of RAP is crucial for preventing compartment syndrome. In suspected cases, radial angiography should be performed before and after the procedure. After detecting radial perforation, balloon support can be used to advance the guidewire. The guidewire allows the completion of coronary intervention by tamponading the radial artery perforation. This method is often sufficient for closing the perforation at the end of the procedure. Placement of extra-long sheaths extending to the brachial artery has also been described. Simultaneous compression with a manual blood pressure cuff may assist in achieving hemostasis. If these methods do not stop the contrast leakage, a graft stent can be placed along the perforation. In the presented case, a successful intervention was performed on the perforated radial artery.

Keywords: Percutaneous coronary intervention, radial artery, perforation, mechanical compression

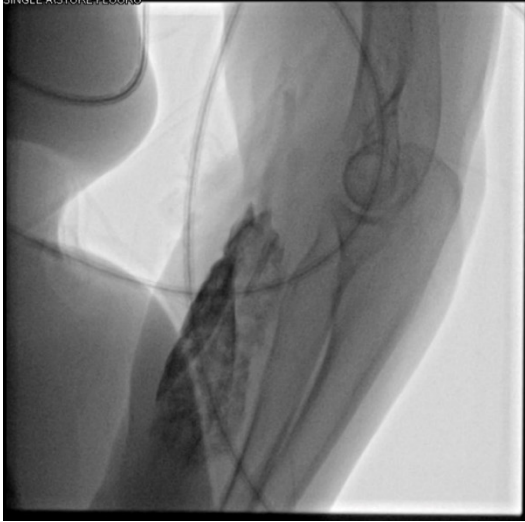

Fig. 1.

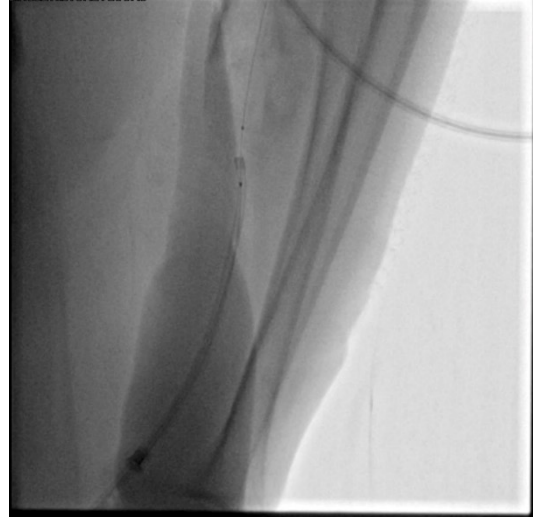

Fig. 2. Balloon assisted

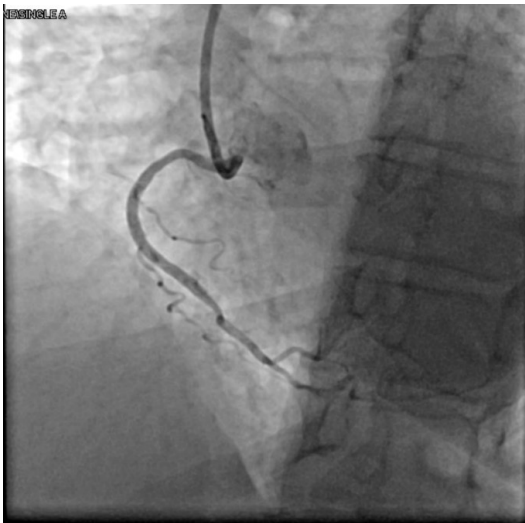


Fig. 3. RCA stent.

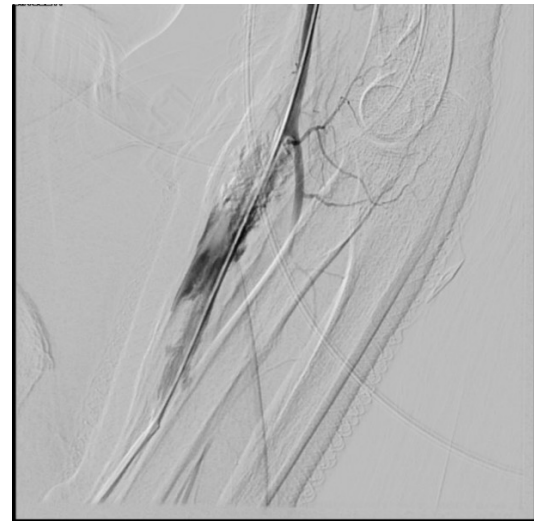


Fig. 3. Extravasation.

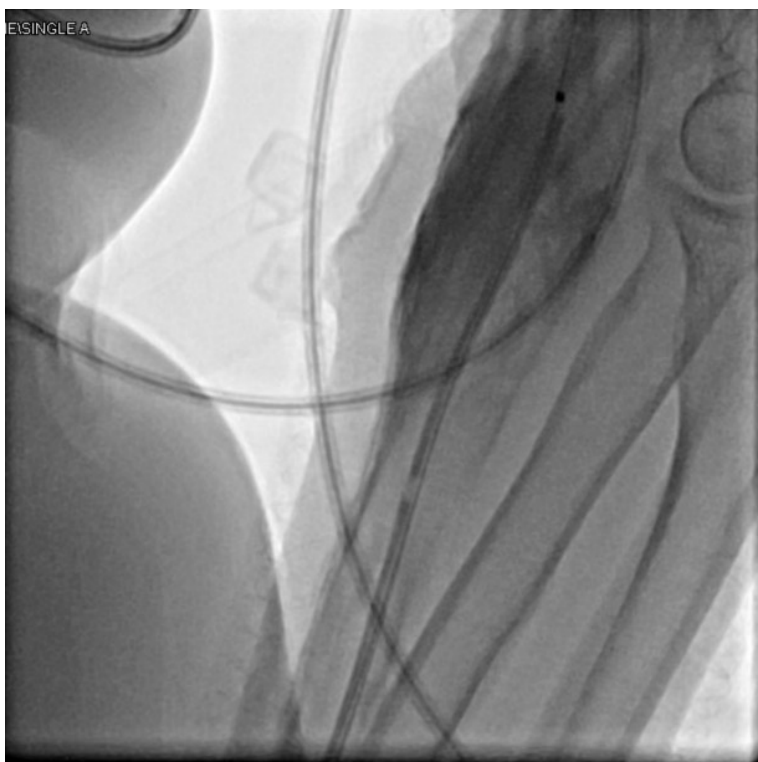

Fig. 5. 2.5×150 mm peripheric balloon.

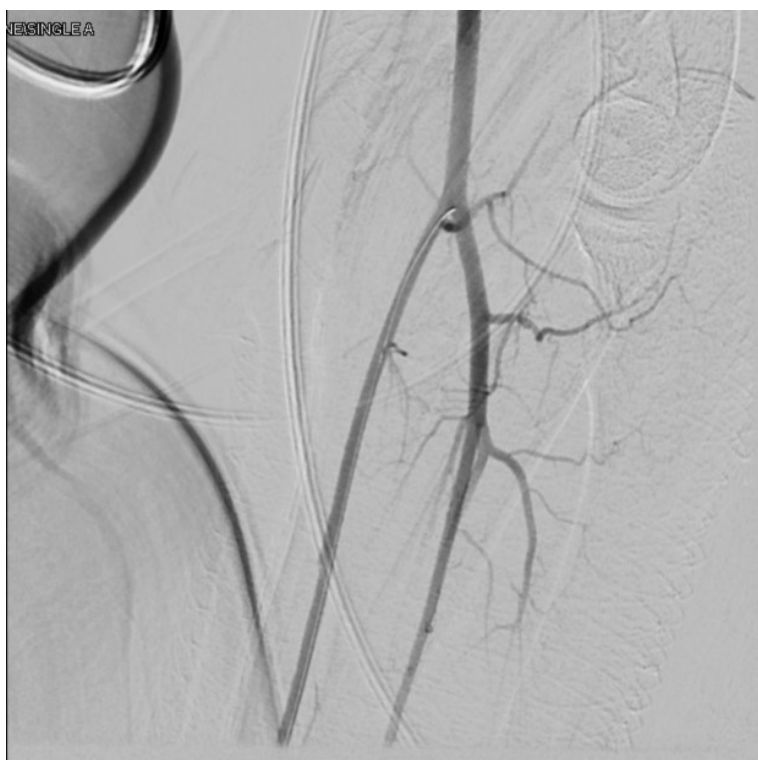

Fig. 6. After 10 min occlusion.

OP-41.

Transcatheter Closure of Atrial Septal Defect in Patients with Coronary Anomaly

Ahmet Fatih Kışpınar, Ayşe Dilara Balyemez, Bilal Mete Ülker, Esra Akpınar, Doğan Ormanlı, Soner Aksüyek, Mehmet Taşci, Abdülsamet Arslan, Mustafa Kani Gözcü, Davut Davutoğlu, Ömer Furkan Demir, Selma Arı, Mehmet Melek, Fahriye Vatanserver Ağca, Hasan Arı

Department of Cardiology, University of Health Sciences, Bursa Yüksek İhtisas Training and Research Hospital, Bursa, Türkiye

Secundum type ASD and coronary artery anomaly together are rare congenital anomalies. For this reason, coronary artery anomaly should be ruled out before ASD closure is performed.

46-year-old woman applied with complaints of exertion dyspnea. In the physical examination, listening to the second left intercostal interval 2/6 systolic murmur was present. ECG also showed sinus rhythm and right ventricular hypertrophy. In TTE the right heart cavities were seen dilated and color flow with colored Doppler was observed in the interatrial septum. In TEE 2.4 cm secundum type ASD was observed (Fig. 1). Right heart catheterization and coronary angiography were performed. In catheterization, Qp/Qs: 2.1 and PVR: 2 Wood were detected. Coronary angiography, LMCA exits non-coronary sinus and RCA exits left coronary sinus. Multislice CT was performed to showing coronary anomaly and ASD (Fig. 2). LMCA relationship with ASD was evaluated with multislice CT (Fig. 3). In cardiology and cardiac surgery council, we decided to percutaneous closing the ASD. Successful ASD close with the 26 mm Amplatzer ASD closure device performed by TEE (Fig. 4). During the procedure abnormal originate LMCA was checked with coronary angiography (Fig. 5) and there was no coronary interaction with ASD device. No coronary interaction was seen in control multislice CT (Fig. 6).

Discussion: Congenital coronary artery anomalies are rare congenital heart malformations. Secundum type ASD is one of the most common congenital heart diseases. Percutaneous ASD closure is the first option treatment in patients with appropriate anatomy. The relationship between ASD and the abnormal coronary artery resulting from the retroaortic trajectory versus the aortic sinus can have significant clinical consequences. Because the retroaortic edge (anterior) of the defect is closely related to the aberrant artery. The ASD closing device implanted due to this association may cause coronary artery compression or deformation, resulting in myocardial ischemia, arrhythmia and sudden cardiac death. In conclusion, in patients with together secundum ASD and coronary anomaly, the decision should be made by detailed evaluation before percutaneous ASD closure.

Keywords: Coronary artery anomaly, secundum type ASD, transcatheter closure

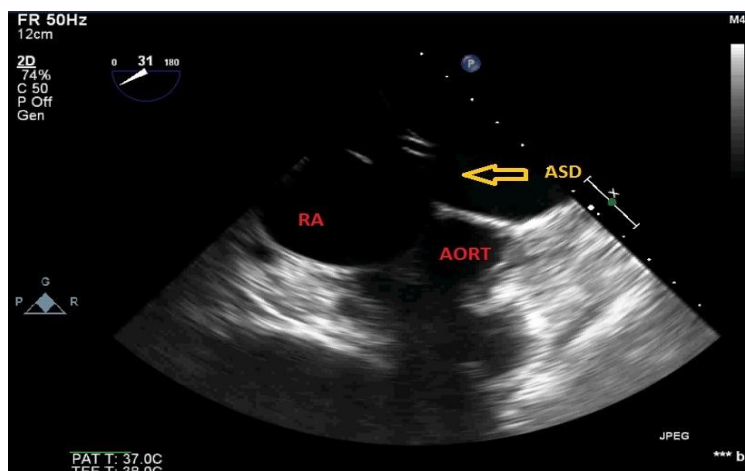


Fig. 1.

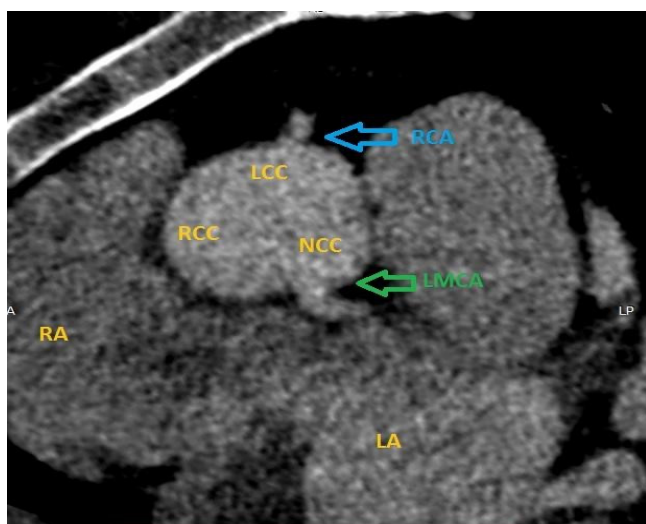


Fig. 2.

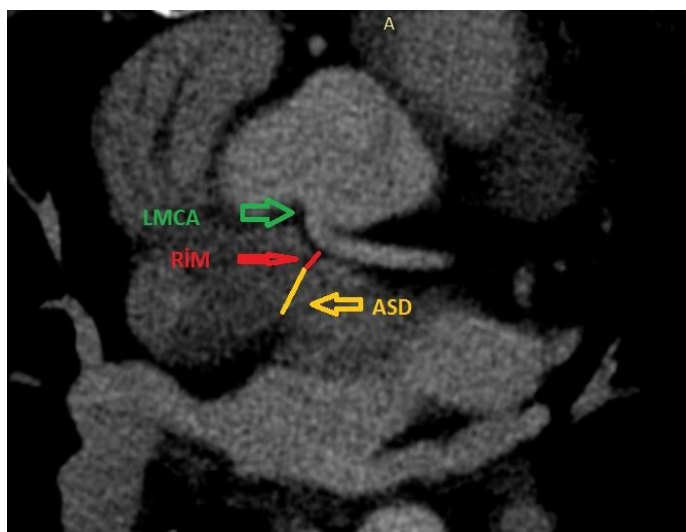


Fig. 3.

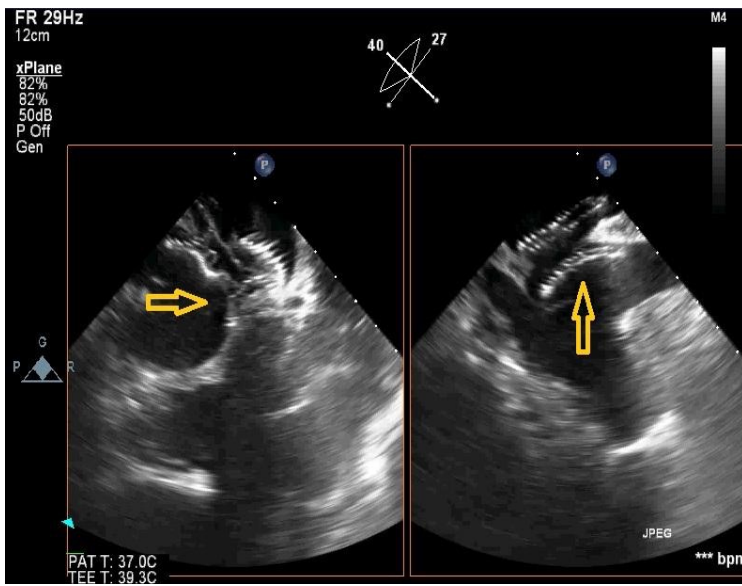


Fig. 4.

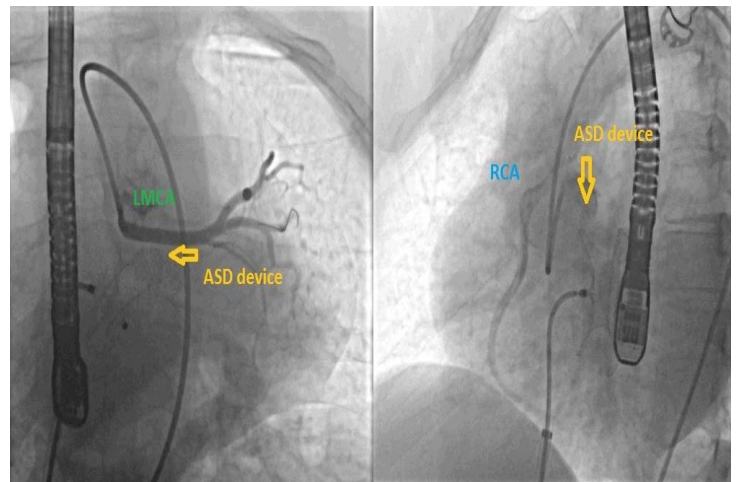


Fig. 5.

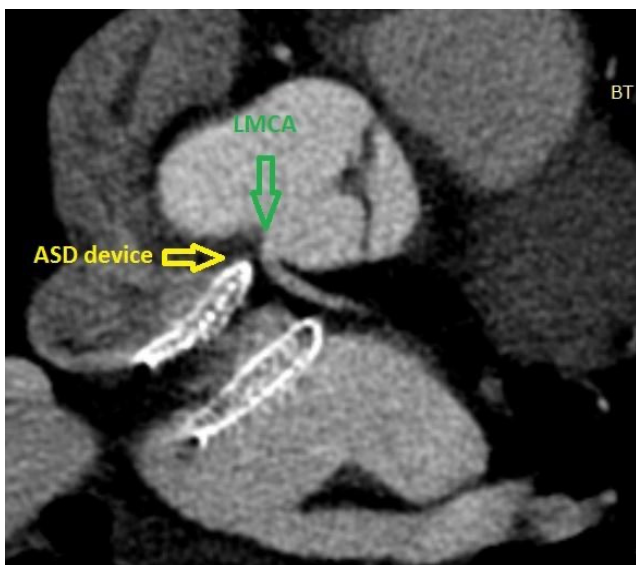


Fig. 6.