

CASE REPORT

## A case of mixed type laryngocele presented with deep neck infection and review of the literature

### *Derin boyun enfeksiyonu ile bulgu veren mikst tip laringosel olgusu ve literatür değerlendirmesi*

Salih Bakır, Aylin Gül, Vefa Kınış, Musa Özbay, Hakan Özkan

#### ABSTRACT

Laryngocele is an abnormal dilatation of the laryngeal ventricular sacculae that may extend into the subcutaneous tissues of the neck through the thyrohyoid membrane or confined to the endolarynx. The etiology is still unclear. Many laryngoceles are asymptomatic. An asymptomatic laryngocele appears and produces symptoms only as it enlarges or when it becomes infected. In this report, we present a 40-year-old female patient, which had an asymptomatic neck swelling for 20 years, referred for deep neck infection, dysphonia and dyspnea. *J Clin Exp Invest* 2012; 3 (3): 415-419

**Key words:** Larynx, laryngocele, laryngopyocele, neck mass

#### INTRODUCTION

Laryngocele, cystic dilatation of the laryngeal sacculae, is a rare benign laryngeal disease. The etiology is still unclear, but congenital and acquired factors have been implicated in its development.<sup>1</sup> Increased air pressure in the larynx (more important role) or anatomical variations such as weakness or defect in laryngeal tissues (less important role) are probably the main factors in the pathogenesis of laryngocele.<sup>1,2</sup>

Based on location, three types of laryngocele have been described. The internal, external and combined (or mixed) laryngocele.<sup>3</sup> Internal laryngocele is confined to the endolarynx (paraglottic space) medial to the thyroid cartilage and thyrohyoid membrane, and it doesn't penetrate the thyrohyoid membrane. The external laryngocele is another type of laryngocele which extends and pass through the thyrohyoid membrane via the opening for the superior laryngeal nerves and vessels and extend into the subcutaneous tissues of the neck. A com-

#### ÖZET

Laringosel, laringeal ventrikül sakkülünün hava ile anormal genişlemesi olup tirohyoid membrandan boyun cilt altı dokulara uzanabilir veya larinks içinde sınırlı kalabilir. Etiyolojisi net değildir. Laringosellerin birçoğu asemptomatiktir. Asemptomatik laringosel çok büyüdüğünde veya enfekte olduğunda belirginleşir ve semptomlar ortaya çıkar. Bu yazıda 20 yıldır boyunda asemptomatik şişliği olan, bu zamana kadar herhangi bir şikayeti olmamasına rağmen şimdi derin boyun enfeksiyonu, ses kısıklığı ve solunum sıkıntısı şikayetleri ile başvuran 40 yaşındaki bayan bir olgu sunulmuştur.

**Anahtar kelimeler:** Larinks, laringosel, laringopyosel, boyun kitlesi

combined laryngocele includes both internal and external components of the laryngocele.<sup>3</sup> Usually, laryngoceles are unilateral and combined. They may present at any age, but are most commonly seen in the 5<sup>th</sup> -6<sup>th</sup> decade.<sup>2</sup> It is more frequent in men than in women at a ratio of five to one.<sup>1</sup> Although very rare, bilateral presentation of laryngocele was reported.<sup>4,5</sup>

Symptoms may be differing according to type of laryngocele. Combined laryngoceles usually associated with a neck mass with or without laryngeal symptoms, as the case hereby presented. The symptoms of internal laryngocele include hoarseness, dyspnea, dysphagia, stridor, sore throat, snoring, cough and foreign body sensation.<sup>6-8</sup> Dyspnea varies from mild to severe according to degree of glottic obstruction.

Laryngocele is named as laryngopyocele if infected. It becomes filled with mucus, and air-fluid level or fluid filled laryngocele forms. Laryngopyoceles are more rare entities compared with laryngo-

Department of ENT & Head and Neck Surgery, Dicle University Medical College, Diyarbakir, Turkey

**Correspondence:** Salih Bakır,

Department of ENT & Head and Neck Surgery, Dicle Medical School Diyarbakir, Turkey Email: drsalihbakir@gmail.com

Received: 28.06.2012, Accepted: 26.08.2012

Copyright © JCEI / Journal of Clinical and Experimental Investigations 2012, All rights reserved

cele, approximately 10% of laryngoceles become infected.<sup>7,8</sup> Infection of a laryngocele can cause acute symptoms or worsen existing symptoms or trigger the asymptomatic condition. Herein we report a case of unilateral combined laryngocele, which was asymptomatic for 20 years.

## CASE REPORT

The patient, 45 year old female housewife, presented to our clinic with neck infection on the right side of the neck. The patient also suffered from sore throat, dysphonia, stridor, dyspnea, obstructive sleep apnea and fever over the last month. In her medical story, she had a swelling on the right side of the neck with a 20 year history but neck infection was occurred just once approximately two years ago. Following the medical treatment, she had not any complaint except smaller mass. But this time, despite the medical treatment with broad spectrum antibiotic, her complaints did not decrease significantly. She pointed that the palpable lesion in her neck had doubled in size during the infection. She did not smoke or had any disorder.

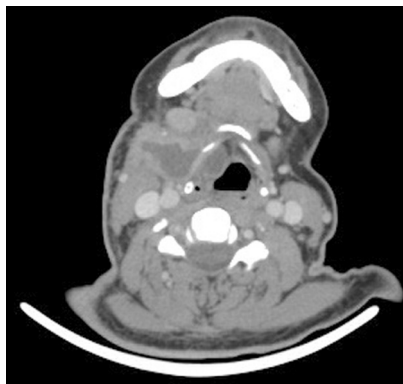
During physical exam, a soft mass covered with normal skin was palpated over the level II and III on the right side of the neck. The Valsalva maneuver produced the swelling. No pulsations could be felt and there were no vascular sounds on auscultation. Indirect laryngoscopic examination with rigid and flexible laryngoscopy revealed a bulging that partially obscured the right true vocal fold, which seemed to be enough to a comfortable airway. Any obvious signs of malignancy or pathological lymph nodes in the neck were not detected.

A laryngocele was suspected according to the physical and endoscopic examination results. Axial computed tomographic (CT) scan confirmed the diagnosis of laryngocele (Figure 1, 2). The patient had two different CT scan. One of them was performed two years ago when she had a smaller neck swelling with infection (Fig. 1). Only medical treatment was administered. The other CT scan was lately performed and revealed a lesion in the larynx and a massive extension through the thyrohyoid membrane and soft tissues of the neck (Figure 2,3).

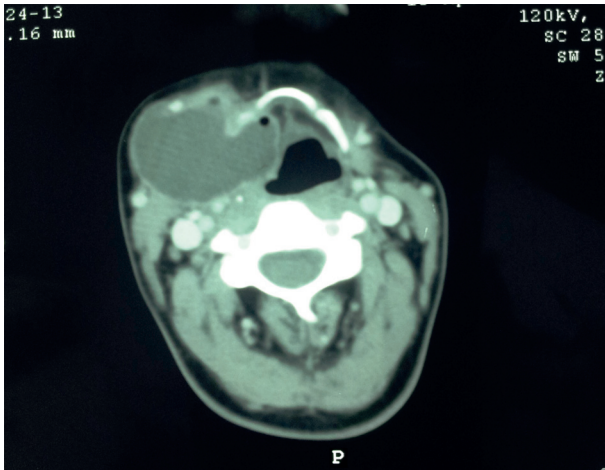
Direct laryngoscopy confirmed that a smooth swelling, originated in the right ventricle, obscured the vocal cords and the laryngeal lumen partially and caused a limited obstruction. We didn't make marsupialization. After the direct laryngoscopic examination to rule out malignancy, extirpation of the laryngocele was performed via external approach. A horizontal neck incision (6 cm) was made at the

superior aspect of the thyroid cartilage, in a skin crease. The lateral aspect of the laryngocele was defined by carefully excising the soft tissue covering on its surface, until the glistening capsule of the laryngocele was clearly identified then followed through the thyrohyoid region. At that time, the laryngopyocele was opened, a large amount of purulent material was drained. Then, the laryngocele was retracted gently as blunt dissection before proceeding with dissection of the intralaryngeal component of the laryngocele (Figure 4). This is especially important posteriorly within the thyrohyoid membrane region, where the superior laryngeal nerve branch is immediately adjacent to the laryngocele.<sup>9</sup> An inferiorly based flap was created from the outer perichondrium of the thyroid ala by incising at the superior border of the thyroid lamina and using a freer elevator for dissection. A triangular section of the thyroid ala is marked out, with its base superiorly, and its apex at a point half way along the vertical distance of the thyroid lamina.<sup>9</sup> This segment of cartilage was removed with a 15 blade (Figure 5). The inner perichondrium was then incised and removed from the triangular region, exposing the paraglottic space. The cartilage was discarded after removal. Finally, the termination of the laryngocele was identified at the base of the saccule. This corresponds with a point 3–5 mm posterior to the midline of the thyroid lamina at the midway point along its vertical height.<sup>9</sup> At the end, the laryngopyocele was excised completely. The specimen was open for evaluation of the mucosa; signs of neoplastic lesion were absent. Tracheotomy was not required.

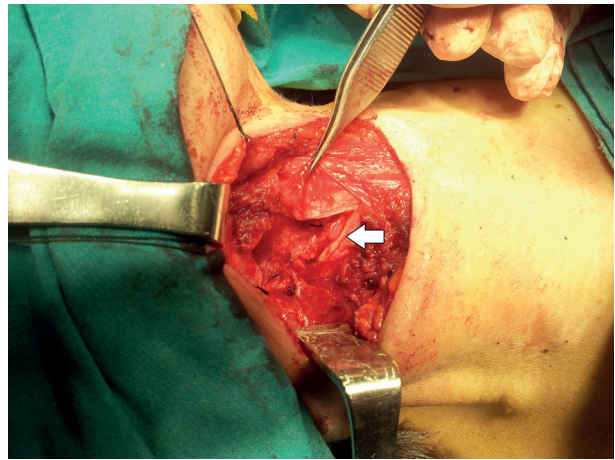
The histopathologic report confirmed the diagnosis of laryngocele. The postoperative period was uneventful and the patient was discharged 4 days after surgery. Follow-up examination was carried out at five months after surgery and she had recovered completely (Figure 6). There were no swelling or infection on the neck and bulging in the larynx.



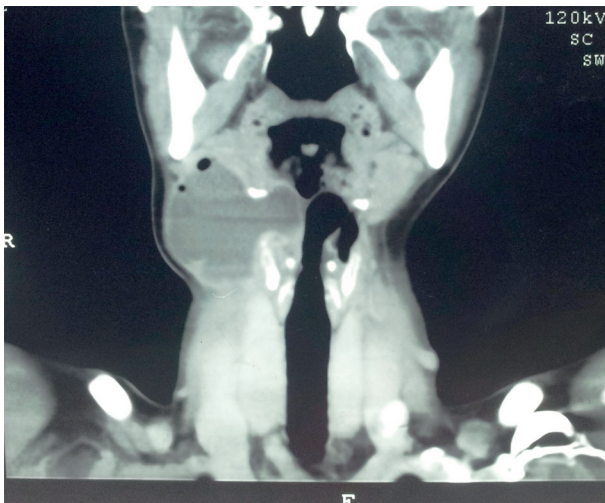**Figure 1.** Axial computed tomography image of a typical unilateral combined laryngopyocele



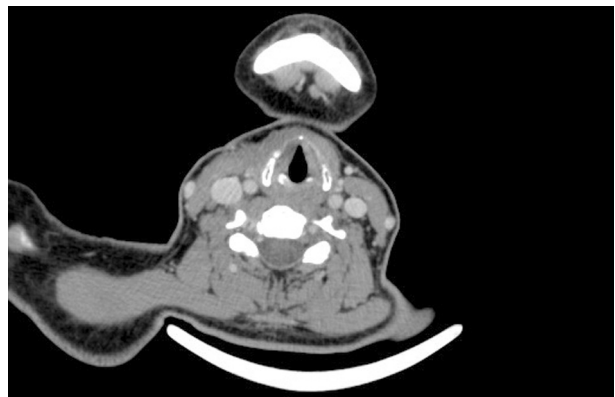
**Figure 2.** Computed tomography (CT) scan showing a giant cystic mass with an internal and external part: extended right laryngopyocele located on soft parts of neck.



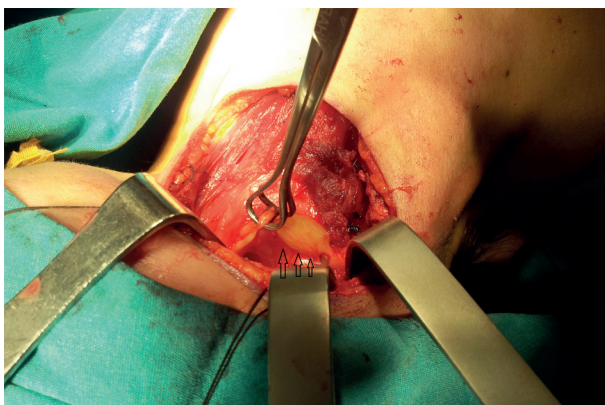
**Figure 5.** Intraoperative view after the removal of triangular section of the thyroid ala and laryngocele (arrow)



**Figure 3.** Coronal computed tomography image of a right-sided laryngopyocele



**Figure 6.** Post-operative CT revealing disappearance of laryngopyocele



**Figure 4.** Lesion removal by an external approach. Intraoperative photo of the laryngocele (arrows)

**DISCUSSION**

Prolonged periods of increased intralaryngeal pressure with presence of a congenital long saccule are the major factors at formation of laryngoceles. The congenital theory suggests that there is an abnormal growth of the saccule (long saccule) between the second and third gestational months during the normal development of the larynx.<sup>1,2</sup> This is a predisposing factor for the future development of laryngocele. There are several suggested theories resulting in enlargement of a congenitally large saccule such as increased laryngeal pressure from airway obstruction, excessive/forced coughing from chronic respiratory diseases, increased phonatory effort, phonatuary misuse and changes in laryngeal neuromuscular mechanics.<sup>2-4,10-12</sup> Sometimes, as in our patient, it may be difficult to find the etiology of acquired laryngoceles if there is not a well-known etiology such as chronic respiratory diseases (“chronic

coughers”), playing a wind instrument, glass blowing, weight lifting or after performing Valsalva manoeuvre, which they lead to increase intralaryngeal pressure.<sup>5-7</sup>

Laryngocele, especially internal type, may remain asymptomatic for a long time and most frequently, discovered incidentally during radiologic studies for other reasons or clinical suspicion in the majority of cases.<sup>4</sup> An asymptomatic laryngocele appears and produces symptoms only as it enlarges or when it becomes infected. The symptoms depend upon the type and size of the mass. The main symptoms are variable and non-specific: airway obstruction, stridor, dysphagia, hoarseness, sore throat, cough, pain, snoring or a visible or palpable mass in the lateral neck.<sup>4,6-8,13</sup> Mass is covered by normal skin and typically, soft, painless, elastic, mobile and conducts vibration during phonation. It increases in size during the Valsalva manoeuvre. Laryngopyocele can become an emergency causing airway obstruction and may present with rapid as a swelling on one or both sides of the neck. In severe cases, urgent management including tracheostomy could be required.<sup>7,8,13</sup>

The diagnosis of a laryngocele/laryngopyocele was primarily made on the basis of the laryngeal examination, and confirmed by CT scan. CT scan has proved to be golden standard imaging method in the diagnosis of laryngocele. CT scan can help distinguish between cysts filled with air from those filled with liquid and also shows the characteristic intralaryngeal and extralaryngeal expansion.<sup>14</sup> Additionally, the differential diagnosis, which includes saccular cyst, thyroglossal duct cyst, branchial cleft cyst, cystic hygroma and presence of a carcinoma, is usually made with CT scan.<sup>4,7,14</sup>

We performed our patient to rule out a neoplasm in the ventricle or false cord with microlaryngoscopy. Although the relationship between laryngocele and laryngeal carcinoma has been debated, according to some authors, there is a high incidence of coexistence between laryngoceles and supraglottic squamous cell carcinoma and if a laryngocele is detected, care must be taken to exclude malignancy.<sup>4,10,11,15</sup> Micheau et al.<sup>15</sup> found 18% of laryngoceles in 546 larynx specimens after total laryngectomy. Close et al.<sup>11</sup> reported that the incidence of asymptomatic laryngoceles was 12.5% in larynx carcinoma. According to Celin et al.<sup>10</sup>, although the clinical diagnosis of laryngoceles simultaneously occurring with squamous cell carcinoma of the larynx is infrequent; the two entities have been associated in 4.9% to 28.8% of cases in specimens. Akbas et al.<sup>4</sup> presented a case of bilateral asymptomatic la-

ryngoceles in a 45-year-old male patient suffering laryngeal squamous cell carcinoma and reported that the laryngoceles were a result of increased intralaryngeal pressure secondary to the mass effect of laryngeal carcinoma. In addition to coexistence with malignancy, the bad results of the recurrent deep neck infection or potential upper airway obstruction should not be underestimated. As in our patient, she had an asymptomatic neck swelling (a combined laryngocele) for 20 years but within a short time she had become suffering from some serious complaints. An adequate intervention may be an option instead of monitoring before a threatening such as neck infection or upper airway obstruction and then tracheotomy. So, the essential question is “How do we have to approach to asymptomatic laryngocele? Don’t we have to do anything before the emergence of those complaints?” Based on the idea “laryngoceles’ close relation with increased malignancy risk” and possibility of serious infection and airway obstruction, preventive surgery may be also presented as a treatment choice besides follow-up. Currently, small or asymptomatic laryngoceles are monitored and removed only if they become symptomatic or have developed into a laryngopyocele or cause some cosmetic alteration. Therefore, this new idea may be debatable.

The definitive management of symptomatic laryngocele and laryngopyocele is surgical excision. The options include endoscopic, external and combined (endoscopic + external) approach.<sup>16,17</sup> Endoscopic approach with the assistance of carbon dioxide laser resection or marsupialisation is currently the preferred method in internal laryngoceles. Also, classical cold steel or laryngeal microdebrider are the other alternative methods.<sup>13</sup> Although treatment of the combined laryngocele is still controversial, most authors prefer solely external approach. Due to a huge mass, we preferred external approach. The external cervical approach allows good exposure of the lesion with minimal functional disability. But, during dissection of the external component of a combined laryngocele, care should be taken to avoid trauma to the superior laryngeal nerves as it enters the thyrohyoid membrane posteriorly.<sup>6</sup> Marsupialization alone is not enough without entire laryngocele removal because of higher risk of recurrence. Tracheotomy is usually not necessary. In severe cases, aggressive antibiotic treatment and aspiration of the purulent content can avoid the need of emergency tracheotomy.<sup>7</sup>

In conclusion, laryngocele/laryngopyocele should be considered as an important differential diagnosis in patients with a soft palpable cervical

mass with/without airway obstruction. When the laryngocele was diagnosed, endoscopic examination should be performed due to malignancy possibility and a biopsy can be taken if necessary. In cases of asymptomatic laryngocele, besides follow-up, preventive surgery may be offered as a treatment option.

## REFERENCES

1. Stell PM, Maran AG. Laryngocele. *J Laryngol Otol* 1975;89(9):915-24.
2. Amin M, Maran AG. The aetiology of laryngocele. *Clin Otolaryngol Allied Sci* 1988; 13(4):267-72.
3. Cassano L, Lombardo P, Marchese-Ragona R, Pastore A. Laryngopyocele: three new clinical cases and review of the literature. *Eur Arch Otorhinolaryngol* 2000;257(5):507-11.
4. Akbas Y, Unal M, Pata YS. Asymptomatic bilateral mixed-type laryngocele and laryngeal carcinoma. *Eur Arch Otorhinolaryngol* 2004;261(6):307-9.
5. Isaacson G, Sataloff RT. Bilateral laryngoceles in a young trumpet player: case report. *ENT Journal* 2000;12(2):272-3.
6. Lancella A, Abbate G, Dosdegani R. Mixed laryngocele: a case report and review of the literature. *Acta Otorhinolaryngol Ital* 2007;27(5):255-7.
7. Vasileiadis I, Kapetanakis S, Petousis A, Stavrianaki A, Fiska A, Karakostas E. Internal laryngopyocele as a cause of acute airway obstruction: an extremely rare case and review of the literature. *Acta Otorhinolaryngol Ital* 2012;32(1):58-62.
8. Upile T, Jerjes W, Sipaul F, El Maaytah M, Singh S, Howard D, et al. Laryngocele: a rare complication of surgical tracheostomy. *BMC Surg*. 2006; 27;6(1):14-5.
9. Rosen CA, Simpson CB (2008). *Operative Techniques in Laryngology*. Springer-Verlag, Berlin
10. Celin SE, Johnson J, Curtin H, Barnes L. The association of laryngocele with squamous cell carcinoma of the larynx. *Laryngoscope* 1991;101(4):529-36
11. Close LG, Merkel M, Burns DK, Deaton Jr. CW, Schaefer SD. Asymptomatic laryngocele: incidence and association with laryngeal cancer. *Ann Otol Rhinol Laryngol* 1987;96(3):393-9
12. Pennings RJ, van den Hoogen FJ, Marres HA. Giant laryngoceles: a cause of upper airway obstruction. *Eur Arch Otorhinolaryngol*. 2001;258(3):137-40
13. Fraser L, Pittore B, Frampton S, Brennan P, Puxeddu R. Laryngeal debridement: an alternative treatment for a laryngopyocele presenting with severe airway obstruction. *Acta Otorhinolaryngol Ital*. 2011;31(2):113-7
14. Nazaroğlu H, Ozates M, Uyar A, Deger E, Simsek M. Laryngopyocele: signs on computed tomography. *Eur J Radiol* 2000;33(1):63-5
15. Micheau C, Luboinski B, Lanchi P, Cachin Y. Relationship between laryngoceles and laryngeal carcinomas. *Laryngoscope* 1978;88(6):680-8
16. Dursun G, Ozgursoy OB, Beton S, Batikhan H. Current diagnosis and treatment of laryngocele in adults. *Otolaryngol Head Neck Surg* 2007;136(2):211-5
17. Matino Soler E, Martinez Vecina V, et al. Laryngocele: clinical and therapeutic study of 60 cases. *Acta Otorinolaringol Esp* 1995;46(2):279-86.