

CASE REPORT

Aggressive angiomyxoma: Case report

Agresif anjiomixoma: Olgu sunumu

Fatma Eskicioğlu¹, Tülay Gökmen²

ABSTRACT

Aggressive angiomyxoma is a rare benign mesenchymal neoplasm. It is often diagnosed in genital, pelvic and perineal region of women in reproductive ages. Aggressive angiomyxoma is associated with a high risk of local recurrence. Aggressive angiomyxoma is mixed with Bartholin's gland cyst, lipoma and vaginal cysts in diagnosis. Generally, stromal invasion is detected in these benign neoplasms. Therefore, wide local excision should be performed to treat. GnRH agonists could be administered in patient with aggressive angiomyxoma, either primary or recurrent. We reported a case with vulvar aggressive angiomyxoma presented with vulvar mass and treated with wide local excision. *J Clin Exp Invest* 2012; 3 (3): 420-422

Key words: Angiomyxoma, myxoma, vulvar mass

ÖZET

Agresif anjiomiksoma nadir görülen benign mezenşimal tümördür. Sıklıkla üreme çağı kadınlarda genital, pelvik ve perineal bölgelerde görülür. Agresif anjiomiksomada lokal rekürrens riski yüksektir. Tanıda agresif anjiomiksoma bartolin kisti, lipoma ve vajinal kist ile karışır. Bu iyi huylu tümörde genellikle stromal invazyon görülür ve geniş lokal eksizyon yapılmalıdır. GnRH agonistleri ile tedavi primer yada rekürren agresif anjiomiksoma olgularında uygulanabilir. Vulvar kitle tanısı ile geniş lokal eksizyon tedavisi uyguladığımız olguyu sunduk.

Anahtar kelimeler: Anjiomiksoma, miksoma, vulvar kitle

INTRODUCTION

Aggressive angiomyxoma was described by Steper and Rosai first time in 1983. Aggressive angiomyxoma is a rare mesenchymal neoplasm.¹ Aggressive angiomyxoma is a slow-growing locally infiltrative neoplasm and has a high rate of local recurrence.² It is most often diagnosed in women in reproductive age and detected in external genital, perineum, and pelvis. Aggressive angiomyxoma has low rate of metastasis in distant regions in the body.² The ratio of occurrence of aggressive angiomyxoma in women compared to men is 6 to 1.³ In men, aggressive angiomyxoma is most often detected in inguinoscrotal regions.⁴ The main treatment method is wide-local excision. Recurrence rates ranging from 30% to 40% after excision in couple have been reported in literature.⁵

CASE REPORT

A 44 year-old female patient (G4P2) was admitted with complaint about painless vulvar mass located in right labium majus for the last two years and

growing more rapidly in recent months. In gynecological examination, a rubber-soft, mobile, polypoid mass with 4 cm diameter is observed in the right distal labium majus. This mass had smooth borders. There were no pathological findings in vagina, cervix, uterus and ovaries. Surgical local excision was performed for the initial diagnosis of lipoma. A jelly-like mass (approximately 3x6x2cm) with smooth borders was excised. It is worth mentioning that the lesion infiltrated into the pelvis. Pathological analysis revealed aggressive angiomyxoma. Microscopically, mid-size hyalinized veins with thick walls were observed among spindle cells inside myxoid stroma (Figure1). Around the veins, collections of myoid composed of mainly smooth muscle cells were found. Stromal cells and collections of myoid were stained with desmin and vimentin (Figure 2). Most of the veins and star-like cells were positive with CD34. However when stained with ES100, they were negative. When stained with estrogen and progesterone receptors, they were positive.

Following the surgery, 3.75 mg per month GnRH analogues were administered to the patient

¹ Merkezefendi Devlet Hastanesi, Kadın Hastalıkları ve Doğum Kliniği, Manisa, Türkiye

² Merkezefendi Devlet Hastanesi, Patoloji Laboratuvarı, Manisa, Türkiye

Correspondence: Fatma Eskicioğlu,

Merkezefendi Devlet Hastanesi, Kadın Hastalıkları ve Doğum Kliniği, Manisa, Türkiye Email: feskioglu@yahoo.com

Received: 19.07.2012, Accepted: 31.07.2012

Copyright © JCEI / Journal of Clinical and Experimental Investigations 2012, All rights reserved

for three months. The patient was informed about the risk of recurrence. The patient was controlled for two years and no recurrence was detected.

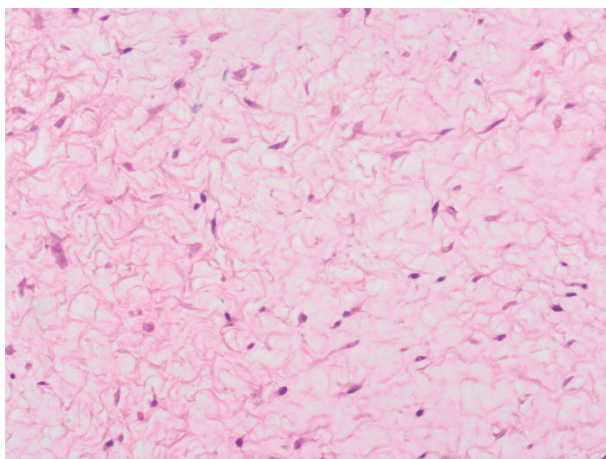


Figure 1. Hyalinized veins among spindled cells in myxoma stroma HEX200

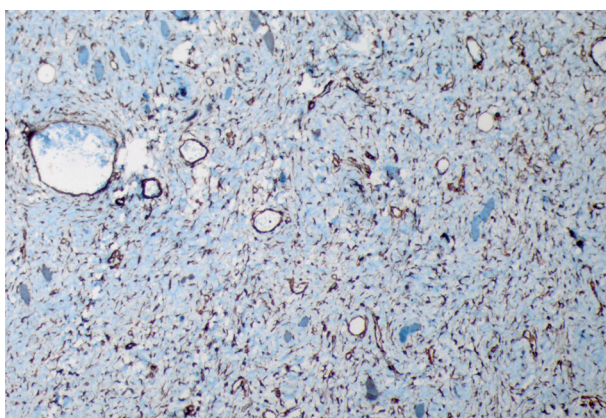


Figure 2. Stromal cells and collection of myoid HEX200

DISCUSSION

Aggressive angiomyxoma is a rare mesenchymal and benign tumor which was first described by Steeper and Rosai.¹ Aggressive angiomyxoma is often diagnosed in women in the fourth decade of their life.³ Aggressive angiomyxoma, rarely diagnosed in men, is most often detected in their inguinoscrotal regions.^{3,4} In female patients, it is most often detected in external genital, perineum, and pelvis. Aggressive angiomyxoma, growing slowly, has low rate of the remote metastasis.² The presenting symptom of the patients is usually painless and slow-growing mass. Due to its location and appearance, aggressive angiomyxoma is usually misdiagnosed as bartholin cyst, lipoma or vaginal cysts. In previous case reports, the diameters of the neoplasms generally

have ranged from 5 to 23 cm.⁹ Jelly-like soft masses are found adhered to the pelvic muscle and fat tissues. The most outstanding feature of aggressive angiomyxoma is its ability of local infiltration. Therefore, the treatment modality is wide-local excision. The rate of local recurrence after the surgery is approximately %30-40.⁵

The methods to establish a final diagnosis are pathological analysis and immunohistochemical stain. Microscopically, these tumors show low to moderate cellularity and are composed of relatively uniform, small, stellate and spindled cells, set in a loosely collagenous, myxoedemayous matrix with scattered vessels of varying caliber and entrapped regional structures. The tumor cells have scant, pale, eosinophilic cytoplasm with poorly defined borders and relatively bland nuclei with an open chromatin pattern and a single, small, centrally located nucleolus. Multinucleated cells rarely are observed. Mitotic figures are infrequent. A characteristic finding that is seen in most cases is the presence of loosely organised island of well-developed myxoid cells around the larger nerve segments and vessels. Tumor cells usually show immunoreactivity for vimentin, desmin, estrogen, progesterone receptor proteins and variable levels of immunoreactivity for actin and CD34.^{10,11} However no immunoreactivity is observed in case of ES100 protein. In our case we observed immunoreactivity for desmin and CD34, estrogen progesterone receptor proteins. In accordance with the literature, no immunoreactivity for ES100 protein was observed.

Angiomyofibroblastoma, a mesenchymal neoplasm with similar clinical, morphological and histopathological, should be considered in the differential diagnosis of the angiomyxoma. While aggressive angiomyxoma invades pelvic soft tissues, angiomyofibroblastoma is a local-restricted lesion residing on the surface of vulva. In contrast to aggressive angiomyxoma, the stroma of angiomyofibroblastoma is lack of hyaluronic acid and contains small and mid-size blood veins. Furthermore, angiomyofibroblastoma is more cellular and has lower rate of recurrence after surgery.¹²⁻¹⁴ Thus, simple local excision is enough in case of angiomyofibroblastoma. Angiomyofibroblastoma is more likely to be smaller than 5 cm in diameter. However, there are several aggressive angiomyxoma cases with almost 60 cm long diameter in literature.¹²

There are publications suggesting treatment with GnRH agonist after surgery for primary or recurrent cases.^{15,16} However, there is no consensus about the effective duration of the treatment in reducing recurrence rate after surgery. In our case,

3.75 mg GnRH analog was administered to the patient for three months.

Taken into consideration the present publications, aggressive angiomixoma should be suspected when polyploidy masses are observed in pelvic and perineal regions. Before surgery, ultrasound or magnetic resonance imaging (MRI) screening could be useful to find out any invasion into the neighboring tissues. Histopathological analysis should be suggested to establish a final diagnosis. After the surgery, clinical follow-up, ultrasound and MR monitoring should be utilized in terms of detection of recurrence. There is insufficient evidence to support utilizing GnRH analogs to prevent recurrence and to accept as a treatment modality for patients, who are not able to be operated.

REFERENCES

1. Steeper TA, Rosai J. Aggressive angiomixoma of the female pelvis and perineum: report of nine cases of a distinctive type of gynecologic soft tissue neoplasm. *Am J Surg Pathol* 1983;7(5):463-75.
2. McCluggage WG. A review and update of morphologically bland vulvovaginal mesenchymal neoplasms. *Int J Gynecol Pathol* 2005;24(1):26-38.
3. Fetsch JF, Laskin WB, Lefkowitz M, Kindblom LG, Meis-Kindblom JM. Aggressive angiomixoma: a clinicopathologic study of 29 female patients. *Cancer* 1996;78(1):79-90.
4. Iezzoni JC, Fechner RE, Wong LE, et al. Aggressive angiomixoma in males. A report of four cases. *Am J Clin Pathol* 1995;104(4):391-6.
5. Nucci MR, Fletcher CD. Vulvovaginal soft tissue tumours: update and review. *Histopathology* 2000;36(2):97-108.
6. Gungor T, Zengeroglu S, Kaleli A, Kuzey GM. Aggressive angiomixoma of the vulva and vagina. A common problem: misdiagnosis. *Eur J Obstet Gynecol Reprod Biol* 2004; 112(1): 114-6.
7. Blandamura S, Cruz J, Faure Vergara L, et al. Aggressive angiomixoma. A second case of metastasis with patient's death. *Hum Pathol* 2003; 34(10):1072-4.
8. Amezcua CA, Begley SJ, Mata N, Felix JC, Ballard CA. Aggressive angiomixoma of the female genital tract: a clinicopathologic and immunohistochemical study of 12 cases. *Int J Gynecol Cancer* 2005;15(1):140-5.
9. Cinel L, Taner D, Nabaei SM, Dogan M. Aggressive angiomixoma of the vagina. Report of a distinctive type gynaecologic soft tissue neoplasm. *Acta Obstet Gynecol Scand* 2000 ;79(3):232-3.
10. van Roggen JF, van Unnik JA, Briaire-de Bruijn IH, Hogendoorn PC. Aggressive angiomixoma: a clinicopathological and immunohistochemical study of 11 cases with long-term follow-up. *Virchows Arch* 2005;446(2):157-63.
11. McCluggage WG, Patterson A, Maxwell P. Aggressive angiomixoma of pelvic parts exhibits oestrogen and progesterone receptor positivity. *J Clin Pathol* 2000;53(8):603-5.
12. Wang J, Sheng W, Tu X, Shi D, Zhu X, Zhang R. Clinicopathologic analysis of angiomixofibrosarcoma of the female genital tract. *Chin Med J (Engl)* 2000;113(11):1036-9
13. Laskin WB, Fetsch JF, Tavassoli FA. Angiomixofibrosarcoma of the female genital tract: analysis of 17 cases including a lipomatous variant. *Hum Pathol* 1997;28(9):1046-55
14. Hisaoka M, Kouho H, Aoki T, Daimaru Y, Hashimoto H. Angiomixofibrosarcoma of the vulva : a clinicopathologic study of seven cases. *Pathol Int* 1995;45(7):487-92
15. Fine BA, Munoz AK, Litx LE, et al. Primary medical management of recurrent aggressive angiomixoma of the vulva with a gonadotropin - releasing hormone agonist. *Gynecol Oncol* 2001;81(1):120-2.
16. Poirier M, Fraser R, Meterissian S. Aggressive angiomixoma of the pelvis: response to luteinizing hormone - releasing hormone agonist. *J Clin Oncol* 2003;21(18):3535-6.