

Nasal septal schwannoma

Burun septum schwannomu

Hüseyin Baki Yılmaz¹, Murat Hakan Karabulut², Seçkin Ulusoy³, Şaban Çelebi⁴

¹Department of Otorhinolaryngology, Tuzla Government Hospital, Istanbul, Turkey

²Department of Patbology, Ümraniye Training and Research Hospital, Istanbul, Turkey

³Department of Otorhinolaryngology, Çorlu Government Hospital, Tekirdağ, Turkey

⁴Department of Otorhinolaryngology, Taksim GOP Training and Research Hospital, Istanbul, Turkey

Abstract

Schwannomas are benign, encapsulated and slowly growing neoplasms arising from schwann cells of the sheath of the peripheral nerves. In the head and neck region, schwannomas are often encountered as acoustic neuromas. A nasal septal mass in a 65-year-old male patient was resected *en-bloc* which was reported to be a schwannoma. No recurrence was observed in the fourth postoperative year. In conclusion, although rarely encountered, nasal septal schwannoma should be considered in the differential diagnosis of nasal masses. Even though total excision of the mass will be sufficient for the prevention of recurrence, the tumor should be sent to pathology for a definite histopathological diagnosis. Since malignant transformation has been reported, long-term follow-up is mandatory.

Keywords: Schwannoma, nasal septum.

Özet

Schwannomlar periferik sinir kılıfının schwann hücrelerinden kaynaklanırlar ve yavaş büyüme gösteren sıklıkla kapsüllü benign neoplazmlardır. Baş boyun bölgesinde sıklıkla akustik nöroma olarak görülmektedir. Nazal septum kaynaklı burun kitlesi olan 65 yaşındaki erkek hastaya septoplasti operasyonu yaparak kitlenin tamamını çıkarttık. Kitle patolojisi schwannom olarak rapor edilen hastada operasyon sonrası dört yıllık dönemde nüks görülmedi. Sonuç olarak nazal kitlelerde ender olarak görüle de ayırıcı tanıda schwannomlar göz önünde tutulmalıdır. Kitlenin total çıkarımı sonrası nüks görülme de histopatolojik olarak tam konulmalı ve malign dönüşüm bildirildiği için hasta uzun dönem takip edilmelidir.

Anahtar sözcükler: Schwannom, burun septumu.

Schwannomas are slowly growing benign, frequently encapsulated neoplasms arising from schwann cells of the sheath of the peripheral nerves. They can be seen in every part of the body, and observed on the head and neck region in 25-45% of the cases, frequently as acoustic neuromas.^[1] Only 4% of the schwannomas of the head and neck region are seen in paranasal sinuses, and nasal cavities.^[2,3] Schwannomas are rarely seen on nasal septum, and only 11 cases have been reported in the literature.^[4]

In this study, we present a case of septal schwannoma which with time grew in size completely obstructing nasal vestibule, and led to complaints of nosebleed, and nasal obstruction.

Case Report

A 65-year-old male patient consulted to our clinic because of a painless, gradually growing mass for nearly 3 years, which obstructed nasal passages, and protruded outside from the right nostril. With its traumatic effect the lesion caused nosebleed (Fig. 1a). Otorhinolaryngologic examination of the patient revealed a 2 cm-mass with smooth contours arising from the anterior aspect of the septum, and obstructing nasal vestibule. Any other abnormality was not detected in this patient. Under local anesthesia septoplasty was performed, and the mass was completely excised together with ipsilateral septum, and perichondrium (Fig. 1b). Contralateral perichondrium was left intact. On macroscop-

Correspondence: Hüseyin Baki Yılmaz, MD. Simpaş Lagün sitesi E1 D3, 34800, Sancaktepe, İstanbul, Turkey.
e-mail: drbakiyilmaz@gmail.com

Received: May 22, 2014; **Accepted:** June 17, 2014

Online available at:
www.jmedupdates.org
doi:10.2399/jmu.2014002009
QR code:



ic examination, it appeared as an ulcerated, pigmented, pink-colored mass measuring 2×3 cm with an elastic consistency. Its free edge had irregular contours and it demonstrated smooth surface near its base. On microscopic examination, a tumoral mass localized on, and under the nasal septum with nodular, encapsulated, and pigmented components having thrombocytic elements was detected. On histopathological examination, tumoral lesion with spindle cells demonstrating diffuse S-100 positivity, and surrounded by a fibrous capsule was observed. With these histopathological findings the case was diagnosed as schwannoma. During postoperative 4 years of follow-up systemic or local recurrence was not seen.

Discussion

As tumors arising from myelin sheaths of the nerves, schwannomas are slowly growing solitary benign tumors, which develop on myelinated nerves. Since autonomic system nerve fibers innervating especially sinonasal region mucosa are devoid of perineural sheaths, schwannomas arising from this region are noncapsulated. However, most of the schwannomas are encapsulated. Schwannoma of our case was also encapsulated.^[4]

Though schwannomas can involve every part of the body, in 25-45% of the cases they are seen on the head and neck region, frequently as acoustic neuromas.^[1] Only 4%

of the head and neck schwannomas are seen in paranasal sinus, and nose.^[2,3] Since optic and olfactory nerves do not contain schwann cells, schwannomas are not encountered on these nerves.^[5] Head and neck schwannomas have been suggested to originate most frequently from ophthalmic, and maxillary branches of the vestibular, and trigeminal nerves.^[6] We think that in our case tumor stemmed from autonomic, and sensorineural nerve fibers innervating nasal septum.

Schwannomas are the most frequently seen in ethmoid sinuses in the sinonasal region, then with decreasing order of frequency, in maxillary sinus, nasal fossa, and sphenoid sinuses. Other regions of involvement include scalp, face, oral cavity, larynx, trachea, parotid, middle ear, and external ear way. Nasal septal schwannomas are rarely seen, and only 11 cases have been reported in the literature.^[4] In our case, the tumor was localized on the anterior aspect of the septum, and its borders could be easily discerned.

In the literature, age range for schwannoma patients has been reported to vary between 6 and 78 years. Similar female/male ratios have been reported without any difference between races.^[5] Schwannomas have been frequently associated with von Recklinghausen disease, and malignant potential of these tumors have been occasionally demonstrated.^[7] Clinical findings are generally variable. The most frequent sign is slowly growing painless mass.

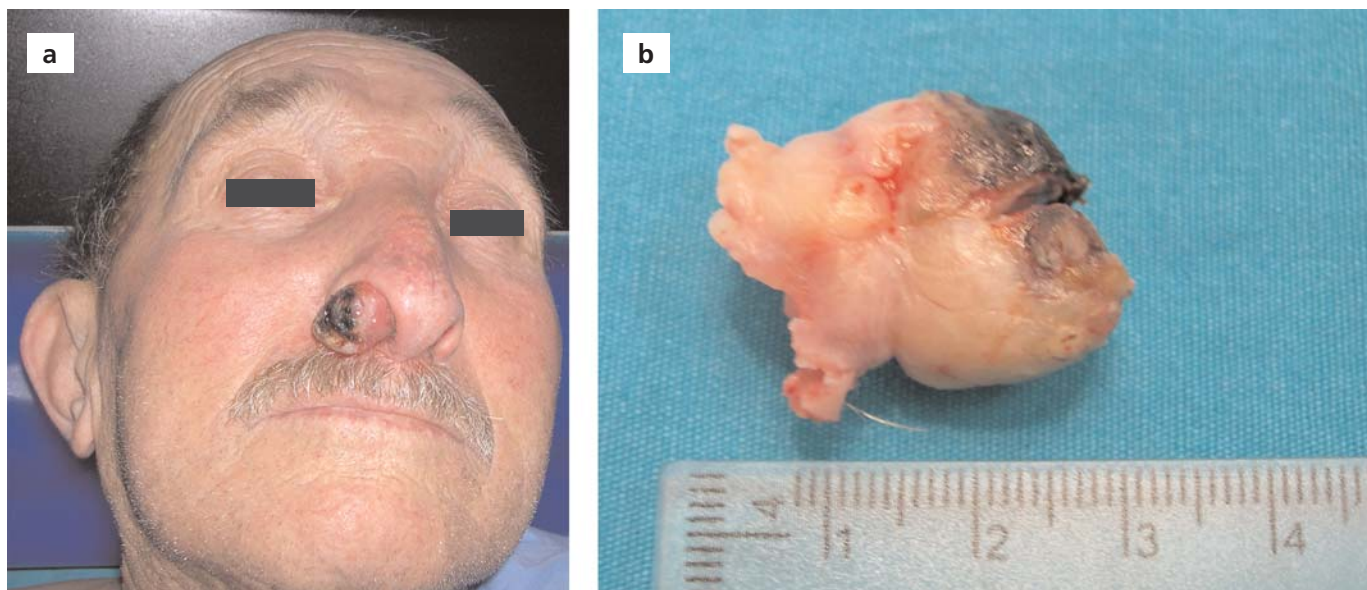


Fig. 1. The appearance of the patient at presentation (a) and the mass after its excision (b).

The patients have complaints of stuffy nose, nosebleed, nasal discharge, anosmia, swollen face, and pain. In our case, the mass lesion was easily visible from outside, while his complaints were rather nosebleed, and stuffy nose. The nosebleed was secondary to trauma. The reason for delayed referral of the patient to our clinic was gradual, and painless growth of the mass within 4 years. Since examination findings and patients' complaints are not specific to schwannomas, the diagnosis of schwannoma is made histopathologically. In differential diagnosis, in addition to carcinoma, sarcoma, inverted papilloma, meningioma, neurofibroma, melanoma, and olfactory neuroblastoma should be considered.^[8]

Macroscopically, schwannomas are yellowish-gray skin-colored solid tumors. In our case, base of the mass was pink, and tip of the mass was black-violet colored. This difference in color can be explained by the presence of hemorrhagic areas, and cystic changes in bulky masses.^[9] Macroscopically, schwannomas are oval-round shaped elastic masses with a smooth surface. In our case, except the free edge of the mass, it had a smooth surface with regular contours.

Microscopically, spindle cell populations with a biphasic pattern having Antoni A, and B areas with a palisade arrangement of nuclei are detected. Antoni A areas are histologically hypercellular areas, and contain Verocay bodies formed by nuclear palisading. Antoni B areas are hypocellular regions. Antoni A areas are formed by densely arranged spindle cells, while Antoni B areas are made up of scattered spindle cells in a loose mixoid stroma. The ratio between these two components varies.^[10] The presence of Schwannoma cells are demonstrated immunohistochemical staining with S-100 protein. S-100 protein positivity demonstrates that the mass lesion originated from Schwann cells. In our case, histopathological examination of the excisional specimen revealed that in a subepithelial area covered with squamous epithelium with a smooth surface, a mesenchymal neoplasm with well-defined contours having oval-round nuclei with diffuse chromatin but without distinct borders were seen. Tumor cells did not display cellular atypia, pleomorphism or necrosis with extremely rare mitoses. Though the tumor was generally hypercellular, hypocellular areas were occasionally seen in a loose connective tissue, and tumor cells formed short decussating bundles with interposing hyalinized vascular structures. Mostly Antoni A, and partially Antoni B areas were seen (Fig. 2a). On immunohisto-

chemical examination, tumor cells demonstrated positive S-100 expression. With these findings the case was diagnosed as schwannoma (Fig. 2b).

Treatment consists of total extirpation of the mass with surgical margin negativity under suitable conditions. In our case since the mass lesion was localized on nasal septum - apart from schwannomas of the head and neck region - with easily discernable contours, it could be totally excised through septoplasty approach under local anesthesia. Though rarely, since malignant transformation of benign schwannomas has been reported in the literature, the case was followed up periodically for 4 years without development of recurrence.

In conclusion, though rarely seen, schwannomas should be considered in the differential diagnosis. Even

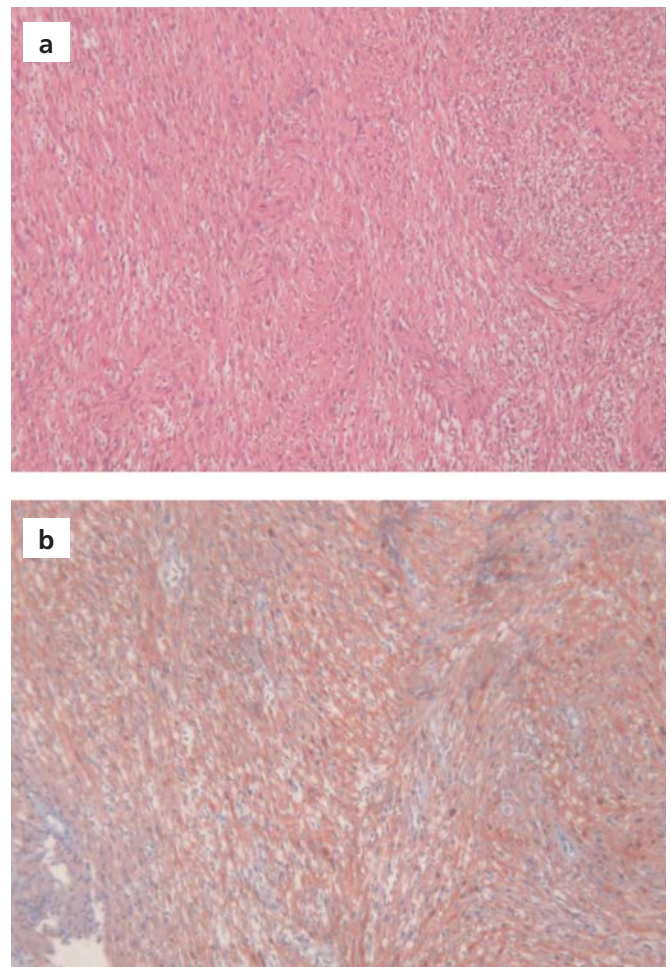


Fig. 2. Results of hematoxylin- eosin staining (a) and immunohistochemical staining with s-100 (b) (HE x100).

though recurrences are not seen after total excision of the mass, histopathological diagnosis should be made, and since malignant transformation has been reported in the literature, the patient should be followed up for a long time.

Conflict of Interest: No conflicts declared.

References

1. Colreavy MP, Lacy PD, Hughes J, et al. Head and neck schwannomas -- a 10 year review. *J Laryngol Otol* 2000;114:119-24.
2. Donnelly MJ, al-Sader MH, Blayney AW. Benign nasal schwannoma. *J Laryngol Otol* 1992;106:1011-5.
3. Persaud RA, Hajioff D, Chevretton EB. Intranasal schwannoma in a young woman. *Int J Clin Pract* 2004;58:426-8.
4. Mey KH, Buchwald C, Daugaard S, Prause JU. Sinonasal schwannoma -- a clinicopathological analysis of five rare cases. *Rhinology* 2006;44:46-52.
5. Berlucchi M, Piazza C, Blanzuoli L, Battaglia G, Nicolai P. Schwannoma of the nasal septum: a case report with review of the literature. *Eur Arch Otorhinolaryngol* 2000;257:402-5.
6. Hegazy HM, Snyderman CH, Fan CY, Kassam AB. Neurilemmomas of the paranasal sinuses. *Am J Otolaryngol* 2001;22:215-8.
7. Mannan AA, Singh MK, Bahadur S, Hatimota P, Sharma MC. Solitary malignant schwannoma of the nasal cavity and paranasal sinuses: report of two rare cases. *Ear Nose Throat J* 2003;82:634-636, 638,640.
8. Siqueira MG, Jennings E, Moraes OJ, et al. Naso-ethmoid schwannoma with intracranial extension: case report. *Arq Neuropsiquiatr* 2001;59(2-B):421-3.
9. Pehlivan S, Ozercan IH, Keles E, Mungan I. Intranasal schwannom: olgu sunumu. *Fırat Üniversitesi Sağlık Bilimleri Tıp Dergisi* 2008;22:109-12.
10. Sheikh HY, Chakravarthy RP, Slevin NJ, Sykes AJ, Banerjee SS. Benign schwannoma in paranasal sinuses: a clinico-pathological study of five cases, emphasising diagnostic difficulties. *J Laryngol Otol* 2008;122:598-602.

This is an open access article distributed under the terms of the Creative Commons Attribution-NonCommercial-NoDerivs 3.0 Unported (CC BY-NC-ND3.0) Licence (<http://creativecommons.org/licenses/by-nc-nd/3.0/>) which permits unrestricted noncommercial use, distribution, and reproduction in any medium, provided the original work is properly cited.

Please cite this article as: Yilmaz HB, Karabulut MH, Ulusoy S, Çelebi Ş. Nasal septal schwannoma. *J Med Updates* 2014;4(2):77-80.