

A Step-by-step Visualization of an Epidermal Cyst Excision on the Neck and Review of Literature

Özgür GÜNDÜZ*, Deniz ÖZTÜRK KARA*, Pınar ATASOY**

* Department of Dermatology and Venerology - University of Kırıkkale, Kırıkkale, TURKEY

** Department of Pathology, University of Kırıkkale, Kırıkkale, TURKEY

Abstract;

Although epidermal inclusion cysts (EIC) are relatively common and usually not paid their deserved medical attention. Extending from a simple inflammation to carcinogenesis¹⁻³, the complication spectrum of EIC is very wide. In this paper, we report a young adult patient with an EIC on his neck with an emphasis on the excisional procedure and histopathology.

Key Words: Epidermal inclusion cyst, traumatic implantation, congenital etiology, granular layer, lamellated keratin, en-bloc excision, minimal incision technique

A Step-by-step Visualization of an Epidermal Cyst Excision on the Neck and Review of Literature

Özet ;

Epidermal inklüzyon kistleri (EİK), göreceli olarak sık görülen lezyonlar olmalarına rağmen hak ettikleri medikal önemi görmemektedirler. EİK, basit bir inflamasyondan karsinogeneze¹⁻³ zemin oluşturmaya kadar oldukça geniş bir komplikasyon profiline sahiptir. Bu makalede, boynunda EİK tespit edilen genç erişkin bir erkek hastada uygulanan eksizyon prosedürü ve EİK'in histopatolojisi anlatılmaktadır.

Anahtar Kelimeler: Epidermal inklüzyon kisti, travmatik implantasyon, konjenital etyoloji, granüler tabaka, lamellar keratin, en-bloc eskizyon, minimal insizyon tekniği

Introduction

EICs, also erroneously referred as “sebaceous cyst”, are practically the most common cysts of cutaneous origin in humans.^{1,2,3} Although not a strict rule, hair-bearing areas are more likely to develop such lesions, so a good portion of cysts are located on visible areas. Besides the cosmetic discomfort caused by epidermal cysts (due to an altered appearance), there are other possible complications, foremost being the infections of the cystic cavity due to its connection with the skin surface. Infected cysts may cause considerable pain and impairment during daily activities. An infected epidermal cyst is considered as prone to recurrent infections. Also risk of malign degeneration in the cyst setting is another uncommon, but serious threat.

Methods

A 22-year old male patient presented with a bulging lesion on his right side of neck. He was worried about this asymptomatic, but persistent lump which occurred 2 years before. His further medical history revealed only prior acne treatment consisting of topical and systemic antibiotics (erythromycin, doxycycline respectively) and topical retinoids.

A solitary non-tender, nodulocystic lesion with limited mobility and 1.0 cm. radius was observed

on the right side of the patient' neck (Fig.1.a.). Although asymptomatic, the cyst was a major source of discomfort for the patient. An excisional biopsy was planned. After a discussion about all the possible complications of the procedure, an informed consent was taken from the patient. The operation was performed in the outpatient clinic of Kırıkkale University Department of Dermatology and Venerology. Operational area was scrubbed initially with alcohol. Then the excision margins were determined and excision lines were drawn according to the relaxed tension skin lines with a sterilized pen (Fig 1.b). An anesthetic solution consisting of Lidocaine HCl 20 mg/ml, Epinephrine HCl 0.0125 mg/ml was employed for the local infiltration anesthesia in a fan-shaped manner in the perioperative area and under the cyst (Fig 1.c – 1.d).

A total dose of 5 ml of anesthetic solution was injected. This relative excess dose of epinephrine containing solution was preferred for a more gentle and easy separation of the cyst from the underlying tissues by inducing a hydrodissection on a smaller scale. Also epinephrine's vasoconstrictive effect enabled us to work on a relative bloodless operative field and a longer operation time. After the local anesthesia, the surgery area was scrubbed with

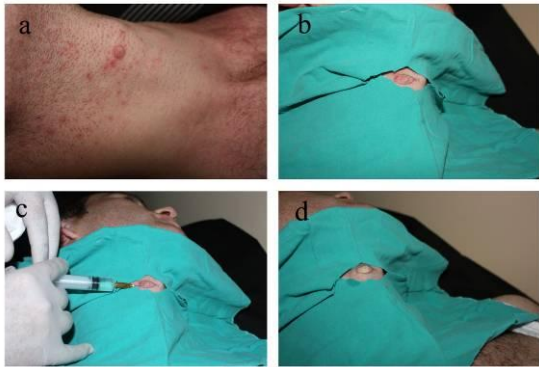


Figure 1 – (a) Solitary papulonodular lesion with a punctum on the patient's neck (b) Marking the excision lines (c) Local anesthesia (d)After the local anesthesia

chlorhexidine solution for a second time. An elliptical excision with primary closure was planned. A 2.0 cm. long excision was performed with a 15 scalpel according to rule of 3:1 ratio of length to width (Fig 2.a). Safety margins between the excision lines and the lesion were minimum 2.0 mm wide at the closest proximity. With careful undermining, the nodulocystic lesion was excised completely (Fig 2.b-2.d,3.a).

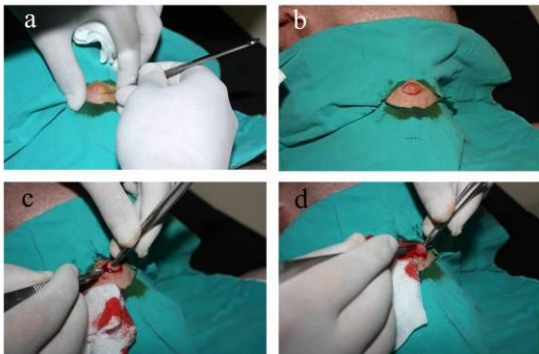


Figure 2 a-d. Removing the cyst with basic elliptical excision

Excised biopsy material was sent for histopathological examination (Fig 3.b).

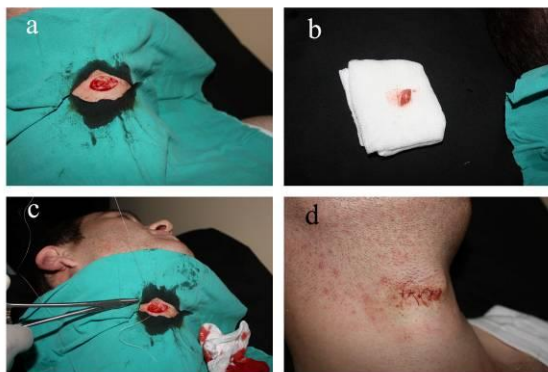


Figure 3 - (a) Skin defect after excision (b) Excisional material (c) Closing the wound with primary suture (d) Sutured wound

Wound edges were closed with primary interrupted sutures (Fig 3.c,3.d). Histopathological examination revealed cystic lesion with an squamous epithelial lining with prominent granular layer and cyst content of lamellar keratin (Fig.4).

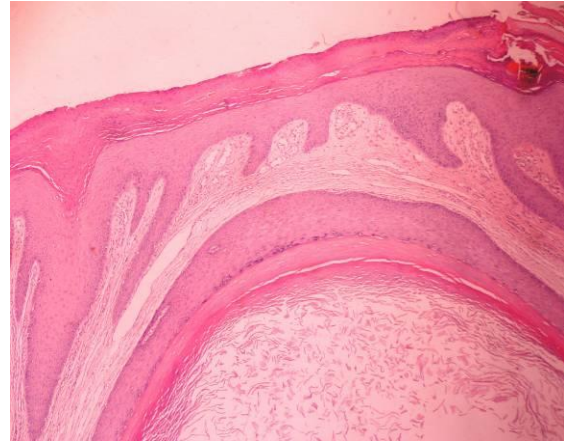


Figure 4 - Squamous epithelial lining of cyst wall and cyst content consisting of lamellar keratin

Discussion

EICs, (also known as epidermoid cyst, follicular infundibular cyst) are acknowledged as congenital lesions originating from the residual ectodermal cells remaining in the fusion plates during embryogenesis³. Also traumatic implantation of epidermal cells in the underlying tissues is another hypothesis for EIC' ethiopathogenesis^{3,4}. Establishing the diagnosis of EIC is usually not a difficult task. Clinician does not need to go further than spotting a firm, round, (and tender if inflamed) mobile bump with a punctum on the skin. Although EICs are most commonly associated with skin, uncommon locations like breast⁵⁻⁷ or bone⁷⁻⁹, has been reported. These deep – seated cysts are believed to originate from epidermal cells trapped in the dermis^{3,4}. "Trapping of epidermal cells in subcutaneous tissues" is hypothesized to be the result of traumatic implantation or proliferation of epidermal remnants along embryonic fusion plates^{3,4}. Several viral pathogens (human papilloma viruses (HPV)¹⁰⁻¹³, pox viruses – molluscum contagiosum¹³⁻¹⁸) have been identified in EICs, suggesting a potential role, especially for human papilloma viruses (HPV). Epidermoid metaplasia due to HPV infection is suspected in the pathogenesis of palmoplantar EICs³.

Histopathological evaluation of biopsy cross-sections reveal typical keratinous cyst content and squamous epithelium linings of cyst wall, sometimes flattened, with a granular layer¹⁵. Rapini classified IECs into three groups¹⁵; milia, hybrid cysts and cysts accompanying certain hereditary syndromes¹⁶⁻²⁰. Also there are several reports

concerning the development of various malign degeneration in an EIC setting^{1-3, 21-25}.

Most likely complications are rupture of the cyst and the likely following infection. An undamaged cyst may become infected without a noticeable trauma due to its surface connection and induce pain and hinder patient's activities. Such an inflamed cyst may pose a very serious threat for the patient's life²⁶. As stated above, EIC may also be a precursor or sign of a more sinister condition. Therefore any patient diagnosed having an EIC should be examined thoroughly and treated. Basic treatment options are antibiotics and antiinflammatory drugs for infected and inflamed cysts and surgery. Incision and drainage or total excision are the surgical treatment options, but one should keep in mind that relapses may be seen after incomplete resection and drainage without excisions. Incomplete resections are usually seen during the removal of the multiloculated epidermoid cysts.

In our case, the epidermal cyst was small and with limited mobility, so to avoid the complications of a possible perilesional fibrosis, we preferred an "en-bloc excision" with a classic elliptic incision and simple interrupted suturing for closure."En-bloc excision" is the procedure of choice when handling with cysts trapped in a fibrotic perilesional area or multiloculated cysts. But, if a cyst is too large (e.g with a diameter of 3-3,5 cm or more), this technique will lead to bigger incision scars. Minimal excision technique is then, the ideal way to remove a large EIC and must be performed as follows^{27,28}; One must first identify the punctum (or the pore) of the cyst. Then the incision line must be marked along the relaxed skin tension lines if possible. Local anesthesia will help to cyst dissection. With a #15 blade, a single, superficial incision must be made transecting the punctum. A whitish cyst sac must be identified before continuing the procedure. The epidermal edges must be pulled out with skin hooks. With proper angling of the blade, cyst walls should be dissected from the surrounding tissue. Once freed, the cyst must be grasped with a hemostat and pulled through the incision. Large cysts can be decompressed through a second incision to the lateral cyst wall extracting the cyst contents. Then the empty cyst sac can be extracted through the incision. If the wound is contaminated during the procedure, it should be irrigated with saline water. Before closing the wound, the margins should be inspected for residual cyst walls. The dead space should be closed with with absorbable sutures (i.e. Vicryl) and epidermis with nonabsorbable sutures such as Prolene.

There is also punch biopsy excision. This technique is very similar to minimal excision, except the incision is made with a punch biopsy

blade. Following the incision, lateral pressure is applied to the cyst walls to extract the cyst content and the walls²⁹. Wound closure with suturing is optional. Minimal and punch biopsy excision techniques are acknowledged as having faster healing times and less scarring^{29,30}.

In recent years, new surgical procedures (some of them being variations of minimal excision technique) have been proposed. Itoh et al. have performed endoscopic surgery for larger EICs on face³¹. To avoid large scars, Itoh et al. have preferred to make incisions at the external acoustic meatus and retroauricular areas and then performed endoscopic curettage and extraction of the cyst contents. Yang et al. proposed a variation on the minimal excision technique for the treatment of facial epidermoid cysts with diameters ranging from 0.5 cm to 1.0 cm³². They performed 3 mm. incisions on the overlying skin of EICs, extracted cyst content and walls with lateral pressure and the cauterized the underlying connective tissue with 20% trichloroacetic acid. The reported outcome was 16 out of 22 facial EIC was successfully treated without any recurrence in 6 months and only faint scar were observed.

References

1. Tsujita-Kyutoku M, Danbara N, Yuri T, Nikaido Y, Hatano T, Tsubura A. Basal cell carcinoma arising from a keratinous cyst of the skin: a case report and review of the literature. *Med Mol Morphol*. 2005 Jun;38(2):130-3.
2. Lin CY, Jwo SC. Squamous cell carcinoma arising in an epidermal inclusion cyst. *Chang Gung Med J*. 2002 Apr;25(4):279-82.
3. Thomas VD, Swanson NA, Lee KL. "Benign Epithelial Tumors, Hamartomas, and Hyperlasias". in Wolff K, Goldsmith LA, Katz SI, Gilchrist B, et al, (eds). " Fitzpatrick's Dermatology in General Medicine", (7 ed), pp 1054-1063, The McGraw-Hill Companies Inc, 2008.
4. Braun-Falco M. Cysts. In: Burgdorf WHC, Plewig G, Wolff HH, Landthaler M. Braun-Falco O (Eds). *Braun-Falco's Dermatology* (3rd ed), pp 1327-29, Heidelberg Springer, 2009.
5. Taira N, Aogi K, Ohsumi S, Takashima S, Kawamura S, Nishimura R. Epidermal inclusion cyst of the breast. *Breast Cancer*. 2007;14(4):434-7.
6. Cooper RA, Ramamurthy L. Epidermal inclusion cysts in the male breast. *Can Assoc Radiol J* 1996; 47: 92-93.
7. Hamad AT, Kumar A, Anand Kumar C. Intraosseous epidermoid cyst of the finger phalanx: a case report. *J Orthop Surg (Hong Kong)*. 2006 Dec;14(3):340-2.
8. Egawa K, Honda Y, Inaba Y, Ono T, De Villiers EM. Detection of human papillomaviruses and eccrine ducts in palmoplantar epidermoid cysts. *Br J Dermatol*. Apr 1995;132(4):533-42.
9. Egawa K, Honda Y, Inaba Y, Kojo Y, Ono T, de Villiers EM. Multiple plantar epidermoid cysts harboring carcinoembryonic antigen and human

- papillomavirus DNA sequences. *J Am Acad Dermatol.* Mar 1994;30(3):494-6.
10. Morgan MB, Stevens GL, Somach S, Tannenbaum M. Carcinoma arising in epidermoid cyst: a case series and aetiological investigation of human papillomavirus. *Br J Dermatol.* Sep 2001;145(3):505-6.
 11. Park HS, Kim WS, Lee JH, et al. Association of human papillomavirus infection with palmoplantar epidermal cysts in Korean patients. *Acta Derm venereol.* 2005;85(5):404-8.
 12. Lee S, Lee W, Chung S, et al. Detection of human papillomavirus 60 in epidermal cysts of nonpalmoplantar location. *Am J Dermatopathol.* Jun 2003;25(3):243-7.
 13. Aloï FG, Pippione M. Molluscum contagiosum occurring in an epidermoid cyst. *J Cutan Pathol.* 1985 Apr;12(2):163-5.
 14. Park SK, Lee JY, Kim YH, Kim SY, Cho BK, Houh W. Molluscum contagiosum occurring in an epidermal cyst--report of 3 cases. *J Dermatol.* 1992 Feb;19(2):119-21.
 15. Rapini RP. Cysts. In *Practical Dermatopathology*, 1st ed. 253-258, Elsevier- Mosby, Philadelphia, 2005.
 16. Ascari-Raccagni A, Baldari U, Righini MG. Cutaneous symptoms of Gardner's syndrome. *J Eur Acad Dermatol Venereol.* Jan 1999;12(1):80-1.
 17. Barr RJ, Headley JL, Jensen JL, Howell JB. Cutaneous keratocysts of nevoid basal cell carcinoma syndrome. *J Am Acad Dermatol.* Apr 1986;14(4):572-6.
 18. Ogata K, Ikeda M, Miyoshi K, et al. Naevoid basal cell carcinoma syndrome with a palmar epidermoid cyst, milia and maxillary cysts. *Br J Dermatol.* Sep 2001;145(3):508-9.
 19. Besser FS. Pachyonychia congenita with epidermal cysts and teeth at birth: 4th generation. *Br J Dermatol.* Jan 1971;84(1):95-6.
 20. Takeshita T, Takeshita H, Irie K. Eruptive vellus hair cyst and epidermoid cyst in a patient with pachyonychia congenita. *J Dermatol.* Oct 2000; 27(10):655-7.
 21. Delacretaz J. Keratotic basal-cell carcinoma arising from an epidermoid cyst. *J Dermatol Surg Oncol.* May-Jun 1977;3(3):310-1.
 22. Cameron DS, Hilsinger RL Jr. Squamous cell carcinoma in an epidermal inclusion cyst: case report. *Otolaryngol Head Neck Surg.* Jul 2003; 129(1):141-3.
 23. Lopez-Rios F, Rodriguez-Peralto JL, Castano E, Benito A. Squamous cell carcinoma arising in a cutaneous epidermal cyst: case report and literature review. *Am J Dermatopathol.* Apr 1999;21(2):174-7.
 24. Perse RM, Klappenbach RS, Ragsdale BD. Trabecular (Merkel cell) carcinoma arising in the wall of an epidermal cyst. *Am J Dermatopathol.* Oct 1987;9(5):423-7.
 25. Swygert KE, Parrish CA, Cashman RE, Lin R, Cockerell CJ. Melanoma in situ involving an epidermal inclusion (infundibular) cyst. *Am J Dermatopathol.* Dec 2007;29(6):564-5.
 26. Eboriadou M, Al Qassis M, Skouli G, Tzouvelekis G, Hatzibougias D, Athanassiadou F. An unusual presentation of an epidermoid cyst of the neck over the lateral cervical region. *J Paediatr Child Health.* 2008 Oct;44(10):601-2.
 27. Affleck AG, Graham C. *Skin Biopsy Techniques.* In: Robinson JK, Haneke CW, Siegel DM, Fratila A (Eds), *Surgery of the Skin:Procedural Dermatology* (2nd ed),pp 180-84, Mosby-Elsevier,2010.
 28. Zuber TJ. Minimal excision technique for epidermoid (sebaceous) cysts. *Am Fam Physician.* 2002 Apr 1;65(7):1409-12, 1417-8, 1420.
 29. Moore RB, Fagan EB, Hulkower S, Skolnik DC, O'Sullivan G. Clinical inquiries. What's the best treatment for sebaceous cysts? *J Fam Pract.* 2007 Apr;56(4):315-6.
 30. Mehrabi D, Leonhardt JM, Brodell RT. Removal of keratinous and pilar cysts with the punch incision technique: analysis of surgical outcomes. *Dermatol Surg* 2002;28:673-677.
 31. Itoh Y. Endoscopic extraction and curettage of epidermal cysts on the face. *Br J Plastic Surg* 1999; 52 : 182-184.
 32. Yang HJ, Yang KC. A new method for facial epidermoid cyst removal with minimal incision. *J Eur Acad Dermatol Venereol.* 2009 Aug;23(8):887-90.

Corresponding author:

Özgür Gündüz

Department of Dermatology, Teaching Hospital of Kırıkkale University
 Millet Cad. 71100 Kırıkkale – TURKEY
 E-mail:gunduzozgur@windowslive.com