



## Retained Surgical Sponge Diagnosed as a Paracardiac Mass 35 Years After Surgery

Ahmet Barış Durukan, Hasan Alper Gürbüz, Halil İbrahim Uçar, Cem Yorgancıoğlu

Medicana International Ankara Hospital, Clinic of Cardiovascular Surgery, Ankara, Turkey

### ABSTRACT

Retained foreign bodies following surgery are of medico-legal importance. Most commonly, surgical sponges are retained. Although the typical localization is in the intraabdominal region, mediastinal presentations are also observed. Here, we report a case of retained sponge diagnosed as a paracardiac mass 35 years after closed mitral commissurotomy. The radiologic diagnosis could not be established with plain X-ray due to absence of radiopaque string in it. The patient had no signs of infection or mass effect. During mitral valve replacement and coronary bypass surgery, surgical removal of the sponge was performed.

**Key Words:** Sponges; surgical; mitral stenosis; surgery

### Otuz Beş Yıl Sonra Parakardiyak Kitle Olarak Saptanan Unutulmuş Cerrahi Spanç

#### ÖZET

Cerrahi sonrasında unutulmuş yabancı cisimler mediko-legal öneme sahiptir. Sıklıkla cerrahi spanç unutulur. Tipik lokalizasyon intraabdominal bölge olsa da, mediastende de görülebilir. Biz çalışmamızda, kapalı mitral komissürotomiden 35 yıl sonra parakardiyak kitle olarak saptanan unutulmuş bir cerrahi spanç vakasını bildiriyoruz. Röntgenografi ile radyolojik tanı, spanç içerisinde radyopak işaret olmadığı için yapılamamıştır. Hastada enfeksiyon bulgusu ya da kitle etkisi yoktu. Mitral kapak replasmanı ve koroner bypass cerrahisi sırasında spanç çıkartılmıştır.

**Anahtar Kelimeler:** Spançlar; cerrahi; mitral darlık; cerrahi

### INTRODUCTION

Following all kinds of surgery, retained foreign bodies, most commonly sponges are encountered in the clinical setting, but are seldom reported due to medico-legal issues. The incidence is reported to range between 1/100 and 1/5000. It can be assumed that the exact incidence is higher than the reported cases. The retained surgical sponge is also called gossypiboma meaning 'hidden cotton'<sup>(1)</sup>. The most common location is intraabdominal region whereas retained sponges in mediastinum have also been reported<sup>(2,3)</sup>.

Here, we report a case with retained sponge following open heart surgery performed 35 years ago.

### CASE REPORT

A 60-year-old male patient was referred to our clinic with severe mitral valve stenosis, mitral regurgitation and intrapericardial mass. Closed mitral commissurotomy had been performed 35 years ago in another center. No reports of

detected retained sponge were found in the past medical records. He had dyspnea and fatigue due to valvular pathology. Clinical examination revealed grade 3/6 systolic murmur at the left sternal edge, the lungs were clear to auscultation. Echocardiography demonstrated left atrial dilatation, moderate to severe mitral insufficiency, severe mitral valve stenosis (MVA: 1.0 cm<sup>2</sup>) and intrapericardial paracardiac mass. Cardiac magnetic resonance imaging demonstrated a paracardiac severely calcified mass inferior to the left ventricle and inferomedial to the inferior vena cava (Figure 1). Coronary angiography demonstrated significant stenosis in the right coronary artery. Mitral valve surgery together with coronary bypass was planned.

Following femoral arterial and venous cannulation, sternotomy was performed with oscillating saw. Dissection was performed to remove the fibrotic connective tissue. A 8x5 cm mass was recognized. Because of extensive surrounding granulomatous tissue, it was difficult to remove the mass completely, so the mass was cut and removed. It was a gauze sponge

#### Correspondence

Ahmet Barış Durukan

E-mail: barisdurukan@yahoo.com

Submitted: 24.01.2013

Accepted: 11.02.2013

surrounded with granulomatous tissue without any signs of infection (Figure 1). No radio-contrast string was detected inside the sponge. Cardiopulmonary bypass was established with moderate hypothermia. Following cross clamping of the ascending aorta and delivery of antegrade intermittent cold blood cardioplegia, mitral valve replacement with 27 mm ATS mechanical prosthesis concomitant with right coronary artery bypass was performed.

The patient stayed in the intensive care unit for 48 hours. The whole postoperative course was uneventful and the patient was discharged on postoperative sixth day.

## DISCUSSION

The sponges are inert within the body, so neither absorbed nor decomposed<sup>(1)</sup>. The retained surgical sponges lead to one of the two typical reactions within the body. First is the exudative inflammatory reaction leading to abscess formation with overt findings of infection. These cases are diagnosed early in the postoperative period and sponges are removed surgically. In the second group, aseptic fibrotic reaction develops around the sponge and presents as a mass. These cases are not diagnosed unless a mass effect is present or incidental radiologic diagnosis is made<sup>(4)</sup>. But in countries like Turkey, where sponges without

radiologic string sign have been used, simple radiologic diagnosis is not always possible<sup>(5)</sup>. Development of malignant fibrous histiocytoma due to retained sponge 32 years after abdominal surgery was reported recently. The mechanism is postulated as inflammation based carcinogenesis<sup>(6)</sup>. But, the manifestations are not always clear-cut and the diagnosis is delayed due to medico-legal issues or confusing clinical presentation and non-specific radiologic findings<sup>(7)</sup>.

The case reported here was the second type; a mass was formed, but did not produce any mass effect. Radiologic diagnosis could not be made previously with plain X-ray probably due to absence of the radioopaque string in it. It was surprising that the mass was also not detected in any of the control echocardiographic examinations throughout the 35 years period, since the last visit in another center where the diagnosis of severe mitral stenosis and regurgitation was made.

Intraoperatively, the sponge could not be removed entirely, so a small portion of it was left in place due to technical considerations. It was very strongly attached to the left ventricular wall and further aggressive attempts to remove it could injure the ventricle. Since we knew that there was no infection, we left a small portion in place.

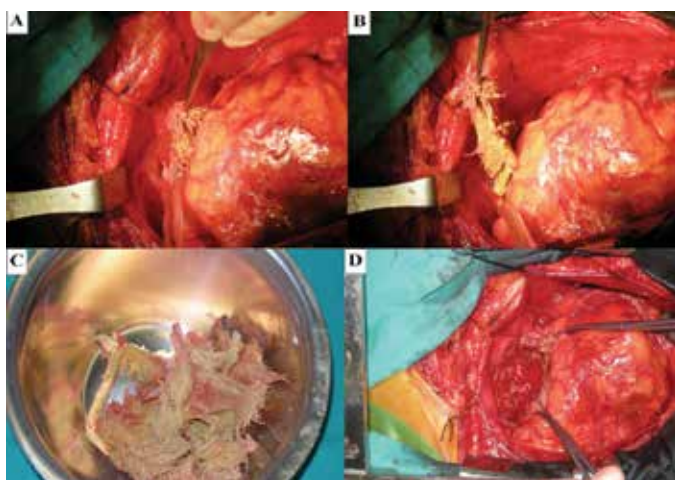
Regarding retained surgical materials, prevention strategy is much easier than the treatment. Correct counts of sponges and other surgical instruments should be done with caution and very strict protocols should be employed.

## CONFLICT of INTEREST

The authors reported no conflict of interest related to this article.

## REFERENCES

1. Sun HS, Chen SL, Kuo CK, Wang SC, Kao YL. Gossypiboma-Retained Surgical Sponge. *J Chin Med Assoc* 2007;70:511-3.
2. Poncelet AJ, Watremez C, Tack D, Noirhomme P. Paracardiac Opacity Following Inferior and Middle-Lobe Resection for Bronchogenic Carcinoma. *Chest* 2005;128;439-41.
3. Hochegger B, Zanetti G, Garcia TS, Marchiori E. Retained surgical sponge presenting as a cardiac mass. *Eur J Cardiothorac Surg* 2012;41:e129.
4. Aminian A. Gossypiboma: a case report. *Cases Journal* 2008;1:220
5. İnci MF, Özkan F, Okumuş M, Köylü A, Yüksel M. Çok nadir bir akut batın nedeni: Gossypiboma. *Dicle Tıp Dergisi* 2012;39:445-8.
6. Kaplan M, İyikosker Hİ. A new complication of retained surgical gauze: development of malignant fibrous histiocytoma--report of a case with a literature review. *World J Surg Oncol* 2012;10:139.
7. Godara R, Marwah S, Karwasra RK, Goel R, Sen J, Singh R. Spontaneous Transmural Migration of Surgical Sponges. *Asian J Surg* 2006;29:44-5.



**Figure 1.**

- a) Retained sponge is strongly attached to the posteroinferior left ventricular wall.
- b) The sponge was cut and removed with caution not to harm the ventricular wall.
- c) The removed sponge material.
- d) The pericardial cavity seen after removal of the sponge.