

URGENT SURGICAL REMOVAL OF THE LEFT ATRIAL GIANT THROMBUS (A CASE REPORT)

V. KUTAY, MD,
H. EKIM, MD,
C. YAKUT, MD,

We report an uncommon clinical observation of a 42-year-old woman with low cardiac output related to a giant left atrial thrombus which has partially occluded the mitral orifice. The patient had a previous medical history of atrial fibrillation, mitral stenosis and pneumonia. The huge left atrial thrombus was successfully removed with a concomitant mitral valve replacement and the postoperative course was uneventful. Disclosure of such a huge thrombus in the left atrial cavity requires prompt surgical treatment because of a high risk of acute hemodynamic decompensation due to the obstruction of the left ventricular inflow and systemic embolic events.

From:

Yüzüncü Yıl University,
Faculty of Medicine,
Department of
Cardiovascular Surgery,
Van, Turkey

Key words: *Giant thrombus, urgent, left atrium*

Left atrial thrombosis is usually a complication of long-standing rheumatic mitral stenosis which can have a catastrophic outcome. Fragmentation of the thrombus followed by central and peripheral embolization or occlusion of the mitral valve partially or totally may cause syncope, pulmonary edema and sudden death. In spite of the surgical correction of the mitral valve disease, factors such as atrial fibrillation, giant left atrium, low cardiac output and dehydration cause stagnation of the blood in the left atrium and consequent thrombus formation [1,2]. Massive cardiac thrombus formation and infection of an atrial and ventricular mural thrombus is very rare, with only occasional case reports in the literature [3-6]. In the present case, cardiogenic shock due to a giant left atrial thrombus associated with mitral stenosis which was treated surgically is described.

**Address for
reprints:**

Yrd.Doç.Dr.Veysel KUTAY
Yüzüncü Yıl Üniversitesi,
Tıp Fak., Araştırma Hastanesi,
Kalp Damar Cerrahi Kliniği,
Van, Türkiye
Tel: +90 432 215 04 74
Fax: +90 432 216 83 52
e-mail: vkutay@ yahoo.com

CASE REPORT

A 42-years-old woman with a one week history of dyspnea, palpitation, fatigue and fever was admitted to a hospital and has been diagnosed with mitral stenosis and lobar pneumonia. At the third day of treatment (digital, diuretics, antibiotics) the patients symptoms were getting worse, and she was referred to our hospital for the assessment of operability of mitral stenosis. On admission, physical examination revealed an irregular heart rate of 120 per minute, hypotension (75/40 mmHg), tachypnea (30 breathsper minute) and the body temperature was 38.5°C. On cardiac auscultation, the first heart sound was accentuated and a II/VI systolic murmur with diastolic rumble was heard at the apex. Electrocardiography demonstrated atrial fibrillation and the chest radiograph showed cardiomegaly with left atrial enlargement and right lung consolidations. (Figure 1)

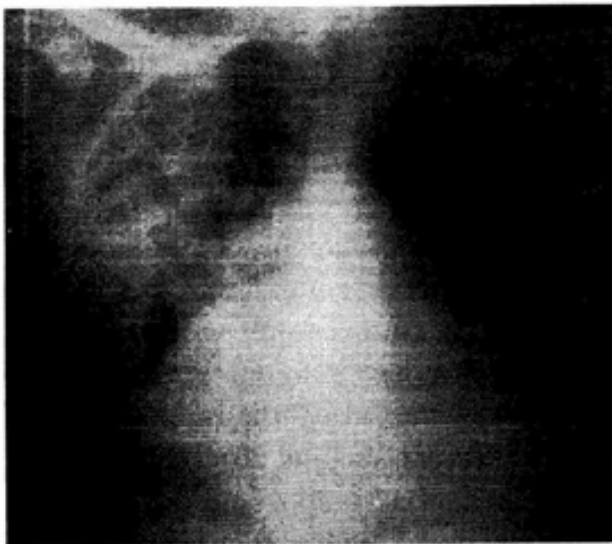


Fig 1: Preoperative telecardiogram showing cardiomegaly with marked dilated left atrium silhouette and diffuse pneumonic infiltration on right lung.

Laboratory findings revealed leukocytosis (18.700cells/ μ L), a mild anemia (Hb;11g/dl) and mild azothemia (BUN: 32mg/dl, Creatinine: 1.7mg/dl). Transthoracic echocardiography showed mitral stenosis with mild regurgitation. Mitral valve area, mean pressure gradient and pulmonary artery pressures were 1.2cm², 16mmHg and 60mmHg, respectively. The left atrium was markedly dilated 62x94mm in diameter-, which had a giant thrombus with

a floating clot. (Figure 2)

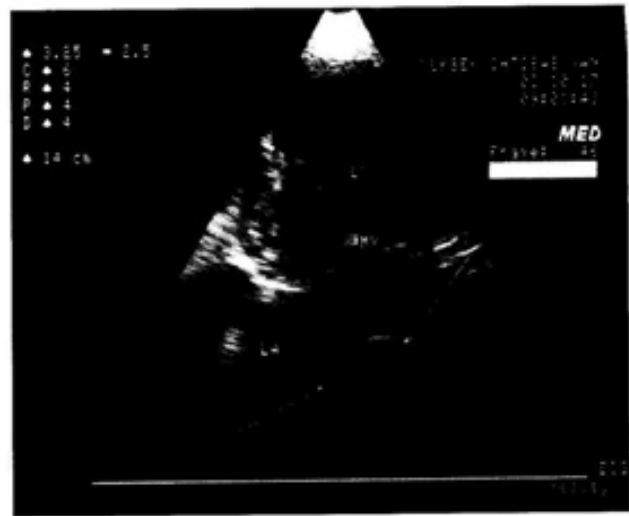

Fig 2: Transthoracic echocardiogram showing free floating thrombus filling the left atrium (LA).

We decided to take this case to operation urgently due to the fact that the giant left atrial thrombus was partially occluding the mitral orifice and the possibility of systemic embolization and also this thrombus might have been the origin of infection. Cardiopulmonary bypass was instituted by standard cannulation of the ascending aorta and bicaval with moderate systemic hypothermia. Through the left atriotomy, a fresh and huge mural thrombus was found to fill the entire left atrial cavity and was removed successfully. (Figure 3)

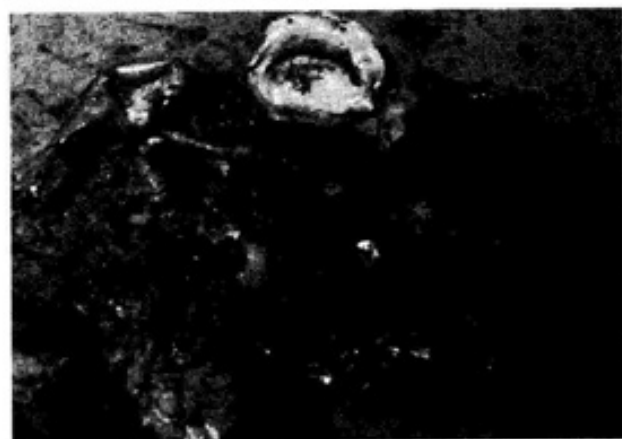

Fig 3: Operative photograph shows, giant mural and fresh left atrial thrombus with stenotic mitral valve after surgical removal approximately 7 x 8 cm in diameter.

The mitral valve demonstrated a typical rheumatic fibrotic deformation which also had spoty calcifications in the posterior annulus. The mitral valve was replaced by a 27-mm bileaflet mechanical prosthesis (St.Jude Medical, Inc, St.Paul Minnesota) and concomitantly left atrial appendix internal ligation was made with a running 3-0 polypropylene suture. Postoperative course was uneventful and postoperative anticoagulation therapy was started with heparin and followed by oral warfarin sodium, with a target international normalized ratio of between 2.5 and 3.0. Intravenous antibiotic therapy (Cefazolin sodium 4g/day) was discontinued at the postoperative seventh day and at the culture of the thrombus and blood, no microbial agent was grown. The preoperative findings of pneumonia and cardiomegaly on teleradiography improved rapidly at the postoperative third day. An antiplatelet regimen of acetylsalicylic acid (150 mg per day) was also added to the postoperative drug therapy. She was discharged on the 11th postoperative day.

DISCUSSION

The presence of a huge thrombus in the left atrium is infrequent but may lead to sudden death due to the obstruction of the mitral valve. Usual reported causes of atrial thrombi include atrial fibrillation, mitral stenosis, enlarged left atrium, low cardiac output, bradycardia and abnormal coagulability of which three of these factors were present in this case. Atrial fibrillation is an unpleasant rhythm in which the lethal and devastating effect of the rhythm lays in the large number of arterial emboli that it produces. Studies have indicated that over 90% of atrial clots are originated from left atrial appendage [7,8]. Johnson et al reported that surgical removal of the left atrial appendage should be considered to prevent the emboli and to reduce strokes [8]. In this case we have not performed a left atrium reduction procedure. We were satisfied with appendage ligation and correction of the basic mitral pathology. Antithrombin III, protein C, protein S and FXII deficiencies are

congenital blood protein defects associated with important causes of recurrent arterial thromboembolism. Recently a case of a huge left atrial thrombus with mitral stenosis was reported, which was removed surgically in a FXII deficient patient [9]. We have not detected any coagulation abnormalities and blood protein defects in our patient. The cases of left atrial ball thrombus are usually reported more often than huge and infected left atrial thrombi [2,10]. Infection of an intracardiac thrombus is very rare and several previously reported cases were associated with myocardial infarction [5,6]. In 80% of prior cases, the causative microorganisms were found in cultures from the blood and thrombus. These organisms were rather unusual among cases of native valve infective endocarditis. In the present case the blood and thrombus cultures results were negative. Infection of the cardiac thrombus has a high mortality because of the difficulty of diagnosis. The thrombus is generally a hypovascular tissue, so diffusion of antibiotics into the tissue is thought to be poor. Transthoracic echocardiography optimized by a transesophageal analysis appears to be the main primary noninvasive tool for diagnosis of the left atrial thrombus. Mobility of the thrombus remains the most important risk factor for cerebral and peripheral arterial embolic events. Therapeutic strategy depends on echocardiographic characteristics, clinical symptoms and previous medical history such as mitral valve stenosis, atrial fibrillation and giant left atrium. A single anticoagulant therapy may be an option in uncomplicated situations but considering the potential complications, surgical management is the main solution. We believed that prompt surgical removal of the thrombus should be performed followed by antithrombotic prophylaxis and postoperative prolonged administration of antibiotics.

In conclusion, we present here the case describing a giant left atrial thrombus which partially occluded the stenotic mitral orifice and resected successfully with a combined mitral valve replacement.

REFERENCES

1. Beppu S. Hypercoagulability in the left atrium: Part I: Echocardiography. *J Heart Valve Dis* 1993; 2(1):18-24
2. Wrisley D, Giambartolomei, Lee I. Left atrial ball thrombus: Review of clinical and echocardiographic manifestations with suggestions for management. *Am Heart J* 1991; 121: 1784-90
3. Okayama H, Kawasaki S, Takagaki Y, et al. Infection of left atrial thrombus associated with mitral stenosis. A case report. *Chest* 2000; 117:1201-3
4. Senior R, Raftery EB. Infection of left ventricular thrombus in a patient with silent myocardial infarction: a unique complication. *Eur Heart J* 1993; 14: 997-8
5. Venezia FR, Thompson JE, Sullivan H, et al. Infection of a ventricular aneurysm and cardiac mural thrombus: survival after surgical resection. *Am J Med* 1984; 77: 551-4
6. Cheung A, Choi A. Infection of mural thrombus: a case report and review of the literature. *J Intern Med* 1990; 227: 281-3
7. Blackshear JL, Odell JA. Appendage obliteration to reduce stroke in cardiac surgical patients with atrial fibrillation. *Ann Thorac Surg* 1996; 61: 755-9
8. Johnson DW, Ganjoo AK, Stone C, et al. The left atrial appendage: our most lethal human attachment. Surgical implications. *Eur J Cardio-thorac Surg* 2000; 17:718-22
9. Hasegawa T, Uematsu M, Tsukube T, et al. Huge left atrial thrombus with mitral stenosis in congenital factor XII deficiency. *Ann Thorac Surg* 2000; 73: 286-8
10. Minatoya K, Okabayashi H, Yokota T. Calcified ball thrombus in the left atrium. *Ann Thorac Surg* 1996; 61: 1513-4