

PSEUDOCYSTIC STRUCTURE IN THE LEFT VENTRICULAR OUTFLOW TRACT

O.K. SALİH, MD*,
M.Ş. TOPÇUOĞLU, MD*,
O.KÜÇÜKOSMANOĞLU,
MD**,
Ş.K.ÇELİK, MD*,
N.ÖZBARLAS, MD**

From: * Faculty of
Medicine, University of
Çukurova, Thoracic and
Cardiovascular Surgery
Department,

** Faculty of Medicine,
University of Çukurova,
Pediatric Cardiology
Department, Adana

**Address for
reprints:**

Orhan Kemal SALİH, MD
Department of Thoracic and
Cardiovascular Surgery,
Faculty of Medicine,
University of Çukurova,
Adana, Türkiye
Phone: 90-322-338 66 84
(ext. 3176,3177)

The present report describes a mass in the left ventricular outflow just beneath the aortic valve that resembles normal valvular tissue. Although there were no signs of circulatory obstruction, the mass was totally excised to avoid embolism and aortic valve degeneration. Pathologic examination revealed the histologic characteristics of normal valvular tissue.

Key words: cardiac tumor, subaortic mass

Cardiac masses (solid or cystic) are rarely seen in pediatric age group (1,2). They are diagnosed incidentally unless they cause cardiac symptoms. In recent years, use of echocardiography as a routine diagnostic tool disclosed many clinically asymptomatic cases (2).

The present article reports a case that had a cystic mass in the left ventricular outflow tract which was diagnosed incidentally and operated.

CASE REPORT

An eight-year-old child was referred to our hospital after a murmur was noted in routine cardiac examination in a pediatric health care center. Physical examination revealed no pathologic signs except a 2/6 systolic ejection murmur auscultated over the mesocardiac area. There were no abnormal findings in telecardiography but ECG showed a slight left ventricular hypertrophy.

2-D echocardiography examination revealed the existence of a cyst-like appearance arising from interventricular septum extending to left ventricular outflow tract. It was noticed that this cyst-like mass

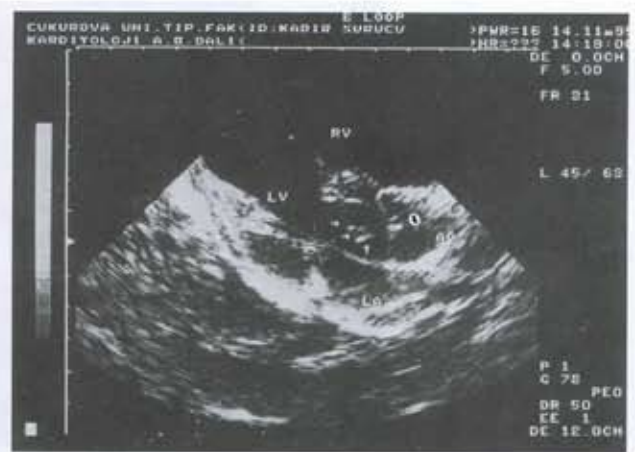
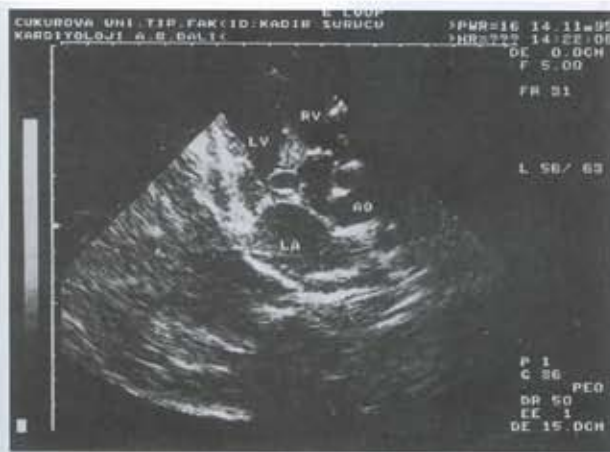
Figure 1. Echocardiographic view showing parasternal long-axis recordings during diastole (A) and systole(B). A mobile cystic appearance arising from the interventricular septum during diastole and prolapsing into the left ventricular outflow tract during systole. Ao: aorta, LA: left atrium, LV: left ventricle, RV: right ventricle

was mobile and changing its shape during diastole and systole (Fig 1). In modified parasternal long axis view, the cyst seemed to have a connection with the ventricular surface of the anterior mitral leaflet. There was an interventricular septal ridge which caused an appearance that looks like a septal malalignment. Doppler echocardiographic examination showed normal flow gradient in the left ventricular outflow tract.

The patient underwent an operation due to this cystic mass of unknown origin. The operation was performed with cardiopulmonary bypass; moderate hypothermia and cold blood cardioplegia was used. After transverse aortotomy, inspected aortic valve was completely normal. The aortic leaflets were gently retracted and a structure of 2 cm diameter and 1 mm thickness was observed in the subaortic region attached to the ventricular septum (beneath the commissure between right and left coronary cusps) and also to the other side to mitral annulus on ventricular surface of anterior mitral leaflet (beneath the commissure between left and non-coronary cusps) (Fig 2). This fibroelastic tissue did not differ from a normal aortic valve cusp. The mass was excised completely. Postoperative period was uneventful, and the patient was discharged on postoperative sixth day.

The microscopic examination of paraffin tissue section showed a valve tissue covered with flat cuboidal endothelial cells having fibromyxoid stromal cells. Immunoenzymatic evaluation revealed positive staining of endothelial cells by Factor VIII antibodies.

DISCUSSION

Several congenital structures and normal variants such as the Chiari network, Eustachian and Thebessian valves, atrial septal aneurysms, moderator bands, false tendons may simulate pathologic intracardiac masses (3). Beside these, epithelium lined cystic tumors, intracardiac teratomas, blood cysts and echinococcal cysts are the masses that look like cystic structures in echocardiogram (4-6).

Another intracardiac lesion can be an accessory atrioventricular valvular tissue that behaves like a balloon-like mass when expanded and causes subaortic stenosis (7). In the present case, although it was observed in the echocardiographic view, no cystic mass was found at the operation when subaortic area was explored. The excised piece which was a flap-like mass that resembled the valvular tissue very closely, was collapsed and lying against the mitral anterior leaflet which

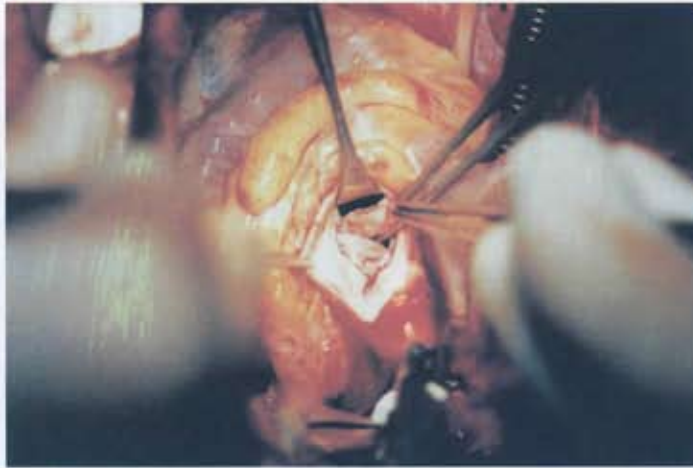


Figure 2. Operative view showing the accessory valve with shiny surface below the left coronary cusp picked up by a forceps.

was possibly the tissue that it originated from. This is a rarely found example of the pathologic mechanisms responsible for subaortic stenosis in pediatric age group (8). Other mitral valve abnormalities like cleft valve or left septal surface attachment of anterior leaflet may coexist with the masses and special effort is required not to miss them in order to avoid postoperative mitral insufficiency (7).

Any intracardiac mass, solid or cystic must be surgically removed if it has the potential to obstruct circulation or behave as a source of emboli (2) and because of the increasing risk of infective endocarditis due to turbulent flow generated by the mass. In the present case, the mass was excised although there were no signs of circulatory obstruction, since it was very mobile and so close to the aortic valve that it could cause systemic embolism and aortic valve degeneration.

REFERENCES

1. Van der Hauwaert LG: Cardiac tumors in infancy and childhood. *Br Heart J* 1971;33:125-132.
2. Fyler DC: Cardiac tumors. In: Fyler DC (ed). *Nadas' Pediatric Cardiology*. Philadelphia, Hanley&Belfus Inc, 1992:727-730.
3. Errichetti A and Weyman AE: Cardiac tumors and masses. In: Weyman AE (ed). *Principles and Practice of Echocardiography*. Philadelphia, 1994, pp1135-1175.
4. Hauser AM, Rathod K, McGill J, Rosenberg BF, Gordon S, Timmis GC: Blood cyst of the papillary muscle: Clinical, echocardiographic and anatomic observations. *Am J Cardiol* 1983;51(3):612-3.
5. Perez-Gomez AM, Duran H, Tamames S, Perrote JL, Blanes A: Cardiac echinococcosis: Clinical picture and complications. *Br Heart J* 1973;35(12):1326-1331.
6. Farooki ZQ, Adelman S, Green EW: Echocardiographic differentiation of a cystic and solid tumor of the heart. *Am J Cardiol* 1977;39:107.
7. Sellers RD, Lillehei CW, Edwards JE: Subaortic stenosis caused by anomalies of the atrioventricular valves. *J Thorac Cardiovasc Surg* 1964;48:289-302.
8. Freedom RM, Dische MR, Rowe RD: Pathologic anatomy of subaortic stenosis and atresia in the first year of life. *Am J Cardiol* 1977;39:1035-1044.