



A Case Giving Early Findings, But Diagnosed Late: Ataxia Telangiectasia Ataxia Telangiectasia Case Report

Hilal AYDIN¹, Ibrahim Hakan BUCAK², Haydar BAGIS³

¹Balıkesir University, Faculty of Medicine, Department of Pediatrics, Balıkesir, Turkey
²Adıyaman University, Faculty of Medicine, Department of Pediatrics, Adıyaman, Turkey
³Adıyaman University, Faculty of Medicine, Department of Genetics, Adıyaman, Turkey

Sorumlu Yazar / Corresponding Author: Hilal Aydin

e-mail: drhilalaydin@gmail.com Balıkesir University, Faculty of Medicine, Balıkesir, Türkiye

Geliş Tarihi / Received: 10.08.2019, **Kabul Tarihi / Accepted:** 22.01.2020

Copyright holder Balıkesir Sağlık Bilimleri Dergisi

Abstract

Ataxia telangiectasia is a neurodegenerative disease exhibiting autosomal recessive genetic transmission. The principal finding of the disease is truncal ataxia emerging in the first years. Gait imbalance and lisp were determined in an 11-year-old boy presenting due to gaze restriction. Mental retardation, dysarthric speech, truncal ataxia, titubation of the head, intention tremor in the hands, horizontal/vertical nystagmus, telangiectasia in the face/sclera, restriction in all gaze fields except for upward lateral, dysmetria, dysdiadochokinesia, and a coarse facial appearance were observed. Cranial magnetic resonance imaging revealed atrophy cerebral hemispheres. Alpha fetoprotein was elevated, at 38 ng/ml (0.9-7.6). Ataxia telangiectasia ATM gene mutation analysis reported a homozygous p. Lys1192Lys (c.3576 G>A) change on the 25th exon. This case report is intended to emphasize that ataxia telangiectasia should be the first condition considered at differential diagnosis in patients with ataxia, neuromotor retardation, telangiectasia, and ocular findings.

Keywords: Ataxia Telangiectasia, Differential Diagnosis, Nystagmus.

Erken Bulgu Veren ancak Geç Tanı Konulan Bir Olgu; Ataksi Telenjektazi

ÖZ

Ataksi-telenjektazi hastalığı otozomal resesif genetik geçiş gösteren nörodejeneratif bir hastalıktır. Bu hastalığın ana bulgusu ilk yaşlarda ortaya çıkan trunkal ataksidir. Bakış kısıtlılığı şikayeti ile başvuran on bir yaşında erkek hastada dengesiz yürüme ve peltek konuşma tespit edildi. Hastada mental gerilik, dizartrik konuşma, trunkal ataksi, başta titubasyon, ellerde intansiyel tremor, horizontal/vertikal nistagmus, yüzde ve sklerada telenjektazik damarlar, yukarı laterale bakış dışında diğer alanlarda bakış kısıtlılığı, dismetri, disdiadokinezi, kaba yüz görünümü olduğu belirlendi. Kranial magnetik rezonans görüntülemesinde her iki serebellar hemisferde atrofi tespit edildi. Alfa fetoprotein değeri 38 ng/ml (0.9-7.6) ile yüksekti. Ataksi Telenjektazi ATM geni mutasyon analizinde 25. ekzonunda bulunan p. Lys1192Lys (c.3576 G>A) değişimini homozigot olarak saptandı. Ataksi, nöromotor retardasyon, telenjektazi ve göz bulgularının olduğu hastalarda Ataksi-telenjektazi hastalığı ilk akla gelen tanılardan biri olmalıdır. **Anahtar Kelimeler:** Ataksi Telenjektazi, Ayırıcı Tanı, Nystagmus.

INTRODUCTION

Ataxia telangiectasia (AT) is a rare neurodegenerative disease exhibiting autosomal recessive genetic transmission and characterized by progressive cerebellar ataxia, ocular apraxia, cutaneous and conjunctival telangiectases, hypersensitivity to ionized radiation, immune deficiency, and an increased risk of malignancy

(Rothblum-Oviatt et al., 2016). The gene responsible for the disease is located on 11q22-23 (Chun & Gatti, 2004). The reported incidence is one in 40.000-100,000 live births. The main finding of AT is truncal ataxia emerging in the first years of life. Telangiectasias first appear at the age of two years, but cases have also been reported in which findings have not emerged until 10 years (Swift et al., 1986).

The purpose of this report is to describe methods employed in the diagnosis of physical and laboratory findings of AT in a patient examined several times with different symptoms.

CASE REPORT

An 11-year-old boy presented to the pediatric neurology clinic due to gaze restriction and dysfunction in eye movements. When a deeper history was taken, the family stated that imbalanced gait had first emerged at the age of four years, that lisping speech had developed at six years, and that tests aimed at identifying the etiology of ataxia had been performed in various centers but had been reported as normal. We learned that ocular apraxia had commenced within the previous year, that the truncal ataxia had worsened over the last six months, and that he was receiving special education due to restriction in cognitive functions. The patient's prenatal and natal histories were unremarkable, but he had received phototherapy in an incubator for two days due to neonatal jaundice.

At physical examination, his weight was 32 kg (3-10p), height 145 cm (50-75p), and head circumference 51.5 cm (0, -2 SD). His general condition was good and he was oriented. Mental retardation, dysarthric speech, truncal ataxia, titubation of the head, intention tremor in the hands, horizontal and vertical nystagmus, telangiectatic vessels in the face and sclera, restriction in all gaze fields except for upward lateral, dysmetria, dysdiadochokinesia, and a coarse facial appearance were observed (Figure 1a and Figure 1b). Other system examinations were normal. Atrophy was observed in the inferior part of both cerebellar hemispheres at cranial magnetic resonance imaging (Figure 2). VEP was within normal limits. Routine biochemistry, creatine kinase, complete blood count, thyroid function tests, B12, folate, 25 OH Vitamin D, and immunoglobulins were also within normal ranges. Alpha fetoprotein (AFP) was 38 ng/ml (0.9-7.6). Since vitamins A and E, CD3, CD4, CD8 cannot be investigated in our hospital, these tests were not sent. The genetics department was consulted with a preliminary diagnosis of AT. Following amplification of exons 19-33 using the PCR method, ataxia telangiectasia ATM gene mutation analysis (2nd stage) revealed homozygous p. Lys1192Lys (c.3576 G>A) change on the 25th exon. The patient was referred to the pediatric immunology department for close observation in terms of malignancy and sinopulmonary infection. He has currently been under observation for five months since diagnosis with no problems.

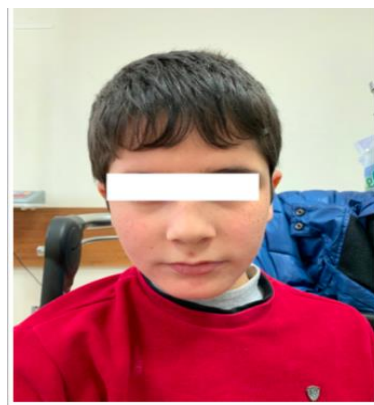

Figure 1a. Telangiectatic vessels in the face and a coarse facial appearance

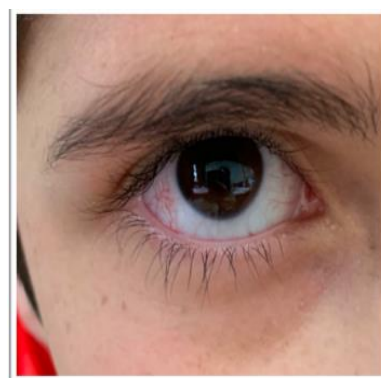

Figure 1b. Telangiectatic vessels in the sclera of Ataxia telangiectasia

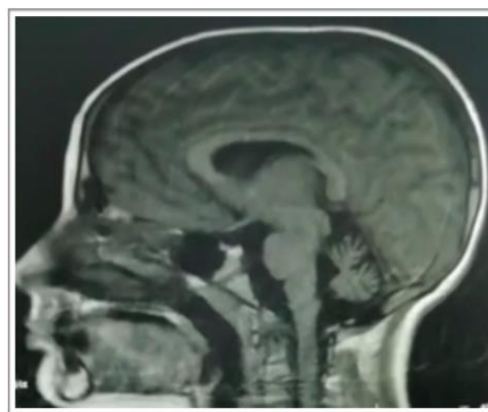


Figure 2. Atrophy was observed in the inferior part of both cerebellar hemispheres at cranial magnetic resonance imaging

DISCUSSION

AT is a rare neurodegenerative disease exhibiting autosomal recessive transmission, that begins with progressive ataxia and that subsequently manifests telangiectasias in the sclera and skin, dermatological findings (hypertrichosis, vitiligo, seborrheic dermatitis, and acanthosis nigricans), and immune failure (Lange et al., 1995). Telangiectasias are generally observed in the sclera, auricle, and the bridge of the nose, are rarely in the eyelids, neck and popliteal fossae. The principle finding of AT is ataxia. Other neurological findings include intension tremor, segmental myoclonus, oculomotor apraxia, progressive digital dystonia, and nystagmus. Ataxia begins at 6-12 months, and gait impairment generally at 9-12 years (Larry, Smith & Stephen, 1985). Imbalanced gait started at four years in our case.

Increased AFP levels after the age of two years has been described as important marker in the diagnosis of AT (Jason & Gelfand, 1979; Woods & Taylor, 1982). In agreement with the literature, AFP was above normal limits in our case. Cranial MRI findings in AT include cerebral hemisphere and vermian atrophy, and dilated ventricle and cisterna magna (Lin, Barker, Lederman & Crawford, 2014). Farina et al. reported diffuse cerebellar atrophy in 11 patients (Farina et al., 1994). In agreement with the literature, we also observed atrophy in both cerebellar hemispheres in our case. The incidence of malignancy is higher in AT than in the normal population. Lymphoid malignancies may be determined in 15% of patients with AT. T-cell and B-cell leukemia and lymphoma are also more common. T-cell malignancies may be determined at any age, while B-cell malignancies are usually seen at more advanced ages (Suarez et al., 2015). In addition to these tumors, accompanying pancreatic tumors, dysgerminomas, gastric carcinoma, and hepatic carcinoma may also be present (Rothblum-Oviatt et al., 2016). Our patient was referred to the pediatric immunology department for observation in terms of malignancy and infection.

The fact that our patient was not definitely diagnosed until the age of 11, despite having been examined by several different centers, shows that the disease can be easily missed. Yet physical examination and laboratory test results (ataxic gait, ocular telangiectasia, AFP elevation, and marked cerebellar atrophy at cranial imaging) easily suggested the diagnosis. AT is one of the first diseases that should be considered at differential diagnosis of ataxia. Several acute and chronic diseases capable of causing ataxia, a symptom of various diseases, must be considered. Causes of chronic ataxia may sometimes lead to diagnostic confusion, and are much confused with one another. In that event, diagnosis may be facilitated by evaluating other clinical cues (mental retardation, telangiectasia, a gradual degenerative course, and ocular findings) and careful history taking (recurrent infection and neuromotor development stages). Although AT was suspected based on clinical findings in our case, diagnosis was confirmed genetically.

AT should be the first diagnosis considered in patients with ataxia, neuromotor retardation, telangiectasia, and ocular findings.

Acknowledgments: The authors would like to extend their sincere thanks to anyone who contributed to this study.

Conflict of Interest: The authors declare no potential conflicts of interest with respect to the research, authorship and/or publication of this article.

REFERENCES

- Chun, H.H., & Gatti, R.A. (2004). Ataxia-telangiectasia, an evolving phenotype. *DNA Repair*, 3, 1187-96.
- Farina, L., Uggetti, C., Ottolini, A., Martelli, A., Bergamaschi, R., Sibilla, L., Zappoli, F., Egitto, M.G., & Lanzi, G. (1994). Ataxia telangiectasia: MR and CT findings. *J Comput Assist Tomogr*, 18, 724-7.
- Jason, J.M., & Gelfand, E.W. (1979). Diagnostic considerations in ataxia-telangiectasia. *Arch Dis Child*, 54, 682-6.
- Lange, E., Borresen, A., Chen, X., Chessa, L., Chlunkar, S., & Concannon, P. (1995). Localization of an Ataxia-telangiectasia gene to an approximately 500-kb interval on chromosome 11q23.1: linkage analysis of 176 families by an international consortium. *Am J Human Genet*, 57, 112-9.
- Larry, L., Smith, M.D., & Stephen, L. (1985). Ataxia-telangiectasia or Louis-Bar syndrome. *J Am Acad Dermatol*, 12, 681-696.
- Lin, D.D., Barker, P.B., Lederman, H.M., & Crawford, T.O. (2014). Cerebral abnormalities in adults with ataxia-telangiectasia. *Am J Neuroradiol*, 35(1), 119-123.
- Rothblum-Oviatt, C., Wright, J., Lefton-Greif, M.A., McGrath-Morrow, S.A., Crawford, T.O., & Lederman, L.M. (2016). Ataxia telangiectasia: a review. *Orpha J. Rare Dis*, 159.
- Suarez, F., Mahlaoui, N., Canioni, D., Andriamanga, C., Dubois d'Enghien, C., Brousse, N., Jais, J.P., Fischer, A., Hermine, O., & Stoppa-Lyonnet, D. (2015). Incidence, presentation, and prognosis of malignancies in ataxia-telangiectasia: a report from the French national registry of primary immune deficiencies. *J. Clin. Oncol*, 33(2), 202-208.
- Swift, M., Morrell, D., Cromartie, E., Chamberlin, A.R., Skolnick, M.H., & Bishop, D.T. (1986). The incidence and gene frequency of ataxia-telangiectasia in the United States. *Am. J. Hum. Genet*, 39(5), 573-583.
- Woods, C.G., & Taylor, A.M. (1992). Ataxia telangiectasia in the British Isles: the clinical and laboratory features of 70 affected individuals. *Q J Med*, 82, 169-79.

