

## Endometriosis at the incision site after cesarean procedure

### Sezaryen sonrası kesi yerinde saptanan endometriozisler

Aylin Hande Gökçe, Atakan Özkan, Feridun Suat Gökçe

Gönderilme tarihi: 03.01.2020

Kabul tarihi: 23.03.2020

#### Abstract

**Purpose:** The detection of endometrial glands and endometrial stroma outside the uterus is called endometriosis. In our study, patients diagnosed with endometriosis after cesarean section, the effects of number of previous cesarean sections, endometriosis size, age and time after cesarean were investigated.

**Materials and methods:** Patients who were operated in our clinic after cesarean between January 2012 and December 2018 and diagnosed as endometriosis were investigated retrospectively. The age, number of previous cesarean sections, time of diagnosis after a cesarean section and endometriosis dimensions of the patients were recorded. The patients were divided into Group 1 with 9 patients with a mass on the right side of the midline and group 2 with 12 patients on the left.

**Results:** Between the two groups; there were no significant differences in terms of age, previous cesarean section numbers, time to cesarean diagnosis and endometriosis size ( $p=0.795$ ,  $p=0.655$ ,  $p=0.432$ , and  $p=0.434$ , respectively). Pain was present in 90% of the cases, and mass in 86%. The majority of cases were detected after the first cesarean section, namely on average  $14.9\pm 6.8$  months.

**Conclusion:** In the diagnosis of patients presented with pain and/or mass complaints in the sub-navel region after a cesarean section, the diagnosis of endometriosis should definitely be kept in mind. In our study, the cases of endometriosis were found more to the left of the midline however the diagnosis and treatment were the same.

**Key words:** Endometriosis, incisional hernia, hematoma, abdominal pain.

Gokce AH, Ozkan A, Gokce FS. Endometriosis at the incision site after cesarean procedure. Pam Med J 2020;13:369-372.

#### Özet

**Amaç:** Endometrial glandların ve endometrial stromanın uterus dışında saptanmasına endometriozis denir. Çalışmamızda sezaryen sonrası endometriozis tanısı alan olgularda; sezaryen sayısı, endometriozis boyutu, yaş ve sezaryen sonrası geçen sürenin etkileri araştırıldı.

**Gereç ve yöntem:** Kliniğimizde 2012 Ocak-2018 Aralık ayı arasında sezaryen sonrası oluşan kitle nedeniyle ameliyat edilip patolojik olarak endometriozis tanısı konulan olgular retrospektif olarak araştırıldı. Hastaların; yaş, önceki sezaryen sayısı, sezaryen sonrası tanıya kadar geçen süre ve endometriozis boyutları kayıt edildi. Hastalar, kitlesi orta hattın sağında olan 9 olgu grup 1, solunda olan 12 olgu ise grup 2 olarak ayrıldı.

**Bulgular:** İki grup arasında; yaş, önceki sezaryen sayısı, sezaryen sonrası tanıya kadar geçen süre ve endometriozis boyutu açısından anlamlı fark saptanmadı (sırasıyla;  $p=0,795$ ,  $p=0,655$ ,  $p=0,432$ ,  $p=0,434$ ). Olguların 90%'ında ağrı, 86%'sında ise kitle şikâyeti mevcuttu. Olguların çoğunluğu ilk sezaryen sonrası, ortalama  $14,9\pm 6,8$  ay sonra saptandı.

**Sonuç:** Sezaryen sonrası göbek altı bölgede ağrı ve/veya kitle şikâyeti ile başvuran hastaların tanısında endometriozis tanısı mutlaka akılda tutulmalıdır. Çalışmamızda endometriozis olguları orta hattın solunda daha fazla saptanmakla birlikte tanı ve tedavi hepsinde aynıdır.

**Anahtar kelimeler:** Endometriozis, insizyonel herni, hematoma, karın ağrısı.

Gökçe AH, Özkan A, Gökçe FS. Sezaryen sonrası kesi yerinde saptanan endometriozisler. Pam Tıp Derg 2020;13:369-372.

Aylin Hande Gökçe, Ass. Prof. Prof., Istanbul Atlas University Medical Faculty, General Surgery, Istanbul, Turkey e-mail: ahgokce79@hotmail.com (orcid.org/0000-0003-1908-2889) (Corresponding Author)

Atakan Özkan, Ass. Prof., Istanbul Atlas University Medical Faculty, General Surgeon. Istanbul, Turkey, e-mail: atakancerrah34@hotmail.com (orcid.org/0000-0003-1729-3148)

Feridun Suat Gökçe, Surgeon Balıklı Rum Hospital, General Surgery, Istanbul, Turkey, e-mail: fsgokce70@hotmail.com (orcid.org/0000-0001-8597-5787)

## Introduction

The detection of endometrial glands and endometrial stroma outside the uterus is called endometriosis [1]. It has been known since the 1900's that endometrial tissue may exist outside the uterus [2]. The location of endometriosis is usually ovarian, peritoneum and pelvis [3]. Numerous theories have been put forward regarding the development of endometriosis. These theories include retrograde menstruation, metaplasia, venous-lymphatic metastasis, and mechanical implantation into the incision scar during surgery. As the most common operations leading to endometriosis the following can be noted, namely hysterectomy, cesarean, amniocentesis and episiotomy [3]. Patients with endometriosis occurring under the Phannenstiel incision scar most frequently are presented with painful mass complaints [4]. These cases should be differentiated particularly from the incisional hernia. In our study, cases with endometriosis under phannenstiel incision after cesarean were investigated. These cases should be differentiated from hernia in formation etiology. Our goal was to determine the importance of age, number of previous cesarean sections and how long the findings appeared after the cesarean surgery.

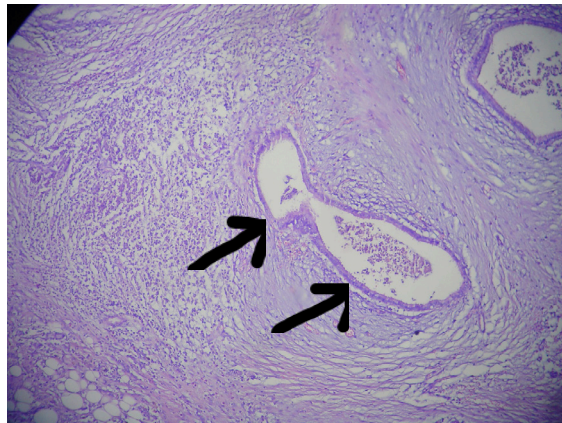
## Materials and methods

This study was conducted in accordance with the recommendations of the Helsinki Declaration, which organizes biomedical researches made on humans. Patients who were operated in our clinic after the cesarean section between January 2012 and December 2018 and whose pathological diagnoses were endometriosis were retrospectively investigated. The ethics committee approval was obtained for our study, which is a retrospective cohort (KA EK-50-Decision No: 1930). The study was conducted in accordance with the principles of the Declaration of Helsinki.

Masses consisting of multiple pregnancies, those with gynecological surgery, collagen tissue disease, and non-endometriosis causes were excluded from our research. Included in the study were patients who developed a post-cesarean incision site, had histopathology endometriosis and had performed a preoperative ultrasonography. In our clinic, the masses of the patients with a mass under the

scar location after a cesarean section were divided into group 1 to the right of the midline and group 2 to the left. The dimensions of the superficial tissue ultrasonography results of the mass were compared. The largest diameter size in measurements was accepted. The ages of the cases, how many cesarean cases were performed before and how long after the last cesarean section were investigated and compared.

The masses were removed during surgery with the surrounding tissue. The part from the operation was examined histopathologically. The preparations were stained with hematoxylin eosinophil dye. In thin sections, there is a lesion consisting of functional endometrial glands and scattered components containing ectopic endometrium, which are accompanied by dense stromal desmoplasia among the striped tissue. Endometrium glands contain old and new hemorrhages in place (Figure 1).



**Figure 1.** Microscopic view of endometriosis stained with hematoxylin eosinophil stain at 10x10 or 40x10 magnification.

## Statistical analysis

Statistical data were analyzed with SPSS (Statistical Package for Social Sciences, Windows, version 22.0) program. The Kolmogorov-Smirnov test was used to test the normal distribution for continuous variables. Continuous variables showing normal distribution Student t test was applied and on the other hand continuous variables that did not show normal distribution were compared using Mann-Whitney U test. Continuous variables were expressed as mean and standard

deviation. Chi-square test was used to compare categorical variables. A P value of less than 0.05 was considered statistically significant.

## Results

32 cases were included in the study. Three of these cases were excluded from the study on multiple pregnancies, two on lipoma, six on hematoma. The study was continued with 21 cases. According to ultrasonography results, endometriosis was divided into 9 cases (group 1) on the right of the midline and 12 cases (group 2) on the left. The mean age of group 1 was  $28.9 \pm 3.8$  years and that of group 2 was  $29.3 \pm 3.8$  years, and there was no statistically significant difference between the two groups ( $p=0.795$ ).

The reason for admission to the outpatient clinic of the cases was painful mass under incision scar in 16 (76%), only pain in 3 (14%) and only mass in 2 (10%). Thirteen of the cases in our study were after the first cesarean section, 6 were after the second cesarean section and two were the ones with endometriosis after the third cesarean section. There was no statistically significant difference in terms of the number of cesarean sections by location ( $p=0.655$ ).

It was assessed that the patients admitted to the outpatient clinic were at the earliest 6 months and at the latest 28 months after cesarean section due to mass and / or pain under the scar. The average application period was  $14.9 \pm 6.8$  months. There was no statistically significant difference between group 1 and group 2 in terms of the time to apply to the outpatient clinic ( $p=0.432$ ).

When the dimensions of the mass under the cesarean scar according to the ultrasonography result are compared the average size was found to be 27.6 millimeters. The smallest mass size was 12x16 millimeters, and the largest mass size was 48x35 millimeters. There was no statistically significant difference in terms of size according to the location ( $p=0.434$ ).

In all cases, the incision was made on the mass under general anesthesia and the rectus muscle was reached, and the mass was removed with the surrounding healthy tissue and was closed primarily. No complication was detected other than wound infection in one patient after the operation.

## Discussion

Most of the endometriosis detected in the abdominal wall is related to the previous operations of the patient. Cesarean and hysterectomy are the most common of these surgeries [5]. In studies, the rate of detection of abdominal wall endometriosis after cesarean has been reported between 0.2-1.96% [5, 6]. In our study, all cases were after cesarean sections. In their study, Pas et al found the mean age of the cases where they detected endometriosis under cesarean scar as 33.4 [7]. In our study, we found the mean age as younger as 28.9 in group 1 and 29.3 in group 2. This situation may be attributed to the earlier average gestational age in our country.

When the complaints of the patients were investigated, Ding et al stated that 65% of the patients had pain [8], and Francica et al. [9] reported a mass under the scar in 80% and reported an average size of 18.2 millimeters [9]. In our study, 90% of cases had pain and 86% had mass. In other words, pain and mass complaints were higher in patients who underwent surgery with the diagnosis of endometriosis under the scar compared to the literature review. In our study, this was attributed to the average size of the masses being 27.6 millimeters, that is, after they reached a larger diameter than the literature.

In the literature, there are detection times ranging from 9.6 to 28.7 months after cesarean delivery [7, 9, 10]. In our study, this time was  $14.9 \pm 6.8$  months on average. The time between cesarean section and endometriosis detection is compatible with the literature.

Two parameters that make a difference to our study, which could not be found when the literature research was conducted, were investigated. One of these parameters is that endometriosis detected under the scar is detected more to the left of the midline. Another parameter is the detection of the majority of endometriosis cases after the first cesarean section. As a result, it was thought that as the number of cesarean increases, the rate of fibrosis tissue increases and it may be difficult to attach endometrial tissue to the anterior abdominal wall.

In conclusion females with pain and/or mass complaints under their caesarean section scar, particularly in the masses that grow and shrink with menstrual cycles endometriosis should be considered. In cases with a mass pre-diagnosed scar, endometriosis may also occur apart from causes such as hematoma and lipoma. In cases where a fine needle aspiration biopsy is performed in patients with endometriosis, implantation is a possibility. In case the diagnosis is incisional hernia, intestinal injury can be done by biopsy. Consequently, when there is a mass under the scar a fine needle aspiration or true cut biopsy should be avoided as much as possible.

**Conflict of interest:** No conflict of interest was declared by the authors.

## References

1. Barlas D, Bozkurt S, Kaya MA, Çelik F. Rektus abdominus kası yerleşimli skar endometriyozisi. *Ulus Travma Acil Cerrahi Derg* 2010;16:371-372.
2. Gordon CW, Singh KB. Cesarean scar endometriosis: a review. *Obstet Gynecol Surv* 1989;42:89-95. <https://doi.org/10.1097/00006254-198902000-00003>
3. Hekimoğlu L, Tatlıkazan S. Incisional endometriosis after caesarean section: a case report. *Türk Aile Hek Derg* 2013;17:23-25. <https://doi.org/10.2399/tahd.12.40085>
4. Tatlı F, Gozeneli O, Uyanikoglu H, et al. The clinical characteristics and surgical approach of scar endometriosis: a case series of 14 women. *Bosn J of Basic Med Sci* 2018;18:275-278. <https://doi.org/10.17305/bjbm.2018.2659>
5. Khachani I, Adib AF, Bezaad R. Cesarean scar endometriosis: an uncommon surgical complication on the isce? Case report and literature review. *Hindawi Case Reports in Obstetrics and Gynecology* 2017;1-4. <https://doi.org/10.1155/2017/8062924>
6. Zhangand J, Liu X. Clinicopathological features of endometriosis in abdominal wall—clinical and analysis of 151 cases. *Clin Exp Obstet Gynecol* 2016;43:379-383.
7. Pas K, Joanna SM, Renata R, Skręć A, Barnas E. Prospective study concerning 71 cases of caesarean scar endometriosis (CSE). *J Obstet Gynaecol* 2017;37:775-778. <https://doi.org/10.1080/01443615.2017.1305333>
8. Ding Y, Zhu J. A retrospective review of abdominal wall endometriosis in Shanghai, China. *Int J Gynaecol Obstet* 2013;121:41-44. <https://doi.org/10.1016/j.ijgo.2012.11.011>
9. Francica G. Reliable clinical and sonographic findings in the diagnosis of abdominal wall endometriosis near cesarean section scar. *World Journal of Radiology* 2012;4:135-140. <https://doi.org/10.4329/wjr.v4.i4.135>
10. Mistrangelo M, Gilbo N, Cassoni P, Micallef S, Faletti R, Miglietta C, et al. Surgical scar endometriosis. *Surg Today* 2014;44:767-772. <https://doi.org/10.1007/s00595-012-0459-3>

**Ethics committee approval:** The study protocol was approved by Clinical Research Ethics Committee (2011-KAEK-50- Decision No).