

Right Patellar Fracture in a Patient with Left Femoral Body Fracture

Sol Femoral Cisim Kırığı Olan Bir Hastada Sağ Patella Kırığı

 Turker Demirtakan,  Nagihan Yılmaz,  Afsin Ipekci

Istanbul University-Cerrahpasa, Cerrahpasa Medical Faculty, Department of Emergency Medicine, Istanbul, Turkey.

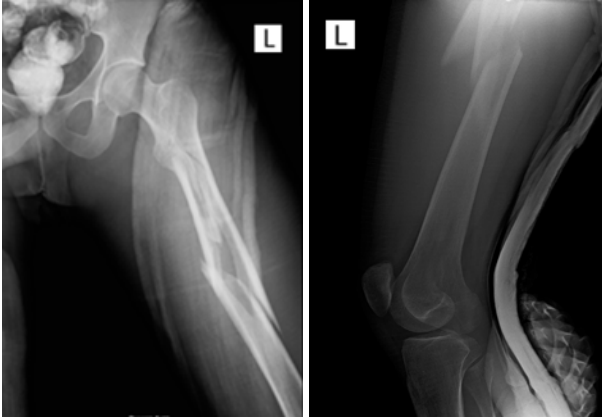


Figure1: Left femur fracture

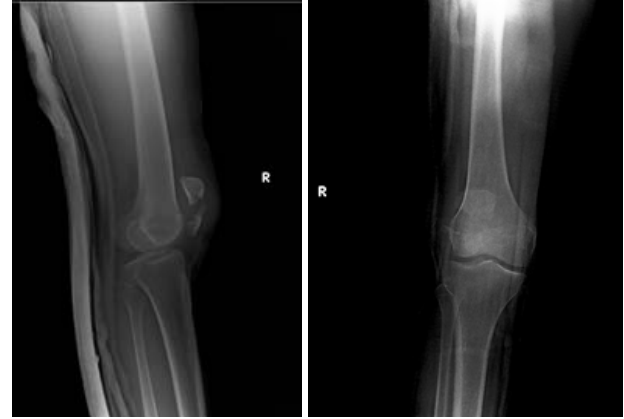

Figure2: Right patella fracture

A patellar fracture is one of the most common knee injuries, usually, after direct trauma to the knee. It represents nearly 1% of all fractures common in those ages between 20-50 years and males. (1-3) The coincidence of patellar fracture with femoral body fracture in the opposite leg is rather low frequency; moreover, it can be missed out unluckily (4). In this case, 24 years old young man is brought to the emergency department after a car accident. According to the patient's claim, he sat on the next seat of the driver without a seatbelt, and the car crashed to a truck from behind. The deformed, swollen, and painful left leg is

clearly noticed, and also the patient is complaining about mild pain on the right knee in a secondary survey. Standard anteroposterior and lateral radiographic evaluation of the left hip and thigh shows that midshaft fracture in the left femoral bone. Besides the broken left femoral body, X-ray imaging of the right knee demonstrates that the right patella separates approximately 8mm from the transverse line, multiple fragmental fractures in the upper part of the broken segment, and displacement of the articular face. Clinicians must remind this kind of accompanied minor fractures during the high-energy trauma management.

REFERENCES

1. Gwinner C, Märdian S, Schwabe P, Schaser KD, Krapohl BD, Jung TM. Current concepts review: Fractures of the patella. *GMS Interdiscip Plast Reconstr Surg DGPW*. 2016;18;5:Doc01.
2. Henrichsen JL, Wilhem SK, Siljander MP, Siljander MP, Kalma J, Karadsheh MS. Treatment of Patella Fractures. *Orthopedics*. 2018;41:747-755.
3. Della Rocca GJ. Displaced Patella Fractures. *J Knee Surg*. 2013;26:293-9.
4. Çırpar M, Türker M, Aslan A, Yalçınsozan M. İki taraflı travmatik patella kırığı: Bir olgu sunumu. *Joint Diseases and Related Surgery*, 2011;22: 110-113.

Received: 26.05.2020

Accepted: 01.10.2020

Correspondence: Turker Demirtakan, Istanbul University-Cerrahpasa, Cerrahpasa Medical Faculty, Department of Emergency Medicine, Istanbul, Turkey. E-Mail: turkerdemirtakan@gmail.com

Cite this article as: Demirkiran T, Yılmaz N, Ipekci A. Right Patellar Fracture in A Patient with Left Femoral Body Fracture. *Phnx Med J*. 2020;2(3):181.