





Aortic Dissection As the Cause of Death in a Patient Treated According to the Pre-Diagnosis of Poisoning: A Case Report

Zehirlenme Ön Tanısıyla Müdahale Edilen Olguda Ölüm Sebebi Olarak Aort Diseksiyonu: Olgu Sunumu

Özgenur KÖKEN TOK¹  Kenan KAYA²  Ebubekir Burak CELİK³  Mete Korkut GULMEN² 

ÖZ

Ani beklenmedik ölümler adli tıp günlük çalışmalarının büyük bir bölümünü oluşturmakta ve çoğunlukla kardiyovasküler sistem bozukluklarından kaynaklanmaktadır. Zehirlenmeler de ani beklenmedik ölüm sebepleri arasında sayılmaktadır. Her zehirlenme vakası adli vaka olarak kabul edilmeli ve ölüm nedeni araştırılmalıdır. Çalışmamızda acil servise endosülfan zehirlenmesi öyküsü ile başvuran olgu, zehirlenmeye yönelik yapılan tüm tıbbi müdahalelere rağmen kurtarılamamıştır. Yapılan otopside ölüm nedeni aort diseksiyonunun neden olduğu perikardiyal tamponat olarak saptanan olguyu sunuyoruz. Olgu üzerinden sunulan bu çalışmanın amacı, acil servise başvuran hastalarda önyargılı tanı yaklaşımının olumsuz sonuçlarına dikkat çekilmesi ve farkındalığın artırılmasıdır. Tanıya ayrıntılı fizik muayene, uygun laboratuvar ve radyolojik incelemeler sonrasında karar verilmesi gerektiğine dikkat çekilmektedir.

Anahtar Kelimeler: endosülfan; otopsi; aort diseksiyonu; zehirlenme

ABSTRACT

Sudden unexpected deaths constitute a large part of the daily work of forensic medicine, and these deaths are mostly caused by cardiovascular system disorders. Poisoning is also considered among the causes of sudden unexpected death. Every poisoning case should be considered as a forensic case, and the cause of death should be investigated. In this study, the patient who was admitted to the emergency department with a history of endosulphan poisoning could not be saved despite all medical interventions for intoxication. We present a case whose cause of death was found to be pericardial tamponade caused by aortic dissection at autopsy. The aim of this study, presented by the case, is to draw attention to the negative consequences of the biased diagnostic approach in patients admitted to the emergency department and to increase awareness. It is pointed out that the diagnosis should be made after a detailed physical examination, appropriate laboratory and radiological examinations.

Keywords: endosulphane; autopsy; aortic dissection; poisoning

Received: 27.05.2020; Accepted: 16.05.2021

¹ Ministry of Justice, Council of Forensic Medicine, Osmaniye, Turkey.

² Department of Forensic Medicine, Cukurova University School of Medicine, Adana, Turkey

³ Ministry of Justice, Council of Forensic Medicine, Adana, Turkey.

Corresponding Author: Özgenur Köken Tok, Ministry of Justice, Council of Forensic Medicine, Osmaniye, Turkey.
e-mail: ozgenurkokenkok@gmail.com

How to cite: Köken Tok Ö, Kaya K, Çelik EB, Gülmen MK. Aortic dissection as the cause of death in a patient treated according to the pre-diagnosis of poisoning: a case report. Ahi Evran Med J. 2021;5(2):165-168. DOI: 10.46332/aemj.743177

INTRODUCTION

Sudden unexpected deaths are constituting a big part of forensic medicine's daily works and mostly caused by cardiovascular system disorders. Sudden cardiac death (SCD) is defined as unexpected, non-traumatic death occurring within 1 hour of the onset of new or worsening symptoms (witnessed arrest) or unwitnessed, within 24 hours of last being seen alive.¹ SCD can be due to structural and functional problems, primary electrical disorders, or uncommon conditions such as trauma/infection.² Acute myocardial infarction and coronary artery diseases are the most common causes, but sudden deaths due to aortic dissection and rupture are less common.³ Aortic dissection is most common in men. It is frequently seen in adults over the age of 50.⁴ Since aortic rupture cases are very severe and progress very rapidly, compensatory mechanisms are not sufficient and mortality rate is very high.

Poisoning is also considered among the causes of sudden unexpected death. Every poisoning case should be considered as a forensic case and the cause of death should be investigated.⁵ Endosulphan is a frequently preferred pesticide. Endosulphan as a neurotoxin affects synapses, damages nerve conduction and causes toxic effects in the brain. It causes neurological symptoms such as tremor, headache, dizziness, ataxia, tonic-clonic convulsions, and unconsciousness.⁶ It can also cause gastrointestinal symptoms and metabolic disorders. All patients should be treated symptomatically. Since there is not any specific antidote, seizures can be controlled by benzodiazepine, and phenobarbital can be used if needed.⁶ In this case report from the forensic medicine community, it was aimed to raise awareness of clinical physicians about the negative consequences of the misdiagnostic approach in the patient's follow-up and treatment. It is pointed out that the best approach is a detailed examination and appropriate laboratory examinations.

CASE REPORT

It was detected that 25 years old male was fainted during spraying his garden and was taken to the hospital. During his physical examination, unconsciousness, dilated pupils, lack of light reflex were detected. He had a Glasgow coma

scale score of 3, tension arterial of 60/30 mmHg and weak pulse. He did not have a known disease in his anamnesis taken from his relatives. As a result of the crime scene investigation and the examination of the sprayed substance, an endosulphan group substance was detected. He was intubated due to shallow respiration right after that electrocardiogram had showed cardiac arrest. He was resuscitated with cardiac massage and medical therapy. A pre-diagnosis of poisoning was considered, and gastric lavage was performed by placing a nasogastric tube. Benzodiazepines were used for treatment. During his medical treatment, he was arrested, then atropinized, defibrillated, and died the same day without responding to resuscitation. He was taken to the morgue of the Forensic Medicine Institute for a medico-legal autopsy. In the external examination of the body, it was observed that there was postmortem hypostasis in the face area. No trauma finding was detected. In the performed medico-legal autopsy, no macroscopic pathology was observed in the brain-cerebellum surface and sections in the medico-legal autopsy. Heart was weighed 380 grams, and 400 cc bloody fluid was detected in the pericardial sac. Right ventricular wall thickness was 0,7 cm and left ventricular was 1,6 cm. Coronary arteries and myocardial sections were viewed naturally. There was a 2 cm dissection at his aortic knob. Other chest and abdominal organs were evaluated as normal. In the results of toxicological analysis of samples which obtained in autopsy, 143 ng/ml active substance which belongs to benzodiazepine family and an antidepressive drug (diazepam) was detected in the blood, and no other substance was detected. The cause of death according to autopsy result was determined as pericardial tamponade which caused by aortic dissection (Figure 1,2). This scientific article was written after the consent of the relatives of the funeral.

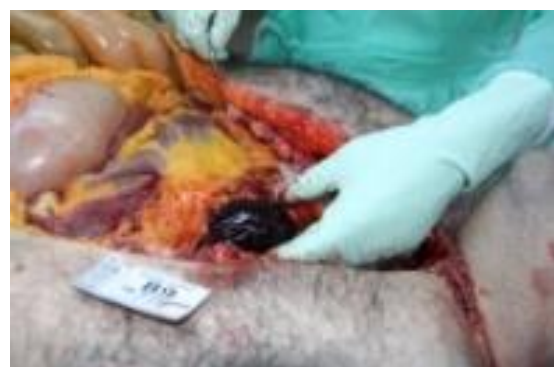

Figure 1. 400 cc bloody fluid was detected at his pericardial sac

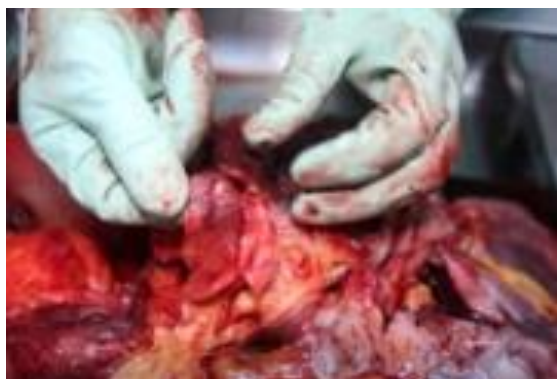

Figure 2. Aortic dissection

DISCUSSION

In the emergency department, the first intervention and treatment plan was determined according to anamnesis. This case was complex; therefore, the anamnesis led us to consider endosulphan poisoning rather than cardiovascular pathologies. However, as a result of the medico-legal autopsy, the cause of death was determined as cardiac tamponade due to aortic dissection. There was no sign of intoxication in the toxicology report. This situation caused a confusion. There may be a couple of possibilities which caused undetected endosulphane level at his toxicology report. In patients living in rural areas and presenting with signs and symptoms of central nervous system toxicity, the possibility of intoxication should be considered before cardiac diseases. However, the majority of healthcare institutions do not have the necessary equipment for the identification of the poison agent. Therefore, in such cases, all techniques and facilities available for diagnosis and treatment should be used. The most common physician mistake is the misdiagnosis that is made without fully evaluating the signs and symptoms. For this reason, the best approach to patients who apply to emergency and outpatient clinics is to make a decision after detailed examination and appropriate laboratory examinations.⁷ During the diagnostic approach, all of the reachable resources must be used. If misdiagnosis occurs due to the lack of using all of the reachable resources, it is accepted as fault. Chosen treatment must be suitable to the current agreeable rules of medicine. Following the patient and improvement of disease closely and taking necessary precautions are obligatory for preventing risky and dangerous results. In our case, endosulphane poisoning diagnosis was a result of the preconception diagnostic

approach. Even though endosulphane intoxication was one of the differential diagnoses, the first thing to consider must be cardiovascular pathologies. Aortic dissection was not diagnosed for endosulphane poisoning. Acute aortic dissection has high mortality, and delay in diagnosis increases the hourly mortality by 1%.⁶ Accurate and rapid diagnosis can reduce the mortality rate below 50%.⁶ Therefore, early diagnosis is an important factor affecting the prognosis in these cases. In the presented case, gastric lavage and the use of activated charcoal as a result of the pre-diagnosis of poisoning created an unfortunate situation for the diagnosis of aortic dissection. Diagnoses at extreme points and even the least frequent diagnoses must be always considered.

An autopsy should be requested in all cases where an unexpected death or cause of death is unclear.⁸⁻⁹ There is always the possibility of a certain percentage of error if the cause of death is decided only by external examinations and information. Even if there is a definite opinion about the cause of medical death, and there is no unusual situation (e.g., clinical cancer disease), autopsy can be extremely useful. A delayed or missed diagnosis and an incomplete or incorrect treatment can cause death. Understanding these at the autopsy does not directly benefit the deceased. What is expected from the autopsy is to learn lessons from untimely deaths and save the lives of other patients in a similar situation.

Conflict of Interests

The authors declare that there is no conflict of interests.

Authors' Contributions

Concept/Design: ÖKT, KK. Data Collection and/or Processing: ÖKT, KK, EBC. Data analysis and interpretation: ÖKT, KK. Literature Search: ÖKT. Drafting manuscript: ÖKT, KK. Critical revision of manuscript: ÖKT, KK, MKG. Supervision: MKG.

REFERENCES

1. Basso C, Aguilera B, Banner J et al. Guidelines for autopsy investigation of sudden cardiac death:2017 update from the Association for European Cardiovascular Pathology. *Virchows Archiv*, 2017;471(6):691-705.

2. Sherwin ED, Berul CI. Sudden Cardiac Death in Children and Adolescents. *Cardiac Electrophysiology Clinics*. 2017;9(4):569-579.
3. Koç S, Çetin G, Kolusayın Ö, Sarı H. Adli otopsilere saptanan patolojik nitelikteki ölümler. I. Adli Bilimler Kongresi. Kongre kitabı. Adana 1994:242-244.
4. Dimairo V, Dimairo D. Death Due to Natural Disease. In: *Forensic Pathology*. 2nd. Edition. Washington; 2001:57-58.
5. Basso C, Corrado D, Thiene G. Cardiovascular causes of sudden death in young individuals including athletes. *Cardiol Rev*. 1999;7(3):127-135.
6. Yağmur F, Din H, Özbek A, Kaya M. Sudden Death Due To Rupture Of Dissection Of The Aorta: Three Cases. *Duzce Med J*. 2010;12(3):68-71.
7. Tuğcu H, Öngürü Ö, Özaslan A, Ulukan MÖ, Celasun B. A Case of Sudden Death Due to Rupture of Dissecting Aortic Aneurysm, *Gulhane Med J*. 2003;45(4):371-375.
8. Shkrum MJ, Ramsay DA. The Complete autopsy, the management of risk, in Shkrum MJ, Ramsay DA. *Forensic Pathology of Trauma*. New Jersey: Humana Press Inc; 2007:1-22.
9. Nashelsky MB, Lawrence CH. Accuracy of cause of death determination without forensic autopsy examination. *Am J Forensic Med Pathol*. 2003;24(4):313-319.