

Pathophysiology and management of radiation-induced lumbosacral plexopathy

Radyasyona bağlı lumbosakral pleksus hasarının patofizyolojisi ve tedavi seçenekleri

Erkan TOPKAN, Hüseyin Cem ÖNAL, Ali Aydın YAVUZ, Melek Nur YAVUZ

Başkent Üniversitesi Tıp Fakültesi, Radyasyon Onkolojisi Anabilim Dalı

Radiation-induced lumbosacral plexopathy (RILP) is a rare but severely debilitating side effect of abdominopelvic irradiation, which is used in the management of a myriad of primary and metastatic tumors involving the abdominal, pelvic and retroperitoneal regions. Although the exact mechanism of RILP is not yet clearly elucidated, postulated mechanisms include radiation-induced vascular injury and radiation fibrosis leading to axonal damage and entrapment of nerves/small vessels, respectively. Effects of radiation are suggested to be correlated to the dose per fraction and total dose of radiation therapy (RT), use of radiosensitizing agents, RT technique, and concurrent administration of chemotherapy. Furthermore, the risk of RILP occurrence particularly increases with intracavitary and intraoperative brachytherapy applications. In the current review, we aimed to summarize the latest literature considering aspects of the pathophysiology, clinical features differential diagnosis, and treatment of this debilitating complication.

Key words: Pathophysiology; radiation-induced lumbosacral plexopathy; treatment.

Radyasyona bağlı lumbosakral pleksus hasarı, karın, pelvis ve retroperiton bölgesinden köken alan primer tümörlerin ve ya bu bölgeleri tutan metastatik tümörlerin radyoterapisi (RT) ardından ender görülen, hasta yaşam kalitesini olumsuz yönde etkileyen bir yan etkidir. Radyasyona bağlı lumbosakral pleksus hasarının oluşum nedenleri tam olarak açıklığa kavuşturulamamış olmasa da öne sürülen mekanizmalar akson hasarına neden olan radyasyon nedenli vasküler hasar ve radyasyon fibrozisi sonrası vasküler yapılar ve sinirlerin sıkışması şeklinde açıklanmaktadır. Klinik tablonun gelişiminde etkisi olabilecek faktörler, fraksiyon büyüklüğü ve toplam radyasyon dozu, RT tekniği, radyasyon duyarlaştırıcılarının kullanımı, eşzamanlı kemoterapi uygulanması ve özellikle intraoperatif veya intrakaviter RT şeklinde bildirilmektedir. Bu yazıda, oldukça nadir bir klinik durum olan radyasyona bağlı lumbosakral pleksus hasarının patofizyolojik ve klinik özellikleri, ayırıcı tanıda yer alan hastalıklar ve tedavi seçenekleri son literatür bilgileri ışığında özetlendi.

Anahtar sözcükler: Patofizyoloji; radyasyona bağlı lumbosakral pleksus hasarı; tedavi seçenekleri.

Radiation therapy (RT) is an effective treatment modality that is commonly used in the management of a myriad of primary or metastatic abdominal and/or pelvic tumors. However, when directed toward management of the malignancies of these regions, RT can result in a variety of complications, including radiation-induced lumbosacral plexopathy (RILP), which has severe detrimental effects on patient quality of life (QoL). RILP is reported particularly in patients treated for uterine, cervical, ovarian, and testicular cancers, as well as lymphomas. RILP is rare, with

an incidence range of 0.3-1.3%.^[1,2] It is more common in patients treated with abdominal irradiation than those treated with pelvic irradiation, with reported incidences of 0.3% and 1.3%, respectively.^[2] Median age at the time of presentation is 47.5 years (range: 34-68 years), with no noted predilection toward any racial group, and a male-to-female ratio of 1:1.2.

In this review, we summarize the latest evidence considering the pathophysiologic and clinical features and treatment of RILP, a rare but severely debilitating side effect of RT.

Anatomy and Pathophysiology

Anatomically, the lumbosacral plexus is composed of two major bundles of nerve root portions: 1) lumbar plexus (L₁-L₄) and 2) sacral plexus (L₅-S₁). These two trunks are connected by the lumbosacral trunk (L₄-L₅). The L₁-L₄ nerve roots transverse through the psoas muscle and then coalesce into the lumbar plexus, which then divides into anterior and posterior divisions. The first three nerves of the seven major branches of the lumbar plexus provide both the motor and sensory innervation to the abdominal wall. The next three nerves innervate the anteromedial part of thigh, and the femoral nerve, a major branch of the lumbosacral plexus, terminates in the saphenous nerve, which provides sensation along the medial aspect of the leg.

Similar with the lumbar plexus, the sacral plexus (L₅-S₁) also divides into anterior and posterior divisions, and a number of peripheral nerves providing sensory motor innervations to the posterior hip girdle, thigh, and anterior and posterior leg emerge from these two divisions. The five major branches are superior gluteal, inferior

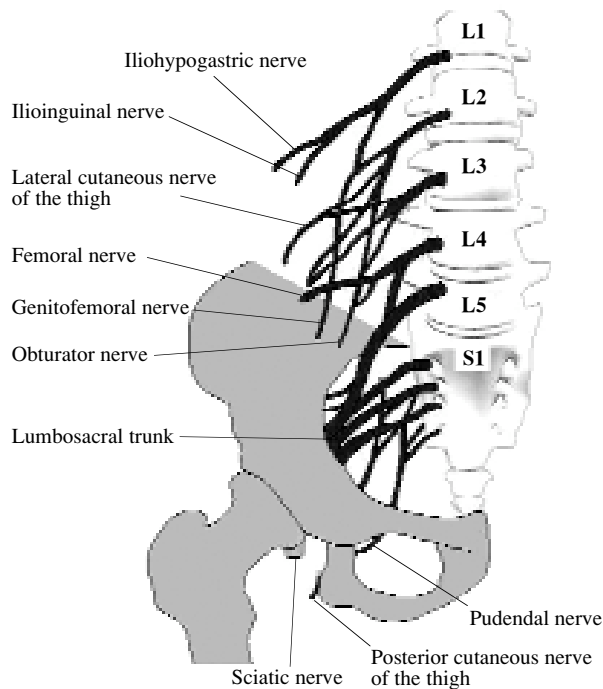


Fig. 1. Simplified anatomical presentation of the lumbosacral plexus and the principal nerves originating from it.

gluteal, posterior femoral cutaneous, sciatic, and pudendal nerves. The sciatic nerve further divides into the common peroneal and tibial nerves in the thigh. The simplified anatomical structure of the lumbosacral plexus H is schematized in Fig. 1.

The pathophysiology of lumbosacral plexopathy can be discussed as two separate but commonly interrelated entities: 1) neoplastic lumbosacral plexopathy (NLSP) and 2) RILP.

Excluding their involvement with the same neural structures, NLSP and RILP are two separate disease conditions with distinct clinical and pathophysiologic characteristics. Lumbosacral plexus involvement occurs most commonly due to intra-abdominal tumor extension (73% of cases), and less commonly with growth from metastases, lymph nodes, or bone structures.^[3] Tumors may invade the plexus directly or track along the connective tissue or epineurium of nerve trunks. The most prevalent tumor types are colorectal (20%), sarcomas (16%), breast (11%), lymphomas (9%), and cervical (9%). Other tumors, including multiple myeloma, account for another 35%.^[3] The most common metastatic lesions originate from breast cancer. In one study, the lumbosacral plexus was involved in 50 of 2261 cases of cervical cancers; however, it was involved in 38 of the 74 patients (51%) in the subgroup with proven retroperitoneal metastasis.^[4]

Lower plexus involvement is more frequent (50%) compared to upper plexus (33%), and the remaining 17% present as panplexopathy. Bilateral plexopathy is reported in 25% of cases, and is usually associated with metastasis from breast cancer. The lower (sacral) plexus involvement generally occurs with colorectal and cervical neoplasms.^[3] Involvement of the sacral sympathetic nerves is less common (10%). Lumbosacral plexopathy may present as malignant psoas syndrome, which is a specific type of proximal lumbosacral plexopathy, first described by Stevens in 1990.^[5] It is characterized by the presence of severe and intractable pain caused by proximal lumbosacral plexus involvement, painful fixed flexion in the ipsilateral hip, and radiologic/histopathologic evidence of malignant involve-

ment of the ipsilateral psoas major muscle.

The lumbosacral plexus may be invaded by malignant tumors directly or through the track along the connective tissue or epineurium of nerve trunks. Alternatively, the tumor mass can cause compression on nerve trunks with resultant significant pain, sensory disturbance, weakness, and disability. Plexus involvement develops as a result of tumor extension or invasion, and heralds a progressive disease course. Furthermore, signs of lumbosacral plexopathy may be part of the initial presentation of cancer in 15% of patients with malignant primaries.^[3]

The predisposing factors and the exact mechanism of RILP development have not yet been clearly elucidated. Nevertheless, effects of radiation are suggested to be correlated with the dose per fraction and total dose in use, concurrent administration of radiosensitizing and/or chemotherapeutic agents, and RT technique.^[1,6,7] Furthermore, the risk of RILP development particularly increases with intracavitary and intraoperative brachytherapy applications.^[6] Although not yet clear, mechanistically RILP has been suggested to be associated with the combination of localized ischemia and subsequent soft tissue fibrosis caused by microvascular insufficiency. With doses above 10 Gy, pathologic changes can be seen in Schwann cells, endoneurial fibroblasts, vascular cells, and perineural cells. Injury to anterior and posterior nerve roots in rodents has been demonstrated with doses of 35 Gy.^[8] The minimum RT dose associated with development of RILP has not been determined yet, but the mean dose to the periphery of the pelvic inlet at the level of the lumbosacral plexus was calculated to be 73 Gy in four women with cervical cancer, who experienced this complication in 8 to 24 months following completion of definitive RT.^[6] However, in the report of Abu-Rustum et al.,^[9] the total dose to the lumbosacral plexus was calculated to be 57.08 Gy, and the onset of plexopathy was much shorter, at just 10 weeks. This finding contradicts the current evidence, which suggests an interval period of six months or more from completion of RT.^[10]

In patients with NLSP, symptoms are rapidly

progressive, which may lead to death in 5.5 months after the establishment of diagnosis,^[3] whereas RILP characteristically has more gradual symptom progression.^[2] Clinical manifestations of RILP have been reported to present in three months to 22 years after the completion of RT.^[11-14] In one study, Jaeckle and associates found that 20% of patients developed moderate or even severe weakness over six months,^[15,16] and others reported that the majority of patients had mild weakness at 4-5 years following the onset of neurological symptoms.^[2,17]

Clinical Features

In patients with a history of prior RT and initial symptoms of RILP, a recurrent tumor may need to be distinguished from the radiation-induced plexopathy. The median symptom-free interval from treatment to the occurrence of initial neurological symptom is five years (range: 1-31 years). Although ultimately it is noted in as many as 50% of cases, most patients commonly present with painless weakness in one or both legs, and pain is present initially in only 10% of patients.^[2] Compared with brachial plexopathy, the incidence of initial pain is lower, and rarely produces severe intractable problems. However, when present, the pain is described in varying forms, such as aching, pulling, burning, lancinating, and cramping.

Another characteristic finding of RILP is the presence of asymmetric lower extremity weakness or paralysis, which may occur acutely a few weeks after the completion of pelvic irradiation, as noted in cervical carcinoma patients treated with RT.^[9] However, further bilateral weakness or lower extremity paraplegia may develop subsequently in the late period of follow-up. Sensory loss eventually occurs in 50-75% of patients and is more severe with greater motor impairment, which can significantly add to disability.^[2] Although the urinary and rectal functions are commonly preserved, fecal and urinary incontinence of presumed plexopathy has been reported in a number of cervical carcinoma patients treated with pelvic irradiation.^[18]

On physical examination, motor deficits in the lower extremities are typically bilateral (80%) and

asymmetric. Diffuse limb weakness with distal predominance in L₅-S₁ distribution is reported in 55% of patients, whereas exclusive proximal paresis, in the distribution of L₂-L₄, and femoral neuropathy are less common, occurring in 10% and 5% of patients, respectively.^[2,3] Moderate weakness is present in 50% of patients, with equal distribution of mild and severe weakness. Deep tendon reflexes are almost always abnormal at the knees, ankles, or both, and usually present bilaterally. Sensory impairments are present in most patients (75%) and more often are bilateral. The distal lower extremities are affected more frequently compared to their proximal counterparts, without a preference to a specific sensation type. Impaired deep sensation occurs with severe superficial sensory loss with accompanying skin changes in areas of radiation portals.

Diagnostic Work-Up and Differential Diagnosis

Routine spine and pelvis radiographs and myelograms have no diagnostic value. In addition to clinical findings, the diagnosis of RILP can be enhanced with studies such as computerized tomography (CT) scans and magnetic resonance imaging (MRI) of the pelvis. In this setting, MRI is more sensitive than CT in differentiation of RILP from tumor recurrences.^[19] Generally, RILP does not produce contrast enhancement in involved neural structures, while enhancement of nerve roots and T2-weighted hyperintensity usually suggest the presence of a tumor mass. Positron emission tomography (PET) scan with 2-fluorodeoxyglucose may further help in differentiation of recurrent tumors. Electromyography (EMG) reveals myokymic discharges in most patients (57%); however, many years pass before such changes become apparent, and furthermore, absence of myokymia does not exclude radiation injury. EMG in clinically weak muscles may also reveal fibrillation potentials (i.e., chronic neurogenic motor unit changes with decreased recruitment). Paraspinal involvement occurs in 50% of cases, and compound muscle action potential of motor nerves may be reduced.^[20,21]

Differential diagnosis of RILP is extremely important as it determines the treatment of choice.

As depicted in Table 1, it includes a myriad of malignant and benign disease conditions as well as traumatic injury to the lumbosacral plexus.

Treatment

Treatment of RILP is exceedingly difficult and at present there are no guidelines to follow. However, a multidisciplinary cooperative approach including radiation oncologists, physiotherapists, and algologists may be helpful.

Physical Therapy: Strengthening of the muscles of the lower extremities, use of ambulatory assistive devices (e.g., cane, walker), and gait training should be considered for patients with weakness and proprioceptive feedback loss. Furthermore, use of orthotics may be beneficial in certain individuals with RILP, and may improve patient QoL.

Occupational Therapy: The patient's ability to perform activities of daily living should be supported with appropriate assistive devices. Specifically, safety with standing transfers may be impaired with more distal involvement, whereas sit-to-stand transfers may also be affected with more proximal involvement. Strengthening exercises, along with sensory re-education techniques, may be employed.

Table 1

Differential diagnosis

Neoplastic Lumbosacral Plexopathy
Meningeal Carcinomatosis (Leptomeningeal Disease)
Chemotherapy Toxicity Associated with Intra-Arterial Treatment
Diabetic Lumbosacral Plexopathy
Lumbar Degenerative Disk Disease
Mononeuritis Multiplex
Thrombocytopenic Retroperitoneal Bleeding
Aortic Aneurysms
Obstetric Procedures
Intragluteal Injections
Primary Plexus Tumors
Epidural Cord Compression
Anticoagulation Therapy
Surgical Intervention for Mesenteric Thrombosis
Kidney Transplantation
Tuberculosis
Trauma
Idiopathic

Pharmacological Treatment: The principle treatment of RILP is symptomatic. Effective pain control can generally be achieved with the use of non-opiate medications, such as tricyclic antidepressants or antiepileptic agents (e.g., gabapentin, carbamazepine). However, in cases with severe and resistant pain, use of steroids and opiates, including methadone, should be considered.

Tricyclic antidepressants have central and peripheral anticholinergic effects, as well as sedative effects, and block the active re-uptake of nor-epinephrine and serotonin. Amitriptyline in 10-100 mg PO q.i.d. dosage may produce effective analgesia.

Pain control is an essential component of RILP management. Analgesics may ensure patient comfort, promote pulmonary function, and cause sedation, which are beneficial for patients who experience pain. Morphine sulfate is such a drug that is used to control short-term acute and chronic moderate to severe pain. It is available in immediate (3-4 h duration) and extended-release preparations (12 h). Switch-over to long-acting preparations should be considered once pain is controlled with short-acting preparations for patients comfort. Tolerance may develop with repeated administration, and abrupt cessation or sudden reduction in dose with prolonged use may result in withdrawal symptoms. Furthermore, morphine can produce drug dependence and has potential for abuse, but physical dependence should not be of paramount importance in terminally ill patients. A 30 mg PO q3-4h initial dose in opiate-naive patients or those with limited opiate exposure may be titrated upward by 50% until achieving adequate pain control. Methadone may be considered as an alternative in patients with resistant severe pain. Methadone inhibits ascending pain pathways, and diminishes both the perception and response to pain. It may be used in 5-20 mg PO/IM/SC q3-8h.

Muscle relaxants act by inhibiting the events involved in muscle contraction. In cases of spasmodic pain, methocarbamol, which reduces nerve impulse transmission from the spinal cord to skeletal muscle, should be considered in appropriate divided doses.

Antiepileptic drugs may be used to manage severe muscle spasms and provide sedation in neuralgia. Pregabalin, which is a structural derivative of gamma amino butyric acid (GABA), binds with high affinity to alpha2-delta calcium channel subunit, and reduces calcium-dependent release of several neurotransmitters, possibly by modulating the calcium channel function. It may be used for controlling neuropathic pain. Although its exact mechanism of action has not yet been determined, a similar drug is gabapentin, which has anticonvulsant and antineuralgic actions. Structurally, it is related to GABA but does not interact with GABA receptors. A dose of 300 to 3600 mg/d PO divided tid/qid may be used to control neuropathic pain of plexopathies including RILP.

Other therapeutic options include transcutaneous electrical nerve stimulation (TENS), hyperbaric oxygen therapy, and the use of anticoagulant drugs. TENS may produce effective pain control in some patients. Although not studied in patients with RILP, and despite some improvement noted particularly in warm sensory threshold with its use, hyperbaric oxygen therapy has been demonstrated to not reverse the symptoms of radiation-induced brachial plexopathy.^[13,22] Anticoagulant therapy, when administered for a period of 3-6 months, has been demonstrated to induce partial recovery of motor functions in a small group of patients.^[23]

Prognosis

NLSP progresses much faster than RILP, and the survival is relatively more limited. Median survival is 5.5 months from the time of diagnosis, with a range of 1-34 months.^[3] In contrast with NLSP, gradual, rather than stepwise, progression of the disease is the rule in RILP. Eventually, patients may have significant or severe disability, and spontaneous neurological recovery is uncommon. Thus, besides therapeutic measures, patient education about the effects of radiation and the reasons for altered function, pain, and sensory deficits is exceedingly important in those in whom treatment with abdominal and/or pelvic irradiation is planned.

Conclusions

Radiation-induced lumbosacral plexopathy is a rare but severe complication of abdominal and/or pelvic irradiation, which is frequently used for the management of various primary and metastatic tumors of these regions. This debilitating complication is rarely encountered by oncologists and it is extremely difficult to treat when diagnosed, since no proven effective treatment measure exists at present. Thus, the principle treatment of RILP remains symptomatic. We believe that oncologists must be alert about its development in patients undergoing abdominal and/or pelvic RT, and when diagnosed, a multidisciplinary cooperative treatment team including radiation oncologists, physiotherapists, and algologists must be involved. Pain control, gait education, rehabilitation targeted at preserving existing muscle strength and functions, and assistive devices to increase patient QoL should be considered.

References

- Ashenhurst EM, Quartey GR, Starreveld A. Lumbosacral radiculopathy induced by radiation. *Can J Neurol Sci* 1977;4(4):259-63.
- Yadav RR. Radiation-induced lumbosacral plexopathy. <http://www.emedicine.com/pmr/topic122.htm>.
- Yadav RR. Neoplastic lumbosacral plexopathy. <http://www.emedicine.com/pmr/topic90.htm>.
- Saphner T, Gallion HH, Van Nagell JR, Kryscio R, Patchell RA. Neurologic complications of cervical cancer. A review of 2261 cases. *Cancer* 1989;64(5):1147-51.
- Stevens MJ, Gonet YM. Malignant psoas syndrome: recognition of an oncologic entity. *Australas Radiol* 1990;34(2):150-4.
- Georgiou A, Grigsby PW, Perez CA. Radiation induced lumbosacral plexopathy in gynecologic tumors: clinical findings and dosimetric analysis. *Int J Radiat Oncol Biol Phys* 1993;26(3):479-82.
- Liao Z, Komaki R, Milas L, Yuan C, Kies M, Chang JY, et al. A phase I clinical trial of thoracic radiotherapy and concurrent celecoxib for patients with unfavorable performance status inoperable/unresectable non-small cell lung cancer. *Clin Cancer Res* 2005;11(9):3342-8.
- Bradley WG, Fewings JD, Cumming WJ, Harrison RM. Delayed myeloradiculopathy produced by spinal X-irradiation in the rat. *J Neurol Sci* 1977;31(1):63-82.
- Abu-Rustum NR, Rajbhandari D, Glusman S, Massad LS. Acute lower extremity paralysis following radiation therapy for cervical cancer. *Gynecol Oncol* 1999;75(1):152-4.
- Aho K, Sainio K. Late irradiation-induced lesions of the lumbosacral plexus. *Neurology* 1983;33(7):953-5.
- González-Caballero G, Arroyo-González R, Vázquez-Pérez AV, de las Heras V, González-Gutiérrez JL. Lumbosacral plexopathy 15 years after radiotherapy for carcinoma of the cervix. [Article in Spanish] *Rev Neurol* 2000;30(1):97. [Abstract]
- Numata K, Ito M, Uchiyama S, Kobayashi I, Takemiya T, Maruyama S. A case of delayed radiation lumbo-sacral plexopathy. [Article in Japanese] *No To Shinkei* 1990;42(7):629-33. [Abstract]
- Videtic GM, Venkatesan VM. Hyperbaric oxygen corrects sacral plexopathy due to osteoradionecrosis appearing 15 years after pelvic irradiation. *Clin Oncol (R Coll Radiol)* 1999;11(3):198-9.
- Dahele M, Davey P, Reingold S, Shun Wong C. Radiation-induced lumbo-sacral plexopathy (RILSP): an important enigma. *Clin Oncol (R Coll Radiol)* 2006;18(5):427-8.
- Jaekle KA, Young DF, Foley KM. The natural history of lumbosacral plexopathy in cancer. *Neurology* 1985;35(1):8-15.
- Jaekle KA. Neurological manifestations of neoplastic and radiation-induced plexopathies. *Semin Neurol* 2004;24(4):385-93.
- Pettigrew LC, Glass JP, Maor M, Zornoza J. Diagnosis and treatment of lumbosacral plexopathies in patients with cancer. *Arch Neurol* 1984;41(12):1282-5.
- Iglicki F, Coffin B, Ille O, Flourié B, Amarenco G, Lémann M, et al. Fecal incontinence after pelvic radiotherapy: evidences for a lumbosacral plexopathy. Report of a case. *Dis Colon Rectum* 1996;39(4):465-7.
- Taylor BV, Kimmel DW, Krecke KN, Cascino TL. Magnetic resonance imaging in cancer-related lumbosacral plexopathy. *Mayo Clin Proc* 1997;72(9):823-9.
- Thomas JE, Cascino TL, Earle JD. Differential diagnosis between radiation and tumor plexopathy of the pelvis. *Neurology* 1985;35(1):1-7.
- Wilbourn AJ. Electrodiagnosis of plexopathies. *Neurol Clin* 1985;3(3):511-29.
- Pritchard J, Anand P, Broome J, Davis C, Gothard L, Hall E, et al. Double-blind randomized phase II study of hyperbaric oxygen in patients with radiation-induced brachial plexopathy. *Radiother Oncol* 2001;58(3):279-86.
- Glantz MJ, Burger PC, Friedman AH, Radtke RA, Massey EW, Schold SC Jr. Treatment of radiation-induced nervous system injury with heparin and warfarin. *Neurology* 1994;44(11):2020-7.

KARE
YAYINCILIK

`info@kareyayincilik.com.tr`