

Role of 6-Shogaol Against Ovarian Torsion Detorsion-Induced Reproductive Organ Damage

Mustafa Can Güler¹, Ayhan Tanyeli^{1*}, Ersen Eraslan², Fazile Nur Ekinçi Akdemir³

¹ Department of Physiology, Faculty of Medicine, Atatürk University, Erzurum, Turkey

² Department of Physiology, Faculty of Medicine, Bozok University, Yozgat, Turkey

³ Department of Nutrition and Dietetics, High School of Health, Ağrı İbrahim Çeçen University, Ağrı, Turkey

Article History

Received 30 May 2020

Accepted 01 June 2020

Published Online 15 June 2020

*Corresponding Author

Dr Ayhan Tanyeli

Department of Physiology,

Faculty of Medicine,

Atatürk University,

Erzurum, 25240, Turkey,

Phone: +905073631654,

E-mail: ayhan.tanyeli@atauni.edu.tr

ORCID: <http://orcid.org/0000-0002-0095-0917>

Abstract: 6-Shogaol (SHO) was examined on ovarian torsion detorsion (T/D) rat model to find out the potential beneficial results exist or not. 4 groups were composed to establish the experimental step. Sprague-Dawley female rats were used in the experiment. Each group included 8 rats and 32 rats were examined totally. Groups were designed as: Sham, T/D, T/D+Dimethyl sulfoxide (DMSO) and T/D+SHO groups. Sham group: Only abdominal incision was performed and closed without any additional process. T/D group: 3 hours torsion and 3 hours detorsion process were established following the abdominal incision. T/D+DMSO group: 0.3 ml of DMSO was given as intraperitoneal 30 minutes before detorsion. T/D+SHO group: SHO was administered as intraperitoneal 30 minutes prior to detorsion. At the end of the experiment, high doses of anesthesia were preferred for the euthanasia of the rats and the ovarian tissues were excised in order to obtain samples. Oxidative and pro-inflammatory biomarkers such as MPO activity, OSI, IL-1 β , MDA, TNF- α and TOS levels elevated significantly but TAS and SOD levels diminished in T/D group compared to sham group. On the other hand, SHO administration provided a decrease in oxidant and pro-inflammatory parameters and elevated TAS and SOD levels, antioxidant mediators. Consequently, SHO demonstrated beneficial activity by protecting the ovarian tissues against ovarian injury induced by experimental T/D rat model. © 2020 NTMS.

Keywords: 6-Shogaol, Torsion Detorsion, Ovary, Rat.

1. Introduction

Ovarian torsion (O/T) is described as the partial or total rotation of the ovary and/or fallopian tube around the vascular axis (1). It is a gynecological emergency and frequently observed in reproductive years, especially in mid-20s (2). Reperfusion damage might be greater than ischemic harm which is also called ischemia reperfusion (I/R) injury (3). Ovarian torsion detorsion (T/D) reduced ovarian reserve levels and just surgical interventions are inadequate to cope with the loss in ovarian reserves (4).

Thereby, studies performed recently aimed to struggle against ovarian damage induced by ovarian T/D. In the main, molecules with anti-inflammatory and antioxidant features were examined (5-7).

Detorsion increases oxygen levels in ovarian tissues due to enhanced vascular reperfusion. Elevation in oxygen levels increase reactive oxygen species (ROS) production and thus causes tissue injury (8-10). ROS are detrimental to tissues because of lipid peroxidation.

They play role in lipid peroxidation and thus, malondialdehyde (MDA) formation. MDA is a harmful molecule for cells (11). Total oxidant status (TOS) shows the oxidant activity while total antioxidant status (TAS) reflects the antioxidant actions (12). Interleukin-1 beta (IL-1 β), tumor necrosis factor-alpha (TNF- α) and the other pro-inflammatory cytokines were found related with ischemic tissue injury in several studies (13, 14). Myeloperoxidase (MPO) exists in neutrophils and plays role in hydroxyl radical formation (15). Various molecules have been used to cope with several organ injuries induced by I/R (16-20), but 6-Shogaol (SHO) has not been examined yet. SHO has been noted with a variety of properties such as anti-inflammatory (21) and antioxidative (22) features. SHO alleviated neuro-inflammation and eased cognitive deficits in an animal dementia model (23). Here, it was aimed to evaluate the possible beneficial effects of SHO against ovarian tissue injury.

2. Material and Methods

2.1. Experimental Animals and Ethical Approval

Atatürk University Experimental Animal Ethics Committee was the competent authority to confirm the study (07.11.2019/205). Atatürk University Experimental Animals Research and Application Center was preferred to follow out the experimental protocols and the animal care. They were housed in laboratory conditions including 12/12-h light and dark cycles, humidity of 55 \pm 5%, polypropylene-individual cages and a constant temperature of 22 \pm 2 °C. Standard rat feed and tap water were free to reach. The rats were fasted 12 hours prior to experiment but allowed to drink water.

2.2. Pre-operative Preparation

As a single species, 32 Sprague-Dawley female rats, each weighing 240-270 g were used to carry out the experiment. They were fastened up in supine position. For each rat, hair was removed from abdominal surgical site and surgical space was cleaned with povidone-iodine. 10 mg/kg i.p. xylazine hydrochloride (Rompun®, Bayer, İstanbul) and 60 mg/kg i.p. ketamine (Ketalar®, Pfizer, İstanbul) were used as anesthetic. SHO and Dimethyl sulfoxide (DMSO) were obtained from Sigma Aldrich Corporation.

2.3. Groups and Experimental Procedure

The rats were grouped randomly (4 groups, n=8). Sham group: Following the pre-operative preparations, abdominal area was incised and closed with 3-0 silk suture. T/D group: Surgical procedure was performed as in sham group and T/D model was carried out as described in a previous study (24).

The ovaries, fallopian tubes and vascular structures were spun in clockwise 360 degrees and fixed via atraumatic clamps for 3 hours to block blood flow (torsion period). Following 3 hours, the clamps were removed to provide blood circulation for 3 hours (detorsion period). T/D+DMSO group: Exactly same steps were followed with T/D group but DMSO was given 0.3 ml intraperitoneally (i.p.) to the rats 30 minutes prior to detorsion. T/D+SHO group: Procedures in T/D group were applied but 20 mg/kg SHO was administered i.p. to the rats 30 minutes before detorsion period (25). When the experiment is over, ovarian tissues were excised and cleaned by washing and kept frozen until the analysis.

2.4. Biochemical Measurements

MDA assessment was performed due to lipid peroxidation determining by the methods of Ohkawa et al (26). Superoxide dismutase (SOD) activity determination depends on the protocol described by Sun et al (27). MPO activity is gauged using a method belongs to Bradley et al (28). TAS and TOS values were gauged via appropriate kits (Rel Assay Diagnostics). TOS to TAS ratio was used as the oxidative stress index (OSI). IL-1 β and TNF- α levels were measured by commercially available kits (Elabscience, Wuhan, China).

2.5. Statistical Analyses

SPPS (version 20.0, for windows) programme was preferred for the data evaluation. One-way ANOVA test was used for data. For multiple comparisons, Tukey HSD test was performed. The results were demonstrated as Mean \pm Standard Deviation (SD). It was accepted as statistically significant when p value was below 0.05.

3. Results

No animal death has occurred as a result of surgical interventions in the experimental groups. Biochemical results were demonstrated in Table 1, Figure 1 and 2. MDA, TOS, MPO and OSI levels elevated but TAS and SOD values declined in T/D and T/D+DMSO groups compared to sham group. SHO administration significantly reduced the oxidative parameters and elevated antioxidant mediators (Table 1 and Figure 1, p<0.001). In addition, in the presented study, it was found that pro-inflammatory cytokine levels (TNF- α and IL-1 β) in the tissue increased significantly due to T/D, while this cytokine levels decreased especially in the SHO treatment group (p<0.001, Figure 2).

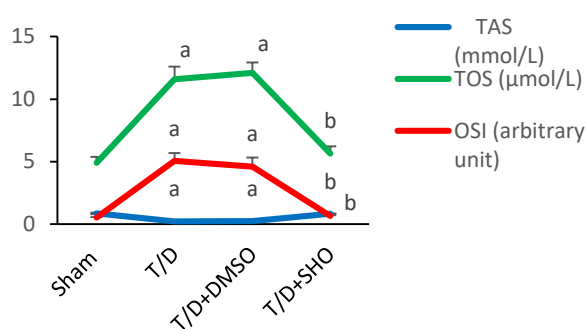


Figure 1: Mean±SD results of TAS, TOS and OSI levels belonging to all experimental groups. Green “a” demonstrates increase in TOS activity, red “a” shows elevation in OSI value and blue “a” means decrease in TAS level of T/D and T/D+DMSO groups. Green “b” reflects decrease in TOS activity, red “b” signs decline in OSI level and blue “b” shows elevation in TAS value of T/D+SHO group.

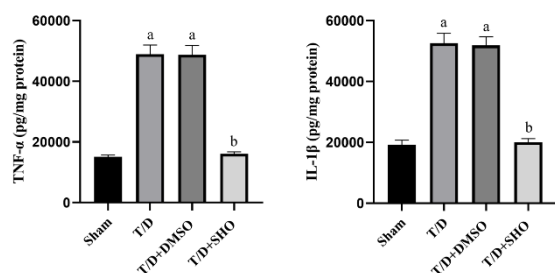


Figure 2: Mean±SD results of TNF-α and IL-1β level(s) belonging to all experimental groups. ^ap<0.001 compared to sham group. ^bp<0.001 compared to T/D group.

Table 1: Mean±SD results of SOD, MPO activities and MDA levels belonging to all experimental groups.

	Sham	T/D	T/D+DMSO	T/D+SHO
SOD (U/mg protein)	403,42±40,79	157,72±8,08 ^a	161,08±8,86 ^a	397,36±27,75 ^b
MPO (U/g protein)	221667,60±16872,18	622968,94±50354,88 ^a	647563,92±41799,52 ^a	243475,92±23078,63 ^b
MDA (μmol/g tissue)	58,07±2,38	129,04±11,49 ^a	129,68±6,40 ^a	64,78±4,68 ^b

^ap<0.001 compared to sham group. ^bp<0.001 compared to T/D group.

4. Discussion

O/T is the interruption of arterial supply due to the twisting of ovary and sometimes fallopian tube (29). Women, particularly in first three decades, expose to O/T which prevents blood flow and results in ovarian tissue injury (30). Women in reproductive age are more affected and thus, early intervention is crucial for the maintaining of fertility. Thereby, coping with torsion via applying detorsion is more valuable than applying the adnexectomy process (31). Detorsion is performed to able to restore blood flow to ovaries but on the other hand, it may lead to a much more damage than the ischemia did (32). This increased damage is related with high free oxygen radical levels which are generated due to excessive oxygen supply during reperfusion (33) and it is called as I/R injury (3).

Various studies have been carried out but a thoroughly mechanism for I/R still remains unclear. Nevertheless, free oxygen radicals have been linked to I/R injury (34). ROS leads to cell membrane, mitochondrial and DNA damage through lipid peroxidation and also induces cytokine generation (35). It has been presented oxidative stress related tissue injury in different experimental animal models (36-39). Ovarian I/R pathophysiology includes several factors and especially inflammation, oxidative stress and free oxygen radicals play a main role (40). MDA value raises during

oxidative stress and high MDA levels point out lipid peroxidation (3).

MDA ruins membrane permeability and separates the cells (41). ROS occurs as a part of aerobic metabolism and it is scavenged by antioxidant system components including SOD (42). Antioxidant enzymes including SOD prevent oxidative stress (43). TAS and TOS are beneficial parameters on considering I/R injury (44). TAS and TOS have negative correlation between each other (12, 45). MPO is produced by neutrophils and plays role in hydroxyl radical generation (15). IL-1β and TNF-α are the samples of pro-inflammatory cytokines and show up in the beginning of inflammation. They induce neutrophil infiltration and release of free radicals (46, 47).

Various molecules which have antioxidant and anti-inflammatory effects were examined in different tissues to observe possible beneficial effects against I/R injuries (48-52). Ginger (*Zingiber officinale* rhizome) is a widespread medicinal herb preferred in traditional medicine especially for cough, asthma and cold (53). SHO, with high levels in ginger, performs anti-inflammatory and antioxidant features (54). SHO has been found effective against Alzheimer's disease, cerebral ischemia, sepsis-induced neuro-inflammation and Parkinson's disease (55, 56).

In several studies, SHO performed beneficial activities against inflammation, neuronal damage and even cancer (23, 56, 57-59).

Here, SHO was examined in ovarian T/D model in order to determine the potential beneficial effects against ovarian injury. In T/D and T/D+DMSO groups, TAS and SOD values diminished while OSI, MDA, TNF- α , MPO, TOS and IL-1 β levels elevated compared to sham group. SHO treatment reversed these parameters. And in the light of these data, SHO reduced tissue injury in ovarian T/D rat model.

5. Conclusions

SHO attenuated T/D-induced ovarian tissue injury. SHO succeeded the amelioration activity through its antioxidant and anti-inflammatory features. As a natural herb derived agent, SHO may be a new potential molecule as to be evaluated in T/D related ovarian tissue injuries.

Conflict of interest statement

None

Financial Support

There is no financial support organization.

References

1. Tuncer AA, Bozkurt MF, Koken T, et al. The Protective Effects of Alpha-Lipoic Acid and Coenzyme Q10 Combination on Ovarian Ischemia-Reperfusion Injury: An Experimental Study. *Adv Med* **2016**; 2016 (8 pages) doi: 10.1155/2016/3415046
2. Sasaki KJ, Miller CE. Adnexal torsion: review of the literature. *J Minim Invasive Gynecol* **2014**; 21: 196-202
3. Carden DL, Granger DN. Pathophysiology of ischaemia-reperfusion injury. *J Pathol* **2000**; 190: 255-266
4. Ozler A, Turgut A, Soydinç HE, et al. The biochemical and histologic effects of adnexal torsion and early surgical intervention to unwind detorsion on ovarian reserve: an experimental study. *Reprod Sci* **2013**; 20: 1349-1355
5. Behroozi-Lak T, Zarei L, Moloody-Tapeh M, et al. Protective effects of intraperitoneal administration of nimodipine on ischemia-reperfusion injury in ovaries: Histological and biochemical assessments in a rat model. *J Pediatr Surg* **2017**; 52: 602-608
6. Kurt RK, Dogan AC, Dogan M, et al. Protective effect of colchicine on ovarian ischemia-reperfusion injury: an experimental study. *Reprod Sci* **2015**; 22: 545-550
7. Gungor AN, Turkon H, Albayrak A, et al. Does Omegaven have beneficial effects on a rat model of ovarian ischemia/reperfusion? *Eur J Obstet Gynecol Reprod Biol* **2014**; 181: 240-245
8. Sengul O, Ferah I, Polat B, et al. Blockade of endothelin receptors with bosentan limits ischaemia/reperfusion-induced injury in rat ovaries. *Eur J Obstet Gynecol Reprod Biol* **2013**; 170: 458-463
9. Park ES, Kim J, Ha TU, et al. TDAG51 deficiency promotes oxidative stress-induced apoptosis through the generation of reactive oxygen species in mouse embryonic fibroblasts. *Exp Mol Med* **2013**; 45: 35
10. Kohen R, Nyska A. Oxidation of biological systems: oxidative stress phenomena, antioxidants, redox reactions, and methods for their quantification. *Toxicol Pathol* **2002**; 30: 620-650
11. Yapca OE, Borekci B, Suleyman H. Ischemia-reperfusion damage. *Eurasian J Med* **2013**; 45:126-137
12. Erel O. A new automated colorimetric method for measuring total oxidant status. *Clin Biochem* **2005**; 38: 1103-1111
13. Karhausen J, Qing M, Gibson A, et al. Intestinal mast cells mediate gut injury and systemic inflammation in a rat model of deep hypothermic circulatory arrest. *Crit Care Med* **2013**; 41: 200-210
14. Zhuang P, Wan Y, Geng S, et al. Salvianolic Acids for Injection (SAFI) suppresses inflammatory responses in activated microglia to attenuate brain damage in focal cerebral ischemia. *J ethnopharmacol* **2017**; 198: 194-204
15. Van Antwerpen P, Boudjeltia KZ, Babar S, et al. Thiol-containing molecules interact with the myeloperoxidase/H₂O₂/chloride system to inhibit LDL oxidation. *Biochemical and biophysical research communications* **2005**; 337:82-88
16. Eraslan E, Tanyeli A, Polat E, et al. 8-Br-cADPR, a TRPM2 ion channel antagonist, inhibits renal ischemia-reperfusion injury. **2019**; *J Cell Physiol* 234: 4572-4581
17. Eraslan E, Tanyeli A, Polat E, et al. Evodiamine alleviates kidney ischemia reperfusion injury in rats: A biochemical and histopathological study. **2019**; *J Cell Biochem* 120: 17159-17266
18. Ozturk D, Erdogan DG, Tanyeli A, et al. The protective effects of urapidil on lung tissue after intestinal ischemia-reperfusion injury. **2019**; 44: 539-548
19. Tanyeli A, Guler MC, Eraslan E, et al. Barbaloin attenuates ischemia reperfusion-induced oxidative renal injury via antioxidant and anti-inflammatory effects. *Med Sci* **2020**; 9: 246-250
20. Dogan C, Halici Z, Topcu A, et al. Effects of amlodipine on ischaemia/reperfusion injury in the rat testis. **2016**; *Andrologia* 48: 441-452
21. Han Q, Yuan Q, Meng X, Huo J, Bao Y, et al. 6-Shogaol attenuates LPS-induced inflammation in BV2 microglia cells by activating PPAR- γ . *Oncotarget* **2017**; 8: 42001-42006
22. Na JY, Song K, Lee JW, et al. Pretreatment of 6-shogaol attenuates oxidative stress and inflammation in middle cerebral artery occlusion-induced mice. **2016**; *Eur J Pharmacol* 788:241-257
23. Moon M, Kim HG, Choi JG, et al. 6-Shogaol, an active constituent of ginger, attenuates

- neuroinflammation and cognitive deficits in animal models of dementia. *Biochem Biophys Res Commun* **2014**; 449: 8-13
24. Celik M, Aksoy AN, Aksoy H, et al. Sildenafil Reduces Ischemia-Reperfusion Injury in Rat Ovary: Biochemical and Histopathological Evaluation. *Gynecologic and Obstetric Investigation* **2014**; 78:162-167
 25. Hassan SM, Hassan AH. The possibility of using shogaol for treatment of ulcerative colitis. *Iran J Basic Med Sci* **2018**; 21:943-949
 26. Ohkawa H, Ohishi N, Yagi K. Assay for Lipid Peroxides in Animal-Tissues by Thiobarbituric Acid Reaction. *Anal Biochem* **1979**; 95:351-358
 27. Sun Y, Oberley LW, Li Y. A Simple Method for Clinical Assay of Superoxide-Dismutase. *Clin Chem* **1988**; 34: 497-500
 28. Bradley PP, Priebe DA, Christensen RD, et al. Measurement of cutaneous inflammation: estimation of neutrophil content with an enzyme marker. *J Invest Dermatol* **1982**; 78: 206-209
 29. McWilliams GD, Hill MJ, Dietrich CS. Gynecologic emergencies. *Surg Clin North Am* **2008**; 88: 265-283
 30. Houry D, Abbott JT. Ovarian torsion: a fifteen-year review. *Ann Emerg Med* **2001**; 38: 156-169
 31. Ugurel V, Cicek AC, Cemek M, et al. Antioxidant and antiapoptotic effects of erdosteine in a rat model of ovarian ischemia-reperfusion injury. *Iran J Basic Med Sci* **2017**; 20: 53-68
 32. Zimmerman BJ, Granger DN. Reperfusion injury. *Surg Clin North Am* **1992**; 72: 65-83
 33. Borekci B, Gundogdu C, Altunkaynak BZ, et al. The protective effect of dehydroepiandrosterone on ovarian tissues after torsion-detorsion injury: a stereological and histopathological study. *Eurasian J Med* **2009**; 41: 22-27
 34. Wu MY, Yiang GT, Liao WT, et al. Current Mechanistic Concepts in Ischemia and Reperfusion Injury. *Cell Physiol Biochem* **2018**; 46: 1650-1667
 35. Pinar N, Soylu Karapinar O, Özcan O, et al. Protective effects of tempol in an experimental ovarian ischemia-reperfusion injury model in female Wistar albino rats. *Can J Physiol Pharmacol* **2017**; 95: 861-875
 36. Tanyeli A, Güzel D. Investigation into the Biochemical Effects of Barbaloin on Renal Tissue in Cecal Ligation and Puncture-Induced Polymicrobial Sepsis Model in Rats. *Southern Clinics of Istanbul Eurasia* **2019**; 30: 285-299
 37. Tanyeli A, Güzel D. Alliin mitigates Cecal Ligation Puncture (CLP)-induced lung injury through antioxidant and antiinflammatory effects. *Turk J Sci* **2019**; 4: 46-59
 38. Ekinçi Akdemir FN, Tanyeli A. The Antioxidant Effect of Fraxin against Acute Organ Damage in Polymicrobial Sepsis Model induced by Cecal Ligation and Puncture. *Turk J Sci* **2019**; 4: 22-29
 39. Tanyeli A, Eraslan E, Güler MC, Sebin SO, et al. Investigation of biochemical and histopathological effects of tarantula cubensis D6 on lung tissue in cecal ligation and puncture-induced polymicrobial sepsis model in rats. *Med Sci* **2019**; 8: 644-650
 40. Refaie MMM, El-Hussieny M. Protective effect of pioglitazone on ovarian ischemia reperfusion injury of female rats via modulation of peroxisome proliferator activated receptor gamma and heme-oxygenase 1. *Int Immunopharmacol* **2018**; 62:7-14
 41. Erkanli Senturk G, Erkanli K, Aydin U, et al. The protective effect of oxytocin on ischemia/reperfusion injury in rat urinary bladder. *Peptides* **2013**; 40: 82-88
 42. Gough DR, Cotter TG. Hydrogen peroxide: a Jekyll and Hyde signalling molecule. *Cell Death Dis* **2011**; 2: 213
 43. Tang Y, Li S, Zhang P, et al. Soy Isoflavone Protects Myocardial Ischemia/Reperfusion Injury through Increasing Endothelial Nitric Oxide Synthase and Decreasing Oxidative Stress in Ovariectomized Rats. *Oxid Med Cell Longev* **2016**; 2016; (14 pages) doi: 10.1155/2016/5057405
 44. Yazici S, Demirtas S, Guclu O, et al. Using oxidant and antioxidant levels to predict the duration of both acute peripheral and mesenteric ischemia. *Perfusion* **2014**; 29: 450-465
 45. Erel O. A novel automated method to measure total antioxidant response against potent free radical reactions. *Clin Biochem* **2004**; 37: 112-129
 46. Eltzschig HK, Collard CD. Vascular ischaemia and reperfusion injury. *BrMed Bul* **2004**; 70: 71-86
 47. Dinarello CA. Proinflammatory cytokines. *Chest* **2000**; 118: 503-518
 48. Tanyeli A, Ekinçi Akdemir FN, Eraslan E, et al. Role of p-Coumaric acid in Alleviating of the Intestinal Ischemia/Reperfusion Injury. *Kocaeli Med J* **2020**; 9: 166-173
 49. Topdagi O, Tanyeli A, Ekinçi Akdemir FN, et al. Preventive effects of fraxin on ischemia/reperfusion-induced acute kidney injury in rats. *Life Sci* **2020**; 242: in press 117217.
 50. Güzel D, Tanyeli A. Investigation of Chlorogenic Acid (Cga) as An Antioxidant in Renal Ischemia-Reperfusion Injury: An Experimental Study. *Sakarya Med J* **2018**; 8: 410-415
 51. Güzel D, Tanyeli A. Investigation of Oxidative Damage of Lung Tissue in Experimental Renal Ischemia Reperfusion Model and The Protective Effects of Chlorogenic Acid (CGA). *Sakarya Med J* **2018**; 8:260-265
 52. Topdağı O, Tanyeli A, Ekinçi Akdemir FN, et al. Higenamine decreases testicular damage injured by ischemia reperfusion: A biochemical study *Turk J Sci* **2019**; (4)2: 92-99
 53. Mascolo N, Jain R, Jain SC, et al. Ethnopharmacologic investigation of ginger (*Zingiber officinale*). *J Ethnopharmacol* **1989**; 27: 129-140
 54. Suekawa M, Ishige A, Yuasa K, et al. Pharmacological studies on ginger. I. Pharmacological actions of pungent constituents,

- (6)-gingerol and (6)-shogaol. *J Pharmacobiodyn* **1984**; 7: 836-848
55. Park G, Kim HG, Ju MS, et al. 6-Shogaol, an active compound of ginger, protects dopaminergic neurons in Parkinson's disease models via anti-neuroinflammation. *Acta Pharmacol Sin* **2013**; 34: 1131-1139
56. Shim S, Kim S, Kwon YB, et al. Protection by [6]-shogaol against lipopolysaccharide-induced toxicity in murine astrocytes is related to production of brain-derived neurotrophic factor. *Food Chem Toxicol* **2012**; 50: 597-602
57. Ha SK, Moon E, Ju MS, et al. 6-Shogaol, a ginger product, modulates neuroinflammation: a new approach to neuroprotection. *Neuropharmacol* **2012**; 63: 211-223
58. Butt MS, Sultan MT. Ginger and its health claims: molecular aspects. *Crit Rev Food Sci Nutr* **2011**; 51: 383-393
59. Kim MO, Lee MH, Oi N, et al. [6]-shogaol inhibits growth and induces apoptosis of non-small cell lung cancer cells by directly regulating Akt1/2. *Carcinogen* **2014**; 35: 683-691

Authors' ORCID

Mustafa Can Güler

<http://orcid.org/0000-0001-8588-1035>

Ayhan Tanyeli

<http://orcid.org/0000-0002-0095-0917>

Ersen Eraslan

<https://orcid.org/0000-0003-2424-2269>

Fazile Nur Ekinci Akdemir

<https://orcid.org/0000-0001-9585-3169><https://dergipark.org.tr/tr/pub/ntms>

All Rights Reserved. © 2020 NTMS.