



COMPARISON OF THE CYTOKINE PROFILES AND ULTRASTRUCTURAL CHANGES IN THE URETEROVESICAL JUNCTIONS OF CHILDREN WITH PRIMARY VESICoureTERAL REFLUX AND CHILDREN WITH PRIMARY VUR FOLLOWING FAILED INJECTION THERAPY WITH DX/HA

PRİMER VEZİKOÜRETERAL REFLÜLÜ (VUR) VE DX/HA İLE BAŞARISIZ ENJEKSİYON TEDAVİSİ SONRASI PRİMER VUR'LU ÇOCUKLARIN ÜRETEROVEZİKAL BİLEŞKESİNDE SİTOKİN PROFİLLERİNİN VE ULTRAYAPISAL DEĞİŞİKLİKLERİNİN KARŞILAŞTIRILMASI

Mutlu DEĞER¹, Volkan İZOL¹, Yurdun KUYUCU², Arbil ACIKALIN³, İbrahim Atilla ARIDOGAN¹, Sait POLAT², Nihat SATAR¹

[0000-0002-8357-5744](https://doi.org/10.36516/jocass.2020.38), [0000-0001-5007-6781](https://doi.org/10.36516/jocass.2020.38), [0000-0001-6289-0860](https://doi.org/10.36516/jocass.2020.38), [0000-0001-6118-9853](https://doi.org/10.36516/jocass.2020.38), [0000-0002-3805-7817](https://doi.org/10.36516/jocass.2020.38), [0000-0003-1646-8831](https://doi.org/10.36516/jocass.2020.38), [0000-0003-4427-3521](https://doi.org/10.36516/jocass.2020.38)

¹ Department of Urology, Faculty of Medicine, University of Çukurova, Adana, Turkey

² Department of Histology and Embryology, Faculty of Medicine, University of Çukurova, Adana, Turkey

³ Department of Pathology, Faculty of Medicine, University of Çukurova, Adana, Turkey

Sorumlu Yazar/Corresponding Author: Mutlu Değer E-mail: drmutludeger@gmail.com

Geliş Tarihi/Received: 23.05.2020 Kabul Tarihi-Accepted: 21.06.2020 Available Online Date/Çevrimiçi Yayın Tarihi: 22.06.2020

Cite this article as: Deger M, Izol V, Kuyucu Y, Acikalın A, Arıdoğan İA, Polat S, Satar N. Comparison of The Cytokine Profiles and Ultrastructural Changes in The Ureterovesical Junctions of Children with Primary Vesicoureteral Reflux and Children with Primary VUR Following Failed Injection Therapy with Dx/HA. *J Cukurova Anesth Surg.* 2020;3(E1),33-45. Doi: 10.36516/jocass.2020.38

Abstract

Purpose: To compare the cytokine profiles and ultrastructural changes in the ureterovesical junctions of children with primary vesicoureteral reflux(VUR) and children with primary VUR following failed injection therapy with dextranomer/hyaluronic-acid (Dx/HA) using immunohistochemical methods and transmission electron microscopy (TEM).

Materials and Methods: 41 children underwent ureteroneocystostomy for VUR and 18 children underwent ureteroneocystostomy for primary VUR following failed injection therapy with Dx/HA. Sixty-seven distal intravesical ureters were obtained during surgery for histopathological and ultrastructural evaluations. The ureteral wall smooth-muscle organization and transforming growth factor- β 1(TGF- β 1), vascular endothelial growth factor(VEGF), and CD34 were evaluated immunohistochemically. The ultrastructural evaluations and morphological descriptions were performed semi-quantitatively.

Results: Of the patients, 10(24,3%) were male and 31(75,7%) were female. 28 ureter had a history of failed Dx/HA injections. *Histopathology;* the amount of TGF- β 1, and the VEGF and CD34 levels were same in the patients with primary VUR and patients with primary VUR following failed injection therapy with Dx/HA but different compared with the control group($p=0.001$, $p<0.001$, and $p<0.001$, respectively), but the differences were not correlated with the grade of reflux($p=0.42$, $p=0.26$ and $p=0.94$ respectively). Ultrastructural changes in the muscle cells were observed in all the VUR specimens.

Conclusions: Our study demonstrated that ultra-structural changes in the muscle cells were observed in all VUR specimens. There was no significant difference in the quantification of cytokine assays between the patients with primary VUR and primary VUR with failed Dx/HA therapy. The quantification of VEGF, CD34, and, TGF- β 1 levels was comparable in both primary VUR groups.

Keywords: Dextranomer/hyaluronic acid, transmission electron microscopy, ureterovesical junctions, vesicoureteral reflux

Öz

Amaç: İmmünohistokimyasal yöntemler ve transmisyon elektron mikroskopisi (TEM) kullanılarak primer vezikoureteral reflü (VUR) ve dekstranomer / hyaluronik asit (Dx/HA) ile başarısız enjeksiyon tedavisi sonrası primer VUR'lu çocukların üreterovezikal bileşkesinde sitokin profollerinin ve ultrayapısal değişikliklerinin karşılaştırılması.

Materyal ve Method: Aralık 2011 ve Ağustos 2014 tarihleri arasında, Uluslararası Reflü Çalışmasına göre grade I-V VUR olarak değerlendirilen 41 çocuğa üreteroneosistostomi uygulandı. Dx / HA ile başarısız enjeksiyon tedavisinin ardından 18 çocuğa primer VUR için üreteroneosistostomi uygulandı. Histopatolojik ve ultrayapısal değerlendirmeler için ameliyat sırasında altmış yedi distal intravezikal üreter elde edildi. Üreter duvarı düz kas organizasyonu ve transforme edici büyüme faktörü- β 1 (TGF- β 1), vasküler endotelial büyüme faktörü (VEGF) ve CD34 immünohistokimyasal olarak değerlendirildi. Ultrayapısal değerlendirmeler ve morfolojik tanımlar yarı kantitatif olarak yapıldı.

Bulgular: Hastaların 10'u (%24,3) erkek, 31'i (%75,7) kadındı. 28 üreterde başarısız Dx/HA enjeksiyon öyküsü mevcuttu. Histopatolojisi; Dx/HA ile başarısız enjeksiyon tedavisini takiben primer VUR hastalarında ve primer VUR hastalarında TGF- β 1 ve VEGF ve CD34 düzeyleri aynıydı ancak kontrol grubu ile karşılaştırıldığında farklı idi (sırasıyla $p=0.001$, $p<0.001$ ve $p<0.001$). Ancak farklar reflü derecesi ile ilişkili değildi (sırasıyla $p = 0.42$, $p = 0.26$ ve $p = 0.94$). Tüm VUR örneklerinde kas hücrelerinde ultrayapısal değişiklikler gözlemlendi.

Sonuç: Çalışmamız, tüm VUR örneklerinde kas hücrelerinin ultra apısal değişikliklerinin gözlemlendiğini göstermiştir. Primer VUR ve başarısız Dx/HA tedavisi olan primer VUR hastalar arasında sitokin miktarında anlamlı bir fark yoktu. VEGF, CD34 ve TGF-21 düzeyleri her iki primer VUR grubunda da karşılaştırılabilir.

Anahtar Kelimeler: Dekstranomer/hyalüronik asit, transmisyon elektron mikroskopisi, üreterovezikal bileşke, vezikoureteral reflü

Introduction

Vesicoureteral reflux (VUR) is characterized by the retrograde flow of urine from the bladder into the upper urinary tract due to an anatomic and/or functional disorder. Moderate to severe VUR can be responsible for potentially serious consequences such as renal scarring, hypertension, and/or renal failure. The pathophysiology of primary VUR and VUR-induced damage of renal parenchyma is poorly understood and remains a debated topic. In the management of these patients, identification of the risk factors to understand the mechanisms of damage is important in considering the options for treatment and preserving renal function.¹⁻⁴

Antibiotic prophylaxis and surgical management by ureteroneocystostomy have so far been the traditional treatments of choice for VUR since the 1970s.⁵⁻⁷

Matouschek et al.⁸ described a less

invasive technique comprising of endoscopic injections (EI) which serve as a bulking agent in the early 1980s. The agent of choice was Dextranomer/hyaluronic acid (Dx/HA) which is made up of cross-linked dextranomer microspheres suspended in a carrier gel of stabilized sodium hyaluronate. The histopathology changes of Dx/HA on intravesical ureters have been investigated by only a few studies.

The knowledge are still limited regarding the assessment of ultrastructural UVJ changes by transmission electron microscopy (TEM) in the usual and refluxed human ureter.⁹⁻¹¹ To our knowledge, this is the first study to evaluate compare of the ultrastructural changes using TEM in the ureterovesical junctions (UVJ) between the patients with primary VUR and patients with primary VUR following failed injection therapy with Dx/HA.

Patients and Methods

Between December 2011 and August 2014, 41 children underwent ureteroneocystostomy for VUR which were graded I to V according to the International Reflux Study¹². 18 children underwent ureteroneocystostomy for primary VUR following failed injection therapy with Dx/HA. The indications for surgery included failed conservative treatment, reflux persistency, reflux nephropathy and parental preference. Urodynamic studies were performed on all patients to rule out the presence of neurogenic bladder and voiding dysfunction before intervention for treatment. After obtaining the necessary approvals from the local Ethics Committee, the parents or legal guardians of the patients were informed that the clinical and laboratory data would be used for scientific purposes, and their written consent was obtained.

Histopathological and ultrastructural evaluation

Sixty-seven distal intravesical ureters were obtained during surgery for histopathological and ultrastructural evaluations. 28 of them had history of failed dextranomer/hyaluronic-acid(Dx/HA) injections. Each sample contained an intramural portion of the ureter with the ureteric orifice. Depending on the order of excision, the preparations were placed in vials that contained formaldehyde for histopathological evaluation or vials that contained a 5% glutaraldehyde solution for ultrastructural evaluation with an electron microscope. All the vials were numbered and evaluated by a single pathologist and histologist. The

ureterovesical junctions of 5 age-matched autopsy specimens without history or evidence of any urological disease served as the control group and were used only for histopathologic and immunohistochemical evaluations.

Electron microscopic examination

The specimens of the distal intravesical ureteric segments for electron microscopic examination were fixed for 4 hours with 5% glutaraldehyde in Millonig phosphate buffer at pH 7.4 and post-fixed with 1% osmium tetroxide in the same phosphate buffer for 2 hours at 4 °C. The samples were dehydrated in a graded series of ethanol and embedded in araldite. Semi-thin sections were taken with Reichert Ultracut-S ultramicrotome and stained with toluidine-blue, and the appropriate areas for electron microscopic observation were determined. Thin sections were taken from the selected areas and stained with uranyl acetate and lead citrate. They were examined with a Jeol JEM 1400 transmission electron microscope. The ultrastructural evaluation and morphological description was made semi-quantitatively

Light microscopic examination

For the histopathological evaluation, formaldehyde fixed, paraffin embedded tissues were cut transversely to 5 µm in width. Hematoxylin and eosin (HE) stained slides were examined under light microscopy (Nikon E600, Tokyo, Japan). Smooth muscle arrangements of the ureteral wall were scored as described by Oswald et al.¹³ This scoring system, based on the absence of a muscular coat, replacement of the muscle fibers with

fibrotic tissue, and enhancement of interstitial collagen was as follows: Score 0- absent; 1- mild (25% or less); 2- moderate (26-50%); 3- severe (51-75%); and 4- extremely severe (more than 75%).

Immunohistochemical examination

Immunohistochemistry was performed on the formalin-fixed paraffin-embedded 5 µm thick tissue sections with a manual streptavidin-biotin complex immunoperoxidase procedure, with antibodies against human VEGF (monoclonal mouse, Dako, M7273; Denmark), TGF β1 (polyclonal rabbit, Santa Cruz, sc-146), and CD34 (monoclonal mouse, DAKO, M 7165, Denmark). For all antibodies tested, antigen retrieval treatment was performed for 15 min in 0.01 M citrate buffer solution (pH 6.0) using a microwave oven, and immune complexes were then visualized by AEC. The slides were counterstained with Mayer's hematoxylin and mounted. The positive controls used were angiosarcoma, tonsil, and hemangioma, respectively, and negative controls were obtained by omitting the primary antibody. All VEGF and TGF-β1 positive cells were counted from 10 randomly selected high-power fields (HPFs) at ×400 magnification. The urothelial and intraluminal cells were not counted. Microvessel density was evaluated by counting positive staining endothelial cells or cell clusters in 10 randomly selected HPFs.

Statistical analysis

Data analysis was performed using the SPSS software, version 15 (SPSS, Inc., Chicago, IL). The categorical

measurements were summarized as numbers and percentages, whereas the numerical measurements were summarized as the means and standard deviations. Chi-square test statistics were used for the comparison of categorical measurements between the groups. The T-test, in independent groups, was used for the comparison of numerical measurements between paired groups. A one-way analysis of variance (ANOVA) was used for the general comparison of numerical measurements between more than 2 groups. In all tests, the statistical significance level was set at $p < 0.05$.

Results

Of the patients, 10 (24,3%) were male and 31 (75,7) were female. 18 patients of them had history of failed dextranomer/hyaluronic-acid (Dx/HA) injections. The mean age of the patients was $88,1 \pm 50,2(12-168)$ months. There was no correlation between the VUR grade and age ($p = 0.32$). Fifteen patients had unilateral VUR, and 26 patients had bilateral VUR. 28 ureter had history of failed dextranomer/hyaluronic-acid(Dx/HA) injections. The number of ureteral refluxes was 3 in grade I, 12 in grade II, 18 in grade III, 22 in grade IV and 12 in grade V according to the International Reflux Study¹². None of the patients had history of failed dextranomer/hyaluronic-acid(Dx/HA) injections had grade V VUR. The mean injected volume for each ureter was 1.0 cc, and the mean time from EI to surgical intervention ranged from 3 to 29 (10.2 ± 7.9) months. No preoperative and postoperative complications were observed.

Electron microscopic evaluation

The surface urothelium, lamina propria and adventitia were observed as normal in all grade VUR specimens (**Figure 1A**). Histopathological changes were observed in muscle cells. Intercellular edema and increased cytoplasmic density of some smooth muscle cells were observed in all the specimens of patients that had history of failed dextranomer/hyaluronic-acid(Dx/HA) injections (**Figures 1B and 1C**). Intercellular edema was observed in the muscular layer in grade IV-V VUR specimens of patients with primary VUR, whereas the intercellular space in grade I-III VUR specimens of patients with primary VUR appeared normal. Heterochromatin clumping in the nucleus and enlargement of perinuclear cisternae in the smooth muscle cells was observed in high grade (Grade III-V) VUR

specimens (**Figures 1B, 1C, 2A, 2B, 2C**). Swollen endoplasmic reticulum cisternae and mitochondria, cristae disorganization in mitochondria, vacuoles that include membranous whorl-type structures in some areas and empty spaces that characterize edema in the cytoplasm of the smooth muscle cells were prominent in high grade (Grade III-V) VUR specimens of patients with primary VUR and prominent in all the VUR (Grade II-IV) specimens of patients had history of failed dextranomer/hyaluronic-acid(Dx/HA) (**Figures 1B, 1C, 2 and 3**). Normal smooth muscle cells were observed in grade I-II VUR specimens of patients with primary VUR. The degree of degeneration was similar in patients with the same grade VUR who were different ages.

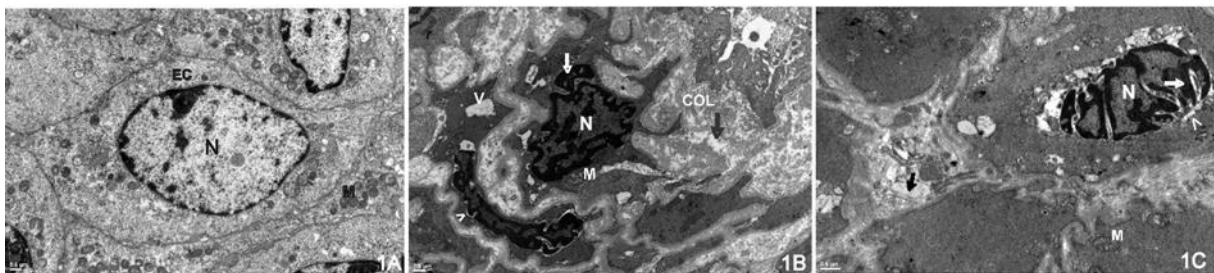


Figure 1A. The sting procedure applied group. Grade 4 VUR. Normal transitional epithelial cells (EC) are observed. Nucleus (N), mitochondrion (M). Bar=0,5 μ m.

Figure 1B. The sting procedure applied group. Grade 4 VUR. Intercellular edema is observed in the muscular layer (black arrow). Heterochromatin clumping (white arrow) in the nucleus (N) and perinuclear cisternae enlargement (arrowhead) in the smooth muscle cells are observed. Swollen mitochondria (M), cristae disorganization in the mitochondria and vacuoles (V) that include membranous whorl structures in the cytoplasm are observed. Collagen (COL). Bar=0,5 μ m.

Figure 1C. The sting procedure applied group. Grade 4 VUR. Intercellular oedema is seen in the muscular layer (black arrow). Heterochromatin clumping (white arrow) in the nucleus (N) especially in the subnuclear envelope and perinuclear cisternae enlargement (arrowhead) of the smooth muscle cells are seen. Swollen mitochondria (M) and disruption of the cristae with membranous whorl structures in the cytoplasm of the cell are seen. Bar=0,5 μ m

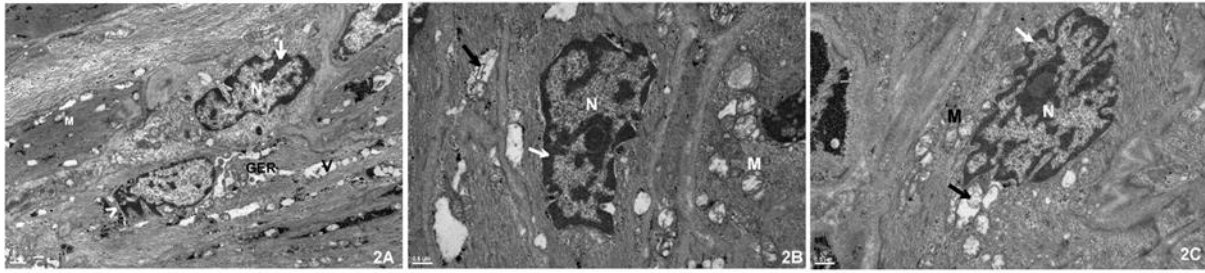


Figure 2A. The sting procedure applied group. Grade 3 VUR. Heterochromatin clumping (arrow) in the nucleus (N) and perinuclear cisternae enlargement (arrowhead) in the smooth muscle cells are observed. Swollen granular endoplasmic reticulum cisternae (GER) and mitochondria (M), cristae disorganization in the mitochondria and vacuoles (V) that include membranous whorl structures in the cytoplasm are observed. Bar=1 μ m.

Figure 2B. The sting procedure applied group. Grade 3 VUR. Heterochromatin clumping (white arrow) in the peripheral zone of the nucleus (N) in the smooth muscle cells are seen. Swollen mitochondria (M), cristae disruption and membranous whorl structures (black arrow) are seen. Bar=0,5 μ m.

Figure 2C. The sting procedure applied group. Grade 3 VUR. The smooth muscle cell revealed heterochromatin clumping (white arrow) in the peripheral zone of the nucleus(N), swelling of the mitochondria (M) and disintegration of the cristae with membranous whorl structures (black arrow). Bar=0,5 μ m.

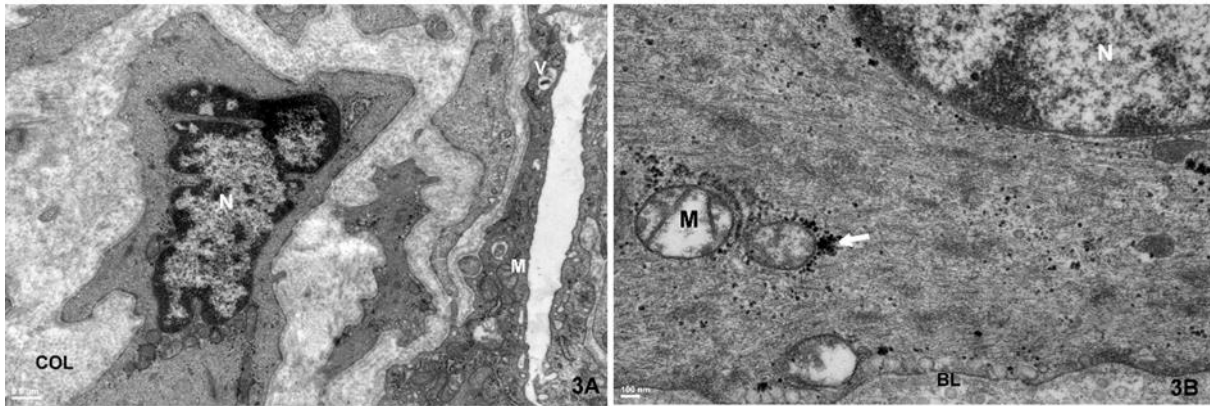


Figure 3A. The sting procedure applied group. Grade 2 VUR. Swollen mitochondria (M) and cristae disorganization and vacuoles (V) that include membranous whorl structures in the cytoplasm are observed. Collagen (COL). Bar=1 μ m.

Figure 3B. The sting procedure applied group. Grade 2 VUR. The smooth muscle cell shows swelling of the mitochondria (M) and disintegration of the cristae. Nucleus(N), glycogen particles (white arrows) and basal lamina(BL) are indicated. Bar=100 nm.

Histopathology

In most VUR cases, collagen and edema was replaced instead of smooth muscle. In most of the VUR cases, the smooth muscle coat was disorganized and widely absent compared to the control group. The mean smooth muscle scores in grade I to V VUR cases with primary VUR and in grade II to

IV VUR cases had history of failed dextranomer/hyaluronic-acid(Dx/HA) injections were 2.0 ± 2.0 (0-4), 1.2 ± 0.8 (0-2), 1.2 ± 1.1 (0-3), 1.0 ± 1.1 (0-4), and 0.6 ± 1.1 (0-4) and 1.6 ± 0.5 (1-2), 1.0 ± 0.6 (0-2), and 1.0 ± 1.4 (0-3), respectively. No significant correlation was found between the reflux grade and the smooth muscle disarrangement score ($p=0.86$).When we

compared the results with the control group, the difference was significant ($p < 0.001$). There was no sign of inflammation, operative injury or cautery artifact in the specimens.

Dx/HA material was in the adventitia in 22(78.6%) cases and in the muscle fibers in 6 (21.4%) cases. A fibrous pseudocapsule surrounding the Dx/HA material was present in only two (7,1%) cases, which were located in the muscle fibers. A giant cell reaction was rapid in 26 (92.9%) of the 28 cases. Giant cell reaction included mild lymphocytes, macrophages and multinucleated giant cells around the Dx/HA material, distributed among muscle fibers (**Figure 4**). In three (10,7%) cases, eosinophilic infiltration was increased compared to the other cases had

history of failed dextranomer/hyaluronic-acid(Dx/HA) injections.

Immunohistochemistry

There was no a significant difference in the amount of cytokines between the patients with primary VUR and patients with primary VUR following failed injection therapy with Dx/HA. The mean VEGF and CD34 scores were 5.7 ± 15.1 (0-80) cells per HPF and 9.6 ± 3.5 (3-21) vessels per HPF in ureters with reflux with primary VUR respectively; and these values were 16.2 ± 23.6 (0-90) cells per HPF and 10.2 ± 3.5 (4-16) vessels per HPF in ureters with reflux had history of failed dextranomer/hyaluronic-acid(Dx/HA) injections these values were 60.6 ± 16.4 (32-84) cells per HPF and 17.8 ± 4.1 (12-24) vessels per HPF in the control group.

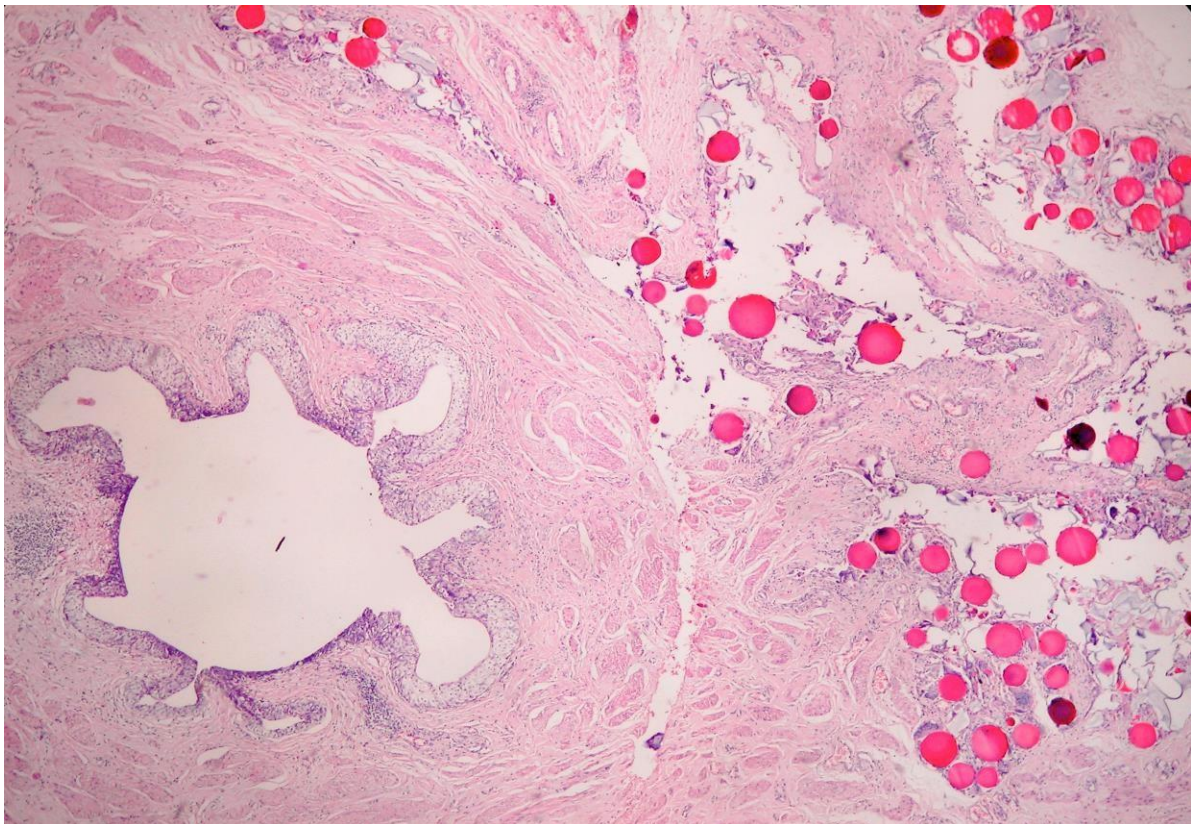


Figure 4. Injection material (Dx/HA) is located in the muscle fibers with a giant cell reaction around.

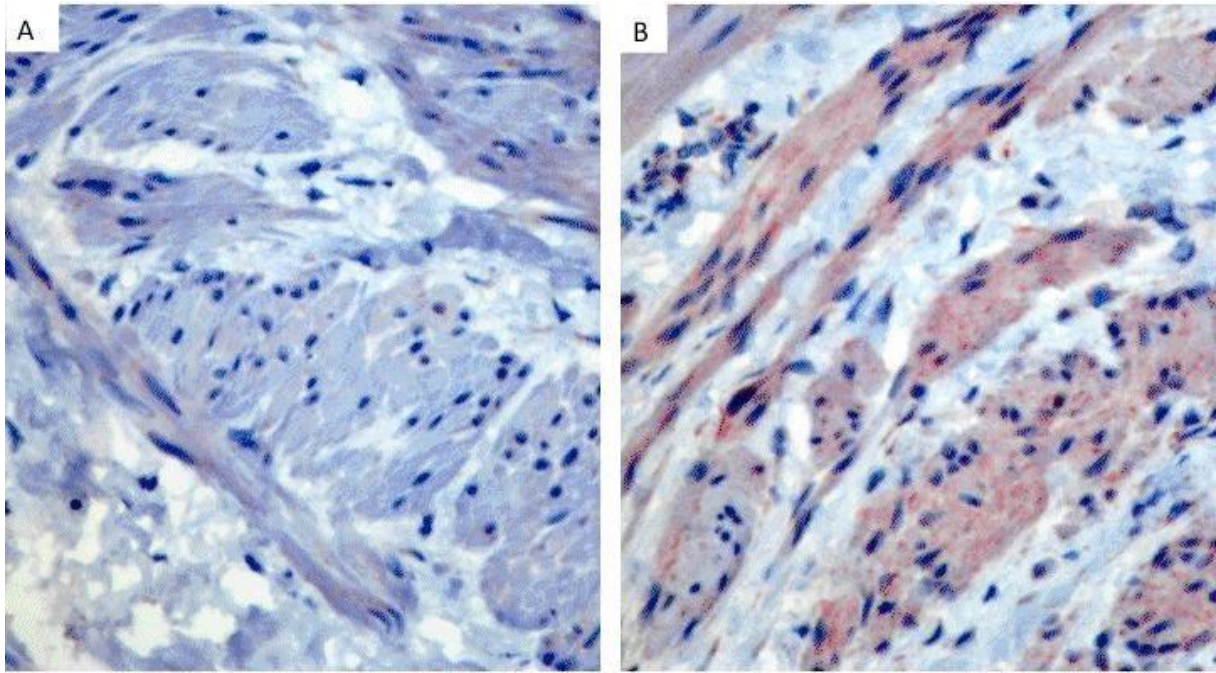


Figure 5. VEGF expression is significantly decreased in Grade III reflux (A) compared with the control group(B) (VEGF by immunohistochemistry, x200).

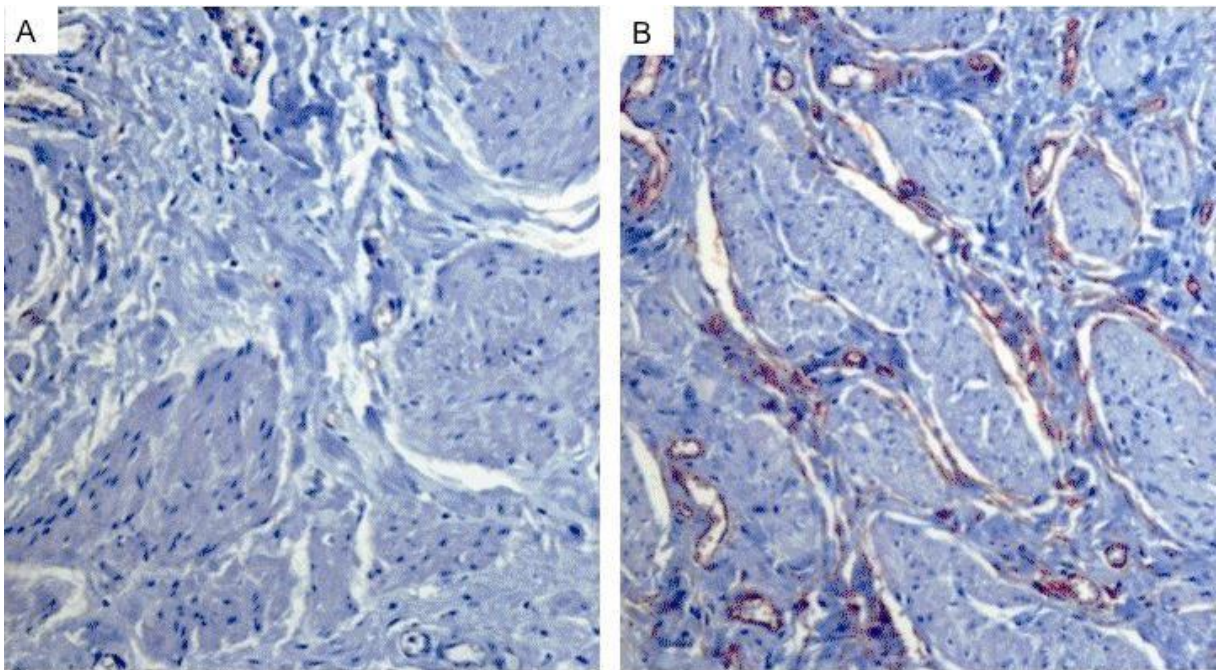


Figure 6. Microvessel density is obviously decreased in Grade IV reflux (A) compared with the control group(B) (CD34 by immunohistochemistry, x100)

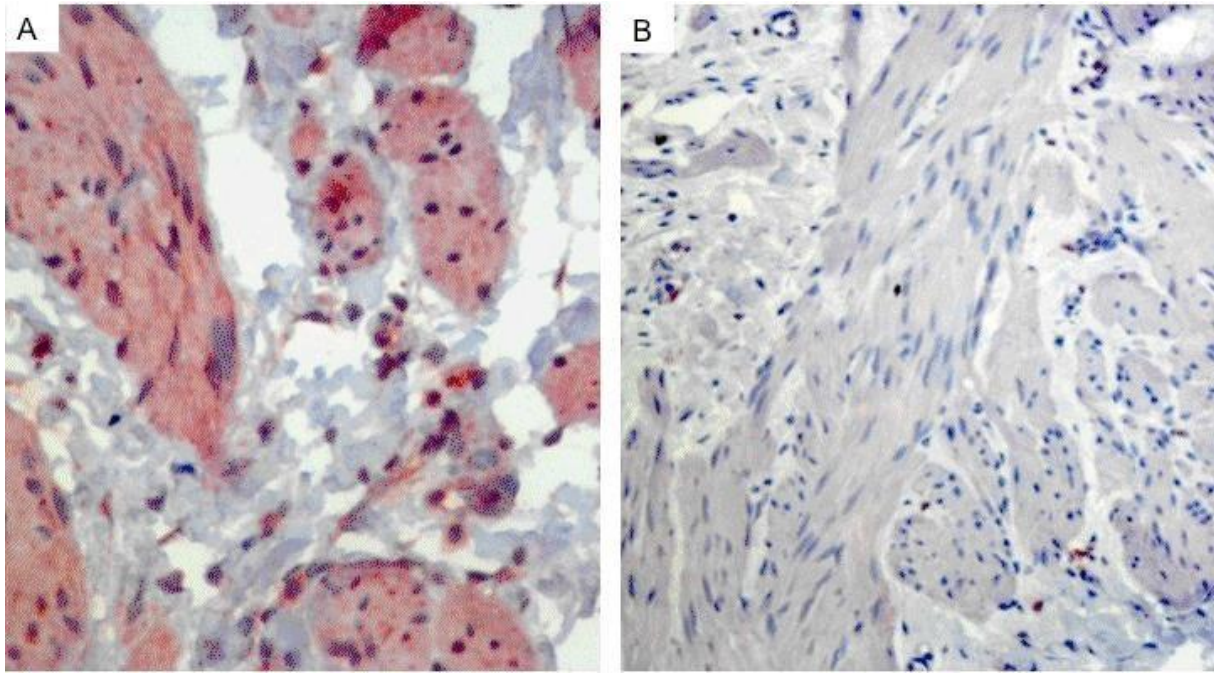


Figure 7. TGFβ1 expression is obviously higher in Grade III reflux (A) compared with the control group(B) (TGFβ1 by immunohistochemistry, x400 (A) and x200 (B)).

The amount of VEGF and CD34 were same both of the patients with primary VUR and patients with primary VUR following failed injection therapy with Dx/HA. However, the amount of VEGF and CD34 were significantly decreased in patients compared with the control group ($p < 0.001$ and $p < 0.001$) (**Figure 5 and 6, subsequently**). The TGF-β1 levels were same in both of the patients with primary VUR and patients with primary VUR following failed injection therapy with Dx/HA. Conversely, TGF-β1 levels were significantly higher in patients with VUR compared with the control group ($p = 0.001$) (**Figure 7**). The amount of VEGF, CD34, and TGF-β1 were not correlated with the grade of reflux ($p = 0.26$, $p = 0.94$, and $p = 0.42$, respectively).

Discussion

Although the exact mechanism of VUR remains unknown, several studies have shown that abnormalities in UV smooth muscle, architectural deficiencies in tunnel length, extracellular matrix composition and neural function, activation of matrix degrading enzymes, accumulation of phagocytes and impaired vascularization, loss of gap junctions and ganglionic cells have a significant role in the pathophysiology of VUR.¹⁴⁻¹⁸ However, there are few electron microscopic studies analyzing the UVJ in depth, which are citable in the literature.¹⁸⁻²⁰

In 1976, Hanna et al firstly described the normal ultrastructure of the UVJ in humans.²¹ The structure of the adventitia, the muscular layers, submucosa, tunica mucosa were distinctly identified by TEM.

In one of the few studies about this topic by Sofikerim et al.²² They examined 24 distal intravesical ureteric by using TEM and found normal and similar structures for the tunica mucosa and the tunica adventitia in all patients irrespective of the VUR grade. However, they reported pathological findings only in the muscular layers. Increasing degrees of intercellular edema and intracytoplasmic vacuoles with increasing VUR grades was shown semi-quantitatively in the smooth muscle layer and the smooth muscle cellular structure. In our study, using TEM, the urothelium, lamina propria and tunica adventitia were seen as normal in all grade VUR specimens. Increased cytoplasmic density of some smooth muscle cells and ultrastructural changes such as intercellular edema in the muscular layer were observed in all the specimens of patients had history of failed dextranomer/hyaluronic-acid(Dx/HA) injections. Intercellular edema was observed in the muscular layer in grade IV-V VUR specimens of patients had no history of dextranomer/hyaluronic-acid(Dx/HA) injections, whereas the intercellular space in grade I-III VUR specimens of patients had no history of dextranomer/hyaluronic-acid(Dx/HA) appeared normal. This study demonstrates that there is damage to the muscular layer of the UVJ in patients with and without endoscopic injection, and these changes may lead to the dysfunction of cells and their organelles and result in reflux. As a result, we proposed that this condition might affect the spontaneous resolution of VUR, particularly in high-grade patients.

Routh et al. evaluated 16 children who underwent ureteroneocystostomy after failed Dx/HA injection.²³ This was the

first study to use the immunohistochemical methods such as CD3, CD20, and MIB-1 staining to examine lymphocyte infiltration and nuclear turnover. They reported slightly increased periureteral inflammation with time and low cell turnover rates (MIB-1), indicating that there was no increase in nuclear proliferation. Ben-Meir et al. investigated the cause of failure of the endoscopic Dx/HA injections.²⁴ Malpositioning of the Dx/HA injections were found in 95% of the examined ureters. In the literature, similar histological findings were reported by other studies as previously discussed.²³⁻²⁴

Schwentner et al.²⁵ studied the extracellular microenvironment and cytokine profiles at the UVJ in children with VUR by immunohistochemistry. Cytokines such as TNF- α , TGF- β 1, IGF-1, NGF, and VEGF, were analyzed in their study. They reported that the amount of TNF- α and TGF- β 1 to be significantly higher in patients with reflux compared with the levels measured in the control group. Whereas IGF-1, NGF, and VEGF were more abundant healthy individuals. The expression of the markers did not correlate with age or VUR grade. Additionally, it was shown that TGF- β 1 is a potent growth inhibitor for ureteral smooth muscle cells, and up-regulation of this cytokine being observed in primary mega-ureters cases.²⁶⁻²⁷ In our study, we showed that TGF- β 1 levels were not significantly difference between the patients with primary VUR and patients with primary VUR following failed injection therapy with Dx/HA. However significantly TGF- β 1 levels were higher in patients with VUR compared with levels in the control group (p= 0.001).

VEGF, which is a stimulator in vasculogenesis is a signal protein produced by muscle or endothelial cells to protect the tissue under conditions of stress, including hypoxia and ischemia. Additionally, it is important for regulating tissue growth, nerve coordination and gap junction metabolism.²⁵ The lack of VEGF in the distal intra-vesical ureters with reflux may be associated with primary VUR secondary to smooth muscle ablation and impaired micro perfusion. The role of microvessel architecture has been investigated by some authors because refluxing ureteral endings display the stigmata of ischemic tissues.²⁸ VEGF has been shown to be a stimulant in the growth of blood vessels. We studied the expression of VEGF and CD34 to determine the relationship with reflux. We discovered that the amount of VEGF and micro vessel density was not significantly different when compared with the patients with primary VUR and patients with primary VUR following failed injection therapy with Dx/HA. However, the amount of VEGF and micro vessel density were significantly lower in patients with reflux when compared with the levels in the control group. This is consistent with the literature ($p < 0.001$, and $p < 0.001$, respectively)^{13,14,28-29}. These results support the hypothesis in the role of ischemia in the pathogenesis of VUR. Additionally, no significant correlation was observed between the degree of reflux and measured VEGF, CD34, and TGF- β 1 levels ($p = 0.84$; $p = 0.76$; and $p = 0.10$, respectively). Nevertheless, we recognize the limitations of this study, which include the lack of an evaluation of autonomic innervations and gene mutations due to the financial restrictions and the small number

in the control group to investigate ultra-structural investigations.

In this study, it was shown that ultrastructural changes of the muscle cells were observed in all VUR specimens of both the patients with primary VUR and patients with primary VUR following failed injection therapy with Dx/HA and the immune-histopathological findings were similar to previous reports regarding the primary refluxing ureters. Both of changes were significantly different compared to the control group. There was no a significant difference in the amount of cytokines between the patients with primary vesicoureteral reflux (VUR) and patients with primary VUR following failed injection therapy with Dx/HA. The amount of VEGF, CD34 and the TGF- β 1 levels were same in both of patients with primary VUR and patients with primary VUR following failed injection therapy with Dx/HA.

Funding

None.

Conflict of Interest

None.

References

1. Skoog SJ, Peters CA, Arant Jr BS, et al: Pediatric Vesicoureteral Reflux Guidelines Panel summary report: clinical practice guidelines for screening siblings of children with vesicoureteral reflux and neonates/infants with prenatal hydronephrosis. *J Urol* 2010;184:1145-51.
2. Drzewiecki BA, Thomas JC, Pope JC 4th, et al: Observation of patients with vesicoureteral reflux off antibiotic prophylaxis: physician bias on patient selection and risk factors for

- recurrent febrile urinary tract infection. *J Urol* 2012;188:1480-4.
3. Tekgül S, Riedmiller H, Hoebeke P, et al: EAU Guidelines on vesicoureteral reflux in children. *Eur Urol* 2012;62(3):534-42.
 4. Peters C, Rushton HG: Vesicoureteral reflux associated renal damage: congenital reflux nephropathy and acquired renal scarring. *J Urol* 2010;184(1):265-73.
 5. Normand IC, Smellie JM. Prolonged maintenance chemotherapy in the management of urinary infection in childhood. *Br Med J*. 1965;1:1023-6.
 6. Politano VA, Leadbetter WF. An operative technique for the correction of vesicoureteral reflux. *J Urol*. 1958;79:932-41.
 7. Glenn JF, Anderson EE. Distal tunnel ureteral reimplantation. *J Urol*. 1967;97:623-6.
 8. Matouschek E. New concept for the treatment of vesico-ureteral reflux. Endoscopic application of teflon. *Arch Esp Urol*. 1981; 34:385-8.
 9. Dixon JS, Jen PY, Yeung CK, et al: The structure and autonomic innervation of the vesico-ureteric junction in cases of primary ureteric reflux. *Br J Urol* 1998;81:146-51.
 10. Hanna MK, Jeffs RD, Sturgess JM, et al: Ureteral structure and the ultrastructure. Part 1. The normal human ureter. *J Urol* 1976; 116(6):725-30.
 11. Sofikerim M, Sargon M, Oruc O, et al: An electron microscopic examination of the intravesical ureter in children with primary vesico-ureteric reflux. *BJU Int* 2007;99:1127-31.
 12. Lebowitz RL, Olbing H, Parkkulainen KV, Smellie JM, Tamminen-Möbius TE. International Reflux Study in Children: international system of radiographic grading of vesicoureteric reflux. *Pediatr Radiol*. 1985; 15: 105-9.
 13. Oswald J, Brenner E, Schwentner C, Deibl M, Bartsch G, Fritsch H and Radmayr C. The intravesical ureter in children with vesicoureteral reflux: a morphological and immunohistochemical characterization. *J Urol* 2003; 170: 2423-7.
 14. Puri P, Pirker M, Mohanan N, Dawrant M, Dass L and Colhoun E. Subureteral dextranomer/hyaluronic acid injection as first line treatment in the management of high-grade vesicoureteral reflux. *J Urol* 2006; 176(4S):1856-60.
 15. Stenberg A, Hensle TW and Lackgren G Vesicoureteral reflux: a new treatment algorithm. *Cur Urol Rep* 2002;3:107-14.
 16. Kirsch AJ, Perez-Brayfield M, Smith EA and Scherz HC. The modified sting procedure to correct vesicoureteral reflux: improved results with submucosal implantation within the intramural ureter. *J Urol* 2004;171:2413-6.
 17. Stenberg A, Läckgren G. A new bioimplant for the endoscopic treatment of vesicoureteral reflux: experimental and short-term clinical results. *J Urol* 1995;154:800-3.
 18. Lackgren G, Wahlin N, Skoldenberg E and Stenberg A. Long term follow up of children treated with dextranomer/hyaluronic acid copolymer for vesicoureteral reflux. *J Urol* 2001;166:1887-92
 19. Routh JC, Vandersteen DR, Pfefferle H, Wolpert JJ and Reinberg Y. Single center experience with endoscopic management of vesicoureteral reflux in children. *J Urol* 2006;175:1889-92.
 20. Lavelle MT, Conlin MJ, Skoog SJ. Subureteral injection of Deflux for correction of reflux: analysis of factors predicting success. *Urology* 2005;65(3):564-7.
 21. Hanna MK, Jeffs RD, Sturgess JM and Barkin M. Ureteral structure and the ultrastructure. Part 1. The normal human ureter. *J Urol* 1976; 116:718-24.
 22. Sofikerim M, Sargon M, Oruc O, Dogan HS and Tekgul S. An electron microscopic examination of the intravesical ureter in children with primary vesico-ureteric reflux. *BJU Int* 2007;99:1127-31.
 23. Routh JC, Ashley RA, Sebo TJ, Vandersteen DR, Slezak J and Reinberg Y. Histopathological changes associated with dextranomer/hyaluronic acid injection for pediatric vesicoureteral reflux. *J Urol* 2007; 178:1707-10.
 24. Ben-Meir D, Morgenstern S, Sivan B, Efrat R and Livne PM. Histology proved malpositioning of dextranomer/hyaluronic acid in submucosal ureter in patients after failed endoscopic treatment of vesicoureteral reflux. *J Urol* 2012;188:258-61.
 25. Schwentner C, Oswald J, Lunacek A, et al. Extracellular microenvironment and cytokine profile of the ureterovesical junction in children with vesicoureteral reflux. *J Urol*. 2008;180:694-700.
 26. Stehr M, Estrada CR, Khoury J et al: Caveolae are negative regulators of transforming growth factor-beta1 signaling in ureteral smooth muscle cells. *J Urol* 2004;172:2451-5.
 27. Tokunaka S, Gotoh T, Koyanagi T et al: Muscle dysplasia in megaureters. *J Urol* 1984; 131: 383-90..
 28. Schwentner C, Oswald J, Lunacek A, et al: Structural changes of the intravesicalureterin children with vesicoureteral reflux—does ischemia have a role? *J Urol* 2006;176(5):2212-18.
 29. Schwentner C, Oswald J, Lunacek A, et al: Loss of interstitial cells of Cajal and gap

junction protein connexin 43 at the vesicoureteral junction in children with vesicoureteral reflux. J Urol 2005;174(5):1981-6.