

## Double Right Coronary Artery: A Report of Two Cases

### Çift Sağ Koroner Arter: İki Vakanın Sunumu

**Kemal Karaağaç, Özlem Arıcan Özlük, Fahriye Vatansver, Mustafa Yılmaz**

Bursa İhtisas Training And Research Hospital, Department Of Cardiology

#### Abstract

Coronary artery anomalies are uncommon and often asymptomatic. A double right coronary artery is an extremely rare coronary artery anomaly, and only a few cases of double right coronary artery have been reported. Interestingly, most of the cases about this anomaly were reported from Turkey. In this case reports, we aimed to present double right coronary artery anomaly in two patients who was admitted with typical chest pain.

**Keywords:** Coronary vessel anomalies, coronary angiography

**Başvuru Tarihi:** 01.10.2012 **Kabul Tarihi:** 30.11.2012

#### Özet

Koroner arter anomalileri nadir görülürler ve genellikle asemptomatiklerdir. Çift sağ koroner arter son derece nadir görülen koroner arter anomalisi olup, sadece birkaç çift sağ koroner arter vakası bildirilmiştir. İlginç olarak, bu anomali ile ilgili vakaların çoğunluğu Türkiye'den bildirilmiştir. Bu olgu sunumunda tipik göğüs ağrısı ile başvuran iki hastadaki çift sağ koroner arter anomalisini sunmayı amaçladık

**Anahtar Kelimeler:** Koroner damar anomalileri, koroner anjiyografi

**Application:** 01.10.2012 **Accepted:** 30.11.2012

#### Introduction

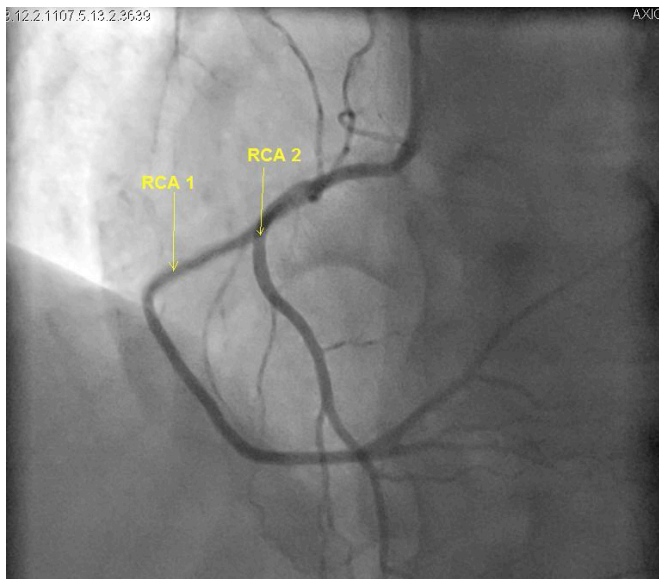
Coronary artery anomalies (CAA) occur in less than 1% of the cases undergoing coronary angiography, and constitute 1-2% of all congenital heart disease.<sup>1</sup> A variable incidence has been reported at autopsy, catheter coronary angiography, surgery, and cross-sectional imaging studies.<sup>2,3</sup> The most common CAA involve the left coronary system.<sup>4</sup> Double right coronary artery (DRCA) is a very rare coronary abnormality that is generally considered benign.<sup>5</sup> In this report, we present two cases of DRCA.

#### Case 1

A 67-year-old woman administered to our hospital due to chest pain. She was complaining of angina and dyspnea on exertion since two weeks. Her risk factors for coronary artery disease included history of diabetes mellitus, hypertension, and obesity. Blood pressure was 150/80 mm Hg and pulse rate was 90 bpm. The physical examination was completely normal. Cardiac enzymes and troponin-T levels were also found normal. An ST segment depression was noted in leads II, III, and aVF on electrocardiography (ECG). The patient underwent selective left and right coronary artery angiography. The

left coronary angiography revealed a normal origin and course of the left main artery (LM), the left circumflex artery (LCx), and the left anterior descending (LAD) arteries. The right coronary angiography revealed two different right coronary arteries arising from a common ostium in the right coronary sinus valsalva **Figure 1**. Both arteries were free of critical atherosclerotic lesions.

**Figure 1 :** Left anterior oblique cranial view showing a double right coronary artery(yellow arrows)



## Case 2

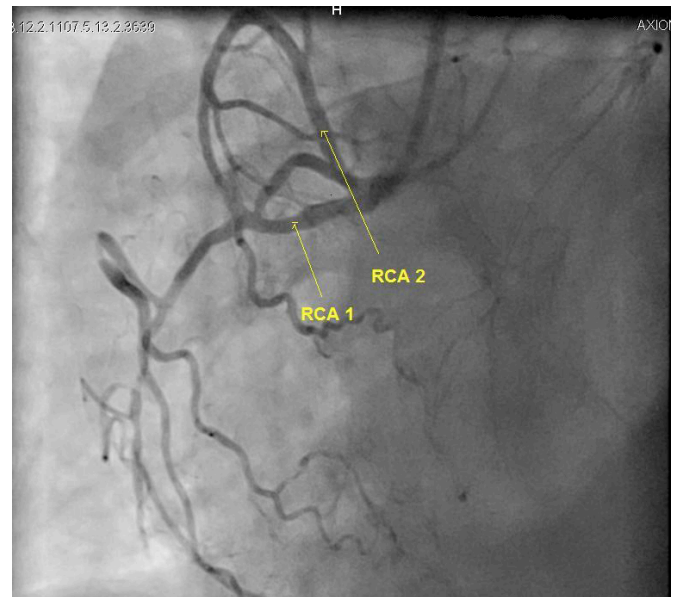
A 50-year-old man administered to our hospital due to chest pain. He was complaining of angina and dyspnea on exertion since one week. He was a chronic smoker and had hypertension for 4 years. Blood pressure was 170/90 mm Hg and pulse rate was 90 bpm. The physical examination was completely normal. Cardiac enzymes and troponin-T were also normal. The patient underwent selective left and right coronary artery angiography. The left coronary arteries were of normal origin and distribution. The right coronary angiography revealed two separate RCAs originating from a single ostium in the right sinus of valsalva **Figure 2**.

## Discussion

DRCA is a very rare coronary anomaly. This anomaly is

seen mostly in males, as are other congenital coronary anomalies.<sup>6</sup> It has been described as a right coronary system formed of two distinct branches running very closely together in the atrioventricular groove, for at least half of the entire course of the right coronary artery.<sup>7</sup>

**Figure 2 :** Left anterior oblique cranial view showing a double right coronary artery(yellow arrows)



In some cases, DRCA arises from two separate ostia in the right sinus of Valsalva, whereas in some cases RCA comes out from a single ostium and after a short distance from the body is divided into two.<sup>8</sup> Therefore, the definition of DRCA presents some differences. In 37 reports 44 cases of DRCA have been reported in the literature as “duplicated right coronary artery”, “dual right coronary artery”, and “split right coronary artery”. Interestingly, most cases of DRCA was reported from Turkey and was classified by Vural M **Table 1**.<sup>9,10</sup> According to this classification, a DRCA arising from double ostia and goes side by side in the atrioventricular groove is defined as a real DRCA. If DRCA does not supply the blood to the left ventricle, does not continue as posterior descending artery (PDA) or posterior lateral artery (PL), and gives off a large right ventricular artery at a point higher than usual, then it is defined as pseudo-DRCA. If not either of the above, then it is defined as atypical DRCA. DRCA may be associated with atherosclerosis leading to

**Table 1** : Classification of double RCA

Classification	Type	Features
Real (G) Dual RCA	G1	Double RCA, origin from the right aortic sinus with separate ostiums and continue in AV sulcus side by side until posterior interventricular sulcus
	G2	Double RCA origin from the right aortic sinus. After a short main RCA, they are divided (in proximal), and continue in AV sulcus side by side until posterior interventricular sulcus
	G3	Duble RCA origin from different aortic sinuses
	G4	RCA-conus branch or RCA-RV artery origin from separate ostiums
Atypical (A) Double RCA	A1	Early PDA (PDA follows normal path from mid part of the RCA . This is also called high-output PLA)
	A2	Advanced RV branch origin from proximal or mid part of RCA ,and terminated as RCA and PDA
	A3	PDA and PLA separated from distal RCA before crux
	A4	Double PDA separated from crux
Pseudo-Double (Y) RCA	Y1	PDA or PLA is not reached to the left ventricle, advanced RV branch is not continued as RCA
	Y2	Other pseudo-dual RCA situations, such as over-dominant RCA

AV: atrioventricular, PDA: posterior descending artery, PLA: right ventricular posterior-lateral branches, RCA: right coronary artery, RV: right ventricle

life-threatening arrhythmia and myocardial infarction.<sup>11</sup> In the absence of atherosclerotic lesions, ischemia leading to chest pain may be due to anatomical malformations, including an acute takeoff angle of the duplicated vessel, myocardial squeezing, vasospasm, and small coronary artery.<sup>12</sup> Angiographic examination of our patients' coronary arteries were free of atherosclerotic lesions.

Multislice computed tomography (MSCT) may also be used to determine the type of DRCA. However, other than the classification of patients, this technique has no additional benefits, and MSCT is not usually required.<sup>10</sup> According to this classification, the first of our cases has

A1 atypical DRCA and the second case has A2 atypical DRCA. Because of no expected additional benefit for our patients, MSCT was not performed following coronary angiography.

We conclude that, although controversy exists about the definition of a double RCA, it is generally considered as a benign entity. Yet it may be atherosclerotic in origin and lead to acute coronary syndrome including myocardial infarction and may be associated with other anomalies.<sup>13</sup> Every operator should be familiar with coronary anomalies to perform an adequate examination.

## References

1. Harikrishnan S, Jacob SP, Tharakan J, Titus T, Kumar VK, Bhat A, et al. Congenital coronary anomalies of origin and distribution in adults: a coronary arteriographic study. *Indian Heart J* 2002;54(3):271-5.
2. Sundaram B, Kreml R, Patel S. Imaging of coronary artery anomalies. *Radiol Clin North Am* 2010;48(4):711-27.
3. Yamanaka O, Hobbs RE. Coronary artery anomalies in 126,595 patients undergoing coronary arteriography. *Cathet Cardiovasc Diagn* 1990;21(1):28-40
4. Click RL, Holmes Jr DR, Vlietstra RE, Kosinski AS, Kronmal RA. Anomalous coronary arteries: location, degree of atherosclerosis and effect on survival— a report from the Coronary Artery Surgery Study. *J Am Coll Cardiol* 1989;13(3):531-7
5. Selcoki Y, Yilmaz OC, Er O, Eryonucu B. Double right coronary artery: a report of two cases. *Clinics (Sao Paulo)*. 2010;65(4):449-51.
6. Misuraca L, Rutigliano D, Pestrichella V, Contegiacomo G, Balbarini A. A very rare congenital abnormality: double right coronary artery. A case report. *J Cardiovascular Medicine*. 2009;10(8):643-5
7. Misuraca L, Balbarini A. Double right coronary artery or split right coronary artery: the same anomaly? *J Cardiovasc Med (Hagerstown)* 2010;11:398
8. Kunimasa T, Sato Y, Ichikawa M, et al. MDCT detection of double right coronary artery arising from a single ostium in the right sinus of Valsalva: report of 2 cases. *Int J Cardiol* 2007;115:239-4
9. Chen YF, Chien TM, Chen CW, et al. Double right coronary artery or split right coronary artery? *Int J Cardiol*. 2012;154(3):243-5
10. Vural M. Suggestions for definition and classification of double right coronary artery, which is frequently seen in Turkey despite its rarity in the literature. *Anadolu Kardiyol Derg (Turkish)* 2008;8:303-4.
11. Rohit M, Bagga S, Talwar KK. Double right coronary artery with acute inferior wall myocardial infarction. *J Invasive Cardiology*. 2008;20:37-40.
12. Tuncer C, Batyraliev T, Yilmaz R, Gökçe M, Eryonucu B, Körolu S. Origin and distribution anomalies of the left anterior descending artery in 70,850 adult patients: multicenter data collection. *Catheter Cardiovasc Interv* 2006; 68: 574-85
13. Halit A, Ferhat O, Mehmet B, et al. A Rare Coronary Anomaly: Atypical Double Right Coronary Artery With an Acute Inferior Myocardial Infarction. *Korean Circ J* 2012;42:208-211