

Giant Left Atrial Thrombus in Mild Mitral Stenosis Without Embolic Complication

Hafif Mitral Stenozda Embolik Komplikasyona Yol Açmayan Dev Trombüs

Hüseyin Gündüz, İbrahim Kocayigit, Mehmet Akif Cakar, Mehmet Bülent Vatan,
Saadet Demirtaş, Altuğ Ösken, Levent Ediş

Sakarya University Medical Faculty, Department of Cardiology, Sakarya, Türkiye²

Abstract

While large left atrial mural thrombi are frequently occurred in moderate and severe mitral stenosis, left atrial thrombi are rarely seen in mild mitral stenosis. In this report we presented a case of 71-year-old woman with rheumatic mild mitral valve stenosis but had a giant left atrial thrombus derected by echocardiography.

Keywords: rheumatic mild mitral valve stenosis, left atrium, giant thrombus, embolic complication

Application: 09.11.2012 **Accepted:** 27.12.2012

Özet

Orta ve ileri mitral darlığında büyük sol atriyal trombüs sık görülmekte iken hafif mitral darlığında sol atriyal trombüs nadirdir. Bu makalede, biz 71 yaşında bir bayanda hafif romatizmal mitral darlığı olmasına rağmen ekokardiyografi ile sol atriyumda dev trombüs tespit edilen bir olgu sunduk.

Anahtar Kelimeler: romatizmal mitral darlığı, sol atriyum, dev trombüs, embolik komplikasyon

Başvuru Tarihi: 09.11.2012 **Kabul Tarihi:** 27.12.2012

Introduction

Although most of the left atrial thrombus are complicated with mitral stenosis and most thrombi are located in the left atrial appendage, left atrial thrombus in mild mitral disease is rare. Regardless of the underlying mechanism, the diagnosis of a left atrial thrombus ball should be regarded as an urgent indication for preventive surgery.¹

Case report

A 71-year-old woman with rheumatic mitral valve steno-

sis was referred to our clinic. She had dispnea without syncope or palpitation. Neurological examination was normal. She was in atrial fibrillation of unknown duration and without oral anticoagulation.

The telecardiogram showed cardiomegaly and mitralization of the heart. Transthoracic echocardiography revealed mild mitral stenosis (mitral valve area was measured 1.7 cm² by pressure half-time) and a large crescent-shaped homogenous mass lying in the left atrium.

Transthoracic echocardiography also revealed normal left ventricular dimension and function and left atrial di-

lation. Transesophageal echocardiography identified a giant left atrial thrombus occupying a large percent of the left atrium filling left atrial appendage (Figure-1, 2). The patient was referred to the surgical department immediately.

Figure 1: Transesophageal echocardiography revealed a giant atrial thrombus expanding left atrial appendage.

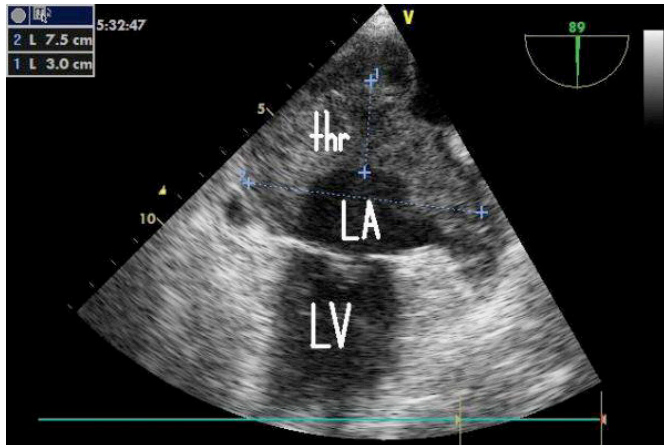
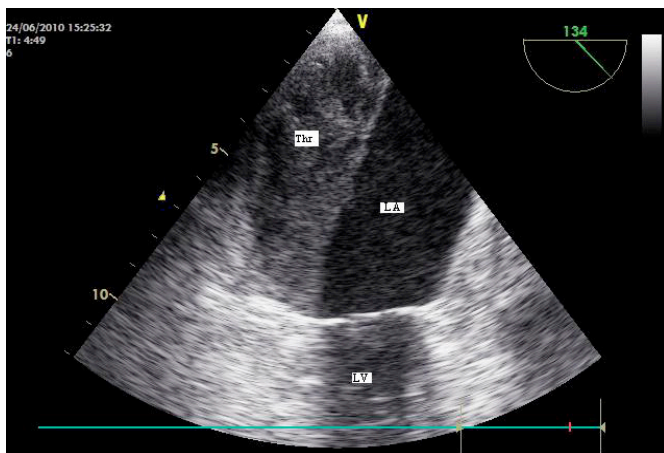


Figure 2: Transesophageal echocardiographic two-chamber view presenting a large thrombus hugging the left atrial wall



Discussion

Atrial fibrillation and left atrial size are independent predictors of clot formation in the left atrium in patients with mitral stenosis. Although left atrial thrombi are not seen frequently, they need treatment when detected as they can lead to catastrophic outcomes. Most thrombi are located in the left atrial appendage, but in 2% of all mitral stenosis the auricular thrombus extends to the left atrial

cavity.² While large left atrial mural thrombi are frequently occurred in moderate and severe mitral stenosis, left atrial thrombi are rarely seen in mild mitral stenosis as in our case.² Early diagnosis is of vital importance and surgical intervention is considered the best treatment option.¹

References

1. Lee JH, Kang SK, Lee CW, Song JK, Park JS, Choo SJ. Giant left atrial ball thrombus in a patient with chronic nonvalvular atrial fibrillation. *Ann Thorac Surg.* 2008;85:313-5.
2. Goswami KC, Yadav R, Bahl VK. Predictors of left atrial appendage clot: a transesophageal echocardiographic study of left atrial appendage function in patients with severe mitral stenosis. *Indian Heart J.* 2004;56:628-35.
3. Rost C, Daniel WG, Schmid M. Giant left atrial thrombus in moderate mitral stenosis. *Eur J Echocardiogr.* 2009;10:358-9.