

Pigmented Villonodular Synovitis İn Lumbar Spine: A Case Report

Lomber Bölgede Pigmente Villonodüler Sinovit:

Olgu Sunumu

Eda Parlak¹, Mustafa Yıldırım², Betül Çelik³, Cengiz Özdemir⁴

¹ Antalya Education and Research Hospital, Department of Radiology, Antalya, Turkey

² Antalya Education and Research Hospital, Department of Medical Oncology, Antalya, Turkey

³ Antalya Education and Research Hospital, Department of Patology, Antalya, Turkey

⁴ Antalya Education and Research Hospital, Department of Brain Surgery, Antalya, Turkey

Abstract

Pigmented villonodular synovitis is benign proliferative disease of the synovial structures. Although it frequently occurs in large joints, it may rarely affect the cervical and lumbar spinal area. This article will discuss the clinical, radiological and histopathologic findings of a case which was histopathologically diagnosed as localized pigmented villonodular synovitis following intradural total mass excision, along with the current literature.

Keywords: Pigmented villonodular synovitis, Lumbar spine, Magnetic Resonance İmaging

Application: 07.08.2011 **Accepted:** 04.11.2011

Özet

Pigmente villonodüler sinovit, sinovial yapıların benign proliferatif bir hastalığıdır. Daha çok diz, kalça eklemi gibi geniş eklemlerde görülmekle birlikte az oranda da olsa servikal ve lomber spinal bölgede de rastlanabilir. Bu yazımızda intradural total kitle eksizyonunu takiben histopatolojik olarak lokalize pigmente villonodüler sinovit tanısı alan olgu klinik, radyolojik ve histopatolojik bulguları ile güncel literatür eşliğinde tartışılacaktır.

Anahtar Kelimeler: Pigmente villonodüler sinovit, lomber spinal, Manyetik Rezonans Görüntüleme

Başvuru Tarihi: 07.08.2011 **Kabul Tarihi:** 04.11.2011

Introduction

Pigmented villonodular synovitis is an idiopathic, benign proliferative disease of the synovial structures, which is common among young or middle-aged adults. Although it frequently occurs in large joints, it may rarely affect the cervical and lumbar spinal area.

This article will discuss the clinical, radiological and his-

topathologic findings of a case which was histopathologically diagnosed as localized pigmented villonodular synovitis following intradural total mass excision, along with the current literature.

Case

A 55-year-old female patient was admitted to our hospital with increased complaints of back pain and leg pain,

which had been going on for a year. Physical examination identified a strength loss of 2-3/5 in the right foot and 3-4/5 in the left foot. The patient underwent magnetic resonance imaging (MRI) in the lumbar area with 1.5 Tesla MR equipment (Phillips Gyroscan Intera, Netherlands). T1 (TE 10-15, TR 500-700) and T2 (TE 120-150, TR 3000-3500) weighted images were obtained on the sagittal plan, and T1 weighted images after injection of contrast material were obtained on the axial plan. MRI revealed an extradural mass lesion of approximately 15 millimeters which was located on the left-posterior side. It was on the level of L4-L5 intervertebral disc, compressing the thecal sac and constricting the spinal tract (Figure 1). The lesion gave hypointense signals at T1-weighted sequences, and mixed signal intensity at T2-weighted sequences. However, in T2-weighted sequences, the peripheral portion gave an image, which was considered hypointensive hemosiderin rim (Figure 1,2). For purposes of excluding possible malignancy, a T1-weighted sequence was applied following intravenous injection of contrast material, and it was demonstrated that the lesion did not contrast on post-contrast T1 images (Figure 3), which was consistent with the benign conditions.

L4-5 distectomy and laminectomy were performed in surgery. A mass which adhered to the dura, particularly forming a head in posterior and stretching along the disc length was seen and excised.

Figure 1: Expansile heterogeneous hyperintensive mass lesion localized in the spinal tract at the L4-5 intervertebral disc level in T2-weighted sagittal lumbar MRI

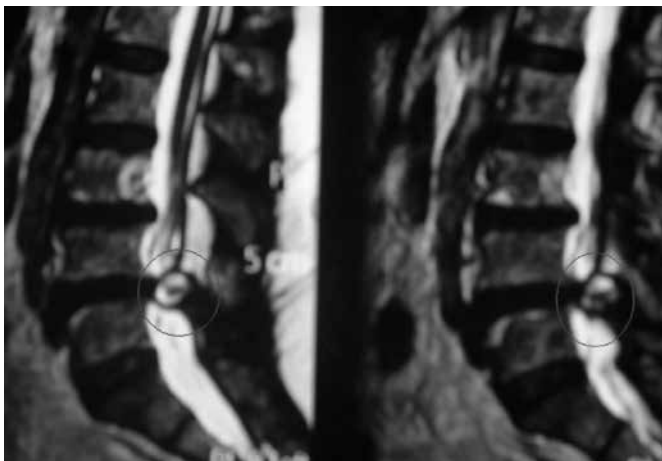


Figure 2: Hyperintensive nodular mass compressing the thecal sac in the left side of epidural area in T2-weighted axial MRI

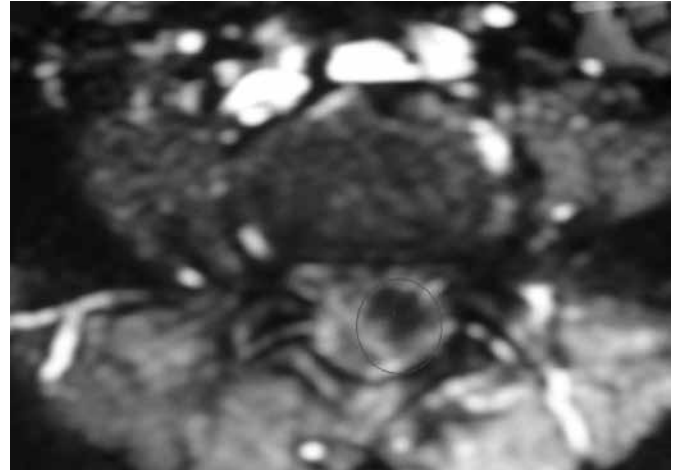
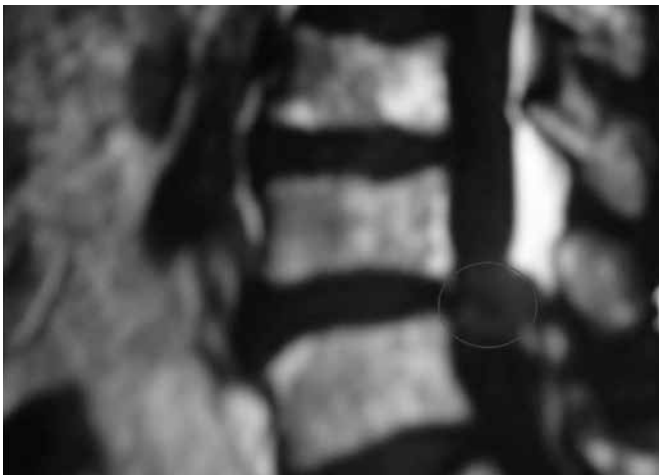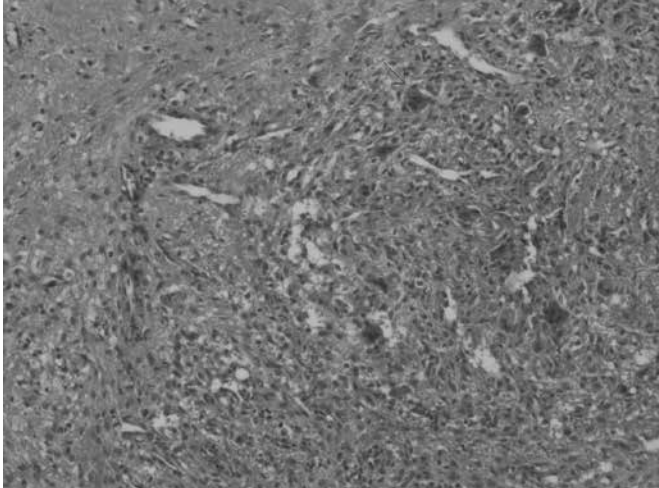


Figure 3: The lesion was hypointensive in post-IVCM T1-weighted sagittal images, and there was not any significant contrasting weighted sagittal images, and there was not any significant contrasting



The lesion and the distectomy and laminectomy material were submitted together to the pathology laboratory. Tissue submitted consisted of 12 cc grayish-tan soft tissue fragments. Histopathologic examination revealed degenerated cartilaginous examples of distectomy and laminectomy specimen and fibroadipose tissues. Within these, admixture of proliferated synovial cells, giant cells and hemosiderin were seen (Figure-4 and 5). The patient was discharged on the seventh day after operation without any neurological deficits. The patient is still on follow-up.

Figure 4-5: Proliferated synovial cells, giant cells and hemosiderin



Discussion

Pigmented villonodular synovitis (PVNS) is characterized by synovial cell hyperplasia and synovial accumulation of hystiocyte-like cells and their reproduction on the joint. It was first defined by Jaffe et al. in 1941. Although usually affects large joints, it rarely occurs in small joints and the spinal area. The first case affecting the spinal area was reported by Kleinman in 1980¹. In spite of attributed etiology to inflammatory reactions, neoplasia, hyperplasia, metabolic reasons and post-traumatic hemorrhages, the primary reason is believed to be trauma. Histopathologic examination reveals a characterization of synovial cell hyperplasia, subsynovial accumulation of hystiocy-

te-origin giant cells and their reproduction on the joint. The radiologic appearance is primarily determined by the amount of foam-like macrophage that contains hemosiderin and fat. Although hemosiderin, adipose tissue and number of giant cells were relatively low in our case, the radiological appearance was spesific.

PVNS frequently affects young adults from 20 to 50 years old. Its occurrence among male and female patients is equal². The patients usually have complaint of secondary findings due to compression of nerves in the affected area or extradural soft tissues as in our case. Our patient also had complaints of long-standing back and leg pain, which increased progressively recently.

PVNS has diffused and localized forms³. While the whole synovial tissue in the joint is affected in the former, it is only focally affected and forms nodules in the latter. The localized form affects small joints, such as hand and feet. The diffused form prefers large joints like knee and hip⁴.

Radiologically, the direct graphy findings in the spinal area are nonspecific. Computer tomography (CT) usually reveals findings of affected bones, such as erosion or destruction, and secondary increased density associated with hemosiderin⁵. Calcification usually does not occur. The best option for diagnostic imaging is MRI, which identifies hemosiderin, hemorrhage and fat contents at secondary mixed signal intensity on lesion T2-weighted images. T1 is typically hypointense. Slight or no contrast imaging may be observed following IVCM⁶. In our case, similar findings were obtained in T1- and T2-weighted images, and no contrast imaging following IVCM.

Another specific characteristic of MRI findings is the continuity of the mass in facet joints. Although the lesion can be diagnosed by MRI, differential diagnosis should consider many lesions that may have similar hypointense properties, such as rheumatoid arthritis, hemophilic arthropathy, synovial osteochondromatosis, fibroma and desmoids tumor, and therefore a histopathologic diagnosis should be made⁷. The principle treatment method is surgical resection, and gross total resection should be

applied⁸. In our case, the mass was completely excised by total laminectomy.

Post-operative recurrence of PVNS varies from 17 to 48%⁹. Therefore, MRI follow-up after surgery is recommended. In our case, there was not a conclusion in terms of recurrence since we did not have a sufficient

long term for follow-up.

Although PVNS typically affects the joints in knees and hips, differential diagnosis should consider other cause of expansile spinal mass affecting posterior vertebral components, particularly when MRI identified signals of hemosiderin.

References

1. Kleinman GM, Dagi TF, Poletti CE: Villonodular synovitis in the spinal canal: case report. *J Neurosurg.* 1980;52:846-848.
2. Akinci O, Akalin Y, İncesu M, Eren A Long-term results of surgical treatment of pigmented villonodular synovitis of the knee. *Acta Orthop Traumatol Turc.* 2011;45(3):149-55
3. Yıldız Y, Altay M, Arıkan M, Ögüt H, Erekuş S, Sağlık Y. Pigmente villonodüler sinovit tedavisinde klinik sonuçlarımız. [Article in Turkish] *Ankara Üniversitesi Tıp Fakültesi Mecmuası* 2001;54:143-8.