

Giant Left Atrial Myxoma Prolapsed To Left Ventricle With Every Cardiac Cyclus Operated With Biatrial Transseptal Incision

Her Kardiyak Siklusta Mitral Kapaktan Prolabe Olan, Biatrilyal Transseptal İnsizyon İle Opere Edilen Dev Sol Atriyal Miksoma

Hakan Saçlı, Alper Erkin, Bilal Perçin, Mehmet Kaan Kırallı

Kalp ve Damar Cerrahi Ana Bilim Dalı, Sakarya Üniversitesi Eğitim ve Araştırma Hastanesi, Sakarya

Özet

Geliş Tarihi: 26.09.2014 Kabul Tarihi: 14.10.2014

İntrakardiyak tümörlerin çoğu benign karakterde olup, en sık gözlenen benign kardiyak tümör miksomadır. Benign karakterde olmasına rağmen tedavi edilmediği süreçte mortalite ve morbiditeye etki edecek komplikasyonlara sebebiyet verebilir. 40 yaşında kadın hasta göğüs hastalıkları polikliniğine sık sık nefes darlığı şikayeti ile başvurdu ve çekilen ekokardiyografide sol atriyum içerisinde mitral kapaktan sol ventrikül içerisine prolabe olan 5x3 cm çapında kitle gözlemlendi. Sol ventrikül sistolik fonksiyonları normal olup, hafif-orta mitral kapak yetmezliği gözlemlendi ve PABs: 75 mmHg olarak ölçüldü. Preoperatif hazırlıklar sonrası hasta operasyona alındı. Kardiyopulmoner bypass'a girilerek, kross klemp konulup cerrahi işleme başlandı. Dubost insizyon kullanılarak kitle eksplore edildi. Kitle interatriyal septuma sapla bağlı olup eksize edildi. Kitle çıkarıldıktan sonra mitral kapak koaptasyonu normal idi ve müdahaleye gerek görülmedi. İnteratriyal septum ve atriotomi perikardiyal yama ile onarıldı. Hastanın yoğun bakım ve servis takip süreci normal olup genel durumu iyi şekilde taburcu edildi. İntrakardiyak kiteller sıklıkla benign karakterde de olsa; emboliye yol açabilmeleri, kapak fonksiyonlarına etki etmeleri, trombus oluşumuna sebebiyet vermeleri nedeniyle tedavi gerektirmektedir. Kitle tamamen rezeke edilmeli ve rekürrensi engellemek için geride kitleye bağlı doku bırakılmamalıdır. Kardiyopulmoner bypass eşliğinde başarılı sonuçlar alınabilmektedir.

Anahtar Kelimeler: Sol atriyal miksoma, Biatrial transseptal insizyon, Dubost insizyonu, Kardiyopulmoner Bypass

Abstract

Received : 26.09.2014 Accepted: 14.10.2014

Primary cardiac tumors are rarely seen. Most of the intracardiac tumors are benign characterised and mainly seen benign cardiac tumor is myxoma. Our patient was 40 years old woman. She is referring with dyspnea complaint to the Chest Diseases clinic for several times. Echocardiography was performed in Cardiology clinic and a giant left atrial mass (myxoma; 5x3 cm diameter) prolapsed to left ventricle through mitral valve with every cardiac cycle was seen. Left ventricle ejection fraction was normal, PABs was 75 mmHg and mild to moderate mitral valve insufficiency was seen. Operation performed with cardiopulmonary bypass and after cross clamping to aorta Dubost's biatrial transseptal incision done. Myxoma was originated from interatrial septum. Myxoma resected and after resection mitral valve assessed; leaflet coaptation and anatomy were normal. Interatrial septum and atrium was repaired with pericardial patch. Intensive care unit and service follow-up of the patient was normal. Postoperative echocardiography has done and PABs decreased to 35mmHg, mitral valve insufficiency has decreased too. Patient was discharged as healthy. Even though intracardiac tumors are benign characterised; these tumors can cause embolisation, thrombus formation and valve incompetence and etc. Successful results can be obtained in the presence of cardiopulmonary bypass and surgeon should be aware of resecting the tumor completely to prevent recurrence.

Keywords: Left atrial myxoma, Biatrial transseptal incision, Dubost's incision, Cardiopulmonary bypass

Introduction

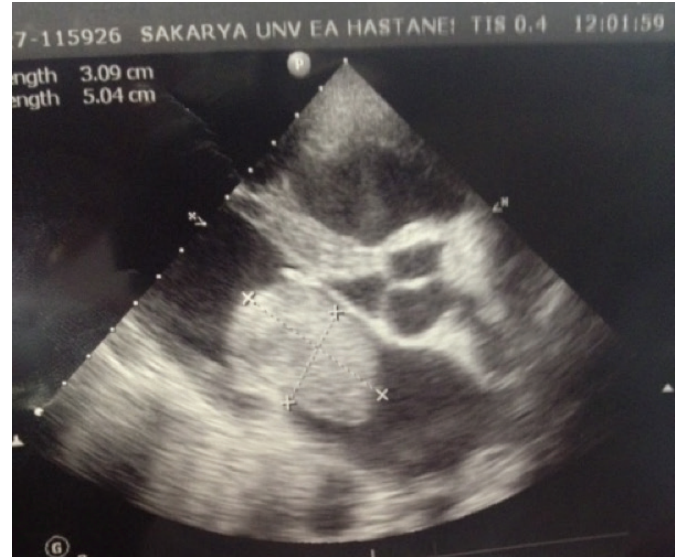Primary cardiac tumors are rarely seen, with a reported incidence of 0,0017 % to 0,19 % (approximately %0,02)^{1,2}. Most of the cardiac tumors are benign characterised (%75) and most of them are myxomas (%40-50)^{3,4}. We want to present a case of giant left atrial myxoma with a symptom of dyspnea.

Case

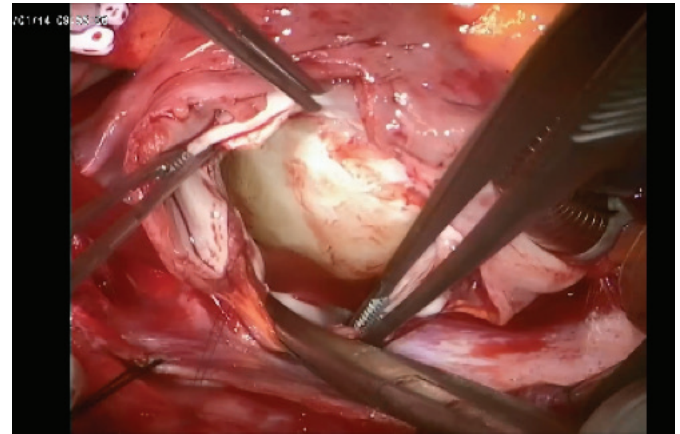
Our patient was 40 years old woman. She was 156 cm height, 65 kg weight and BSA (body surface area) was 1,8 m². She is referring with dyspnea complaint to the Chest Diseases clinic for several times. She was admitted to the emergency room with dyspnea, mild lung edema and pretibial edema at the last time. Echocardiography was performed in Cardiology clinic; and a giant left atrial mass (myxoma; 5x3 cm diameter) prolapsed to left ventricle through mitral valve with every cardiac cycle was seen (Picture 1). Left ventricle ejection fraction was normal, PABs was 75 mmHg and mild to moderate mitral valve insufficiency was seen. Her NYHA class was 3-4 so she followed in intensive care unit before operation. Diuretic medications were given to provide negative fluid balance. After the patient's clinical status improved after medical therapy and preoperative preparations she delivered to the operation. Operation performed with cardiopulmonary bypass and after cross clamping to aorta Dubost's biatrial transseptal incision⁵ done. Myxoma was originated from interatrial septum (Picture 2). Myxoma resected and after resection mitral valve assessed; leaflet coaptation and anatomy were normal (Picture 3 and 4). Interatrial septum and atrium was repaired with pericardial patch. Intensive care unit and service follow-up of the patient was normal. Postoperative echocardiography has done and PABs decreased to 35mmHg, mitral valve insufficiency has decreased too. Patient was discharged and followed as healthy for 6 months.

Discussion

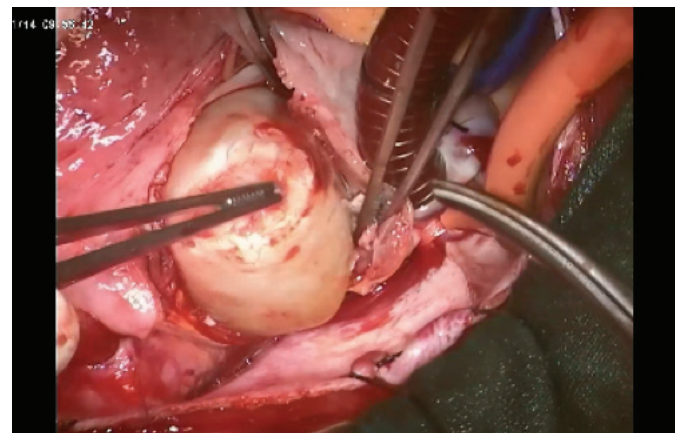
As we know that cardiac tumors are rarely seen most of them are originated from left atrium and rarely from right atrium³. In some cases tumoral mass originate from interatrial septum and ventricle. It is more frequent in females; sometimes can be familial; and the mean age of appearance of myxomas is approximately 50 years^{6,7}.



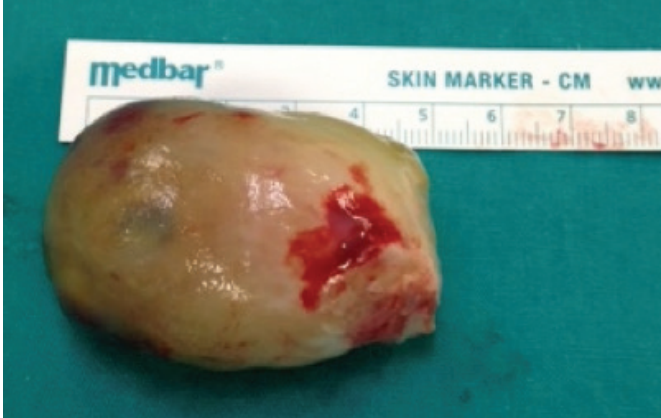Picture 1: Preoperative Echocardiographic image of myxoma prolapsing from mitral valve.



Picture 2: After Biatrial transseptal incision (Dubost's incision) myxoma is seen in left atrium.



Picture 3: Myxoma is taken out from the left atrium.



Picture 4: Myxoma is seen after resection.

Clinical manifestations are presenting in a wide range. It can cause constitutional symptoms such as fatigue, fever, malaise, weight loss, arthralgia, night sweats. But they can cause cardiac symptoms such as arrhythmia, pulmonary hypertension, congestive heart failure, pericardial involvement, chest pain. These symptoms are because of the obstruction in cardiac cavities and valves. Obstruction results from dyspnea, orthopnea to sudden death⁸. Embolization to several focuses can be the first sign of the cardiac tumors; this can be in one third of all patients especially cerebral arteries, visceral, renal and coronary arteries^{1,8}. Because of the mechanical destruction of the mass hemolytic anemia and thrombocytopenia can occur³.

Diagnoses can be made by echocardiography and computed tomography. Physical examination, laboratory findings and chest X ray is helpful for diagnoses and follow up.

Operation has to be done with cardiopulmonary bypass. Approach to the tumoral mass has got several way. Left atriotomy and biatrial approach are the most common two ways to reach the tumoral mass but Dubost's biatrial transseptal incision as we done is not common as the other techniques. Some tumoral mass is derived from the atrial wall beneath to the interatrial septum, and if the tumoral mass is so big as in our case it is more complicated to open classic incisions. So a biatrial transseptal incision is advantageous to manage the cardiac tumors like this situation.

Recurrence of the cardiac tumor is the most important complication after the long follow period of the operation. Recur-

rence rates are between %1 and %3 for sporadic myxomas^{7,8}. A complete resection of the tumor has to be done to avoid such a situation like this.

Conclusion

Even though intracardiac tumors are benign characterised; these tumors can cause embolisation, thrombus formation and valve incompetence and etc. Successful results can be obtained in the presence of cardiopulmonary bypass and surgeon should be aware of resecting the tumor completely to prevent recurrence.

References

1. Reynen K, Cardiac Myxomas. N Engl J Med. 1995; 333: 1610-17
2. Reynen K, Frequency of primary tumors of the heart. The American J Card 1996;77(1):107
3. Silverman NA, Primary Cardiac Tumors. Ann Surg. 1980;191(2): 127-138
4. Rengan R, Thomas Jr. CR, Primary Cardiac Tumors. Encyclopeida of Radiation Oncology 2013; pp 647-649
5. Dubost C, Guilmet D, de Parades B, Pedefferri G, New technic of opening of the left auricle in open-heart surgery: the transseptal bi-auricular approach. Press Med 1966; 74: 1607-1608
6. Gavrielatos G, Letsas KP, Pappas LK, Dedeilias P, Sioras E, Kardaras F. Large left atrial myxoma presented as fever of unknown origin: a challenging diagnosis and a review of the literature. Cardiovasc Pathol. 2007; 6: 365-367
7. Akhtar J, Wasay M, Rauf J, Unusual presentation of more common disease/injury Atrial myxoma: a rare cause of cardioembolic stroke. BMJ Case Reports Sep 7 2012; 1-3
8. Lazaros G, Masoura C, Brili S, Stavropoulos G, Kafiri G, Stefanadis C . Large Left Atrial Myxoma in an Oligosymptomatic Young Woman. Hellenic J Cardiol 2013; 54: 60-63