

## Use of a dynamic axial external fixator combined with internal cross pins for metacarpal fracture treatment in calves

### Research Article

Volume: 4, Issue: 2  
August 2020  
Pages: 43-50

Ziya YURTAL<sup>1\*</sup>, Muhammed Enes ALTUĞ<sup>1</sup>, Mehmet Zeki Yılmaz DEVECİ<sup>1</sup>, Cafer Tayer İŞLER<sup>1</sup>, İbrahim ALAKUŞ<sup>1</sup>

1.Hatay Mustafa Kemal University, Faculty of Veterinary Medicine, Clinical Sciences, Department of Surgery, Box 31040, Hatay, Turkey.

Yurtal Z. ORCID: 0000-0001-6080-1860; Altuğ M.E.: ORCID: 0000-0003-3896-9944; Devci M.Z.Y. ORCID: 0000-0002-9532-247X; İşler C.T. ORCID: 0000-0002-1910-8316; Alakuş İ. ORCID: 0000-0002-2031-7035.

### ABSTRACT

This study aimed to investigate the effectiveness of using dynamic axial external fixator combined with cross pins in the treatment of distal metacarpal fractures in calves. The results of distal metaphyseal metacarpal fractures treated with this method in six calves (four females, two males) were examined. The ages of the patients were  $17.16 \pm 13.22$  and their weight was  $52 \pm 9.48$ . The calves were born by pulling during labor and they could not stand up after birth. The clinical and radiological examinations found a distal metaphyseal metacarpal fracture. Dynamic axial external fixator with cross pin support was applied to all patients in the operative treatment. The patients' foot postures, stepping, walking and running were found to be smooth and adequate in the postoperative examination. Therefore, cross-pin supported dynamic axial external fixation was found to be a strong enough, well-tolerated and easy-to-apply technique which can be used especially in the treatment of open and infected metacarpal fractures.

**Keywords:** calf, cross pin, dynamic axial external fixator, fracture healing

### Article History

Received: 05.05.2020  
Accepted: 29.06.2020  
Available online:  
29.06.2020

DOI: <https://doi.org/10.30704/http-www-jivs-net.732607>

**To cite this article:** Yurtal, Z., Altuğ, M.E., Devci, M.Z.Y., İşler C.T., Alakuş, İ. (2020). Use of a dynamic axial external fixator combined with internal cross pins for metacarpal fracture treatment in calves. *Journal of Istanbul Veterinary Sciences*. 4(2), 43-50, **Abbreviated Title:** *J Ist Vet Sci*

### Introduction

Limb fractures are more common than other fractures (skull, spine, pelvis, sacrum, etc.) in cattles (Akin, 2017). Fractures may occur in the long bones of calves due to traumatic reasons such as incorrect interventions during labor, mother's stepping on the calf, falling or kicking (Gülaydın and Sarierler, 2018). Metacarpal fractures rank first in long bone fractures in calves, and the most common cause is excessive pulling at birth (Belge et al., 2016). Metacarpal and metatarsal fractures

approximately comprise 50% of the fractures in calves (Tulleners, 1986; Auer et al., 1993; Bilgili et al., 2008). Metacarpal fractures are twice the incidence rate of metatarsal fractures, and higher than the total incidence rate of radial and tibial fractures (Ferguson, 1982; Steiner et al., 1993; Bilgili et al., 2008). Metacarpal fractures are most commonly observed in the distal epiphysis and metaphyseal part of the bone in calves, and the Salter - Harris Type I fracture is the most common

\*Corresponding Author: Ziya Yurtal  
E-mail: ziyayurtal@gmail.com , ziyayurtal@mku.edu.tr

<https://dergipark.org.tr/tr/pub/http-www-jivs-net>



fracture type (Belge et al., 2016). The type and localization of the fracture, the state of fracture (open or closed fracture), economic value of the animal, cost of treatment and care conditions during the recovery period are considered when determining the treatment option (Aksoy et al., 2009). The economic status of the patient owner plays a crucial role in consideration of the treatment option as well as the shape and location of the fracture (Oztas and Avki, 2015).

There are conservative and surgical treatment options for long bone fractures in cattles (Belge et al., 2016). Rest and bandage applications are carried out in a restricted area in the conservative treatment (Yanmaz et al., 2014). Plaster is the most commonly used method for simple transverse and mid-diaphyseal bone fractures (Ferguson, 1982; Tulleners, 1986; Bilgili et al., 2008). Additionally, treatment of closed fractures is often performed using bandage techniques combined with Thomas split or bandage, as well as bandaging techniques supported by certain materials such as polyvinylchloride (PVC) and aluminum (Auer et al., 1993; Nuss et al., 2011; Arican et al., 2014). Internal and external fixation methods are used for surgical treatment (Yanmaz et al., 2014). Internal fixation methods are recommended for the dislocated, multifragmental or complicated fractures. Techniques such as intramedullary nailing, cerclage, screw, dynamic compression plate (DCP), interlocking pins are applied for internal fixation (Arican et al., 2014). The main purpose of external fixation is to maintain normal joint mobility and return the patient to normal life as soon as possible without losing weight after surgery (Anderson and Jean, 1996). This fixation method can be especially useful in multifragmented, open and infected fractures (Singh et al., 2007). Materials and tools such as transfixation pinning and bandages, dynamic axial external fixator and circular external fixator are used for external fixation methods (Singh et al., 2007; Bilgili et al., 2008).

Internal (cross pin) and external fixation (dynamic axial external fixator) methods were used in combination for the surgical treatment of metacarpal fractures in six calves and the effectiveness and long-term results of this

treatment were evaluated in this study.

## Materials and Methods

The study material consisted of six calves brought to Hatay Mustafa Kemal University Veterinary Health, Practice and Research Hospital and diagnosed with distal metaphyseal metacarpal fracture. Demographic data on calves are presented in Table 1. The reason for the fractures was found to be the irregular extraction force applied in difficult labor conditions. The results of distal metaphyseal metacarpal fractures treated with this method in six calves (four females and two males) were examined. The ages of the patients were  $17.16 \pm 13.22$  and their weight was  $52 \pm 9.48$ . Two of our cases were open fractures and four of them were closed fractures. The patient owners were informed about anesthesia and surgical complications. Consent was obtained from all patient owners. Then, the routine procedures mentioned below were applied to the cases.

**Anesthesia:** 0.1 mg / kg dose xylazine (Alfazyne % 2; Egevet, Turkey) and 5 mg / kg ketamine (Alfamine %10; Egevet, , Turkey) was allowed to be given as anesthesia induction. Following intubation, 100% oxygen was administered and anesthesia was maintained with a concentration of 1-3% sevoflurane (Sevorane; Aesica Queenborough Ltd, UK).

**Preoperative preparation and planning:** Anterioposterior and mediolateral radiographs of the broken limb were taken after the affected extremities and surrounding tissues were carefully examined. The dynamic axial fixator to be applied according to the shape and length of the bone fracture (TIPS, Turkey) size was determined by radiography.

**Surgical method:** Operative procedures in all of our patients started with a horizontal incision over the fracture line (Figure 1. A). Fragments of the fracture were reduced and internal fixation was achieved by cross-nailing after reaching the broken bone (Figure 1B-C). Following this, the incision line was closed using no.1 absorbable suture material (Ethicon, Johnson&Johnson, Belgium) (Figure 1D). Six threaded pins (3 mm and 4 mm in diameter) were inserted into the proximal and distal of the fracture line and fixed

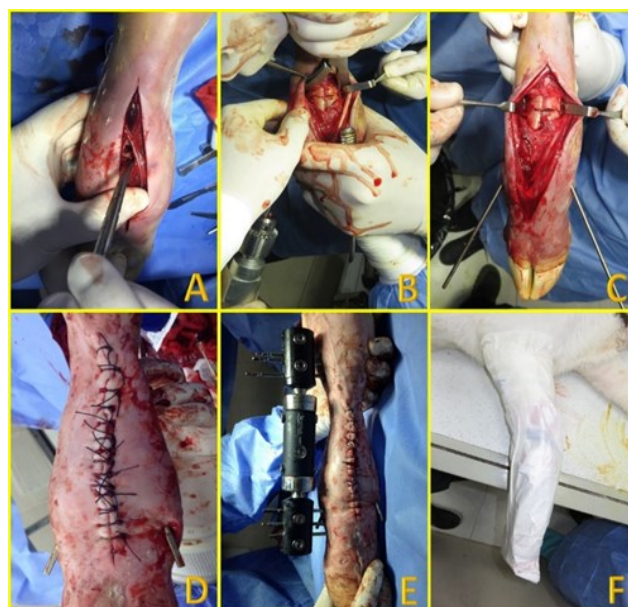
**Table 1.** Demographic data and clinical findings in calves

Case number	Age / Weight	Sex	Breed	R/L	Open / Closed	Bone/ Localization / Shape	Cause	Complications	Result
1	1 d/40 kg	F	Holstein	R	Closed	Bone : Metacarpus Location: Distal metaphyseal Shape: Transverse	During birth	Pin tract infection and soft tissue inflammation	Excellent
2	20 d/52 kg	M	Belgian blue	R	Closed	Bone : Metacarpus Location: Distal metaphyseal Shape: Transverse	During birth	Pin tract infection and soft tissue inflammation	Excellent
3	30 d/61 kg	F	Holstein-Simmental hybrid	R	Open	Bone : Metacarpus Location: Distal metaphyseal Shape: Transverse	During birth	The bone was broken again as a result of trauma. Pin tract infection and soft tissue inflammation	Moderate
4	1 d/42 kg	F	Holstein	L	Closed	Bone : Metacarpus Location: Distal metaphyseal Shape: Transverse	During birth	2 pins sent to the proximal fragment were broken. Pin tract infection and soft tissue inflammation	Excellent
5	21d/54 kg	F	Simmental	L	Open	Bone : Metacarpus Location: Distal metaphyseal Shape: Fragmented	During birth	Anesthesia intolerance	Dead (Post-op 1st day)
6	30 d/63 kg	M	Simmental	L	Closed	Bone : Metacarpus Location: Distal metaphyseal Shape: Transverse	During birth	Anesthesia intolerance	Dead (Post-op 1st day)

R: right, L: left, d: days, M: Male, F: Female

on the dynamic axial external fixator in the external fixation processes except in that of case three (Figure 1E). Proximal pins were placed in the metaphysis and distal pins in the first phalanx due to the lack of sufficient bone tissue in the distal fragment in all cases. Similar to the other cases, only the third patient was applied two threaded pins to the proximal of the fracture line and three threaded pins to the first phalanx. Since the structure of this patient was smaller than other cases, there was enough space to place two threaded pins in the proximal fragment.

**Postoperative maintenance:** After the fixation was completed, the radiographs were taken for the check of fixation. Antibiotics containing benzyl penicillin and dihydrostreptomycin (intramuscular 5.7 mg benzyl penicillin and 10 mg dihydrostreptomycin / kg / day, Reptopen, Ceva, Turkey) were postoperatively used. Additionally, 10% povidin iodine was used for 14 days for pin tract care, rifamycin (Rif ampul 250 mg; Koçak- Pharma, Turkey), and flunixin meglumine (2.2 mg/kg) (Fulimed, Alke, Turkey)



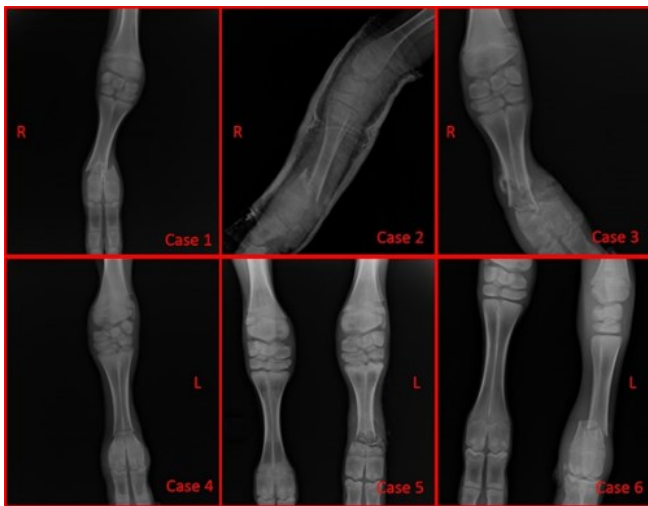
**Figure 1.** A: Horizontal incision above the fracture line (Case 6), B–C: Reduction of the broken line with a cross pin (Case 4), D: Closing the incision line with sutures (Case 2) E: Dynamic axial fixator application (Case 2) F: Covering a breathable perforated sack over the bandage (Case 3).

for analgesia and anti-inflammatory activity. Patient owners were informed about possible postoperative complications and pin tract care. A protective bandage was applied to patients

and a perforated sack was attached to this bandage to keep the operation area cleaner (Figure 1F). The affected limb was evaluated at short intervals for edema, swelling, color change, pain, increase in temperature and loss of function. Calves were called for routine postoperative controls with two weeks intervals and callus formation was followed by radiography. During the removal of the external fixators, the screws were loosened and the external fixators and pins were removed on the 78th day. The holes where the pins came out were cleaned with antiseptic solution. Bandages were not applied again. The activities of the animals were restricted for two weeks.

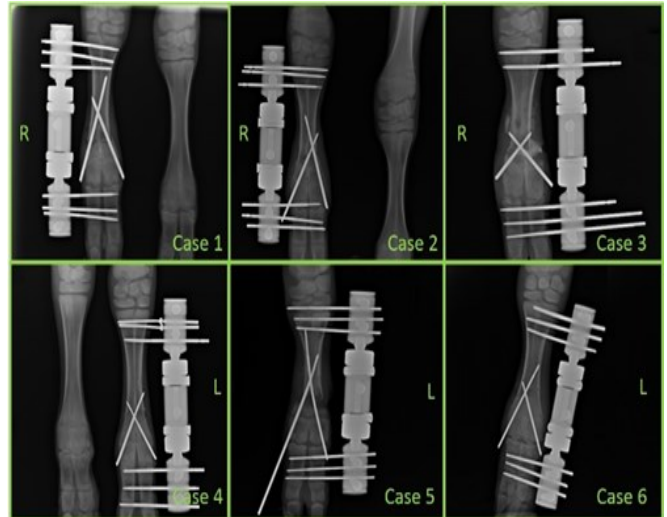
## Results

The clinical information of the calves used in the study are shown in Table 1. According to the anamnesis information received from animal owners, the fractures were formed as a result of excessive force application during delivery. Distal metaphyseal metacarpus fracture was detected in the clinical and radiographic examination (Figure 2).



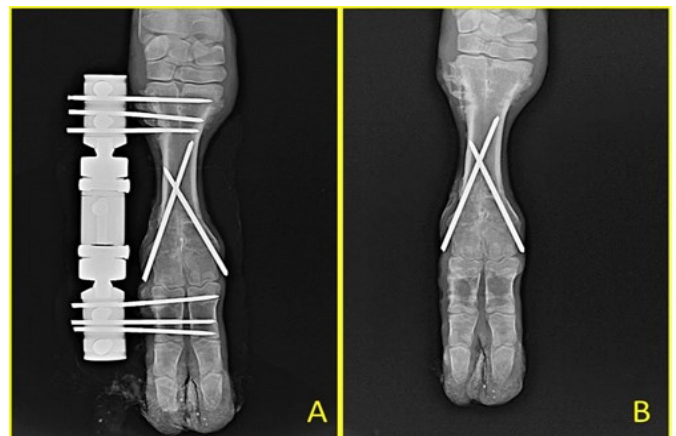
**Figure 2.** Preoperative radiography images of cases.

Dynamic axial external fixator with cross pin support was used in all cases. Closed fractures did not have infections while the open fractures were infected. Based on the control radiographs taken postoperatively, the fractures reduced (Figure 3). The first case was initially applied a synthetic plaster bandage. Upon this, the procedure of operation was determined and the operation was performed in accordance with the procedure



**Figure 3.** Postoperative radiography images of cases

described above. However, the foot swell and limped. It was prescribed both ceftriaxone (30 mg / kg / day, two times a day intramuscularly, Unacefin; Yavuz Medicine, Turkey) and flunixin meglumine (2.2 mg / kg, Fulimed, Alke, Turkey) systemically and 10% povidone iodine and rifamycin locally. According to the radiograph taken at the third month of follow-up, the healing between fractures was sufficient; so, the external fixator was removed (Figure 4).

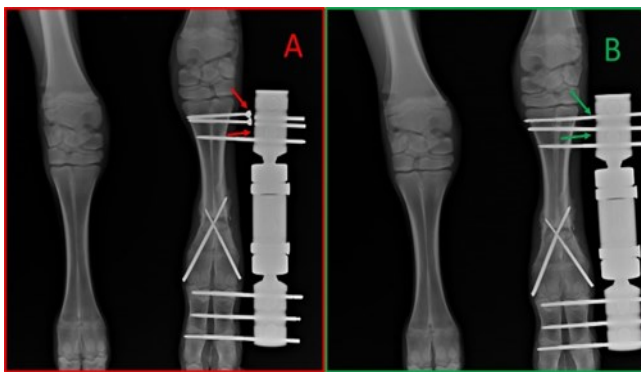


**Figure 4.** A: Radiographic view before dynamic axial external fixator removal (case 1) B: Radiographic view after dynamic axial external fixator removal (case 1)

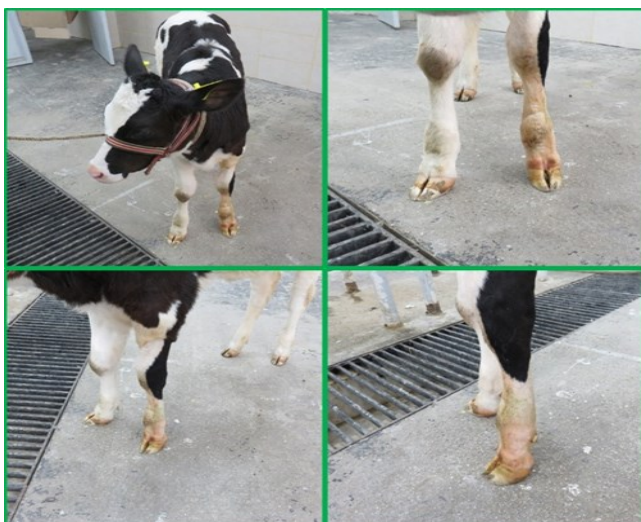The patient's sixth month postoperative control revealed that there was no difficulty in pressing his foot and he used his foot very well. Another physician applied bandage to the second case. The information obtained from the anamnesis revealed that the second case had his foot bandaged. The radiography found distal metacarpal fracture and there was no improvement in the broken bone. The operation



was carried out with the same procedure. The case was completely recovered in the postoperative fourth month follow-up. The third case was infected and open fractured. Infection was controlled using rivanol bandage. Then, a cross pin was inserted internally and a dynamic axial external fixator was attached externally in accordance with the operation procedure. It was supported by medical treatment against the risk of infection. This case had a broken the bone at the same location as a result of the pressure on the door of the external fixator applied to the limb on the 56th postoperative day. Following the control, the patient was referred to be cut at the request of the patient owner. In the fourth case, two of the pins sent to the proximal fragment of the fracture were broken at the third week postoperative control (Figure 5A). Fixation was achieved by sending new ones instead of the broken pins (Figure 5B).



**Figure 5.** A: The postoperative 3rd week control revealed that 2 of the pins sent to the proximal fragment of the fracture were broken B: Fixation was achieved by sending a new one in place of the broken pins (case 4).



**Figure 6.** Photographs taken from different angles in the third month postoperative control (case 4).

The patient used his foot very well in the third month postoperative control (Figure 6). The most important postoperative finding was pin tract infection and the lameness related to it. These clinical symptoms were overcome with medical treatment.

## Discussion

Based on our clinical experience, when carpal fractures are not treated in calves, they mostly result in death due to infection or cutting without commercial carcass value. Under market conditions, considering that a 20 days old calf is sold at around 500-600 \$ it causes significant economic loss for the enterprise if proper treatment is not performed. Various treatment techniques for metacarpal fractures in calves are applied (Akin, 2017). Although bandage applications are generally preferred in fractures for some ruminants due to economic reasons, as it was also observed in our study, it is accepted as an imperative to treat metacarpus fractures and to treat the fracture with external and internal methods (Denny et al., 1988; Anderson and Jean, 1996). In our study, two metacarpus fractures were bandaged by some private veterinary clinics before admission to our hospital; however, the callus was not shaped and one turned into an open fracture (Figure. 2, second case). We achieved improvement by applying dynamic axial external fixator in both cases. We have considered the application of dynamic axial external fixator in calves to be a suitable and successful technique in clinical practice for the distal metaphyseal metacarpal fractures that cannot be stabilized by bandages.

External fixators are commonly used in angular deformity treatments and bone lengthening surgeries in cats and dogs (Thommasini and Betts, 1991; Marcellin-Little et al., 1998; Stallings et al., 1998). Internal fixation technique can be used in the treatment of all closed or open metaphyseal, diaphysis and especially epiphysis fractures and external fixation in closed fractures that cannot be stabilized with traction and bandages, periarticular fractures extending to the diaphysis, and long bone fractures (Gülaydin et al., 2019). The present study found the use of external

fixator was found to be very important in calves, especially in the treatment of distal extremity fractures.

Podolski and Chao reported that the thickness of the pin diameter increased in line with the rigidity of the external fixator (Podolski and Chao, 1993). Circular external fixators are most frequently used in humans with polyaxial and 1.5-2 mm diameter pins (Kummer, 1992) and 1-1.6 mm pins in cats and dogs (Ferretti, 1991; Aithal et al., 2007). The fixators used in current study were the dynamic axial external fixator and it is monoaxial. Therefore, thicker pins were preferred to provide sufficient durability. Edgerton et al. reported that the thickness of the pins selected should not exceed 20% of the affected bone diameter in general to not decrease bone strength (Edgerton et al., 1990). The pin diameters selected in our study were 10% of the affected bone diameter.

The pins must be fixed to the external fixator system from two points at least while fixing fracture fragments in external fixator applications (Cakmak and Bilen, 1999; Gülaydin et al., 2019). The weakest part of using circular external fixators is that the pin diameters are small (Bianchi-Maiocchi, 1994; Aithal et al., 2004). We used three pins for each of the proximal and distal parts of the fracture line in five patients in our study. We applied two pins on the proximal line and three pins on the distal line in one of our cases. The application and diameter of the pin may vary according to the case and proper diameter and number of pins that provide sufficient fixation should be used.

Anderson and St Jean reported that implant failures such as clamp or sidebar malfunctions, pin bending or pin breakage may occur in circular external fixators and limit the use of external fixators in large animals (Anderson and Jean, 1996). We used dynamic axial external fixators in our study to prevent these reported adverse conditions. The use of clamps, nuts or rods used in this technique for circular external fixators was considered to be advantageous while pin breakage was considered to be caused by the owner's irresponsibility. However, the fixation of the fracture could be impaired if the external fixator was not supported with cross pins.

Aithal et al. stated that the animals placed a load

on their feet immediately after the surgery since their fixation in the circular external fixator was stiff enough (Aithal et al., 2004). In our study, animals were able to put a load on their feet immediately after the surgery, therefore; the use of dynamic axial external fixators is sufficient for fixation.

Pin tract infections and lameness were reported as complications in circular external fixator applications (Aithal et al., 2004; Aithal et al., 2007; Gülaydin et al., 2019;). In our study, pin tract infection and lameness occurred in four cases due to this infection, in line with the literature. Singh et al. reported that pin path infections decrease gradually by regularly washing them with sterile saline solution containing ciprofloxacin (Singh et al., 2007). In our study, this complication was eliminated by using local 10% povidone iodine solution, local injection of rifamycin and systematic administration of third generation cephalosporin and flunixin meglumine.

Heo et al. emphasized that complications such as pin migration and poor strength of the transcortical pins are common in newborn calves due to the low density of bones and thin cortexes (Heo et al., 2012). As threaded pins were used in the transcortical pinning process, no complication such as pin migration was encountered in our study.

## Conclusions

Dynamic axial external fixation technique can be used as it is easy to apply and well tolerated by patients. This was considered to be an important advantage especially in the treatment of open and infected metacarpus fractures near the joint. Consequently, dynamic axial external fixation combined with cross pin was a successful technique in fixation and treatment of distal extremity fractures in calves.

## Acknowledgement

The authors would like to thank Halil ALAKUŞ and Ömer KIRGIZ (Hatay Mustafa Kemal University, Faculty of Veterinary Medicine, Department of Surgery) for their support in the clinical work of the study.

## Conflicts of interest

The authors declared that there are no conflicts of interest.

## References

- Aithal, H. P., Singh, G. R., Hoque, M., Maiti, S. K., Kinjavdekar, P., Pawde, A. M., & Setia, H. C. (2004). The use of a circular external skeletal fixation device for the management of long bone osteotomies in large ruminants: an experimental study. *Journal of Veterinary Medicine Series A*. 51, 284-293.
- Aithal, H. P., Kinjavdekar, P., Pawde, A. M., Singh, G. R., Hoque, M., Maiti, S. K., & Setia, H. C. (2007). Management of fractures near the carpal joint of two calves by transarticular fixation with a circular external fixator. *The Veterinary Record*. 161, 193-198.
- Akın, I. (2017). Calf metacarpal fractures in association with bovine dystocia: Case series among calves. *Atatürk University Journal Of Veterinary Sciences*. 12, 235-241.
- Aksoy, O., Ozaydin, I., Kilic, E., Ozturk, S., Gungor, E., Kurt, B., & Oral, H. (2009). Evaluation of fractures in calves due to forced extraction during dystocia: 27 cases (2003-2008). *Kafkas Üniversitesi Veteriner Fakültesi Dergisi*. 15, 339-344.
- Anderson, D. E., & Jean, G. S. (1996). External skeletal fixation in ruminants. *Veterinary Clinics of North America: Food Animal Practice*. 12, 117-152.
- Arıcan, M., Erol, H., Esin E., & Parlak, K. (2014). A retrospective study of fractures in neonatal calves: 181 cases (2002-2012). *Pakistan Veterinary Journal*. 34, 247-250.
- Auer, J. A., Steiner, A., Iselin, U., & Lischer, C. (1993). Internal fixation of long bone fractures in farm animals. *Veterinary and Comparative Orthopaedics and Traumatology*. 6, 36-41.
- Belge, A., Akın, I., Gulaydin, A., & Yazıcı, M. F. (2016). The treatment of distal metacarpus fracture with locking compression plate in calves. *Turkish Journal of Veterinary and Animal Sciences*. 40, 234-242.
- Bianchi-Maiocchi, A (1994). The Ilizarov compression-distraction apparatus. In A. Bianchi-Maiocchi (Ed). *Advances in Ilizarov Apparatus Assembly*. (pp. 5-14). Milan Italy: Medicalplastic.
- Bilgili, H., Kurum, B., & Captug, O. (2008). Use of a circular external skeletal fixator to treat comminuted metacarpal and tibial fractures in six calves. *The Veterinary Record*. 163, 683-687.
- Çakmak, M., & Bilen, F. E. (1999). Çerçeve kurma teknikleri. In M. Çakmak, M. Kocaoglu (Ed). *İlizarov Cerrahisi ve Prensipleri*. (pp. 99-105). İstanbul, Turkey: Nobel Tıp Kitabevi.
- Denny, H. R., Sridhar, B., Weaver, B. M., & Waterman, A. (1988). The management of bovine fractures: a review of 59 cases. *The Veterinary Record*. 123, 289-295.
- Edgerton, B. C., An, K. N., & Morrey, B. F. (1990). Torsional strength reduction due to cortical defects in bone. *Journal of Orthopaedic Research*. 8, 851-855.
- Ferguson, J. G. (1982). Management and repair of bovine fractures. *Compendium on Continuing Education for the Practising Veterinarian*. 4, 128-36.
- Ferretti, A (1991). The application of the Ilizarov technique to veterinary medicine. In J. Aronson (Ed). *Operative Principles of Ilizarov*. (pp. 551-570). Philadelphia, US: Williams & Wilkins.
- Gulaydin, A., & Sarierler, M. (2018). Treatment of Long Bone Fractures in Calves with Ilizarov External Fixator. *Veterinary and Comparative Orthopaedics and Traumatology*. 31, 364-372.
- Gulaydin, A., Sarierler, & Bozkan, M. Z. (2019). Treatment of Proximal Tibial Fracture of a Calf by Using Linear External Fixator. *Turkish Journal of Veterinary Research*. 3, 73-79.
- Heo, S. Y., Kim, E. J., Kim, M. S., Lee, K. C., Kim, N. S., & Lee, H. B. (2012). Use of Cross Pins and Temporal External Skeletal Fixator for Stabilization of a Tibial Physeal Fracture in a Korean Native Calf. *Journal of Veterinary Clinics*. 29, 198-201.
- Kummer, F. J. (1992). Biomechanics of the Ilizarov external fixator. *Clinical orthopaedics and related research*. 280, 11-14.
- Marcellin-Little, D. J., Ferretti, A., Roe, S. C., & Deyoung, D. J. (1998). Hinged Ilizarov external fixation for correction of antebrachial deformities. *Veterinary Surgery*. 27, 231-245.
- Nuss, K., Spiess, A., Feist, M., & Kostlin, R. (2011). Treatment of long bone fractures in 125 newborn calves. A retrospective study. *Tierarztl Praxis Ausgabe G Grosstiere Nutztiere*. 39, 15-26.
- Oztaş, E., & Avki, S. (2015). Evaluation of Acrylic Pin External Fixation (APEF) System in Metacarpal Fractures of Newborn Calves: Cheap But Effective? *Kafkas Üniversitesi Veteriner Fakültesi Dergisi*. 21, 433-436.

- Podolsky, A., & Chao, E. Y. (1993). Mechanical performance of Ilizarov circular external fixators in comparison with other external fixators. *Clinical orthopaedics and related research*. 293, 61-70.
- Singh, G. R., Aithal, H. P., Amarpal, M., Kinjavdekar, P., Maiti, S. K., Hoque, M., Pawde, A. M., & Joshi, H. C. (2007). Evaluation of two dynamic axial fixators for large ruminants. *Veterinary Surgery*. 36, 88-97.
- Stallings, J. T., Lewis, D. D., Welch, R. D., Samchukov, M., & Marcellin-Little, D. J. (1998). An introduction to distraction osteogenesis and the principles of the Ilizarov method. *Veterinary and Comparative Orthopaedics and Traumatology*. 11, 59-67.
- Steiner, A., Iselin, U., Auer, J. A., & Lischer, C. J. (1993). Physeal fractures of the metacarpus and metatarsus in cattle. *Veterinary and Comparative Orthopaedics and Traumatology*, 6, 131-137.
- Thommasini, M. D., & Betts, C. W. (1991). Use of the "Ilizarov" external fixator in a dog. *Veterinary and Comparative Orthopaedics and Traumatology*, 4, 70-76.
- Tulleners, E. P. (1986). Metacarpal and metatarsal fractures in dairy cattle: 33 cases (1979-1985). *Journal of the American Veterinary Medical Association*. 189, 463-468.
- Yanmaz, L. E., Mahir, K. A. Y. A., Doğan, E., & Okumuş, Z. (2014). Sığır ve buzağılardaki kırık olgularının değerlendirilmesi. *Yüzüncü Yıl Üniversitesi Veteriner Fakültesi Dergisi*, 25, 23-26.