

N. Radialis ve N. Musculocutaneus Tarafından İnnerve Edilen M. Brachioradialis A Case Report: Dual Innervations of the Brachioradialis Muscle

Murat Diramalı, Rengin Kosif

Abant İzzet Baysal Üniversitesi, Anatomi Anabilim Dalı, Bolu



Özet

Bu çalışmada, sol üst ekstremitesinde n. radialis ve n. musculocutaneus tarafından innerve edilen m. brachioradialis'e sahip erkek kadavra ile ilgili bir varyasyon sunulmaktadır. N. radialis m. triceps brachii'ye muskuler dallarını verdikten sonra m. brachioradialis'i besliyor ve yüzeysel ve derin dallarına ayrılarak seyrine devam ediyordu. N. musculocutaneus ise fossa cubiti'de n. cutaneus antebrachii olarak sonlanmadan önce m. brachioradialis'e giren iki dal veriyordu. Üst ekstremiteye ait ameliyatlarda cerrahların bu ve benzeri varyasyonları göz önünde bulundurmalarının önemi olacağını düşünüyoruz.

Anahtar Kelimeler: Musculus brachioradialis, çift innervasyon, nervus radialis, nervus musculocutaneus, varyasyon

Abstract

In this subject, we present a variation of the brachioradialis muscle with two innervations on the left side in a male cadaver. After giving its muscular branches to triceps brachii muscle, radial nerve was innervating brachioradialis muscle and after that bifurcating to superficial and deep branches as its routine course. Musculocutaneous nerve was giving two branches to brachioradialis muscle in cubital fossa before ending as lateral cutaneous nerve of forearm. It is important to know the variations of the brachial plexus in surgery of upper extremity and can be used in explaining unusual clinical symptoms.

Keywords: Brachioradialis muscle, dual innervations, radial nerve, musculocutaneous nerve, variation

INTRODUCTION

The brachial plexus is formed by the union of the lower four cervical nerves and the first thoracic nerve. Brachial plexus innervates the upper limb and extrinsic back muscles [1, 2]. The musculocutaneus nerve is the continuation of lateral cord of the brachial plexus; it penetrates coracobrachialis muscle, innervates all of the three muscles in anterior aspect of the arm and ends as the lateral cutaneous nerve of the forearm (1, 2, 3). The radial nerve, which is the both sensory and muscular nerve of the backside of the arm and forearm, originates from the posterior cord of the brachial plexus. After supplying triceps brachii muscle, it passes between two heads of the supinator muscle, gives muscular branches to brachioradialis muscle with extensor muscles of the forearm and ends by innervating the back side of the hand (1, 4).

Variations of the formations of the brachial plexus and its branches are common and they are reported in the studies since 19th century

(2, 4). Peripheral nerve variations must be known by orthopedists, neurologists, physiotherapists and radiologists in both diagnosis and treatment [4]. An anterior surgical approach to the distal humerus can be done by longitudinally bisecting the brachialis muscle or by splitting the muscle mass between the brachialis and brachioradialis muscles (5). In the latter approach, an unknown variation may put the radial branch to the brachioradialis muscle at risk.

Despite being supplied by an 'extensor' nerve: Radial nerve; brachioradialis is a flexor of the elbow and forms the lateral border of the cubital fossa. The muscle fibres arise from the proximal two-thirds of the lateral supracondylar ridge of the humerus and end in a flat tendon which inserts on the lateral side of the distal end of the radius (1). The brachioradialis is often used as a donor muscle in tendon-transfer operations to restore hand functions and special efforts should be made to avoid cutting or injuring the nerve branches (6).

CASE REPORT

During routine anatomy dissections in a 55 year old male cadaver, in his upper extremity brachioradialis muscle was seen to be different on the left. Brachioradialis muscle was innervated by both musculocutaneuos and radial nerves. Radial nerve, 33.67 mm below from the upper arising point of muscle fibres gave two branches to brachioradialis muscle. The linear distance between the points of origin of the two branches was 12, 52 mm. The length of the first branch was 23.10 mm while the latter was 29.68 mm. There was no variation in its course in forearm and arm. Also, at the same side of the cadaver, musculocutaneuos nerve, 18.63 mm distal to the origin of the lateral cutaneous nerve of the forearm and 105.25 mm below from the upper arising point of the brachioradialis muscle, gave two branches to brachioradialis muscle. The length of the first branch was 23.10 mm while the latter was 29.88 mm. On the right side of the cadaver, only radial nerve was innervating the brachioradialis muscle (Figure 1). In the same cadaver, on the right side there was a variation that we reported before about a communicating branch between musculocutaneous nerve and median nerve (2).

DISCUSSION

Variation of the brachial plexus and its terminal branches are common in the population, in the literature incidence of these variations are reported between % 13-65.3 [3, 7]. Most of these variations are seen in musculocutaneous nerve, median nerve and their distributions; a communicating branch to median nerve originating from musculocutaneous nerve and innervation of coracobrachialis by musculocutaneous nerve without penetrating it [2, 8]. Innervation of coracobrachialis by musculocutaneous nerve without (9).

Shylaja and Dakshayani observed in right upper limb of a male cadaver that muscular branch to

coracobrachialis muscle emerged from lateral cord and musculocutaneous nerve didn't pierce the muscle. Also they reported that nerve was lying medial to the brachial artery in upper third of arm (9).

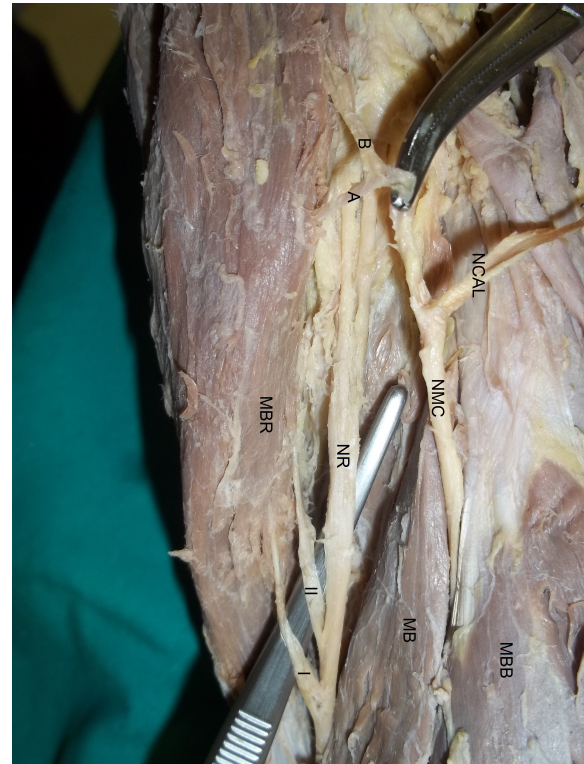


Figure 1. MBB: Biceps brachii muscle, MB: Brachialis muscle, MBR: Brachioradialis muscle, NMC: Musculocutaneous nerve, A&B: Muscular branches to brachioradialis muscle from musculocutaneous nerve, NR: Radial nerve, I&II: Muscular branches to brachioradialis muscle from radial nerve, NCAL: Lateral cutaneous nerve of forearm

Prasada Rao and Chaudhary observed two musculocutaneous nerve out of 24 cadavers. In one these cadavers nerve to coracobrachialis muscle was originating from lateral cord and in both cadavers median nerve gave muscular and sensory branches instead of musculocutaneous nerve (10).

Yogesh observed in a routine cadaver dissection that a branch of median nerve represented musculocutaneous nerve, didn't pierce coracobrachialis muscle, innervated all of the three muscles in the anterior aspect of arm and continued its course as lateral cutaneous nerve in forearm (11).

There are a few studies on variations between musculocutaneous nerve and radial nerve in the literature. Yogesh reported a unilateral variation of the radial and musculocutaneous nerves on the left side in a male cadaver. Although radial nerve was supplying triceps brachii muscle and giving its sensory branches in arm, it ended without going any further. Musculocutaneous gave muscular branches to anterior side of arm, lateral cutaneous nerve to forearm as usual and supplied the brachioradialis, extensor carpi radialis longus and extensor carpi radialis brevis muscles (4).

In our case, different from Yogesh brachioradialis muscle was innervating by two nerves musculocutaneous and radial nerves. In the literature, we couldn't find any variation same as our cadaver (4).

Knowledge of variations of the brachial plexus and its branches are important in diagnosis of unusual clinical symptoms and surgical treatments to prevent unwanted nerve injuries in procedures such as utilization of brachioradialis muscle in tendon-transfer operations, reconstructive surgery of elbow joint, shoulder arthroscopy and management of traumatology of the upper limb.

ACKNOWLEDGMENTS

This case report was presented as a poster presentation in 15th National Anatomy Congress at Samsun.

CONFLICT OF INTEREST

There is no actual or potential conflict of interest in relation to this article.

REFERENCES

1. David Johnson: Pectoral Girdle and Upper Limb, In: Susan Standring (Ed.): Gray's Anatomy: The Anatomical Basis of Clinical Practice. 40th edition, Elsevier Ltd, Spain 2008: 775-906.
2. Sevinc O et al. Variation in the formation of the median nerve involving a communicating branch from the musculocutaneous nerve. Case Rep Clin Pract Rev 2007; 8: 143-146.

3. Fregnan, JHT et al. Absence of the musculocutaneous nerve: a rare anatomical variation with possible clinical-surgical implications. Sao Paulo Med J 2008; 126(5): 1-3.
4. Yogesh et al. Musculocutaneous nerve substituting for the distal part of radial nerve: a case report and its embryological basis. J Neuro Sci Rural Pract 2011; 2(1): 74-76.
5. Mahakkanukrauh P and Somsarp V. Dual innervation of the brachialis muscle. Clinical Anatomy 2002; 15:206-209
6. Fridén J et al. Biomechanical analysis of the brachioradialis as a donor in tendon transfer. Clin Orthop Relat Res 2001; 383: 152-161.
7. Jamuna M and Amudha G. A cadaveric study on the anatomic variations of the musculocutaneous nerve in the infraclavicular part of the brachial plexus. Journal of Clinical and Diagnostic Research November (Suppl-1), 2011; Vol-5 (6): 1144-1147.
8. Guerri-Guttenberg RA and Ingolotti M. Classifying musculocutaneous nerve variations. Clinical Anatomy 2009; 22: 671-683.
9. Shylaja DK and Dakshayani KR. Unilateral variation in the origin and course of musculocutaneous nerve. Anatomica Karnataka 2013; Vol-7, (1): 38-40.
10. Prasada Rao PV and Chaudhary SC. Absence of musculocutaneous nerve: two case reports. Clinical Anatomy 2001; 14: 31-35.
11. Yogesh et al. Unilateral variant origin of musculocutaneous nerve. International Journal Of Anatomical Variations 2010; 3: 59-60.