

Elaphostrongylus cervi (Cameron, 1931) in Red deer (*Cervus elaphus*): First Record in Turkey

Kürşat KARTAL¹, Mustafa ESER^{2*}, Hakan GÜZEL³

¹Gazî Mustafa Kemal Anatolian High School, Biology Teacher, TR-26470 Eskişehir, Turkey

²Anadolu University Open Education Faculty Health Programs, Yunusemre Campus, TR-26470 Eskişehir, Turkey

³Dinar Directorate of Provincial Agriculture And Forestry, Dinar/Afyonkarahisar, Turkey

ABSTRACT

This study was carried out to determine the presence of *Elaphostrongylus cervi* infection found in Red deer at Eskişehir Çatacık Red Deer Production Station between June-July 2020. Based on the red deer traces and signs in the study area, 32 fresh faeces of animals were collected from the places where the faeces density was found. Stool samples were examined for cestode rings macroscopically, and microscopically by sedimentation, saturated salt flotation, and Baermann Wetzel methods. Larvae were found in all the collected faeces. The larvae obtained by the Baerman technique were identified at the species level using the relevant literature. *E. cervi* identified in red deer with this study is the first record in our country. Thus, it will provide valuable data for the red deer in Turkey

Keywords: *Elaphostrongylus cervi*, Red deer, First record, Eskişehir

Kızıl geyiklerde (*Cervus elaphus*) *Elaphostrongylus cervi* (Cameron, 1931): Türkiye’de İlk Kayıt

ÖZ

Bu çalışma Haziran-Temmuz 2020 tarihleri arasında Eskişehir Çatacık Kızıl Geyik Üretim İstasyonu’ndaki Kızıl geyiklerde bulunan *Elaphostrongylus cervi* enfeksiyonunun varlığını belirlemek amacıyla yapılmıştır. Çalışma alanında bulunan Kızıl geyik iz ve belirtilerinden hareket edilerek dışkı yoğunluğunun bulunduğu yerlerden hayvanlara ait 32 taze dışkı toplanmıştır. Dışkı örnekleri cestod halkaları yönünden makroskobik olarak, sedimentasyon, doymuş tuzlu su flotasyon ve Baermann Wetzel yöntemleri ile mikroskobik olarak incelenmiştir. Toplanan dışkıların hepsinde larvalara rastlanmıştır. Baerman tekniği ile elde edilen larvalar ilgili literatürlerden faydalanılarak tür düzeyinde teşhis edilmiştir. Yürütülen bu çalışmayla Kızıl geyiklerde teşhis edilen *E. cervi* ülkemizde ilk kayıttır. Bu sebeple Türkiye’de Kızıl Geyikler için değerli bir veri oluşturacaktır.

Anahtar Kelimeler: *Elaphostrongylus cervi*, Kızıl geyik, İlk kayıt, Eskişehir

To cite this article: Kartal K, Eser M, Güzel H. *Elaphostrongylus cervi* (Cameron, 1931) in Red deer (*Cervus elaphus*): First Record in Turkey. Kocatepe Vet J. (2020) 13(4):433-438

Submission: 12.08.2020

Accepted: 30.09.2020

Published Online: 10.11.2020

ORCID ID; KK: 0000-0002-0803-2635, ME: 0000-0003-1542-2989, HG: 0000-0002-5734-2891

*Corresponding author e-mail: meser961@anadolu.edu.tr

INTRODUCTION

Elaphostrongylus cervi which is an important helminth parasite in Red Deer (*Cervus elaphus*) is found in muscles, brain and the epidural space of the spinal cord in many deer species including Caspian red deer (*Cervus elaphus maral*), Canadian deer (*Cervus elaphus canadensis*), Japanese deer (*Cervus nippon*) and roe deer (*Capreolus capreolus*). The intermediate hosts are various land snails (Mason, 1989). Mature parasites are 4-6 cm long, pale, and in thread-shaped structure. Transmission of the parasite is through the infective larvae reaching the lungs through the bloodstream. Symptoms include lung inflammation and nervous disorders in the brain (Boden 2005). This parasite is found especially in domestic, and wild ruminants in Europe, including Scotland, Australia, and North America, and has widespread (Mason 1989). Parasites have a significant impact on wildlife populations, including reproduction and survival (Anderson 1978). Although there are many studies on

the wild animals in Turkey (Uslu et al. 2008, Acııcı et al. 2012, Acııcı et al. 2017, Bolukbas et al. 2012, Girisgin et al. 2018, Dik and Kılınç 2015), studies on helminth infections that infect red deer are limited (Cengiz et al. 2019). So far, there has not been a study to determine the *Elaphostrongylus cervi* infection in red deer in Turkey.

With this first study in Turkey, it is aimed to determine the state of *E. cervi* infection in the red deer in Eskisehir and to contribute to the detection of the local fauna.

MATERIAL and METHODS

This study was carried out between June-July 2020 in Eskisehir (Figure 1). Based on the traces and signs of red deer in the Catacik region of Eskisehir, 32 fresh fecal samples belonging to animals from the places where the faeces density was found were taken into transparent nylon bags and recorded by numbering. The faeces obtained were brought to laboratory.

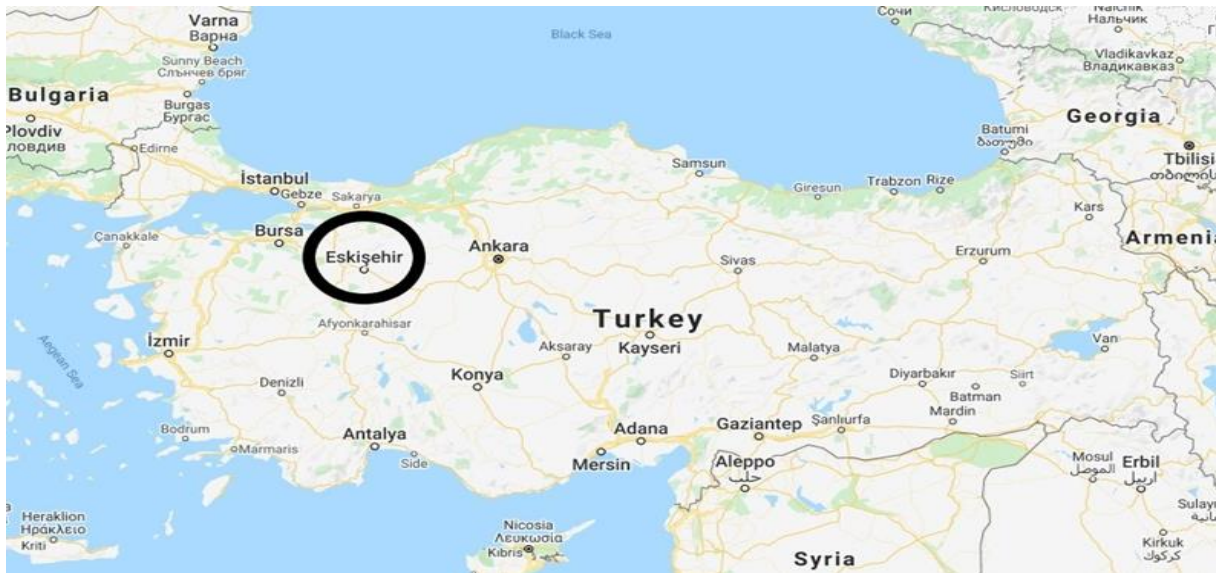

Figure 1. Location of Turkey and Eskisehir province (with black circles).

Stool samples were examined for cestode rings macroscopically, and microscopically by sedimentation, saturated salt flotation, and Baermann Wetzel methods. (Thienpont and et al. 1986). Light microscope (Olympus CX31-Olympus Imaging System LC30) was used for the identification of larvae obtained by Baerman technique. Total body length, maximum body width, tail length (from the anus to tail tip), tail extension length, and dorsal spine length were measured in a total of 50 dorsal spiny larvae in lactophenol solution.

RESULTS

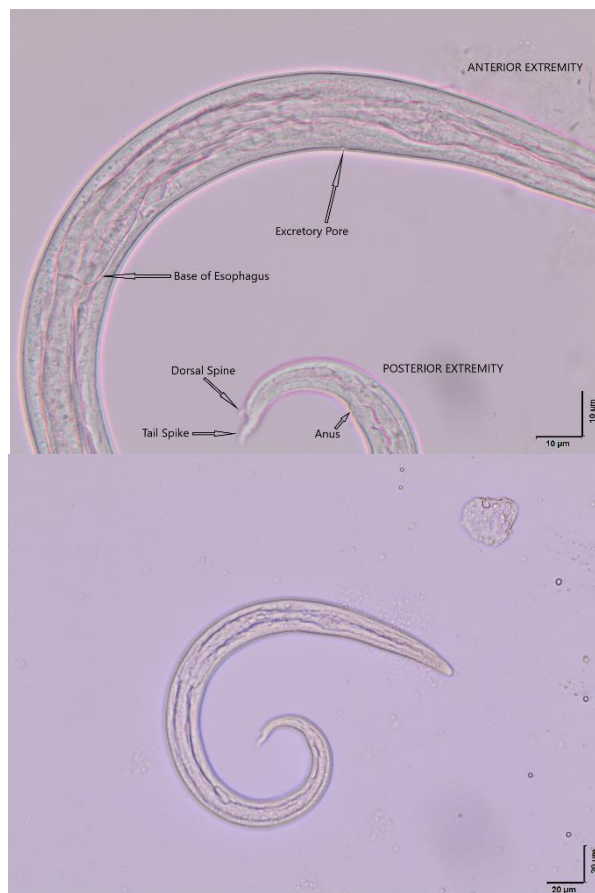In the study, it was determined that the dorsal spiny larvae, whose morphometric measurements were made, belonged to the *E. cervi* species. Looking at the morphometric measurements of the dorsal-spined larvae, the average total length was 408 μm , the width was 20 μm , the tail was 38 μm , tail extension length was 9.23 μm , and dorsal spine was 2.69 μm . (Table 1).

Table 1. Measures (in μm) of dorsal-spined larvae recovered from red deer (*Cervus elaphus*).

References		This study	Baruš and Blazek 1973	Kutzer and Prosl 1975	English et al. 1985	Demiaszkiewicz 1986	Řezáč 1990	Vicente and Gortázar 2001	Morandi et al., 2006	Panayotova-Pencheva and Alexandrov 2008
Total length	Mean	408	-----	407	410	424	422	401	-----	423
	Min-Max	377-437	342-408	364-452	391-460	382-463	390-459	365-425	390-430	377-473
Width	Mean	20			18	19	19	-----		20
	Min-Max	16-26	18-20	17-21	16-21	16-24	16-23		18-20	18-24
Tail extension length	Mean	9,23	-----	-----	-----	-----	-----	-----	-----	-----
	Min-Max	7,81-9,98								
Dorsal Spine	Mean	2,69	-----	-----	-----	-----	-----	-----	-----	-----
	Min-Max	2,08-2,79								
Tail	Mean	38		43	42	-----	44	-----	-----	37
	Min-Max	34-42	26-35	35-50	32-52		41-49			32-42

First stage *E. cervi* larvae have rhabditiform type esophagus. The excretory hole is in the anterior ventral of the body. Genital primordium is found in

the last 1/3 of the body. The tail has a characteristic shape. They have a distinct triangular spine on the dorsal side parallel to the tail tip (Figure 2).



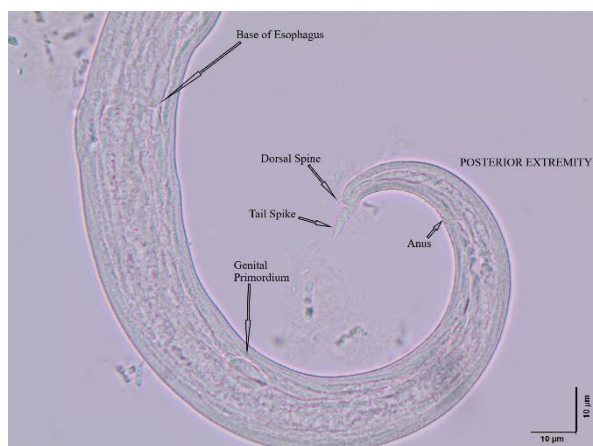


Figure 2. First stage *E. cervi* larva found in red deer (*C. elaphus* L.) from Turkey (original).

DISCUSSION and CONCLUSION

The red deer are ruminants that roam wildly in limited areas or are reared in certain protected environments in Turkey. Although there are many studies on the wild animals in Turkey (Uslu et al. 2008, Acıacı et al. 2012, Acıacı et al. 2017, Bolukbas et al. 2012, Girişgin et al. 2018, Dik and Kılınc 2015), studies on helminth infections that infect red deer are limited (Cengiz et al. 2019). So far, there has not been a study on *E. cervi* infection in Turkey.

This first study in Turkey reports the *E. cervi* infection in red deer in Eskişehir. First stage *E. cervi* larvae were found in all 32 stool samples. There are many studies abroad on *E. cervi* supported by both stool and necropsy examinations. (Hutsch et al. 2020, Panayotova-Pencheva and Alexandrov 2011, Alberti et al. 2011, Demiaszkiewicz et al. 2016, Sutherland 1976, Bregoli et al. 2006, Valcárcel and Garcia Romero 2002).

It was reported that 16.6% of the Red deer examined in Poland were infected with *Elaphostrongylus* sp (Hutsch et al. 2020). In another study, it was noted that 76.7% of the red deer were infected with *E. cervi* (Demiaszkiewicz et al. 2016).

In a study conducted in Italy, it was reported that 45.2% of the red deer were infected with *E. cervi* (Alberti et al., 2011). In the stool examination of 110 Red deer in Bulgaria, 75 (68%) of them were found to be infected with *E. cervi*. In the same study, *E. cervi* was found in the lung tissue of 5 deer by the necropsy (Panayotova-Pencheva and Alexandrov 2011).

In a study conducted on the red deer in New Zealand, it was reported that mature *E. cervi* were found in connective tissue associated with skeletal muscles and its larvae in the lungs, causing various pathological lesions in these tissues (Sutherland, 1976). In Italy, mature *E. cervi* were diagnosed in the submeningeal region for the first time in the red deer with neurological symptoms, and cerebral nematodiasis was reported (Bregoli et al. 2006).

In a study conducted in Spain, it was reported that 31.5% of the red deer were infected with mature *E. cervi* in the central nervous system, and *E. cervi* was recorded for the first time in the central nervous system of red deer in Spain (Valcárcel and Garcia to Romero. 2002)

Eskişehir province, where the study was conducted, is suitable for the survival of slugs that serve as an intermediate host to helminth infections, considering that it has a continental and humid climate under the influence of the Black Sea and Central Anatolia. The field where the study was conducted is not suitable for water slugs, but because of the dry areas suitable for land slugs, it only strengthens the possibility of *E. cervi* infections in deer. (Kuligowska and Demiaszkiewicz 2010). *E. cervi* also causes neurological lesions in small ruminates. Therefore, the grazing of domesticated small ruminates in areas where deer are present indicates that the disease with a high prevalence in deer may also transmit to small ruminates (Alberti et al. 2011, Handeland et al. 2000). The literature research has proven that this species has not been reported in Turkey before. *E. cervi*, diagnosed in Red deer with this study, is reported for the first time with this study. Therefore, this research will provide valuable data for the red deer in Turkey. More research is needed to determine the parasitic fauna of the red deer that live wildly in limited areas or are reared in certain protected environments in our country.

ACKNOWLEDGMENTS

This study was supported by the Scientific Research Projects Coordination Unit of Anadolu University (Project number: 2005S062).

Ethical statement: No ethical committee approval is required as the experimental animal is not used.

To carry out this research, the permission of the Ministry of Agriculture and Forestry dated 05/05/2020-E.19084 was obtained.

Conflict of interest : The authors declare that they have no conflict of interest.

REFERENCES

- Acıacı M, Bolukbaş CS, Beyhan YE, Pekmezci GZ, Gurler AT, Umur Ş.** Ectoparasites on roe deer (*Capreolus capreolus*) in Samsun, Turkey. *Turk J Vet Anim Sci.* 2012; 36(4): 456- 459. Doi:10.3906/vet-1009-471
- Acıacı M, Demirtaş S, Umur Ş, Gurler AT, Bolukbaş CS.** Infestations of flea species on small, wild mammals in the provinces of Aydın and Manisa in the Aegean Region, Turkey. *Turk J Vet Anim Sci.* 2017; 41(3): 449-452. Doi:10.3906/vet-1610-68
- Alberti EG, Gioia G, Sironi G, Zanzani S.** *Elaphostrongylus cervi* in a population of red deer (*Cervus elaphus*) and evidence of cerebrospinal nematodiasis in small ruminants in the province of Varese, Italy. *Journal of Helminthology.* 2011; 85(3), 313-318. Doi: 10.1017/S0022149X10000647
- Anderson RM.** The regulation of host population growth by parasitic species. *Parasitology.* 1978; 76, 119–57. Doi: 10.1017/S0031182000047739
- Baruš V, Blažek K.** Report on the finding of larval nematodes *Elaphostrongylus cervi* (Protostrongylidae) in the cranial cavity of a stag. *Folia Parasitol (Praha).* 1973; 20:279–280. Doi: 10.1007/s10344-008-0206-7
- Bregoli M, Natale A, Cova M, Vascellari M, Pasolli C.** Meningeal nematodiasis in a red deer (*Cervus elaphus*) in northeastern Italy - a case report. *Vet. Arhiv.* 2006; 76 (Suppl.), 287-293.
- Bolukbaş CS, Gurler AT, Beyhan YE, Acıacı M, Umur S.** Helminths of roe deer (*Capreolus capreolus*) in the middle Black Sea region of Turkey. *Parasitol Int.* 2012; 61:729–730. Doi: 10.1016/j.parint.2012.06.008
- Boden E.** Black's Veterinary Dictionary 21. Ed. A&C Black Publishers Limited, 38 Soho Square, London. sy. 174. 2005
- Cengiz G, Tenekeci GY, Bilgen N.** Molecular and morphological characterization of *Cysticercus tenuicollis* in red deer (*Cervus elaphus*) from Turkey. *Acta Parasitologica.* 2019; 64:652–65. doi: 10.2478/s11686-019-00085-1. Doi: 10.2478/s11686-019-00085-1
- Demiaszkiewicz AW.** Laboratoryjna diagnostyka różnicowa Protostrongylidoz jeleniowatych. *Med Welt,* 1986; 42:660–663 in Polish
- Demiaszkiewicz AW, Merta D, Kobielski J.** Infection of red deer by parasites in South-Western Poland (Lower Silesian Wilderness). *Med. Weter.* 2016; 72 (5), 317-320.
- Dik B, Kılınç ÖO.** First case of *Trichodectes pinguis* (Phthiraptera: Ischnocera: Trichodectidae) on a Bear (*Ursus arctos*) in Turkey. *Turkiye Parazitoloj Derg.* 2015; 39, 313-315. Doi: 10.30782/uluvfd.405325
- English A, Watt C, Corrigan W.** Larvae of *Elaphostrongylus cervi* in the deer of Scotland. *Vet Rec.* 1985; 116:254–256
- Girişgin AO, Çimenlikaya N, Bah SA, Aydın L, Girişgin O.** Türkiye'de bazı yabani memelilerde bulunan dış parazit türlerinin ilk kayıtları. *Uludağ Univ Vet Fak Derg.* 2018; 37(2), 133-136. Doi: 10.30782/uluvfd.405325
- Handeland K, Gibbons LM, Skorpung A.** Experimental *Elaphostrongylus cervi* Infection in Sheep and Goats. *Journal of Comparative Pathology.* 2000; 123(4):248-57. Doi: 10.1053/jcpa.2000.0414
- Hutsch KF, Czopowicz M, Świstockac M, Ratkiewicz M, Borkowskac A, Kowalczykd R, Demiaszkiewicz AW.** Patterns of parasite eggs, oocysts and larvae shedding by moose in the Biebrza marshland (NE Poland). *IJP: Parasites and Wildlife.* 2020; 11 191–197. doi: 10.1016/j.ijppaw.2020.02.007
- Kuligowska I, Demiaszkiewicz AW.** Infection of terrestrial snails with larvae of *Elaphostrongylus cervi* (Nematoda, Protostrongylidae) in Białowieża National Park Helminthologia. 2010; 47, 1: 25 – 28. Doi:10.2478/s11687-010-0004-0
- Kutzer E, Prosl H.** Zur Kenntnis von *Elaphostrongylus cervi* Cameron, 1931. I. Morphologie und Diagnose. *Wien Tierarztl Mschr.* 1975; 62:258–266
- Morandi F, Galuppi R, Nicoloso S, Benazzi C, Tampieri MP, Simoni P.** Larvae of *Elaphostrongylus cervi* in a Population of Freelifving Red Deer in Italy. *J Wildl Dis.* 2006; 42:870-872 Doi: 10.1007/s10344-008-0206-7
- Mason PC.** *Elaphostrongylus cervi*-a review. *Surveillance.* 1989, 16(1): 3-10.
- Panayotova-Pencheva M, Alexandrov M.** Morphometric characteristics of first stage *Elaphostrongylus cervi* (Nematoda: Protostrongylidae) larvae from Bulgaria. *Eur J Wildl Res* 54:771–774 2008; DOI 10.1007/s10344-008-0206-7
- Panayotova-Pencheva MS, Alexandrov MT.** Etiopathological aspects of *Elaphostrongylus cervi* and *Varestrongylus sagittatus* infections in red deer in Bulgaria. *Acta Vet Brno.* 2011; 80(4): 349–352. Doi: 10.2754/avb201180040349
- Řezáč P.** Diferenciální diagnostika larev 1. stadia hlístic *Varestrongylus sagittatus* a *Elaphostrongylus cervi*. *Veterinarstvi* 1990; 40:311–313 in Czech. Doi: 0.1007/s10344-007-0143-x
- Sutherland RJ.** *Elaphostrongylus cervi* in Cervids in New Zealand. *New Zealand Veterinary Journal.* 1976; 24:11, 263-266. Doi: 10.1080/00480169.1976.34334
- Thienpont D, Rochette F, Vanparijs OFJ.** Diagnosing Helminthiasis by Coprological Examination. Second edition. Belgium: Janssen Research Foundation. 1986.
- Uslu U, Dik B, Gokcen A.** Ectoparasites of the ground squirrel (*Citellus citellus* (L.)) in Turkey. *Turkiye Parazitoloj Derg.* 2008; 32: 142-145.
- Valcárcel F, Garcı'a Romero C.** First report of *Elaphostrongylus cervi* in Spanish red deer (*Cervus elaphus hispanicus*). *Journal of Helminthology.* 2002; 76, 91–93. Doi: 10.1079/JOH2003232

Vicente J, Gortázar C. High prevalence of large spiny-tailed protostrongylid larvae in Iberian red deer. *Vet Parasitol.* 2001; 96:165–170 doi:10.1016/S0304-4017(00)00425-8
Doi: 10.1007/s10344-008-0206-7