



Jugular Venous Distention Presenting with Bilateral Giant Vascular Sacs on the Neck

Juguler Venöz Distansiyonun Neden Olduğu İki Taraflı Büyük Vasküler Keseler

Çağlar Kaya¹, Utku Zeybey¹, Savaş Hereklioğlu², Kenan Yalta¹

¹ University of Trakya, Faculty of Medicine, Department of Cardiology, Edirne, Turkey

² University of Trakya, Faculty of Medicine, Department of Radiology, Edirne, Turkey

A 79 year-old female was presented with the symptoms of dyspnea and swelling on her legs. She had a history of diabetes mellitus, hypertension, and heart failure (HF). Vital signs were unremarkable, except for an irregular pulse that was consistent with atrial fibrillation on electrocardiogram. A physical examination revealed 3-4/6 pansystolic murmur at the lower left sternal border along with signs of fluid retention such as mild ascites, ++ pitting edema in lower extremity. However, the most prominent finding on inspection was the presence of massive bilateral lumps on her neck. Notably, on palpation, these lumps appeared to be vascular sacs that were compressible, tortuous, and saggy in nature (the one on the right side was greater and measured 54 x 49 mm in size) (Figure 1). These lumps might have possibly emerged due to enhanced central venous pressure (CVP) associated with long-standing and advanced right HF (possibly because of both myocardial failure and severe tricuspid regurgitation). Accordingly, transthoracic echocardiogram demonstrated left ventricular systolic dysfunction, severely dilated right heart chambers along with severe tricuspid regurgitation, and systolic pulmonary arterial pressure of \approx 100 mmHg (Figure 2). Figure 3 demonstrates ultrasonographic images of left-sided distended internal-external jugular veins and thickness of the right-sided vascular sac (14 mm) that was probably undermeasured due to its easily compressible nature. Bilateral jugular venous distension (JVD) is a relatively specific and frequent sign in patients with HF that reflects enhanced CVP in this setting. However, the manifestation of JVD as giant, lump-like vascular sacs (as reported herein) has been an extremely rare finding in clinical practice.

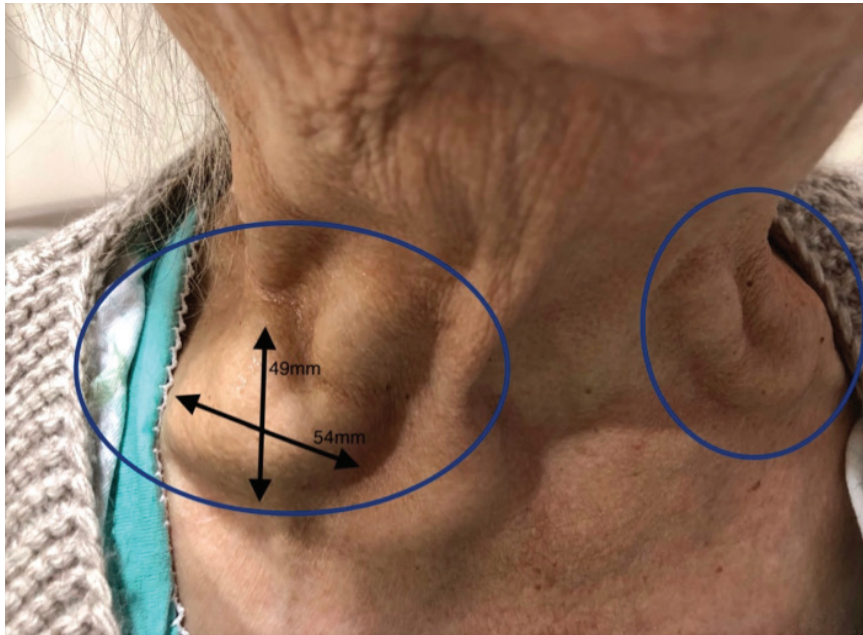


Figure 1. Massive bilateral vascular sacs detected on inspection.

Cite this article as: Kaya Ç, Zeybey U, Hereklioğlu S, Yalta K. Jugular venous distention presenting with bilateral giant vascular sacs on the neck. Koşuyolu Heart J 2020;23(1):76-8.

Correspondence

Çağlar Kaya

E-mail: caglarkaya2626@gmail.com

Submitted: 20.07.2019

Accepted: 05.02.2020

Available Online Date: 30.04.2020

© Copyright 2020 by Koşuyolu Heart Journal. Available on-line at www.kosuyoluheartjournal.com

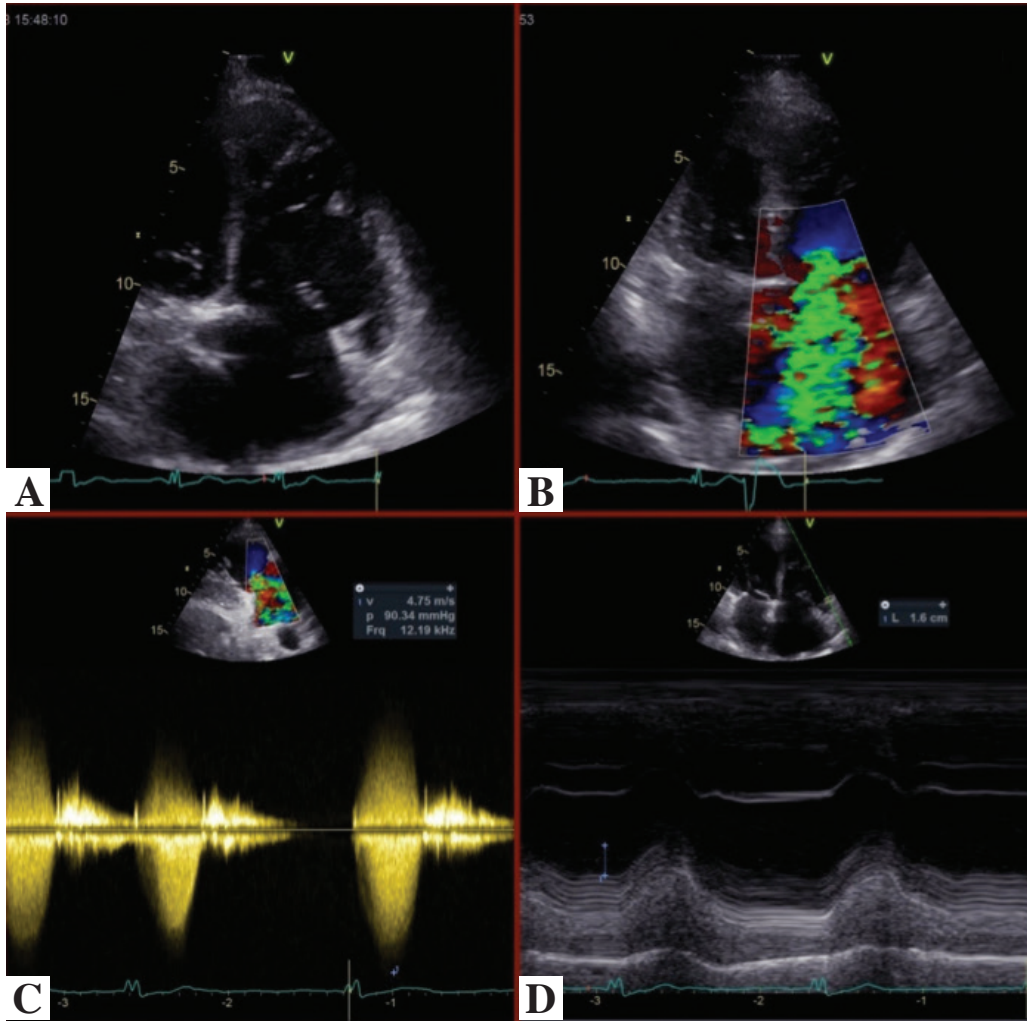


Figure 2. Transthoracic echocardiographic images demonstrating enlarged right-sided cardiac chambers, severe tricuspid regurgitation, severe pulmonary hypertension, and borderline right ventricular systolic function. **A.** Enlarged right atrium and ventricle. **B.** Severe tricuspid regurgitation as measured with color Doppler. **C.** Peak systolic transtricuspid regurgitant flow velocity and gradient consistent with severe pulmonary hypertension (PHT). **D.** Borderline tricuspid annular plane systolic excursion (TAPSE) (16 mm).

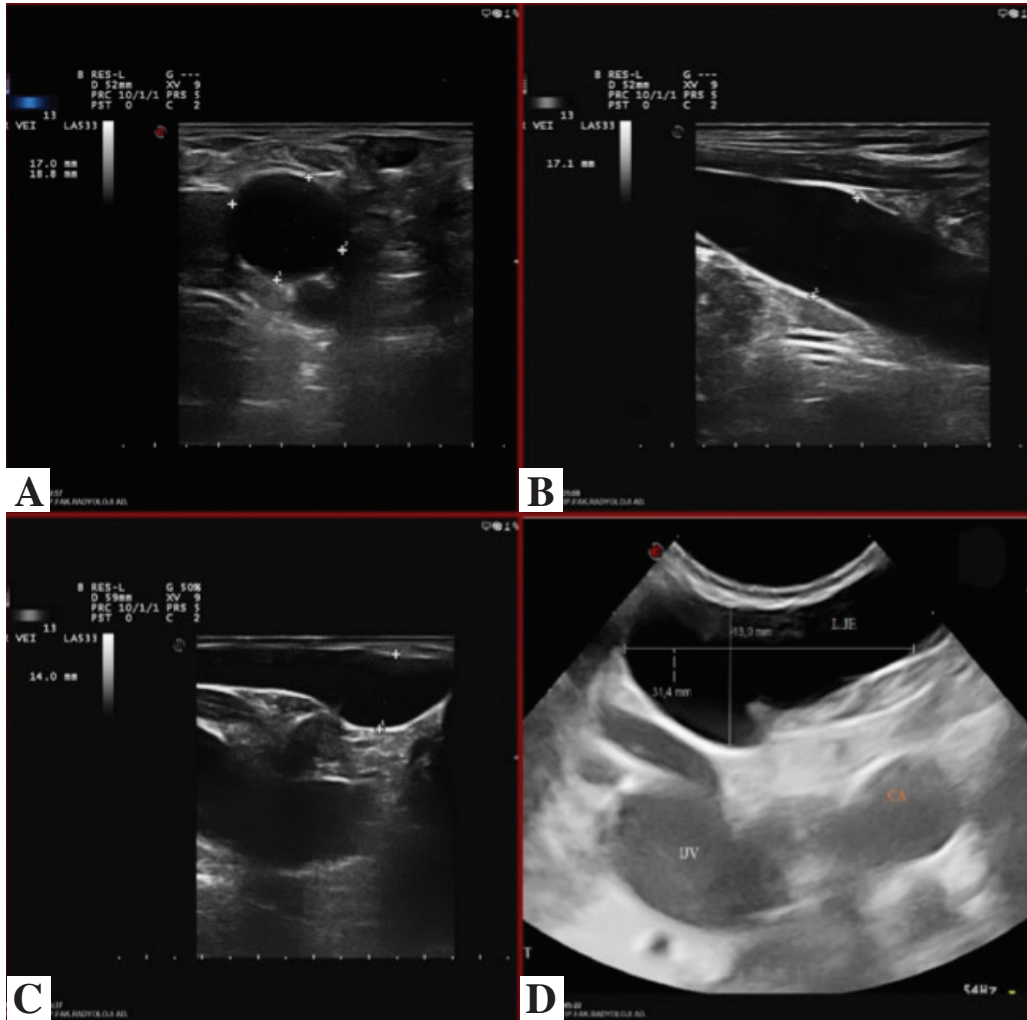


Figure 3. Ultrasonographic images of left-sided distended internal-external jugular veins and right-sided vascular sac. **A.** Left-sided internal jugular vein measuring ≈ 18 mm on transverse plane. **B.** Left-sided internal jugular vein measuring ≈ 17 mm (maximum size) on longitudinal plane. **C.** Right-sided vascular sac measuring 14 mm in thickness on longitudinal plane. **D.** Left-sided vascular sac vein measuring $\approx 13 \times 31$ mm.

Informed Consent: Written informed consent was obtained from patient who participated.

Peer-review: Externally peer-reviewed.

Author Contributions: Concept/Design – ÇK; Analysis/Interpretation – KY, SH, ÇK; Data Collection – ÇK, UZ; Writing – ÇK, KY, UZ; Critical Revision – KY; Final Approval – ÇK, KY; Statistical Analysis – KY, UZ, ÇK; Obtained Funding – ÇK, UZ; Overall Responsibility – ÇK, KY, UZ

Conflict of Interest: The authors have no conflict of interest to declare.

Financial Disclosure: The authors declared that this study has received no financial support.