



Percutaneous Mitral Balloon Valvuloplasty as a Safe Treatment Modality for Mitral Stenosis in a Patient with Pancytopenia and Severe Liver Failure

Pansitopeni ve Karaciğer Yetmezliği Olan Mitral Stenozu Hastasında Güvenli Bir Tedavi Modalitesi Olarak Perkütan Mitral Balon Valvüloplasti

Gökhan Demirci¹, Serkan Kahraman¹, Ahmet Anıl Şahin¹, Fatih Uzun¹, Mustafa Yıldız²

¹ Istanbul Mehmet Akif Ersoy Cardiovascular Surgery Training and Research Hospital, Department of Cardiology, Istanbul, Turkey

² Istanbul University Cardiology Institute, Department of Cardiology, Istanbul, Turkey

A 43-year woman was referred to our tertiary center for severe mitral stenosis. She had end-stage liver failure and pancytopenia caused by primary biliary cirrhosis; liver transplantation was planned. Sclerotherapy was performed three times as a result of the esophageal varices bleeding (Figure 1). She had demonstrated increased dyspnea for 6 months. Electrocardiography revealed normal sinus rhythm. Transesophageal echocardiographic examination demonstrated severe rheumatic mitral stenosis with a mitral valve area of 0.9 cm² (peak gradient, 28 mmHg; mean gradient, 19 mmHg) and without left atrial thrombus (Figure 2A,B). Our cardiology and cardiovascular surgery team planned percutaneous mitral balloon valvuloplasty. Before the procedure, one unit of platelet apheresis was given to the patient as a result of pancytopenia. Successful percutaneous mitral balloon valvuloplasty was performed under transthoracic echocardiographic examination without general anesthesia

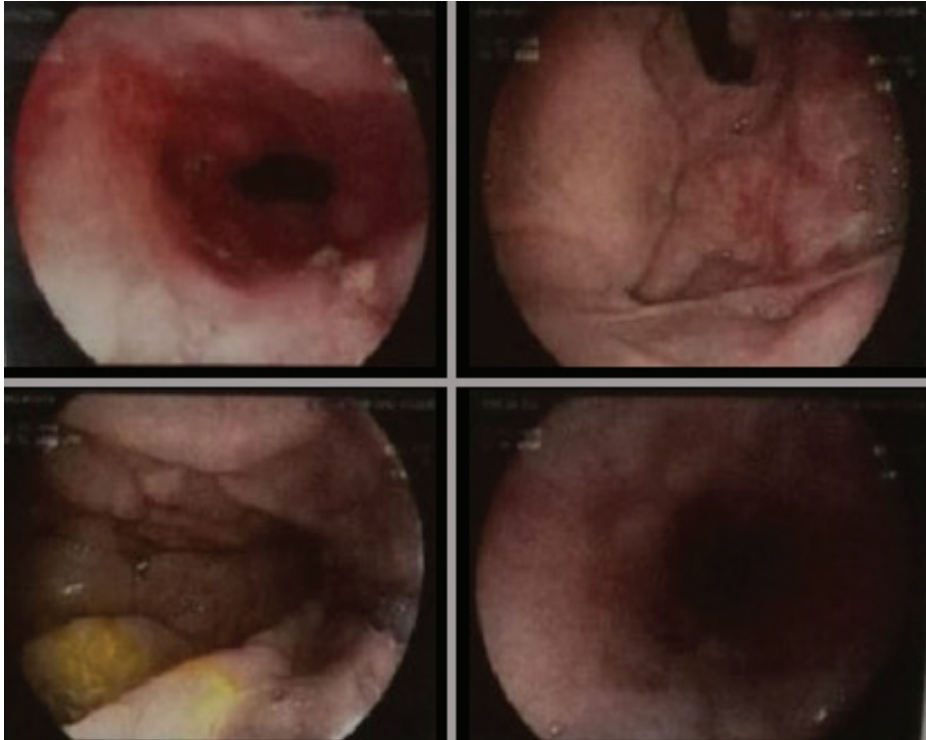


Figure 1. Gastroscopy images of the patient.

Cite this article as: Demirci G, Kahraman S, Şahin AA, Uzun F, Yıldız M. Percutaneous mitral balloon valvuloplasty as a safe treatment modality for mitral stenosis in a patient with pancytopenia and severe liver failure. Koşuyolu Heart J 2020;23(1):79-80.

Correspondence

Serkan Kahraman

E-mail: serkankahraman_86@outlook.com

Submitted: 15.01.2020

Accepted: 21.02.2020

Available Online Date: 30.04.2020

© Copyright 2020 by Koşuyolu Heart Journal.

Available on-line at

www.kosuyoluheartjournal.com

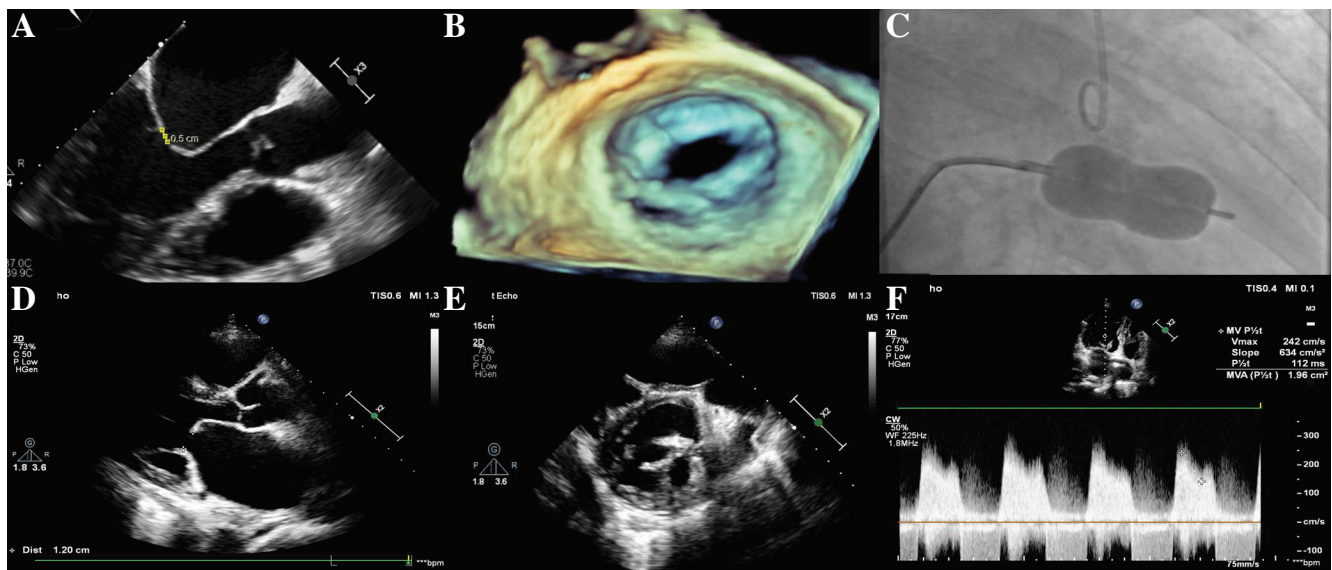


Figure 2. Mitral valve images before and after percutaneous mitral balloon valvuloplasty. **A.** The distance between the mitral valve leaflets before the procedure. **B.** Transesophageal echocardiographic image of the mitral valve before the procedure. **C.** Angiographic image of percutaneous mitral balloon valvuloplasty. **D.** The distance between the mitral valve leaflets after the procedure. **E.** Transesophageal echocardiographic image of the mitral valve after the procedure. **F.** Echocardiographic measurement of the mitral valve area using the pressure half time method.

and transesophageal echocardiography (Figure 2C). After the procedure, the mean gradient decreased from 19 to 6 mmHg, and the mitral valve area increased from 0.9 to 1.9 cm² (Figure 2D-F). The patient was discharged from the hospital two days after the intervention without complications or symptoms. Percutaneous mitral balloon valvuloplasty without complication can be performed safely and without the use of intracardiac ultrasound and transesophageal echocardiography at experienced centers in patients with pancytopenia and severe liver failure⁽¹⁾. Liver transplantation was also planned as soon as possible.

Author Contributions: Concept/Design – SK, GD, AAŞ, FU, MY; Analysis/Interpretation – SK, GD, AAŞ, FU, MY; Data Collection – SK, GD, AAŞ, FU, MY; Writing – SK, GD, AAŞ, FU, MY; Critical Revision – SK, GD, AAŞ, FU, MY; Final Approval – SK, GD, AAŞ, FU, MY; Statistical Analysis – SK, GD, AAŞ, FU, MY; Overall Responsibility – SK, GD, AAŞ, FU, MY

Conflict of Interest: The authors have no conflict of interest to declare.

Financial Disclosure: The authors declared that this study has received no financial support.

REFERENCE

1. Baumgartner H, Falk V, Bax JJ, De Bonis M, Hamm C, Holm PJ, et al. 2017 ESC/EACTS Guidelines for the management of valvular heart disease. *Eur Heart J* 2017;38:2739-91. <https://doi.org/10.1093/eurheartj/ehx391>

Informed Consent: Written informed consent was obtained from patient who participated.

Peer-review: Externally peer-reviewed.