

An Unusual Occurrence of Acute Cerebellar Infarct After Self-Cervical Manipulation: A Case Report

Enis ADEMOĞLU¹, Mehmet Muzaffer İSLAM¹, Gökhan AKSEL¹, Serkan Emre EROĞLU¹

¹University of Health Sciences, Umraniye Training and Research Hospital, Emergency

Abstract

Introduction: Spinal manipulation is a widely used method in the treatment of neck pain, but it has the potential for serious complications. Although controversial, stroke can occur especially after cervical manipulation. Stroke secondary to self-cervical manipulation is rare and only a few cases have been reported.

Case Report: We reported a 28-year-old male patient with complaints of dizziness, neck pain and right hemiparesis. Except the cerebellar gait and right hemiparesis, his neurological examination was normal. It was learnt that his complaints started an hour after the self-cervical manipulation. His brain computed tomography, brain and cervical computed tomography angiography were normal limits. The brain diffusion magnetic resonance imaging (MRI) revealed an acute infarction area. He was discharged without sequelae with antiaggregant treatment, after 8 days of follow-up in the hospital.

Conclusion: Although it is controversial whether the risk of stroke increases after cervical manipulation, we believe the risk of stroke may increase, especially when the manipulation is performed by non-professionals. Especially in younger patients with a history of cervical manipulation and neurological complaints, stroke should be suspected even if the neurological examination is normal.

Keywords: Stroke, cerebellar infarction, chiropractic manipulation, Self neck manipulation

Introduction

Stroke, which is one of the leading causes of morbidity and mortality in the world, is divided into two groups as ischemic and hemorrhagic. Ischemic stroke is 4 times more common. Various causes such as atherosclerosis, cardioembolism, genetics, trauma and arterial dissection play a role in the etiology of ischemic stroke¹.

Manual cervical spinal manipulation, the place of which is being discussed in the etiology of stroke, is a common treatment technique, especially for neck pain. However, although the results have been controversial, it may cause complications, such as cervical artery dissection (CAD), vertebral artery dissection (VAD), vertebrobasilar insufficiency (VBI), or a cerebellar or brain stem infarction²⁻⁴. In the literature, several cases of infarction have been reported after chiropractic therapy and, to a lesser extent, after self-cervical manipulation. And all of these cases are associated with vascular pathologies⁵⁻⁸.

In this case report, we present a 28-year-old male patient with an unusual case of cerebellar infarction, without any

vascular pathology who admitted to our emergency department with neck pain, dizziness and right hemiparesis.

Case Presentation

A 28-year-old male patient with no known medical history or drug use was admitted to our emergency department with complaints of dizziness, neck pain and right hemiparesis that began the previous day. It was learned from the patient's history that he was a plumber and sometimes experienced neck pain. He stated that he was not subjected to any neck trauma and was practicing self-rotational neck manipulations to relieve his neck pain. It was learnt that his complaints started an hour after the neck manipulation. The patient then applied to another emergency department the previous day but had not been diagnosed. After he was discharged from the hospital, he applied to our emergency department because his complaints did not recede. The patient's arterial blood pressure was 125/79 mmHg, heart rate was 85 beats/min, oxygen saturation was 95%, and electrocardiography (ECG) showed a normal sinus rhythm.

Corresponding Author: Enis ADEMOĞLU **e-mail:** ensademoglu@gmail.com

Received: 02.09.2020 • **Accepted:** 12.12.2020

DOI: 10.33706/jemcr.789735

©Copyright 2020 by Emergency Physicians Association of Turkey - Available online at www.jemcr.com

On neurological examination, there were cerebellar ataxia, hemiparesis in the right upper extremity, mild effacement in the left nasolabial sulcus and paresthesia in the left half of the face. Dysmetria or dysdiadochokinesia was not detected in the patient's cerebellar tests. He had no nystagmus. There were no motor findings giving sides. Routine laboratory tests, including complete blood tests, liver and kidney function tests, and electrolyte values, were within normal limits. Cervical and brain computed tomography (CT) of the patient was within normal limits. However, the brain diffusion magnetic resonance imaging (MRI) revealed an acute infarction area in the left cerebellar hemisphere inferior region (Figure 1). Brain and cervical CT angiography was performed and both vertebral arteries and the basilar artery were intact and patent. The patient was hospitalized with the diagnosis of cerebellar infarction secondary to cervical manipulation. The anticoagulant enoxaparin sodium 6000 anti-Xa IU/0.6 ml 1x1 was administered subcutaneously and antiaggregant treatment with acetylsalicylic acid (ASA) 100 mg 1x1 P.O. was given. During the follow-up examination, a transthoracic echocardiography (TTE), a transesophageal echocardiography (TEE), a bilateral carotid-vertebral color Doppler ultrasonography, and a control brain CT scan were performed and found to be normal. The patient's tests for coagulopathy, thrombophilia and connective tissue diseases (ANCA, ANA, anti-dsDNA, lupus anticoagulant, anti-Sm, anti Sm-RNP, anti-SSA, anti-SSB, antiphospholipid IgG, anticardiolipin IgG-IgM, anti beta-2 glycoprotein IgG-IgM, antithrombin III, protein c, protein s, homocysteine) were seen within normal limits. After 8 days of follow-up, the patient was discharged without any sequelae with antiaggregant treatment (ASA 100 mg 1x1 po). Informed consent was

obtained from the patient for the publication of his information and images.

Discussion

Chiropractic manipulation, which is an alternative treatment method used for cervical pain, is very common worldwide and performed by licensed people in some countries⁹. However, it is difficult to determine the frequency and results of all these practices. The safety of a spinal manipulation or the incidence of complications, such as infarction and dissection, after manipulation remains unknown¹⁰. A case-controlled study found that spinal manipulation therapy is associated with VAD, regardless of pain, even if it controls neck pain¹¹. In the literature, there have been several infarction cases reported following chiropractic treatment and self-cervical manipulation. The common feature of these cases is that they all have vascular pathologies such as vertebral or cervical or cerebral artery occlusion or dissection⁵⁻⁸. Contrary to these cases, no findings in favor of dissection or occlusion were found as a result of imaging performed in our case. Both the carotid arteries and vertebral arteries were intact. As in our case (28-year-old), the history of neck manipulation, especially in young patients without comorbid disease, suggests that the cause of the stroke may be manipulation. Rothwell et al. founded that patients under the age of 45 had an increased risk between vertebral artery dissections or occlusions after cervical manipulation². However, it was stated in a systematic review and meta-analysis that there is a weak relationship between cervical neck manipulation and cervical artery dissection, but studies in the literature may be

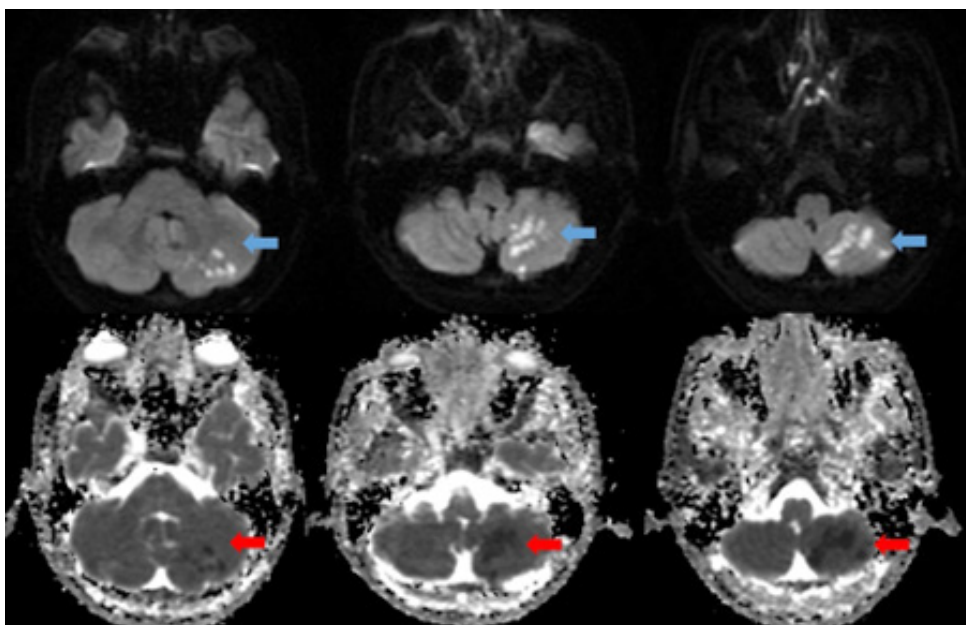


Figure 1: The acute infarct area in the left cerebellar hemisphere, is indicated by the arrow on the diffusion-weighted imaging (DWI) and Apparent diffusion coefficient (ADC) sequence in the diffusion MRI.

biased and there is no causal evidence¹². In a cross randomized controlled trial published in May 2019, MRI measurements were performed to investigate the effects of cervical manipulation on vertebral arteries and cerebral perfusion. The results suggest that cervical manipulation did not cause cerebral perfusion changes compared with a neutral neck position or a maximal neck rotation, and it may not increase the risk of cerebrovascular events with a hemodynamic mechanism¹³. However, as in our case, the possible risk of injury following manipulation, especially when performed by non-professionals, cannot be ruled out. As no etiology was found to explain the infarction in our case, such as any vascular pathology, infection, connective tissue disease, we concluded that cervical manipulation may be the etiological cause of this infarct. A study by the American Heart Association and American Stroke Society (AHA/ASA) in 2014 suggests that patients should be informed about the cause and effect relationship before manipulation since the risk of cervical dissection secondary to cervical manipulation treatment is not clear¹⁴. Since the effects and complications of cervical manipulation are very controversial, studies with a higher degree of scientific evidence are needed.

Conclusion

Stroke is a common cause of emergency admissions, and the patient's story may not always be clear. Clinicians should keep all kinds of etiology in mind. Although it is controversial whether the risk of stroke increases after cervical manipulation, we believe the risk of stroke may increase, especially when the manipulation is performed by non-professionals.

References

1. Boehme, A. K., Esenwa, C., & Elkind, M. S. (2017). Stroke risk factors, genetics, and prevention. *Circulation research*, 120(3), 472-495.
2. Rothwell DM, Bondy SJ, Williams JI. Chiropractic manipulation and stroke: a population- based case-control study. *Stroke*. 2001 May;32(5):1054-60. doi: 10.1161/01.str.32.5.1054.
3. Haldeman S, Kohlbeck FJ, McGregor M. Stroke, cerebral artery dissection, and cervical spine manipulation therapy. *J Neurol*. 2002 Aug;249(8):1098-104. doi: 10.1007/s00415-002-0783-4.
4. Albuquerque FC, Hu YC, Dashti SR, Abila AA, Clark JC, Alkire B, et al. Craniocervical arterial dissections as sequelae of chiropractic manipulation: patterns of injury and management. *J Neurosurg*. 2011 Dec;115(6):1197-1205. doi: 10.3171/2011.8.JNS111212.
5. Mukherjee ST. Cervical Manipulation Leading to Cerebellar Stroke in a Pilot. *Aerosp Med Hum Perform*. 2015 Dec;86(12):1066-9. doi: 10.3357/AMHP.4400.2015.
6. Kowlgi NG, Gowani SA, Mota P, Haider J. Self-inflicted vertebral artery dissection: a case report and review of literature. *Conn Med*. 2013 Oct;77(9):551-2. PMID: 24266133
7. Jeret JS, Bluth M. Stroke following chiropractic manipulation. Report of 3 cases and review of the literature. *Cerebrovasc Dis*. 2002;13(3):210-3. doi: 10.1159/000047778.
8. Jeong DK, Hwang SK. A Case of Posterior Inferior Cerebellar Artery Infarction after Cervical Chiropractic Manipulation. *Korean J Neurotrauma*. 2018 Oct;14(2):159-163. doi: 10.13004/kjnt.2018.14.2.159.
9. Beliveau PJH, Wong JJ, Sutton DA, Simon NB, Bussi eres AE, Mior SA, et al. The chiropractic profession: a scoping review of utilization rates, reasons for seeking care, patient profiles, and care provided. *Chiropr Man Therap*. 2017 Nov 22;25:35. doi: 10.1186/s12998-017-0165-8.
10. Nielsen SM, Tarp S, Christensen R, Bliddal H, Klokke L, Henriksen M. The risk associated with spinal manipulation: an overview of reviews. *Syst Rev*. 2017 Mar 24;6(1):64. doi: 10.1186/s13643-017-0458-y.
11. Smith WS, Johnston SC, Skalabrin EJ, Weaver M, Azari P, Albers GW, et al. Spinal manipulative therapy is an independent risk factor for vertebral artery dissection. *Neurology*. 2003 May 13;60(9):1424-8. doi: 10.1212/01.wnl.0000063305.61050.e6
12. Church EW, Sieg EP, Zalatimo O, Hussain NS, Glantz M, Harbaugh ER. Systematic Review and Meta-analysis of Chiropractic Care and Cervical Artery Dissection: No Evidence for Causation. *Cureus*. 2016 Feb; 8(2): e498. doi: 10.7759/cureus.498.
13. Moser N, Mior S, Noseworthy M, C ot e P, Wells G, Behr M, et al. Effect of cervical manipulation on vertebral artery and cerebral haemodynamics in patients with chronic neck pain: a crossover randomised controlled trial. *BMJ Open*. 2019; 9(5): e025219. doi: 10.1136/bmjopen-2018-025219.
14. Biller J, Sacco RL, Albuquerque FC, Demaerschalk BM, Fayad P, Long PH, et al. American Heart Association Stroke Council. Cervical arterial dissections and association with cervical manipulative therapy: a statement for healthcare professionals from the american heart association/american stroke association. *Stroke*. 2014 Oct;45(10):3155-74. doi: 10.1161/STR.0000000000000016.