



Closure of Three Separate Complex Paravalvular Defects with Four Devices By Transapical Approach

Alev Kılıçgedik¹, Deniz Çevirme¹, Mehmet Muhsin Türkmen², Cevat Kıırma², Mehmet Özkan²

¹ University of Health Sciences, Istanbul Kartal Kosuyolu High Speciality Training and Research Hospital, Department of Cardiovascular Surgery, Istanbul, Turkey

² University of Health Sciences, Istanbul Kartal Kosuyolu High Speciality Training and Research Hospital, Department of Cardiology, Istanbul, Turkey

ABSTRACT

Paravalvular leaks (PVL) that complicate prosthetic valve replacement may be observed in 2%-12% of the patients after mitral valve replacement and 1%-5% of the patients after aortic valve replacement. The percutaneous closure of PVL is considered as a less invasive alternative to a surgical closure for symptomatic relief in high-risk patients. The objective of this case report is to present a successful transapical closure of three separate mitral paravalvular defects with four devices in a patient with severe hemolysis.

Key Words: Paravalvular leak; echocardiography

Üç Ayrı Paravalvüler Defektin Transapikal Yol ile Dört Ayrı Cihazla Kapatılması

ÖZET

Protez kapak yerleştirilmesi operasyonlarının bir komplikasyonu olarak paravalvüler kaçaklar (PVL) mitral protez kapak yerleştirilmesi sonrası %2-12 ve aortik protez kapak yerleştirilmesi sonrası %1-5 oranında görülebilir. Semptomatik yüksek riskli hastalarda, perkütan PVL kapatma işlemi cerrahiye göre daha az invaziv bir alternatiftir. Bu olgu bildirisinde, ciddi hemolizi olan semptomatik bir hastada üç ayrı mitral paravalvüler defektin dört cihaz ile transapikal başarılı olarak kapatılması sunulmuştur.

Anahtar Kelimeler: Paravalvüler yetersizlik; ekokardiyografi

INTRODUCTION

Paravalvular leaks (PVL) that complicate prosthetic valve replacement may be observed in 2%-12% of the patients after mitral valve replacement (MVR) and 1%-5% of the patients after aortic valve replacement⁽¹⁾. Most of the patients who underwent PVL have a benign clinical course but 1%-5% of these patients present with the symptoms of congestive heart failure and hemolysis⁽¹⁻³⁾. Although surgical intervention is recommended in these patients with symptoms, a redo surgery carries a high recurrence rate along with a greater risk of morbidity and mortality than the initial procedure^(1,2). Therefore, the percutaneous closure of PVL is considered as a less invasive alternative to a surgical closure for symptomatic relief in high-risk patients⁽⁴⁾. The purpose of this case report is to present a successful transapical closure of three separate mitral paravalvular defects with four devices in a patient with severe hemolysis.

CASE REPORT

A 48-year-old woman with complaints of dyspnea and fatigue was admitted to our hospital. She belonged to class III according to the New York Heart Association Functional Classification. She underwent bioprosthetic MVR because of previous acute rheumatic fever in 1988. She had redo-MVR in 1997. Moreover, she underwent aortic valve replacement and redo MVR because of PVL in 2007. In the same year, she received thrombolytic therapy for prosthetic valve thrombus.

Her complaints had intensified within a last few months (before admission). Laboratory examination revealed that her urea (32.4 mg/dL) and creatinine (0.66 mg/dL) levels were

Cite this article as: Kılıçgedik A, Çevirme D, Türkmen MM, Kıırma C, Özkan M. Closure of three separate complex paravalvular defects with four devices by transapical approach. Koşuyolu Heart J 2020;23(2):148-52.

Correspondence

Alev Kılıçgedik

E-mail: akilicgedik@yahoo.com

Submitted: 21.07.2020

Accepted: 21.07.2020

Available Online Date: 25.08.2020

© Copyright 2020 by Koşuyolu Heart Journal. Available on-line at www.kosuyoluheartjournal.com

within the normal range. Additionally, her hemoglobin (8.7 g/dL) and iron (56 mg/dL) levels were very low, and the LDH levels were increased significantly (2486 U/L). In fact, her AST (42.7 U/L) and ALT (U/L) levels were also high. She had been diagnosed with microangiopathic anemia due to prosthetic valvular leak. She needed more than 20 units of blood via transfusion in the last six months. Echocardiographic examination detected normal prosthetic aortic valve gradients (44/25 mmHg), increased prosthetic mitral valve gradients (23/13 mmHg) with moderate to severe mitral regurgitation (MR), moderate tricuspid regurgitation, and normal left ventricular (LV) systolic function. A real-time three-dimensional transesophageal echocardiography (RT-3D TEE) demonstrated three separate paravalvular defects in which two of them were like a slit and the third one was oval-shaped, between five and seven o'clock on a surgeon's view. From medial to lateral region, the first defect measured 5 mm, the second defect measured 8 mm, and the third defect measured 4 mm in diameter (Figure 1). The patient was evaluated in the cardiovascular council, and transapical paravalvular leak closure was considered because of the high operational risk.

The patient was taken to the catheterization laboratory and was intubated. The procedure was performed under TEE imaging. A surgical team performed lateral thoracotomy, and a 7F

sheath was placed through the LV apex to LV chamber. First, a left Amplatz 1 (AL 1) catheter and a 0.35 hydrophilic guidewire were crossed/passed through the most lateral defect. After crossing/passing through the defect on the hydrophilic guidewire, the 2D TEE imaging showed a quite mobile, fibrillar mass measuring 7 mm, which was considered as thrombus. The patient was heparinized while the team was paying attention to the activating clotting time, which was kept at 300-350 sec after a mutual decision. Then, a stiff wire and delivery catheter were advanced through the defect. AMPLATZER Vascular Plug (AVP) III measuring 6 x 3 mm was successfully placed into this defect. Consequently, the mid paravalvular defect was crossed again by the 0.35 guidewire and AL 1 catheter. The stiff wire and the delivery catheter were advanced through the mid paravalvular defect. AVP III measuring 10 x 5 mm was placed into this defect. However, TEE disclosed moderate regurgitation from the medial side of the defect. A 0.35 wire and AL 1 catheter were crossed/passed through this defect. Stiff guidewire and delivery catheter were advanced, and AVP III measuring 8 x 4 mm was placed into this mid paravalvular defect. The delivery catheter slipped between the two devices that were previously placed on TEE examination. The third device was placed over the defect and released successfully. Trace residual regurgitation was observed in the placement position of these three de-

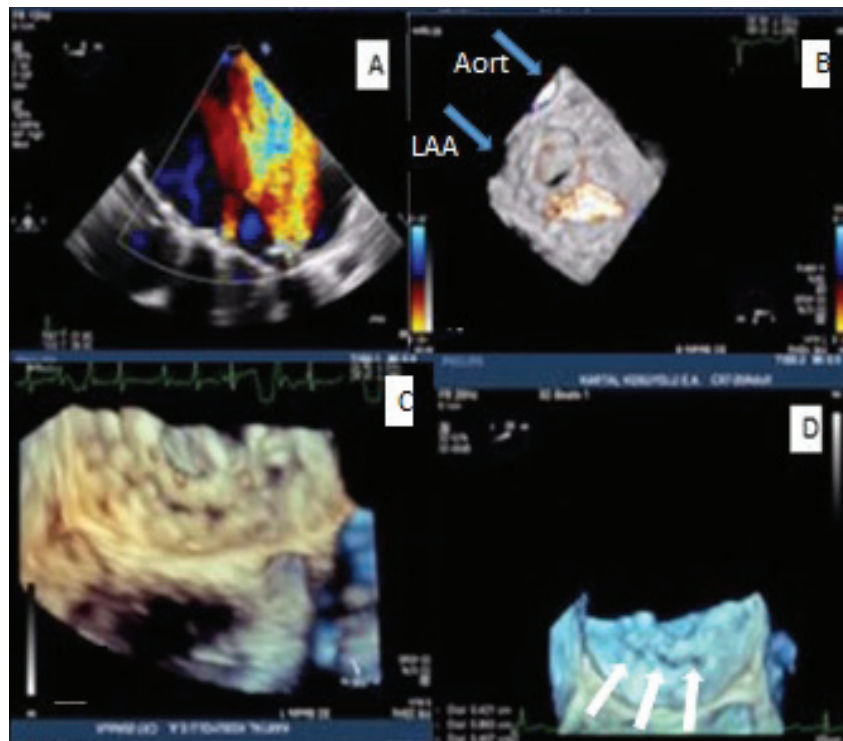


Figure 1. A: Severe mitral regurgitation is shown in two-dimensional (2D) color transesophageal echocardiography (TEE) images and B: in three-dimensional (3D) color TEE. The 3D TEE images of the three defects in (C) the anatomic position and in (D) the surgical position from medial to lateral side showed that the first defect had a size of 4-5 mm, the second defect had a size of 8 mm, and the third defect had a size of 3-5 mm.

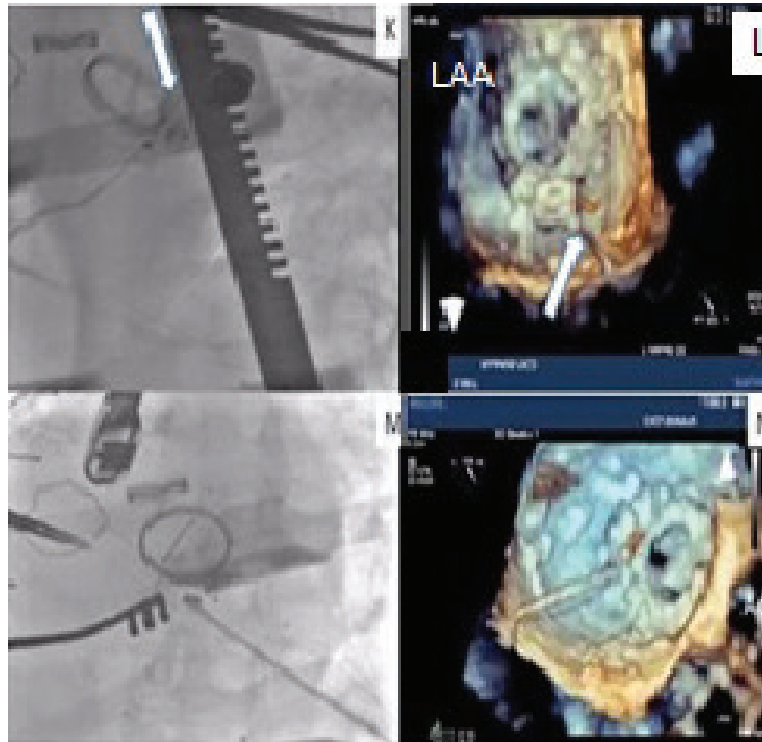


Figure 2. K, M: Angiographic images of the placement of the third device. L, N: Advanced 0.35 guidewire from the second defect after the second device was implanted.

vices (Figure 2). Finally, a 0.35 wire and AL 1 catheter were crossed/passed through the third defect. The stiff guidewire and delivery catheter were advanced, and AMPLATZER™ Duct Occluder (ADO) II device measuring 6 x 6 mm was deployed because of the oval shape of the defect. Immediately after the procedure, MR disappeared and severe spontaneous echocardiographic contrast was observed in the left atrium (Figures 3, 4). Three months after the procedure, there was a marked decrease in the LDH values (2486 U/L to 580 U/L), along with a marked increase in the hemoglobin levels (8.7 g/dL to 11.6 g/dL).

DISCUSSION

PVL is a rare but serious complication of surgical MVR. It is generally a consequence of suture dehiscence that lead to an incomplete apposition of the sewing ring to the native tissue⁽⁵⁾. Although surgical intervention is recommended in this case, the mortality rates are reported to be approximately 16%⁽⁵⁾. Transcatheter PVL closure has become an acceptable alternative to redo surgery in the symptomatic patients whose symptoms are related to regurgitation from the paravalvular defect^(6,7). The success of transcatheter mitral PVL closure varies with experience⁽²⁾. Transcatheter PVL closure can be performed antegradely or retrogradely via venous or arterial transfemoral access or transapical approach that may be performed with a small surgical incision with a limited exposure of the

left ventricle. This approach provides a more direct access to the therapeutic target irrespective of defect location⁽⁴⁾. Medial PVLs are particularly difficult for transcatheter closure; hence, this anatomic location requires a greater effort to access with the delivery systems that are not designed specifically for this purpose⁽⁵⁾. Taramasso et al found that a transcatheter closure via transapical approach appeared to be a safe and effective therapeutic option in selected high-risk patients with PVL and was associated with a lower hospital mortality than surgical treatment. The devices for the closure of other cardiovascular defects are used in an off-label fashion for PVL closure⁽²⁾. AVP III is preferable than AVP II because of a higher diameter of the middle module and significant elongation and protrusion of the AVP II after deployment⁽⁶⁾. In a prospective registry, Smolka et al showed that transcatheter PVL closure with a simultaneous deployment of multiple AVP III occludes was feasible with a success rate of 89.7% in mitral PVL with no significant periprocedural complications. In the majority of cases, the full occlusion was achieved with the use of up to four plugs⁽⁶⁾. We successfully treated three separate defects by using three AVP III and one ADO device. The defects were posteriorly located and relatively hard to reach via a transseptal approach. The transapical approach provides us with a direct access to the defects in a relatively short time.

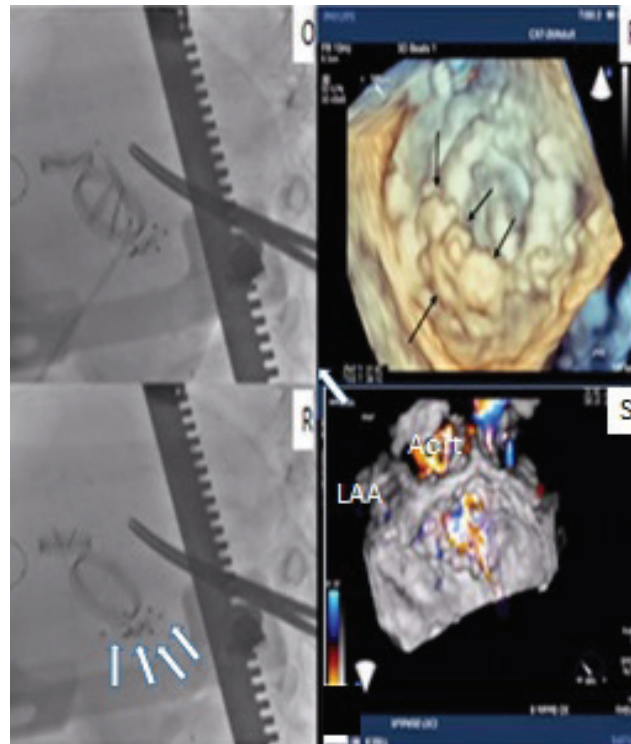


Figure 3. O, R: Angiographic images of the placement of the fourth device. (P) 3D transesophageal echocardiography (TEE) image and (S) color 3D TEE image of the fully closed paravalvular leaks after the implementation of fourth device (arrows).

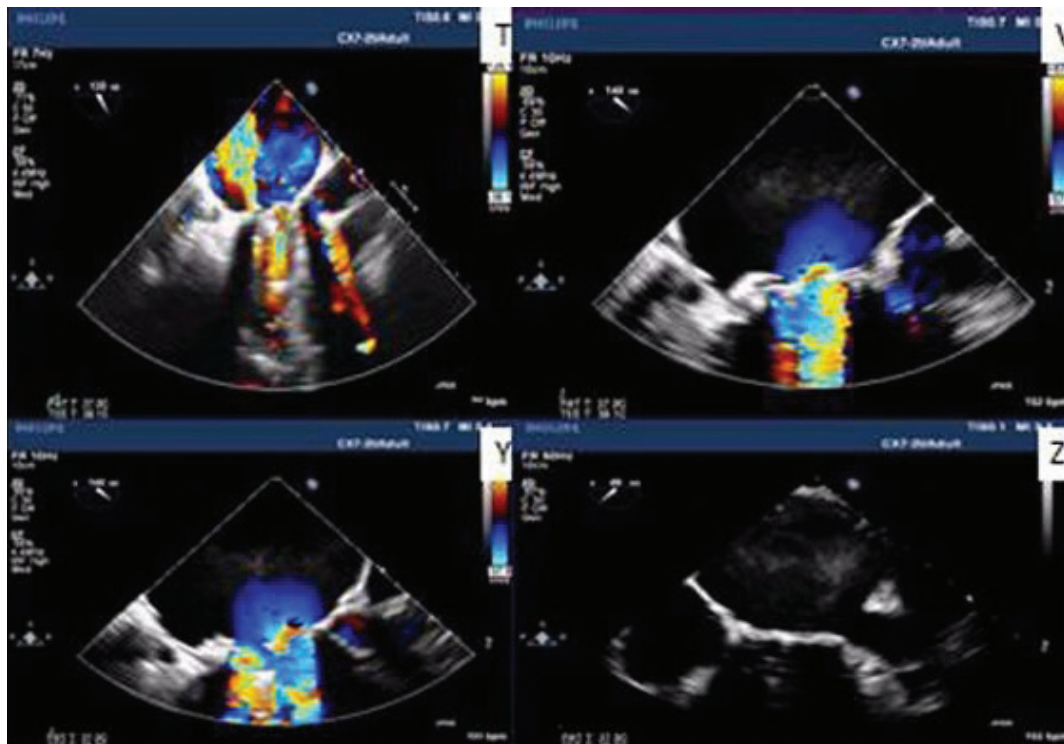


Figure 4. T: 2D color transesophageal echocardiography image of severe mitral regurgitation (MR); V and Y show no MR after the closure of paravalvular defects with four devices. Z: 2D transesophageal echocardiography image of spontaneous echocardiographic contrasting once the severe mitral regurgitation has disappeared.

One of the most important difficulties about transcatheter PVL closure is the adequate visualization of the defect⁽²⁾. We have used RT-3D TEE to define defect anatomy and guide transcatheter PVL closure. All 3D echocardiographic studies are performed using an iE33 ultrasound system (Philips Healthcare, Andover, Massachusetts). We also used 3D TEE to assess the device stability and interaction with the surrounding structures. RT-3D TEE provides us with the rapid assessment of the size, site and shape of the defect, and assessment of the regurgitation with the use of 3D full volume. Simultaneously, it also guides the wire for the delivery of catheter while facilitating the accurate positioning of the closure device⁽⁸⁾. In a prospective registry, all the cases of device failure were found to be related to the underestimation of PVL size caused by overextended and unpredicted compliance of the channel's surrounding tissue⁽⁶⁾. In our case, sizes and locations of defects along with the tissue that separate the defects into three parts were adequately visualized by 3D TEE.

In PVL closure, the residual shunts passing through the closure devices may have significant clinical consequences. It was reported that an incomplete prosthetic mitral PVL closure with an AMPLATZER™ Septal Occluder device having a residual shunt through the device caused significant hemolysis and pigment-induced nephropathy with renal failure after several weeks⁽²⁾. The complete closure of the defects is crucial in this patient because her symptoms were primarily related to hemolysis. The presence of regurgitation after device implantation could cause continuing or worsening of the hemolysis.

At the beginning of the procedure, after crossing through the first defect, a thrombus image was observed on 2D TEE, which was successfully managed. Whether the thrombus was newly formed or whether it was already present in the defect remains unknown.

CONCLUSION

Transapical approach is feasible in patients with a high operational risk for the closure of complex PVLs, which are localized posteriorly and/or medially, are difficult to reach, and may require multidevice intervention.

Informed Consent: Written informed consent was obtained from the patient who participated in this study.

Peer-review: Externally peer-reviewed.

Author Contributions: Concept/Design - All of authors; Analysis/Interpretation - All of authors; Data Collection - All of authors; Writing - All of authors; Critical Revision - All of authors; Final Approval - All of authors.

Conflict of Interest: The authors have no conflict of interest to declare.

Financial Disclosure: The authors declared that this study has received no financial support.

REFERENCES

1. Krishnaswamy A, Tuzcu EM, Kapadia SR. Percutaneous paravalvular leak closure. *Curr Treat Options Cardiovasc Med* 2013;15:565-74.
2. Kim MS, Casserly IP, Garcia JA, Klein AJ, Salcedo EE, Carroll JD. Percutaneous transcatheter closure of prosthetic mitral paravalvular leaks: are we there yet? *JACC Cardiovasc Interv* 2009;2:81-90.
3. Gürsoy OM, Astarcioglu MA, Gökdeniz T, Aykan AC, Bayram Z, Cakal B, et al. Severe mitral paravalvular leakage: echo-morphologic description of 47 patients from real-time three-dimensional transesophageal echocardiography perspective. *Anadolu Kardiyol Derg* 2013;13:633-40.
4. Taramasso M, Maisano F, Latib A, Denti P, Guidotti A, Sticchi A, et al. Conventional surgery and transcatheter closure via surgical transapical approach for paravalvular leak repair in high-risk patients: results from a single-centre experience. *Eur Heart J Cardiovasc Imaging* 2014;15:1161-7.
5. Yuksel UC, Tuzcu EM, Kapadia SR. Percutaneous closure of a posteromedial mitral paravalvular leak: the triple telescopic system. *Catheter Cardiovasc Interv* 2011;77:281-5.
6. Smolka G, Pysz P, Jasinski M, Roleder T, Peszek-Przybyła E, Ochala A, et al. Multiplug paravalvular leak closure using Amplatzer Vascular Plugs III: a prospective registry. *Catheter Cardiovasc Interv* 2016;87:478-87.
7. Calvert PA, Northridge DB, Malik IS, Shapiro L, Ludman P, Qureshi SA, et al. Percutaneous device closure of paravalvular leak: combined experience from the United Kingdom and Ireland. *Circulation* 2016;134:934-44.
8. Ozkan M, Gürsoy OM, Astarcioglu MA, Wunderlich N, Sievert H. Percutaneous closure of paravalvular mitral regurgitation with Vascular Plug III under the guidance of real-time three-dimensional transesophageal echocardiography. *Turk Kardiyol Dern Ars* 2012;40:632-41.