





Permanent hemodialysis catheter tip detected in the right atrium: A case report

SAĞ ATRİUMDA TESPİT EDİLEN KALICI HEMODİYALİZ KATETER UCU: OLGU SUNUMU

 Mehmet Şerif ALP¹,  Ebru ÇANAKÇI¹,  İlker COŞKUN¹,  Ahmet KARATAŞ²

¹Ordu Üniversitesi, Tıp Fakültesi, Anestezi ve Reanimasyon AD, Ordu

²Ordu Üniversitesi, Tıp Fakültesi, İç Hastalıkları AD, Nefroloji BD, Ordu

ABSTRACT

Vascular access routes and types and complications of them are among the most important factors affecting morbidity, mortality and health expenditures in hemodialysis patients. A 59-year-old female patient had CKD for 5 months. Since the catheter did not work, the permanent catheter was removed by the cardiovascular surgeon and a temporary HD catheter was inserted through the jugular vein. A foreign body was noticed in the right atrium in the postero-anterior chest X-ray. It was noticed that the foreign body was the tip of the permanent catheter that was removed. The foreign body was removed by non-invasive methods using endovascular forceps under local anesthesia by cardiovascular surgery. It may be a rational approach to confirm that catheter is completely removed by using imaging methods. The aim of this case report was to present the complications that occur during the removal of HD catheters in the light of the literature.

Keywords: foreign body, right atrium, hemodialysis, catheter, complication

ÖZ

Vasküler giriş yolları, tipleri ve yol açtıkları komplikasyonlar, hemodiyaliz hastalarında morbiditeyi, mortaliteyi ve sağlık harcamalarını etkileyen en önemli etkenlerdendir. Elli dokuz yaşında bayan hasta, yaklaşık 5 aydır KBY mevcut idi. Kateterinin çalışmaması üzerine kalp damar cerrahisi tarafından kalıcı kateteri çekilmiş, juguler venden geçici HD kateteri takılmış idi. Hasta kateter çekilmesinden sonra çekilen P-A akciğer grafisinde sağ atriumda yabancı cisim fark edilmesi üzerine hastanemize yeniden geri gönderildi. Yabancı cismin hastanın çıkarılan kalıcı kateterinin ucu olduğu fark edildi ve kalp damar cerrahisi tarafından lokal anestezi altında endovasküler forseps kullanılarak noninvaziv yöntemle çıkarıldı. Görüntüleme yöntemlerini kullanarak kateterin tam olarak çıktığının teyit edilmesi akılcı bir yaklaşım olabilir. Bu olgu sunumundaki amacımız, HD kateteri çekilmesi sırasında oluşan komplikasyonları literatür eşliğinde sunmaktır.

Anahtar Sözcükler: yabancı cisim, sağ atrium, hemodiyaliz, kateter, komplikasyon

Ebru ÇANAKÇI

Ordu Üniversitesi Tıp Fakültesi

Anestezi ve Reanimasyon AD.

Eğitim ve Araştırma Hastanesi

52200 ORDU

 orcid.org/0000-0003-2093-9229

Hemodialysis is usually performed through surgically created arteriovenous fistulas (AVF) or HD catheters (1). Hemodialysis (HD) catheters are vital tools for patients with chronic renal failure (CKD); they provide vascular access in the short-term and can also be used subsequently. There are two types of HD catheters, permanent and temporary (2). The most important factor that determines whether the catheter to be inserted is temporary or permanent is the expected duration of catheter use. Permanent HD catheters should be preferred in cases where long-term catheter use is required, since use of temporary HD catheters longer than 3-4 weeks increases the rate of complications (3). The most important one among the basic indications of use of HD catheters, whether temporary or permanent, is the urgent need for HD. Permanent HD catheters are ideal catheters for longer use when there is no chance to create an arterio-venous fistula (AVF) or AVF is contraindicated (advanced heart failure, peripheral artery disease or short life expectancy) (4). The rate of tunneled or non-tunneled catheter use in patients with CKD is 18% (5).

Vascular access routes and types and complications of them are among the most important reasons affecting morbidity, mortality and health expenditures in hemodialysis patients.

The aim of this case report was to present the complications that occur during the removal of HD catheters in the light of the literature.

CASE

A 59-year-old female patient had hypertension for about 3 years. She had a newly diagnosed Alzheimer's type dementia disease. In order to publish this article, informed consent was obtained from relatives of the case. She was using regular medication due to hypertension. Her general condition was moderate. Auscultation revealed decreased respiratory sounds in bilateral basal lungs. There was no pretibial edema in either leg. Biochemical values were as follows: creatinine: 5.26 mg/dL, K: 4.47 meq/dL, and Na: 147meq/dL. She was on HD 3 times a week for 5 months due to CKD. A permanent hemodialysis catheter was inserted 3 months ago by a cardiovascular surgeon through the right subclavian vein for HD. Since the catheter did not

work, echocardiography was performed and thrombus was detected at the catheter tip. Catheter tip was seen reaching in the right ventricle. The catheter tip did not cause any damage to the tricuspid valve. The permanent catheter was removed by the cardiovascular surgeon and a temporary HD catheter was inserted through the left jugular vein to continue HD on the same day. The patient was sent back to the center she was being followed-up since the HD was successful. The patient was sent back to our hospital 6 days after catheter removal, after a foreign body was noticed in the right atrium on the postero-anterior chest radiograph (PA-AC radiograph), which was obtained due to symptoms such as tachycardia, arrhythmia and hypertension. The PA-Chest X-ray is shown in Figure 1. On the PA-Chest X-ray obtained in our hospital, it was noticed that the foreign body in the right atrium was the tip of the permanent catheter that was removed by non-invasive methods under local anesthesia by cardiovascular surgery team using endovascular forceps. The patient was followed-up in the intensive care unit for 2 days. After removal of the catheter tip, the patient's tachycardia, arrhythmia and hemodynamia was improved. PA-AC radiography after the catheter tip removal is shown in Figure 2. The patient with a normotensive course was discharged home in good health at the end of the 2nd day.

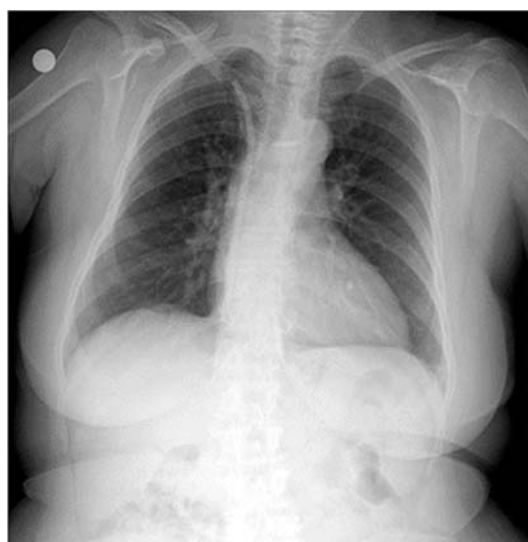

Figure 1. Permanent catheter tip remaining in the right atrium

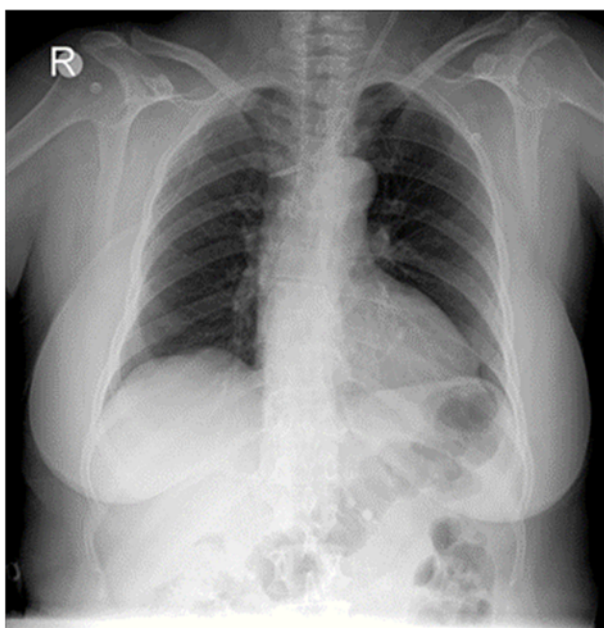


Figure 2. PA-Chest X-ray after catheter tip removal

DISCUSSION

Hemodialysis catheters are generally used to provide vascular access for HD until the use of permanent AV fistulas is possible. The advantages of these catheters are that they provide high volume blood flow, can be used for dialysis immediately after the procedure, cause less pain during use, and provide long-term vascular access (1). The most important disadvantages are their complications. Main complications are infection, dysfunction, stenosis in venous structures and thrombosis (2). A rare complication, as seen in our case is breaking off the catheter during its removal (9). Complicated cases have been reported in which the HD catheter is forgotten in the vascular area and removed under general anesthesia using various methods such as vein exploration, laparotomy, thoracotomy or under local anesthesia using a Dormier basket and endovascular forceps by noninvasive methods. In these cases, it was pointed out that carelessness, inexperience, hastiness, fatigue, multiple failed interventions and inadequate supervision by experienced clinicians may be the reasons that explain leaving the ruptured part of the catheter in the vascular area (10). The increased experience of the clinician performing the procedure reduces the

complication rate by half in catheter applications, and three or more unsuccessful attempts increase the complication rate by six times (11). In our case, the severed part of the catheter was removed by the cardiovascular surgeon using endovascular forceps without the need for an open surgery.

In the case report presented by Akçay et al., the catheter reached the right ventricular apex. Similarly, as in our case, they did not detect any damage to the tricuspid valve. Authors said that, echocardiography is the most frequently used imaging modality for assessment of intracardiac mass and it allows characterization of mass (location, attachment, shape, size and mobility)(12). In a study conducted by Dilek et al., 50 patients were included in the study and catheter-related thrombus was detected in 9 patients (18%). The duration of catheterization in patients with or without thrombus was 24.66 ± 22.62 months and 18.02 ± 15.54 months, and there was no significant difference in duration of catheterization between the two groups. The study conducted by Dilek et al. shows more common atrial thrombus among female and diabetic patients compared to male and nondiabetic patients, but there were not any statistical significance. The authors stated that this situation may be related to the low number of cases. (13).

Among the studies on permanent HD catheters in the literature, Develter et al, in a 11-year study evaluated 245 patients with permanent HD catheters. The site of insertion of the catheters was right jugular vein, left jugular vein and other veins in 60%, 16% and 24%, respectively. Mean duration of catheter patency was reported to be 276 days. The longest catheter patency rate was found in catheters inserted through the right jugular vein. In this present case, the catheter was placed in the right subclavian vein. The catheter was operating for approximately 3 months. The catheter was removed by a cardiovascular surgeon working at this center and a temporary hemodialysis catheter was placed since the catheter didn't work after 3 months. In this present case, a complication of catheter rupture was developed during the withdrawal of the catheter. This rare complication of rupture supposedly occurs due to entrapment of the catheter between the first rib and the clavicle (14). Another late complication of permanent HD catheters is catheter thrombosis.

Coagulation and insufficient flow is a quite common problem and is more common in catheters placed on the left side. Jean et al. evaluated 125 patients with CRF in their study and analyzed two different types of permanent dialysis catheters inserted in their patients. They found the one-year patency rate as 53% and the rate of catheter thrombosis as 20.9% (15). In this present case, no catheter dysfunction due to thrombosis of the catheter was the point in question.

In conclusion, use of permanent tunneled HD catheters with a lower rate of complications compared to permanent HD catheters is a good choice in patients who require HD and are anticipated to be on HD for more than four weeks. The most important factors that determine the life of permanent HD catheters are the location of insertion and the complications of the catheter. Choosing primarily the right jugular vein and US-scopy when placing the catheters and a good catheter care prolong the life of the catheter. In addition, the patient and HD unit employees should take care of the catheter at all times in order to prolong the life of the catheter. The care taken while the catheter is inserted should be shown exactly when the catheter is removed. Removal should not be forceful. One needs to make sure that the catheter is completely removed. Using imaging methods might be wise approach to confirm this.

REFERENCES

1. El Minshawy O, Abd El Aziz T, Abd El Ghani H. Evaluation of vascular access complications in acute and chronic hemodialysis. *J Vasc Access*. 2004;5:76-82.
2. Karakaya D, Baris S, Güldogus F, Incesu L, Sarihasan B, Tür A. Brachial plexus injury during subclavian vein catheterization for hemodialysis. *J Clin Anesth*. 2000;12:220-3.
3. Weijmer MC, Vervloet MG, ter Wee PM. Compared to tunnelled cuffed haemodialysis catheters, temporary untunnelled catheters are associated with more complications already within 2 weeks of use. *Nephrol Dial Transplant*. 2004;19:670-7.
4. Droll KP, Lossing AG. Carotid-jugular arteriovenous fistula: case report of an iatrogenic complication following internal jugular vein catheterization. *J Clin Anesth*. 2004;16:127-9.
5. Registry of The Nephrology, Dialysis and Transplantation In- Turkey, Registry 2015, The Turkish Society of Nephrology. Ankara 2016.
6. Dhingra RK, Young EW, Hulbert-Shearon TE, Leavey SF, Port FK: Type of vascular Access and mortality in US hemodialysis patients. *KidneyInt*. 2001; 60: 1443-51.
7. Pastan S, Soucie JM, McClellan WM: Vascular Access and increased risk of death among hemodialysis patients. *Kidney Int*. 2002; 62:620-6.
8. Astor BC, Eustace JA, Powe NR, Klag MJ, Fink NE, Coresh J: Type of vascular Access and survival among incident hemodialysis patients: The Choices for Healthy Outcomes in Caring for ESRD (CHOICE) Study. *J Am Soc Nephrol*. 2005;16:1449-55.
9. Fisher R, Ferreyro R. Evaluation of current techniques for nonsurgical removal of intravascular iatrogenic foreign bodies. *Am J Roentgenol*. 1978;130:541-8.
10. Kusminsky RE. Complications of central venous catheterization. *J Am Coll Surg*. 2007;204:681-96.
11. Taylor RW, Palagiri AV. Central venous catheterization. *Crit Care Med*. 2007;35:1390-6.
12. Akçay M, Deşer SB, Gedikli Ö, Yüksel S, Gülel O. Successful management of complications after inappropriate positioning of a hemodialysis catheter. *Anatol J Cardiol*. 2017;18:E7-8.
13. Dilek M, Kaya C, Karatas A, Ozer I, Arık N, Gülel O. Catheter-related atrial thrombus: tip of the iceberg? *Ren Fail*. 2015;37:567-71.
14. Develter W, De Cubber A, Van Biesen W, Vanholder R, Lameire N. Survival and complications of indwelling venous catheters for permanent use in hemodialysis patients. *Artif Organs*. 2005;29:399-405.
15. Jean G, Charra B, Chazot C, Vanel T, Terrat JC, Hurot JM. Long-term outcome of permanent hemodialysis catheters: A controlled study. *Blood Purif* 2001;19:401-7.