

Torticollis due to aneurysmal bone cyst located in the thoracic vertebrae: A case report

Torasik vertebrada bulunan anevrizmal kemik kistine bağı tortikollis: Olgu sunumu

Ali Şahin¹, Ayşe Kaçar Bayram², Abdulfettah Tümtürk³, Hüseyin Per⁴, Ali Kurtsoy³

¹ Department of Neurosurgery, Kayseri City Education and Research Hospital, Kayseri, Turkey

² Department of Pediatrics, Division of Pediatric Neurology, Kayseri City Education and Research Hospital, Kayseri, Turkey

³ Department of Neurosurgery, Erciyes University, Faculty of Medicine, Kayseri, Turkey

⁴ Department of Pediatrics, Division of Pediatric Neurology, Erciyes University, Faculty of Medicine, Kayseri, Turkey

ORCID ID of the author(s)

AS: 0000-0001-7231-2394
AKB: 0000-0003-0261-9336
AT: 0000-0001-5883-9819
HP: 0000-0001-9904-6479
AK: 0000-0002-5777-8871

Corresponding author / Sorumlu yazar:
Ali Şahin

Address / Adres: Kayseri Şehir Eğitim ve Araştırma Hastanesi Nöroşirürji Kliniği, Kayseri, Türkiye

E-mail: dralishn@gmail.com

Informed Consent: The authors stated that the written consent was obtained from the parents of the patient presented with images in the study. Hasta Onamı: Yazarlar çalışmada görüntüleri ile sunulan hastanın ebeveynlerinden yazılı onam alındığını ifade etmiştir.

Conflict of Interest: No conflict of interest was declared by the authors.

Çıkar Çatışması: Yazarlar çıkar çatışması bildirmemişlerdir.

Financial Disclosure: The authors declared that this study has received no financial support.

Finansal Destek: Yazarlar bu çalışma için finansal destek almadıklarını beyan etmişlerdir.

Published: 9/30/2020
Yayın Tarihi: 30.09.2020

Copyright © 2020 The Author(s)
Published by JOSAM

This is an open access article distributed under the terms of the Creative Commons Attribution-Non Commercial-NoDerivatives License 4.0 (CC BY-NC-ND 4.0) where it is permissible to download, share, remix, transform, and build upon the work provided it is properly cited. The work cannot be used commercially without permission from the journal.



Abstract

Aneurysmal bone cyst is a benign, tumor-like, highly vascular, locally aggressive and relatively rare osteolytic lesion of unknown etiology. Aneurysmal bone cysts of the spine account for 12%–30% of all aneurysmal bone cyst cases. They mostly occur in the lumbar vertebrae, followed by the thoracic, cervical, and sacral vertebrae. Torticollis, a condition characterized by an abnormal tilted position, rotation, and flexion of the head and neck is considered a sign rather than a specific diagnosis. To our knowledge, the presentation of torticollis in children with aneurysmal bone cysts in the thoracic vertebrae has not been reported in the literature. We should keep in mind that acquired torticollis can be a sign of underlying life-threatening conditions. Here we present the case of a 9-year-old boy with muscle spasm, progressively increasing pain, and right torticollis (lasting for 45 days) who presented to the emergency department with paraplegia.

Keywords: Aneurysmal bone cyst, Torticollis, Acute paraplegia, Children

Öz

Anevrizmal kemik kisti, etiyojisi bilinmeyen, iyi huylu, tümör benzeri, oldukça vasküler, lokal olarak agresif ve nispeten nadir osteolitik bir lezyondur. Omurganın anevrizmal kemik kistleri, tüm anevrizmal kemik kisti vakalarının% 12 ila 30'unu oluşturur. Çoğunlukla lomber vertebralarda, ardından torasik, servikal ve sakral vertebralarda görülürler. Doğal olmayan bir baş ve boyun eğik pozisyonu, rotasyonu ve fleksiyonu olan tortikollis, spesifik bir tanıdan çok bir işaret olarak kabul edilir. Bildiğimiz kadarıyla, literatürde, çocuklarda torasik vertebrada oluşan anevrizmal kemik kistleri tortikollis ile birlikte bildirilmemiştir. Edinilmiş tortikollisin altta yatan yaşamı tehdit eden koşulların bir işareti olabileceğini aklımızda tutmalıyız. Bu rapor, acil servise parapleji ile başvuran; kas spazmı, giderek artan ağrı ve 45 gündür süren sağ tortikollisi olan 9 yaşında bir erkek çocuğu tanımlamaktadır.

Anahtar kelimeler: Anevrizmal kemik kisti, Tortikollis, Akut parapleji, Çocuklar

Introduction

Aneurysmal bone cysts (ABCs) are rare benign bone tumors that were first described by Jaffe and Lichtenstein in 1942 [1]. ABC is the third most common benign bone tumor after osteoid osteoma and osteoblastoma; however, ABCs are relatively uncommon with annual incidences ranging from 1.4 to 3.2 cases per million people [2].

ABCs of the spine account for approximately 10%–30% of all ABC cases and approximately 10%–20% of all spinal tumors [3]. ABC occurs as a primary lesion in 70% of cases, whereas it is associated with other bone diseases (chondroblastoma, giant cell tumor, telangiectatic osteosarcoma, osteoblastoma) in 30% of cases [4]. Despite being benign, ABCs can be locally expansive and destructive and can lead to pathological fractures of the vertebrae and neurological complications [3,4].

The most common complaint associated with ABCs is pain; it occurs especially at night and is localized to the site of the lesion. Neurological symptoms are present if the lesion encroaches on the nerve roots or spinal cord. Neurological involvement is uncommon but can manifest as paraplegia, cord compression and cauda equina syndrome. Thus, to prevent disabling neurological sequelae, early recognition and treatment of ABCs is necessary [5-7].

Direct radiographs, computed tomography (CT) and magnetic resonance imaging (MRI) are helpful in diagnosis. An expansile osteolytic cavity on direct radiographs as well as fluid levels seen on both CT and MRI are pathognomonic [6,7].

Torticollis, a condition characterized by an abnormal tilted position, rotation, and flexion of the head and neck, is considered a sign rather than a specific diagnosis. Torticollis can be congenital or acquired in childhood. The underlying causes of torticollis in children can vary from relatively benign to life-threatening conditions [8-10]. Torticollis due to ABCs is rare [11,12] and mostly occurs in cases of ABCs located in the cervical vertebrae. However, to our knowledge, the presentation of torticollis in children with ABCs in the thoracic vertebrae has not been reported in the literature.

Here we describe the case of a 9-year-old boy with muscle spasm, progressively increasing pain, and right torticollis (lasting for 45 days) who presented to the emergency department with paraplegia.

Case presentation

A 9-year-old boy presented to our hospital with acute weakness in the bilateral lower limbs and painful torticollis. He had no history of trauma and systemic illness. He had been treated with physical therapy including hot pack therapy and home stretching exercises for 45 days. He developed abnormal head posture and started experiencing neck pain 45 days prior to admission. The pain was severe enough to disturb his sleep; furthermore, the patient had painful torticollis unresponsive to conservative therapy, which included naproxen medication. He was admitted with the complaints of bilateral lower limb weakness, inability to walk and painful torticollis lasting for 2 days.

On physical examination, while the patient's head turned to the left, his jaw turned to the right (Figure 1). The patient had back pain and scoliosis with torticollis. Muscle strength was 2/5 in the bilateral lower extremities. Deep tendon reflexes were exaggerated, with positive bilateral Babinski sign.

Spinal MRI showed a large cystic lesion arising from the posterior parts of the vertebrae, with fluid levels causing prominent mass effect on the spinal cord at T4-5 level (Figure 2a, 2b). Histopathological examination revealed an aneurysmal bone cyst. The patient underwent emergency surgery; total tumor resection was performed, and no postoperative complications were observed. After the surgery, the patient immediately recovered from the neck pain. In the first 24 h, the patient started walking using a crutch and his torticollis improved. On the 15th postoperative day, the patient started walking without support and his focal neurological deficit improved. No signs or symptoms of neurological dysfunction were observed in the 1-year postoperative follow-up visit.

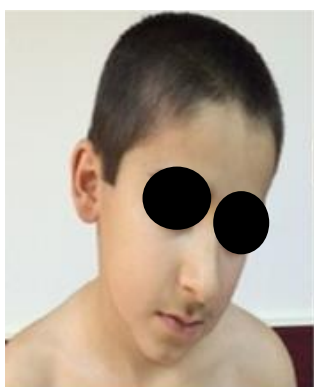

Figure 1: Torticollis view of the patient before surgery

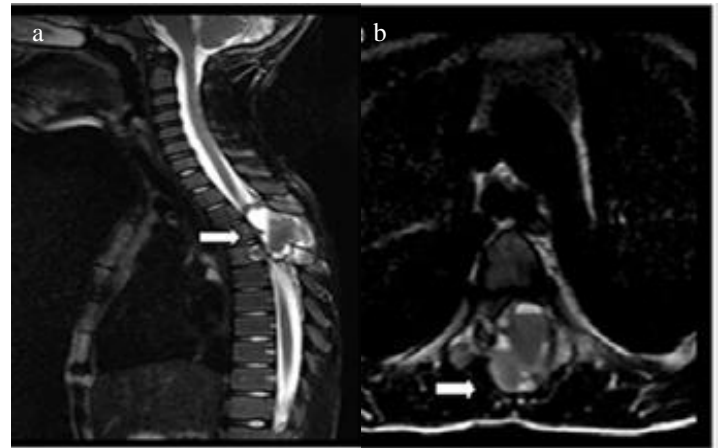


Figure 2: Sagittal (a) and axial (b) spinal MRI show a large cystic lesion arising from posterior parts of vertebrae with fluid levels causing prominent mass effect to the spinal cord at T4-5 level.

Discussion

ABC is a benign, tumor-like, highly vascular, locally aggressive, and relatively rare osteolytic lesion of a completely unknown etiology. The following causes have been suggested for ABC development: Vascular disturbances of the bone, hemorrhage into a preexisting lesion and improper repair of a traumatic subperiosteal hemorrhage [3]. Most patients are aged <20 years, and slight female predominance has been observed [2]. In our patient, the tumor had appeared in the first decade.

Primary ABCs represent 1.4% of all primary bone tumors. The lesions are usually present in the long bones, particularly the humerus, femur, tibia and fibula and the vertebral column. In the vertebral column, the lesions mostly occur in the lumbar vertebrae, followed by the thoracic, cervical, and sacral vertebrae [13]. The posterior elements of the vertebrae (lamina, pedicle, facet joints) are more frequently affected, and the lesions may also spread to the nearby vertebrae and costa through the facet joints and intervertebral disc [4], like in our patient, in which a similar tumor was detected in the T4-T6 segment.

Despite being benign, ABCs can result in pathological fractures of the vertebrae and neurological complications and can be locally expansive and destructive. Neurologic symptoms are observed when the lesion encroaches on the nerve roots or spinal cord. A palpable mass may be present in the posterior elements, and tenderness may be elicited. The most common complaint of patients with ABC is back pain and a palpable mass [6,14]. Our patient presented to the hospital with complaints of acute weakness in the bilateral lower limbs and painful torticollis. Two days before the presentation, he had developed acute paraplegia due to spinal cord compression. Thus, delay in the diagnosis and treatment of patients with ABC may result in the development of acute paraplegia.

More than 80 different causes of torticollis have been described; it is observed in childhood with an estimated incidence of 1.3% [15]. The differential diagnosis of torticollis in children is wide, extensive and includes all systems. The differential diagnosis in children with acquired torticollis is common because of the wide range of underlying trauma, infection, ligamentous inflammatory, vascular, muscular, drug reactions, osseous, ocular, psychiatric, and neurologic disorders [8-10]. The underlying central nervous system pathologies can originate from three main regions: Brain, spinal cord, and spinal

nerve root/peripheral nerve. Delay in the diagnosis in case of pathologies arising from these regions may lead to progressive neurological deterioration and an increase in the tumor size. However, early diagnosis of these disorders helps reduce mortality and morbidity. In our patient, the diagnosis of ABC in the thoracic region was delayed. If torticollis had been detected earlier and spinal imaging performed, the patient would not have come to hospital in a severe condition. Pediatric clinicians and neurosurgery practitioners must be aware of the exaggeration of this warning sign.

The treatment of ABC is controversial; treatment options include curettage with or without bone grafting, complete excision, arterial embolization, intralesional drug injections, chemotherapy, and radiation [6,7]. Surgical treatment is the first choice in cases with pathological fractures or spinal instability or symptomatic cord compression [6,7]. Early diagnosis and appropriate surgical treatment of ABCs in the spine remain the key factors to successful management [7]. Our patient underwent emergency surgery with total tumor resection. No postoperative complications were observed. The patient immediately recovered from neck pain, torticollis, and inability to walk after the surgery. No signs or symptoms of neurological dysfunction were observed in the postoperative 1-year follow-up.

Conclusion

In this report, we presented a case of torticollis caused by an ABC in the thoracic vertebrae. It is noteworthy that acquired torticollis can be a sign of underlying life-threatening conditions and requires an extensive multidisciplinary approach.

References

- Jaffe HL, Lichtenstein L. Solitary unicameral bone cyst. *Arch Surg.* 1942;44:1004-25.
- Leithner A, Windhager R, Lang S, Haas OA, Kainberger F, Kotz R. Aneurysmal bone cyst. A population based epidemiologic study and literature review. *Clin Orthop Relat Res.* 1999;363:176-9.
- Boriani S, De Iure F, Campanacci L, Gasbarrini A, Bandiera S, Biagini R, et al. Aneurysmal bone cyst of the mobile spine: report on 41 cases. *Spine (Phila Pa 1976).* 2001;26:27-35. doi: 10.1097/00007632-200101010-00007
- Barbanti-Brodano G, Girolami M, Ghermandi R, Terzi S, Gasbarrini A, Bandiera S, et al. Aneurysmal bone cyst of the spine treated by concentrated bone marrow: clinical cases and review of the literature. *Eur Spine J.* 2017;26(1):158-66. doi: 10.1007/s00586-017-4978-x
- Mesfin A, McCarthy EF, Kebaish KM. Surgical treatment of aneurysmal bone cysts of the spine. *Iowa Orthop J.* 2012;32:40-5.
- Zhao Y, He S, Sun H, Cai X, Gao X, Wang P, et al. Symptomatic aneurysmal bone cysts of the spine: clinical features, surgical outcomes, and prognostic factors. *Eur Spine J.* 2019;28(6):1537-45. doi: 10.1007/s00586-019-05920-7
- Zileli M, Isik HS, Ogut FE, Is M, Cagli S, Calli C. Aneurysmal bone cysts of the spine. *Eur Spine J.* 2013;22(3):593-601. doi: 10.1007/s00586-012-2510-x
- Tumturk A, Kaya Ozcora G, Kacar Bayram A, Kabaklioglu M, Doganay S, Canpolat M, et al. Torticollis in children: an alert symptom not to be turned away. *Childs Nerv Syst.* 2015;31(9):1461-70. doi: 10.1007/s00381-015-2764-9
- Per H, Canpolat M, Tumturk A, Gumus H, Gokoglu A, Yikilmaz A, et al. Different etiologies of acquired torticollis in childhood. *Childs Nerv Syst.* 2014;30(3):431-40. doi: 10.1007/s00381-013-2302-6
- Tomczak KK, Rosman NP. Torticollis. *J Child Neurol.* 2013;28(3):365-78. doi: 10.1177/0883073812469294
- Mishra A, Pruthi N, Nandeesh BN, Shukla D. Cervical Spine Osteoblastoma with an Aneurysmal Bone Cyst in a 2-Year-Old Child: A Case Report. *Pediatric Neurosurgery.* 2019;54(1):46-50. doi: 10.1159/000495065
- Karampalis C, Lenthall R, Boszczyk B. Solid variant of aneurysmal bone cyst on the cervical spine of a child: case report, differential diagnosis and treatment rationale. *Eur Spine J.* 2013;22(3):523-31. doi: 10.1007/s00586-012-2548-9
- Hay MC, Paterson D, Taylor TK. Aneurysmal bone cysts of the spine. *J Bone Joint Surg Br.* 1978;60:406-11.
- Benayada B, Allali N, Sefiani S, Arkha Y, Dafiri R. Aneurysmal bone cyst: A rare cause of medullary compression and painful scoliosis in children. *Presse Med.* 2010;39(7-8):837-40. doi: 10.1016/j.lpm.2010.01.008
- Cheng JCY, Au AWY. Infantile torticollis: a review of 624 cases. *J Pediatr Orthop.* 1994;14:802-8.

This paper has been checked for language accuracy by JOSAM editors.

The National Library of Medicine (NLM) citation style guide has been used in this paper.