

Thoracic outlet syndrome: efficiency of surgery

Torasik Outlet Sendromunda Cerrahi Tedavinin Etkinliği

Oktay Aslaner^{1*}

¹.Department of Thoracic Surgery, Alanya Alaaddin Keykubat University, School of Medicine, Alanya, Turkey

ABSTRACT

Aim: In this study, we aimed to evaluate the effectiveness of surgical treatment in patients diagnosed with thoracic outlet syndrome.

Patients and Methods: This study was conducted by analyzing the age, sex, occupational distribution, anamnesis and physical examination findings, symptoms, preoperative examinations, operation findings, postoperative complications, postoperative hospital stay and operation results of thirty seven patients who were diagnosed with Thoracic Outlet Syndrome, and were operated on between 1991 and 2004.

Results: Most of the patients were in the 15-35 age group (72.97%) and female (91.9%). Most of these cases were housewives (51.4%). The most common symptoms were pain (94.6%) and numbness (78.4%). The most commonly used test in physical examination was the Adson test, which provided an 86% positive rate. The most common pathology encountered in radiological tests was cervical rib anomaly (37.8%). It was found that EMG of upper extremity supported TOS with a rate of 48.6% and arterial doppler of upper extremity supported TOS with a rate of 13.5%. We applied first rib and cervical rib resection scalenectomy and cutting of fibromuscular bands as a surgery by transaxillary approach. A 78.4% complete recovery was observed in the early period after surgery and there was no mortality in any of the cases.

Conclusion: In this study, the results were satisfactory in TOS patients on suitable cases and with good surgical technique. Surgical success rate can reach up to 97%.

Key Words: thoracic outlet syndrome, cervical costa, transaxillary approach.

ÖZ

Amaç: Bu çalışmada, Torasik outlet sendromu tanısı konulan hastalarda cerrahi tedavinin etkinliğini değerlendirmeyi amaçladık.

Hastalar ve Yöntem: 1991 ile 2004 yılları arasında Torasik Outlet Sendromu tanısı almış ve tedavi yöntemi olarak cerrahi uygulanmış otuz yedi olgunun yaş, cins, meslek dağılımı, anamnez ve fizik muayene bulguları, semptomları, preoperatif tetkikleri, operasyon bulguları, postoperatif komplikasyonları, postoperatif hastanede kalış süreleri ve operasyon sonuçları incelenerek yapıldı.

Bulgular: Olguların çoğu 15-35 yaş grubunda (% 72.97) ve kadınlardan (% 91.9) oluşmaktaydı. Bu olguların çoğu ev hanımıydı (% 51.4). En sık rastlanılan semptomlar ağrı (%94,6) ve uyuşma (% 78.4) idi. Fizik muayenede en sık kullanılan test Adson testi idi. Adson testi %86 oranında pozitif bulundu. Radyolojik testlerde en sık karşılaşılan patoloji servikal kosta anomaliydi (% 37.8). üst ekstremité EMG sinin %48.6, üst ekstremité arteriel dopplerinde% 13.5 oranında TOS u desteklediği bulundu. Cerrahide transaksiller girişim ile birinci kosta ve servikal kosta rezeksiyonu. skalenektomi fibromusküler bantların kesilmesi işlemlerini uyguladık. Cerrahiden sonra erken dönemde %78.4 oranında tam düzelme görüldü. Olguların hiçbirinde mortalite olmadı.

Sonuç: Bu çalışmada TOS hastalarda, uygun olgularda ve iyi cerrahi teknik ile sonuçlar tatmin edici bulundu. Cerrahi başarı oranı %97 lere kadar çıkabilmektedir.

Anahtar kelimeler: Torasik Outlet Sendromu, Servikal Kosta, Trnsaksiller yaklaşım.

Received: 10.09.2020 Accepted: 28.09.2020 Published (Online):29.10.2020

*Corresponding author: Oktay Aslaner. Alanya Alaaddin Keykubat University, School of Medicine, Department of Thoracic Surgery, Alanya, Turkey. Tel:+90 541 974 0207 e-mail: oktay.aslaner@alanya.edu.tr

ORCID: 0000-0002-2952-6677

To cited: Aslaner O. Thoracic outlet syndrome: efficiency of surgery. Acta Med. Alanya 2020;4(3):270-277. doi:10.30565/medalanya.792279

INTRODUCTION

Thoracic outlet syndrome is a group of symptoms occurring due to the vascular and neurological structures at the upper thorax outlet being compressed by other upper thorax outlet structures, for congenital or acquired causes. While only one of the vascular or neurological symptoms can be seen in one person, symptoms shared by both can also be observed in the same person. The severity of the symptoms of thoracic outlet syndrome does not correlate clinically with the severity of anatomic pressure. For this reason, thoracic outlet syndrome does not have any physical examination results or laboratory tests that will lead to a definite diagnosis. While there was no evidence of severe pressure in the physical examinations, EMG findings or operations of some patients with severe symptoms, severe pressure findings may be observed in the physical examinations, EMG findings or operations of patients with low level symptoms. Therefore, it is not possible to talk about a complete correlation between anatomic pressure and symptoms, which leads to difficulties in the diagnosis. Taken together, the clinical experience of the physician in said cases is very important [1,2]

In diagnosed patients, physical therapy methods accompanied by medical treatment are suggested as a first line treatment[3]. Medical treatment combined with physical therapy can lead to serious clinical relief, although it can never completely improve the current mechanical pressure[6]. In patients where the desired level of clinical relief could not be maintained despite physical therapy and medical treatment, surgical treatment can be recommended [4,5]. The purpose of surgical treatment is to completely remove the components that cause pressure[6], and they include the first rib and if present, cervical ribs and scalene muscles [7-11]. Patient's complaints almost completely disappear shortly after the surgical treatment performed without damaging the plexus brachialis, subclavian artery and subclavian vein, and as long as there are no leaking bleeding spots left in the operation area to cause future adhesions, the likelihood of recurrence of thoracic outlet syndrome in later periods is very low [6,12,13].

In this study, we retrospectively examined our

cases where we applied surgical treatment and tried to demonstrate the effectiveness of surgical treatment in thoracic outlet syndrome .

PATIENTS AND METHODS

Our study included 37 patients diagnosed with thoracic outlet syndrome in the Department of Thoracic Surgery of the Akdeniz University Medical Faculty between 1991-2004, who were expected to benefit from surgical treatment in the light of preoperative evaluations and examinations, and were operated on. The cases were examined with retrospective evaluation by observing patient anamnesis forms, surgical reports, preoperative examinations (EMG, upper extremity arterial doppler, cervical MR, etc.) and postoperative clinical monitoring from patient records. Preoperative symptoms, physical examination findings and preoperative examination results were evaluated by comparison and the consistency was examined. Also, postoperative healing was compared with the length of stay in the hospital to detect how much the patients had benefited from the surgery.

Our exact diagnosis criteria in our clinical approach; The positivity of the Adson test was that the nerve compression was compatible with TOS in the EMG in neurogenic TOS, and the Adson test positivity in the vascular TOS was the compression findings compatible with TOS in the vascular doppler Pressure signs in vascular doppler Venous thrombosis in the thoracic outlet and distal, arterial thrombosis, and deceleration in arterial flow velocities distal to the thoracic outlet. It was accepted as definite TOS in cases who had complaints consistent with TOS and had no other pathological condition that could cause these complaints and also had a positive Adson test. In cases with complaints compatible with TOS, no other pathological condition that could lead to these complaints, and EMG and vascular doppler results that do not support TOS, cases with suspicious positive Adson test were accepted as possible TOS.

Patients who were suspected of having definite or possible TOS and whose other diseases were excluded in the differential diagnosis were firstly treated medically with NSAI, whereas the cases that could not be obtained were directed to the

physical therapy and rehabilitation clinic, and received physical therapy.

The surgical technique we clinically adopted and applied in TOS was the transaxillary approach. We operated all our cases with this surgical method and we removed first rib in all patients (Image 1 and Image 2).

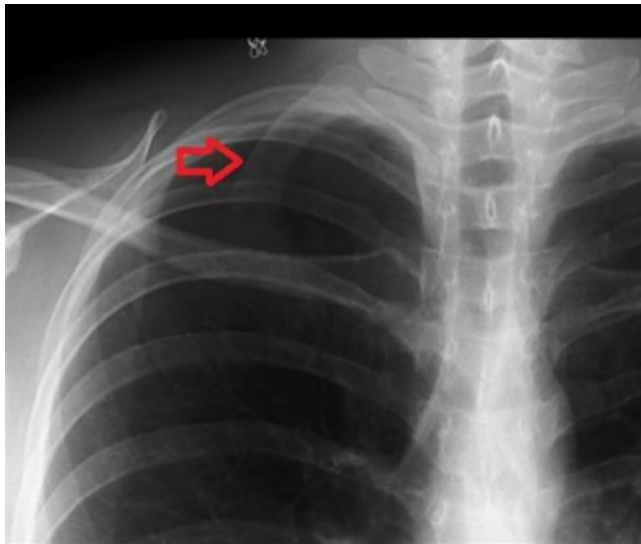


Image 1. Preop, presence of 1st rib

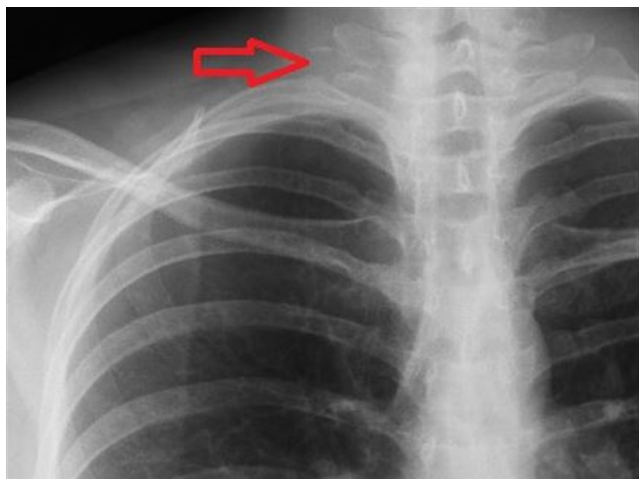


Image 2. Postop, after 1st rib resection.

Wound dressing was applied daily and antibiotic prophylaxis was applied to all patients. Tube thoracostomy cases were followed up with daily chest x-ray, and daily chest tube maintenance was performed. The aim was to remove the risk of infection and tube pain by pulling the chest tubes as soon as possible.

In the first week, the patients were advised not to get the wound areas wet, to make movements to strengthen the upper extremity and to prevent

restriction, not to put excessive load on the extremity and not to force it excessively. All patients were called for control at regular intervals within the first year. Clinical examination and direct radiological imaging were performed routinely during the controls. During certain periods of the controls, EMG in neurogenic TOS and doppler tests in vascular TOS were requested and compared with preoperative findings.

Our criteria for improvement were the statements of the patient about the improvement level of their complaints, the negative Adson test on physical examination, as well as the improvement in the EMG and Doppler findings. Statements of the patients about recovery were categorized as complete recovery, partial improvement and no change: We determined our recovery results using these criteria and we ensured the study was carried out according to ethical rules.

Statistical methods: The data obtained was compared with the chi-squared analysis test using the SPSS 10 statistics program in a Windows XP processor. Firstly, demographic data of the patients were recorded and descriptive statistics were made, comparing the presence of the patients' clink healing preop and postop symptoms. The investigation of cases with positive Adson test and EMG positive cases was done with the chi-square. The relationship between the presence of cervical ribs and the severity of symptoms was investigated by the Pearson correlation.

RESULTS

The ages of the patients differed between 18 and 60 years and the average was 33.2432. Thirty-four of the patients (91.9%) were female and 3 were male (8.1%). Thoracic outlet syndrome was detected unilaterally in 35 cases (94.59%) and 2 bilateral cases (5.41%) were identified. Housewives accounted for the majority of the patients (51.4%), whereas students and workers were in the second and third place at an equal 18.9% (Table 1).

In our study, we separated the symptoms into the two main groups of vascular and neurological. In 33 of the cases (89.2%), there were symptoms of neurological origin and 2 of them (5.4%) had vascular symptoms. Two cases (5.4%) had both

neurological and vascular symptoms; the Adson tests of all the cases were examined. Upper extremity arterial doppler was performed in 22 (59.5%) of the patients and 5 (13.5%) of the findings were compatible with pressure, while arterial doppler results of 17 (45.9%) came in normal. Arterial doppler was not performed on 15 of the patients (40.5%), while on radiological examination, cervical graphs and cervical MR images of the cases were examined. All of the cases had cervical graphs, cervical MR scans were performed on 11 (29.72%) cases and positive findings were encountered in 5 (45.45%) of these. In cervical graphs, a cervical rib was encountered in 14 cases (37.8%) and not encountered in 23 cases (62.2%). Another test that we used for electrophysiological diagnosis was the EMG, which was performed on all cases except for 3 (%8.81). It turned out positive in 18 cases (48.6%) and negative in 16 (43.2%) (Table 2).

Table 1. Demographic Data

Age (Mean±SD)	39±10
Gender (Female/Male)	34 (%91.9)/ 3 (%8,1)
Side (Right/Left)	21/18
Occupation (House-wife/Worker/Student/Other)	19/7/7/4

Table 2. Clinical Signs

	Preop	Postop	P value
Adson test (+)	39	3	0,03**
	-		
Emg *(+)	18	3	0,001**
	-		
Cervical Costa	14	0	0,001**
Vascular symp-tom***	4	0	0,001**
Neurological***	35	5	0,001**

*3 were not performed, ** Chi Square test(Monte Carlo Method's),

*** both symptom was positive: neurological and vascular

Among the 37 cases in our study, the most common complication was pneumothorax, at 14 (37.8%). In contrast to the other series where the Horner syndrome was not observed at all, hemothorax occurred in 2 cases (5.4%) and infection occurred in 1 case (2.7%). When the early results of the cases were evaluated, 29 patients (78.4%) were fully recovered and 5 patients (13.5%) were partially recovered, whereas in 3 cases (8,1%), there was no change in symptoms (Table 3).

Table 3. Early Postop Recovery Results

Results	Number	%
Total Recovery	29	78,4
Partial Recovery	5	13,5
No Changes	2	8,1
TOTAL	37	100

DISCUSSION

The main result of this study is that there was 78.4% complete recovery in the early period after surgery. The debate over whether the method used for TOS treatment should be a conservative approach or a surgical approach, has not yet been clarified. Despite the fact that there are many studies advocating both treatment methods in the literature, the view that is prevailing in recent years is that the cases should be treated with conservative treatments, including physical therapy and rehabilitation, until the last moment, and that surgical treatment should only step in if the complaints continue or are not reduced to a satisfactory level. Krusen et al. reported in his study published in 1968 that physical therapy and rehabilitation is the first treatment to be done in TOS [3]. According to them, it is possible to obtain results in the middle age group through neck-region massages, active neck exercises, exercises performed by stretching and loosening the upper trapezius muscle and scalene muscles, as well as hot applications. All cases included in our study had firstly applied various conservative treatments. When early results of the cases were evaluated, 29 cases (78.4%) were fully recovered and 5 cases (13.5%) were partially recovered, whereas in 3 cases (8,1%), there was no change in symptoms. With all cases in which partial recovery was achieved as a result of surgical treatment, complete recovery was achieved after physical therapy and rehabilitation. This rate is higher than many series reported in the literature. The full recovery rate of 78.4% in our study was also in accordance with the success rates of the studies done in our country, but one of the best success rates in the literature belongs to Sanders, who reported a 70% success rate [1,4]. The highest success rate ever reported was by Urschel in his series, at 97%.

In the surgical treatment of thoracic outlet syndrome, the most commonly used intervention

since the 1960s is transaxillary intervention. It can easily reach the first rib, cervical rib and neurovascular structures, and protection of neurovascular structures can be achieved during the removal of the first rib [4,9,15]. We too have performed transaxillary intervention on all of the cases in our operations and we performed first rib resection and scalenectomy in all cases. In cases with cervical rib and fibromuscular bands, we had to excise these structures.

In a long-term study, success rates were reported as 92% for transaxillary intervention, 83% for supraclavicular intervention, and 86% for posterior intervention. Postoperative complication rates do not exceed 4% in the literature [1,2,9,10,16], whereas in our study, the most common complication in 37 cases was pneumothorax, at 14 (37.8%). In contrast to the other series, there was no occurrence of the Horner syndrome, while hemothorax occurred in 2 cases (5.4%) and infection in 1 case (2.7%). None of the cases developed phrenic nerve palsy, but *Acinetobacter Baumannii* occurred in the case with infection: the patient remained in the hospital for a total of 10 days, during which time the infection was controlled without further progress and the patient was discharged with a complete recovery. Our complication rate was high, however, in comparison to the literature, such as with the series from Roos [7] and Urschel [17] which were around 1%. We attributed the fact that pneumothorax made up the highest portion of our complications to the fact that sufficient care was not shown to protect the pleura during operation and in addition, our complication rate would be down to 8% if we excluded pneumothorax. In some publications for thoracic outlet syndrome, the recurrence rate is reported to be 25% within the first two years [18,19] and Zatocil reported a recurrence rate of 45% in a series of 112 cases published in 1997 [20]. Many of the recurrent cases later benefited from physical therapy and rehabilitation methods and they were able to carry on asymptomatic or with symptoms that do not affect their lives [4,9,21,22]. Two of our cases (5.4%) applied with recurrence complaints about one year later, and both benefited from physical therapy and rehabilitation methods. Long-term routine follow-ups of the patients were not performed, but we did not have similar complaints again except with

these 2 cases.

On the other hand, we found that the demographic findings of the cases included in our study were partially compatible with the literature and on occasion, quite different. For instance, in series with large numbers of cases, the age group of 20-40 years is reported as the most frequent age group of thoracic outlet syndrome [1,2,4,9]. Nelson et al. reported an average age of 35 years [9], while Jamieson et al. reported 36 years in a group of 409 patients [23]. In our study, which included 37 cases, the average age was found to be 33.25 and this average was in accordance with the literature. Women account for 60-80% of thoracic outlet syndrome cases in all published series [1,2,4,9] and Jamieson reported this rate at 86% in his publication in 1996 [23]. In our study, 91.9% of the cases were females, however the regional situation of the clinic where the study was conducted and the gender distribution of the patients included may have had some effect on these results.

One of the most important points to note when examining the etiology history of thoracic outlet syndrome is the occupation of the person, as professional predisposition must definitely be known in TOS. The likelihood of thoracic outlet syndrome is an increasingly reported disease in occupations such as computer operators, secretaries, and bodybuilders who use the upper extremities for a long period of time [1,2,24-27]. In our study, we have found that 19 patients who constituted 51.4% of thoracic outlet syndrome cases were housewives and did not actively work in any particular occupation. However, the most frequent occupation in the literature is reported to secretaries in thoracic outlet syndrome female cases. We hypothesized that the majority of females in countries where thoracic outlet syndrome related studies were conducted participated in active work lives, and that the rates of housewives included in the cases of our study were critically low.

In the meta-analysis of 17 multicenter studies by Sanders, published in various years, they reported trauma at 54%, headache at 36% and neck pain at 68% between 1964 and 1971. In 1972-1979, these rates reached 89%, 74% and

92% respectively, and between 1980 and 1985, they reached 91%, 83% and 85% respectively. What can be understood from these ratios is that trauma is becoming an increasing etiologic cause in thoracic outlet syndrome. In this, the role of traffic accidents takes up a lot of space, whereas none of the cases in our study had trauma stories. Despite the increasing number of traffic accidents in our country in recent years, it was an interesting finding that there was no trauma as the etiologic cause in any of our cases. We related this due to the fact that thoracic outlet syndrome was neglected because of not being suspected by physicians and not being examined in this respect, or perhaps because of more serious complications rising in cases resulting from trauma.

Anamnesis and physical examination have the most important place in diagnosis of thoracic outlet syndrome, as in the diagnosis of many other diseases, however some radiological diagnostic methods must be used for determinative diagnosis. Upper extremity EMG and upper extremity doppler are now routinely performed in cases where thoracic outlet syndrome is suspected in many centers. Many centers also routinely recommending cervical MR imaging in these cases. In our study, we observed that 34 of the cases (91.9%) had the EMC test, 22 patients (59.5%) underwent upper extremity arterial doppler and 11 patients (29.7%) underwent cervical MR examination. The upper trunk consisting of the C5-C7 roots of the brachial plexus is the most anatomic formation under pressure, affected by the hypertrophy of the scalene muscles: the pressure of the upper trunk leads to symptoms such as pain, numbness, weakness. The most common symptoms in TOS in the literature are reported as numbness, pain, weakness and the occurrence of these goes up to 95% in the literature [1,2,4,6,9,13]. In many publications, neurological symptoms are more common than vascular symptoms [1,2,9], therefore in our study we distinguished the symptoms into two main groups of vascular and neurological: of all the cases, 33 (89.2%) had symptoms of neurological origin and 2 (5.4%) had symptoms of vascular origin, whereas 2 cases (5.4%) had both neurological and vascular symptoms. In most of the cases, more than one symptom was present together, the most common one being pain, at 94.6%. As the second most common symptom,

numbness was seen in 78.4% of the cases and the next common complaints were chills at 13.5%, weakness at 27%, atrophy at 10.8% and cyanosis at 10.8%; these findings were also consistent with the literature.

The most commonly used test for physical examination in thoracic outlet syndrome is the Adson test, the aim of which is to cause a contraction of the anterior and medial scalene muscles and consequently, to pressurize the subclavian artery and brachial plexus. While the susceptibility of the Adson test remained at 27% in some series, Murphy reported a 100% positive response to the it [28]; in our study, this rate was 86.5%. False positivity is much lower in the Adson test than in the costoclavicular test and hyperabduction test [28,29]: Rayan reported a false positive rate of 13.5% for the Adson test and 47% for the costoclavicular test in a study in 200 extremities of 100 volunteers [29]. Pleva reported a false positive rate of 62% for the hyperabduction test and 11% for the Adson test in a study of 53 medical students with no symptoms [30]. All these suggest that the Adson test is not a definite diagnostic criterion for thoracic outlet syndrome, but is a supporting finding for thoracic outlet syndrome. Despite the fact that Adson test was applied to all cases in our study, a healthy statistical evaluation could not be performed since no regular records were found about the hyperabduction test in retrospective examination.

In patients suspected to have thoracic outlet syndrome, the first radiological examination to be requested is a two- or four-way direct cervical graph. The detection of cervical ribs on direct cervical graphs implies a highly possible thoracic outlet syndrome diagnosis if the clinical data support it. The diagnosis should be supported by EMG, and if necessary, with arterial doppler [4].

Though cervical graphs were present for all the cases, cervical MR examinations were performed in only 11 (29.72%) of the cases and 5 (45.45%) had positive findings. In cervical graphs, 14 cases (37.8%) had cervical ribs, whereas 23 cases (62.2%) did not. In thoracic outlet syndrome, the rate of normal radiological examinations in literature varies between 1% and 10% [8,13,17]. In our study, this rate is 62.2%, which is in fact

incompatible with the literature.

EMG is the most reliable test showing pressure on brachial plexus in thoracic outlet syndrome [3,4]. In our study, EMG was performed on all cases except for 3 (8.1%): it was positive in 18 cases (48.6%) and negative in 16 (43.2%).

While the main cause of neurogenic symptoms in thoracic outlet syndrome is scalene muscle hypertrophy [2,13,18], the main cause of vascular symptoms is bone anomalies with type 7, type 8 and type 9 congenital fibromuscular bands. In our study there were no bone anomalies in any case. Scalene muscle hypertrophy and congenital fibromuscular bands were present in many cases and this explains why the symptoms in our cases are mostly neurological. However, since these data were not recorded regularly in operation notes, healthy statistics could not be made regarding scalene muscle hypertrophy and congenital fibromuscular bands. Arterial doppler is the most reliable and the most practical method of showing vascular pressure in TOS [1,2,9,20,25]: the examination is widely used because it is both non-invasive, relatively inexpensive and applicable to all patients. Upper extremity arterial doppler was performed in 22 (59.5%) of our cases and of these, 5 (13.5%) were found to have findings compatible with compression, whereas 17 (45.9%) had normal arterial doppler results. Arterial doppler was not performed on 15 of the patients (40.5%). There was a correlation between low rates of arterial pressure symptoms and low arterial doppler positivity in our study.

Limitations: The most important limitation of our study is that it is retrospective. Other limitations were the fact that the EMG tests of the patients were not performed by the same person and that the patient statements - one of the recovery criteria - were subjective.

CONCLUSION

Our results showed that a higher rate of complete recovery was achieved in the early postoperative period. We think that physical therapy and rehabilitation methods should be tried first in TOS, and favorable results can be obtained with appropriate and effective surgery in suitable cases. Moreover, these results indicated that

higher surgical success rates can be obtained by using this strategy.

Funding sources: The authors declared that this study has received no financial support

Conflict of Interest: No conflict of interest was declared by the authors.

Acknowledgements

The author wishes to thank Professor Doctor Abid DEMİRCAN, who supported in the study as thesis advisor.

REFERENCES

- Pajaj E, Alimehmedi R, Dashi F. Neurogenic Thoracic Outlet Syndrome Reviewed. *Albanian Journal of Trauma and Emergency Surgery* (2020) 4/2: 705 - 710 DOI: 10.32391/ajtes.v4i2.119
- Illig KA, Zoppi ER, Bland T. The Incidence of Thoracic Outlet Syndrome. *Annals of Vascular Surgery*. <https://doi.org/10.1016/j.avsg.2020.07.029>
- Krusen EM. Cervical pain syndromes. *Arch Phys Med Rehabil*. 1968;49:376-82 PMID: 4385559
- Keshishian JM, Smyth NPD. Thoracic Outlet Syndrome. Diagnosis and management. *Ann Thoracic Surgery* 1970;9:391-400. DOI: 10.1016/s0003-4975(10)65529-4
- Hwang JI, Ku S, Jeong JH. Traditional medicine treatment for thoracic outlet syndrome. *Medicine* (Baltimore). 2020 Jul 2; 99(27): e21074. doi: 10.1097/MD.00000000000021074
- Gelabert HA, Rigberg DA, O'Connell JB, Jabori S, Jimenez JC, Farley. Transaxillary decompression of thoracic outlet syndrome patients presenting with cervical ribs. *J Vasc Surg*. 2018 Oct;68(4):1143-1149. doi: 10.1016/j.jvs.2018.01.057. Epub 2018 Apr 25.PMID: 29705086
- Roos DB. Experience with first rib resection for Thoracic Outlet Syndrome. *Ann Thoracic Surg* 1971;173:429-42 doi: 10.1097/0000658-197103000-00015.
- Rob CG, Standover A. Arterial occlusion complicating Thoracic Outlet Syndrome. *Br Med J* 1958;2:709 doi: 10.1136/bmj.2.5098.709.
- Nelson RM, Davis RW. Thoracic Outlet Compression Syndrome. *Ann Thoracic Surg*. 1969;8:437-51. doi: 10.1016/s0003-4975(10)66074-2.
- Roos DB. New concepts of Thoracic Outlet Syndrome that explain etiology, symptoms, diagnosis and treatment. *S Vascular Surgery* 1989;10:626-34. doi: 10.1177/153857447901300503
- Machleder HI, Moll F, Verty A. The anterior scalene muscle in thoracic outlet syndrome: histochemical and morphometric studies. *Arc surg* 1986;121:1141-4. doi:10.1001/archsurg.1986.01400100047009
- Mingoli A, Feldhouse RJ, Farina C, Cavallari N, Sapienza P, Cavallaro A. Long-term outcomes after transaxillary approach for Thoracic Outlet Syndrome *Surgery* 1995;118(5):840-4 doi: 10.1016/S0039-6060(05)80274-0
- Panda N, Phillips W, Geller A, Lipsitz SR. Supraclavicular Approach for Neurogenic Thoracic Outlet Syndrome (nTOS): Description of a Learning Curve and Patient Functional Outcomes. *Thoracic Surgery*. 231; 4: 294, DOI: 10.1016/j.jamcollsurg.2020.07.434
- Jamieson WG, Chinnick B. Thoracic outlet syndrome: fact or fancy? A review of 409 consecutive patients who underwent operation. *Can J Surg* 1996;39(4):321-6. PMID: 8697324
- Stilo F, Montelione N, Benedetto F et al. Thirty-year experience of transaxillary resection of first rib for thoracic outlet syndrome. *International Angiology : a Journal of the International Union of Angiology*, 05 Dec 2019, 39(1):82-88 DOI: 10.23736/s0392-9590.19.04300-1
- Povlsen B, Hansson T, Povlsen. Treatment for thoracic outlet syndrome. *Cochrane Database Syst Rev*. 2014 Nov 26;(11):CD007218. doi: 10.1002/14651858.CD007218.pub3.
- Urschel HC, Razzuk MA. Upper plexus Thoracic Outlet Syndrome: Optimal Therapy. *Ann Thoracic Surgery* 1997;63:935-9. doi: 10.1016/S0003-4975(97)00188-4
- Weisz W, Husfeldt KJ. Thoracic Outlet Syndrome an interdisciplinary topic. Experience with diagnosis and therapy in a 15-year patient cohort (80 transaxillary resection of the 1st rib in 67 patients) and a literature review. *Z Orthop litre Grenzgeb* 1997;135(1):84-90. doi: 10.1055/s-2008-1039561.
- Mingoli A, Feldhaus RJ, Farina C, Cavallari N, Sapienza P, Di Marzo L, Cavallaro A. Long-term outcome after transaxillary approach for Thoracic Outlet Syndrome. *Surgery* 1995;118(5):840-4. doi: 10.1016/S0039-6060(05)80274-0
- Zatocil Z, Leybold J, Roubal P. Resection of the first rib for the upper thoracic outlet syndrome long-term experience. *Rozhli Chir* 1997;76(5):242-5. PMID: 9340816
- Glass BA. The relationship of axillary venous thrombosis to the thoracic Outlet Compression Syndrome. *Ann Thoac Surg* 1975;19:613-21. doi: 10.1016/s0003-4975(10)63821-0.

22. Blank RH, Connor RG. Arterial complications associated with thoracic outlet compression syndrome. *Ann Thorac Surg* 1974;17:315-21. doi: 10.1016/S0003-4975(10)65657-3
23. Lju JE, Tahmouh AJ, Roos DB, Schwartzman RJ. Shoulder-arm pain from cervical bands and scalene muscle anomalies. *J Neurol Sci* 1995;128(2):175-80. doi:10.1016/0022-510X(94)00220-1
24. Franklin GM, Fulton-Kehoe D, Bradley C, Smith-Weller T. Outcome of surgery for thoracic outlet syndrome in Washington State workers' compensation. *Neurology* 2000;54(6):1252-7. DOI: <https://doi.org/10.1212/WNL.54.6.1252>
25. Richardson AB. Thoracic outlet syndrome in aquatic athletes. *Clin Sports Med* 1999;18(2):361-78. doi: 10.1016/S0278-5919(05)70151-4
26. Nichols AW. The thoracic outlet syndrome in athletes. *J Am Board Fam Pract* 1996;9(5):346-55. DOI: <https://doi.org/10.3122/jabfm.9.5.346>
27. Dugas JR, Weiland AJ. Vascular pathology in the throwing athlete. *Hand Clin* 2000;16(3):477. PMID: 10955220
28. Murphy TO, Clinton AP, Kanar EA, McAlexander RA. Subclavicular approach of the First rib for thoracic outlet syndrome. *Am J Surg*. 1980;139:634-6. doi: 10.1016/0002-9610(80)90351-7
29. Rayan GM, Jensen C. Thoracic Outlet Syndrome: provocative examination maneuvers in a typical population. *J Shoulder Elbow Surg* 1995;4(2):113-7. doi: 10.1016/S1058-2746(05)80064-3
30. Plewa MC, Delinger M. The false-positive rate of Thoracic Outlet syndrome shoulder maneuvers in healthy subjects. *Acad Emerg Med* 1998;5(4):337-42. doi: 10.1111/j.1553-2712.1998.tb02716.x