



EDİTÖRE MEKTUP / LETTER TO THE EDITOR

Post-traumatic perforated mesenteric cystic lymphangioma

Travma sonrası perforé mezenterik kistik lenfanjiyom

Mustafa Tuşat¹, Mehmet Semih Demirtaş²

1Aksaray University, Faculty of Medicine, Department of Pediatric Surgery, Aksaray, Turkey

2Aksaray University Education and Research Hospital, Department of Pediatrics, Aksaray, Turkey

Cukurova Medical Journal 2020;45(4):1859-1861

To the Editor,

Abdominal lymphangiomas are a rare congenital cysts of the mesenteric and/or retroperitoneal lymphatics. They may occur mainly in childhood as a result of proliferation and enlargement of lymphatic vessels due to a obstruction of the lymphatic system¹. Although abdominal lymphangiomas are located most commonly in the small-bowel mesentery, they have been reported as less than 1% of all lymphangiomas². The clinical presentation of the cases is variable, which ranges from asymptomatic abdominal mass to acute abdomen^{3,4}. Although they can be identified by imaging methods such as abdomen ultrasonography, tomography or magnetic resonance imaging, the definitive diagnosis is made by histopathological examination^{4,5}. In this report, a case of mesenteric cystic lymphangioma which was ruptured due to trauma and caused an acute abdomen, is presented as a rare clinical presentation of MCL.

A five-year-old girl presented to pediatric emergency department with complaints of increasing abdominal pain and vomiting, which started after fell on her abdomen. The patient had a history of intermittent abdominal pain in the last one year before admission to hospital. In addition, the child was hospitalized two a year ago due to abdominal pain with a preliminary diagnosis of intussusception and was discharged after spontaneous reduction of the intussusception. The physical examination revealed a palpable mass on the periumbilical region, measuring around 10 cm, mobile, and accompanied by

abdominal tenderness with guarding and scarce bowel sounds. Laboratory examination showed erythrocyte sedimentation rate of 89 mm per hour, C reactive protein 118 mg/L, leucocyte elevation of 19.3×10^{10} /L and hemaglobin 9.1 mg/dl.

Abdominal x-ray revealed sign of ileus (Figure 1). Abdominal CT taken to the patient with a history of trauma showed two cystic lesions compressing the small intestines superiorly and left laterally in the abdominopelvic region and the larger one is 85x95 mm in size. Also, free fluid spread to all abdominal quadrants was observed (Figure 2). The patient then underwent an emergency surgery with preliminary diagnosis of intestinal duplication, mesentery or ovarian cyst perforation. In exploration, there were two cysts, tightly adherent to the jejunum, one intact and the other ruptured in the jejunal mesentery and free fluid with chylose character that spread all the quadrants. The intact cyst was a large 9x8x9 cm in size, yellowish-white looking containing chylous fluid (Figure 3-4). They were located at approximately 45 - 50 cm from the Treitz ligament. Resection of the mass along with the adjacent jejunum was performed (Figure 5), and the continuity of gastrointestinal motility was maintained. Tissue samples were sent for histopathological examination. The patient did not develop any complications in the postoperative period. The patient was discharged after 1 week of treatment in the hospital. The histological analysis of the cysts were reported as MCL. The patient was given detailed information about the current diagnosis and treatment. Signature was obtained for informed consent form from the patient. No

Yazışma Adresi/Address for Correspondence: Dr. Mehmet Semih Demirtaş, Aksaray University, Faculty of Medicine, Department of Pediatric Surgery, Aksaray, Turkey E-mail: md.semihdemirtas@gmail.com
Geliş tarihi/Received: 14.09.2020 Kabul tarihi/Accepted: 17.10.2020 Çevrimiçi yayın/Published online: 30.12.2020

recurrence was observed during the 2 years 2 months follow-up period.

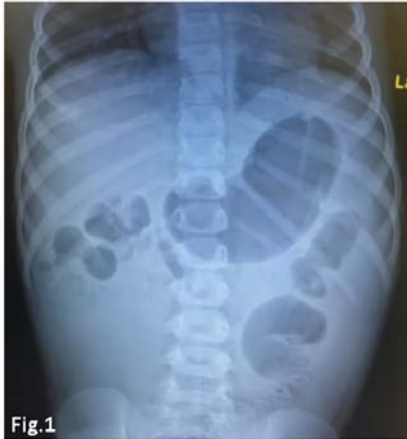

Figure 1. Abdominal X-ray finding of ileus

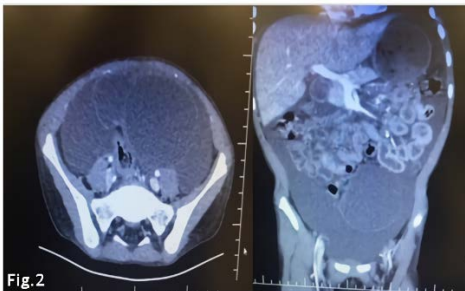


Figure 2. Axial and coronal section computed tomography: Widespread free fluid and two cystic lesions compressing the small intestines superiorly and left laterally, in the abdominopelvic region

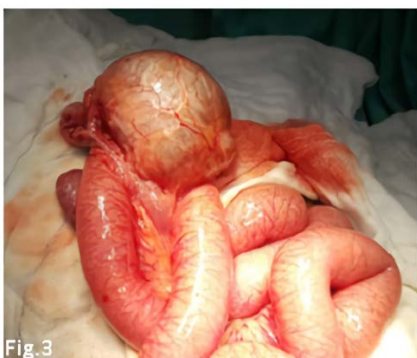

Figure 3. Intraoperative view of the non-ruptured MCL with thin-walled chylous fluid-filled

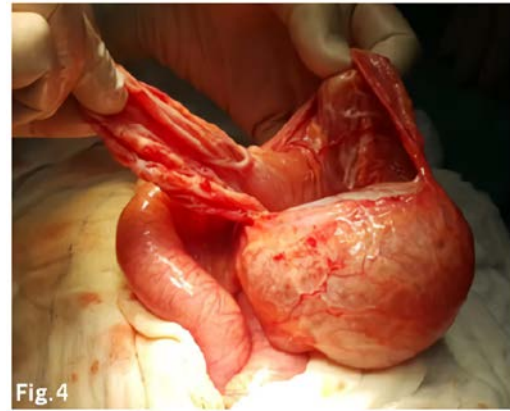


Figure 4. Intraoperative view of the non-ruptured and ruptured MCL

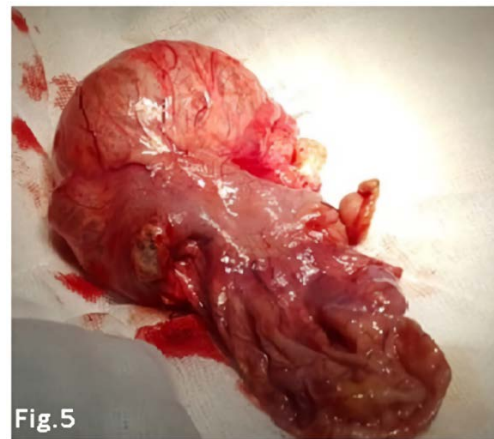


Figure 5. A surgical resection specimen of MCLs along with jejunum segment

MCLs are an uncommon intraabdominal cystic lesions of the mesenteric lymphatics and compose 1 / 100000-250000 of hospital admissions.

Lymphangiomas which seen in childhood are usually diagnosed 40% in the first year of age and 80% of them are up to 5 years of age^{6,7}. Although MCL is usually asymptomatic, the patient may present with chronic or acute abdominal pain, distension and an palpated abdominal mass. Also MCL may cause acute presentation because of an intestinal obstruction or peritonitis caused by infected cysts, torsion, compression of adjacent organs, intestinal ischemia, malrotation, bleeding into the cyst^{3,4,8,9} or as in our case, acute abdomen may develop due to post-traumatic cyst rupture, which is rarely seen. Although abdomen ultrasonography to show its cystic nature,

CT and MRI to show its complex anatomic relationships are highly sensitive^{5,9}. Duplication cyst, ovarian cyst, omentum cyst, peritoneal inclusion cyst, echinococcal cysts and multiloculated acid that causes intra-abdominal cystic appearance should be considered in differential diagnosis. The definitive diagnosis is made by histological examination of tissue^{3,9}.

The treatment for abdominal mesenteric lymphangioma is complete surgical excision, sometimes including resection of the the intestinal segment that is closely related with the cyst because of the risk of recurrence and malignant transformation^{4,8,10}.

As a conclusion, MCLs are extremely rare intra-abdominal cystic masses in children. As they may not lead to any clinical complaints, as in our case, may rarely present with acute abdominal findings due to post-traumatic cyst rupture and should be kept in mind in the differential diagnosis of intra-abdominal cystic masses.

Yazar Katkıları: Çalışma konsepti/Tasarımı: MT; Veri toplama: -; Veri analizi ve yorumlama: MSD; Yazı taslağı: MT; İçeriğin eleştirel incelenmesi: MSD; Son onay ve sorumluluk: MT, MSD; Teknik ve malzeme desteği: -; Süpervizyon: MSD; Fon sağlama (mevcut ise): yok.

Hakem Değerlendirmesi: Dış bağımsız.

Çıkar Çatışması: Yazarlar çıkar çatışması beyan etmemişlerdir.

Finansal Destek: Yazarlar finansal destek beyan etmemişlerdir.

Author Contributions: Concept/Design : MT; Data acquisition: -; Data analysis and interpretation: MSD; Drafting manuscript: MT; Critical revision of manuscript: MSD; Final approval and accountability: MT, MSD; Technical or material support: -; Supervision: MSD; Securing funding (if available): n/a.

Peer-review: Externally peer-reviewed.

Conflict of Interest: Authors declared no conflict of interest.

Financial Disclosure: Authors declared no financial support

REFERENCES

1. Losanoff JE, Richman BW, El-Sherif A, Rider KD, Jones JW. Mesenteric cystic lymphangioma. *J Am Coll Surg.* 2003;196(4):598-603.
2. Suthiwartnarueput W, Kiatipunsodsai S, Kwankua A, Chaumrattanakul U. Lymphangioma of the small bowel mesentery: a case report and review of the literature. *World J Gastroenterol* 2012;18:6328-32.
3. Gunadi, Kashogi G, Prasetya D, Fauzi AR, Daryanto E, Dwihantoro E. Pediatric patients with mesenteric cystic lymphangioma: A case series. *Int J Surg Case Rep.* 2019;64:89-93
4. Mabrouk MB. Intra-abdominal cystic lymphangioma: report of 21 cases. *Journal of Cancer Therapy.,* 2015;6:572-8.
5. Poroos F, Petermann D, Andrejevic-Blant S, Labгаа I, Di Mare L. Pediatric cystic lymphangioma of the retroperitoneum: A case report and review of the literature. *Medicine (Baltimore).* 2020;99(28):e20827.
6. Chim H, Chuwa EW, Chau Y, Chow PKH.. Gastrointestinal mesenteric cystic lymphangioma. *J Gastroenterol Hepatol.* 2006;21:916.
7. Suthiwartnarueput W, Kiatipunsodsai S, Kwankua A, Chaumrattanakul U. Lymphangioma of the small bowel mesentery: a case report and review of the literature. *World J Gastroenterol.* 2012;18:6328-32.
8. Xu X, Zheng C , He X , Zhao Y , Hong T . Gastrointestinal: giant mesenteric cystic lymphangioma. *J Gastroenterol Hepatol.* 2017;32:290.
9. Mesic M, Cigit I, Zganjer M, Cizmi A, Zupan B , Madzar Z. Cystic lymphangioma of jejunal mesentery mimicking acute appendicitis: case report, *Acta Clin. Croat.* 2013;52:129-32.
10. Lilia BH, Rym K, Ali G et al. Abdominal cystic lymphangioma complicated by mesenteric volvulus: a case report. *Tunis Med.* 2014;92:356-8.