

Kanser Tanısında Tüm Vücut MR ile PET-CT Karşılaştırması

The Comparison of Whole Body Diffusion MRI with PET-CT in Cancer Diagnosis

Aykut Recep AKTAŞ¹ , Rumeysa ELMAS ALKAN¹ , Mehmet ÇALLIOĞLU¹ 

¹Süleyman Demirel University Faculty of Medicine Dept. of Radiology, Isparta, Turkey



Ö Z E T

AMAÇLAR: Tüm vücut difüzyon ağırlıklı manyetik rezonans görüntüleme (DW-MRI), tümörlerin tespiti ve karakterizasyonu ve tedavi yanıtının izlenmesi için onkolojik vakalarda giderek daha fazla kullanılmaktadır. Altın standart olarak kabul edilen pozitron emisyon tomografisi/bilgisayarlı tomografi (PET/BT) ile difüzyon ağırlıklı görüntülemenin (DWI) tümör saptama kapasitesini ve tanısal doğruluğunu karşılaştırmayı amaçladık. **GEREÇ VE YÖNTEM:** Çalışmaya yaşları 38 ile 86 arasında değişen, çeşitli kanser türlerine sahip ve tedavi yanıtını evrelemek veya değerlendirmek için PET/BT endike olan 29 yetişkin hasta (13 erkek ve 16 kadın) dahil edildi. PET/BT'de FDG tutulumu gösteren lezyonlar tanımlandı ve standardize uptake değeri (SUV)max değerleri kaydedildi. DAG görüntülerinde FDG-PET/BT'de pozitif olan toplam 240 lezyon tespit edildi ve her lezyon için DWI sinyal şiddeti ve görünür difüzyon katsayısı (ADC) değeri ölçüldü. Her iki yöntem için PET pozitif lezyonların ve lezyon alanlarının SUVmax, ADC ve DWI yoğunluk değerleri Mann-Whitney U testi ve Spearman korelasyon testi kullanılarak karşılaştırıldı. **BULGULAR:** Lezyonların SUVmax ve DWI yoğunluklarının karşılaştırılması, bu iki parametre arasında anlamlı ters korelasyon gösterdi (Spearman korelasyon katsayısı= -0.296, p<0.0001). SUVmax ve ADC değerleri arasında anlamlı bir korelasyon yoktu (Spearman korelasyon katsayısı= -0.0421, p<0.5712). Çapı ≤1 cm olan lezyonlar için SUVmax ile DAG yoğunluğu arasında anlamlı bir ilişki bulunmazken (r=-0.09; p=0.66), çapı 1 cm'den büyük lezyonlar için SUVmax ile DAG yoğunluğu arasında zayıf bir korelasyon vardı. (r=-0.26; p=0.0008). SUVmax ile ADC değeri arasındaki ilişki lezyon çapına göre incelendiğinde anlamlı bir ilişki bulunmadı, yani lezyonun boyutunun küçük veya büyük olmasının bu ilişkiye etkisi olmadı. Lezyon boyutunun SUVmax, ADC veya DWI yoğunluğu ile ilişkili olup olmadığını analiz ettiğimizde lezyon çapı ile DWI yoğunluğu arasında zayıf bir ters korelasyon bulduk (r=-0.30; p=0.0001). ADC ile lezyon çapı arasında ters bir korelasyon vardı (r= -0.25; p=0.0005). Ayrıca SUVmax ile lezyon çapı arasında da anlamlı bir ilişki bulundu (r=0.38; p<0.0001). **SONUÇ:** DWI değerinin genellikle iki yöntem arasında çok yakın özgüllük ve duyarlılık değerleriyle PET/BT ile korele olduğunu gözlemledik. Onkolojik vakaların araştırılmasında PET/BT'ye alternatif veya tamamlayıcı olarak tüm vücut DAG kullanılabilir.

Anahtar Kelimeler: Kanser tespiti; Onkolojik görüntüleme; tüm vücut difüzyon MRI; PET-CT

Alınış / Received: 30.10.2020 Kabul / Accepted: 23.02.2021 Online Yayınlanma / Published Online: 15.08.2021



ABSTRACT

Objective: Whole body diffusion-weighted imaging (DWI) has been increasingly used in oncological cases for detection and characterization of tumors and monitoring of treatment response. We compared the tumor detection capacity and diagnostic accuracy of DWI with positron emission tomography/computed tomography (PET/CT), which is regarded as the gold standard. **Materials and Methods:** The study included 29 adult patients (13 men and 16 women) aged between 38 and 86 years who had various types of cancer, and for whom PET/CT was indicated for staging or evaluating treatment response. A total of 240 lesions that were positive in FDG-PET/CT were identified in the DWI images, and DWI signal intensity and apparent diffusion coefficient (ADC) value were measured for each lesion. SUVmax, ADC, and DWI intensity values of PET-positive lesions and lesion areas for both methods were compared using Mann-Whitney U test and Spearman correlation test. **Results:** SUVmax and DWI intensities of the lesions showed significant correlation (Spearman correlation coefficient= -0.296, p<0.0001). When we analyzed whether lesion size was associated with SUVmax, ADC, or DWI intensity, we found a correlation between lesion diameter and DWI intensity (r=-0.30; p=0.0001). **Conclusion:** The DWI was generally correlated with PET/CT with very close specificity and sensitivity values between the two methods. Whole body DWI can be used as an alternative or complementary to PET/CT in investigation and follow-up of oncological cases.

Keywords: Cancer detection; Oncologic imaging; whole body diffusion MRI; PET/CT



1. Introduction

Accurate diagnosis and staging as well as proper follow-up are necessary for management of cancer cases. PET/CT is commonly used in various important stages of cancer treatment, such as detection of relapsing lesions, determination of tumoral response to treatment, and correlation of suspicious radiological findings. However, intravenous injection of radioactive substances and radiation exposure are disadvantages. Moreover, inflammatory processes and post-operative and post-radiotherapy changes have the potential to increase metabolic activity, leading to false negative results. Also, the presence of associated stress, as well as recent excessive physical activity by the patient, can affect the patient's metabolism and lead to deceptive results. Patients with hyperglycemia may show reduced FDG uptake by tumor tissue (1).

Diffusion-weighted magnetic resonance imaging (DW-MRI) is based on the detection of the restriction of Brownian motion, also known as the random motion of water molecules. The diffusion coefficient of water molecules is influenced by the surrounding biological membranes and molecules (2). The measured magnitude of the diffusion is expressed as ADC (Apparent Diffusion Coefficient). This value is high for benign lesions but low for malignant lesions. Main areas of application include ischemic stroke, detection of suspicious tumors (primary tumor, recurrence, and metastasis), grading of tumors, and monitoring treatment response (2). Whole body DWI has powerful diagnostic potential in the evaluation of bone marrow and its diseases, and therefore, in detection and monitoring of bone metastases (3).

In this study, we aimed to compare the tumor detection capacity and diagnostic accuracy of DW-MRI with PET/CT, which is accepted as the gold standard.

2. Materials and Methods

The study was included 29 adult patients (13 men and 16 women) aged between 38 and 86 years with various types of cancers who had been referred to PET/CT examination with indication of staging or monitoring treatment response by having institutional review board approval.

Whole body DWI was performed with a Siemens Avanto (Germany) device using head, cervical, and body coils. The body was scanned from vertex to proximal thigh in a supine position with arms extended, using five stations. DWI sequences were obtained from echoplanar spin echo T2 in axial plane. DWI images were obtained with EPI technique, with 50 sec/mm² and 800 sec/mm² b values, and ADC maps were automatically generated by the device. Parameters of DWI were as follows: TR: 7100 msec, TE: 86 msec, FoV: 500 mm, Matrix: 192x153, Section Thickness: 6 mm.

PET/CT imaging of patients was performed using a Philips Gemini TF System (USA) brand 64-section PET/CT. Fasting blood sugar level was measured in every patient. Following 4-6 hours of fasting, 12-14 mCi 18-fluorodeoxyglucose (FDG) was administered intravenously, and sequential images were obtained 1 hour later with the patient in the supine position and included all body areas from vertex to proximal femur. Images were obtained with 4 mm section thickness.

In DWI, trace images were obtained using b=50 sec/mm² and b=800 sec/mm² values to generate negative images. For evaluation of lesions, images obtained with these two values were used. DWI was performed at 5 stations. Accordingly, the first region included the head, second region cervix and thoracic inlet, third region middle-lower thoracic and upper abdominal area, fourth region upper abdomen, and fifth region pelvis. PET/CT and DWI images of patients were evaluated at the same workstation (Apple-iMac/USA) using OsiriX (MD v.2.0.1 64-bit) program. Evaluation was made in reference to FDG-PET/CT. Lesions showing FDG uptake in PET/CT were identified, and their SUV_{max} values were recorded. A total of 240 lesions that were positive in FDG-PET/CT were identified in the DWI images, and DWI intensity and ADC value were measured for each lesion. Lesions were categorized into five groups based on their locations. While measuring intensity and ADC, areas that showed the most profound diffusion restriction were manually marked as ROI (region of interest) by the radiologist. For measurement of ADC, attention was given to keep cystic and necrotic components outside of the marked ROI area.

The long axis of each lesion was measured in the transverse plane in both PET/CT and DWI images. SUV_{max}, ADC, and DWI intensity values of PET-positive lesions, and lesion areas in both methods were compared using Mann-Whitney U test and Spearman correlation test. University medical board had given the permission for the study.

3.Results

Patient age varied between 38 and 86 years, with a mean age of 59.9 years. Two patients had negative PET/CT and DWI examinations, and these were excluded from the statistical analyses, leaving 27 patients. Of these, twelve (44.4%) were men and fifteen (55.6%) were women. All patients had a definitive diagnosis made following either biopsy or surgical operation. One patient had two primary malignancies as esophageal and breast cancers (Table 1).

Table 1: Distribution of sex, age, and primary tumor

Patient Number	Sex	Age	Primary Tumor
1	Man	48	Small cell lymphocytic lymphoma
2	Man	40	Seminoma
3	Man	38	Malignant melanoma
4	Woman	53	Oesophagus squamous cell carcinoma
			Invasive ductal breast carcinoma
5	Man	65	Squamous cell lung carcinoma
6	Man	69	Squamous cell lung carcinoma
7	Woman	65	Clear cell renal carcinoma
8	Woman	74	Cervix squamous cell carcinoma
9	Woman	68	Non hodgkin's lymphoma
10	Woman	52	Cervix squamous cell carcinoma
11	Man	57	Larynx squamous cell carcinoma
12	Man	42	Hepatocellular carcinoma
13	Man	64	Non small cell lung carcinoma
14	Woman	45	Rectum adenocarcinoma
15	Woman	59	Epithelial ovarian carcinoma
16	Man	55	Signet-ring cell gastric carcinoma
17	Man	62	Non small cell lung carcinoma
18	Woman	65	High grade endometrial stromal sarcoma
19	Man	86	Colon adenocarcinoma
20	Woman	55	Invasive ductal breast carcinoma
21	Woman	76	Cervix squamous cell carcinoma
22	Woman	43	Ovarian serous adenocarcinoma
23	Man	73	Squamous cell carcinoma of the skin
24	Woman	70	Gastrointestinal stromal tumor (GIST)
25	Woman	64	Invasive ductal breast carcinoma
26	Woman	58	Endometrial serous adenocarcinoma
27	Woman	56	Ovarian serous papillary carcinoma
28	Man	47	Larynx squamous cell carcinoma
29	Woman	53	Invasive ductal breast carcinoma

Two patients, one with malignant melanoma and the other with ovarian cancer, did not have any lesions showing FDG uptake. The remaining 27 patients had a total of 240 lesions detected in FDG-PET/CT. One patient with non-small cell lung cancer (NSCLC) had multiple brain metastases that could not be detected in PET/CT but were identified with DWI and later confirmed with contrast-enhanced conventional brain MRI. Another patient with NSCLC had a lesion at the lower pole of the right kidney showing diffusion restriction identified with DWI, but this lesion could not be observed with PET/CT. This lesion was later demonstrated again with contrast-enhanced abdominal CT examination (3 2).

Table 2: Number of lesion types, distribution, and frequency according to region

<u>Lesion types</u>	<u>Lesion numbers</u>	<u>Frequency</u>
<u>Primary</u>	<u>43</u>	<u>%17,9</u>
<u>Metastasis</u>	<u>197</u>	<u>%82,1</u>
<u>Total</u>	<u>240</u>	<u>%100</u>

<u>Area</u>	<u>Lesion numbers</u>	<u>Frequency</u>
1. <u>Area</u>	<u>7</u>	<u>%2,9</u>
2. <u>Area</u>	<u>67</u>	<u>%27,9</u>
3. <u>Area</u>	<u>95</u>	<u>%39,5</u>
4. <u>Area</u>	<u>38</u>	<u>%15,8</u>
5. <u>Area</u>	<u>33</u>	<u>%13,7</u>
<u>Total</u>	<u>240</u>	<u>%100</u>

For the 183 lesions that were positive in both PET and DWI, the largest and the smallest lesions in DWI had diameters of 120 mm and 7 mm, respectively (mean diameter 20.5 mm and median diameter 16 mm). In PET/CT, the largest and smallest lesions had diameters of 120 mm and 8 mm, respectively (mean diameter 21.7 mm and median diameter 17 mm). In DWI, the highest and lowest intensities observed were 437 sec/mm² and 12 sec/mm², respectively (mean 72 sec/mm²). The lowest and highest ADC values were 0.29x10⁻³ mm²/sec and 1.9x10⁻³ mm²/sec, respectively (mean 0.88x10⁻³ mm²/sec). The highest and lowest SUV_{max} values were 28.9 and 2.27, respectively (mean 5.1) (Table 3).

SUV_{max}, ADC, and DWI intensities of PET/CT-positive lesions, and lesion sizes for both methods were compared with Mann–Whitney U and Spearman’s correlation tests.

Comparison of lesion sizes between the two methods showed significant correlation between PET/CT and DWI. That is, no significant difference was found between the diameters measured with PET/CT and DWI (p=0.10). There was no difference between these two parameters (r=0.90; p<0.0001) (As shown in Figure 1).

Analysis of the relationship between DWI intensity and ADC values of the lesions showed a weak correlation between these two parameters (Spearman correlation coefficient=0.266, p=0.0003) (As shown in Figure 2).

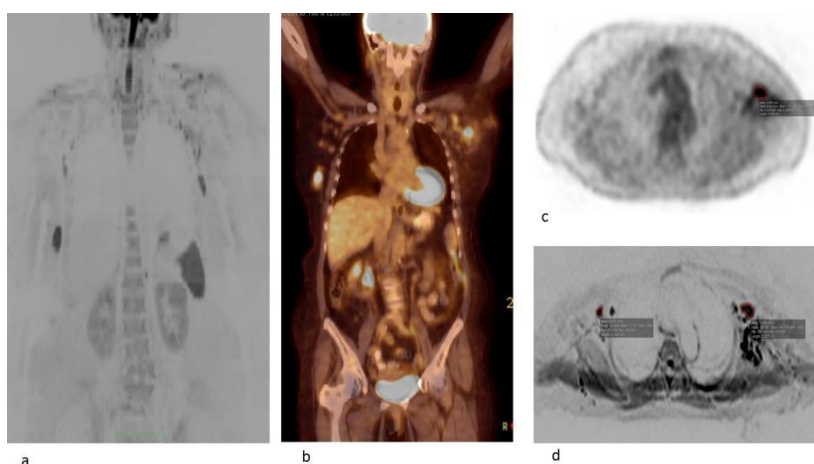
Comparison of SUV_{max} and DWI intensities of the lesions showed a significant inverse correlation between these two parameters (Spearman correlation coefficient=-0.296, p<0.0001).

Table 3: Mean DWI intensity, ADC, and SUV_{max} values according to cancer type

Cancer Type	DAG Intensity(sn/mm ²)	ADC Value (mm ² /sn)	SUV-max	Frequency	Patient Number
Seminoma	-40	0,63	4,6	%3,7	1
RCC	0	0	5,91	%3,7	1
Esophagus Ca	-75	0,65	4,12	%3,7	1
Hepatocellular Ca	-54	0,97	5,8	%3,7	1
Rectum Ca	-92	1,15	7,52	%3,7	1
Colon Ca	-80	0,71	28,68	%3,7	1
Stomach Ca	-97	0,89	4,69	%3,7	1
GIST	-98	0,94	5,97	%3,7	1
SCC(skin)	-76	1,28	5,55	%3,7	1
Endometrium Ca	-103	0,87	3,98	%3,7	1
Endometrial Sarcoma	-50	0,59	7,38	%3,7	1
Larynx Ca	-169	0,81	11,77	%7,4	2
Lymphoma	-75	0,72	3,86	%7,4	2
Cervix Ca	-93	0,78	8,48	%11,1	3
Ovarian Ca	-85	0,88	7,54	%11,1	3
NSCLC	-102	1,02	6,26	%14,8	4
Breast Ca	-65	0,91	4,33	%14,8	4

The relationship between DWI intensity and SUV_{max} was examined according to different body areas, and it was found that their correlation was influenced by the location of the lesion. Accordingly, a significant inverse relationship between SUV_{max} and DWI intensity was found for the lesions localized to the second and fifth regions (As shown in Figure 3). Regression analysis showed significant association between SUV_{max} and DWI intensity in the second and fifth regions.

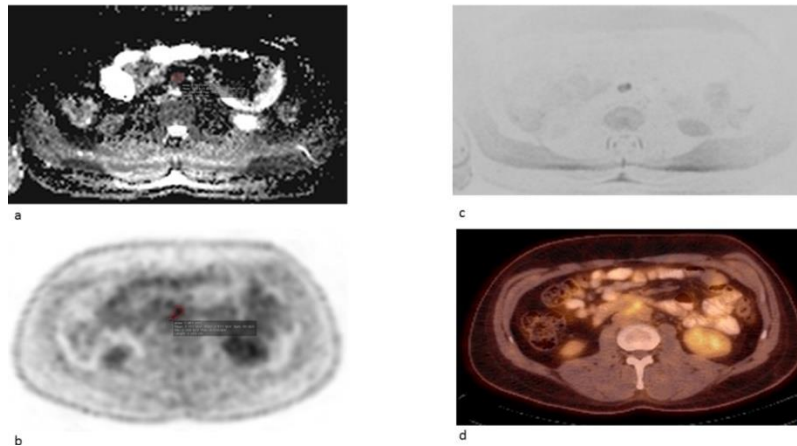
Figure 1: Axillary lymphadenopathy in female patient with Non-Hodgkin lymphoma a) coronal MIP image obtained by b=800 images b) Hypermetabolic axillary lymphadenopathy in coronal PET/CT images c) Measurement of DAG intensity from left axillary LAP in b=50 images d) Measurement of SUV_{max} from left axillary LAP



Comparison of SUV_{max} and ADC values of the lesions did not show a significant correlation between these two parameters (Spearman correlation coefficient=-0.0421, p=0.5712). Only a superficial relationship was

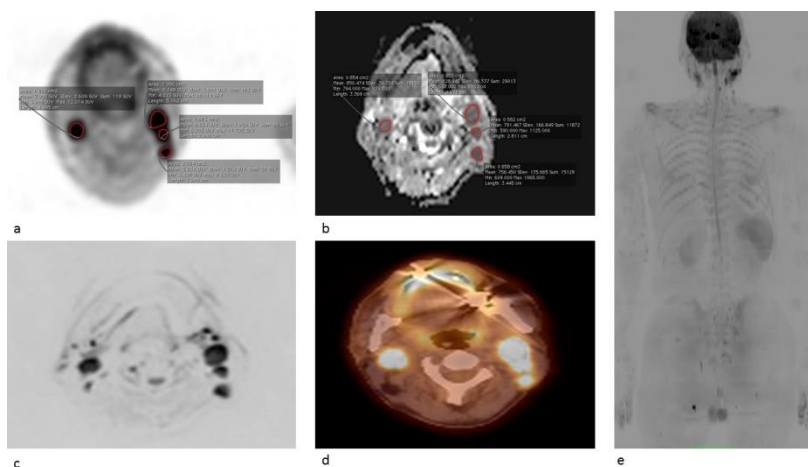
present for lesions localized to the fifth region (Spearman correlation coefficient=0.361, $p=0.0594$) (As shown in Figure 4).

Figure 2: Interaortocaval lymphadenopathy in male patient with operated seminoma a) ADC value of lymphadenopathy in ADC map b) SUVmax value of lymphadenopathy in PET image c) Interaortocaval lymphadenopathy showing diffusion restriction in $b=800$ image d) Hypermetabolic axillary lymphadenopathy in PET/CT



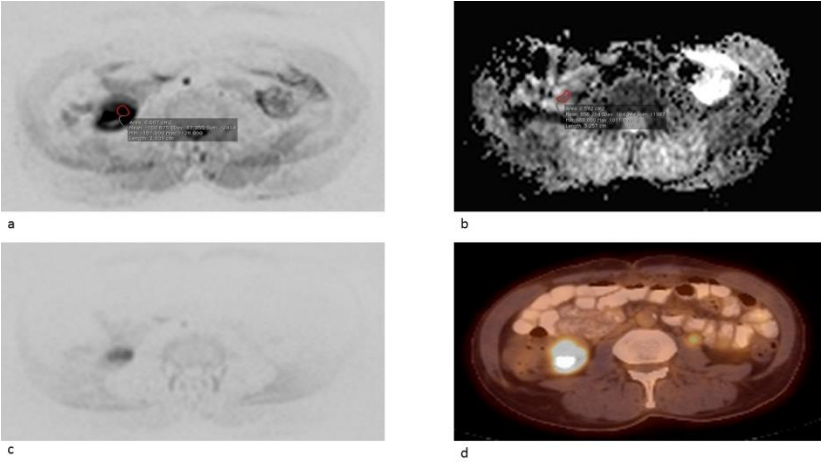
The relationship between SUV_{max} and DWI intensity was examined after categorizing the lesions as those with SUV_{max} value lower or higher than five, and accordingly, significant correlation was observed in both groups. However, this relationship was stronger for lesions with $SUV_{max}>5$ ($p=0.0003$) (As shown in Figure 5 and 6).

Figure 3: Bilateral cervical lymphadenopathy in male patient with operated larynx Ca a) Measurement of DAG intensity from lymphadenopathy in $b=50$ image b) Measurement of ADC value from lymphadenopathy in ADC map c) Bilateral cervical lymphadenopathy showing diffusion restriction in $b=800$ image d) Hypermetabolic bilateral cervical lymphadenopathy in PET/CT e) coronal MIP image obtained by $b=800$ images



There was significant correlation between SUV_{max} and DWI intensity for lesions having a diameter >1.5 cm ($r=-0.26$; $p=0.009$) (As shown in Figure 7).

Figure 4: Mass on left kidney lower lobe in male patient with NSCLC a) Measurement of DAG intensity from mass in b50 image b) Measurement of ADC value from mass in ADC map c) Mass showing diffusion restriction in Trace b=800 image d) Nonvisualization of mass in PET/CT because of intensive FDG accumulation on pelvicalyceal system



A significant correlation was observed between lesion diameter and SUV_{max} ($r=0.38$; $p<0.0001$).

Figure 5: Female patient with primary breast cancer a) Measurement of DAG intensity from mass in b50 image b) Measurement of SUVmax from mass on PET image c) Breast cancer showing diffusion restriction in Trace b=800 image d) View of mass on contrast-enhanced breast MRI

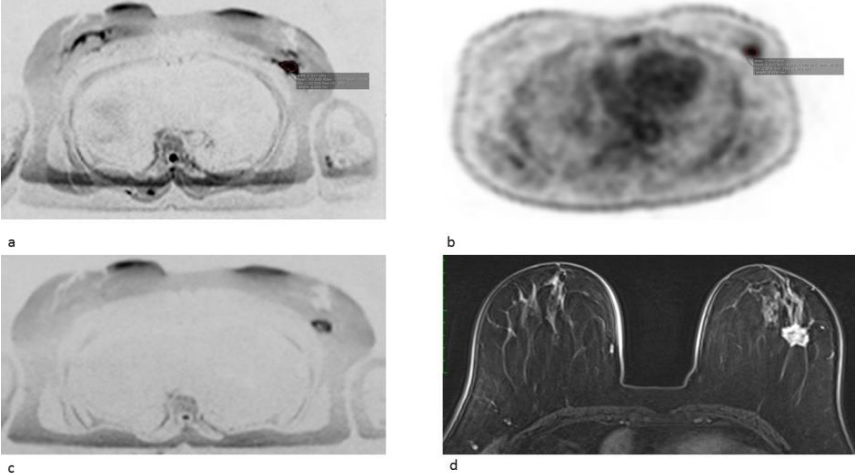
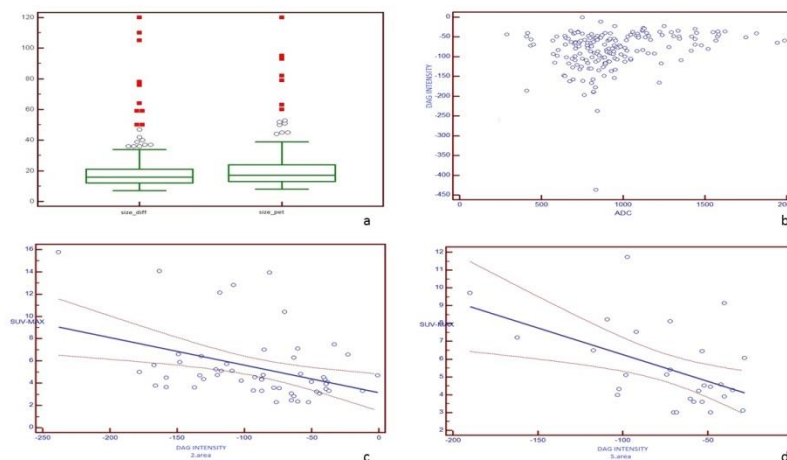


Figure 6: a) Correlation of lesion sizes measured with PET/CT and DWI, b) The correlation between DWI intensity and ADC value, c) The relationship between SUVmax and DWI intensity for lesions localized to the second region, d) The relationship between SUVmax and DWI intensity for lesions localized to the fifth region.



4. Discussion

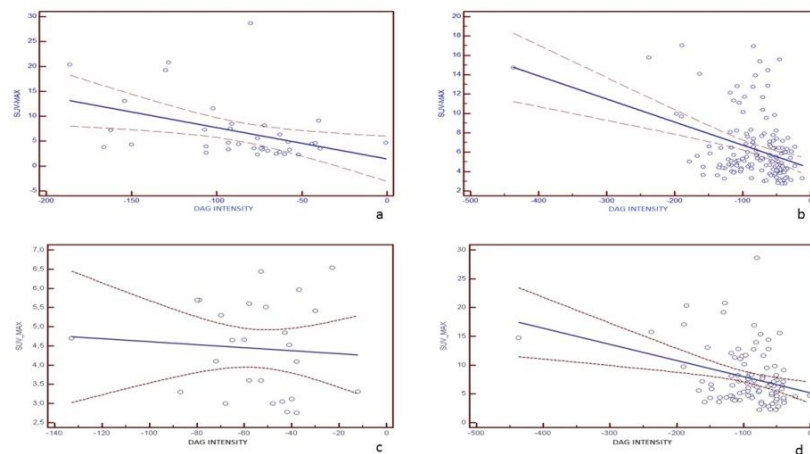
By the late 1990s, DWI had become a diagnostic tool for ischemia in the field of neuroradiology. Until recently, DWI could not be used for whole body MRI scans because of greater section thickness and inadequate fat suppression. Thanks to the research of Takahara et al. in 2004 that pioneered the way for obtaining multiple thin sections in DWI using STIR-EPI sequence, which enables getting more quality images from 3D reconstruction images, today DWI can be applied to the whole body (4). This technique provides a good suppressed background image by suppressing signals from tissues such as vessels, muscle, and fat via heavy diffusion and STIR pulses.

Longer times allow multiple signal averaging, high signal-to-noise ratio (SNR), and greater number of sections with fat suppression. Diffusion weighted images with high b values have high tumor-normal tissue contrast, thus increasing detectability of tumor lesions and infiltrative spread. Conversion of the obtained DWI images to gray scale makes lesions appear black while suppressing the tissues in the background, producing a PET/CT-like image (5, 6).

DWI images can be evaluated qualitatively or quantitatively. Qualitative evaluation is made using b value images. With increasing b value, normal tissues that have free diffusion are suppressed more, making it easier to distinguish tumoral tissue with restricted diffusion from the surrounding tissues. Imaging with varying b values makes quantitative analysis possible. Quantitative analysis is made via ADC mapping. ADC mapping also allows elimination of T2 "shine-through" effect (7).

In oncological imaging, DWI is used for detection of disease, characterization of lesions, and evaluation of treatment response. Additionally, whole body DWI has been increasingly used for staging systemic diseases such as lymphoma, bone metastases, and hematological malignancies. In recent years, DWI has gained an important potential for investigation of prostate cancer (8). DWI is commonly used for the vertebrae. It is used to investigate the etiology of vertebral collapse and in benign-malignant discrimination of collapse fractures (9).

Figure 7: a)The relationship between SUVmax and DWI intensity for lesions with SUVmax value lower than 5, b)The relationship between SUVmax and DWI intensity for lesions with SUVmax value higher than 5, c)The relationship between SUVmax and DWI intensity for lesions having diameter <1 cm., d)The relationship between SUVmax and DWI intensity for lesions having diameter >1.5 cm.



Radiological imaging modalities such as CT and MRI have been extensively used for a long time for characterization of tumors and evaluation of tumoral spread and treatment response. However, tumoral activity is also very important when evaluating malignancy. For this reason, PET/CT has become a very important oncological imaging tool in recent years. However, it has some disadvantages like the presence of radiation exposure and the possibility of being influenced by external physical factors (patient's exposure to cold environment, physical activity) and stress. DWI, on the other hand, is more advantageous than PET/CT as it is not affected by external conditions, and does not result in radiation exposure. Several studies have demonstrated the diagnostic contribution of DWI to MRI. Moreover, according to some authors, it has the potential to replace FDG PET/CT in cancer staging (10).

Most DWI studies use b values varying between 0 and 1000 sec/mm². For breast and prostate tissue, utilization of b values greater than 1000 sec/mm² facilitates visualization of lesions. Although utilization of high b values is appealing clinically, it tends to cause serious eddy-current distortions (3).

Most DWI studies in the literature have focused on certain cancer types, and there are a limited number of studies comparing whole body DWI and FDG-PET/CT. No previous study has directly compared SUV_{max}, ADC, and DWI intensity before. In our study, we evaluated lesions in inverted DWI images. We found significant correlation between SUV_{max} and DWI intensity, which we believe is because PET images and inverted DWI images visually resemble each other.

Both PET and DWI are functional imaging modalities that create high lesion-background contrast and are based on distinct biophysical and biochemical principles. As FDG-PET and DWI are based on different mechanisms, they can provide complementary information. For example, FDG-PET can be used for spleen and mediastinal structures for which DWI has limited use. On the other hand, DWI can provide a diagnostic contribution to FDG-PET in evaluation of organs such as renal collecting system and bladder where FDG is accumulated in high concentrations, as well as pelvic organs neighboring the bladder, and in imaging of well-differentiated breast, prostate, liver, and thyroid cancers, neuroendocrine tumors, and low-grade lymphomas that show low-level FDG uptake (7). Our findings are in support of this view. One of our cases who had NSCLC had brain metastases that could not be detected in PET/CT but were easily distinguished with DWI. Similarly, another case had a renal tumor that could not be detected in PET/CT due to intense FDG accumulation but could be visualized with DWI.

Several studies have found FDG-PET/CT to be superior to DWI in evaluation of organs including mediastinum, lungs, and spleen. However, PET/CT can be negative in prostate cancer, hepatocellular carcinoma, and low-grade gliomas. DWI is more advantageous for such cases. DWI stands out for organs where the physiological FDG uptake is high, such as brain, liver, bone marrow, and urinary system.

The combination of FDG-PET/CT and whole body DWI can provide a more detailed examination for detecting tumoral lesions. Moreover, lesions detected with DWI can be confirmed with conventional and contrast-enhanced sequences to increase the diagnostic value (5,11,12).

In our study, we found significant inverse correlation between DWI intensity and SUV_{max} in general evaluation of the lesions. The reason for this inverse correlation may be that inverted images that are called "virtual PET" were used instead of the original DWI images. We observed that these inverted images were quite similar to that of PET/CT, with a great degree of overlap between the visualized lesions.

5.Conclusion

There was not a significant correlation between SUV_{max} and ADC. This may be because lymph nodes and metastatic/primary mass lesions were grouped separately for statistical analysis. When we examined SUV_{max} and ADC values of lesions, we observed a lack of diffusion restriction and high ADC values for lymph nodes, particularly the small-sized nodes. According to our observations, diffusion restriction was more profound in primary and metastatic mass lesions and in lymph nodes that had a diameter greater than 1 cm. Smaller lesions were not grouped separately for statistical analyses but were evaluated together with all other lesions. We believe this might be responsible for the lack of significant correlation between SUV_{max} and ADC values. We observed that lesions localized to organs that show high degree of physiological FDG uptake, such as brain and kidneys, can be detected with DWI. In our opinion, combined use of PET/CT and DWI can contribute to staging of lesions and increase the diagnostic accuracy.

References

- [1] Culverwell AD, Scarsbrook AF, Chowdhury FU. False-positive uptake on 2-(18F)-fluoro-2-deoxy-D-glucose (FDG) positron-emission tomography/computed tomography (PET/CT) in oncological imaging. *Clinical Radiology* 2011;66:366-382.
- [2] Tuncel E. MR Fizik. *Klinik Radyoloji, Nobel & Güneş Tıp Kitabevi* 2008: 249 - 353.
- [3] Matthew D. Blackledge, Martin O. Leach, David J. Collins, et al. Computed diffusion-weighted MR imaging may improve tumor detection. *Radiology* 2011;261:573-581.
- [4] Takahara T., Imai Y., Yamashita T., Yasuda S., Nasu S., Cauteren M.V.. Diffusion weighted whole body imaging with background body signal suppression (DWIBS): technical improvement using free breathing, STIR and high resolution 3D display. *Radiation Medicine* 2004;22:275-282.
- [5] Wilhelm T, Stieltjes B, Schlemmer HP. Whole-body-MR-diffusion weighted imaging in oncology. *Rofo* 2013;185:950-958.
- [6] Charles-Edwards EM, deSouza NM. Diffusion-weighted magnetic resonance imaging and its application to cancer. *Cancer Imaging* 2006;13:135-143.
- [7] Kwee TC, Takahara T, Ochiai R, Koh DM, Ohno, Nakanishi K et al. Complementary Roles of Whole-Body Diffusion Weighted MRI and 18F-FDG PET. *Journal of Nuclear Medicine* 2010;51:1549-1558.
- [8] Gibbs P, Tozer DJ, Liney GP, Turnbull LW. Comparison of quantitative T2 mapping and diffusion weighted imaging in the normal and pathologic prostate. *Magnetic Resonance Medicine* 2001;46:1054-1058.
- [9] Maeda M, Sakuma H, Maier SE, Takeda K. Quantitative assessment of diffusion abnormalities in benign and malignant vertebral compression fractures by line scan diffusion-weighted imaging. *American Journal of Roentgenology* 2003; 181:1203-1209.
- [10] Heusner TA, Kuemmel S, Koeninger A, Hamami ME, Hahn S, Quinzen A et al. Diagnostic value of diffusion-weighted magnetic resonance imaging (DWI) compared to FDG PET/CT for whole-body breast cancer staging. *European Journal of Nuclear Medicine and Molecular Imaging* 2010;37:1077-1086.
- [11] Koh DM, Collins DJ. Diffusion-weighted MRI in the body: Applications and challenges in oncology. *American Journal of Roentgenology* 2007;188:1622-1635
- [12] Bozgeyik Z, Onur MR, Poyraz AK. The role of diffusion weighted magnetic resonance imaging in oncologic settings. *Quantitative Imaging in Medicine and Surgery* 2013;3:269-278.