



An Abnormal Course of the Internal Carotid Artery in the Neck

Ramazan Öçalan ¹, Fatma Ceyda Akın Öçalan ¹, Zeliha Korkmaz Dişli ², Samet Özlügedik ³, Adnan Ünal ⁴

¹Malatya State Hospital, Department of Otorhinolaryngology, Malatya, Turkey

²Malatya State Hospital, Department of Anesthesiology, Malatya, Turkey

³Oncology Research and Training Hospital, Department of Otorhinolaryngology, Ankara, Turkey

⁴Ankara Numune Hospital, Research and Training Hospital, Department of Otorhinolaryngology, Ankara, Turkey

Abstract

Internal carotid artery anomalies are extremely rare and may cause unexpected complications during surgery. The magnetic resonance imaging of the neck of a 83-year old patient was admitted to the ear, nose, and throat clinic with a mass in the neck, which was reported to be a giant mass lesion in the right side of the neck, inferior of the angle of mandible, to the anterolateral of the sternocleidomastoid muscle. After the fine needle aspiration biopsy the patient was thought to be a malignant melanoma case, making us plan chemoradiotherapy after the surgery. During the radical neck dissection, while the surface of the internal carotid artery was being dissected superiorly, it was noticed that the artery was springing abnormally in the form of the siphon posteriorly. Although these types of anomalies are rare variations, they can cause serious life-threatening complications during neck surgery.

Key Word: Internal Carotid Artery, Neck; Complications.

Boyunda Anormal Seyir İzleyen Arteria Carotis Interna

Özet

Arteria carotis interna anomalileri son derece nadir olup cerrahi sırasında beklenmedik komplikasyonlara neden olabilir. Boyunda kitle şikayeti ile kulak burun boğaz kliniğine kabul edilen 83 yaşındaki hastanın boyun magnetik rezonans incelemesinde boyun sağ tarafında angulus mandibula'nın inferiorunda, sternokleidomastoid kasi anterolateralinde dev kitle lezyonu saptandı. Yapılan ince iğne aspirasyon biyopsisinde malign melanoma tespit edildi. Yapılan ileri tetkikler sonucu hastanın tanısı primeri bilinmeyen boyun metastazı olarak kabul edildi ve hastaya cerrahi sonrası kemoradyoterapi planlandı. Radikal boyun diseksiyonu sırasında arteria carotis interna'nın üzeri superiora doğru diseke edilirken arterin posteriora doğru sifon şeklinde anormal bir yaylanma yaptığı görüldü. Bu tür anomaliler nadir görülen varyasyonlar olmasına rağmen boyun cerrahisi sırasında hastanın yaşamını tehdit eden ciddi komplikasyonlara neden olabilir.

Anahtar Kelimeler: Arteria Karotis Interna; Boyun; Komplikasyonlar.

INTRODUCTION

Arteria carotis interna (ACI) begins as a terminal branch of arteria carotis communis at the level of the upper edge of the thyroid cartilage. Initially, it starts at the lateral of the external carotid artery, and, as it continues upwards, it turns first towards the posterior and then to the medial of the external carotid artery, eventually ending up in the head skeleton through canalis caroticus (1). ACI anomalies are rare but setting such anomalies aside during surgery may cause serious life-threatening complications. During neck surgery, in order to prevent unexpected complications, it is of utmost important to be familiar with the anatomy of this region and adjacent structures and to take variations and anomalies into account (2).

In this case report, we aim to present an abnormal case of ACI during a radical neck dissection operation for malignant melanoma metastases and to discuss the surgical importance of such anomalies.

CASE REPORT

A 83-year-old female patient was admitted to our clinic with complaints of a mass in the neck. On physical examination, we observed a 6x6x7cm vibrant, smooth-surfaced, and hard consistency mass that was covered with purple skin on the right side of the neck. Other ear, nose and, throat examination findings were normal. Magnetic resonance imaging of the neck was reported that the mass was a "giant mass lesion on the right side of the neck, inferior to the angulus mandibula, to the anterolateral of the sternocleidomastoid muscle, and enhancing towards the skin." The fine-needle aspiration biopsy disclosed the patient to have malignant melanoma though we did not determine any area of primary suspect in the whole-body scan. The cranial and chest computed tomography results along with the upper and lower abdomen ultrasonography findings were all within normal limits. Panendoscopy did not show any suspicious areas. The patient was scheduled for radical neck dissection followed by chemoradiotherapy. The island skin over the neck

tumour and neck dissection specimens were removed altogether as a whole. During the radical neck dissection, as we were dissecting the the ACI surface towards the superior, we noticed an abnormal springing move of the artery in the posterior direction (Figure 1); finally, we completed the dissection with extra care.

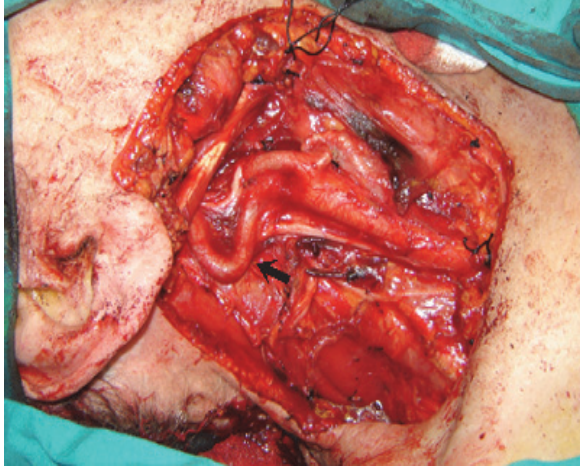


Figure 1. The abnormal arteria carotis interna after the radical neck dissection.

DISCUSSION

To avoid fatal complications in neck surgery, practitioners should be knowledgeable about the anatomy of the carotid system. The abnormal course of ACI is reported to be between 4% and 66%, and 5.1% and 19% in autopsy series and angiographic series, respectively (3-4). Weibel and Fields have divided the variations in the course of ACI into 4 types: plain course, S or C-shaped course, the course in which one or more segments make sharp turn(s), and spiral course (5-6). Leipzig and Dohrman, on the other hand, evaluate the variations of the carotid artery in two groups (7). The first group contains the courses that involve elongation, fluctuating or S-shaped courses or courses that fall under "tortuosis" while the second group contains the set of variations with sharp turns.

Looking at the etiology of ACI variations, we see that atherosclerosis, hypertension, and congenital deformities are the main factors (8). Meanwhile, resulting in fibrous bands and adhesions, granulomatous diseases may also lead to rotation in vessels. Besides aneurysms may sometimes be mistaken for vascular tortuosity. In our case, the pressure on ACI created by the neck mass may be regarded as reason behind the formation of this anomaly but this is not possible due to the fact that the mass is located to the lateral of the sternocleidomastoid muscle.

ACI anomalies are usually asymptomatic (9). They are incidentally detected during surgery or during angiography performed for other reasons. Palpable pulsatile masses in the neck may be taken as one of symptoms (10). But in the presence of causes that would

disrupt blood vessel elasticity, reduction or disappearance of vessel pulsation should be kept in mind. In such cases, in particular, the abnormal ACI may be perceived as a metastatic lymph node during neck dissection (10). When unnoticed, these anomalies may cause fatal complications or complications with a high morbidity rate. ACI anomalies rarely push the lateral pharyngeal wall medial-wards or cause the tonsillary plaque to have a spring-like forward movement (11-12). These anomalies may lead to very unexpected complications even during commonly performed surgical procedures like adenoidectomy, tonsillectomy, and peritonsillar abscess drainage. ACI anomalies in the neck area, however, are recognised more easily because of the wide surgical exposure; in such occasions the risk of injury is quite low (10). Highly resilient and inferior to the digastric muscle, the ACI was recognised and carefully dissected in our case (Figure 1).

A conclusive remark would be to underline the serious life-threatening complications variations ACI anomalies, which are de facto rare, may cause during neck surgery. Therefore, variations and anomalies should always be kept in mind in neck surgeries. In order to avoid potential complications and to prevent morbidity and mortality once such complications are ineluctable, surgeons should be familiar with such cases by developing their professional knowledge and experience. Moreover, careful evaluation of variations of large vessels during preoperative radiological examinations may help surgeons have acquaintance with probable ACI complications while also reducing the risk of further drawbacks.

REFERENCES

1. Arıncı K, Elhan A. *Anatomi 2.cilt. 4. Baskı*. Ankara: Güneş Tıp Kitapevleri; 2006.p. 33-8.
2. Aygenc E, Gür E, Öksüzler Ö, Özdem C. İnternal Karotid Arter Anomalisi: Olgu Sunumu. *KBB ve BBC Dergisi*, 2006;14:72-4.
3. Bussuttil R, Memsic L, Thomas D. Coiling and kinking of the carotid artery. *Vascular Surgery* 1989;2:1406-11.
4. Barbour PJ, Castaldo JE, Rae-Grant AD, Gee W, Reed JF 3rd, Jenny D, et al. Internal carotid artery redundancy is significantly associated with dissection. *Stroke* 1994;25:1201-06.
5. Weibel J, Fields WS. Tortuosity, Coiling, and kinking of the internal karotid artery. Etiology and radiographic anatomy. *Neurology* 1965;15:7-18.
6. Weibel J, Fields WS. Tortuosity, Coiling, and kinking of the internal karotid artery. Etiology and radiographic anatomy. *Neurology* 1965;15:462-8.
7. Leipzig TJ, Dohrman GJ. The tortuous or kinked carotid artery: pathogenesis and clinical considerations. A historical review. *Surg Neurol* 1986;25:478-86.
8. Ozgur Z, Celik S, Govsa F, Aktug H, Ozgur T. A study of the course of the internal carotid artery in the parapharyngeal space and its clinical importance. *Eur Arch Otorhinolaryngol* 2007;264:1483-89.
9. Claros P, Bandos R, Gilea I, Claros A Jr, Capdevila A, Garcia Rodriguez J, et al. Major congenital anomalies of the internal carotid artery: agenesis, aplasia and hypoplasia. *Int J Pediatr Otorhinolaryngol* 1999;49:69-76.
10. Öğretmenoğlu O. Asymptomatic looping of the internal carotid artery: a case report. *Kulak Burun Bogaz İhtis Derg* 2004;12:144-46.

11. Sichel JY, Chisin R. Tortuous internal carotid artery: a rare cause of oropharyngeal bulging diagnosed by magnetic resonance angiography. Ann Otol Rhinol Laryngol 1993;102:964-66.

12. Bektaş D, Caylan R, Korkmaz O, Savaş FS. Acquired and congenital internal carotid artery anomalies in two cases: an important threat for the otolaryngologist. Kulak Burun Bogaz Ihtis Derg 2004;13:35-37.

Received/Başvuru: 21.02.2014, Accepted/Kabul: 31.03.2014

Correspondence/İletişim

Zeliha KORKMAZ DIŞLİ
Malatya State Hospital, Department of
Otorhinolaryngology, MALATYA, TURKEY
E-mail: zelihakorkmazdisli@hotmail.com



For citing/Atıf için

Ocalan R, Ocalan Akin FC, Korkmaz Disli Z, Ozlugedik S, Unal A. Abnormal course of the internal carotid artery in the neck. J Turgut Ozal Med Cent 2014;21:297-9 DOI: 10.7247/jtomc.2014.1820.