



## Telangiectasia Macularis Eruptiva Perstans: A Case Report

Mahmut Sami Metin<sup>1</sup>, Ömer Faruk Elmas<sup>1</sup>, Okan Kızılyel<sup>1</sup>, Betül Gündoğdu<sup>2</sup>, Necmettin Akdeniz<sup>1</sup>

<sup>1</sup>Ataturk University Faculty of Medicine, Department of Dermatological and Veneral Diseases, Erzurum, Turkey

<sup>2</sup>Ataturk University Faculty of Medicine, Department of Medical Pathology, Erzurum, Turkey

### Abstract

Cutaneous mastocytosis is a group of diseases characterized by infiltration of mast cells in the skin. Telangiectasia macularis eruptiva perstans is a rare form of cutaneous mastocytosis and it is usually seen in adults. Round, oval, brown-red macular lesions are usually seen on the trunk. Systemic involvement may be observed in one third of the patients. Treatment depends on the presence of systemic involvement and clinical symptoms of patients. Our patient was a 39 years old man presented with widespread brownish pruritic macular lesions on his trunk and arms. There was no systemic involvement. The patient was diagnosed with telangiectasia macularis eruptiva perstans both clinically and histopathologically. We decided to report this case because telangiectasia macularis eruptiva perstans is an atypical form of cutaneous mastocytosis and is rarely seen.

**Key Words:** Cutaneous Mastocytosis; Systemic Involvement; Telangiectasia Macularis Eruptiva Perstans.

### Telenjektazia makülaris erüptiva perstans: Bir olgu sunumu

### Özet

Kutanöz mastositozlar, deride mast hücre infiltrasyonu ile karakterize hastalık grubudur. Deri lezyonlarına iç organ tutulumu da eşlik edebilir. Telenjektazia makülaris erüptiva perstans, kutanöz mastositozların nadir bir formudur ve genellikle erişkinlerde görülür. Sıklıkla gövdede yuvarlak, oval, kahverengi kırmızı maküler lezyonlar görülür. Olguların üçte birinde sistemik tutulum olabilir. Tedavi, hastalarda sistemik tutulum ve klinik bulguların varlığına göre değişir. 39 yaşındaki erkek hasta gövde ve kollarda yaygın, kahverengi, kaşıntılı maküler lezyonlarla başvurdu. Klinik ve histopatolojik olarak telenjektazia makülaris erüptiva perstans tanısı konan hastada sistemik tutulum saptanmadı. Telenjektazia makülaris erüptiva perstans kutanöz mastositozun atipik bir formu olması ve nadir görülmesi nedeniyle olgumuzu sunmayı uygun gördük.

**Anahtar Kelimeler:** Kutanöz Mastositoz; Sistemik Tutulum; Telenjektazia Makülaris Erüptiva Perstans.

## INTRODUCTION

Macularis telangiectasia eruptiva perstans (TMEP) was first described by Parkes Weber in 1930. It is a rare form of mastocytosis and usually seen in adults though there are reported cases about children effected by TMEP (1-6). The word mastocytosis refers to a group of diseases characterised by infiltration of mast cells in the skin and/or various organs. They have been classified as urticaria pigmentosa, mastocytoma, systemic mastocytosis, TMEP, and diffuse cutaneous mastocytosis (6). TMEP is the kind that is observed in less than 1% of mastocytosis patients. TMEP usually is limited to the skin, especially around the trunk and extremities. Lentil-sized, round or oval, and with borders that are not exactly obvious, telangiectasia containing brown-reddish maculopapular lesions usually accompany TMEP.

In one third of the mastocytosis cases, systemic involvement has been reported. Bone marrow, gastrointestinal tract, liver, spleen, and lymph node involvements are not uncommon either. Mast cell infiltration related flushing, urticaria, abdominal pain, nausea, vomiting, diarrhoea, bone pain, and headache

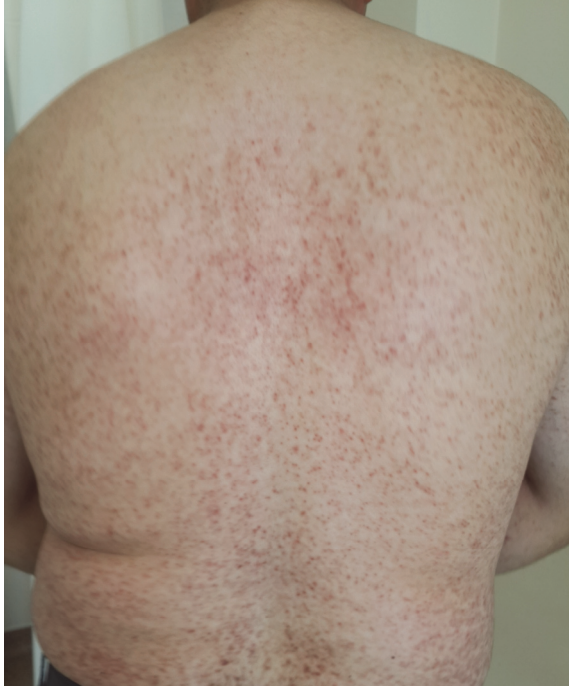are among clinical symptoms of mastocytosis. In addition to the possibility of haematological abnormalities, there are also reports on the relationship between mastocytosis and multiple myeloma and polycythemia vera (7). Therefore, in terms of systemic involvement, patients should be carefully evaluated (8).

In TMEP, histopathologically speaking, mast cell infiltration, particularly concentrated around the vessels, is observed in the papillary dermis. Treatment is symptomatic and there is no established treatment method (1,7).

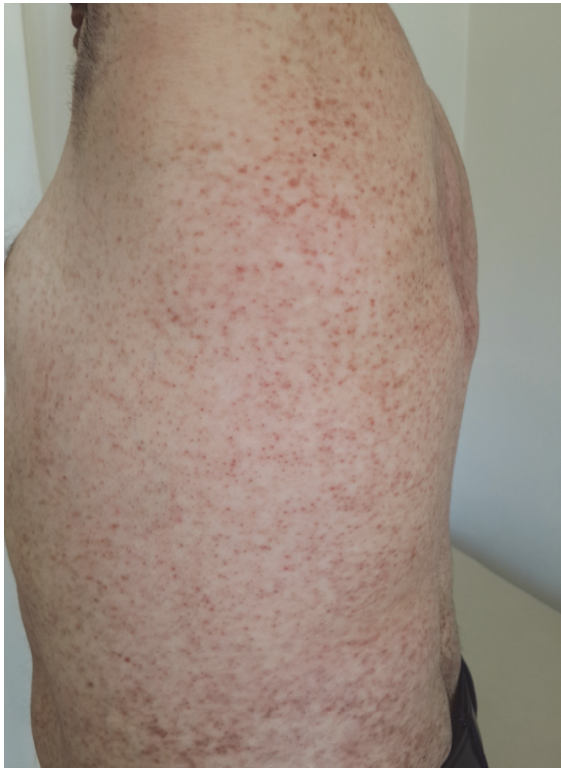## CASE REPORT

A 39 year old male patient was referred to our clinic with spots starting in the back and extending to the trunk and arms for six years. The spots were red at first and they gradually turned brownish. Lesions were rarely itching but once they were, reddened papular lesions occurred due to scratching. The patient's self and family histories were unremarkable. All systems were normal on physical examination. The liver and spleen were non palpable and we did not observe lymphadenopathy. On dermatological examination, there were reddish-brown

maculopapular lesions on the back, chest, axilla, shoulders, and arms (Figure 1-2).



**Figure 1.** Reddish-brown maculopapular lesions on the back, axilla, shoulders, and arms.

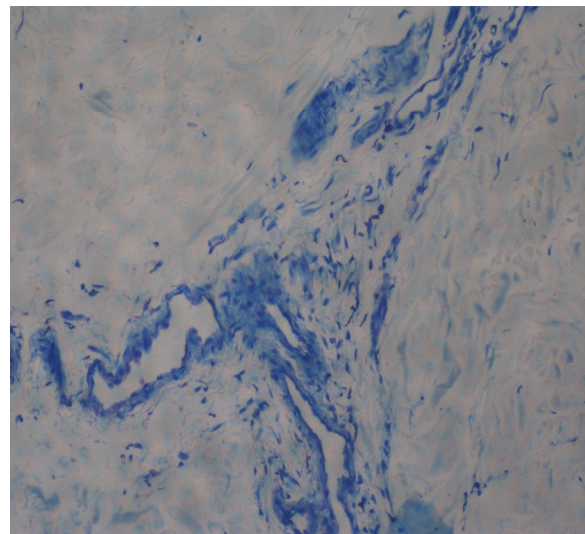


**Figure 2.** Reddish-brown maculopapular lesions on the chest, axilla, and abdominal region.

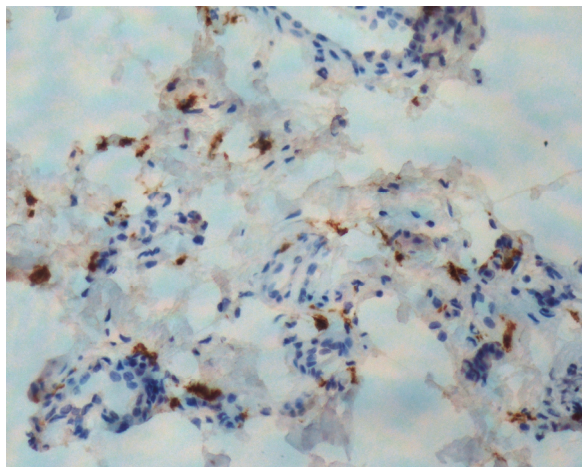
We detected telangiectasias in some of the lesions. Darier's sign was positive. Genital mucosa, oral mucosa, and the skin did not reveal any pathologies. The patient's body temperature was 37.1 ° C. His blood pressure was 130/90 mmHg with a heart rate of 111 bpm, and a respiratory rate of 17 rpm. The test results were as follows: erythrocyte count:  $4,9 \times 10^6/\text{mm}^3$ ; haemoglobin count: 14,5 g/dL; leucocyte count:  $7,8 \times 10^3/\text{mm}^3$ ; thrombocyte count:  $276 \times 10^3/\text{mm}^3$ ; ferritin: 83,4 ng/mL; erythrocyte sedimentation rate: 6 mm/hr; blood urea nitrogen: 15,8 mg/dL; creatinine: 0,7 mg/dL; uric acid: 5,6 mg/dL; AST: 20 U/dL; ALT: 27 U/dL; alkaline phosphatase: 57 U/L; glucose: 85 mg/dL; sodium: 139 mEq/L; potassium: 4,3 mEq/L; calcium: 9,9 mg/dL; phosphor: 6,3 mg/dL; total cholesterol: 182 mg/dL; triglyceride: 212 mg/dL; parathyroid hormone: 38,1 pg/mL; total protein: 8,0 gr/dL; and albumin: 5,0 gr/dL. Peripheral blood smear, urinalysis, prothrombin time, activated partial thromboplastin time were normal. No pathology was detected in the pelvis, vertebrae, ribs, skull, and long bone radiographs. Abdominal ultrasonography showed the liver and the spleen in their regular size. Having normal laboratory and physical examination results, liver biopsy was not considered.

Gastrointestinal tract endoscopy was evaluated as normal. Regarding TMEP as the major option, biopsies were taken from the surface of the back of the patient. In histopathological examination, we identified multi-layered squamous epithelial with acanthoses on the surface and localized mast cell infiltration in the papillary dermis especially concentrating around the veins; the latter has been applied positive staining with toluidine blue and c-kit (Figure 3,4).

TMEP confirmed after the histologic examination, the patient was recommended to take PUVA therapy. However, the patient declined to take the PUVA therapy. We, therefore, gave the patient antihistamines and offered him to attend follow-up examinations.



**Figure 3.** Localised mast cell infiltration stained with toluidin blue positive.



**Figure 4.** Mast cells stained with c-kit positive, particularly concentrated around the veins.

## DISCUSSION

Cutaneous mastocytosis is characterised by the proliferation of mast cells in the skin without the involvement of other organs. TMEP is a rare form of cutaneous mastocytosis and, unlike other forms, mainly affects young adults. Patients often have brown erythematous macules settled on the trunk. These are highly hyperpigmented, telangiectatic macules and share irregular borders. TMEP usually does not bring about itchy lesions and urticaria are smaller in size compared to those in pigmentosa. Darier's sign is not found in most cases (1,6,7). Although usually seen in adults, there are also congenital and familial cases in the literature. Neri et al. reports a TMEP case in a 23-month-old baby, its mother, and grandmother alike (9). Urticarial plaque formation as a result of physical irritation in the lesions is called "Darier's sign." Darier's sign is usually negative in TMEP (6). Darier's sign was positive in our case. 1/3 of the patients with TMEP have been reported to have systemic involvement. The most common reports involve mast cell infiltration in the bone, liver, spleen, lymph nodes, and the gastrointestinal tract (7,8,10). The systemic involvement may increase as patients get older. Systemic involvement may take place within six years or more after the onset of the disease. Therefore patients should be monitored in regular intervals (8). In the majority of patients with skeletal system involvement, radiologically visible bone lesions can be identified. In these cases, lytic, cystic, sclerotic foci, general osteoporotic or osteosclerotic changes can be observed in bone radiographs. In our case, the pelvis, vertebrae, ribs, skull, and long bone radiographs were normal (10,11). Depending on histamine release, flushing, tachycardia, hypertonia or hypotonia can be observed. In the involvement of the gastrointestinal tract, however, nausea, vomiting, abdominal pain, bleeding, diarrhoea, gastric and duodenal ulcers, and steatorrhea are among possible symptoms. We performed endoscopy in the case of our patient but the results did not reveal any pathological findings. In patients with TMEP, anemia, eosinophilia,

leukocytosis, leukopenia, thrombocytopenia, thrombocytosis, basophils, and prolonged prothrombin are among haematological signs (10). In our case, the blood values were within normal limits. 12% of TMEP cases have been reported to have hepatomegaly or splenomegaly. 37% of the patients with systemic involvement, on the other hand, have been reported to have lymphadenopathy (10). We did not detect hepatomegaly, splenomegaly or lymphadenopathy in our patient.

In TMEP, in terms of histopathology, one may observe mast cell infiltration in the papillary dermis, particularly concentrated around the vessels. Mast cells are metachromatically stained by giemsa, toluidine blue, elders stain while they are also immunohistochemically known to show immunoperoxidase positivity to c-kit and CD-68 (7). In our case, especially concentrated around the veins, we found localized mast cell infiltration through c-kit positive and toluidine blue staining. Based on the tests performed, our case was not thought to have any systemic involvement. In the differential diagnosis of TMEP, carcinoid syndrome - in the presence of episodic flushing, and pseudo-allergic food reactions - in the presence of anaphylaxis - should be considered (10,12). In carcinoid syndrome, one can observe persistent erythema on the face and neck and cyanosis, as a result of the chronic dilation of the capillaries and venules. There was no such a clinical view in the case of our patient. To differentiate pseudo-allergic food reactions, histopathological and negative allergy food tests are helpful during the diagnosis process.

Treatment of TMEP patients depends on the presence of systemic involvement and clinical symptoms. Patients should be educated about avoiding factors that increase mast cell disruption such as being exposed to sunlight, extreme temperatures, and alcohol and drug. H1 receptor antagonists like hydroxyzine, loratadine, and doxepin can be used in the treatment of itching and flushing in mastocytosis. Using H1 and H2 receptor blocker antihistamines together, or using mast cell stabilisers such as disodium cromoglycate along with the application of PUVA, 585 nm Dye laser, potent topical corticosteroids and intralesional steroid injections, systemic steroids, leukotriene antagonists, interferon- $\alpha$ 2b, or electron beam treatment are possible treatment options in TMEP. It is known that PUVA therapy blocks mast cell degranulation and is effective in the treatment of skin lesions (7,14). PUVA therapy also gives very good results in relapsed cases. We recommended PUVA therapy to the patient. Rejecting to take the PUVA therapy, we decided to see the patient on follow-ups after giving him H1 and H2 receptor blocker antihistamines. Keeping the possibility of systemic involvement that may arise in the future, we asked the patient to come to the clinic for follow-ups in six-month intervals.

Although initially asymptomatic and insidious, TMEP is a rare form of mastocytosis usually seen in young adults. To improve the quality of life of patients, dermatologists should be tactful to recognise TMEP in early stages.

## REFERENCES

1. Soter NA. The skin in mastocytosis. *J Invest Dermatol* 1991;96:32-9.
2. Soter NA. Mastocytosis and the skin. *Hematol Oncol Clin North Am* 2000;14:537-55.
3. Kalayciyan AK, Kotoğyan A. Telangiectasia macularis eruptiva perstans. *J Eur Acad Dermatol Venerol* 2001;15:263-4.
4. Rishpon A, Matz H, Gat A, Brenner S. Telangiectasia macularis eruptiva perstans: unusual presentation and treatment. *Skinmed* 2006;5:300-2.
5. Sarkany RP, Monk BE, Handfield-Jones SE. Telangiectasia macularis eruptiva perstans: a case report and review of the literature. *Clin Exp Dermatol* 1998;23:38-9.
6. Gibbs NF, Friedlander SF, Harpster EF. Telangiectasia macularis eruptiva perstans. *Pediatr Dermatol* 2000;17:194-7.
7. Sotiriou E, Apalla Z, Ioannides D. Telangiectasia macularis eruptiva perstans successfully treated with PUVA therapy. *Photodermatol Photoimmunol Photomed* 2010;26:46-7.
8. K k am İ, Saral Y, Yavrucuođlu E, Sađlam S, Yılmaz Ő, Uyar B. Telangiectasia macularis eruptiva perstans (urticaria pigmentosa adultorum). *T Klin J Dermatol* 1997;7:203-7.
9. Neri I, Guareschi E, Guerrini V, Patrizi A. Familial telangiectasia macularis eruptiva perstans. *Pediatr Dermatol* 2005;22:488-9.
10. Yıldırım M, Baysal V,  zt rk H, Sarı A. Telenjektazia Mak laris Er ptiva Perstans: Bir Olgu Sunumu. *T Klin Tıp Bilimleri* 2002;22:193-5.
11. Metcalfe DD. The mastocytosis syndrome. In: Fitzpatrick TB, Eisen AZ, Wolf K, Freedberg IM, Austton KF, eds. *Dermatology in General Medicine*. 5th edition. New-york, McGraw-Hill Book Company; 1998. P.1902-7.
12. Vidal C, del Rio E, Su rez-Pe aranda J, Armis n M. Telangiectasia macularis eruptiva perstans presented as a pseudoallergic food reaction. *J Investig Allergol Clin Immunol* 2000;10:248-50.
13. Costa DL, Moura HH, Rodrigues R, Pineiro-Maceira J, Ramos-E-Silva M. Telangiectasia macularis eruptiva perstans: a rare form of adult mastocytosis. *J Clin Aesthet Dermatol* 2011;4:52-4.

Received/Başvuru: 30.10.2013, Accepted/Kabul: 06.01.2013

### Correspondence/İletişim

Okan KIZILYEL  
Ataturk University Faculty of Medicine, Department of  
Dermatological and Veneral Diseases, ERZURUM, TURKEY  
E-mail: erester.34@hotmail.com

### For citing/Atıf için

Metin MS, Elmas OF, Kızılyel O, Gundogdu B, Akdeniz N.  
Telangiectasia macularis eruptiva perstans: a case report. *J  
Turgut Ozal Med Cent* 2014;21:229-32 DOI:  
10.7247/jtomc.2013.1461