




Original Article / Araştırma Makalesi

MORPHOMETRIC COMPARISON OF DIFFERENT RADIAL HEAD TYPES

Farklı Radius Başlı Tiplerinin Morfometrik Karşılaştırılması

Deniz ŞENOL¹  Fatih ÇAVUŞ²  Furkan ÇEVİRGEN³ 

Muhammed Furkan ARPACI⁴  Davut ÖZBAĞ⁵ 

¹Düzce University, Faculty of Medicine, Düzce

^{2,3,4,5}Inonu University, Faculty of Medicine, Malatya

Geliş Tarihi / Received: 11.11.2020

Kabul Tarihi / Accepted: 26.12.2020

Yayın Tarihi / Published: 25.03.2021

ABSTRACT

The aim of this study is to determine morphometric measurements difference of radial head (RH) types. 49 dry radial bones were included in the study. After determining the types of radius, morphometric measurements were made with digital calliper. The parameters were determined as the length of radius, height of the radius, transverse diameter of RH, anterior-posterior diameter of RH, radial tuberosity transverse diameter and height, length and transverse diameter of ulnar notch. As the result of RH classification, it has been determined that; 20 bones had irregular, 15 bones had oval and 14 bones had round type. In order to on all group average; radius length of RH, the height of RH, transverse diameter of RH, anteroposterior diameter of RH were calculated as 207.99±21.97 mm, 9.45±1.68 mm, 19.94±3.15 mm, 20.20±3.09 mm respectively. In order to on all group average; transverse diameter of radial tuberosity, height of radial tuberosity, the height of ulnar notch, transverse diameter of ulnar notch were 12.07±1.3 mm, 25.36±2.78 mm, 13.86±1.56 mm, 5.27±0.8 mm respectively. According to the results of One Way Anova analysis, no statistically significant difference was found between RH types (p>0.05). No statistically significant difference was found between RH types in all parameters.

Keywords: Morphometry, Orthopedic, Radial Head Types

ÖZ

Bu çalışmanın amacı radius başı (RB) tiplerinin morfometrik ölçüm farklılıklarını belirlemektir. Çalışmaya 49 kuru radius kemiği dahil edildi. Radius tipleri belirlendikten sonra dijital kumpas ile morfometrik ölçümler yapıldı. Parametreler; radius uzunluğu, radius yüksekliği, RB'nin enine çapı, RB'nin ön-arka çapı, tuberositas radii'nin enine çapı ve yüksekliği, incisura ulnaris'in uzunluğu ve enine çapı olarak belirlendi. RB sınıflandırmasında sonuç olarak; 20 kemiğin düzensiz, 15 kemiğin oval ve 14 kemiğin yuvarlak tipte olduğu belirlendi. Tüm grup ortalamaları; RB uzunluğu, RB yüksekliği, RB transvers çapı, RB ön-arka çapı için sırasıyla 207,99± 21,97 mm, 9,45±1,68 mm, 19,94±3,15 mm, 20,20±3,09 mm. olarak hesaplandı. Tüm grup ortalamaları; tuberositas radii enine çapı ve tuberositas radii yüksekliği, incisura ulnaris'in yüksekliği, incisura ulnaris'in enine çapı için sırasıyla 12,07±1,3 mm, 25,36±2,78 mm, 13,86±1,56 mm, 5,27±0,8 mm olarak hesaplandı. One Way Anova analizi sonuçlarına göre, RB tipleri arasında istatistiksel olarak anlamlı bir fark bulunmadı (p>0,05). Tüm parametrelerde RB tipleri arasında istatistiksel olarak anlamlı bir fark bulunmadı (p>0,05).

Anahtar kelimeler: Radius Başlı Tipleri, Morfometri, Ortopedi

INTRODUCTION

The radius bone has very important functions in making complex movements, harmony with the joint faces it creates and joint movements of the wrist and elbow. In general, there is no distinction between radial neck and radial head (RH) fractures in the literature, but they do not actually express the same situation (Leung & Peterson, 2000; Zimmerman, Kalish, Hresko, Waters, & Bae, 2013). A good command of the anatomy of the proximal radius is very important in understanding fractures. Fractures may not be detected before the early ossification or ossification of the head of radius (Nicholson & Skaggs, 2019). Radial neck fractures are much more common when compared to RH fractures. RH fractures usually occur after closure of the proximal physis, as a result of particularly weak intra-articular injuries (Leung & Peterson, 2000; Zimmerman et al., 2013). Annular ligament of radius wraps around the epiphyseal plate and blends into the joint capsule extending to the proximal metaphysis (Peterson, 2007). The authors think that this strong limited structure protects the underlying physis and produces a stress factor in the metaphysis, and therefore fractures occur more in this area than in the weak physis. There is less healing potential for proximal radial fractures, because 75% of radial growth is derived from distal radial physis. This point should not be ignored in older pediatric cases (Noonan & Price, 1998).

Although there are many studies about the RH in the literature, there are very few studies that draw attention to the relationship between the proximal radius and the RH (Koslowsky et al., 2007; Popovic, Djekic, Lemaire, & Gillet, 2005). In addition, there is no gender discrimination or an equal distribution in terms of gender (Roidis et al., 2003; Swieszkowski, Skalski, Pomianowski, & Kedzior, 2001).

For the construction of RH prostheses, it is necessary to know the shape and size of the head of radius. RH and neck fractures compose 1.7- 5.4 % of all radius fractures. Unstable and displaced fractures of the RH are almost always associated with a complex injury (Caputo, Mazzocca, & Santoro, 1998). This study has investigated different types of RH morphometry. The aim was to provide an idea to orthopedic surgeons before surgery for implant applications and prosthesis modeling according to different morphometrics.

MATERIAL AND METHOD

Measurements were taken from radius bones with different RH types which were found in Duzce and Inonu University Faculty of Medicine Department of Anatomy. Morphometric measurements of 49 radial bones were made in total (Figure 1). 2020/1064 numbered

permission was taken from Inonu University Non-Invasive Clinical Investigation Ethical Committee. Morphometric measurements were taken with digital calliper. After determining radius bones; 13 bones which had incomplete ossification and deformity were excluded from this study. The parameters were measured in supinated and semi-pronated position.




Figure 1: Radial Head Types **A:** Irregular Type **B:** Oval Type **C:** Round Type

1) Length of radius (L): The length of radii was measured as the interval between the tip of styloid process and the most lateral part of RH (Gupta, Kalthur, Malsawmzuali, & D'souza, 2015).

2) Height of radial head: The height of RH was measured as the interval between the top of radial head to neck of radius origin (Figure 2), (Gupta et al., 2015).

3) Height of radial tuberosity: The distance between maximum transverse width is named the transverse diameter of radial tuberosity (Figure 2), (Gupta et al., 2015).

4) The transverse diameter of radial tuberosity: The distance between maximum vertical width of radial tuberosity is named the height of radial tuberosity (Figure 2), (Gupta et al., 2015).



Figure 2: Radius Measurements; **1.** Length of Radius, **2.** Height of Radial Head, **3.** Height of Radial Tuberosity, **4.** The Transverse Diameter of Radial Tuberosity

5) Anteroposterior diameter diameters of radial head: The distance between maximum anteroposterior length and maximum transverse length of RH (Figure 3), (Gupta et al., 2015).

6) Transverse diameter of radial head: The distance between maximum transverse length of RH (Figure 3), (Gupta et al., 2015).




Figure 3: Measurements of Radial Head;

5. Anterior- Posterior Diameter of Radial Head **6.** Transverse Diameter of Radial Head

7) The transverse diameter: The distance between maximum transverse width of ulnar notch is named transverse diameter of ulnar notch (Figure 4), (Gupta et al., 2015).

8) Length of ulnar notch: The distance of maximum vertical width of ulnar notch is named the length of ulnar notch (Figure 4), (Gupta et al., 2015).

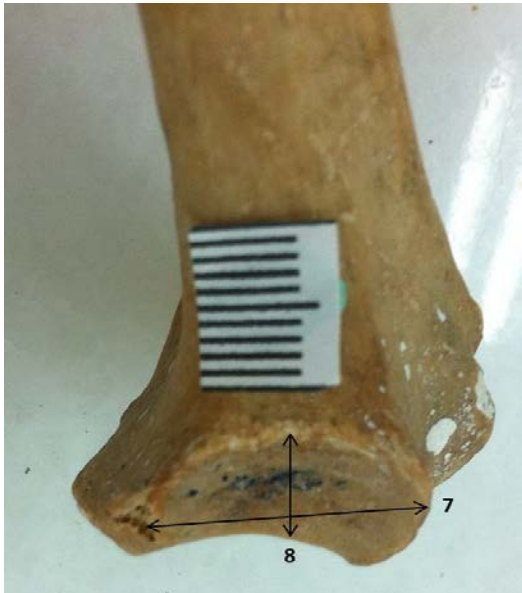

Figure 4: Ulnar Notch Measurements;

7. The Transverse Diameter of Ulnar Notch **8.** Length of Ulnar Notch

Statistical analysis

The compliance of the data to the normal distribution was examined with the Kolmogorov Smirnov test. Mean (\pm sd), minimum (min) and maximum (max) values of the data were given.

One Way Anova test was applied to the data to compare the RH types. Values of $p < 0.05$ were considered significant. IBM SPSS Statistics 22.0 for Windows package program was used for statistical analysis.

RESULT

This study has demonstrated the most common RH types as; round (14 bones) in 28.6% of bones, oval (15 bones) in 30.6%, and irregular (20 bones) in 40.8% of bones. Average radius measurements of irregular RH bones are shown in Table 1.

Table 1. Average Measurements of Irregular Radial Head Bones

Measurements	Mean±sd	Min-Max
Length of radius	213.91±22.49	190.31-272.55
Height of RH*	10.03±2.01	7.79-14.86
Transverse diameter of RH	19.43±3.25	16.75-24.94
Ant-post** diameter	19.64±3.19	16.53-25.36
Transverse diameter of tuberositas radii	12.23±1.55	10.11-15.06
Height of tuberositas radii	53.92±10.50	36.62-69.73
Height of inc.*** ulnaris	13.45±1.61	10.32-15.21
Transverse diameter inc. ulnaris	5.19±0.84	4.22-6.75

*RH: radial head, **Ant-post: Anterior posterior, ***inc: incisura

Average radius measurements of oval radial head bones are shown in Table 2.

Table 2. Average Measurements of Oval Radial Head Bones

Measurements	Mean±sd	Min-Max
Length of radius	199.69±19.71	181.11-238.53
Height of RH*	8.83±1.10	7.53-11.33
Transverse diameter of RH	21.09±2.73	17.37-24.14
Ant-post** diameter	21.45±2.47	18.13-24.49
Transverse diameter of tuberositas radii	12.08±1.05	10.44-13.74
Height of tuberositas radii	58.01±12.11	41.66-77.89
Height of inc***. ulnaris	14.69±1.49	13.03-16.93
Transverse diameter inc. ulnaris	5.41±0.82	3.62-6.25

*RH: radial head, **Ant-post: Anterior posterior, ***inc: incisura

Average radius measurements of round radial head bones are shown in Table 3.

Table 3. Average Measurements of Round Radial Head Bone

Measurements	Mean±sd	Min-Max
Length of radius	206.49±23.18	180.93-233.96
Height of RH*	9.07±1.36	7.01-10.63
Transverse diameter of RH	19.50±3.54	14.39-23.89
Ant-post** diameter	19.74±3.53	14.46-24.15
Transverse diameter of tuberositas radii	11.76±1.17	10.32-13.76
Height of tuberositas radii	51.51±12.39	36.15-70.62
Height of inc***. ulnaris	13.61±1.38	11.89-15.49
Transverse diameter inc. ulnaris	5.27±0.82	4.27-6.54

*RH: radial head, **Ant-post: Anterior posterior, ***inc: incisura

In order to on all groups; average radius length of RH, the height of RH, transverse diameter of RH, anteroposterior diameter of RH were calculated as 207.99 ± 21.97 mm, 9.45 ± 1.68 mm, 19.94 ± 3.15 mm, 20.20 ± 3.09 mm respectively.

In order to on all group averages; transverse diameter of radial tuberosity, height of radial tuberosity, the height of ulnar notch, transverse diameter of ulnar notch were 12.07 ± 1.3 mm, 25.36 ± 2.78 mm, 13.86 ± 1.56 mm, 5.27 ± 0.8 mm respectively.

According to the results of One Way Anova analysis, no statistically significant difference was found between RH types in all parameters (Table 4), ($p > 0.05$).

Table 4. The Difference Analyze of Evaluation on Parameters of RH Types

Measurements	p
Length of radius	0.361
Height of RH*	0.235
Transverse diameter of RH	0.487
Ant-post** diameter	0.413
Transverse diameter of tuberositas radii	0.766
Height of tuberositas radii	0.543
Height of inc***, ulnaris	0.205
Transverse diameter inc. ulnaris	0.842

*RH: radial head, **Ant-post: Anterior posterior, ***inc: incisura

DISCUSSION

This study measured proximal radius bones, and the results indicated that there was no significant difference between oval, round and irregular RH types. Some articles have reported the significance of accurate measurement of the RH while performing prosthesis implantation (Tejwani & Mehta, 2007). After elbow fracture treatment, correct implant size is essential to prevent subluxation of RH (Puchwein, Heidari, Dorr, Struger, & Pichler, 2013).

Captier et al. reported that radius was elliptical in 57% head of and round in 43% (Captier, Canovas, Mercier, Thomas, & Bonnel, 2002). This study indicated the most common RH types as; round in 26%, oval in 29.6%, and irregular in 44.4% of bones. The oval and round types of RH rates are similar in Captier et al's and in this study. Captier et al. also reported that biomechanics of oval and round RH types were dissimilar, these involved the structure of the angle between the radial neck and the radial diaphysis (Captier et al., 2002).

The importance of biomechanics must be taken into account in the construction of RH prosthesis. Puchwein et al. reported the mean RH length on medial-lateral sides as 11.7 and 11.8 mm, while this study measured the average RH height values as 9.45 mm (Puchwein et al., 2013). This difference could have occurred from the bones chosen by randomization.

Captier et al and Puchwein et al. reported the mean anteroposterior diameter of the RH at its most wide portion as 21.6 mm and 23 mm and in the transverse plane as 21 and 22.4 mm, respectively (Captier et al., 2002; Puchwein et al., 2013). In this study, anterior-posterior diameter was measured as 20.20 mm, while transverse diameter was measured as 19.94 mm. These values indicate that the values of RH are similar; thus, the results of this study support Captiar and Puchwein's studies.

Gupta et al found the average length of radius bone, RH's height at lateral and medial tips, anteroposterior, transverse diameter of RH to be 235 mm, 9 mm, 7.5 mm, 19.1 mm, 18.5 mm, respectively (Gupta et al., 2015). In this study, the values were 207.99 mm for length of radius, 9.45 mm for height of RH, 20.20 mm for anterior-posterior diameter and 19.94 mm for transverse diameter. The results of Gupta's study and this study are similar.

Van Riet et al. reported the average radial length as 235 mm and in this study average radius length was measured as 207.99 mm (Van Riet et al., 2004). Mazzocca et al. reported the average length and width of radial tuberosity as 22 and 15 mm, respectively (Mazzocca et al., 2007). In this study, we measured the average length and width of radial tuberosity as 25.36 mm and 12.07 mm. These minimal differences could be due to the society difference. These dimensions of the radial tuberosity, RH values are essential in various surgical procedures such as RH reconstruction and surgery at trauma of proximal radius and prosthesis implantation. New modular designs have improved copying the anatomy of the proximal radius bone, and these designs have become easier to place intraoperatively (Chien, Chen, Huang, Cheng, & Hsu, 2010). Giannicola et al. reported that osteosynthesis of RH and neck fractures should be done in reliable zone, where a plate could be implemented without risking the proximal radioulnar joint. Thus, the surgeons will bend the radius bone on the safe zone and this will allow them to choose the most appropriate plate and succeed in well reduction and anatomical restoration of the proximal of the radius bone (Giannicola et al., 2012).

Thus, this study measured and classified different RH types to determine safe zone values.

CONCLUSION

In this investigation we concluded that these datas will be valuable in both orthopedic surgery and prosthetics applications on radial bone.

The authors declared no conflict of interest.

The authors declared that this study received no financial support.

REFERENCES

- Captier, G. Canovas, F. Mercier, N. Thomas, E. Bonnel, F. (2002). *Biometry of the radial head: biomechanical implications in pronation and supination. Surg Radiol Anat, 24, 295-301.*
- Caputo, A.E. Mazzocca, A.D. Santoro, V.M. (1998). *The nonarticulating portion of the radial head: Anatomic and clinical correlations for internal fixation. J Hand Surg Am, 23, 1082-1090.*
- Chien, H.Y. Chen, A.C. Huang, J.W. Cheng, C.Y. Hsu, K.Y. (2010). *Short- to Medium term outcomes of radial head replacement arthroplasty in posttraumatic unstable elbows: 20 to 70 months follow-up. Chang Gung Med J, 33, 668-678.*
- Giannicola, G. Manauzzi, E. Sacchetti, F.M. Greco, A. Bullitta, G. Vestri, A. Cinotti, G. (2012). *Anatomical variations of the proximal radius and their effects on osteosynthesis. J Hand Surg Am, 37, 1015-1023.*
- Gupta, C. Kalthur, S.G. Malsawmzuali, J.C. D'Souza, A.S. (2015). *A morphological and morphometric study of proximal and distal ends of dry radii with its clinical implications. Biomed J, 38(4), 323-328.*
- Koslowsky, T.C. Beyer, F. Germund, I. Mader, K. Krieglstein, C.F. Koebke, J. (2007). *Morphometric parameters of the radial neck: an anatomical study. Surg Radiol Anat, 29, 279-284.*
- Leung, A.G. Peterson, H.A. (2000). *Fractures of the proximal radial head and neck in children with emphasis on those that involve the articular cartilage. J Pediatr Orthop, 20, 7-14.*
- Mazzocca, A.D. Cohen, M. Berkson, E. Nicholson, G. Carofino, B.C. Arciero, R. Romeo, A.A. (2007). *The anatomy of the bicipital tuberosity and distal biceps tendon. J Shoulder Elbow Surg, 16, 122-127.*
- Nicholson, L.T. Skaggs, D.L. (2019). *Proximal Radius Fractures in Children. J Am Acad Orthop Surg, 1, 27(19), e876-e886.*
- Noonan, K.J. Price, C.T. (1998). *Forearm and distal radius fractures in children. J Am Acad Orthop Surg, 6, 146-156.*
- Peterson HA. (2007). *Proximal radius. in: Peterson HA, ed: Epiphyseal Growth Plate Fractures (ss.695). New York: Springer Berlin Heidelberg.*
- Popovic, N. Djekic, J. Lemaire, R. Gillet, P. (2005). *A comparative study between proximal radial morphology and the floating radial head prosthesis. J Shoulder Elbow Surg, 14, 433-440.*
- Puchwein, P. Heidari, N. Dorr, K. Struger, L. Pichler, W. (2013). *Computer aided analysis of radial head morphometry. Orthopedics, 36, e51-57.*
- Roidis, N. Stevanovic, M. Martirosian, A. Abbott, D.D. Mc Pherson, E.J. Itamura, JM. (2003). *A radiographic study of proximal radius anatomy with implications in radial head replacement. J Shoulder Elbow Surg, 12, 380-384.*
- Swieszkowski, W. Skalski, K. Pomianowski, S. Kedzior, K. (2001). *The anatomic features of the radial head and their implication for prosthesis design. Clin Biomech (Bristol, Avon), 16, 880-887.*
- Tejwani, N.C. Mehta, H. (2007). *Fractures of the radial head and neck: current concepts in management. J Am Acad Orthop Surg, 15, 380-387.*
- Van Riet, R.P. Van Glabbeek, F. Neale, P.G. Bimmel, R. Bortier, H. Morrey, B.F., ...An, K.N. (2004). *Anatomical considerations of the radius. Clin Anat, 17, 564-569.*
- Zimmerman, R.M. Kalish, L.A. Hresko, M.T. Waters, P.M. Bae, D.S. (2013). *Surgical management of pediatric radial neck fractures. J Bone Joint Surg Am, 95, 1825-1832.*