

Percutaneous Hydatid Cyst Treatment in Children: Technical Differences and Long-Term Follow-Up Results

Çocuklarda Perkütan Kist Hidatik Tedavisi: Teknik Farklılıklar ve Uzun Dönem Takip Sonuçları

Gulsah BAYRAM ILIKAN

Ankara City Hospital Children Hospital, Department of Radiology, Ankara, Turkey



ABSTRACT

Objective: To evaluate efficacy, safety and the long-term results of percutaneous imaging-guided treatment of hydatid cysts (HC) in children and to discuss the differences of applied percutaneous interventional techniques.

Material and Methods: Our retrospective study was conducted with the approval of the local ethics committee. Between October 2009 and April 2014, 34 children (22 female, 12 male; mean age 9.1±3.2 years) with type WHO-CE 1 and CE 3a, 60 HC underwent percutaneous treatment. For 32 cysts smaller than 6 cm in longest diameter the method of treatment was ‘Puncture, Aspiration, Injection, Reaspiration’ (PAIR), for 28 cysts with diameters larger than 6 cm the method of treatment was catheterization. Catheter was leaved to free drainage in 16 cysts, out of which 12 was ended in single session. All patients were followed first month and every 3 months during the 1st year, every 6 months during the 2nd year, and after then yearly.

Results: Thirty two cysts with a diameter of less than 6 cm were treated with the PAIR method, and 28 cysts with a diameter greater than 6 cm were treated with catheterization method. While the catheter was left in free drainage in 16 cysts, the catheter was removed at the end of the procedure in 12 cysts, and the treatment was terminated in one session. Percutaneous treatment of HC was successful in all patients. Mean volume reduction was 74.6% with PAIR, 78.7% with single session catheterization, and 57.9% in catheterization – free drainage methods. The most potent method is single session drainage followed by catheterization – drainage and lastly PAIR ($p < 0.000$). Mean of hospitalization periods were 16 hours for both of those patients treated with the PAIR technique, and single session catheterization, 2.1 days for the patients treated by catheterization – free drainage. The mean follow-up was 93.6 months.

Conclusion: Percutaneous HC treatment is a highly efficient, successful and safe procedure. Percutaneous treatment should be preferred in WHO CE type 1 and 3a cysts especially in pediatrics. Performing the catheterization without keeping it in the cavity makes it advantageous in pediatrics because of convenience of approach, low pain, high patient adherence, and short hospitalization period.

Key Words: Children, Hydatid Cyst, Percutaneous Treatment

ÖZ

Amaç: Çocuklarda perkütan yöntemle kist hidatik tedavisinin etkinliğinin, güvenilirliğinin ve uzun dönem takip sonuçlarının değerlendirilmesi, uygulanan perkütan girişim tekniklerinin farklılıklarının tartışılması amaçlandı.

Gereç ve Yöntemler: Retrospektif olan çalışmamız hastanemiz akademik kurullundan onayı alınarak yapıldı. Çalışmaya, Ekim 2009 ve Nisan 2014 tarihleri arasında perkütan tedavi uygulanan WHO tip 1 ve 3a, toplam 60 kisti bulunan, 34 çocuk hasta (22 kız, 12 erkek; ortalama yaşları 9.1±3.2 yıl) dahil edildi. Çapı 6 cm’den küçük kistler ‘Puncture, Aspiration, Injection, Reaspiration’ (PAIR) yöntemi ile, 6 cm’den büyük kistler kataterizasyon yöntemi ile (tek seansta



BAYRAM ILIKAN G : 0000-0001-5833-022X

Conflict of Interest / Çıkar Çatışması: On behalf of all authors, the corresponding author states that there is no conflict of interest.

Ethics Committee Approval / Etik Kurul Onayı: The study was conducted with the approval of our hospital’s academic board.

Contribution of the Authors / Yazarların katkısı: BAYRAM ILIKAN G: Constructing the hypothesis or idea of research and/or article, Planning methodology to reach the Conclusions, Organizing, supervising the course of progress and taking the responsibility of the research/study, Taking responsibility in patient follow-up, collection of relevant biological materials, data management and reporting, execution of the experiments, Taking responsibility in logical interpretation and conclusion of the results, Taking responsibility in necessary literature review for the study, Taking responsibility in the writing of the whole or important parts of the study, Reviewing the article before submission scientifically besides spelling and grammar.

How to cite / Atıf yazım şekli : Bayram Ilıkan. Percutaneous Hydatid Cyst Treatment in Children: Technical Differences and Long-Term Follow-Up Results. Turkish J Pediatr Dis 2021;15: 52-58.

Correspondence Address / Yazışma Adresi:

Gulsah BAYRAM ILIKAN

Ankara City Hospital Children Hospital, Department of Radiology, Ankara, Turkey
E-posta: gulsahbayram@hotmail.com

Received / Geliş tarihi : 11.11.2020

Accepted / Kabul tarihi : 07.01.2021

Online published : 20.01.2021

Elektronik yayın tarihi

DOI: 10.12956/tchd.824540

veya kataterin serbest drenaja bırakılması şeklinde) tedavi edildi. Hastalar işlem sonrası 1. ay, ilk yıl 3 ayda bir, ikinci yıl 6 ayda bir ve sonra yıllık kontrollere çağrıldı.

Bulgular: Çapı 6 cm'den küçük 32 kist PAIR yöntemi ile, 6 cm'den büyük 28 kist ise kateterizasyon yöntemi ile tedavi edildi. On altı kistte katater serbest drenaja bırakılırken, 12 kistte işlem sonunda kateter çekilerek tedavi tek seansta sonlandırıldı. Perkütan tedavi tüm kist hidatiklerde başarı ile sonuçlandı. Ortalama volüm kaybı PAIR yönteminde %74.6, tek seans kateterizasyonda %78.7, serbest drenaja bırakılmış kateterizasyonda ise % 57.9'du. Tek-seans kateterizasyon en etkin yöntem olarak saptandı ve bunu sırasıyla kateterizasyon ve PAIR yöntemleri izledi ($p<0.000$). Ortalama hastanede kalış süresi PAIR ve tek seans kateterizasyon yöntemlerinde 16 saat, serbest drenaja bırakılmış kateterizasyon yönteminde ise 2.1 gündü. Ortalama takip süresi 93.6 aydı.

Sonuç: Perkütan kist hidatik tedavisi oldukça etkin, başarılı ve güvenilir bir yöntemdir. Özellikle çocuklarda, tip 1 ve tip 3a kistlerde tercih edilmelidir. İşlem sırasında konforu, işlem sonrası ağrının azlığı, yüksek hasta uyumu nedeniyle tek seans kateterizasyon çocuklarda oldukça avantajlıdır.

Anahtar Sözcükler: Çocuk, Kist hidatik, Perkütan tedavi

INTRODUCTION

Hydatid cyst (HC) disease is a medical treatment-resistant infestation, still having endemic regions over the world and in our country (1,2). Because of the high incidence, HC is a serious problem in children in our country (3).

Especially in abdominal HC disease, percutaneous interventional approach is the most preferred management modality in selected cases because of low morbidity, mortality and cost – benefit rates. Percutaneous therapy (PT) is suggested by expert panel of World Health Organization- Informal Working Group on Echinococcosis (WHO – IWGE) in first line in patients with CE1 (Cystic Echinococcosis type 1) and CE3a (Cystic Echinococcosis type 3a) cysts, and those not accepting surgery, as well as previously operated cases (4). PAIR ‘Puncture, Aspiration, Injection, Reaspiration’ method, catheterization-followed by free drainage and single session catheter drainage are percutaneous treatment methods that have been defined.

Purpose of this study is to evaluate efficacy, safety and the long-term results of percutaneous imaging-guided treatment of hydatid liver cysts in children and to reveal the differences of applied percutaneous interventional techniques, including single session catheterization, and catheterization followed by free drainage.

MATERIALS and METHODS

Patient population

The study was conducted with the approval of our hospital's academic board. The details of PT were explained to the patients, and/or their parents, and written informed consent was obtained before therapy.

This retrospective study included 34 consecutive patients (12 male/22 female, mean age 10.3 ± 3.7 , age ranges 4-17 years) with 60 HC (WHO CE1 [n=56] and CE 3a [n=4]) who underwent percutaneous interventional radiologic treatment for HC

between October 1, 2009 and April 1, 2014 (5). The diagnoses of the patients were made by US examination performed by an interventional radiologist (GBI) who has approximately 15 years of experience in hydatid cysts. The diagnosis was confirmed by observing an anechoic cyst (WHO CE1) with a stretched wall due to its pressurized content, or a cystic structure with a collapsed germinative membrane (WHO CE3a). Five cysts were extrahepatic extra-hepatic localization (mesenteric [n = 2], renal [n=1], adrenal [n = 1], and splenic [n=1]), 55 cysts were hepatic localization (Table I). Although localizations were different, same PT techniques were applied to all cysts (6,7). None of the cysts subject to this study underwent surgery before the episode of PT. Prophylactic Albendazole (Andazol®, Biyofarma, İstanbul, Turkey) treatment was initiated 1 week before and continued till 6 months after the procedure, with monthly control of liver function tests. Also, prophylactic antibiotherapy (single dose cephalosporine) was given to all patients before the PT. Indirect hemagglutination test was performed in all patients of which 26 % (9/34) of results were negative. Exclusion criteria for the patients in the study included a) having active multivesicular and/or semisolid cysts (WHO CE 2, 3b) and inactive (WHO CE 4, 5) cysts and b) inadequate follow – up after treatment.

Interventional Procedure

All interventions were performed with ultrasound (US) (Hitachi, Preirus) and fluoroscopy (Mindray, DC-3) guidance and operating room conditions. Intravenous midazolam and propofol were administered for deep sedation and analgesia by the anesthesiology team under continuous monitoring. Local anesthesia was implemented using Bupivacain.

PAIR technique described by Ben Amor et al. (8) After US – guided puncture with an 18–20 gauge puncture needle, cyst content was aspirated. Under fluoroscopic guidance 5–10 cc contrast was injected to the cyst cavity to check for the presence of biliary communication. If there had been no communication, fluid content was almost totally aspirated. 20% hypertonic saline solution at 30–50% the volume of the initial cyst cavity was injected into the cavity under fluoroscopic control. After 6 – 10 minutes of waiting, the maximum possible amount of fluid was re-aspirated. At last step, 96% ethanol at 30–50% of

the volume of the initial cyst was injected into the cavity and re-aspirated after 5 minutes and the needle was withdrawn.

For cysts with diameters larger than 6 cm the method of treatment was catheterization. After US-guided puncture with an 18–20 gauge puncture needle, a 6 Fr or 8 Fr pigtail catheter (Flexima™, Boston Scientific, USA) was placed into the cavity over the guide wire (Amplatz guide wire, pbn Medicals, Denmark). PAIR method was applied after the catheter was placed. While the catheter was left in free drainage in some of the patients (catheterization-free drainage), the procedure was terminated by pulling the catheter in others (single session catheterization).

In the first years, we left the catheter in free drainage in all patients we catheterized. However, we experienced some difficulties in pediatric patients tolerating the catheter. Pain, prolonged hospital stays, and catheter dislocation, especially in younger patients, were some of these difficulties. Considering the success rates in studies in which single session catheterization was applied in the literature, we performed the procedure in single session in all patients we applied catheterization in recent years and we did not leave the catheter in free drainage (9).

After initial fluid aspiration, observation of clear fluid under high pressure and detachment of endocyst from pericyst after puncture or during waiting period with saline solution, were highly suggestive of viability of hydatid cyst (10,11). The initially aspirated cyst content was examined for fragments of germinal membrane, hooklets, and scoleces or daughter cysts and the diagnosis was confirmed cytologically. Criteria for the cure after treatment were either total or more than 50 % volume reduction, and gaining semi-solid (heterogeneous) appearance.

All patients were followed first month and every 3 months during the 1st year, every 6 months during the 2nd year, and after then yearly. An US examination was performed at every follow-up, and changes in cyst volume and morphology were recorded.

Statistical analysis

Continuous data that were expressed as the mean \pm standard deviation (SD) or median (interquartile range) were analyzed using a t-test or Mann-Whitney U test. Categorical data that were expressed as numbers with percentages were compared using a χ^2 , McNemar or Fisher's exact test. Binary logistic regression analysis was performed to identify compare the therapeutic efficacy of 3 methods. The reason for this test was the possible bias caused by significantly different pre-treatment cyst volumes that could affect the results of the t test without correcting for this confounding factor. Statistical analysis was conducted with statistical software (SPSS, version 18.0; SPSS Inc, Chicago, IL, USA). Results were considered statistically significant at $p < 0.05$.

Table I: Demographic data and clinical features of patients, localizations and classification of HC.

	n (%)
Sex	
Female	13 (21)
Male	38.2 (61.8)
Complaints	
Pain	27 (79.4)
Mass	2 (5.9)
Asymptomatic	5 (14.7)
Localization	
Liver	55 (90.3)
Mesenteric	2 (3.8)
Adrenal	1 (1.9)
Kidney	1 (1.9)
Spleen	1 (1)
Cyst classification	
WHO, CE1*	56 (92.1)
WHO, CE 3a	4 (7.9)

*World Health Organization, Cystic Echinococcosis type 1 and 3a

RESULTS

Thirty-two cysts were treated with PAIR. For 28 of the cysts, the intervention was performed with catheterization. After the injection of the hypertonic saline solution, 6 F (n=9) or 8 F (n=19) pigtail catheter was placed into the cavity. In 16 of these cysts, catheter was withdrawn and procedure was ended in same session (single session drainage). After placement of the catheter, it was remained to free drainage in 12 cysts. The average drainage time was 2.1 days (range, 1-4 days). Catheter was completely withdrawn when cumulative drainage was less than 10 cc daily. The mean hospitalization periods were 1 day (mean, 16 hours) for the patients treated with the PAIR technique alone, and catheter withdrawal in same session. The mean hospitalization periods were 1-4 days (mean, 2.1 days) for the catheterization-free drainage patients.

The mean follow-up was 93.6 months (range, 6–120 months). Average cyst volumes before treatment were 43.8 ± 65.2 ml for the lesions treated by the PAIR technique and 230.4 ± 197.6 ml for the lesions treated by the catheterization technique. Disappearance, significant volume loss (more than 50%), semisolid appearance (heterogeneous echo pattern) were each considered as cure parameters (Figure 1). The volume reduction of the cysts was 74.6% for treated with PAIR, 78.7% for treated with single session catheterization, and 57.9% for treated with catheterization free drainage methods. Pretreatment cyst volumes, posttreatment volume loses and statistical results were shown at table II. When the effectivity of 3 therapeutic procedures are compared by the linear regression analysis, results show the most potent method is single session drainage followed by catheterization-drainage and lastly PAIR ($p < 0.001$). Volume reduction of catheterized cysts in first month was more in freely drained catheterized cyst than others ($p < 0.001$). But

Table II: Evaluation of cyst volumes in three methods.

Method (n)	Pretreatment cyst volume (ml)	Posttreatment cyst volume (ml)	Average volume loss%	p	Time for 50 % and more volume loss (mean)
PAIR (n =32)	43.8 ± 65.2	14.3 ± 28.6	74.6	0.04	5 weeks
Single Session Catheterization (n=16)	250.3 ± 227.6	70.6 ±112.2	78.7	0.02	7 weeks
Catheterization-free drainage (n=12)	202.2 ± 150.1	78.2 ± 130.3	57.9	0.009	4 weeks

Table III: Two catheterized group’s volume analysis.

	Posttreatment cyst volume in first month (ml)	Posttreatment cyst volume in last follow-up(ml)	Average volume loss(%)	p
Single session catheterization (n=16)	140.7 ± 119.7	70.6 ± 112.2	77.2 ± 9.7	0.1
Catheterization – free drainage (n= 12)	184.2 ± 188.4	78.2 ± 130.3	66.8 ± 19.5	0.002

in last follow-up, there was no statistical difference between two catheterized groups. More time after PT led to more volume reduction and solid appearance in cysts and statistical difference was significant (Table II) (p<0.001).

During and after procedure, 5 (14.7%) patients experienced minor complications. Two (5.8 %) patients presented with mild urticaria during the procedure and responded to antihistamines. Two (5.8%) patients developed a mild fever spike at first 8 hours after intervention and responded antipyretic – analgesic treatment. In one patient (2.9%), intracavitary minor hemorrhage developed. The catheter was allowed drain freely. After 24 hours, drainage stopped and there was no residual collection. Follow-up US examination revealed resorption and cure. Two (5.8%) patients showed gastric intolerance according to oral albendazole treatment. Medication was stopped in one week and no recurrence was seen in this group. There was no anaphylactic reaction, recurrence, cavity infection, abscess and mortality due to the procedure. As major complications, two patients (5.8%) undergone re-catheterization because of insufficient cavitory volume reduction. In one patient, had 650 cc volume type CE 1 cyst treated with single session catheterization, US examination showed insufficient volume reduction and internal echoes at 3rd month control. Cyst was re – catheterized and treated with single session catheterization again. After second procedure, cyst volume reduction was more than 50% and there was no internal echo (Figure 2). In one patient (2.9%) with CE 1 cyst that was 14 cm in diameter treated with catheterization free drainage, US examination demonstrated increase of volume at 2nd year control. This 10 cm in diameter cyst was re-catheterized and biliary fistula was shown with fluoroscopic guidance. After two weeks, daily catheter drainage was less than 10 cc and catheter was withdrawn. At first month control US examination showed that diameter of cyst was 10 cm again. Cyst was re-catheterized and required endoscopic intervention (sphincterotomy, biliary stent implantation). Eventually after 2 months, the patient required surgery because the fistula was still patent.

DISCUSSION

Image-based, stage-specific approach is recommended for choosing most appropriate therapeutic modality in CH (2,4,12,13). The most important determining factor in choosing therapeutic approach is cyst type. Thus far different treatment methods are reported for active CE 1-2-3 cysts (5,12). Surgery is preferred for complicated cysts, WHO CE2 and CE3b cysts or cysts communicating with the biliary tree and have high recurrence, morbidity, mortality rates (1,2,14-17). It has been reported that, surgical morbidity in pediatric patients is 8–16%, average hospitalization time is 14–15 days (18-20).

PT is mostly preferred in properly selected patients (10,11,16). Recurrence (0–3.5%) and major complication (0–10%) rates are lower than surgical series (9,10,16,17,21-24). PT is described as first choice in inoperable patients and those who refuse surgery, in cases of relapse after surgery and, in CE1 and CE 3a cysts by WHO-IWGE specialists (4). Transhepatic approach make it strongly controlled and safe (10,14,23,25). In our study there is no seeding, anaphylactic reaction secondary to cyst rupture and peritoneal implantation and this situation shows transhepatic puncture’s priority. Medical treatment alone has been proven to be inadequate for HC but combination with PT increases success (2,14,15,25,26). There is no consensus of prophylactic anti-helminthic therapy time in the literature (27). Oral Albendazole therapy was applied 6 months after the procedure in our patients, and it is thought of that contributed to the success. Alcohol injection reduces recurrence, and should apply also considering toxic side effects (10,16,23,28,29). In this study, there is no complication secondary to alcohol, because alcohol was used after seeing no biliary communication by scopic guidance (Figure 3).

Ustunsoz et al. have reported that small cysts (6–8 cm) became solid in the catheterization group earlier than in the PAIR group. They maintained chosen percutaneous method type and cyst size was important in determining the result (10). Kabaalioglu

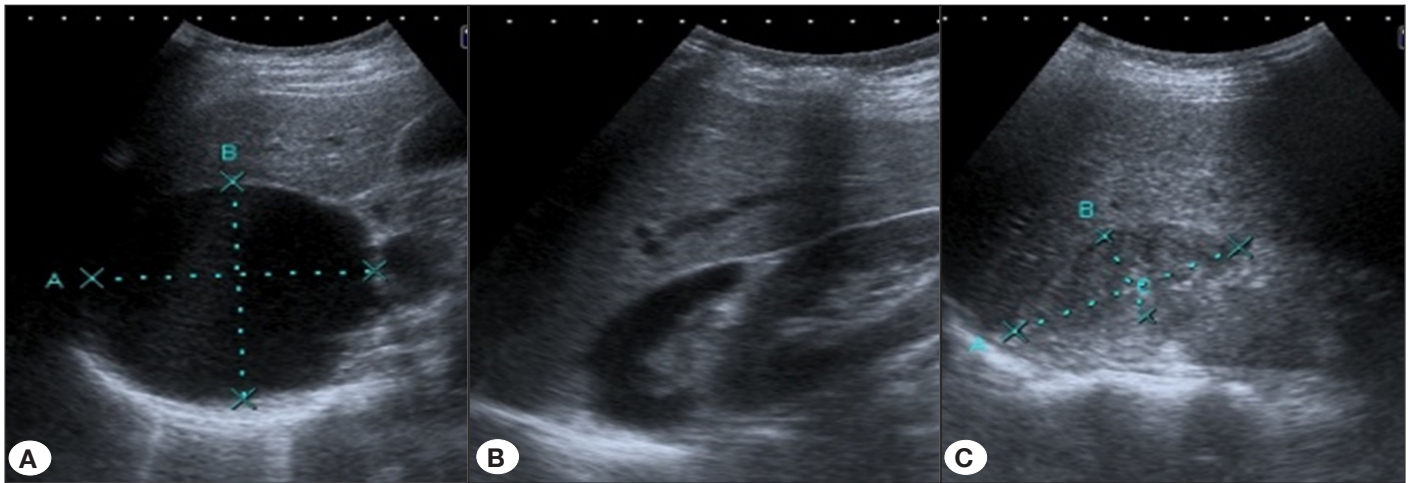


Figure 1: A 12-year-old female with WHO CE type 1 HC. **A)** US image shows the pretreatment view of the cyst. **B)** After single session catheterization; cystic component was obviously reduced, there was a volume lose more than 50 % at first month US. **C)** US image shows the semisolid apperance of the cyst at first year follow-up.

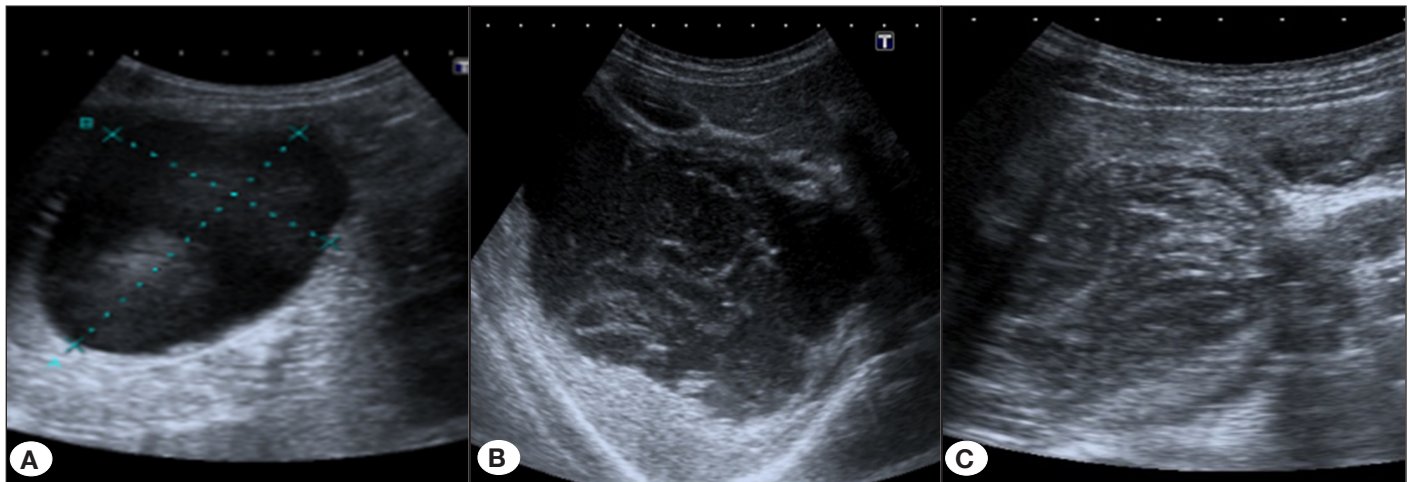


Figure 2: A 14 year-old female with WHO CE type 1 HC. **A)** US image shows the pretreatment view of the cyst. **B)** After single session catheterization; germinative membrane was detached but there was no significant volume reduction at 3rd month follow-up. **C)** After second single session catheterization, cyst was semisolid at 2nd month examination.

et al. (21) suggested that PAIR method even cysts bigger than 6 cm in diameter. In their prospective study, which compared PAIR and catheterization methods there is no difference in complication and success rates (30). Polat et al. (9) treated 120 HC with single-session catheterization, and reported significant size reduction in long-term follow-up.

There are only limited reports of PT in children (18,31,32). Dilsiz et al.(31) treated 14 HC and used only PAIR method even in cyst 11 cm in diameter with high efficacy and safety. They suggested that PAIR was adequate even in cysts bigger 6 cm in diameter. In cases with relatively large cysts, there is a known and frequent risk of needle occlusion seen in the PAIR method, due to high concentration of scoleces inserting a drainage catheter increase the effectivity, but can be a challenging way in the already uncooperative child patient, who is traumatised psycho

– socially due to illness itself. In the modern era, least invasive possible methods with the shortest durations are sought, in all but especially difficult to cooperate cases like in pediatrics. Catheterization mostly followed by free drainage for few days, is the method of choice in the cysts larger than 6 cm in diameter. In the study consisted of 51 liver HC, cysts bigger than 6 cm in diameter were catheterized and allowed drained freely (32). One day after the procedure, they applied ethanol injection under scopic guidance, accompanied by an anesthetists and sedation again. It creates need for hospitalization, adequate fixation – to prevent dislocation, which can be frequent in a restless child, and more resource utilization. Single session catheter drainage followed by removal of the tube after adequate shrinkage of the cyst, is a potential candidate to replace this method in this manner. This can decrease the costs, and increase the patient adherence, but the non – inferiority of the method is a subject to

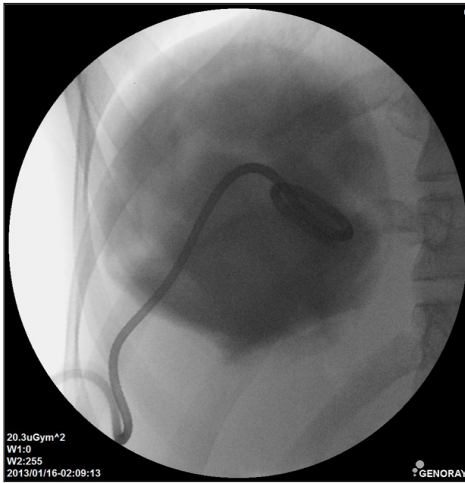


Figure 3: There was no biliary communication in cystogram.

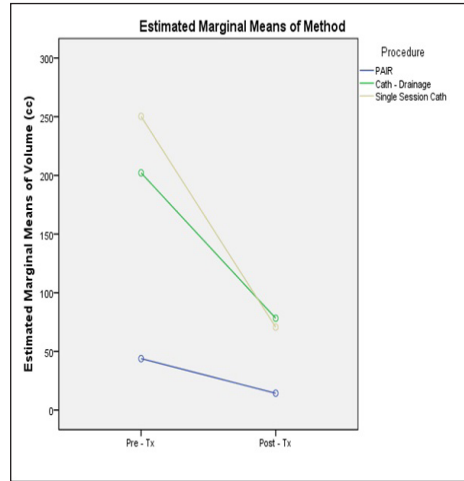


Figure 4: Linear regression analysis graph comparing the pre & post – treatment cyst volumes by 3 methods.

question in pediatric cases. In our study, cystogram and ethanol injection was applied in same session. Single session approach eliminates second sedation need. Additionally, in this group, they failed during reaspiration in 33.3% of cysts; and they could reaspirate half of the volume in 14.3% of cysts in PAIR group and volume reduction was insufficient in post-treatment first year follow-up. Post- procedure pain was main complaint in catheterization group (48.1%) (32). In our study, drainage with catheterization dissolved the problem of obstruction in needle and procedural complications. In the method of catheterization kept in cavity for freely drainage, child should be stay at hospital and catheter leads disturbance and pain. Pain is tolerated badly especially in children and young age or mental-motor retarded children can pull away the catheter. Catheter withdrawal eliminates these risks and post- procedural pain. Procedure time is shorter and it means child exposures anesthetic agents shorter.

Early volume reduction in PAIR group is considered related to pretreatment cyst volume rather than technique (Table II). Volume reduction of catheterized cysts in first month was more in freely drained catheterized cyst than others, but in last follow-up, there was no statistical difference between two catheterized groups. It was thought treatment efficacy of both catheterized groups were similar (Table III). Linear regression analysis showed, single session drainage is a more potent, at least non – inferior, PT approach than catheterization – drainage in large cysts (Figure 4).

The low number of our patients compared to adult series is one of the limitations of our study. In addition, our study is retrospective. Multi-center and prospective studies with larger number of patients are needed to compare different treatment methods.

In conclusion, in determining the percutaneous approach, size of the cyst as well as patient’s age and cooperation status are

important. In cysts less than 6 cm in diameter PAIR is usually effective, on the other hand, in larger cysts single session catheterization makes it advantageous because of convenience of approach, low pain and short hospitalization period, and non-inferior in the rate of volume reduction compared to catheterization–drainage method.

REFERENCES:

1. Brunetti E, Garcia HH, Junghanss T; International CE Workshop in Lima, Peru, 2009. Cystic echinococcosis: chronic, complex, and still neglected. *PLoS Negl Trop Dis* 2011 5:e1146.
2. Nunnari G, Pinzone M R, Gruttadauria S, Celesia BM, Madeddu G, Malaguarnera G, et al. Hepatic echinococcosis: clinical and therapeutic aspects. *World J Gastroenterol* 2012;18:1448-58.
3. Gargouri M, Ben Amor N, Ben Chehida F, Hammou A, Gharbi HA, Ben Cheikh M, et al. Percutaneous treatment of hydatid cysts (*Echinococcus granulosus*). *Cardiovasc Intervent Radiol* 1990;13:169-73.
4. Brunetti E, Kern P, Vuitton DA. Writing Panel for the WHO-IWGE. Expert consensus for the diagnosis and treatment of cystic and alveolar echinococcosis in humans. *Acta Trop* 2010;114:1-16.
5. WHO Informal Working Group. International classification of ultrasound images in cystic echinococcosis for application in clinical and field epidemiological settings. *Acta Trop* 2003; 85: 253-61.
6. Akhan O, Canyigit M, Kaya D, Koksal A, Akgoz A, Yucesoy C, et al. Long-term follow-up of the percutaneous treatment of hydatid cyst in the adrenal gland: a case report and review of the literature. *Cardiovasc Intervent Radiol* 2011; 34: 256-9.
7. Akhan O, Koroglu M. Hydatid disease of the spleen. *Semin Ultrasound CT MR* 2007; 28: 28-34.
8. Ben Amor N, Gargouri M, Gharbi HA, Ghorbel A, Golvan YJ, Hammou-Jeddi H, et al. Traitement du kyste hydatique du foie du mouton par ponction sous échographie [Treatment of hepatic hydatid cyst in sheep by echographic puncture]. *Tunis Med* 1986;64: 325-31.

9. Polat KY, Balik AA, Oren D. Percutaneous drainage of hydatid cyst of the liver: long-term results. *HPB (Oxford)* 2002;4:163-6.
10. Ustunsoz B, Akhan O, Kamiloglu MA, Somuncu I, Ugurel MS, Cetiner S. Percutaneous treatment of hydatid cysts of the liver: long-term results. *AJR Am J Roentgenol* 1999;172:91-6.
11. Khuroo MS, Wani NA, Javid G, Khan BA, Yattoo GN, Shah AH, et al. Percutaneous drainage compared with surgery for hepatic hydatid cyst. *N Engl J Med* 1997;337:881-7.
12. Gharbi HA, Hassine W, Brauner MW, Dupuch K. Ultrasound examination of the hydatid liver. *Radiology* 1981;139:459-63.
13. Turgut AT, Akhan O, Bhatt S, Dogra VS. Sonographic spectrum of hydatid disease. *Ultrasound Q* 2008; 24:17-29.
14. Kapan S, Turhan AN, Kalayci MU, Alis H, Aygun E. Albendazole is not effective for primary treatment of hepatic hydatid cysts. *J Gastrointest Surg* 2008;12: 867-71.
15. Akhan O, Yildiz AE, Akinci D, Yildiz BD, Ciftci T. Is the adjuvant albendazole treatment really needed with pair in the management of liver hydatid cysts? A prospective, randomized trial with short-term follow-up results. *Cardiovasc Intervent Radiol* 2014; 37:1568-74.
16. Odev K, Paksoy Y, Arslan A, Aygün E, Sahin M, Karaköse S, et al. Sonographically guided percutaneous treatment of hepatic hydatid cysts: Long-term results. *J Clin Ultrasound* 2000; 28: 469-78.
17. Giorgio A, Di Sarno A, De Stefano G, Farella N, Matteucci P, Scognamiglio U, et al. Percutaneous treatment of hydatid liver cyst. *Recent Pat Antiinfect Drug Discov* 2009;4:29-36.
18. Kabaalioglu A, Karaali K, Apaydin A, Melikoglu M, Sindel T, Luleci E. Ultrasound-guided percutaneous sclerotherapy of hydatid liver cysts in children. *Pediatr Surg Int* 2000; 16:346-50.
19. Celebi F, Balik AA, Salman B, Oren D. Hydatid disease in childhood. *Pediatr Surg Int* 2002; 18: 417-9.
20. Yagci G, Ustunsoz B, Kaymakcioglu N, Bozlar U, Gorgulu S, Simsek A, et al. Results of surgical, laparoscopic, and percutaneous treatment for hydatid disease of the liver: 10 years experience with 355 patients. *World J Surg* 2005; 29: 1670-9.
21. Kabaalioglu A, Ceken K, Alimoglu E, Apaydin A. Percutaneous imaging-guided treatment of hydatid liver cysts: Do long-term results make it a first choice? *European J Radiol* 2006; 59:65-73.
22. Giorgio A, de Stefano G, Esposito V, Liorre G, Di Sarno A, Giorgio V, et al. Long-term results of percutaneous treatment of hydatid liver cysts: a single center 17 years experience. *Infection* 2008; 36: 256-61.
23. Filice C, Stroselli M, Brunetti E, Colombo P, D'Andrea F. Percutaneous drainage of hydatid liver cysts. *Radiology* 1992;184:579-80.
24. Kahriman G, Ozcan N, Donmez H. Hydatid cysts of the liver in children: percutaneous treatment with ultrasound follow-up. *Pediatr Radiol* 2011;41:890-4.
25. Chai J, Menghebat, Jiao W, Sun D, Liang B, Shi J, Fu C, et al. Clinical efficacy of albendazole emulsion in treatment of 212 cases of liver cystic hydatidosis. *Chin Med J* 2002;115:1809-13.
26. Smego RA Jr, Bhatti S, Khaliq AA, Beg MA. Percutaneous aspiration-injection-reaspiration drainage plus albendazole or mebendazole for hepatic cystic echinococcosis: a meta-analysis. *Clin Infect Dis* 2003;37:1073-83.
27. Nasser-Moghaddam S, Abrishami A, Taefi A, Malekzadeh R. Percutaneous needle aspiration, injection, and re-aspiration with or without benzimidazole coverage for uncomplicated hepatic hydatid cysts. *The Cochrane Library* 2011, Issue 1 <http://www.thecochranelibrary.com>
28. Akhan O, Dincer A, Gokoz A, Sayek I, Havlioglu S, Abbasoglu O, et al. Percutaneous treatment of abdominal hydatid cysts with hypertonic saline and alcohol. An experimental study in sheep. *Invest Radiol* 1993; 28:121-7.
29. Giorgio A, Tarantino L, Francica G, Mariniello N, Aloisio T, Soccia E, et al. Unilocular hydatid liver cysts: treatment with US-guided double percutaneous aspiration and alcohol injection. *Radiology* 1992;184:705-10.
30. Akhan O, Erdogan E, Ozmen M. Comparison of the effectiveness of PAIR and catheterization techniques for the percutaneous treatment of liver hydatid cysts: a prospective randomized study. Presented at CIRSE 2004; 166:46.
31. Dilsiz A, Acikgozoglu S, Gunel E, Dağdönderen L, Köseoğlu B, Gündoğan AH. Ultrasound-guided percutaneous drainage in the treatment of children with hepatic hydatid disease. *Pediatr Radiol* 1997;27:230-3.
32. Goktay AY, Secil M, Gulcu A, Hosgor M, Karaca I, Olguner M, et al. Percutaneous treatment of hydatid liver cysts in children as a primary treatment: long-term results. *J Vasc Interv Radiol* 2005;16:831-9.