



An Asymptomatic Systemic Embolus Originating from a Thrombus with a Wide Pedicle in Ascending Aorta

Adem Güler*, Mehmet Ali Şahin*, Kıvanç Atılgan*, Mehmet Yokuşoğlu**, Ertuğrul Özal*, Mehmet Arslan*

* Gulhane Military Medical School, Department of Cardiovascular Surgery, Ankara

** Gulhane Military Medical School, Department of Cardiology, Ankara

The natural course, prognostic significance, and optimal therapy of asymptomatic thoracic aortic mural thrombi detected incidentally are not well defined in the literature. We report a case of asymptomatic thoracic aortic mural thrombi in a 64-year-old man with a history of right cerebellar infarct. The patient was treated with anticoagulation during the preoperative diagnostic work-up without any embolic complication.

Key Words: Aorta; Thromboembolism; Thrombosis.

Asendan Aortada Geniş Pediküllü Bir Trombüsten Kaynaklanan Aseptomatik Sistemik Emboli

Tesadüfen saptanan asemptomatik torasik aortik mural trombüslerin doğal seyri, prognostik önemi ve optimal tedavisi literatürde iyi tanımlanmamıştır. Sağ serebellar infarkt öyküsü olan 64 yaşında erkek hastada asemptomatik aortik mural trombüs olgusunu sunmaktayız. Hasta operasyon öncesi hazırlık safhasında antikoagülan tedaviyle embolik komplikasyon olmadan tedavi olmuştur.

Anahtar Kelimeler: Aort; Tromboembolizm; Tromboz.

Aortic mural thrombi has been accepted as a definitive clinical entity and a source of arterial thromboembolism.¹ The mural thrombi are usually located in the abdominal aorta but rarely they can occur in the thoracic aorta.² The true incidence of thoracic aortic thrombus is not known, however, in an autopsy series the incidence of mural thrombus in the nonaneurysmatic thoracic aorta was reported of 0.09%.¹ With the development of diagnostic tools such as transesophageal echocardiography the diagnosis of thoracic aortic thrombus has become more readily identified as a source of peripheral arterial emboli.

Case

A 64-year-old man, with a history of right cerebellar infarct, was admitted to neurology department with dizziness. He did not have any atherosclerotic risk factor. Color Doppler ultrasonography revealed a thrombus in the right vertebral artery causing interruption of blood flow and it was confirmed by computed tomography (Figure 1).

Computed tomographic angiography also showed a large thrombus attached to the ascending aorta with a

wide pedicle, measuring 35.4x17.1 mm (Figure 2).

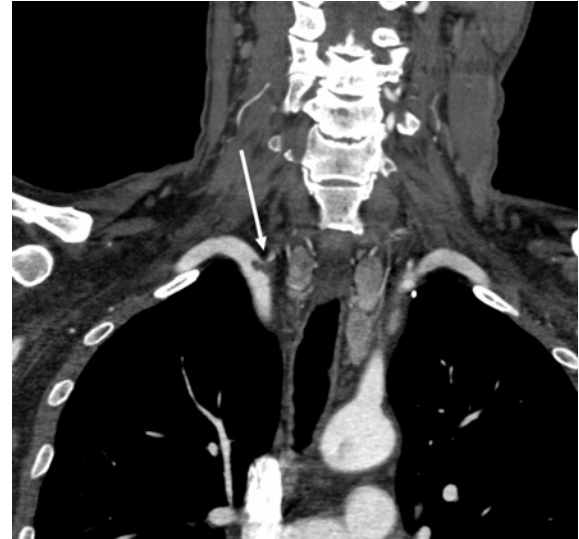

Figure 1. Thrombus located on the right subclaviovertebral arterial junction.

Başvuru Tarihi: 08.11.2010, Kabul Tarihi: 11.01.2011

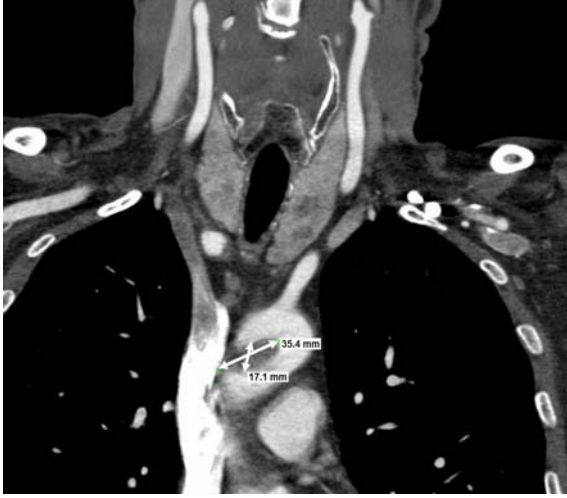

Figure 2. Thrombus with a wide pedicle located in the ascending aorta, measuring 35.4x17.1 mm

Preoperative coronary angiography was planned and anticoagulation was performed with warfarin and low molecular weight heparin. Two days later, during the coronary angiography which revealed normal coronary anatomy, we did not observe the thrombus in ascending aorta, and on the control computed tomographic angiography a remnant of the thrombus was seen in the ascending aorta, measuring 10.3 x 8.4 mm (Figure 3).

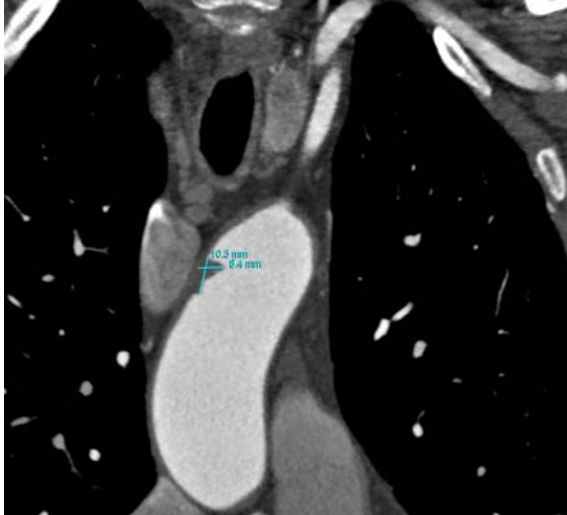


Figure 3. Remaining part of thrombus in ascending aorta on the control computed tomographic angiography, measuring 10.3x8.4 mm.

During the period of these diagnostic workup within two days the patient has free of any complaint and no positive sign of vascular pathology was present. Based on these findings the patient was discharged.

Discussion

The frequent noncardiac sources of systemic thromboembolism is mural thrombus of aorta with proximal aneurysms, ulcerated atherosclerotic plaques and rarely in patients with hypoplastic left ventricle, and after coil occlusion of patent ductus arteriosus.^{3,4} The optimal management of asymptomatic thoracic aorta mural thrombi has not been clearly established. Because of the natural history and prognostic significance of asymptomatic thoracic aorta thrombi are not known and the data regarding the treatment of thrombi presenting with peripheral arterial emboli is inconclusive, the management of these asymptomatic lesions is unclear.

When considering therapeutic options for thoracic aorta thrombi, it is necessary to take in consideration them as a heterogeneous group rather than a single entity, each having a different clinical course and prognosis depending upon its nature and etiology. In a study it is declared that a 73% incidence of embolic events among patients with pediculated and highly mobile aortic thrombi, as opposed to only 12% when those thrombi were layered and immobile.⁵ Similarly, aortic lesions can cause either macro emboli or atheroembolization (micro emboli). The later have shown to be optimally treated by surgical resection, while the former is best managed by anticoagulation.

References

1. Machleder HI, Takiff H, Lois JF, Holburt E. Aortic mural thrombus: an occult source of arterial thromboembolism. *J Vasc Surg* 1986;4:473-8.
2. Lozano P, Gomez FT, Julia J, M-Rimbau E, Garcia F. Recurrent embolism caused by floating thrombus in the thoracic aorta. *Ann Vasc Surg* 1998;12:609-11.
3. Owens ST, Gomez-Fifer C, Ensing GJ. Thrombus formation in the native aortic root in patients with hypoplastic left heart syndrome. *Pediatr Cardiol* 2006;27:385-7.
4. Villafañe J, Vega-Arrillaga F. Aortic thrombus after coil occlusion of a type E patent ductus arteriosus. *Tex Heart Inst J* 2002;29:210-2.
5. Karalis DG, Chandrasekaran K, Victor MF, Ross JJ Jr, Mintz GS. Recognition and embolic potential of intraaortic atherosclerotic debris. *J Am Coll Cardiol* 1991;17:73-8.

İletişim Adresi: Dr. Mehmet YOKUŞOĞLU, MD

Gulhane Military Medical School,
Department of Cardiology, 06010, Etilik Ankara

Tel: (312) 304 42 67

Faks: (312) 304 42 50

E-mail: myokusoglu@gata.edu.tr,

E-mail: myokusoglu@yahoo.com