



Urinary Retention Caused By a Prostatic Polyp⁺

Ali Beytur*, Emine Şamdancı**, Nurhan Şahin**, Yücel Tatar***,

* İnönü Üniversitesi Tıp Fakültesi, Üroloji Anabilim Dalı, Malatya

** İnönü Üniversitesi Tıp Fakültesi, Patoloji Anabilim Dalı, Malatya

*** Devlet Hastanesi Üroloji Kliniği, Malatya

AIM: Urinary retention is inability to voluntarily urinate. Here a young male with a prostatic polyp and caused to obstruction, has presented and as a rare cause of urinary obstruction.

CASE: 35 years old male patient visited our clinic with infravesical obstruction. Ultrasonographic and magnetic resonans imajın (MRI) investigation revealed a lesion. This lesion extending from verumontanum to the bladder neck. The polip was resected by transurethral resection. Symptoms of the patient was completely improved. The pathology result of case was reported as benign urethral polyp.

RESULT: Urinary retention is an important problems of aging males and diffent ethiologic causes are responsible Prostatik polyp, although rare, must be taken into consideration young patient with urinary retention.

Key Words: Polyp, Prostate, Urinary Retention

Prostatik Polibe Bağlı Gelişen Üriner Retansiyon

Amaç: Üriner retansiyonda idrar yapma isteği olmasına rağmen, idrar yapılamaz. Burada genç bir hastada idrar retansiyonuna neden olan prostat polibi, idrar tıkanmasının nadir bir nedeni olarak sunulmuştur.

Olgu: 35 yaşında erkek hasta infravezikal tıkanıklık ile kliniğimize başvurdu. Ultrasonografi ve manyetik rezonans incelemesinde (MRI) verumontanumdan mesane boynuna kadar uzanan polipoid bir lezyon saptandı. Transüretral rezeksiyon ile polip eksize edildi. Hastanın semptomları tamamen düzeldi. Olgunun patoloji sonucu benign üretral polip olarak rapor edildi.

Sonuç: Üriner retansiyon yaşlı erkeklerde önemli bir sorun olup etyolojide farklı nedenler vardır. Üriner retansiyonlu genç hastalarda da nadir bir neden olan prostatik polip ayırıcı tanıda unutulmamalıdır.

Anahtar Kelimeler: Polip, Prostat, Üriner Retansiyon

+Çalışmamız, 08-10 Ekim 2009 tarihlerinde İzmir'de düzenlenen 9. Uluslararası Prostat Forumu'nda poster olarak sunulmuştur.

Aim

Urinary retention is inability to voluntarily urinate. The patients with urinary retention can present with complete lack of voiding, incomplete bladder emptying or overflow incontinence. The most common causes of urinary retention are benign prostatic hyperplasia, prostatitis, cystitis, urethritis, and vulvovaginitis, anticholinergic and alphaadrenergic agonist medications and cortical, spinal, or peripheral nerve lesions.^{1,2}

Urinary retention by prostatic polyp is a rare clinical manifestation developed by inability to urine void from the bladder.^{3,4} In this report, a young male with a prostatic polyp which extending to the bladder neck and caused to complete obstruction, has been presented.

Başvuru Tarihi: 07.01.2010, Kabul Tarihi: 17.06.2010

Case

A 35 years old male patient applied to the urology clinic with a history of urination failure. He reported that he had a prostatitis four years ago, and receiving many antibiotherapy courses due to suspect of urinary infection. In the previous month, an urethral foley catheter was placed due to globe vesicale. The patient was sent to our clinic due to development of the complete urinary retention after the drawing of the catheter. In the first examination, globe vesicale was the most significant finding.

Urine flow was maintained with urethral catheterization. Urine and serum analyses were found as normal ranges. Ultrasonographic and MRI imaging revealed a 2.5 x 4.5cm cystic or polypoid lesion

extending from verumontanum to the bladder neck (Figure 1).

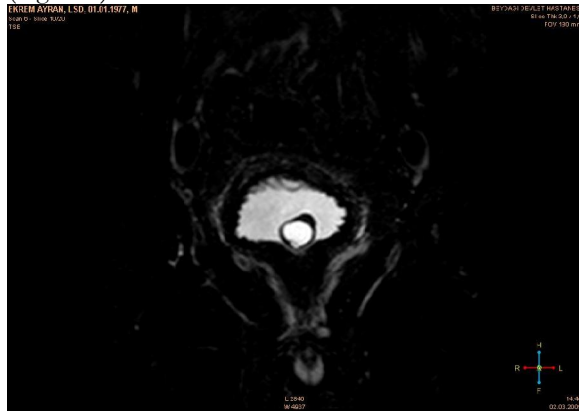

Figure 1. MRI images of the polyploid lesion.

The polypoid mass was observed during cystoscopy. Under the spinal anesthesia, a large the lesion was removed with transurethral resection. The foley catheter was drawn after one day of operation and urination was maintained with no residue urine in the bladder. In the postoperative second day, patient was discharged with no complication and one week of levofloxacin therapy.

Microscopically hematoxylin and eosin (H-E) stained sections were showed a polypoid mass with a lot of small prostatic glandular proliferation are lined by two layers of acini epithelium (Figure 2).

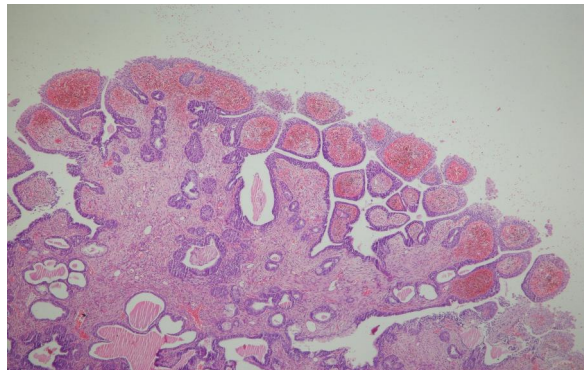


Figure 2. Both glands and papillary structures lined by prostatic epithelium (H-E X40).

Some of acini has basal cell proliferations. Immunohistochemically 34 β E12 (high-molecular-weight cytokeratin, HMWCK) was stained basal cells (Figure 3).

Histomorphologically and immunohistochemically the case was diagnosed as benign prostatic polyp. In the postoperative one month control, normal uroflowmetric parameters and complete emptying of the bladder were observed.

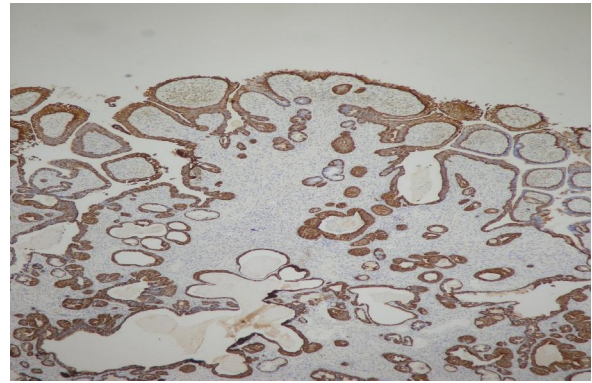


Figure 3. Basal cells showed positive staining with HMWCK (X40).

Discussion

Urinary retention is not an unusual condition and important problem of aging males. It has an increasing prevalence with the age. Men are affected than women. Urinary retention can be an acute or chronic condition that caused by an obstruction in the urinary tract or by nerve problems that interfere with signals between the brain and the bladder.^{3,4}

It routinely requires medical attention, sometimes hospitalization, for treatment, symptom relief, and detection of the underlying cause. Failure to treat the condition can lead to infections or damage to the urinary tract and kidneys.⁵ Different causes of urinary retention published in the literature. The most common cause of blockage of the urethra in men is enlargement of the prostate. Urinary infection, surgery, bladder stones, some medication can caused urinary retention. Polypoid lesions of prostate have been rarely reported in adults.⁶⁻⁸

Although the urethral polyp has been thought to be a developmental error in the invagination process of the submucous glandular material of the inner zone of the prostate.⁹

Inflammatuar processes probably caused by urinary infection might be the cause of the prostatic polyp development in our patient. Urinary retention may be considered at two different manifestations according to its pathophysiology. Acute urinary retention is the sudden and often painful inability to void despite having a full bladder and chronic urinary retention is painless retention associated with an increased volume of residual urine.³ In this report, we presented a chronic progress with urinary retention due to a polypoid lesion in the prostate. This was possibly due to growing of the lesion by the time. It is still unclear whether the urinary complaints of the patients, reported for four years, were due to this polyp or, whether the recurrent

Urinary Retention Caused By a Prostatic Polyp

urinary infection was caused the development of this lesion. Prostatic polyp, although rare, must be taken into consideration as a cause of urinary retention.

References

1. Kirby R, Lepor H. Evaluation and nonsurgical management of BPH. In: Walsh P, editor. Campbell Walsh Urology. 9th ed. Philadelphia: Saunders; 2007: 2766-802.
2. Choong S, Emberton M. Acute urinary retention. BJU Int 2000; 85: 186-201.
3. Selius BA, Subedi R. Urinary retention in adults: Diagnosis and initial management. American Family Physician 2008; 77: 643-50.
4. Lanzas P, Menendez F, Perez G, Gutierrez G, Gonzalez T, Guate O. Fibroepithelial polyp of the urethra in an adult. Actas Urol Esp 2003; 27: 654-6.
5. Jacobsen SJ, Jacobsen DJ, Girman CJ, Roberts RO, Rhodes T, Guess HA, Lieber MM. Natural history of prostatism: risk factors for acute urinary retention. J Urol 1997; 158: 481-7.
6. Kılıç S, Karadağ N, Altunoluk B, Beytur A, Karaca S. Acute Urinary Retention in an Old Male Caused By a Prostatic Urethral

Polyp. Journal of Inonu University Medical Faculty 2006; 13: 51-3.

7. Mattei FM, Giovannelli V, Del Vecchio MT, Minacci C. Congenital fibroepithelial polyp of prostatic urethra in an adult. Arch Ital Urol Androl 1998; 70: 173-5.
8. Chepurov AK, Krivoborodov GG, Raksha AP, Malenko VP, Shvarts PG. Acute urinary retention caused by urethral polyp. Urologia 2001; 2: 45-7.
9. Walsh IK, Keane PF, Herron B. Benign urethral polyps. British Journal of Urology. 1998; 72: 937-8.

Correspondence: Yrd.Doç.Dr. Ali BEYTUR
İnönü Üniversitesi Tıp Fakültesi
Üroloji Anabilim Dalı, MALATYA
İş telefonu: 0 422 342 06 60 (5802)
Cep Telefonu: 0532 620 79 96
e-mail: alibeytur@inonu.edu.tr