



# Pneumomediastinum, Pneumoperitoneum, Pneumothorax and Cervical Subcutaneous Emphysema Following Diagnostic Colonoscopy: A Case Report

Erdoğan Öztürk\*, Aytaç Yücel\*, Muhammet Gökhan Turtay\*\*, Mustafa Said Aydoğan\*,  
Demet Tekdemir\*, M. Özcan Ersoy\*

\* İnönü University Medical Faculty, Anesthesiology and Reanimation Department, Malatya, Turkey

\*\* İnönü University Medical Faculty, Emergency Department, Malatya, Turkey

**Abstract:** The use of diagnostic colonoscopy has increased recently. Colonic perforation is a rare complication during diagnostic colonoscopic procedures. This case report evaluates diagnosis, treatment and clinical presentation of a 77 year old man patient with pneumomediastinum, pneumoperitoneum, pneumothorax and cervical subcutaneous emphysema who experienced colonic perforation after diagnostic colonoscopy.

**Key Words:** Diagnostic Colonoscopy, Colonic Perforation, Pneumomediastinum, Pnömooperitoneum, Subcutaneous Emphysema

**Tanısıl Kolonoskopi Sonrası Gelişen, Pnömomediastinum, Pnömooperitoneum, Pnömotoraks ve Servikal Subkutan Amfizem Olgusu**

**Özet:** Tanısıl kolonoskopinin günümüzde kullanım sıklığı artmıştır. Ancak tanısıl kolonoskopinin uygulanması sırasında kolon perforasyonuna neden olması nadir bir komplikasyondur. Bu olgu raporu 77 yaşında diagnostik kolonoskopi sonrası iatrojenik oluşan sigmoid kolon perforasyonlu erkek hastanın klinik prezentasyonu, tanı ve tedavisini anlatmaktadır.

**Anahtar Kelimeler:** Tanısıl Kolonoskopi, Kolon Perforasyonu, Pnömomediastinum, Pnömooperitoneum, Ciltaltı Amfizem

## Introduction

Colonoscopic complications are rare but may lead to serious morbidity and mortality. If colonic perforation occurs, urgent surgical treatment should be performed. We presenta patient with pneumomediastinum, pneumoperitoneum and subcutaneous emphysema who experienced colonic perforation after diagnostic colonoscopy.

## Case Report

A 77-year-old man was admitted to the Emergency Department with a sudden onset of neck swelling. Approximately two hours prior to his admission, the patient had undergone colonoscopy.

He complained shortness of breath, hoarseness, and face swelling. The swelling, which had started on the right side of the neck, spread rapidly to involve the whole neck. The patient was admitted to the hospital and managed conservatively with cessation of oral intake, intravenous (i.v.) fluids, and i.v. antibiotics. Physical examination revealed subcutaneous emphysema of thorax, neck, head and chick. Clinical

**Başvuru Tarihi: 02.09.2009, Kabul Tarihi: 09.11.2009**

examination of the patient revealed a temperature of 36.8°C on admission, reaching 37.4°C about 1 h later. The heart rate was 110/min, and systolic blood pressure was 115, and diastolic blood pressure was 65 mmHg. The abdominal examination revealed bloating and evidence of peritonitis with hypoactive bowel sounds. In abdominal palpation sensitivity, defense and rebound were present.

Subcutaneous emphysema was observed in abdominal and cervical region. Blood tests showed a normal white cell count of  $7,8 \times 10^3/\text{mL}$  with 83% neutrophilia. Other tests including hemoglobin, platelets, urea, creatinine, electrolytes, blood glucose and liver functions were normal. A computed axial tomography scan confirmed the presence of right upper-lobe bullous emphysema (Fig. 1).

Chest X-ray showed pneumothoraces, pneumomediastinum, surgical emphysema air under the diaphragm, subcutaneous air in the neck and retroperitoneal gas delineating the psoas muscles (psoas shadow) (Fig. 2)

Considering colonic perforation after colonoscopy the patient was operated on immediately. A free infected

fluid up to 2000 mL was seen during the abdominal exploration and was aspirated. Sigmoid loop colostomy was performed. The patient was admitted to the intensive care unit with tracheal intubation. A combination of a third-generation cephalosporin and metronidazole was used to cover both aerobic and anaerobic intestinal bacteria. During the intensive care follow-up, sepsis occurred in the patient. The patient died three days after the operation.

## Discussion

We report a case of diagnostic colonoscopy in which air insufflation resulted in iatrogenic perforation with the patient developing the whole spectrum of extra-luminal air: extensive subcutaneous emphysema, pneumoperitoneum, pneumothorax and pneumoretroperitoneum.

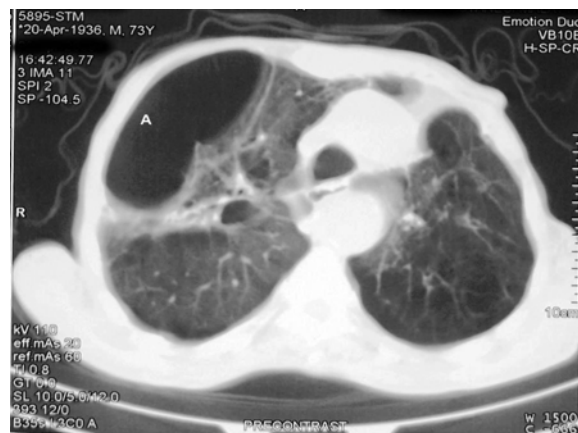Colonoscopic complications are not frequent; however, they can lead to serious morbidity and even lead to a fatal outcome. The most common complications requiring urgent surgical treatment are perforations and massive bleeding of the colon.<sup>1</sup>

This varies in frequency from 1:500 to 1:5000 and is more frequent with therapeutic procedures, particularly colonic dilatation. Other higher-risk settings include difficult colonoscopies because of colonic strictures, dense pelvic adhesions, severe diverticulosis and the potential for incarceration of the colonoscope in an inguinal or other hernia. Other complications include colonic bleeding (largely after polypectomy), splenic injury, colonic volvulus and a post-polypectomy syndrome that might be related to microperforation. There can also be complications from the bowel preparation, particularly in patients who are elderly and unwell and others with renal impairment.<sup>2</sup>

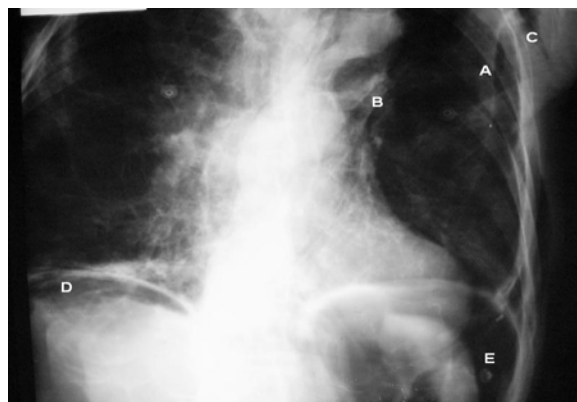
Some perforations are clinically hidden and silent (occult), and thus, often remain undiagnosed.<sup>1</sup>

Bowel perforation is a well recognized, but uncommon complication of colonoscopy. The incidence has been reported to range from 0.03% to 0.65% in diagnostic colonoscopies, and from 0.073% to 2.14% in therapeutic colonoscopies. Extracolonic gas collections that have been reported following diagnostic or therapeutic colonoscopy include pneumoperitoneum, pneumoretroperitoneum, pneumotosis cystoids coli, pneumomediastinum, pneumoscrotum and subcutaneous emphysema. Pneumothorax and pneumopericardium rarely occur.<sup>3</sup>

Air may then pass into the abdomen or thorax by a number of routes. Retroperitoneal air results either from direct retroperitoneal colonic perforation or by



**Figure 1.** Computed axial tomography scan of chest demonstrating right upper-lobe bullous emphysema (A)



**Figure 2.** Chest X-ray showing pneumothorax (A), pneumomediastinum (B), subcutaneous emphysema (C), air under the diaphragm (D) and retroperitoneal gas delineating (E) the psoas muscles (psoas shadow).

dissection of air through the colonic wall (pneumatosis coli) and subsequent passage along the mesentery to the retroperitoneum. Once in the retroperitoneum, air may travel along the fascial planes to enter the mediastinum. Subsequent rupture of the mediastinal pleura allows air to decompress into the pleural cavity and cause a pneumothorax.<sup>4</sup>

Cases with colon perforations without the presence of pneumoperitoneum are very rare, and those with the development of tension pneumothorax are even rarer.<sup>1</sup> Higher morbidity and mortality rates may be suspected due to the site of the perforation (intra or extraperitoneal) and the extent of the perforation (complete or incomplete).<sup>5</sup> Perioperative morbidity rate after colonoscopic perforations is 40%, while perioperative mortality is 8–30%, mostly due to late complications and late diagnosis.<sup>6</sup> Our case presented

## **Pneumomediastinum, Pneumoperitoneum, Pneumothorax and Cervical Subcutaneous Emphysema Following Diagnostic Colonoscopy: A Case Report**

with complete colonic perforation that resulted in mortality.

Complete intra-peritoneal perforation may be suspected by the presence of the symptoms and signs of peritonitis and presence of gas under the diaphragm. In the absence of such symptoms and signs, it seems reasonable to initiate conservative treatment in the form cessation of oral intake, i.v. fluids and i.v. antibiotics. It is important, however, to keep the patient under close observation to guard against the delayed onset of symptoms, which could take up to 9 h. Some authors add i.v. steroids to the conservative regimen while others do not. The use of steroids may mask the signs of inflammation, which could mean the termination of conservative treatment. The antibiotics used with success by different authors include a combination of kanamycin, clindamycin and penicillin, ampicillin only, or combination of cefuroxime and metronidazole.<sup>5</sup>

In our case, we used combination of ceftriaxon and metronidazole. It appears to be appropriate to use broad-spectrum antibiotic combination against aerobic and anaerobic bowel organisms.

A good outcome is anticipated if perforation is recognized early and treated promptly and effectively. The presence of appropriate by trained staff to monitor

the patient is of paramount importance in the detection of complications.

### **References**

1. Ignjatović M, Jović J. Tension pneumothorax, pneumoretroperitoneum, and subcutaneous emphysema after colonoscopic polypectomy: a case report and review of the literature. *Langenbecks Arch Surg* 2009;394(1):185-9.
2. Iser D, Ekinçi E, Baichi MM, Arifuddin RM, Maliakkal BJ. Images of interest. Gastrointestinal: complications of colonoscopy. *J Gastroenterol Hepatol* 2005;20(8):1301.
3. Webb T. Pneumothorax and Pneumomediastinum During Colonoscopy. *Anaesth Intensive Care*, 1998 J; 26(3):302-4.
4. Marwan K, Farmer KC, Varley C, Chapple KS. Pneumothorax, pneumomediastinum, pneumoperitoneum, pneumoretroperitoneum and subcutaneous emphysema following diagnostic colonoscopy. *Ann R Coll Surg Engl* 2007; 89(5):W20-1.
5. El Shallaly G, Raimes S. Cervical emphysema, pneumomediastinum, and retroperitoneum following sigmoidoscopy and rectal biopsy. *Int J Colorectal Dis*. 2005; 20(6):547-8.
6. Iqbal CW, Chun YS, Farley DR. Colonoscopic perforations: a retrospective review. *J Gastrointest Surg*. 2005 Dec; (9):1229-35.

### **Corresponding Author:**

Erdoğan ÖZTÜRK, MD

Inonu University Medical Faculty, Anesthesiology and Reanimation Department, MALATYA, TURKEY

0 422 341 06 60 / 31 10

E-mail: [ozturk@inonu.edu.tr](mailto:ozturk@inonu.edu.tr)

