



Imperforate Hymen; A Rare Cause of Urinary Retention: A Case Report

Musatafa Koç, Muammer Akyol

Fırat Üniversitesi Tıp Fakültesi Radyodiagnostik AD, Elazığ

Imperforate hymen is an uncommon obstructive anomaly of the female reproductive tract. Although it is usually sporadic, familial cases have been reported. The patient usually presents with intermittent abdominal pain. Acute urinary retention is a rare symptom. It is rarely diagnosed in the neonatal period, and most cases occur in the adolescent period. Pelvic ultrasonography is the essential initial diagnostic radiological modality to confirm the diagnosis. We report a 13 year-old girl who presented main complaint of acute urinary retention and hematocolpos diagnosed by ultrasonography due to imperforate hymen.

Key Words: Imperforate hymen, Hematocolpos, Ultrasonography,

Nadir Bir Akut Üriner Retansiyon Sebebi; İmperfore Hymen: Olgu Sunumu

İmperfore hymen kız çocuklarının üreme sisteminde nadir görülen obstrüktif bir anomalidir. Ailesel olgular bildirilmesine rağmen genellikle sporadik olarak görülür. Olgular sıklıkla aralıklı karın ağrısı şikâyeti ile başvururlar. Akut üriner retansiyon nadir bir semptomdur. Olguların çoğu adölesan dönemde tanı almakla birlikte nadiren neonatal dönemde de tanı konulabilmektedir. Pelvik ultrasonografi (US) tanıyı doğrulamak için başvurulacak ilk radyolojik yöntemdir.

Biz bu yazıda akut üriner retansiyon şikâyeti ile başvuran ve US' de imperfore hymene bağlı hematokolpos tespit edilen 13 yaşındaki kız olguyu sunduk.

Anahtar Kelimeler: İmperfore hymen, hematokolpos, ultrasonografi

Imperforate hymen is an uncommon obstructive anomaly of the reproductive tract occurring in approximately 1 in 2000 females, although accurate incidence is difficult to obtain.¹ It is usually sporadic, although familial cases have been reported.² The hymen is an embryological remnant that normally ruptures during the perinatal period. Imperforate hymen is the result of a failure of canalization of the hymen.³

The patients usually complain of intermittent and cyclical abdominal pain mainly in the lower part of the abdomen. The patients may also rarely present with acute urinary obstruction. Ultrasonography (US) is a valuable diagnostic radiological method and computed tomography (CT), magnetic resonance imaging (MRI) also can be used. The treatment of uncomplicated imperforate hymen is cruceate hymenectomy.

We report a 13 year-old girl presenting with a complaint of acute urinary retention and hematocolpos diagnosed by ultrasonography due to imperforate hymen.

CASE REPORT

A 13 year-old girl presented to our emergency department with acute urinary retention and intermittent abdominal pain in the lower abdomen. There was no history of nausea, vomiting and fever. She had no menarche. Secondary sexual characteristics were present. A suprapubic mass was detected on abdominal examination.

Pelvic ultrasonography revealed dilated vagina with dense fluid suggestive of hematocolpos (178 mm x 78 mm) (Figure 1A-B). Vesicle globe was also noted. There was no concomitant urogenital abnormalities on US. Her bladder was catheterized. Thereafter she was taken to the operating room and a cruceate hymenectomy was

performed. Postoperative US of the pelvis showed resolution of hematocolpos. She was discharged from the hospital on the following day.

Figure 1: Pelvic ultrasonography showing dense fluid in the vagina (hematocolpos) (arrows) (A-B).

Figure1A

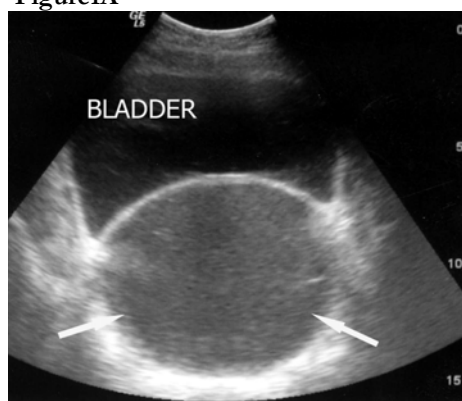
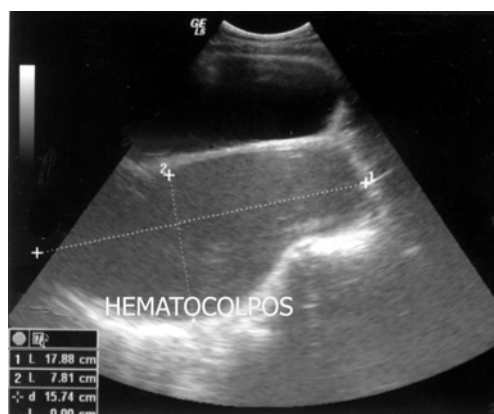

Figure1B



DISCUSSION

Imperforate hymen is an uncommon anomaly of the female reproductive tract. Embryologically, the hymen is derived from the epithelium of the urogenital sinus, and during the fetal stage it represents the distal part of vagina. An imperforate hymen is usually the result of the urogenital sinus not canalizing. It is rarely associated with other müllerian abnormalities. Thus, extensive investigation for such anomalies is often unnecessary in view of the rarity of such associations.^{3,4}

Familial cases have been reported but are more often sporadic.² It is rarely diagnosed in the neonatal period.

The patient usually presents in the teenage years. In female infants, it may present with a bulging hymen which is a mucocoele. The patient usually presents in the adolescent period with complain of lower abdominal pain, which is usually cyclical. If the condition remains undetected, retained menstrual blood collects in the vagina, causing a slow dilation from hymen to cervix; thereafter, it progresses to hematometra, and finally to hematosalpinx. Acute retention of urine is another symptom. The accumulation of menstrual blood in the vagina may result with a mechanical effect on the urethra and bladder and lead to the obstructive urinary symptoms. Acute urinary retention may be the first sign leading to a diagnosis of imperforate hymen.^{5,6} Low back pain and pelvic mass are the other symptoms.

Pelvic US is the essential initial diagnostic modality to confirm diagnosis, and it may be performed via the transabdominal, transperineal, or transrectal route. A pelvic US most often demonstrates a hematocolpos, hematometra, and possibly hematosalpinges when the diagnosis is made after the onset of menarche.⁷

The differential diagnosis of primary amenorrhea, pelvic pain, and pelvic mass in pubertal developmental stage includes transverse vaginal septum, longitudinal vaginal septum, vaginal agenesis, and cervical atresia. Magnetic resonance imaging (MRI) will demonstrate these abnormalities and is considered gold standard to diagnose female pelvic disease.⁸

The treatment for uncomplicated imperforate hymen is cruciate hymenectomy. The patients with imperforate hymen were managed using a Foley catheter as a new technique without damaging the structure of the hymen.^{9,10} This new technique is less invasive than other methods and prevents many social problems by preventing destruction of the architecture of hymen and providing annular-intact hymeneal ring.

In conclusion, the symptoms of imperforate hymen do not always suggest a gynecological disorder. Pelvic US is the essential initial diagnostic modality to confirm diagnosis. The treatment is surgical, and the prognosis is good.

REFERENCES

1. Posner JC, Spandorfer PR. Early detection of imperforate hymen prevents morbidity from delays in diagnosis. *Pediatrics* 2005; 115:1008-12.
2. Usta IM, Awwad JT, Usta JA, Makarem MM, Karam KS. Imperforate hymen: report of an unusual familial occurrence. *Obstet Gynecol* 1993; 82:655-6.
3. Moore KL, Persaud TVN. The urogenital system. In: Moore KL, Persaud TVN (eds). *The developing Human*. Philadelphia: W.B. Saunders Company 1993; 265-303.

Imperforate Hymen; A Rare Cause of Urinary Retention: A Case Report

- Edmonds DK. Normal and abnormal development of the genital tract. In: Edmonds DK (ed). Dewhurst's Textbook of Obstetrics and Gynaecology for Postgraduates. Oxford: Blackwell Science 1999; 1-11.
- Chang JW, Yang LY, Wang HH, Wang JK, Tiu CM. Acute urinary retention as the presentation of imperforate hymen. J Chin Med Assoc 2007; 70:559-61.
- Hall DJ. An unusual case of urinary retention due to imperforate hymen. J Accid Emerg Med 1999; 16:232-3.
- Atalar M, Topaktaş S, Petik B et al. Hematometrokolpos: US ve BT bulguları. C. Ü. Tıp Fakültesi Dergisi 2004; 26: 37-9.
- Burgis J. Obstructive Mullerian anomalies: Case report, diagnosis, and management. Am J Obstet Gynecol 2001; 185:338-44.
- Ali A, Cetin C, Nedim C, Kazim G, Cemalettin A. Treatment of imperforate hymen by application of Foley catheter. Eur J Obstet Gynecol Reprod Biol 2003; 106:72-5.
- Acar A, Balci O, Karataylı R, Çapar M, Colakoglu MC. The treatment of 65 women with imperforate hymen by a central incision and application of Foley catheter. BJOG 2007; 114:1376-9.

Yazışma Adresi:

Dr. Mustafa KOÇ
Fırat Üniversitesi Tıp Fakültesi,
Radyoloji Anabilim Dalı
23119 Elazığ