



Collagenous Fibroma (Desmoplastic Fibroblastoma): Different Localization. A Case Report⁺

Aylin Orgen Çallı*, Mine Tunakan*, Ayşegül Sarı*, Zuhâl Kuş*

*Department of Pathology Izmir Atatürk Training and Research Hospital

Collagenous fibroma is an extremely rare benign soft tissue tumor which arises in the subcutaneous tissue or muscle. We report a rare case of a collagenous fibroma in a 44-year-old woman who presented with a mass in the anterior chest wall. Microscopically, the tumor was hypocellular and consisted of diffuse bland spindle to stellate – shaped cells embedded in a collagenous stroma. Immunohistochemically, the tumor cells were diffusely and strongly positive for vimentin. Some cells contained alpha smooth muscle actin. They were uniformly negative for S-100 protein and CD34. After surgical excision, no recurrence or metastasis was observed during a 6 month follow-up period. A discussion of the histopathological features and a review of the literature is given.

Key Words: Collagenous fibroma, Desmoplastic fibroblastoma, Soft tissue tumors, Immunohistochemistry

Kollajenöz Fibrom (Desmoplastik Fibroblastom): Farklı Bir Lokalizasyon. Olgu Sunumu

Kollajenöz fibrom kas veya subkutan dokuda gelişen çok nadir bir yumuşak doku tümördür. Bu makalede göğüs ön duvarında kitle şikayetiyle başvuran ve kollajenöz fibrom tanısı alan 44 yaşındaki olguyu sunmayı amaçladık. Mikroskopik olarak hiposellüler tümör, kollajenöz stroma içerisinde yerleşmiş atipi göstermeyen iğsi ve yıldızlı şekilli hücrelerden oluşmakta idi. İmmunohistokimyasal olarak tümöral hücreler vimentin ile yaygın ve kuvvetli pozitif, alfa düz kas aktini ile ise fokal pozitif idi. S-100 ve CD34 boyaları ise negatif idi. Lezyonun cerrahi ekzizyonundan sonraki 6 aylık izlem döneminde rekürrens veya metastaz izlenmedi. Tümörün histopatolojik özellikleri literatürler eşliğinde tartışıldı.

Anahtar Kelimeler: Kollajenöz fibrom, Desmoplastik fibroblastom, Yumuşak doku tümörleri, İmmunohistokimya

+ Bu makale 7-11 Mayıs 2006, 18. Ulusal Patoloji Sempozyumunda poster olarak sunulmuştur.

A distinctive fibrous soft tissue tumor, originally named as desmoplastic fibroblastoma, is a benign soft tissue lesion with low cellularity, abundant collagen and large fibroblasts with reactive appearance. This tumor was first proposed by Evans in 1995 as desmoplastic fibroma and later renamed as collagenous fibroma by Nielsen et al.^{1,2} Collagenous fibroma (CF) typically arises in the subcutaneous tissue or muscle.^{1,3} Dermal involvement is rare. There is a predilection for adult males. This entity has been reported in various locations, including the upper extremities, posterior neck, upper back, lower extremities, abdominal wall and hip.⁴⁻⁷ However, few cases have been reported in the head and neck region, including three cases in the oral cavity, one case in thyroid, and one case in parotid gland.⁸⁻¹⁰ In addition, CF (desmoplastic fibroblastoma) of pectoralis minor muscle has also been reported.¹¹

We describe the clinico-pathological features of CF which arose within pectoralis major and illustrate the difficulties that may be encountered in differentiating it from other benign soft tissue tumors.

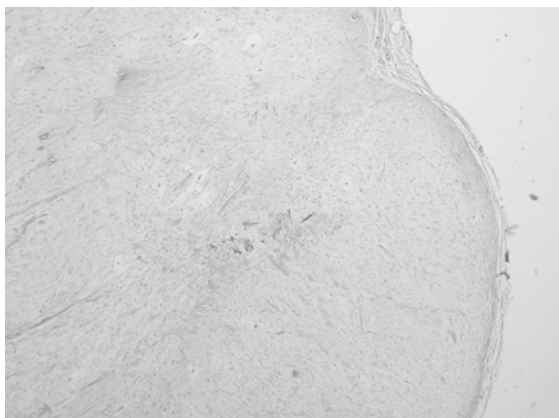
CASE REPORT

A 44-year-old woman presented with a slow-growing mass on the upper chest. She had first observed the mass 1 year previously, which gradually enlarged. Her past medical history was unremarkable. The patient underwent an excisional biopsy. The tumor was easily removed in the surgical excision. Macroscopically, the excised specimen

contained well demarcated subcutaneous mass measuring 3x2,5x1cm. The cut surface showed a yellowish-white solid tumor without necrosis.

The excised specimen was fixed in 10% neutral formalin and embedded in paraffin. Sections were stained with hematoxylin–eosin. Histologically, the tumor was well-circumscribed, hypocellular and characterized by a proliferation of large, stellate and spindle cells set in a densely fibromyxoid stroma (Figure 1,2). Small areas of the tumor had keloid-like thick bands of collagen, dispersed between the neoplastic cells. Neither cellular atypia nor mitotic figures were observed. There was no tumor necrosis. Blood vessels were scarce and inconspicuous. Immunohistochemically, spindle-to stellate –shaped tumor cells showed diffuse and intense reactivity for vimentin (Figure 3). Tumor cells were focally positive for muscle-specific actin. Immunostaining for desmin and S-100 protein were negative.

Figure 1. Low-power photomicrograph of the tumor demonstrating a well-circumscribed fibrous tumor (H&E, original magnification x40)



DISCUSSION:

CF (desmoplastic fibroblastoma) is a rare benign soft tissue tumor morphologically characterized by a hypocellular proliferation of stellate and spindle-shaped fibroblasts separated by a collagenous or myxocollagenous matrix. The tumor usually occurs in the subcutaneous tissue but approximately 25% involve skeletal muscle.⁷ The lesion presents as a firm, well circumscribed, painless mass of long duration and is commonly located in the subcutaneous tissue or skeletal muscle in adults. The tumors range in size from 1 to 20 cm. The tumors are firm and tender. There is a predilection for adult males.^{2,4-7,12} We believe that the case described here

presents similar characteristics to the one described by Evans. The tumor has a wide anatomical distribution including arms, shoulders, feet or ankles, legs and hands. Case reports in the literature indicate additional sites including thyroid and parotid glands, palate, skin, spinal epidural region and pectoralis minor (Table 1).

Figure 2. Photomicrograph illustrates hypocellular lesion, with widely spaced bland cells embedded in a fibromyxoid stroma (H&E, original magnification x200)


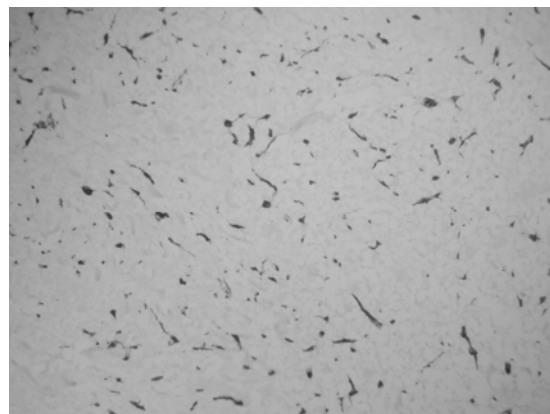


Figure 3. The cells in the tumor showed strong expression of vimentin (Immunohistochemical stain, original magnification, x100)



The differential diagnosis includes a variety of benign and low-grade lesions, predominantly fibrous lesions. CF should be differentiated from fibromatosis, which has a high risk of local recurrence when simple local excision is performed. Fibromatosis is more cellular and shows short fascicular arrangement of tumor cells and shows greater infiltration at the periphery of the lesion than CF.¹¹ By contrast, the nuclei in CFs exhibit no particular alignment or polarity and the tumor is hypocellular overall.

Collagenous Fibroma (Desmoplastic Fibroblastoma): Different Localization. A Case Report

Table 1: Clinical data on 8 patients with collagenous fibroma

Source/case no	Year of publication	Age,y/Sex	Localization	Tumor Size	Follow up
Shimayoma T et al. Case 1	2005	48/F	Palate	6 cm	No evidence of disease/ 4 year NP
Hao S et al. Case 2	2003	45/M	Pectoralis minor muscle	9.5 cm	
Mesquita et al. Case 3	2001	35/F	Palate	5cm	No evidence of disease/6month
Wilson et al. Case 4	200	88/M	Thyroid gland	4cm	No evidence of disease/a few months
Kamimura et al. Case 5	2000	20/F	Thorasic spinal epidura	NP Th5-6	No evidence of disease/4 years
Ide F et al. Case 6	1999	50/F	Parotid gland	5cm	No evidence of disease/6 years
Weisberg et al. Case 7	1999	67/M	Forehead	2cm	No evidence of disease/2month
Present case Case 8	2006	44/F	Pectoralis major muscle	3cm	No evidence of disease/6 months

NP indicates not provided

CFs may grossly mimic neurofibromas because of their well-circumscribed appearance, but they are generally negative for S100 protein immunohistochemically. Occasional tumors may show faint positivity, but always to a lesser degree than is seen in neurofibromas. In contrast to CF, neurofibroma is composed of cells with a wavy configuration which are often dispersed in a myxocollagenous stroma.^{2,5}

Calcifying fibrous pseudotumor, which affects children and young adults, is distinguished from CF by psammomatous calcifications and by the presence of lymphoplasmacytic infiltrate.¹³ Calcifications and lymphoplasmacytic infiltration were not present in the current case.

Solitary fibrous tumor is a rare mesenchymal neoplasm, primarily described in visceral pleura. Histopathologically, solitary fibrous tumors are well-circumscribed or encapsulated and composed of bland spindle cells with some hypercellular areas and myxoid to collagenized background. Areas with a hemangiopericytomatous vascular pattern and focally increased cellularity are present in some cases. Solitary fibrous tumors are much more cellular than CFs and invariably express CD34.¹⁴

Elastofibroma almost always occurs in the lower subscapular area and is characterized by elastic fibers, some of which show branching. These fibers, that are absent in CF, are highlighted with an elastin stain.⁴

Low-grade fibromyxoid sarcoma is typically more cellular than CF. Its characteristic feature is the whorling growth pattern, often seen at the transition zone. In contrast to CF, its stroma may be

hypocellular or hypercellular with areas showing myxoid change.¹⁵

Nodular fasciitis of long duration may resemble this lesion but usually is more cellular than CF. Compared to CF, nodular fasciitis usually demonstrates storiform areas, interconnecting bundles, myxoid areas or focal mucinous microcyst formation and numerous slit-like spaces. These spaces often contain erythrocytes, along with scattered lymphocytes and macrophages.^{5,6,12}

Ultrastructural studies on CF have yielded fibroblastic or myofibroblastic lineage^{2,7} and they are diploid on flow cytometry.¹⁵ Sciort et al. have recently published two such tumors with aberrations of 11q12, similar to those described for fibroma of the tendon sheath.¹⁶ However, it is still unclear if this lesion is a reactive process or a true neoplasm.

In summary, awareness and recognition of CF as a distinct pathologic entity should be emphasized due to its tendency to mimic others. In the present case, the tumor had a benign histology and surgical excision was curative. Histopathologic examination and immunohistochemical analysis may help in the diagnosis of CF and the treatment of choice is en bloc excision. Prognosis is excellent and no recurrence is expected.

REFERENCES

1. Evans HL. Desmoplastic fibroblastoma. A report of seven cases. *Am J Surg Pathol.* 1995 Sep;19(9):1077-81.
2. Nielsen GP, O'Connell JX, Dickersin GR, Rosenberg AE. Collagenous fibroma (desmoplastic fibroblastoma): a report of seven cases. *Mod Pathol.* 1996 Jul;9(7):781-5.
3. Hasegawa T, Shimoda T, Hirohashi S, et al. Collagenous fibroma (desmoplastic fibroblastoma): report of four cases and review of the literature. *Arch Pathol Lab Med.* 1998 May;122(5):455-60. Review.

4. Jang JG, Jung HH, Suh KS, Kim ST. Desmoplastic fibroblastoma (collagenous fibroma). *Am J Dermatopathol.* 1999 Jun;21(3):256-8.
5. Weisberg NK, DiCaudo DJ, Meland NB. Collagenous fibroma (desmoplastic fibroblastoma). *J Am Acad Dermatol.* 1999 Aug;41(2 Pt 2):292-4.
6. Junkins-Hopkins JM, Johnson WC. Desmoplastic fibroblastoma. *J Cutan Pathol.* 1998 Sep;25(8):450-4.
7. Miettinen M, Fetsch JF. Collagenous fibroma (desmoplastic fibroblastoma): a clinicopathologic analysis of 63 cases of a distinctive soft tissue lesion with stellate-shaped fibroblasts. *Hum Pathol.* 1998 Jul;29(7):676-82.
8. Ide F, et al. Collagenous fibroma (desmoplastic fibroblastoma) presenting as a parotid mass. *J Oral Pathol Med* 1999; 28:465-8.
9. Mesquita, R. A. et al. Collagenous fibroma (desmoplastic fibroblastoma) of the palate: a case report. *Oral Surg Oral Med Oral Pathol Oral Radiol Endod.* 2001; 91: 80-4.
10. Shimoyama T, Horie N, Ide F. Collagenous fibroma (desmoplastic fibroblastoma): a new case originating in the palate. *Dentomaxillofac Radiol.* 2005 Mar;34(2):117-9
11. Hao S, Cherian R, Templeton KJ, et al. Collagenous fibroma (desmoplastic fibroblastoma) of pectoralis minor muscle. *Orthopedics.* 2003 Dec;26(12):1227-8.
12. Allen PW. Selected case from the Arkadi M. Rywlin International Pathology Slide Seminar: desmoplastic fibroblastoma (collagenous fibroma). *Adv Anat Pathol.* 2001 Jan;8(1):23-6.
13. Fetsch CF, Montgomery EA, Meis JM. Calcifying fibrous pseudotumor. *Am J Surg Pathol* 1993;17:502-8.
14. Westra WH, Gerald WL, Rosai J. Solitary fibrous tumor. Consistent CD34 immunoreactivity and occurrence in the orbit. *Am J Surg Pathol* 1994;18:1992.
15. Huang HY, Sung MT, Eng HL, et al. Superficial collagenous fibroma: immunohistochemical, ultrastructural, and flow cytometric study of three cases, including one pemphigus vulgaris patient with a dermal mass. *Apmis* 2002; 110(4):283-9.
16. Sciot R, et al. Collagenous fibroma (desmoplastic fibroblastoma): genetic link with fibroma of tendon sheath? *Mod Pathol.* 1999;12:565-8.

Corresponding Author:

Dr.Aylin ORGEN CALLI

Izmir Atatürk Training and Research Hospital, Department of Pathology, Yeşilyurt Izmir Turkey

Tel :232 243 4343 - 2383, 2686

E-mail :calliaylin@gmail.com