



## Chilaiditi Syndrome: A Case Report

Özkan Yetkin\*, Gülseren Karabıyıkoglu\*\*

\* Department of Chest Disease, School of Medicine, Inonu University, Malatya, Turkey

\*\* Department of Chest Disease, School of Medicine, Ankara University, Ankara, Turkey

Hepatodiaphragmatic interposition of small or large intestine is known as Chilaiditi syndrome. This syndrome is a rare disease and diagnosed incidentally. Chilaiditi syndrome is typically asymptomatic, but it can be associated with symptoms ranging from intermittent, mild abdominal pain to acute intestinal obstruction, constipation, chest pain and breathlessness. We report a 54 years old woman previously misdiagnosed as pulmonary infection and gastric ulcer.

**Key Words:** Chilaiditi Syndrome, Hepatodiaphragmatic Interposition, Chest Pain

### Chilaiditi Sendromu: Olgu Sunumu

Hepatodiaphragmatik interpozisyon olarak bilinen Chilaiditi sendromu nadir rastlanan bir sendromdur. Barsak ansları diafram ve karaciğer arasında yerleşmiştir. Olguların çoğuna tesadüfen tanı konur, hafif abdominal ağrı, intestinal obstrüksiyon, göğüs ağrısı, nefes darlığı gibi semptomlarla ortaya çıkabilir. Bizim olgumuz 54 yaşında bayan hasta, daha önce solunum yolu enfeksiyonu veya peptik ülser olarak tedavi edilmiş bir olgu. Sendromun nadir görülmesi ve tipik radyolojik görünümü nedeniyle yayınlamayı uygun gördük.

**Anahtar Kelimeler:** Chilaiditi Sendromu, Hepatodiaphragmatik İnterpozisyon, Göğüs Ağrısı

Chilaiditi syndrome, first described in 1910 by a radiologist Chilaiditi, is the interposition of the right colon between the liver and the right hemi diaphragm<sup>1</sup>. This syndrome is a rare disease and has been reported sporadically. Chilaiditi syndrome is typically asymptomatic, but it can be associated with symptoms ranging from intermittent, mild abdominal pain to acute intestinal obstruction, constipation, intestinal obstruction, chest pain and breathlessness. Chilaiditi syndrome frequently occurs at the right side of colon and is seen in routine chest X-ray. Chest x-ray findings are named Chilaiditi's sign, this sign is bowel contained air interposed between diaphragm and liver. The presence of hepatodiaphragmatic interposition of the intestine requires no specific treatment in the absence of symptoms. Incidence of Chilaiditi is less than 3% of general population.<sup>2</sup> Here we report a case diagnosed via chest x-ray with Chilaiditi's sign.

### CASE REPORT

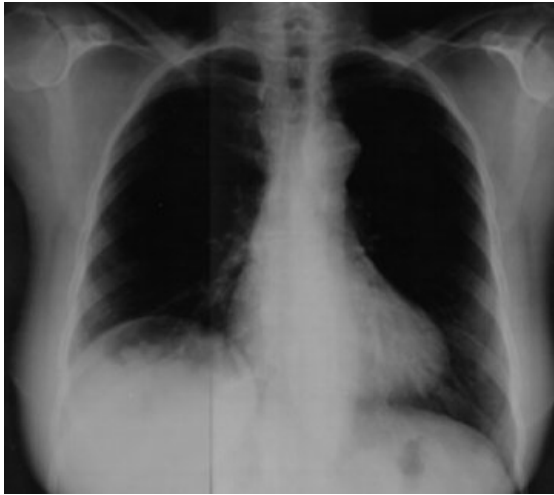
54 years old woman was admitted to the Ankara University School of Medicine, Department of Pulmonary Medicine with complaints of frequent abdominal and chest pain, cough episodes. Her symptoms began when she was 30 years old. The presenting respiratory symptoms were together with abdominal pain which occurred especially after meals. Many times this patient had been diagnosed as respiratory infection and was treated with antibiotics. Sometimes, she has been given gastric ulcer treatment. On physical examination, no pathological pulmonary findings were detected. Her abdomen was distended but no mass or organomegaly were detected on palpation. Laboratory studies, including complete blood count, blood chemistry and urine analysis were within normal ranges. The chest X-ray revealed an elevation of the right hemi diaphragm, dilated colonic loop under the right hemi diaphragm (Fig.1,2). Chilaiditi syndrome was confirmed by abdominal ultrasonographic examination.

### DISCUSSION

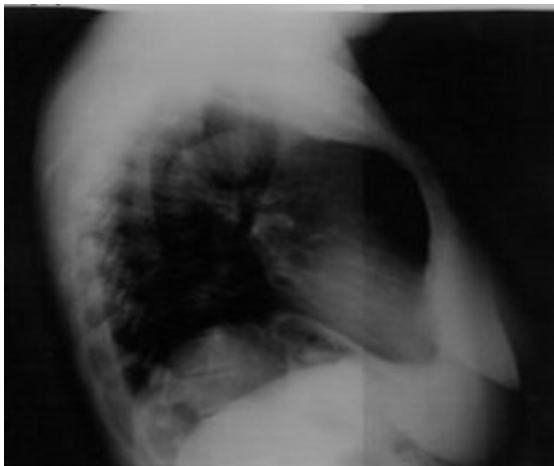
Chilaiditi syndrome, first described in 1910 by a radiologist Chilaiditi, is the interposition of the right colon between

the liver and the right hemi diaphragm<sup>1</sup>. Hepatodiaphragmatic interposition of the colon or Chilaiditi syndrome, is an uncommon disease. This syndrome is generally asymptomatic, reported as an incidental finding on chest or abdominal radiographs. The most common symptoms are nausea, anorexia, constipation, vomiting, flatulence and right upper quadrant or epigastric pain<sup>2,3</sup>. Less common are associated with respiratory distress, cardiac arrhythmias and some severe complications such as volvulus of the colon and acute intestinal obstruction. In our case, the presenting symptom was respiratory distress together with abdominal pain which occurred particularly after meals.

**Figure 1.** Chest X-ray. Colonic gas under right diaphragm



**Figure 2.** Lateral chest x-ray: colonic gas under right diaphragm



The differential diagnosis of x-ray findings include subdiaphragmatic abscess, posterior hepatic lesions, pneumoperitoneum, retroperitoneal masses and omental fat.<sup>4</sup> Diagnosis are confirmed via abdominal computerised tomographic imaging or ultrasonographic examination after x-ray.<sup>3</sup>

The treatment of Chilaiditi syndrome is generally conservative. Surgical treatment may be required in cases of intestinal obstruction<sup>5</sup>. Our patient has shown considerable improvement after the conservative treatment. We conclude that this rare entity should be included in the differential diagnosis in patients who have recurrent respiratory distress.

In conclusion, this syndrome should be kept in mind in differential diagnosis of long-standing respiratory and abdominal symptoms and/or unexplained radiological findings.

## REFERENCES

1. Chilaiditi D. Zur frage der hepatoptose und ptose im allgemein in anschluss an drei fälle von temporärer, partieller leberverlgerung. *Fortschr. Geb. Rontgenstr.* 1911;16: 173–208. (in German).
2. Sato M, Ishida M, Konno K *et al.* Chilaiditi Syndrome: sonographic findings. *Abdom. Imaging* 2000;25:397–9.
3. Plorde JJ, Raker EJ. Transverse colon volvulus and associated Chilaiditi's syndrome: case report and literature review. *Am. J. Gastroenterol.* 1996;91:2613–6.
4. Uzzau A, Anna D, Terrosu G, *et al.* Chilaiditi syndrom as a surgical and non surgical problem. *Surgery, Gynecology & Obstetrics* 1993;176:55-8
5. Saber AA, Boros MJ. Chilaiditi's syndrome: what should every surgeon know? *Am Surg.* 2005;71:261-3.

## Address for Correspondence:

Yrd.Doç.Dr.Özkan Yetkin  
Inonu University School of Medicine,  
Department of Chest Disease,  
44069, Malatya, Turkey  
E mail: ozkanyetkin@hotmail.com