

## Ileus Secondary to Pancreatic Pseudocyst : A Case Report

Süleyman Büyükberber, MD<sup>1</sup>, Kamran Mahmutyazıcıoğlu, MD<sup>2</sup>, Ertuğrul Ertaş, MD<sup>3</sup>,  
Orhan Şencan, MD<sup>1</sup>, Mustafa Şahin, MD<sup>3</sup>, Vahap Orakçı, MD<sup>3</sup>

*Intra or extrapancreatic pseudocyst is a common local complication in pancreatitis, but involvement of the colon secondary to acute and chronic pancreatitis is a rare complication. A CT scanning of a 45 year-old female with complaints of abdominal pain radiating to back and constipation for three days, was consistent with ileus resulting from compression of the pseudocyst to the transverse colon. Oral intake of the patient was stopped, and parenteral alimentation and nasogastric decompression is started. Abdominal CT scanning findings improved gradually, with resolution of the transverse colonic compression, in accordance with clinical and laboratory findings. [Turgut Özal Tıp Merkezi Dergisi 1996;3(2):124-126]*

**Key Words:** Ileus, pseudocyst, pancreatitis

### Pankreatik pseudokiste bağlı ileus : olgu sunumu

*İntra veya ekstrapankreatik pseudokistler pankreatitin sık görülen bir lokal komplikasyonudur, fakat akut veya kronik pankreatitte kolonun tutulumu nadir bir komplikasyondur. Üç gündür devam eden, sırta vuran karın ağrısı ve konstipasyonu olan 45 yaşındaki bir kadın hastanın CT'si bir pseudokistin transvers kolona basısına bağlı ileusla uyumluydu. Hastanın oral alımı durduruldu ve parenteral alimentasyon ve nazogastrik dekompresyon yapıldı. Transvers kolona bası düzelirken, klinik ve laboratuvar bulgularıyla uyumlu olarak CT bulguları da tedrici olarak düzeldi. [Journal of Turgut Özal Medical Center 1996;3(2):124-126]*

**Anahtar Kelimeler:** İleus, pseudokist, pankreatit

Intra or extrapancreatic pseudocyst is a common local complication in pancreatitis (1,2). Pathological involvement of the colon secondary to acute and chronic pancreatitis is a rare complication of major clinical interest. Contiguity with the tail of the pancreas and certain anatomical relationships, particularly at the level of the peritoneal reflections, explain the involvement of, particularly, the left flexure of the colon and the adjacent part of the transverse colon. We report a patient, presenting with ileus resulting from pressure of a giant pseudocyst secondary to acute pancreatitis, to share the diagnostic and

chronologic follow-up CT scanning findings of this rare complication.

**CASE:** A 45 year-old female was admitted to our clinic with complaints of abdominal pain radiating to back and constipation for three days. On physical examination, she was normotensive. There were abdominal distension, no bowel sounds, and an epigastric mass.

On laboratory examination, her amylase and lipase levels were 438 U/L (60-290), 435 U/L (0-190) respectively and other biochemical parameters, CBC, urinalysis, chest X-ray and ECG findings were normal. Upright abdominal X-

<sup>1</sup> Department of Internal Medicine, İnönü University, School of Medicine, Malatya

<sup>2</sup> Department of Radiology, İnönü University, School of Medicine, Malatya

<sup>3</sup> Department of General Surgery, İnönü University, School of Medicine, Malatya

rays revealed air-fluid levels. On CT scanning of the abdomen, there was a cystic, lobulated and irregular fluid collection which started from the neck of the pancreas and lied to the cauda, compressing the transverse colon and elevating the anterior abdominal muscles. There were also mesenteric cysts adjacent to the head of the pancreas and duodenum. The walls of these cysts enhanced with i.v contrast. There was dilatation on proximal portion of the compressed transverse colon and air-fluid levels were seen in segments of small intestine (Figure 1).

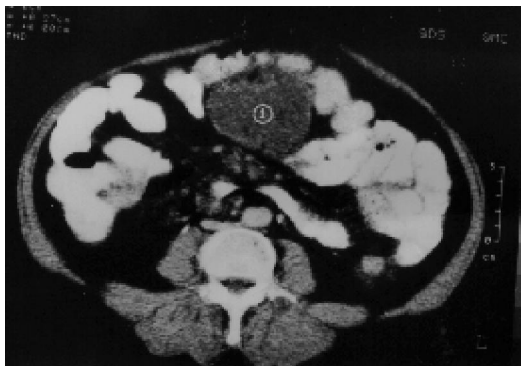
These findings were thought to be consistent with ileus resulting from compression of the pseudocyst to the transverse colon. Oral intake of the patient was stopped, and parenteral alimention and nasogastric decompression were started. The abdominal findings improved on 4<sup>th</sup> day and nasogastric tube was withdrawn. Oral intake was restarted on 7<sup>th</sup> day. Serum amylase and lipase levels were decreased gradually and every other day measurements were found to be 438, 398, 255, 220, 153, 69 U/L and 435, 429, 424, 414, 405, 324 U/L respectively. Abdominal CT scanning findings were also improved gradually, with resolution of the transverse colonic compression, in accordance with clinical and laboratory findings (Figure 2).

## DISCUSSION

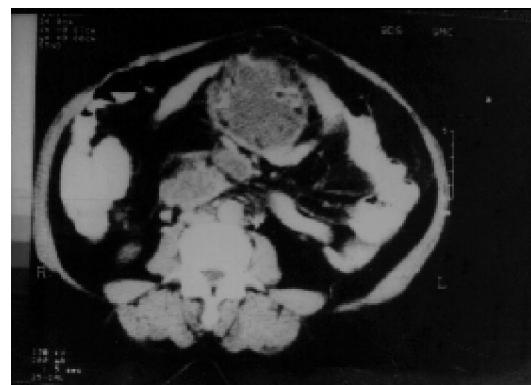Pathological involvement of the colon secondary to acute and chronic pancreatitis is a rare complication of clinical interest. Contiguity with

the tail of the pancreas and certain anatomical relationships, particularly at the level of the peritoneal reflections, explain the involvement of the left flexure of the colon and the adjacent part of the transverse colon. The clinical forms may be listed as follows: 1) Adynamic ileus of the transverse colon associated, on direct radiological examination, with the picture of proximal colon distention with clear-cut interruption at the level of the transverse colon or left flexure, 2) Stenosis of the left flexure due to pericolicitis and to the fibrosclerosing process that may take in other contiguous organs also. 3) Fistula of the left flexure or on the adjacent part of the transverse colon due to parietal necrosis and vascular impairment (3). Commonly, 80% of the pseudocysts were smaller than 6 cm, 46% were in the range from 2 to 6 cm, and 34% were smaller than 2 cm (4). In addition to these possible mechanisms, this very large pseudocyst caused this ileus by direct mechanical effect in our case.

In fact, diagnosis and management of pseudocysts of the pancreas often present difficult clinical problems. Owing to advances in pancreatic imaging, cystic lesions of the pancreas are being recognized with increasing frequency. Computed tomography (CT) is the best overall imaging modality in the clinical evaluation of acute pancreatitis. It can detect complications such as phlegmenous extension outside the gland, abscess, and pseudocyst formation and hemorrhage. CT is the imaging modality of choice in clinically severe pancreatitis of patients representing diagnostic dilemmas or failing responds to conservative therapy and in patients with suspected complications (1,2,4-6). Pancreatic necrosis can be



**Figure 1.** CT scanning of the abdomen; demonstrates dilatation on proximal portion of the compressed transverse colon on 1<sup>st</sup> day.



**Figure 2.** CT scanning of the abdomen; demonstrates resolution of the transverse colonic compression on 7th day.

diagnosed with the use of dynamic CT scanning after the rapid bolus injection of iodinated contrast media. The information gathered can be used to guide clinical management and provide anatomic detail for percutaneous aspiration and drainage or surgical intervention when indicated (1,5,6). Sensitivity in detection of cysts based on intraoperative findings (gold standart) was 98% for CT, and 94% for ultrasonography (4). MRI was also equivalent to CT in assessing the location and extent of peripancreatic inflammatory changes and fluid collection (7). The value of the CT scanning in diagnosis and follow-up is also shown as seen from the presented figures.

## REFERENCES

1. Mainwaring R, Kern J, Schenk WG 3d, Rudolph LE. Differentiating pancreatic pseudocyst and pancreatic necrosis using computerized tomography. *Ann Surg* 1989; 209(5): 562-67.
2. Jones DR, Vaughan RA, Timberlake GA. Pancreatic pseudocyst: diagnosis and management. *South Med J* 1992; 85 (7): 729-34.
3. Benedetti Valentini G, Sciutti S, Mariani E, Bartocci M, Minciotti E, Furios P. Lesions of the colon secondary to pancreatitis. *Minerva Chir* 1981; 36 (3): 143-50.
4. Mayer D, Malfertheiner P, Kemmer TP, Stanescu A, Kuhn K, Buchler M, Ditschuneit H. The value of ultrasound and computerized tomography in detection of cystic changes in chronic pancreatitis. *Z Gastroenterol* 1992; 30 (10): 709-12.
5. Marincek B. Predictive value of tomographic images in pancreatic diseases. *Schweiz Rundsch Med Prax* 1994; 83 (29-30): 823-27.
6. Hill MC, Huntington DK. Computed tomography and acute pancreatitis. *Gastroenterol Clin North Am* 1990; 19(4): 811-42.
7. Saifuddin A, Ward J, Ridgway J, Chalmers AG. Comparison of MR and CT scanning in severe acute pancreatitis: initial experiences. *Clin Radiol* 1993; 48 (2): 111-6.

## Corresponding Address:

Yrd.Doç.Dr. Süleyman BÜYÜKBERBER  
İnönü Üniversitesi Tıp Fakültesi  
İç Hastalıkları ABD  
44100 MALATYA