

## Focal fatty deposits of the liver simulating metastatic disease

Mustafa ÜNAL\*, M.D., Cihangir EREM\*\*, M.D., Kemal SERÇE\*, M.D., Ömer İLELİ\*\*, M.D.

*Diagnosis of focal hepatic fatty lesions mimicking metastases is often difficult on ultrasound(US) images. Focal fatty infiltration has increased echogenity on US images, and low attenuation on computed tomographic(CT) images, potentially mimicking focal metastatic masses. We reported this case having a focal increased echogenity on US images and a suspicious zone of decreased attenuation on CT scans and normal T2-weighted (magnetic resonance)MR images and, slightly increased signal intensity on T1-weighted MR images. [Journal of Turgut Özal Medical Center 2(2):196-198,1995]*

**Key Words:** Fatty deposits, liver, ultrasound, MRI

### **Metastatik hastalığa benzeyen karaciğerdeki fokal yağlı odaklar**

*Metastaza benzeyen karaciğerin fokal yağlı lezyonlarının tanısı, ultrason (US) ile sıklıkla zordur. Fokal yağlı infiltrasyon US'de ekojenite artışı ve bilgisayarlı tomografide (BT) düşük dansitede alanlar olarak görülür ve potansiyel olarak fokal metastatik kitlelere benzer. Biz US'de fokal artmış ekojenite, BT'de şüpheli azalmış dansitede şüpheli saha, T2 ağırlıklı manyetik rezonans (MR) görüntülerinde normal, T1 ağırlıklı MR görüntülerinde hafif artmış sinyal yoğunluğu gösteren vakayı rapor ettik. [Turgut Özal Tıp Merkezi Dergisi 2(2):196-198,1995]*

**Anahtar Kelimeler:** Yağlı odaklar, karaciğer, US, MR.

### **Case report**

Radiologic assessment of liver tumor suspects is commonly complicated by the coexistence of other abnormalities in the substrate of the liver parenchyma. These may be focal or diffuse, neoplastic or metabolic, and related or unrelated to the neoplasm being evaluated<sup>1</sup>.

A 64-year-old man with right upper quadrant pain and normal liver function tests was found on sonograms to have multiple discrete echogenic foci within the anteromedial, subcapsular localized of right lobe of the liver. He had with diabetes mellitus and had been underwent prostatic surgery before 5 years.

Fatty metamorphosis of the liver causes diagnostic problems and often requires correlation of several imaging techniques to resolve. Focal areas of

normal liver may be spared of fat and retain their normal higher CT density and thus simulate metastatic deposits<sup>2</sup>.

Several reports have described focal fatty deposits with a rounded shape and sharp margins almost indistinguishable from metastatic disease<sup>3</sup>. Fatty liver is most commonly associated with alcoholism and also can be seen in patients with diabetes mellitus, obesity, as a complication of intravenous hyperalimentation, in patients who are receiving hepatotoxic drugs, and in patients with hepatitis. The only predisposing condition in our case was diabetes mellitus.

Focal fatty deposits are often multiple and may enlarge or regress. A typical location is adjacent to the fissure for the falciform ligament as our case. MR, although generally insensitive to diffuse hepatic fat on conventional sequences, may show these focal

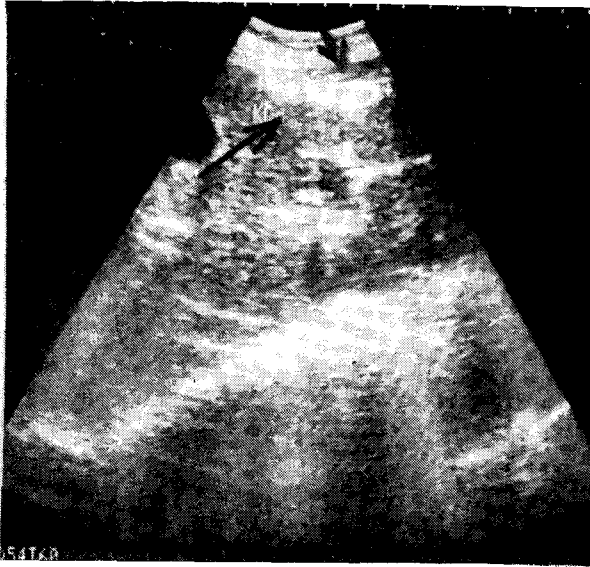
\* : Karadeniz Technical University Faculty of Medicine Departments of Radiology - Trabzon

\*\* : Karadeniz Technical University Faculty of Medicine Departments of Internal Medicine - Trabzon

\*\*\* : Karadeniz Technical University Faculty of Medicine Departments of General Surgery - Trabzon

fatty deposits to have typical short T1 bright signal<sup>4</sup>. Conventional SE images are relatively insensitive to mild or moderate fatty infiltration. A suspicious zone of decreased attenuation seen on a CT scan is likely to represent focal fatty infiltration if it appears normal on T2-weighted MR images, especially if the area has slightly increased signal intensity on T1-weighted images as our case. The level of accuracy of this method of diagnosis focal fat is likely to be unsatisfactory, however, since it relies on not seeing something<sup>5</sup>.

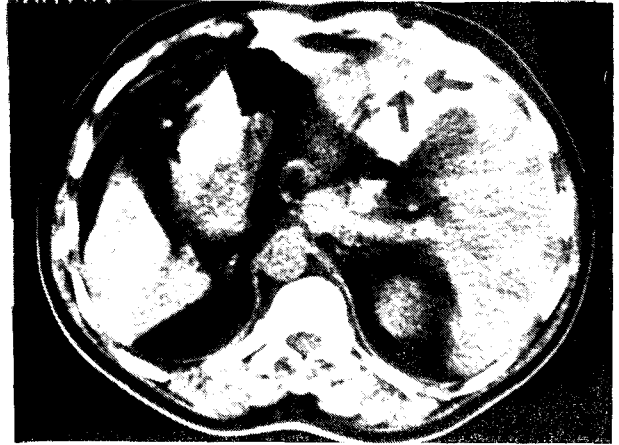
Although metastatic disease is the most common cause of multiple, discrete liver lesions, focal fatty infiltration should be considered, especially in patients with a predisposing condition.



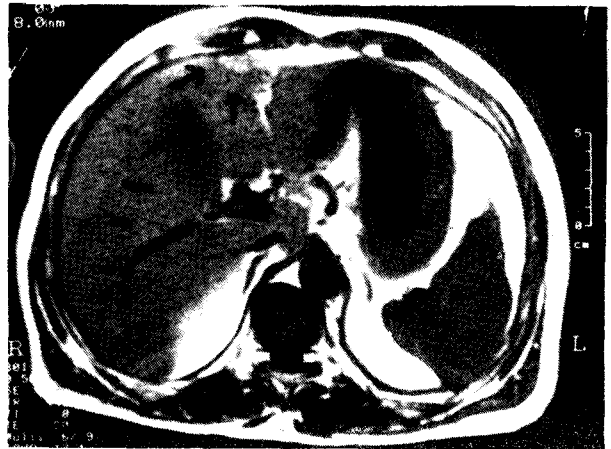
**Figure 1.** Ultrasound images revealed focal increased echogenicity within the anteromedial, subcapsular localized of right lobe of the liver.

## REFERENCES

1. Ferrucci JT. Staging Neoplasms: Liver tumor imaging (current concepts). *Radiol Clin North Am* 1993;32:39-53.
2. Halvorsen RA, Korobkin M, Ram PC, et al. CT appearance of focal fatty infiltration of the liver. *AJR* 1982;139:277-81.



**Figure 2.** A suspicious zone of decreased attenuation on a CT scan.



**Figure 3.** Slightly increased signal intensity on a T1-weighted MR image.

3. Kahnens YC, Streight YA. Focal fatty infiltration of the liver simulating metastatic disease. *Radiology* 1986;159:83-4.

4. Lee JKT, Dixon WT, Ling D, et al. Fatty infiltration of the liver: demonstration by proton spectroscopic imaging. *Radiology* 1984;153:195-201.
5. Mitchell DG. Hepatic imaging : techniques and unique applications of magnetic resonance imaging. *Magn Reson Q* 1993;9:84-112.

**Correspondence address :** Mustafa ÜNAL, M.D.,  
Assistant Professor, Department of Radiology,  
Faculty of Medicine,  
Karadeniz Technical University  
TRABZON